

Pheochromocytoma is Characterized By Catecholamine Myocarditis, Focal and Diffuse Fibrosis, and Persistent Subclinical Systolic and Diastolic Dysfunction

Ferreira, Vanessa; Marcelino, Mafalda; Piechnik, Stefan; Marini, Claudia; Karamitsos, Theodoros; Ntusi, Ntobeko; Francis, Jane; Robson, Matthew; Arnold, Ranjit; Mihai, Radu; Thomas, Julia; Herincs, Maria; Hassan-Smith, Zaki; Greiser, Andreas; Arlt, Wiebke; Korbonits, Marta; Karavitaki, Niki; Grossman, Ashley; Wass, John; Neubauer, Stefan

DOI:

[10.1016/j.jacc.2016.03.543](https://doi.org/10.1016/j.jacc.2016.03.543)

License:

Creative Commons: Attribution (CC BY)

Document Version

Publisher's PDF, also known as Version of record

Citation for published version (Harvard):

Ferreira, V, Marcelino, M, Piechnik, S, Marini, C, Karamitsos, T, Ntusi, N, Francis, J, Robson, M, Arnold, R, Mihai, R, Thomas, J, Herincs, M, Hassan-Smith, Z, Greiser, A, Arlt, W, Korbonits, M, Karavitaki, N, Grossman, A, Wass, J & Neubauer, S 2016, 'Pheochromocytoma is Characterized By Catecholamine Myocarditis, Focal and Diffuse Fibrosis, and Persistent Subclinical Systolic and Diastolic Dysfunction', *Journal of the American College of Cardiology*, vol. 67, no. 20, pp. 2364–2374. <https://doi.org/10.1016/j.jacc.2016.03.543>

[Link to publication on Research at Birmingham portal](#)

General rights

Unless a licence is specified above, all rights (including copyright and moral rights) in this document are retained by the authors and/or the copyright holders. The express permission of the copyright holder must be obtained for any use of this material other than for purposes permitted by law.

- Users may freely distribute the URL that is used to identify this publication.
- Users may download and/or print one copy of the publication from the University of Birmingham research portal for the purpose of private study or non-commercial research.
- User may use extracts from the document in line with the concept of 'fair dealing' under the Copyright, Designs and Patents Act 1988 (?)
- Users may not further distribute the material nor use it for the purposes of commercial gain.

Where a licence is displayed above, please note the terms and conditions of the licence govern your use of this document.

When citing, please reference the published version.

Take down policy

While the University of Birmingham exercises care and attention in making items available there are rare occasions when an item has been uploaded in error or has been deemed to be commercially or otherwise sensitive.

If you believe that this is the case for this document, please contact UBIRA@lists.bham.ac.uk providing details and we will remove access to the work immediately and investigate.

Download date: 01. Feb. 2019



Pheochromocytoma Is Characterized by Catecholamine-Mediated Myocarditis, Focal and Diffuse Myocardial Fibrosis, and Myocardial Dysfunction

Vanessa M. Ferreira, SB, MD, DP_{HLL},^a Mafalda Marcelino, MD,^b Stefan K. Piechnik, DSc, PhD, MS_{CEE},^a Claudia Marini, MD,^a Theodoros D. Karamitsos, MD, PhD,^a Ntobeko A.B. Ntusi, DP_{HLL},^a Jane M. Francis, DCR(R), DNM,^a Matthew D. Robson, PhD,^a J. Ranjit Arnold, MBChB, DP_{HLL},^a Radu Mihai, MD, PhD,^c Julia D.J. Thomas, MBBS, PhD,^d Maria Herincs, MD,^d Zaki K. Hassan-Smith, MBBS, BM_{EDSci}, PhD,^{e,f} Andreas Greiser, PhD,^g Wiebke Arlt, MD, DSc,^{e,f} Márta Korbonits, MD, PhD,^d Niki Karavitaki, MSc, PhD,^{b,e,f} Ashley B. Grossman, BA, BSc, MD,^b John A.H. Wass, MD, MA,^b Stefan Neubauer, MD^a

ABSTRACT

BACKGROUND Pheochromocytoma is associated with catecholamine-induced cardiac toxicity, but the extent and nature of cardiac involvement in clinical cohorts is not well-characterized.

OBJECTIVES This study characterized the cardiac phenotype in patients with pheochromocytoma using cardiac magnetic resonance (CMR).

METHODS A total of 125 subjects were studied, including patients with newly diagnosed pheochromocytoma (n = 29), patients with previously surgically cured pheochromocytoma (n = 31), healthy control subjects (n = 51), and hypertensive control subjects (HTN) (n = 14), using CMR (1.5-T) cine, strain imaging by myocardial tagging, late gadolinium enhancement, and native T₁ mapping (Shortened Modified Look-Locker Inversion recovery [ShMOLLI]).

RESULTS Patients who were newly diagnosed with pheochromocytoma, compared with healthy and HTN control subjects, had impaired left ventricular (LV) ejection fraction (<56% in 38% of patients), peak systolic circumferential strain (p < 0.05), and diastolic strain rate (p < 0.05). They had higher myocardial T₁ (974 ± 25 ms, as compared with 954 ± 16 ms in healthy and 958 ± 23 ms in HTN subjects; p < 0.05), areas of myocarditis (median 22% LV with T₁ >990 ms, as compared with 1% in healthy and 2% in HTN subjects; p < 0.05), and focal fibrosis (59% had nonischemic late gadolinium enhancement, as compared with 14% in HTN subjects). Post-operatively, impaired LV ejection fraction typically normalized, but systolic and diastolic strain impairment persisted. Focal fibrosis (median 5% LV) and T₁ abnormalities (median 12% LV) remained, the latter of which may suggest some diffuse fibrosis. Previously cured patients demonstrated abnormal diastolic strain rate (p < 0.001), myocardial T₁ (median 12% LV), and small areas of focal fibrosis (median 1% LV). LV mass index was increased in HTN compared with healthy control subjects (p < 0.05), but not in the 2 pheochromocytoma groups.

CONCLUSIONS This first systematic CMR study characterizing the cardiac phenotype in pheochromocytoma showed that cardiac involvement was frequent and, for some variables, persisted after curative surgery. These effects surpass those of hypertensive heart disease alone, supporting a direct role of catecholamine toxicity that may produce subtle but long-lasting myocardial alterations. (J Am Coll Cardiol 2016;67:2364-74) © 2016 by the American College of Cardiology Foundation.



Listen to this manuscript's audio summary by JACC Editor-in-Chief Dr. Valentin Fuster.



From the ^aOxford Centre for Clinical Magnetic Resonance Research, Division of Cardiovascular Medicine, Radcliffe Department of Medicine, University of Oxford, John Radcliffe Hospital, Oxford, United Kingdom; ^bDepartment of Endocrinology, Oxford Centre for Diabetes, Endocrinology & Metabolism (OCDEM), Churchill Hospital, University of Oxford, Oxford, United Kingdom; ^cDepartment of Surgery, Oxford University Hospitals NHS Foundation Trust, Oxford, United Kingdom; ^dDepartment of Endocrinology, Barts and the London School of Medicine, Queen Mary University of London, London, United Kingdom; ^eInstitute of

Pheochromocytomas are rare neuroendocrine catecholamine-secreting tumors originating from chromaffin cells within the adrenal medulla or extra-adrenal paraganglia, with an annual incidence of approximately 0.8/100,000 person-years (1-3). Catecholamine-induced cardiovascular complications carry a high risk of morbidity and mortality and may include hypertensive crisis, stroke, aortic dissection, myocardial infarction (MI), arrhythmia, and heart failure (4-6). Various cardiac pathologies have been described, including cardiac hypertrophy, stress-induced cardiomyopathy, myocarditis, systolic and diastolic dysfunction, and dilated cardiomyopathy (4-7). Further, catecholamines have been shown to influence the extracellular matrix with collagen deposition and subsequent fibrosis in the myocardium (6,8). These changes are beyond hypertensive effects alone, mediated by catecholamines via stimulation of myocardial alpha- and beta-adrenoceptors (9,10) or as a direct toxic effect on myocytes (11-14).

SEE PAGE 2375

Due to the condition's rarity, studies of cardiac pathology in pheochromocytoma are mostly limited to case reports or series (1), and the true underlying phenotype is not well-described. Few clinical studies have fully characterized cardiac involvement in patients with pheochromocytoma, with most employing electrocardiography or echocardiography, which are limited by the lack of myocardial tissue characterization; thus, the true extent of myocardial involvement is unknown.

Cardiac magnetic resonance (CMR) is ideal for examining the heart in pheochromocytoma due to its multiparametric capabilities for myocardial tissue characterization. It provides an accurate and reproducible method for left ventricular (LV) anatomy, cardiac indexes, and regional and global function. Tagged CMR measures myocardial strain parameters and detects subtle systolic and diastolic dysfunction. Late gadolinium enhancement (LGE) imaging allows

visualization of the type and distribution of ischemic versus nonischemic type focal fibrosis. There have been 2 case reports demonstrating the utility of CMR in detecting catecholamine myocarditis in pheochromocytoma (15,16). Most recently, CMR T_1 mapping, on the basis of measurement of the magnetic property myocardial T_1 (or the proton spin-lattice relaxation) times on a pixel-by-pixel basis, has proven to be a robust tool sensitive to myocardial inflammation and diffuse fibrosis in a variety of cardiac conditions (17,18). Thus, CMR provides a comprehensive means to characterize the cardiac phenotype in pheochromocytoma.

We performed the first prospective, systematic study to determine the extent of cardiac involvement in patients with pheochromocytoma using CMR. We hypothesized that cardiac involvement would be common and detectable using advanced tissue characterization techniques.

METHODS

This was a prospective study including 125 subjects: 60 patients with a new ($n = 29$) or previous ($n = 31$) diagnosis of pheochromocytoma, without known cardiovascular disease; 51 healthy control subjects (age- and sex-matched), and 14 patients with essential hypertension. Patients with pheochromocytoma were recruited from 3 hospitals in the United Kingdom: 1) Department of Endocrinology, Oxford Centre for Diabetes, Endocrinology and Metabolism, Churchill Hospital, Oxford; 2) Department of Endocrinology, Barts and the London School of Medicine, Queen Mary University of London; and 3) Department of Endocrinology, Queen Elizabeth Hospital, University Hospitals Birmingham NHS Foundation Trust, Birmingham. Patients underwent CMR at the University of Oxford Centre for Clinical Magnetic Resonance Research, John Radcliffe Hospital between

ABBREVIATIONS AND ACRONYMS

CMR = cardiac magnetic resonance
IQR = interquartile range
LGE = late gadolinium enhancement
LV = left ventricular
LVEF = left ventricular ejection fraction
LVH = left ventricular hypertrophy

Metabolism and Systems Research, University of Birmingham, Birmingham, United Kingdom; ⁵Centre for Endocrinology, Diabetes and Metabolism, Birmingham Health Partners, Birmingham, United Kingdom; and the ⁶Siemens Healthcare GmbH, Erlangen, Germany. This study, Dr. Ferreira, and Dr. Piechnik are funded in part by the National Institute for Health Research (NIHR) Oxford Biomedical Research Centre at The Oxford University Hospitals NHS Foundation Trust and the University of Oxford. Dr. Ferreira has received funding from the Alberta Innovates Health Solutions Clinical Fellowship and the University of Oxford Clarendon Fund Scholarship. Drs. Piechnik and Robson have 2 pending U.S. patents: 61/387,591, systems and methods for shortened look locker inversion recovery (sh-molli) cardiac gated mapping of T_1 , all rights sold exclusively to Siemens Medical Solutions; and 61/689,067, color map design method for immediate assessment of the deviation from established normal population statistics and its application to cardiovascular T_1 mapping images. Dr. Greiser is an employee of Siemens Healthcare GmbH. Dr. Neubauer has received support from the British Heart Foundation Centre of Research Excellence, Oxford. All other authors have reported that they have no relationships relevant to the contents of this paper to disclose. Drs. Wass and Neubauer are joint senior authors.

Manuscript received October 14, 2015; revised manuscript received February 26, 2016, accepted March 8, 2016.

August 2009 and December 2014. Patients had a diagnosis of pheochromocytoma, as assessed by consultant endocrinologists, on the basis of biochemical testing (including urinary catecholamines and plasma and/or urinary metanephrines), and confirmed with cross-sectional imaging and subsequent positive histopathology (more clinical and tumor details available in the [Online Appendix](#)).

Newly diagnosed patients were assessed preoperatively after initiation of alpha-blockade with or without beta-blockade. Of these, 18 patients were available for repeat post-operative CMR scanning; other patients were not available due to serious illness (noncardiac or endocrine causes; $n = 2$), permanent pacemaker insertion precluding CMR ($n = 1$), living long distances away ($n = 3$), choosing not to participate ($n = 4$), or being lost to follow-up ($n = 1$). Additionally, we invited 31 previously diagnosed patients who were surgically cured and were without evidence of ongoing disease.

Exclusion criteria included inability to tolerate CMR, contraindications to CMR, known significant cardiac disease (previous MI, previous myocarditis, heart failure, significant valvular disease, or other chronic cardiac condition), and significant renal impairment (estimated glomerular filtration rate <30 ml/min).

Healthy volunteers (age- and sex-matched) with no cardiac history or risk factors, who were not on cardiovascular medications, and who had a normal electrocardiogram acted as control subjects. Patients with a diagnosis of essential hypertension ([Online Appendix](#)) without other significant comorbidities who had been on antihypertensive treatment for at least 3 months and were without severe left ventricular hypertrophy (LVH) acted as another control group. Hypertensive control subjects without severe LVH were specifically chosen to more closely match the morphological LV phenotype of the patients with pheochromocytoma. Ethical approval was granted for all study procedures; all subjects gave written informed consent.

CMR was performed on a single 1.5-T magnetic resonance system (Magnetom Avanto, Siemens Healthcare, Erlangen, Germany) using established CMR techniques and a 32-channel phased-array coil, as previously published (19). These included cine, strain imaging by myocardial tagging, LGE, and native T_1 mapping (Shortened Modified Look-Locker Inversion recovery) (20). For further details, see the [Online Appendix](#).

STATISTICAL ANALYSIS. Normality of data was tested using the Kolmogorov-Smirnov test. Normally distributed data are presented as mean \pm SD;

nonparametric data as median with interquartile ranges (IQRs). Paired samples were assessed by paired Student t test or the Wilcoxon signed rank test for nonparametric data. Unpaired samples were assessed by the unpaired 2-tailed Student t test or the Mann-Whitney U test for nonparametric data. Any segmental analysis was averaged on a per-subject basis before any interindividual and group comparisons to control for clustering of segments within each subject. To determine the presence of significant differences in subject groups when using multiple CMR methodologies, analysis of variance was performed with Bonferroni-corrected post hoc comparisons for parametric data; for nonparametric data, the Kruskal-Wallis 1-way analysis of variance was performed with post-hoc pairwise comparisons. To compare the extent of myocardial injury measured by 2 different CMR tissue characterization sequences (LGE and T_1 mapping) within the same patient subgroup, the Wilcoxon test was used for nonparametric data with post hoc comparisons. The Fisher exact test was used for comparison of categorical data. All statistical tests were 2-tailed, with p values <0.05 considered statistically significant. Statistical analyses were performed using MedCalc (version 11.5.1.0, MedCalc Software, Mariakerke, Belgium).

RESULTS

Baseline characteristics of patients with pheochromocytoma compared with matched control subjects are presented in [Table 1](#).

Newly diagnosed patients underwent CMR soon after diagnosis and before surgery (median 2 months; IQR: 1 to 4 months). Most (97%) were in sinus rhythm, whereas 1 (3%) was in atrial fibrillation and another (3%) had frequent ectopy at the time of scan. Follow-up CMR was performed at a mean of 12 ± 5 months.

Previously diagnosed and cured patients underwent CMR examination at a median of 51 months (IQR: 27 to 83 months) from the date of surgical resection of their pheochromocytoma. All were in sinus rhythm at the time of scan. In this group, only those who had abnormal CMR findings (7 of 31, 23%) were invited for a repeat CMR examination for follow-up (mean 25 ± 10 months; $n = 5$).

CARDIAC FINDINGS USING CMR CHARACTERIZATION. The CMR findings ([Central Illustration](#), [Figure 1](#)) for each group of patients were compared with both healthy control subjects (age- and sex-matched) and hypertensive control subjects ([Table 1](#)).

Newly diagnosed patients had a lower mean left ventricular ejection fraction (LVEF) compared with both healthy and hypertensive control subjects

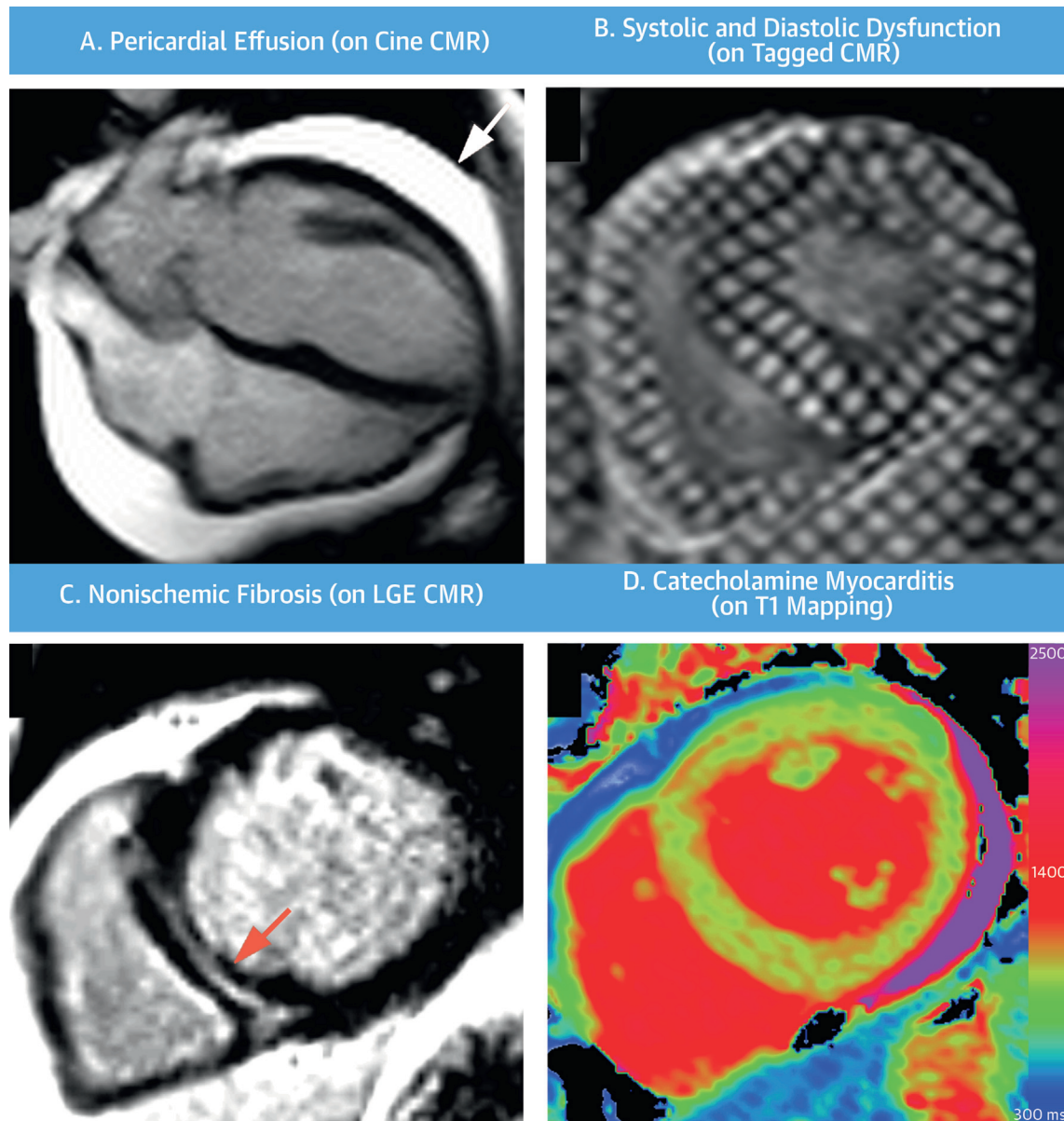
TABLE 1 Clinical and CMR Characteristics

	New Pheochromocytoma Dx Patients (n = 29)	Matched Control Subjects (n = 29)	Previous Pheochromocytoma Dx Patients (n = 31)	Matched Control Subjects (n = 31)	HTN Control Subjects (n = 14)
Clinical characteristics					
Age, yrs	50 ± 14	50 ± 13	52 ± 14	50 ± 12	55 ± 7
Female	15 (52)	15 (52)	17 (55)	17 (55)	5 (36)
Pre-existing hypertension	5 (17)	0 (0)	3 (10)	0 (0)	14 (100)
Pre-existing diabetes mellitus	5 (17)	0 (0)	3 (10)	0 (0)	0 (0)
Smoking	17 (59)	0 (0)	19 (61)	0 (0)	0 (0)
Time from diagnosis and CMR, months	2 (1-4)	N/A	51 (27-83)	N/A	N/A
On alpha-blockers at time of CMR scan	29 (100)	0 (0)	5 (16)	0 (0)	0 (0)
On beta-blockers at time of CMR scan	21 (72)	0 (0)	2 (6)	0 (0)	1 (7)
Other antihypertensive agents at time of CMR scan					
Angiotensin-converting enzyme inhibitor	8 (28)	0 (0)	0 (0)	0 (0)	7 (50)
Angiotensin II receptor blocker	1 (3)	0 (0)	1 (3)	0 (0)	6 (43)
Dihydropyridine calcium-channel blocker	0 (0)	0 (0)	0 (0)	0 (0)	1 (7)
Nondihydropyridine calcium-channel blocker	6 (21)	0 (0)	0 (0)	0 (0)	2 (14)
Thiazide diuretic agent	0 (0)	0 (0)	1 (3)	0 (0)	3 (21)
Thiazide-like diuretic agent	0 (0)	0 (0)	0 (0)	0 (0)	2 (14)
Systolic blood pressure at CMR scan, mm Hg	137 ± 20	130 ± 13	129 ± 19	127 ± 13	135 ± 17
Diastolic blood pressure at CMR scan, mm Hg	83 ± 12	75 ± 8	80 ± 10	75 ± 8	80 ± 11
Heart rate at CMR scan, beats/min	72 ± 14	62 ± 10	67 ± 10	63 ± 9	63 ± 7
Body mass index, kg/m ²	22.4 ± 2.5	25.4 ± 3.2	25.9 ± 4.6	24.5 ± 3.6	27.1
CMR characteristics					
LV ejection fraction, %	60 ± 9*†	67 ± 4	67 ± 5	67 ± 4	67 ± 4
LV end-diastolic volume indexed to BSA, ml/m ²	79 ± 18	73 ± 14	69 ± 12	74 ± 11	78 ± 10
LV end-systolic volume indexed to BSA, ml/m ²	33 ± 13*†	24 ± 6	23 ± 6	24 ± 5	26 ± 4
LV mass indexed to BSA, g/m ²	56 ± 12‡	53 ± 11	49 ± 9†	51 ± 9	61 ± 12*
Peak systolic circumferential strain, s ⁻¹	-15.8 ± 2.9*†	-18.5 ± 1.4	-17.1 ± 2.4*	-18.7 ± 1.3	-17.3 ± 8.1
Peak diastolic circumferential strain rate, s ⁻¹	72.8 ± 22.4*†	128.7 ± 29.3	62.8 ± 16.2*†	133.5 ± 25.5	104.7 ± 25.1*
Mean myocardial T ₁ , ms	974 ± 25*†	954 ± 16	959 ± 22	958 ± 19	958 ± 23
Myocardial injury by T ₁ ≥ 990 ms, %	22 (10-37)*†	1 (0-4)	12 (4-19)*†	2 (0-4)	2 (0-5)
Presence of LGE	17 (59)*†	0 (0)	6 (19)*	0 (0)	2 (14)
LV myocardium with LGE >2 SD, %	5 (2-7)*	2 (0-5)	1 (0-3)	0 (0-5)	2 (1-4)
Values are mean ± SD, n (%), or median (interquartile range). *Significantly different from normal control subjects. †Significantly different from HTN control subjects (p < 0.05). ‡Significantly different from patients with a previous diagnosis of pheochromocytoma. BSA = body surface area; CMR = cardiac magnetic resonance; Dx = diagnosis; HTN = hypertension; LGE = late gadolinium enhancement; LV = left ventricular.					

(both p < 0.05) (Table 1). On paired analysis, the average LVEF improved post-operatively in follow-up (from 60 ± 9% to 63 ± 5%; paired Student t test p < 0.03). Mild global LV dysfunction (LVEF 44% to 56%) was seen in 38% (11 of 29) of patients, but typically normalized post-operatively by 1 year (63 ± 5%; range 54% to 70%) in all available for follow-up. At baseline, newly diagnosed patients had impaired peak systolic circumferential strain compared with healthy and hypertensive control subjects (both p < 0.05) (Figure 2A, Table 1) and diastolic strain rate (both p < 0.05) (Figure 2B, Table 1). These abnormalities persisted at follow-up on paired analyses (both p = NS) (Table 2).

Patients with previously diagnosed and surgically cured pheochromocytoma had a normal mean LVEF

(67 ± 5%; range 60% to 78%), which was higher than in newly diagnosed patients (60 ± 9%; p < 0.001), but no different from healthy or hypertensive control subjects (67 ± 4% for each respectively; both p = NS). Interestingly, despite having normal LVEF, these patients had slightly impaired peak systolic circumferential strain compared with healthy control subjects, but it was not different from hypertensive control subjects (p = NS) (Figure 2A, Table 1). Previously diagnosed patients had significantly more impaired diastolic strain rate compared with both healthy and hypertensive control subjects (all p < 0.001) (Figure 2B, Table 1). This diastolic functional impairment was similar to that seen in newly diagnosed patients post-operatively in follow-up (62.8 ± 16.2 s⁻¹ vs. 64.3 ± 18.1 s⁻¹; p = NS).

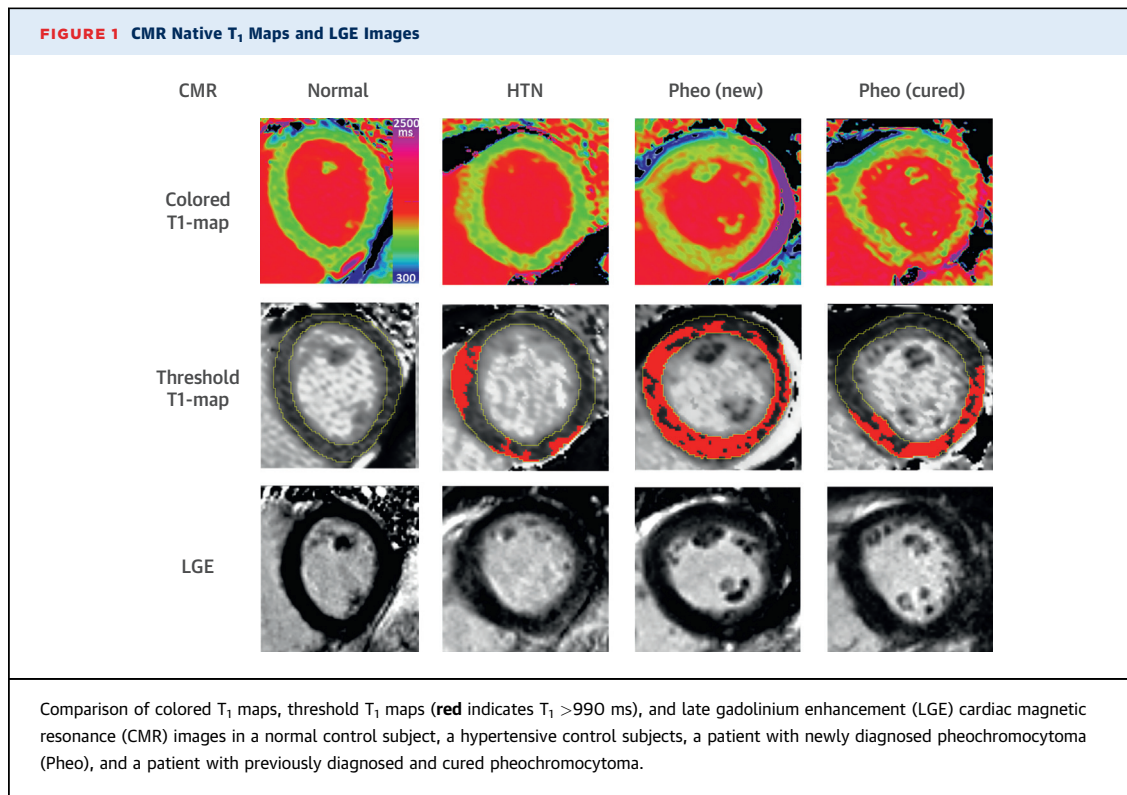
CENTRAL ILLUSTRATION CMR Characterization of Catecholaminergic Cardiac Toxicity in Pheochromocytoma

Ferreira, V.M. et al. J Am Coll Cardiol. 2016;67(20):2364-74.

Cardiac magnetic resonance (CMR) imaging using advanced myocardial tissue characterization techniques was able to detect a wide range of abnormalities related to catecholamine cardiac toxicity in a live patient cohort with pheochromocytoma. These include **(A)** left ventricular dysfunction and pericardial effusion (**arrow**) (cine imaging, end-diastolic still frame); **(B)** subclinical systolic and diastolic dysfunction on strain parameters (tagged CMR; end-systolic still frame); **(C)** focal and diffuse fibrosis (LGE imaging demonstrating nonischemic midwall pattern of focal fibrosis) (**arrow**); and **(D)** catecholamine myocarditis (T_1 map showing elevated global myocardial T_1 values >990 ms). These changes appear to be beyond those seen in hypertensive heart disease alone, and some persisted over time. LGE = late gadolinium enhancement.

Of note, LVH was atypical in patients with pheochromocytoma. Newly diagnosed patients had a normal left ventricular mass index (LVMI) that was not significantly different from healthy or hypertensive

control subjects (all $p = \text{NS}$) (**Table 1**). Compared with baseline, these patients demonstrated regression of the LVMI in post-operative follow-up on matched analyses ($p = 0.02$) back to a level similar to healthy



control subjects (Tables 1 and 2). Previously diagnosed patients had a normal LVMI compared with healthy control subjects ($p = \text{NS}$) and a lower LVMI compared with hypertensive control subjects and newly diagnosed patients pre-operatively (both $p < 0.05$) (Table 1).

FOCAL MYOCARDIAL FIBROSIS (LGE IMAGING).

There was an increased incidence of focal myocardial fibrosis, as detected by LGE imaging, in patients both newly diagnosed and previously diagnosed with pheochromocytoma. In newly diagnosed patients, a significant proportion (59%; $n = 17$) demonstrated scarring, all with a nonischemic pattern (midwall, subepicardial, or patchy), but these areas were small (median 5% of LV myocardium; IQR: 2% to 7%) and did not progress in size or distribution on follow-up. Interestingly, the frequency of these scars was significantly higher than that seen in hypertensive control subjects (59% vs. 14%; $p < 0.003$), but the area of scarring tended to be small in both groups (median 5% vs. 2%; $p = 0.1$).

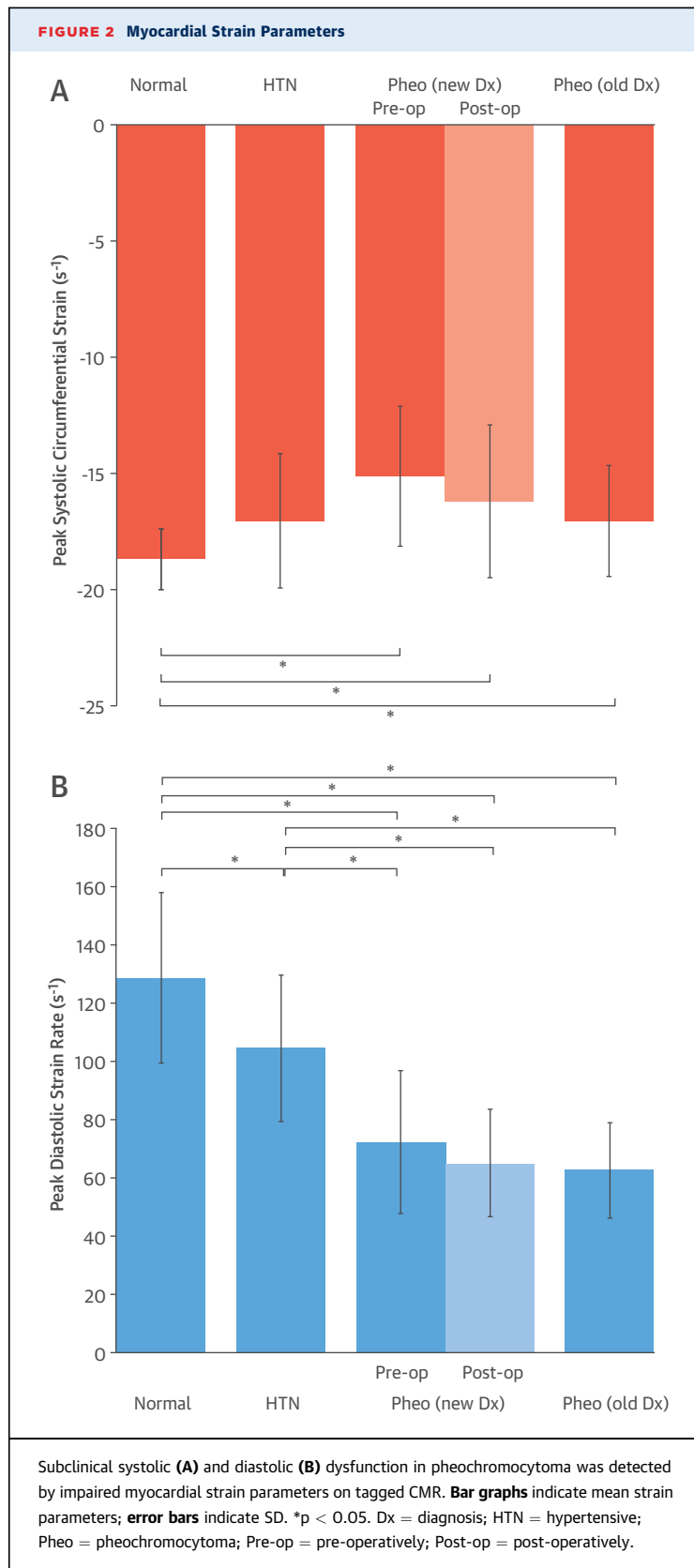
In previously diagnosed patients, a smaller proportion (19%; $n = 6$) demonstrated scarring compared with newly diagnosed patients that, again, were all nonischemic in pattern, were small in area (median 1% of LV myocardium; IQR: 0 to 3%), and did not

progress on follow-up. No patient in either group had evidence of MI (isolated subendocardial scarring in a single coronary distribution).

MYOCARDIAL INFLAMMATION AND INVOLVEMENT (T₁ MAPPING). Native T₁ mapping revealed significant areas of myocardial abnormality beyond those detected by conventional CMR imaging techniques (Table 1, Figures 1 and 3).

Newly diagnosed patients had significantly higher average LV myocardial T₁ values compared with healthy and hypertensive control subjects ($974 \pm 25 \text{ ms}$ vs. $954 \pm 16 \text{ ms}$ and $958 \pm 23 \text{ ms}$, respectively; both $p < 0.05$). Further, using the T₁ cut-off of 990 ms previously established for detecting acute myocarditis (19,21), these patients showed significantly larger areas of myocardial involvement compared with healthy and hypertensive control subjects (median 22% vs. 1% and 2% LV myocardium, respectively; both $p < 0.05$). On follow-up, the area of T₁ abnormality had regressed significantly on paired analysis (median 19% to 12%; $p < 0.02$), but not back to normal as compared with healthy control subjects (median 1%; $p < 0.05$).

Patients with previously diagnosed, surgically treated pheochromocytoma without evidence of active disease also demonstrated significantly larger



areas of myocardial involvement detected by native T₁ mapping compared with healthy and hypertensive control subjects (median 12% vs. 2% and 2%, respectively; both *p* < 0.05). This is comparable to that seen in newly diagnosed patients post-operatively in follow-up (also median 12%).

DISCUSSION

This is the first systematic study using advanced CMR imaging, including mapping techniques, to characterize the cardiac phenotype in stable patients with pheochromocytoma (**Central Illustration**). We have shown that: 1) cardiac involvement is common in this cohort, including global LV dysfunction, impaired systolic and diastolic strain parameters, myocarditis, pericardial effusion, and markers for focal and diffuse fibrosis; 2) although some abnormalities, such as global LV dysfunction and myocardial edema, are reversible, there are subclinical abnormalities that persisted over time, even after curative resection of the pheochromocytoma without biochemical evidence of ongoing disease, including subclinical systolic and diastolic dysfunction and markers for focal and diffuse fibrosis; and 3) compared with hypertensive control subjects, the cardiac changes are beyond and distinct from those observed in hypertensive heart disease alone, and importantly, LVH is not a typical feature in pheochromocytoma. These findings support the direct role of catecholamine toxicity to the heart, which may lead to a form of catecholamine-induced myocarditis that produces some subtle but long-lasting myocardial alterations.

FINDINGS IN CATECHOLAMINE MYOCARDITIS. Catecholamines have been shown to cause direct myocardial toxicity, with pathological changes such as contraction band necrosis via mechanisms such as alpha-receptor-mediated vasoconstriction and oxygen-derived free radical injury, leading to myocyte membrane damage and death (8,14,22,23). Van Vliet et al. (22) examined the hearts of 26 patients who died with a pheochromocytoma compared with 256 control subjects, taking into account sex, age, degree of coronary atherosclerosis, hypertension, and types of myocardial disease (22). Pathological cardiac findings revealed disseminated focal myocardial lesions in 58% of the patients (similar to our findings of nonischemic focal fibrosis in 59% of newly diagnosed patients), characterized by focal degeneration and necrosis of myocardial fibers, and foci of inflammatory cells and diffuse myocardial edema, designated as “active catecholamine myocarditis.” We detected increased fibrous tissue in

the same distribution as the inflammatory lesions that appeared to have replaced myocardial fibers around small vessels. In patients without active catecholamine myocarditis, 2 demonstrated marked myocardial fibrosis, similar in appearance and distribution to the fibrosis of those with active myocarditis without severe coronary atherosclerosis to explain the findings, and likely represented the healed stage of the acute catecholamine myocarditis. Importantly, patients who had nonfunctioning pheochromocytomas did not demonstrate these lesions, and only 7% in the control group demonstrated histological evidence of myocarditis, of which none had the same histologic characteristics of patients with pheochromocytoma.

These findings were similar to those of earlier studies in experimental animal models and patients treated with L-norepinephrine and in patients with pheochromocytoma, described as both acute necrotic and inflammatory lesions, as well as chronic fibrosing lesions (23-26). No evidence of eccentric or disproportional septal hypertrophy was observed. Thus, catecholamines in pheochromocytoma exert a direct cardiotoxic effect; this is a distinct entity whose footprint may be observed histologically in various stages of this pathological process, including degenerative changes in muscle fibers, foci of necrosis, acute inflammation, chronic interstitial inflammatory exudation, and reparative fibrosis. On CMR, these may be observed noninvasively as myocardial necrosis, edema, and focal and diffuse fibrosis that may lead to short- or long-term functional changes.

Indeed, many of these morpho-functional alterations were demonstrated by this CMR study. Acute myocarditis may be detected using highly sensitive myocardial T₁ mapping (19). In patients with newly diagnosed pheochromocytoma, native T₁ mapping detected significant areas of myocarditis compared with control subjects; this diminished post-operatively over time along with LV mass regression, supporting a degree of acute myocarditis that is reversible post-surgical treatment, but T₁ did not completely normalize. Similarly, patients with previous surgically treated pheochromocytoma, without clinical evidence of active disease, also demonstrated myocardial T₁ abnormalities, albeit to a lesser degree than the newly diagnosed patients. It should be noted that diffuse and focal myocardial fibrosis may elevate native myocardial T₁ (27,28). Thus, it is plausible that in some of these patients, after acute myocarditis resolution, T₁ mapping may detect reparative changes that have begun, including development of focal and diffuse myocardial fibrosis (6). The high incidence (59%) of focal myocardial fibrosis on LGE imaging

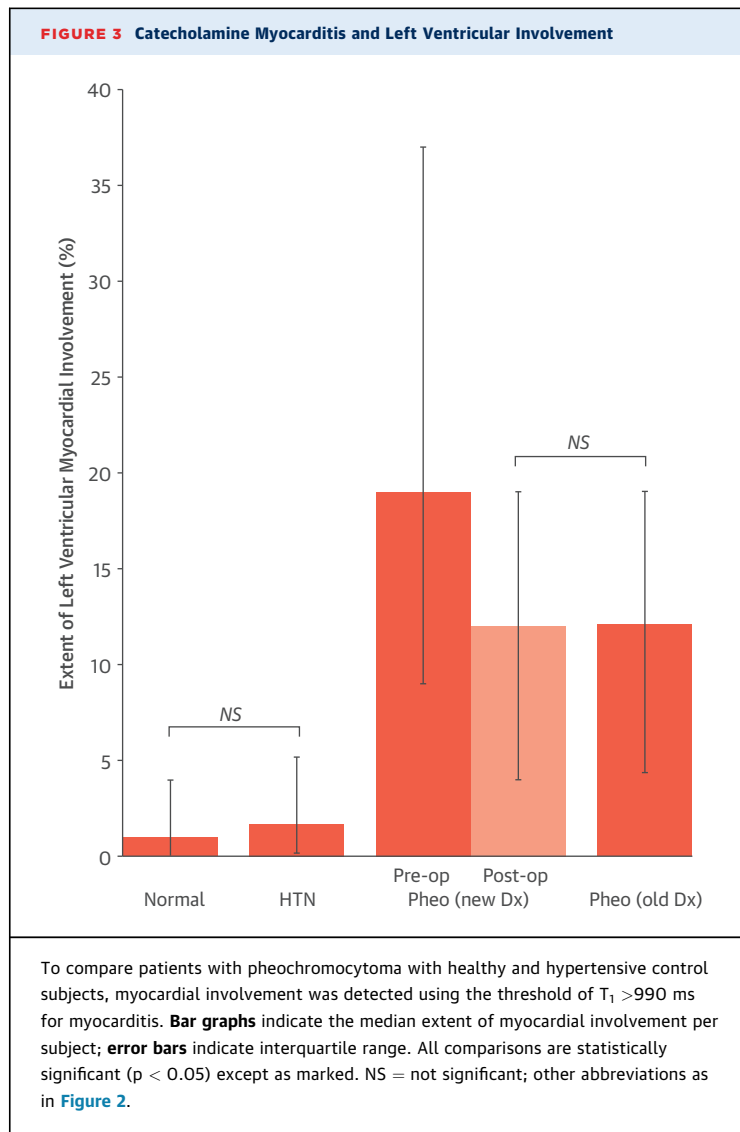
TABLE 2 Paired Comparison of CMR Characteristics Pre- and Post-Surgery

	Patients With New Dx of Pheochromocytoma Pre-Operation	Patients With New Dx of Pheochromocytoma Post-Operation	p Value
LV ejection fraction, %	60 ± 9	63 ± 5	<0.03*
LV end-diastolic volume indexed to BSA, ml/m ²	76 ± 16	71 ± 13	<0.02*
LV end-systolic volume indexed to BSA, ml/m ²	32 ± 13	27 ± 8	<0.02*
LV mass indexed to BSA, g/m ²	58 ± 13	52 ± 8	0.02*
Peak systolic circumferential strain (s ⁻¹)	-15.1 ± 3.0	-16.2 ± 3.3	NS
Peak diastolic circumferential strain rate, s ⁻¹	72.3 ± 24.5	65.1 ± 18.4	NS
Mean myocardial T ₁ , ms	973 ± 26	964 ± 24	NS
Myocardial injury by T ₁ ≥ 990 ms, %	19 (9-37)	12 (4-19)	<0.02*
LV myocardium with LGE > 2 SD, %	5 (3-7)	5 (2-12)	NS

Values are mean ± SD or median (interquartile range). *Statistically significant on paired analysis; follow-up CMR was performed at a mean of 12 ± 5 months. Abbreviations as in Table 1.

seen in newly diagnosed patients supports the notion that the T₁ changes seen at pre-operative baseline may represent a combination of acute and chronic myocardial changes, depending on the age and functional status of a patient's pheochromocytoma. Although we do not have verification via histopathological correlation, this hypothesis is an attractive explanation consistent with both human and animal histopathological studies and the natural history of this condition (1,4,6,8,22,24,26).

Further, these myocardial abnormalities appear to be distinct from those of hypertensive heart disease or pressure overload alone. First, the catecholamine-induced pattern of hypertension is highly variable, often paroxysmal either on a background of sustained hypertension or normotension in between periods of hypertension (6). Second, blood pressure patterns also appear to be distinct from essential hypertension (10), with greater daytime variability and lack of a nocturnal dip (29,30), implying different mechanisms of hypertension, making it difficult to find matching control subjects (1). Perhaps most convincing: although some studies have described an association between plasma norepinephrine levels and LVH (22,31,32), only a subset (~25% to 40% of patients) with pheochromocytoma demonstrated echocardiographic evidence of LVH in other studies (1,6,33-35). Our study demonstrated a similar lack of LVH in these patients, and we have carefully chosen hypertensive control subjects without severe LVH to more closely match the morphological LV phenotype of patients with pheochromocytoma; these patients demonstrated cardiac findings that are distinct from and



beyond those seen in patients with essential hypertension, supporting a direct role of catecholamine myocardial toxicity (10).

Exposure to catecholamines may result in myocardial alterations that lead to overt or subclinical myocardial dysfunction, which may or may not reverse over time. Per reports, myocardial contractile dysfunction and catecholamine-induced cardiomyopathies are reversible with pharmacological and surgical treatment of the pheochromocytoma (1,4,7,36). Although our findings are generally consistent with the reversibility of overt LV dysfunction measured via global indexes such as LVEF, we uncovered subclinical systolic and diastolic dysfunction that persisted over time, despite surgical cure of the pheochromocytoma and with no clinical evidence

of ongoing catecholamine activity. As discussed, this is accompanied by findings of focal fibrosis on LGE imaging and the failure of myocardial T_1 values to completely normalize in follow-up, possibly reflecting development of some diffuse myocardial fibrosis detectable using T_1 mapping (27). This paralleled a recent study by Galetta et al. (37) that examined myocardial wall texture in patients with pheochromocytoma using ultrasonic tissue characterization of the myocardium, expressed as tissue integrated backscatter. Their results demonstrated adverse myocardial remodeling characterized by an increase in the overall myocardial backscatter level compared with hypertensive and normotensive control subjects; this is consistent with increased myocardial collagen content and fibrosis, which determines early diastolic dysfunction (37). The findings from this and our study suggest that the myocardial injury sustained during the course of catecholamine exposure may be accompanied by reparative processes such as focal and diffuse fibrosis or other ultrastructural changes post-catecholamine myocarditis. Furthermore, catecholamine toxicity is not completely benign and may not be quickly reversible, leaving long-lasting changes in the form of subtle systolic and diastolic dysfunction.

STUDY LIMITATIONS. Due to the rarity of the condition, this study has a relatively small sample size, although it is the largest study to date using CMR as a phenotypic tool. Given that the changes are subclinical, larger studies are needed to confirm these findings and determine their long-term clinical significance. We recruited patients with pheochromocytoma mostly from the outpatient setting, so selection bias existed, and this study's findings characterize a more stable cohort without more severe cardiovascular complications (6). Similar to other studies of patients with pheochromocytoma, it is difficult to find an appropriate hypertensive control group (4,10) to match the variable patterns of hypertension in pheochromocytoma that seem to be distinct from those of essential hypertension and to clearly delineate which findings are attributable to hypertension alone, are attributable to catecholamine toxicity, or may be synergistic. Endomyocardial biopsy was not indicated in these patients, and as such, direct histopathological correlation to the imaging findings is not available.

CONCLUSIONS

Cardiac involvement was frequent and often persistent in pheochromocytoma, including myocarditis,

global LV dysfunction, subclinical systolic and diastolic dysfunction, and focal and diffuse fibrosis. These changes extended beyond the effects of hypertensive heart disease alone, supporting a direct role of catecholamine toxicity that may result in subtle but long-lasting myocardial alterations. Larger and longer-term studies may determine whether early detection of catecholamine-induced cardiac changes may be useful for risk stratification, predicting clinical cardiovascular events, or early treatment to minimize long-term myocardial damage in pheochromocytoma.

REPRINT REQUESTS AND CORRESPONDENCE: Dr. Vanessa Ferreira, Oxford Centre for Clinical Magnetic Resonance Research, Division of Cardiovascular Medicine, Radcliffe Department of Medicine,

University of Oxford, John Radcliffe Hospital, Level 0-OCMR, Headley Way, Oxford OX3 9DU, United Kingdom. E-mail: vanessa.ferreira@cardiov.ox.ac.uk.

PERSPECTIVES

COMPETENCY IN MEDICAL KNOWLEDGE: Beyond the effects of hypertension, pheochromocytoma is associated with catecholamine-induced cardiac toxicity. This is characterized by myocardial inflammation, myocyte necrosis, and fibrosis that can lead to systolic and diastolic dysfunction.

TRANSLATIONAL OUTLOOK: Further research is needed to identify specific CMR imaging findings associated with long-term prognosis in patients with pheochromocytoma.

REFERENCES

1. Prejbisz A, Lenders JWM, Eisenhofer G, Januszewicz A. Cardiovascular manifestations of pheochromocytoma. *J Hypertens* 2011;29:2049-60.
2. Lenders JW, Eisenhofer G, Mannelli M, Pacak K. Pheochromocytoma. *Lancet* 2005;366:665-75.
3. Beard CM, Sheps SG, Kurland LT, Carney JA, Lie JT. Occurrence of pheochromocytoma in Rochester, Minnesota, 1950 through 1979. *Mayo Clin Proc* 1983;58:802-4.
4. Zelinka T, Petrak O, Turkova H, et al. high incidence of cardiovascular complications in pheochromocytoma. *Horm Metab Res* 2012;44:379-84.
5. Yu R, Nissen N, Bannykh S. Cardiac complications as initial manifestation of pheochromocytoma: frequency, outcome, and predictors. *Endocr Pract* 2012;18:483-92.
6. Galetta F, Franzoni F, Bernini G, et al. Cardiovascular complications in patients with pheochromocytoma: a mini-review. *Biomed Pharmacother* 2010;64:505-9.
7. Park J-H, Kim KS, Sul J-Y, et al. Prevalence and patterns of left ventricular dysfunction in patients with pheochromocytoma. *J Cardiovasc Ultrasound* 2011;19:76-82.
8. Edmondson EF, Bright JM, Halsey CH, Ehrhart EJ. Pathologic and cardiovascular characterization of pheochromocytoma-associated cardiomyopathy in dogs. *Vet Pathol* 2015;52:338-43.
9. Zierhut W, Zimmer HG. Significance of myocardial alpha- and beta-adrenoceptors in catecholamine-induced cardiac hypertrophy. *Circ Res* 1989;65:1417-25.
10. Stolk RF, Bakx C, Mulder J, et al. Is the excess cardiovascular morbidity in pheochromocytoma related to blood pressure or to catecholamines? *J Clin Endocrinol Metab* 2013;98:1100-6.
11. Kassim T, Clarke D, Mai V, Clyde P, Shakir KM. Catecholamine-induced cardiomyopathy. *Endocr Pract* 2008;14:1137-49.
12. Todd GL, Baroldi G, Pieper GM, et al. Experimental catecholamine-induced myocardial necrosis I. Morphology, quantification and regional distribution of acute contraction band lesions. *J Mol Cell Cardiol* 1985;17:317-38.
13. Mann DL, Kent RL, Parsons B, Cooper G 4th. Adrenergic effects on the biology of the adult mammalian cardiocyte. *Circulation* 1992;85:790-804.
14. Singal PK, Kapur N, Dhillon KS, et al. Role of free radicals in catecholamine-induced cardiomyopathy. *Can J Physiol Pharmacol* 1982;60:1390-7.
15. Roghi A, Pedrotti P, Milazzo A, et al. Adrenergic myocarditis in pheochromocytoma. *J Cardiovasc Magn Reson* 2011;13:4.
16. de Miguel V, Arias A, Paissan A, et al. Catecholamine-induced myocarditis in pheochromocytoma. *Circulation* 2014;129:1348-9.
17. Moon J, Messroghli D, Kellman P, et al. Myocardial T1 mapping and extracellular volume quantification: a Society for Cardiovascular Magnetic Resonance (SCMR) and CMR Working Group of the European Society of Cardiology consensus statement. *J Cardiovasc Magn Reson* 2013;15:92.
18. Ferreira VM, Piechnik SK, Robson MD, et al. Myocardial tissue characterization by magnetic resonance imaging: novel applications of T1 and T2 mapping. *J Thorac Imaging* 2014;29:147-54.
19. Ferreira VM, Piechnik SK, Dall'Armellina E, et al. T1 mapping for the diagnosis of acute myocarditis using CMR: comparison to T2-weighted and late gadolinium enhanced imaging. *J Am Coll Cardiol Img* 2013;6:1048-58.
20. Piechnik SK, Ferreira VM, Dall'Armellina E, et al. Shortened Modified Look-Locker Inversion recovery (ShMOLLI) for clinical myocardial T1-mapping at 1.5 and 3 T within a 9 heartbeat breathhold. *J Cardiovasc Magn Reson* 2010;12:69.
21. Ferreira V, Piechnik S, Dall'Armellina E, et al. Non-contrast T1-mapping detects acute myocardial edema with high diagnostic accuracy: a comparison to T2-weighted cardiovascular magnetic resonance. *J Cardiovasc Magn Reson* 2012;14:42.
22. Van Vliet PD, Burchell HB, Titus JL. Focal myocarditis associated with pheochromocytoma. *N Engl J Med* 1966;274:1102-8.
23. Szakacs JE, Mehlmán B. Pathologic changes induced by L-norepinephrine: quantitative aspects. *Am J Cardiol* 1960;5:619-27.
24. Szakacs JE, Cannon A. L-Norepinephrine myocarditis. *Am J Clin Pathol* 1958;30:425-34.
25. Pearce RM. Experimental myocarditis: a study of the histological changes following intravenous injections of adrenalin. *J Exp Med* 1906;8:400-9.
26. Kline IK. Myocardial alterations associated with pheochromocytomas. *Am J Pathol* 1961;38:539-51.
27. Bull S, White SK, Piechnik SK, et al. Human non-contrast T1 values and correlation with histology in diffuse fibrosis. *Heart* 2013;99:932-7.
28. Ntusi NAB, Piechnik SK, Francis JM, et al. Diffuse myocardial fibrosis and inflammation in rheumatoid arthritis: insights from cardiovascular magnetic resonance T1 mapping. *J Am Coll Cardiol Img* 2015;8:526-36.
29. Zelinka T, Pacak K, Widimsky J Jr. Characteristics of blood pressure in pheochromocytoma. *Ann N Y Acad Sci* 2006;1073:86-93.
30. Zelinka T, Strauch B, Pecan L, Widimsky J Jr. Diurnal blood pressure variation in pheochromocytoma, primary aldosteronism and Cushing's syndrome. *J Hum Hypertens* 2004;18:107-11.
31. Kelm M, Schafer S, Mingers S, et al. Left ventricular mass is linked to cardiac noradrenaline in normotensive and hypertensive patients. *J Hypertens* 1996;14:1357-64.
32. Simpson P. Norepinephrine-stimulated hypertrophy of cultured rat myocardial cells is an alpha 1 adrenergic response. *J Clin Invest* 1983;72:732-8.

- 33.** Fouad-Tarazi FM, Imamura M, Bravo EL, et al. Differences in left ventricular structural and functional changes between pheochromocytoma and essential hypertension. Role of elevated circulating catecholamines. *Am J Hypertens* 1992; 5:134-40.
- 34.** Shub C, Cueto-Garcia L, Sheps SG, et al. Echocardiographic findings in pheochromocytoma. *Am J Cardiol* 1986;57:971-5.
- 35.** Denolle T, Chatellier G, Julien J, et al. Left ventricular mass and geometry before and after etiologic treatment in renovascular hypertension, aldosterone-producing adenoma, and pheochromocytoma. *Am J Hypertens* 1993;6:907-13.
- 36.** Agarwal G, Sadacharan D, Kapoor A, et al. Cardiovascular dysfunction and catecholamine cardiomyopathy in pheochromocytoma patients and their reversal following surgical cure: results of a prospective case-control study. *Surgery* 2011; 150:1202-11.
- 37.** Galetta F, Bernini G, Franzoni F, et al. Preclinical cardiac involvement in phaeochromocytoma: a study with integrated backscatter. *Clin Endocrinol (Oxf)* 2008;68:756-61.

KEY WORDS cardiac magnetic resonance, catecholamine toxicity, T₁ mapping

APPENDIX For a supplemental Methods section, please see the online version of this article.