

UNIVERSITY OF BIRMINGHAM

Research at Birmingham

Deep brain stimulation for tremor resulting from acquired brain injury

Sitsapesan, H A; Holland, P; Oliphant, Z; De Pennington, N; Brittain, John-Stuart; Jenkinson, Ned ; Joint, C; Aziz, T Z; Green, A L

DOI:

[10.1136/jnnp-2013-305340](https://doi.org/10.1136/jnnp-2013-305340)

License:

Other (please specify with Rights Statement)

Document Version

Peer reviewed version

Citation for published version (Harvard):

Sitsapesan, HA, Holland, P, Oliphant, Z, De Pennington, N, Brittain, J-S, Jenkinson, N, Joint, C, Aziz, TZ & Green, AL 2014, 'Deep brain stimulation for tremor resulting from acquired brain injury', *Journal of Neurology Neurosurgery and Psychiatry*, vol. 85, no. 7, pp. 811-5. <https://doi.org/10.1136/jnnp-2013-305340>

[Link to publication on Research at Birmingham portal](#)

Publisher Rights Statement:

This is the Author Accepted Manuscript Version of the article published in final form at: <http://dx.doi.org/10.1136/jnnp-2013-305340>.

Checked July 2015

General rights

Unless a licence is specified above, all rights (including copyright and moral rights) in this document are retained by the authors and/or the copyright holders. The express permission of the copyright holder must be obtained for any use of this material other than for purposes permitted by law.

- Users may freely distribute the URL that is used to identify this publication.
- Users may download and/or print one copy of the publication from the University of Birmingham research portal for the purpose of private study or non-commercial research.
- User may use extracts from the document in line with the concept of 'fair dealing' under the Copyright, Designs and Patents Act 1988 (?)
- Users may not further distribute the material nor use it for the purposes of commercial gain.

Where a licence is displayed above, please note the terms and conditions of the licence govern your use of this document.

When citing, please reference the published version.

Take down policy

While the University of Birmingham exercises care and attention in making items available there are rare occasions when an item has been uploaded in error or has been deemed to be commercially or otherwise sensitive.

If you believe that this is the case for this document, please contact UBIRA@lists.bham.ac.uk providing details and we will remove access to the work immediately and investigate.

Deep brain stimulation for tremor resulting from acquired brain injury

H A Sitsapesan,^{1,2} P Holland,^{1,2} Z Oliphant,³ N De Pennington,^{1,3} J-S Brittain,^{1,4} N Jenkinson,^{1,2} C Joint,¹ T Z Aziz,^{1,2} A L Green^{1,2}

¹Oxford Functional Neurosurgery and Experimental Neurology, Oxford University, Oxford, Oxfordshire, UK

²Nuffield Department of Surgical Sciences, Oxford University, Oxford, Oxfordshire, UK

³Department of Physiology, Anatomy and Genetics, Oxford University, Oxford, Oxfordshire, UK

⁴Oxford University, Institute for Biomedical Engineering, Oxford, Oxfordshire, UK

Introduction

Tremor is a debilitating comorbidity which can develop following acquired brain injury (ABI)^{1,2}. There is well-established evidence for the efficacy of thalamic deep brain stimulation (DBS) in the treatment of tremor, particularly in PD and ET³. The standard electrode target is the ventralis intermedius (Vim) thalamic nucleus.

DBS is also effective for treating more complex tremor syndromes such as those associated with MS³⁻⁵. For complex tremor syndromes, often with proximal and distal components, DBS targeted to the ventro-oralis posterior (Vop)/zona incerta (ZI) has shown good efficacy⁶. This is explained by the fact that in Vop/ZI DBS, the electrode is sited in such a way that it traverses both areas, and stimulation can be adjusted to blend the effects of Vop stimulation, which tends to target proximal tremor, and ZI stimulation, effective for distal tremor.

Like MS tremor, post-ABI tremor is a highly variable syndrome, with heterogenous patterns of neural damage producing complex movements composed of distal and proximal components. Positive results have been reported from trials of DBS for post-ABI tremor⁶⁻¹⁰, but mostly in the form of case reports and small series. Here we report surgical experience and follow-up of a series of 8 patients diagnosed with post-ABI tremor resulting from

acquired brain injury (ABI) and treated with DBS to the contralateral Vop/ZI. To the authors' knowledge this is the largest cohort study reported to date.

Methods

Patients

A consecutive series of eight patients with post-ABI tremor underwent Vop/ZI DBS surgery. All patients provided informed consent for the use of anonymized data in clinical research. Table 1 displays a summary of the clinical characteristics of the patients. Patients had evidence of neural damage to midbrain or cerebellar pathways (n=6), thalamus (n=1) and peri-rolandic cortex (n=1). It is possible that patients had additional neural injury not evident on available imaging. Video assessments were part of the standard clinical assessment and post-operative follow-up. Testing was in accordance with principles of the Declaration of Helsinki and ethical approval obtained from the Oxfordshire REC C: 05/Q1605/47.

Surgery

Surgery was performed by one surgeon between 1999 and 2007 across two centres, Oxford, UK and Charing Cross, UK. All patients underwent surgery for implantation of DBS electrodes (Medtronic 3387, Medtronic, Minneapolis, MN, each with four 1.5mm contacts spaced 1.5mm apart, spanning a total distance of 12mm) targeting the Vop/ZI contralateral to the side of tremor. Details of surgical technique have previously been published by our group⁵. The intended target for VOP was 12, 0, 0 (mm) relative to the MCP in each patient, while ZI was visually targeted, aiming just above the STN. Final electrode position was determined clinically by awake intraoperative testing, producing a possible discrepancy between the original target location and the final positions chosen. Stereotactic co-ordinates relative to the AC-PC line, electrode configuration and stimulation parameters for each

patient are given in table 2. Figure 2 demonstrates the electrode trajectory (A) and the position of the 2 active contacts (B, C) mapped onto the Schaltenbrand-Wahren atlas for a single patient, illustrating how the electrode can traverse Vop and ZI. The typical anatomical distance between the targets varies between individuals and, if calculated linearly, also depends on the angle of approach. However, based on our subjects and the atlas localization of the electrode contacts, the distance between ZI and Vop is between 3 and 6 mm. For example, in patient 3, where the angle of the electrode relative to the AC-PC line was 49 degrees, the centre of contact 10 was within ZI and the centre of contact 11 was within Vop, giving an estimated anatomical separation of 3 mm (see table 2 and figure 2).

Electrode placement was confirmed by post-operative CT scan co-registered to the pre-operative MRI. Patient 3 was additionally implanted with a second electrode in the ipsilateral globus pallidus pars interna (GPi) with the intention of suppressing dyskinesias. This lead was turned off throughout testing. Patient 3 had previously undergone a thalamotomy, which produced only transient alleviation of tremor.

No adverse neurological reactions to surgery were reported. One patient suffered two infections at the implantable pulse generator site (IPG) (Medtronic Kinetra Model 7428, Medtronic, Minneapolis, MN) resulting in repositioning of the IPG with no further complications. One patient suffered an IPG failure resulting in rapid tremor recurrence, which was abolished upon IPG replacement. During follow-up, patients 3, 5 and 6 had replacement of IPG due to end of battery of life.

Clinical Rating Scale

The severity of tremor was measured using Bain's standardized clinical rating scale for tremor¹¹. Anonymized video clips of clinical assessments were digitised, randomised, and rated by two consultant members of the clinical care team blinded to the patient's operative and stimulation status. Post-operative videos from the longest follow-up period available were selected. Ratings addressed severity of tremor in the affected arm in 5 categories; rest, postural, kinetic, proximal and distal. Ratings were scored out of 10 for each category with 0 representing the absence of tremor and 10 being the most severe. Ratings were based on the amplitude and intermittency of tremor. Clinical definitions of tremor components have previously been established and described in detail¹². The mean score from the two observers was used for statistical testing.

Results

All patients were assessed and videoed ON stimulation (n=8) at a mean length of follow-up of 26 months. ON-stimulation tremor scores were compared either with OFF-stimulation scoring of videos made at the time of follow-up assessment, or with scores from pre-operative videos. 6 patients had pre-operative video assessments for comparison and 5 patients had follow-up OFF stimulation video assessments, taken after a sufficient wash-out period. Pre-operative videos were used in preference over follow-up videos in the 6 patients where these were available. In the patient with a GPi lead, this was turned OFF throughout all assessments. For the 6 patients with pre-operative and ON stimulation assessments, all showed reductions in tremor severity across the 5 components of the Bain scale (mean reduction 69.13%, SD 38.69%). Similar results were obtained for the two patients in which ON and OFF stimulation conditions were instead compared (Patient 7: mean reduction 77.78% and Patient 5: mean reduction 87%). Taken together, there was an overall reduction of tremor severity by 80.75% following stimulation. Figure 1 displays the mean component scores across conditions (pre-operative, ON stimulation, OFF stimulation). The scores from

the two observers showed a highly significant correlation (n=95, $p < 0.001$, $r = 0.838$, Pearson Correlation).

All five tremor elements showed significant reduction in the ON stimulation condition, compared to pre-operative levels (n=6, Rest $p = 0.046$, $Z = -1.997$; Postural $p = 0.003$, $Z = -2.943$; Kinetic $p = 0.003$, $Z = -2.940$; Proximal $p = 0.018$, $Z = -2.371$; Distal $p = 0.003$, $Z = -2.991$, Wilcoxon Signed Rank). Similarly, significant differences in all five components of the tremor score were observed on comparison between the ON and OFF stimulation conditions (n=5, Rest $p = 0.042$, $Z = -2.032$; Postural $p = 0.005$, $Z = -2.814$; Kinetic $p = 0.005$, $Z = -2.807$; Proximal $p = 0.018$, $Z = -2.375$; Distal $p = 0.005$, $Z = -2.823$, Wilcoxon Signed Rank). However, there were no significant differences between the pre-operative scores and those recorded OFF stimulation (n=3, Rest $p = 1$, $Z = 0$; Postural $p = 0.339$, $Z = -0.957$; Kinetic $p = 1$, $Z = 0$; Proximal $p = 0.786$, $Z = -0.271$; Distal $p = 0.221$, $Z = -1.225$, Wilcoxon signed Rank).

All patients also experienced some degree of functional benefit with 3 regaining the ability to write legibly and 3 more regaining the ability to hold a cup of fluid. The main side effects are summarised in table 1. In general, these were insignificant relative to the degree of clinical benefit, and were usually minimised by altering stimulation parameters.

Discussion

The results of this study provide strong evidence for the efficacy of Vop/ZI DBS in reducing the severity of unilateral post-ABI tremor. Statistically significant improvements following DBS were demonstrated across all 5 components of the Bain tremor score, evaluated in a blinded fashion by 2 consultants considered to be expert in the assessment of tremor. The

strong benefits of DBS demonstrated in this study are underlined by the report of rapid tremor recurrence following IPG failure in one patient.

Tremor can be a debilitating outcome following severe head injury or stroke^{1,2}, remaining chronic and refractory to medical therapy in some patients. Damage to the cerebellothalamic pathway may result in kinetic and proximal tremors, and that if damage encompasses both cerebellothalamic and nigrostriatal regions, a Holmes tremor may result¹³. All patients in our cohort experienced a kinetic or postural tremor, and Holmes' tremor was diagnosed in 6 patients (patients 1, 2, 4, 6, 7, 8). Damage to the cerebellum or cerebellar pathways may also result in ataxia (patients 2 and 5), which is unaffected by DBS and may be a source of remaining functional disability.

One of the remarkable features of our study is that benefit was achieved for all patients despite heterogeneity within the cohort in terms of the neuroanatomical locus of injury (Table 1). We suggest that this may be due to the selection of Vop/ZI as the target for surgical intervention, in contrast to the more widely targeted Vim nucleus. The choice is borne of clinical experience regarding the efficacy of Vop/ZI in the treatment of complex tremors with heterogenous patterns of underlying neural damage, such as those associated with MS^{5,14}. A recent DTI study from our group has demonstrated that Vop and Vim have different patterns of connectivity, which may account for the difference in clinical effect of stimulating the two regions¹⁵. However, as with all forms of DBS, a detailed understanding of the mechanistic principles underlying the mechanism of action of Vop/ZI stimulation is still lacking. Nevertheless, the clinical benefit demonstrated in the present cohort is compelling.

We note some limitations of our data, including different lengths of follow-up and the presence of a pre-existing thalamotomy in one patient (however, this had failed to provide lasting clinical benefit which is why the patient was considered for DBS surgery). Our

assessment was limited to tremor evaluation in the experimental setting and we did not assess the effect of DBS on co-existing symptoms such as ataxia; nor did we assess chronic effects of stimulation. Future studies would also benefit from more comprehensive symptom evaluation, testing over longer durations of stimulation and more extensive quality of life and activities of daily living outcomes. Future studies would also benefit from detailed anatomical mapping of both the lesion site and electrode targets, combined with DTI analysis, to gain deeper mechanistic understanding of the stimulation effects.

Summary

Vop/ZI DBS produced a significant reduction in tremor symptoms in 8 consecutive patients treated for post-ABI tremor despite apparent heterogeneity in the underlying anatomical lesion. Our results confirm earlier reports in small case series and case reports that DBS may be an effective treatment option for post-ABI tremor⁷⁻¹⁰.

Acknowledgements

Oxford Functional Neurosurgery is supported by the MRC, BRC, EPSRC, The Wellcome Trust, The Norman Collison Foundation and The Charles Wolfson Charitable Trust.

References

1. Ferbert, A. and M. Gerwig, *Tremor due to stroke*. Movement Disorders, 1993. **8**(2): p. 179-182.
2. Krauss, J.K. and J. Jankovic, *Head Injury and Posttraumatic Movement Disorders*. Neurosurgery, 2002. **50**(5): p. 927-939.
3. Benabid, A.L., et al., *Chronic electrical stimulation of the ventralis intermedius nucleus of the thalamus as a treatment of movement disorders*. Journal of Neurosurgery, 1996. **84**: p. 203-214.
4. Schuurman, P.R., et al., *A comparison of continuous thalamic stimulation and thalamotomy for suppression of severe tremor*. New England Journal of Medicine, 2000. **342**: p. 461-468.
5. Bittar, R.G., et al., *Thalamotomy versus thalamic stimulation for multiple sclerosis tremor*. Journal of Clinical Neuroscience, 2005. **12**(6): p. 638-642.

6. Foote, K.D. and M.S. Okun, *Ventralis Intermedius plus Ventralis Oralis Anterior and Posterior Deep Brain Stimulation for Posttraumatic Holmes Tremor: Two Leads May Be Better than One: Technical Note*. Neurosurgery, 2005. **56**(2 Suppl.): p. E445.
7. Umemura, A., et al., *Thalamic deep brain stimulation for posttraumatic action tremor*. Clinical Neurology and Neurosurgery, 2004. **106**: p. 280-283.
8. Broggi, G., et al., *A case of posttraumatic tremor treated by chronic stimulation of the thalamus*. Movement Disorders, 1993. **8**(2): p. 206-208.
9. Diederich, N.J., et al., *Ventral Intermediate Thalamic Stimulation in Complex Tremor Syndromes*. Stereotactic and Functional Neurosurgery, 2008. **86**: p. 167-172.
10. Kudo, M., et al., *Bilateral thalamic stimulation for Holmes' tremor caused by unilateral brainstem lesion*. Movement Disorders, 2001. **16**: p. 170-174.
11. Bain, P.G., et al., *Assessing tremor severity*. Journal of Neurology, Neurosurgery and Psychiatry, 1993. **56**(8): p. 868-873.
12. Deuschl, G., et al., *Consensus Statement of the Movement Disorder Society on Tremor*. Movement Disorders, 1998. **13**(Supplement 3): p. 2-23.
13. Elble, R.J., *Animal Models of Action Tremor*. Movement Disorders, 1998. **13**(Suppl. 3): p. 35-39.
14. Nandi, D., et al., *Electrophysiological confirmation of the zona incerta as a target for surgical treatment of disabling involuntary arm movements in multiple sclerosis: use of local field potentials*. Journal of Clinical Neuroscience, 2002. **9**(1): p. 64-68.
15. Hyam, J., et al., *Contrasting connectivity of the Vim and Vop nuclei of the motor thalamus demonstrated by probabilistic tractography*. Neurosurgery, 2012. **70**(1): 162-9

Case	Sex	Tremor side	Age of onset	Age at surgery	Follow-up (months)	Etiology	Side effects
1	M	L	11	30	78	RTA, MRI shows cerebellar atrophy	None noted
2	M	R	36	40	24	Right vertebral artery occlusion	Worsening of jerk-like movements if amplitude exceeds 3.3mA
3	F	R	23	40	46	Right hemisphere periorolandic infarction during pregnancy	None noted
4	F	R	40	43	12	Right midbrain haematoma, involving right cerebellar peduncle	None noted
5	M	R	11	30	78	RTA, MRI shows cerebellar atrophy	None noted
6	M	L	14	24	24	RTA, diffuse axonal injury to frontal lobes + left cerebellum	None noted
7	F	R	64	68	6	Ischaemic CVA, diffuse damage and large left thalamic infarct	Postural tremor well suppressed with arm outstretched but more troublesome with arm bent and on intention. Right leg heaviness and dragging of leg when walking.
8	M	L	20	22	12	RTA, diffuse injury involving brainstem + fluid on cerebellum	Transient pins and needles on changing settings but no other lasting symptoms

Table 1: Table 1. Summary of clinical characteristics for patient's involved in this study. RTA=Road Traffic Accident, AVM=Arteriovenous Malformation, CVA=Cerebrovascular Accident.¹

Patient	Electrode side	Electrode configuration	Electrode contacts in the target areas	Stimulation parameters	Angle between electrode and AC PC line in sagittal plane	Stereotactic co-ordinates of active contacts relative to AC-PC line
1	Left	Case (+), 3(-) <i>(monopolar)</i>	<i>0 in ZI</i>	2.0V, 90 μ s, 130Hz	64 degrees	7.3 posterior, 12.2 left, 2.5 inferior 2.0 posterior, 14.5 left, 6.3 superior
2	Right	3(+), 2(-)	<i>1 in ZI, 2 and 3 in VOP</i>	2.5V, 90 μ s, 130Hz	68 degrees	0.8 anterior, 10.4 left, 4.6 superior 0.4 posterior, 9.1 left, 2.5 superior
3	Right	9(-), 10(+)	<i>10 in ZI, 11 in VOP</i>	3.0V, 210 μ s, 100Hz	49 degrees	3.2 posterior, 12.0 right, 1.6 inferior 2.8 posterior, 12.6 right, 1.9 superior
4	Right	4(-), 6(+)	<i>0 in ZI, 2 and 3 adjacent to VOP</i>	1.5V, 90 μ s, 130Hz	80 degrees	5.1 posterior, 13.1 right, 2.5 inferior 3.7 posterior, 14.7 right, 2.9 superior
5	Right	5(-), 7(+)	-	2.3V, 210 μ s, 180Hz	-	-
6	Left	3(+), 2(-)	-	3.6V, 360 μ s, 130Hz	-	-
7	Right	0(-), 2(+)	-	2.6V, 300 μ s, 130Hz	-	-
8	Left	1(+), 3(-)	<i>1 in ZI, 2 and 3 in VOP</i>	3.3V, 156 μ s, 130Hz	60 degrees	3.1 posterior, 10.8 right, 3.2 inferior 0.7 posterior, 13.9 right, 2.3 superior

Table 2: Active electrode contacts, stimulation parameters and stereotactic co-ordinates for each patient where data is available. A dash indicates unavailable data due to missing scans. Numbering of contacts is based on 2 different systems; older devices have contacts numbered 0-3 and 4-7 while newer devices have contacts numbered 0-3 and 8-11. Column 4 shows which contacts fall within the target area based on the Schaltenbrand & Wahren atlas

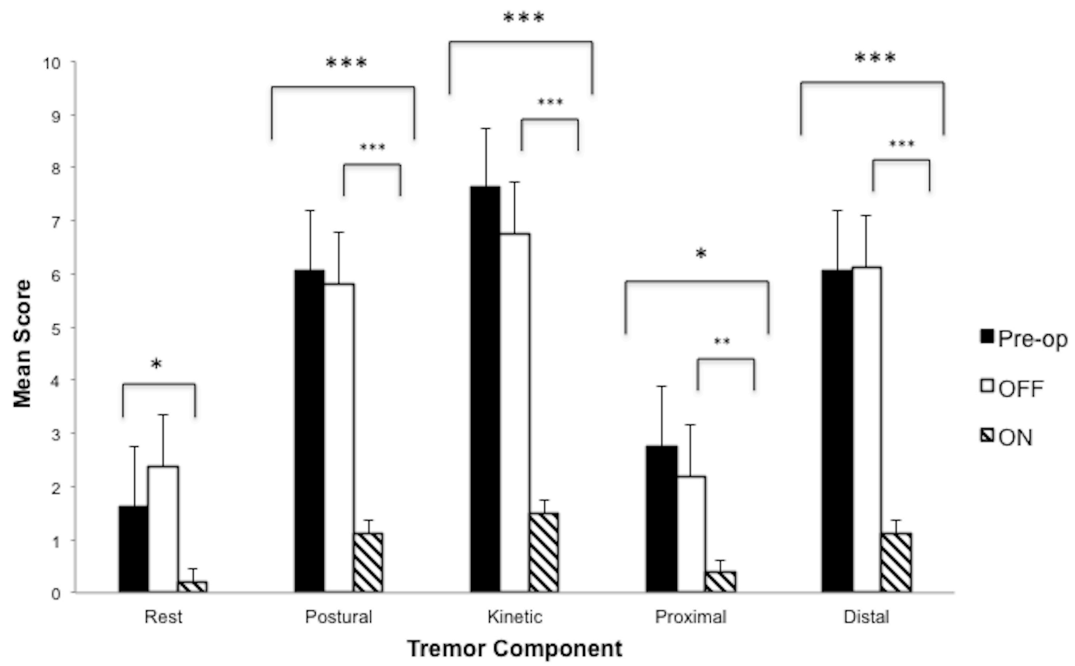


Figure 1 Mean component scores for rest, postural, kinetic, proximal and distal elements across all assessed conditions (preoperative n=6, ON stimulation n=8, OFF stimulation n=5). Error bars are shown as SE of the mean (*p<0.05, **p<0.01, ***p<0.001, two-tailed independent t test).

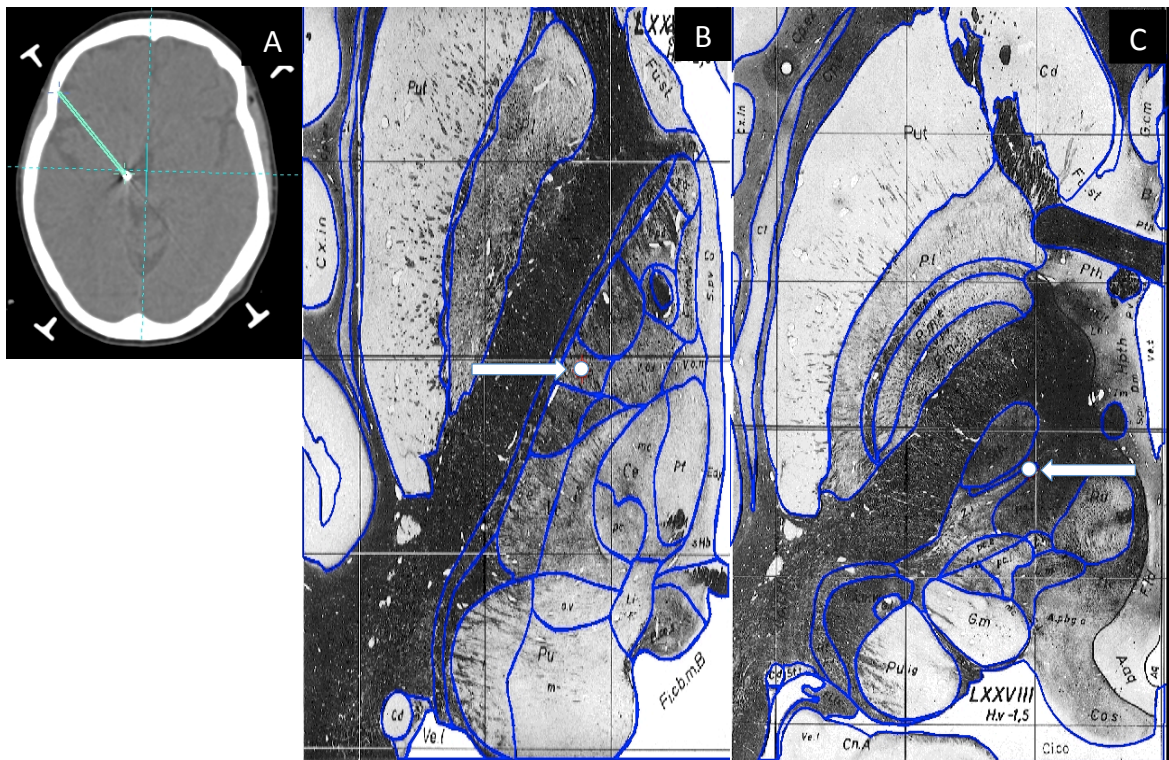


Figure 2: Electrode trajectory (A) and location of active contacts (white circle indicated by white arrow) for a single patient (patient 3) displayed on Schaltenbrand–Wahren atlas. (B) Contact 11, located in ventro-oralis posterior and (C) contact 10 in zona incerta.