

UNIVERSITY OF BIRMINGHAM

Research at Birmingham

A rare cause of ascites: pseudomyxoma peritonei and a review of the literature

Chauhan, Abhishek; Patodi, Nishant; Ahmed, Monz

DOI:

[10.1002/ccr3.188](https://doi.org/10.1002/ccr3.188)

License:

Creative Commons: Attribution (CC BY)

Document Version

Publisher's PDF, also known as Version of record

Citation for published version (Harvard):

Chauhan, A, Patodi, N & Ahmed, M 2015, 'A rare cause of ascites: pseudomyxoma peritonei and a review of the literature', *Clinical Case Reports*, vol. 3, no. 3, pp. 156-159. <https://doi.org/10.1002/ccr3.188>

[Link to publication on Research at Birmingham portal](#)

Publisher Rights Statement:

Eligibility for repository : checked 19/10/2015

General rights

Unless a licence is specified above, all rights (including copyright and moral rights) in this document are retained by the authors and/or the copyright holders. The express permission of the copyright holder must be obtained for any use of this material other than for purposes permitted by law.

- Users may freely distribute the URL that is used to identify this publication.
- Users may download and/or print one copy of the publication from the University of Birmingham research portal for the purpose of private study or non-commercial research.
- User may use extracts from the document in line with the concept of 'fair dealing' under the Copyright, Designs and Patents Act 1988 (?)
- Users may not further distribute the material nor use it for the purposes of commercial gain.

Where a licence is displayed above, please note the terms and conditions of the licence govern your use of this document.

When citing, please reference the published version.

Take down policy

While the University of Birmingham exercises care and attention in making items available there are rare occasions when an item has been uploaded in error or has been deemed to be commercially or otherwise sensitive.

If you believe that this is the case for this document, please contact UBIRA@lists.bham.ac.uk providing details and we will remove access to the work immediately and investigate.

CASE REPORT

A rare cause of ascites: pseudomyxoma peritonei and a review of the literature

Abhishek Chauhan^{1,2}, Nishant Patodi¹ & Monz Ahmed¹

¹Department of Gastroenterology, Good Hope Hospital, Sutton, Coldfield, United Kingdom

²University of Birmingham, Edgbaston, Birmingham, B15 2TT, United Kingdom

Correspondence

Abhishek Chauhan, 51, Camp Lane, Kings Norton, Birmingham B38 8SL, United Kingdom. Tel: +44 7515359460; Fax: +44 1214261052; E-mail: abhichauhan@mac.com

Funding Information

The Wellcome Trust has helped to fund this report.

Received: 8 July 2014; Revised: 12

September 2014; Accepted: 25 October 2014

Clinical Case Reports 2015; 3(3): 156–159

doi: 10.1002/ccr3.188

Case Presentation

A 75-year-old gentleman was referred to outpatient gastroenterology services due to a 3-month history of weight loss, abdominal pain, and abdominal distension. His past medical history was significant for atrial fibrillation, hypertension, bilateral knee replacements, and obstructive sleep apnoea. On presentation to the outpatient clinic, the patient appeared cachectic with marked abdominal distension. The patient denied significant alcohol consumption and a thorough history ruled out any risk factors for liver disease. He did, however, admit to increasing lethargy and malaise. Examination confirmed generalized muscle wasting; abdominal palpation revealed a huge epigastric mass and abdominal distension consistent with ascites. No signs of chronic liver disease were seen.

Differential Diagnosis

The weight loss and ascites point toward a diagnosis of malignancy, possibly disseminated. Isolated right or biventricular failure remains a possibility especially, given the associated lethargy. Although unlikely in the absence of signs of chronic liver disease and compatible history,

Key Clinical Message

Pseudomyxoma peritonei is rare. The rarity is highlighted by the lack of published evidence regarding management. The latest treatments have altered the prognosis of a once incurable disease. This report serves to both raise awareness and critically appraise the literature regarding the latest management.

Keywords

Ascites, mucinous adenocarcinoma, mucinous ascites, peritoneal mucinous tumor, pseudomyxoma peritonei.

decompensated liver disease remains in the differential diagnosis and was therefore investigated for other rarer differentials encompassing tuberculosis and sarcoidosis.

In the author's experience, in a gentleman presenting with ascites, the "default" diagnosis appears to be decompensated alcoholic liver disease. Such stereotyping is unacceptable and undoubtedly results in missed diagnoses, poor clinical care, and is a source of anxiety and distress amongst patients. In this patient, a thorough alcohol consumption history and clinical examination by the admitting team helped avoid this.

Investigations

Blood investigations were essentially normal apart from a raised Ca19-9 (208) and CEA (88) levels. An ascitic tap revealed an almost gelatinous, straw-colored fluid. Cytological analysis of the fluid revealed the presence of foamy cytoplasm-containing mesothelial cells with eccentric nuclei (mucin-containing epithelial cells). A liver screen was negative.

Computed tomography (CT) of the abdomen revealed extensive ascites and a large cystic tubular structure measuring 15 × 6 cm, consistent with an appendiceal muco-

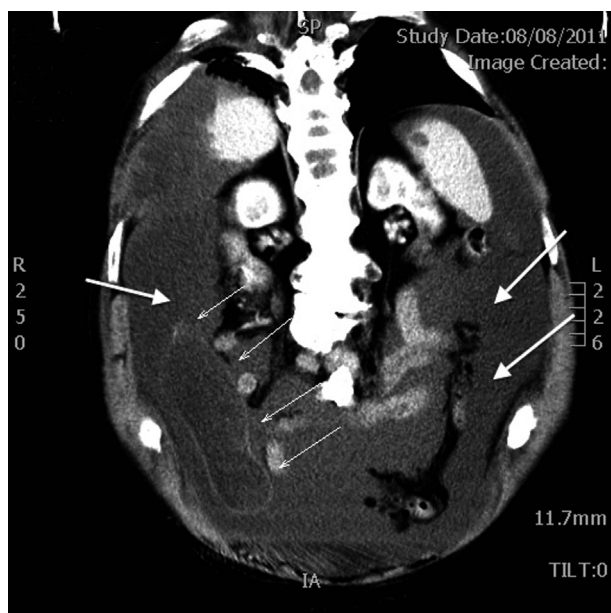


Figure 1. Coronal CT scan. The thin arrows highlight the appendiceal mucocele. The thick arrows highlight the ascites.

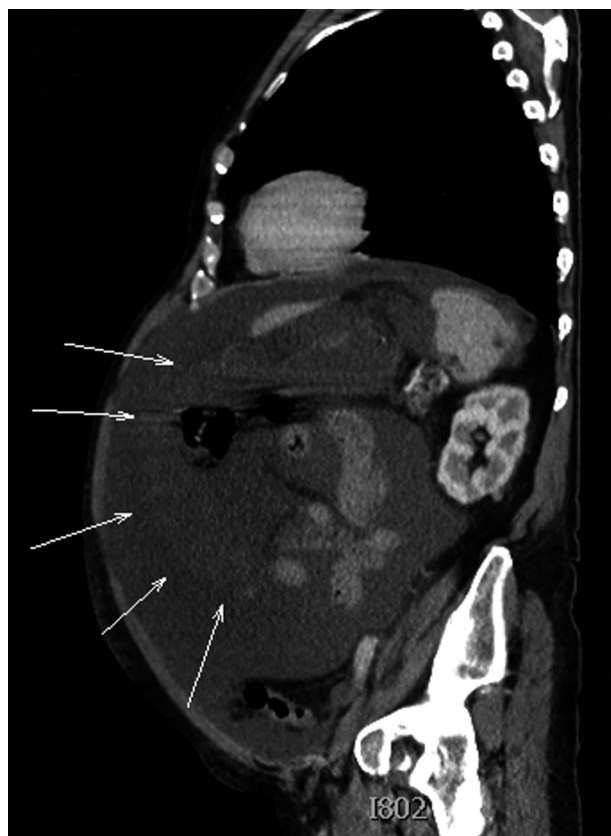


Figure 2. Sagittal view. The arrows highlight the omental cake.

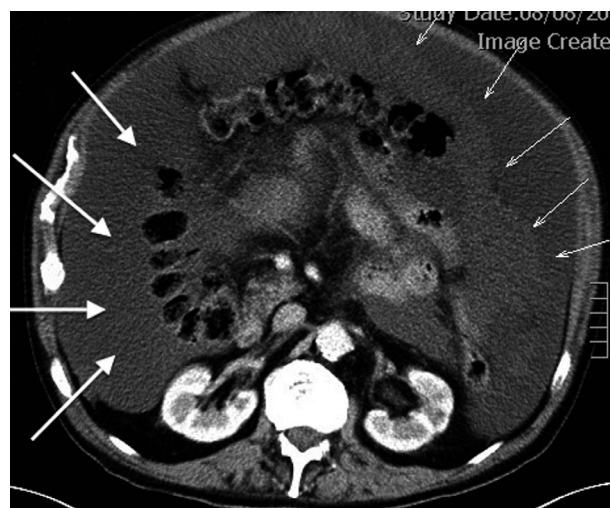


Figure 3. Transverse view. The thin arrows highlight the extensive omental cake and the thick arrows again point towards the ascites.

cele (Fig. 1, coronal section). Further, sections of the CT scan (Sagittal and Transverse) revealed extensive omental caking in the epigastric region (Figs. 2 and 3).

Outcome and Follow Up

The patient underwent an extensive debulking operation; histology from peritoneal and adipose tissue revealed disseminated peritoneal adenomucinosis (DPAM). He has subsequently had heated intraperitoneal chemotherapy (HIPEC) (mitomycin C), and is in clinical remission.

Literature Review

Pseudomyxoma peritonei (PMP) is a rare diagnosis with an incidence of 1–2 per million [1]. Coined by Werth in 1884 [2], PMP was initially thought of as a peritoneal reaction to the “jelly-like” secretions produced by an ovarian neoplasm [1]. Points of contention as to the exact origin of this condition, especially in women, stem from the fact that synchronous appendiceal and ovarian disease is common and the overall female preponderance for PMP [3]. Immunohistochemistry and molecular genetics have, however, lent strength to the current concept of an appendiceal origin for the vast majority of PMP in both men and women [1].

Most cases originate from a minimally invasive mucinous epithelial neoplasm (as mentioned above primarily appendiceal but ovarian and colonic sources have also been described), which eventually ruptures and releases mucinous tumor cells into the peritoneal cavity [4]. These cells show a high propensity for spread to peritoneal surfaces, but almost no lymphatic or hematogenous metastases [5]. Accumulation and the reproduction of free and

implanted tumor cells leads to progressive peritoneal mucinous tumor and ascites [4]. The disease is characterized by diffuse intra-abdominal gelatinous collections (jelly belly) with mucinous implants on peritoneal surfaces and the omentum [4]. The locoregional progression of the disease (redistribution phenomenon) [6] results in intestinal failure and malnutrition secondary to raised intra-abdominal pressure, fistula formation, and infection [7], hence the associated considerable mortality and morbidity. Ronnett et al. proposed three pathological subtypes of the condition [8]. DPAM, a low-grade lesion with a good prognosis; peritoneal mucinous adenocarcinoma (PMCA), which is histopathologically a high-grade metastatic adenocarcinoma, usually derived from the appendix and colon, with a poor prognosis; and intermediate type PMP (PMCA-I), which includes lesions that demonstrate predominantly features of DPAM, but also contain focal areas of PMCA (intermediate prognosis) [9]. Other classification systems exist but the one devised by Ronnett et al. is the most commonly used one.

The imaging and staging modality of choice is abdominal CT scanning [10], with scalloping and characteristic patterns of disease on visceral surfaces being almost pathognomic of PMP. In most cases, the striking feature is the relative sparing of the small bowel and its mesentery, with the small bowel “compartmentalized” in the center of the abdomen by a large omental cake [11]. Septa, curvilinear or amorphous calcification, areas of soft tissue attenuation due to solid elements within mucinous material and compressed mesentery are seen as the volume of disease increases [12]. Lee et al. argue that due to high water content, mucin has a similar appearance to water on both CT and MR imaging, but when the mucin produced is thick and proteinaceous then it tends to be hyperdense compared to water and hyperintense on T1- and hypointense on T2-weighted images. The role of MR imaging in PMP is, however, yet to be established [13].

Although anaemia is a common finding, laboratory studies are of very limited use in diagnosing PMP, with the definitive diagnosis usually being established at laparotomy [14]. Tumor markers CEA, CA-19.9, and CA-125 are raised, the specificity and sensitivity of these markers in PMP has not been extensively studied and therefore their diagnostic utility in PMP is likely to be restricted at best. Baratti et al. however demonstrate a role for these markers in post-treatment prognostication. They reveal a correlation between a normal preoperative CA-125 with the likelihood of achieving adequate cytoreduction at surgery (a significant prognostic factor for PMP) and go on to suggest that an increased baseline CA19.9 is an independent inverse predictor of progression-free survival after treatment [15]. Tumor markers can be used to monitor response to treatment and as surveillance tools to look for recurrence.

In the past, this disease was uniformly fatal. Treatment was essentially restricted to interval debulking with no realistic prospect of long-term cure [6]. The natural history of the disease has substantially been altered by Sugarbaker et al., who in 1994 devised a procedure involving a radical peritonectomy aimed at removing as much macroscopic disease (cytoreductive surgery, CRS) as possible. The operation takes about 10 hours to complete and includes:

- Removal of the right hemicolon, spleen, gall bladder, greater omentum, and lesser omentum
- Stripping of the peritoneum from the pelvis and diaphragm
- Stripping of tumor from the surface of the liver
- Removal of the uterus and ovaries in women
- Removal of the rectum in some cases.

The surgery is followed by HIPEC to eliminate microscopic and residual disease (<http://publications.nice.org.uk/complete-cytoreduction-for-pseudomyxoma-peritonei-sugarbaker-technique-ipg56>). This remains the best treatment regime in patients medically fit enough. No clear strategy exists for patients not fit enough to undergo this complex and aggressive treatment; palliative interval debulking appears to be the favored option here, however there may be a role for systemic chemotherapy as well. Technically a demanding procedure, requiring specialized equipment, the Sugarbaker procedure is not without reasonable postoperative morbidity and mortality [1]. Major morbidity includes anastomotic leakage, enteric and pancreatic fistulation, pneumonia, thromboembolism, and intra-abdominal abscesses [16]. Morbidity from intraperitoneal chemotherapy (mitomycin C), takes the form of septic sequelae especially neutropenic sepsis [17].

Glehen et al. [18] report a median survival of 156 months, with 5- and 10-year survival of 72% and 55%, respectively, in 501 PMP patients who had undergone CRS (complete and incomplete) followed by HIPEC. The majority (~70%) had complete cytoreduction. This uniform treatment approach has shown improved 10-year survival, as compared with historical controls [19, 20]. Overall, however, long-term survival rates remain poor with 5 and 10-year survival rates of 50% and 10–30%, respectively [20–22].

Learning Points

- 1 PMP is no longer an incurable condition.
- 2 Once diagnosed, patients should be referred to a specialist unit early for further management.
- 3 Although technically curable, the morbidity from this condition is sizeable and a multidisciplinary approach with specialist input from the nutrition team is essential. Regular and thorough monitoring of nutritional status in patients earmarked for aggressive therapy is

appropriate, as if intestinal failure (known consequence of bulky PMP) is suspected parenteral nutrition may be necessary to optimize preoperative status.

- 4 In patients deemed not fit for very aggressive treatment, palliative options including limited debulking and systemic chemotherapy should be considered.

Conflict of Interest

None declared.

References

1. Bevan, K. E., F. Mohammed, and B. J. Moran. 2010. Pseudomyxoma peritonei. *World J. Gastrointest. Oncol.* 2:44–50. doi: 10.4251/wjgo.v2.i1.44
2. Werth, R. 1884. Klinische and Anatomische Untersuchungen Zur Lehre von der Bauchgeswullsten und der laparotomy. *Arch. Gynecol. Obstet.* 84:100–118.
3. Carr, N. J., J. Finch, I. C. Ilesley, K. Chandrakumaran, F. Mohamed, A. Mirnezami, et al. 2012. Pathology and prognosis in pseudomyxoma peritonei: a review of 274 cases. *J. Clin. Pathol.* 65:919–923.
4. Ioannidis, O., A. Cheva, G. Paraskevas, N. Papadimitriou, A. Konstantara, S. Chatzopoulos, et al. 2012. Pseudomyxoma retroperitonei: report of 2 cases and review of the literature. *Rev. Esp. Enferm. Dig.* 104:268–275.
5. Moran, B., D. Baratti, T. D. Yan, S. Kusamura, and M. Deraco 2008. Consensus statement on the loco-regional treatment of appendiceal mucinous neoplasms with peritoneal dissemination (pseudomyxoma peritonei). *J. Surg. Oncol.* 98:277–282. doi: 10.1002/jso.21054
6. Sugarbaker, P. H. 1994. Pseudomyxoma peritonei. A cancer whose biology is characterized by a redistribution phenomenon. *Ann. Surg.* 219:109–111.
7. Smeenk, R. M., V. J. Verwaal, N. Antonini, and F. A. Zoetmulder 2007. Survival analysis of pseudomyxoma peritonei patients treated by cytoreductive surgery and hyperthermic intraperitoneal chemotherapy. *Ann. Surg.* 245:104–109.
8. Ronnett, B. M., C. M. Zahn, R. J. Kurman, M. E. Kass, P. H. Sugarbaker, and B. M. Shmookler 1995. Disseminated peritoneal adenomucinosis and peritoneal mucinous carcinomatosis. A clinicopathologic analysis of 109 cases with emphasis on distinguishing pathologic features, site of origin, prognosis, and relationship to “pseudomyxoma peritonei”. *Am. J. Surg. Pathol.* 19:1390–1408.
9. Ronnett, B. M., H. Yan, R. J. Kurman, B. M. Shmookler, L. Wu, and P. H. Sugarbaker 2001. Patients with pseudomyxoma peritonei associated with disseminated peritoneal adenomucinosis have a significantly more favorable prognosis than patients with peritoneal mucinous carcinomatosis. *Cancer* 92:85–91.
10. Jacquet, P., J. S. Jelinek, D. Chang, P. Koslowe, and P. H. Sugarbaker 1995. Abdominal computed tomographic scan in the selection of patients with mucinous peritoneal carcinomatosis for cytoreductive surgery. *J. Am. Coll. Surg.* 181:530–538.
11. Sulkin, T. V., H. O’Neill, A. I. Amin, et al. 2002. CT in pseudomyxoma peritonei: a review of 17 cases. *Clin. Radiol.* 57:608–613.
12. Yang, D. M., D. H. Jung, H. Kim, J. H. Kang, S. H. Kim, J. H. Kim, et al. 2004. Retro- peritoneal cystic masses: CT, clinical, and pathologic findings and literature review. *Radiographics* 24:1353–1365.
13. Lee, N. K., S. Kim, H. S. Kim, T. Y. Jeon, G. H. Kim, D. U. Kim, et al. 2011. Spectrum of mucin-producing neoplastic conditions of the abdomen and pelvis: cross-sectional imaging evaluation. *World J. Gastroenterol.* 17:4757–4771. doi: 10.3748/wjg.v17.i43.4757
14. Jivan, S., and V. Bahal. 2002. Pseudomyxoma peritonei. *Postgrad. Med. J.* 78:170–172.
15. Baratti, D., S. Kusamura, and D. Nonaka. 2009. Pseudomyxoma peritonei: biological features are the dominant prognostic determinants after complete cytoreduction and hyperthermic intraperitoneal chemotherapy. *Ann. Surg.* 249:243–249. doi: 10.1097/SLA.0b013e3181818e64
16. Mohamed, F., T. Cecil, B. Moran, and P. Sugarbaker 2011. A new standard of care for the management of peritoneal surface malignancy. *Curr. Oncol.* 18:e84–e96.
17. Baratti, D., S. Kusamura, B. Laterza, M. R. Balestra, and M. Deraco 2010. Early and long-term postoperative management following cytoreductive surgery and hyperthermic intraperitoneal chemotherapy. *World J. Gastrointest. Oncol.* 2:36–43. doi: 10.4251/wjgo.v2.i1.36
18. Glehen, O., F. Mohamed, and P. H. Sugarbaker. 2004. Incomplete cytoreduction in 174 patients with peritoneal carcinomatosis from appendiceal malignancy. *Ann. Surg.* 240:278–285.
19. González-Moreno, S., and P. H. Sugarbaker. 2004. Right hemicolectomy does not confer a survival advantage in patients with mucinous carcinoma of the appendix and peritoneal seeding. *Br. J. Surg.* 91:304–311.
20. Hinson, F. L., and N. S. Ambrose. 1998. Pseudomyxoma peritonei. *Br. J. Surg.* 85:1332–1339.
21. Spyropoulos, C., A. Rentis, E. Alexaki, J. K. Triantafyllidis, and C. Vagianos. 2014. Appendiceal mucocele and pseudomyxoma peritonei; the clinical boundaries of a subtle disease. *Am. J. Case Rep.* 15:355–360. doi: 10.12659/AJCR.890837
22. Andréasson, H., T. Lorant, L. Pålman, W. Graf, and H. Mahteme. 2014. Cytoreductive surgery plus perioperative intraperitoneal chemotherapy in pseudomyxoma peritonei: aspects of the learning curve. *Eur. J. Surg. Oncol.* 40:930–936. doi: 10.1016/j.ejso.2014.03.001