

UNIVERSITY OF BIRMINGHAM

Research at Birmingham

Are There Progressive Brain Changes in Schizophrenia? A Meta-Analysis of Structural Magnetic Resonance Imaging Studies

Olabi, B; Ellison-Wright, I; McIntosh, AM; Wood, Stephen; Bullmore, E; Lawrie, SM

DOI:

[10.1016/j.biopsych.2011.01.032](https://doi.org/10.1016/j.biopsych.2011.01.032)

Document Version

Peer reviewed version

Citation for published version (Harvard):

Olabi, B, Ellison-Wright, I, McIntosh, AM, Wood, S, Bullmore, E & Lawrie, SM 2011, 'Are There Progressive Brain Changes in Schizophrenia? A Meta-Analysis of Structural Magnetic Resonance Imaging Studies', *Biological Psychiatry*, vol. 70, no. 1, pp. 88-96. <https://doi.org/10.1016/j.biopsych.2011.01.032>

[Link to publication on Research at Birmingham portal](#)

Publisher Rights Statement:

NOTICE: this is the author's version of a work that was accepted for publication in *Biological Psychiatry*. Changes resulting from the publishing process, such as peer review, editing, corrections, structural formatting, and other quality control mechanisms may not be reflected in this document. Changes may have been made to this work since it was submitted for publication. A definitive version was subsequently published in *Biological Psychiatry* [Volume 70, Issue 1, (1 July 2011)] <http://dx.doi.org/10.1016/j.biopsych.2011.01.032>

General rights

Unless a licence is specified above, all rights (including copyright and moral rights) in this document are retained by the authors and/or the copyright holders. The express permission of the copyright holder must be obtained for any use of this material other than for purposes permitted by law.

- Users may freely distribute the URL that is used to identify this publication.
- Users may download and/or print one copy of the publication from the University of Birmingham research portal for the purpose of private study or non-commercial research.
- User may use extracts from the document in line with the concept of 'fair dealing' under the Copyright, Designs and Patents Act 1988 (?)
- Users may not further distribute the material nor use it for the purposes of commercial gain.

Where a licence is displayed above, please note the terms and conditions of the licence govern your use of this document.

When citing, please reference the published version.

Take down policy

While the University of Birmingham exercises care and attention in making items available there are rare occasions when an item has been uploaded in error or has been deemed to be commercially or otherwise sensitive.

If you believe that this is the case for this document, please contact UBIRA@lists.bham.ac.uk providing details and we will remove access to the work immediately and investigate.

Are There Progressive Brain Changes in Schizophrenia? A Meta-Analysis of Structural Magnetic Resonance Imaging Studies

Bayanne Olabi, Ian Ellison-Wright, Andrew M. McIntosh, Stephen J. Wood, Ed Bullmore, and Stephen M. Lawrie

Background: It is well established that schizophrenia is associated with structural brain abnormalities, but whether these are static or progress over time remains controversial.

Methods: A systematic review of longitudinal volumetric studies using region-of-interest structural magnetic resonance imaging in patients with schizophrenia and healthy control subjects. The percentage change in volume between scans for each brain region of interest was obtained, and data were combined using random effects meta-analysis.

Results: Twenty-seven studies were included in the meta-analysis, with 928 patients and 867 control subjects, and 32 different brain regions of interest. Subjects with schizophrenia showed significantly greater decreases over time in whole brain volume, whole brain gray matter, frontal gray and white matter, parietal white matter, and temporal white matter volume, as well as larger increases in lateral ventricular volume, than healthy control subjects. The time between baseline and follow-up magnetic resonance imaging scans ranged from 1 to 10 years. The differences between patients and control subjects in annualized percentage volume change were -0.07% for whole brain volume, -0.59% for whole brain gray matter, -0.32% for frontal white matter, -0.32% for parietal white matter, -0.39% for temporal white matter, and $+0.36\%$ for bilateral lateral ventricles.

Conclusions: These findings suggest that schizophrenia is associated with progressive structural brain abnormalities, affecting both gray and white matter. We found no evidence to suggest progressive medial temporal lobe involvement but did find evidence that this may be partly explained by heterogeneity between studies in patient age and illness duration. The causes and clinical correlates of these progressive brain changes should now be the focus of investigation.

Key Words: Longitudinal studies, meta-analysis, schizophrenia, structural MRI, systematic review

The issue of whether schizophrenia is a progressive brain disorder has been unresolved since the time of Emil Kraepelin (1). He described an early-onset dementia with progressive mental deterioration because of degeneration of the frontal and temporal neocortices. More than 100 years later, disease progression in schizophrenia remains a disputed topic among researchers (2–4). Some early longitudinal pneumoencephalography and computed tomography studies reported progressive increases in ventricular size in patients over time (5–7) but the majority did not (8–15). These studies tended, however, to have no control subjects for comparison, could only make measurements with considerable error, and did not have sufficient power to detect relatively subtle changes over time.

Whether or not there are progressive structural brain changes in schizophrenia is of fundamental importance as to whether schizophrenia is a neurodevelopmental or neurodegenerative disorder

From the Division of Psychiatry (BO, AMM, SML), School of Molecular and Clinical Medicine, University of Edinburgh, Royal Edinburgh Hospital, Edinburgh; Avon and Wiltshire Mental Health Partnership National Health Service Trust (IE-W), Salisbury; Department of Psychiatry (IE-W, EB), Behavioural & Clinical Neuroscience Institute, University of Cambridge, Cambridge; and School of Psychology (SJW), University of Birmingham, Edgbaston, United Kingdom; and Melbourne Neuropsychiatry Centre (SJW), Department of Psychiatry, The University of Melbourne and Melbourne Health, Melbourne, Australia.

Address correspondence to Stephen M. Lawrie, M.D., University of Edinburgh, Division of Psychiatry, Royal Edinburgh Hospital, Kennedy Tower, Edinburgh EH10 5HF, UK; E-mail: S.Lawrie@ed.ac.uk.

Received Oct 28, 2010; revised Jan 21, 2011; accepted Jan 22, 2011.

0006-3223/\$36.00
doi:10.1016/j.biopsych.2011.01.032

(16). The neurodevelopmental model posits that disturbances caused by susceptibility genes and environmental insults occurring during early life cause developmental brain insults that culminate in the onset of schizophrenia decades later (17–20). This is supported by observations that obstetric complications are associated with schizophrenia in later life (21,22), that aberrant early postnatal brain maturation and synaptogenesis are possible in those who later develop schizophrenia (23,24), that there is an absence of gliosis at postmortem (25), and that several brain morphology studies have demonstrated structural brain volume differences even before the emergence of psychotic symptoms (26–28). The dichotomy of the neurodevelopmental and neurodegenerative hypotheses is, however, somewhat artificial, as the pathophysiology of schizophrenia may encompass both processes.

The hypothesis that schizophrenia has a progressive and even neurodegenerative component has re-emerged in recent years, based primarily on some prospective longitudinal magnetic resonance imaging (MRI) studies (29–33). Studies addressing the issue of progressive brain structural changes during the course of the schizophrenia have, however, yielded mixed results (2–4). An available technique to resolve such discrepancies is to conduct a systematic review and meta-analysis of the literature. Several meta-analyses have demonstrated replicable abnormalities in cross-sectional MRI studies of patients with first-episode and chronic schizophrenia. Reductions in whole brain and gray matter volume, primarily in the prefrontal and temporal lobes, and enlargement of the lateral ventricles compared with healthy control subjects are among the most replicated findings (34–37), which are largely evident at first episode (38,39). Two anatomic likelihood estimation meta-analyses of cross-sectional, voxel-based morphometry MRI studies have identified structural morphometric differences between studies of patients with first-episode schizophrenia and

those of chronic schizophrenia, suggesting progressive brain changes during the course of the illness (40,41), although such comparisons between two sets of cross-sectional design case-control studies are unable to exclude the possibility that apparent differences related to chronicity of illness simply reflect the selection of more severely ill patients in samples of chronic schizophrenia. A meta-analysis of longitudinal studies is therefore required to clarify the course of putative progressive structural abnormalities in schizophrenia. The need for this evidence was highlighted at a meeting attended by researchers worldwide held by the American College of Neuropsychopharmacology (42). The aim of this systematic review and meta-analysis was to quantitatively characterize any morphometric differences over time in patients with schizophrenia compared with healthy control subjects by 1) identifying prospective longitudinal MRI studies measuring tissue volume in regions of interest (ROIs), and 2) synthesizing findings from these eligible primary studies using random-effects meta-analysis.

Methods and Materials

Literature Search

A comprehensive search of the electronic databases EMBASE (from 1980), PsycINFO (from 1801), and Ovid MEDLINE (from 1950) was conducted using the following search strategy: ([Magnetic Resonance Imaging] OR [MRI]) AND ([Schizophrenia] OR [schizo*]) AND ([Cohort] OR [Prospective] OR [Longitudinal] OR [Follow-up] OR [Follow adj2 up] OR [Repeat] OR [Reassessed] OR [Change adj2 time]). Both free-text and expanded medical subject headings were used. The search strategy was supplemented using a cited reference search and by inspecting the reference lists and citing articles of included papers. The initial search was conducted in May 2009 and was then updated to the end of September 2009.

Criteria for Inclusion/Exclusion

Studies were considered for the review using the following inclusion criteria: 1) they were published in English as a peer-reviewed article (rather than a letter, abstract, or case report); 2) they compared a sample of formally diagnosed subjects with a group of unrelated healthy control subjects; 3) cases and control subjects were followed-up over a specified time period, with two or more MRI scans taken; 4) they used ROI volumetric analysis of structural MRI data; and 5) the means and standard deviations of the volume change over time of the brain region under study were reported (or could be extracted or retrieved from the authors) for both cases and healthy control subjects. Studies of both child-onset schizophrenia (COS) and adult-onset schizophrenia (AOS) were included.

Studies were excluded if 1) there were insufficient data to extract the number of subjects in each group; 2) there were fewer than five subjects in either the schizophrenia group or the comparison group; 3) the comparison groups consisted of patients with minor nonpsychiatric illnesses; 4) the structure measurement was an area (from a single slice) rather than a volume (i.e., from multiple slices); 5) the studies used the voxel-based morphometry, deformation-based morphometry, or tensor-based volumetric method for measuring brain regional volumes; and 6) the data contributed to another publication, in which case the publication with the largest group size for each specific brain region under study was selected.

Data Abstraction

Clinical heterogeneity, sample characteristics, and anatomical landmarks for ROI are likely to be the main factors leading to heterogeneous results. Therefore, data extracted from the studies included the authors, year of publication, demographic variables (number of subjects, age at baseline, gender, and handedness),

illness variables (diagnosis and duration of illness), duration of follow-up, and the mean and standard deviation of the percentage change in volume of each of the brain regions under study. The percentage volume change over time in each study was calculated using the following formula:

$$\frac{(\text{Volume at follow-up} - \text{Volume at baseline})}{\text{Volume at baseline}} \times 100$$

We also calculated the sex and handedness distributions and the total numbers of subjects according to the original studies.

Statistical Analysis

Cohen's estimator of standardized effect size and its variance was calculated from each study using pooled means and standard deviations. When articles provided data for defined subgroups (for example, by sex or illness stage), data were combined such that each study contributed only one data point per region of interest to the meta-analysis.

Standardized effect sizes were combined to produce a single summary estimate using random-effects techniques based on the method of maximum likelihood (43). We also estimated annualized rates of tissue loss in patients and control subjects by dividing the percentage volume change over time in each study by the mean interscan interval. We used these as the raw means for meta-analysis and combined them by the Cooper-Hedges method (44).

Publication bias was assessed using Egger's test. The magnitude of between-study heterogeneity was estimated using the I^2 statistic (a measure of the proportion of variance in summary effect size because of heterogeneity) and its statistical significance calculated using Cohen's q (45). Significant heterogeneity was then explored using weighted linear regression, with the study effect size as the independent variable and either age, interscan interval, or illness duration before baseline separately as the dependent variable.

Statistical analysis was performed using R (R Foundation for Statistical Computing, Vienna, Austria; <http://www.R-project.org>). The meta package was used to perform all statistical summaries except for the meta-regression analyses, which were performed using the lme package.

Results

The electronic literature search of the three databases yielded 486 articles, of which 151 were retrieved in full-text format (Figure S1 in Supplement 1). Fifty-three studies were identified as being potentially appropriate to be included in the meta-analysis. However, seven of these studies concerned regions that were not examined in any other paper and so were not suitable for meta-analysis. Several studies did not report means and standard deviations of brain volume changes over time, in which case we contacted the study authors and requested additional data. Most authors complied with our requests but data from six studies were unavailable upon request. A further 13 studies were excluded on the basis of publishing data on overlapping patient groups, in which case we took the most recent and largest data set.

Twenty-seven patient cohorts from 25 different articles were identified as suitable to be included in the meta-analysis, having published both baseline and follow-up ROI volumetric measures using structural MRI techniques and containing sufficient data, including means and standard deviations of percentage volume changes of defined brain regions in schizophrenia patients and healthy control subjects. We also contacted the corresponding authors of articles for complementary information where necessary. Different brain regions were investigated in each study, with whole

Table 1. Demographic Characteristics of Included Study Populations

Study First Author (Year) (Reference)	Schizophrenic Subjects						Control Subjects				
	<i>n</i>	% M	% RH	Age at Initial MRI (Years)	Illness Duration (Years)	Duration of Inter-MRI Interval (Years)	<i>n</i>	% M	% RH	Age at Initial MRI (Years)	Duration of Inter-MRI Interval (Years)
DeLisi (1997) (29)	50	65	—	27.4	1.2	4.7	20	60	—	26.5	4.3
Nair (1997) (46)	18	78	—	30.9	8.6	2.6	5	40	—	40.6	2.6
Gur (1998) (47)	40	58	—	29.2	5.7	2.5	17	76	—	31.9	2.7
Rapoport (1999) (48)	15	40	73	13.9	3.6	4.2	34	50	88	12.8	4.3
Saijo (2001) (30)	18	50	—	37.5	15.1	10.0	12	58	—	37.1	10.0
Wood (2001) (49)	42	71	—	25.2	3.1	2.0	26	54	—	23.8	2.2
Cahn (2002) (31)	34	85	91	26.2	1.4	1.1	36	83	86	24.5	1.0
James (2002, 2004) (50,51)	9	100	100	17.7	2.0	2.4	9	100	69	15.7	1.7
	7	0	80	15.3	1.0	3.1	7	0	60	16.4	1.7
Ho (2003) (52)	73	73	—	24.5	3.0	3.3	23	65	—	26.9	3.4
Kasai (2003) (53)	13	77	79	27.2	.4	1.4	14	93	79	25.6	1.6
Keller (2003) (54)	35	57	60	14.5	4.2	2.4	34	59	82	14.5	2.8
Sporn (2003) (55)	39	61	—	15.0	4.6	2.4	43	63	—	14.8	2.7
DeLisi (2004) (56)	26	65	96	27.4	1.2	10.0	10	60	90	26.5	10.0
Molina (2005) (57)	29	69	100	27.8	4.5	2.2	11	55	100	28.4	2.3
Whitworth (2005) (58)	38	100	100	23.7	3.9	2.9	20	100	100	27.8	3.7
Addington (2007) (59)	49	61	67	14.5	5.8	2.4	107	62	93	14.5	2.8
Nakamura (2007) (60)	17	82	77	24.7	—	1.5	26	85	75	23.6	1.5
Brans (2008) (61)	19	53	89	38.6	15.7	5.0	54	63	76	35.5	4.8
Rais (2008) (33)	51	88	88	22.7	1.0	5.3	31	81	84	24.7	5.2
van Haren (2008) (32)	96	73	86	32.2	11.0	4.8	113	67	85	35.3	4.9
Wang (2008) (62)	56	66	—	36.6	15.7	2.2	62	55	—	36.2	2.2
Koolschijn (2009) (63)	68	79	85	34.5	12.6	4.8	83	66	87	38.0	4.9
Mitelman (2009) (64,65)	49	86	96	42.7	18.7	4.1	16	56	100	41.6	4.2
Reig (2009) (66)	16	100	94	15.7	.3	2.0	21	100	86	15.2	2.0
	5	0	80	15.7	.3	2.0	13	0	85	15.2	2.0
Yoshida (2009) (67)	16	100	80	38.6	16.3	3.1	20	100	80	40.9	1.4

Data for age at initial MRI, illness duration, and duration of inter-MRI interval are expressed as means.

M, male subjects; MRI, magnetic resonance imaging; *n*, number of subjects; RH, right-handed patients; —, no data available.

brain volume and lateral ventricular volume changes reported most often. Table 1 summarizes the information about demographic and clinical variables of the subjects and control subjects in the 27 independent patient cohorts we identified.

A total of 1795 subjects in the 27 studies were included, which comprised 928 patients and 867 control subjects. Among the patient group, the smallest size sample was 13 schizophrenia patients (53), and the largest size sample was 96 schizophrenia patients (32). These studies were published from 1997 to 2009.

Demographic Characteristics

The mean age of patients with schizophrenia in the included studies ranged from 13.9 to 42.7 years. Altogether seven studies (48,50,51,54,55,59,66) comprised samples of people with childhood- or adolescent-onset schizophrenia. The youngest patient sample was from a study of childhood-onset schizophrenia (mean age = 13.9 years, SD = 2.3) (48). The remaining 19 studies were all adult patient samples ranging from a mean of 22.7 years (33) to 42.7 years (64,65). The percentage of male patients in each study ranged from 40% to 100% (48,58,67), with male patients greatly outnumbering female patients overall (male patients *n* = 668, female patients *n* = 260).

Meta-Analysis

Random effects analyses were conducted for the 32 ROI and results presented in Figure 1 and Table 2.

Whole Brain and Lateral Ventricles. Greater global brain volume reductions were found in patients with schizophrenia over

time in subjects compared with healthy control subjects (*n* = 14 studies; Cohen's *d*: $-.40$; 95% confidence interval [CI]: $-.62$ to $-.19$) (Figure 1). This effect was also significant for whole brain gray matter (*n* = 12; *d*: $-.52$; 95% CI: $-.76$ to $-.28$), although no differences were found for whole brain white matter, whole brain cerebrospinal fluid, and cerebellar volume.

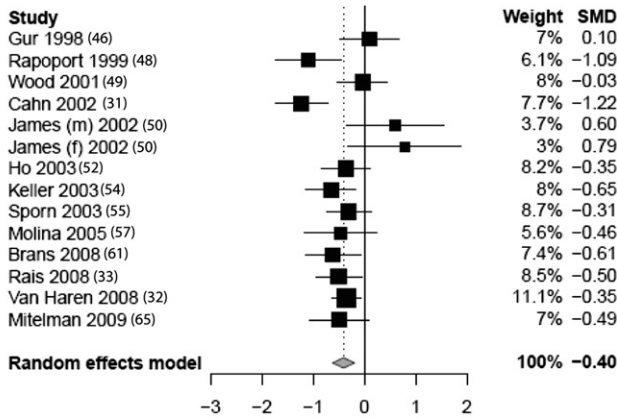
The analyses also demonstrated greater increases in bilateral lateral ventricular volume over time in subjects with schizophrenia compared with control subjects (*n* = 10; *d*: $.53$; 95% CI: $.28$ to $.78$) (Figure 1), whereas no significant difference in third ventricular volume change between groups was detected.

Frontal, Parietal, Temporal, and Occipital Lobes. There were significant reductions over time in patients with schizophrenia compared with control subjects in frontal lobe volume (*n* = 3; *d*: $-.48$; 95% CI: $-.78$ to $-.18$), frontal lobe gray matter (*n* = 9; *d*: $-.34$; 95% CI: $-.66$ to $-.02$), frontal lobe white matter (*n* = 5; *d*: $-.51$; 95% CI: $-.76$ to $-.26$), parietal lobe white matter (*n* = 4; *d*: $-.53$; 95% CI: $-.84$ to $-.23$), and temporal lobe white matter (*n* = 6; *d*: $-.49$; 95% CI: $-.76$ to $-.21$).

No significant differences were found between groups for frontal lobe cerebrospinal fluid, parietal lobe gray matter, parietal lobe cerebrospinal fluid, temporal lobe tissue, right and left temporal lobes, temporal lobe gray matter, temporal lobe cerebrospinal fluid, or occipital lobe gray and white matter.

Hippocampi, Amygdalae, and Caudate Nuclei. No significant differences between groups in hippocampal, amygdala, or right caudate volume change were detected, although greater pro-

A. Whole Brain



B. Lateral Ventricles

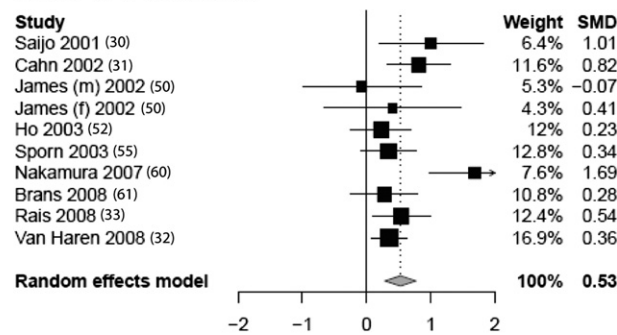


Figure 1. Forest plots (random effects) showing the mean difference in percentage change over time in (A) whole brain volume and (B) lateral ventricles in schizophrenia subjects and healthy control subjects. SMD, standard mean difference.

gressive decreases in left caudate volume were found in subjects with schizophrenia compared with control subjects ($n = 3$; $d = -.34$; 95% CI: $-.60$ to $-.07$).

Annual Percentage Changes. Using the Cooper-Hedges method, the annual percentage volume change difference between patients and control subjects were derived (Table S1 in Supplement 1). Where statistically significant differences emerged between patients and control subjects in terms of progression overall, the difference between patients and control subjects in annualized percentage volume change were $-.07\%$ for whole brain volume, $-.59\%$ for whole brain gray matter, $-.32\%$ for frontal lobe white matter, $-.32\%$ for parietal lobe white matter, $-.39\%$ for temporal lobe white matter, and $+36\%$ for bilateral lateral ventricles.

Publication Bias, Heterogeneity Bias, and Meta-Regression Analyses

Egger’s test and subsequent multiple comparisons correction analysis indicated that there was no significant relationship between study precision and estimated effect size for any brain region of interest considered by this meta-analysis, indicating no significant evidence of publication bias.

Statistically significant clinical heterogeneity was detected in several brain regions (whole brain volume, whole brain gray matter, whole brain white matter, bilateral lateral ventricles, left lateral ventricle, frontal gray matter, frontal cerebrospinal fluid, parietal gray matter, parietal cerebrospinal fluid, temporal gray matter, occipital gray matter, and right hippocampus). Regions in which no

heterogeneity was found and that showed significant differences in volume change over time include the frontal lobe tissue, frontal white matter, parietal white matter, and temporal white matter.

The modifying effects of age, illness duration, and interscan interval were investigated using meta-regression, to examine factors that could contribute to heterogeneity between study results. Although more than 20 individual tests were conducted, only three significant associations between these variables and effect size were revealed. Age at study entry was positively associated with the effect size in the right hippocampus. Because the overall estimate for this structure was negative, implying a greater reduction in subjects with schizophrenia, this finding suggests that the magnitude of this reduction diminishes with increasing age. Furthermore, illness duration before baseline was negatively associated with the effect size in the right and left hippocampi, implying that the magnitude of this reduction increases with increasing prior duration of illness. No modifying effect of interscan interval was seen.

To address possible effects of age at onset, we conducted tests of potential child- versus adult-onset schizophrenia stratification in STATA (StataCorp, College Station, Texas) using the *metan.ado* script. There was no overall heterogeneity between these subgroups ($p = .8$). There was, however, significant heterogeneity between the groups for frontal gray matter, indicating possibly greater tissue loss in COS (standard mean difference = $-.6$, three studies) than AOS (standard mean difference = $-.2$, five studies); occipital gray matter, COS $-.5$ versus AOS $.0$ (two vs. three studies); and parietal cerebrospinal fluid, $-.8$ versus $.3$ (one study each) but no heterogeneity for the hippocampi. It should be noted that only frontal gray matter was significantly reduced in the full meta-analysis of both groups combined and that only a small number of studies have been conducted.

Discussion

Progressive Brain Changes in Schizophrenia

Findings from this systematic review and meta-analysis suggest that patients with schizophrenia in comparison with healthy control subjects exhibit statistically significant progressive reductions in whole brain, whole brain gray matter, and frontal lobe volumes, as well as frontal, parietal, and temporal lobe white matter decrements and lateral ventricular volume enlargement over time. In contrast, no progressive volumetric changes were detected in medial temporal lobe subregions, namely the bilateral hippocampi, amygdala, and amygdala-hippocampal complexes. Our findings are supported by an absence of publication bias. Although heterogeneity was considerable and largely unexplained, several results were not subject to heterogeneity, and we used a random effects statistical model to take account of heterogeneity where evident.

Our results support the idea that schizophrenia has a progressive component to its pathophysiology, although this is not necessarily degenerative, and this model and the neurodevelopmental model are not mutually exclusive (68). Many of the genes implicated in the illness appear to have functional roles throughout the life course, and therefore, it has been suggested that its pathophysiology involves an ongoing interplay of genetic, epistatic, and environmental factors in both early and later life (19,69,70).

The findings of global brain volume reduction and lateral ventricular volume enlargement over time are consistent with previous postmortem studies, which have repeatedly documented reductions in regional cell size (71) and raised the possibility of increased cell loss (72,73) in schizophrenia. Information about the underlying

Table 2. Mean Differences in the Percentage Change over Time Across 32 Brain Regions of Interest Between Schizophrenia and Control Groups with Effect Sizes and Estimates of Heterogeneity

Brain Region	Number of Studies	Number of Subjects		Volume Difference			Heterogeneity			Studies (Reference)
		Schizophrenia	Control Subjects	SMD	<i>p</i> Value	95% CI	<i>I</i> ² (%)	χ^2	<i>p</i> Value	
Whole Brain	14	538	454	-.404	.0002	(-.62, -.19)	57.0	30.2	.004	(47,48,49, 31,50,51,52,54,55,57,60, 33,32,64,65)
Cerebellum	6	254	222	.029	.773	(-.17, .22)	5.2	5.3	.383	(31,50,51,52,54,32)
Whole Brain GM	12	405	523	-.52	<.0001	(-.76, -.28)	62.3	29.2	.002	(48,31,54,55,57,59,60,33,32,66)
Whole Brain WM	11	366	480	-.129	.366	(-.41, .15)	70.6	34.0	.0002	(48,31,54,57,59,60,33,32,66)
Whole Brain CSF	6	95	72	.126	.494	(-.24, .49)	14.1	5.8	.324	(46,47,50,51,66)
Bilateral Lateral Ventricles	10	360	354	.530	<.0001	(.28, .78)	51.7	18.6	.029	(30,31,50,51,52,55,60,33,32)
Lateral Ventricle (R)	5	95	58	.393	.034	(.03, .76)	10.6	4.5	.346	(30,50,51,56,58)
Lateral Ventricle (L)	5	95	58	.242	.411	(-.33, .82)	62.1	10.6	.032	(30,50,51,56,58)
Third Ventricle	6	216	250	.180	.059	(-.01, .37)	.0	5.0	.416	(31,50,51,60,33,32)
Frontal Lobe Tissue	3	132	94	-.478	.002	(-.78, -.18)	.0	.2	.922	(47,52,60)
Frontal GM	9	262	241	-.340	.035	(-.66, -.02)	59.8	19.9	.011	(48,52,55,57,60,64,65,66)
Frontal WM	5	185	138	-.512	<.0001	(-.76, -.26)	.0	1.2	.886	(48,52,57,60,64,65)
Frontal CSF	3	94	57	.522	.136	(-.16, 1.21)	64.8	5.7	.058	(66)
Parietal GM	7	172	192	-.161	.352	(-.50, .18)	52.6	12.7	.049	(48,55,57,60,64,65,66)
Parietal WM	4	112	115	-.533	.001	(-.84, -.23)	4.0	3.1	.373	(48,57,60,64,65)
Parietal CSF	3	94	57	-.255	.610	(-1.24, .73)	82.5	11.5	.003	(52,66)
Temporal Lobe Tissue	5	148	110	-.089	.666	(-.49, .31)	47.5	7.6	.107	(47,50,51,52,60)
Temporal Lobe (R)	4	108	62	-.066	.737	(-.45, .31)	22.1	3.9	.278	(28,49,50,51)
Temporal Lobe (L)	4	108	62	.056	.728	(-.26, .37)	.0	.3	.964	(28,49,50,51)
Temporal GM	10	205	234	-.204	.289	(-.58, .17)	68.0	28.1	.001	(48,50,51,55,57,60,64,65,66)
Temporal WM	6	128	131	-.485	.001	(-.76, -.21)	.0	3.9	.569	(48,50,51,57,60,64,65)
Temporal CSF	5	110	73	.150	.356	(-.17, .47)	.0	2.0	.732	(50,51,52,66)
Occipital GM	6	133	149	-.174	.491	(-.67, .32)	69.9	16.6	.005	(48,57,60,64,65)
Occipital WM	4	112	115	-.327	.117	(-.74, .08)	45.9	5.5	.136	(48,57,60,64,65)
HAC (R)	5	83	70	-.060	.716	(-.38, .26)	.0	1.5	.836	(50,51,53,58,67)
HAC (L)	5	83	70	.107	.518	(-.22, .43)	.0	.6	.969	(50,51,53,58,67)
Hippocampus (R)	8	283	241	.145	.337	(-.15, .44)	57.2	16.4	.022	(28,49,50,51,53,58,62,63)
Hippocampus (L)	8	283	241	.089	.490	(-.16, .34)	42.9	12.3	.093	(28,49,50,51,53,58,62,63)
Amygdala (R)	5	123	112	-.138	.362	(-.43, .16)	12.5	4.6	.334	(50,51,53,58,62)
Amygdala (L)	5	123	112	.019	.887	(-.24, .28)	.0	1.1	.888	(50,51,53,58,62)
Caudate (R)	3	155	98	-.132	.470	(-.49, .23)	41.6	3.4	.180	(28,62,64,65)
Caudate (L)	3	155	98	-.336	.013	(-.60, -.07)	.0	.9	.641	(28,62,64,65)

CI, confidence interval; CSF, cerebrospinal fluid; GM, gray matter; HAC, hippocampal amygdala complex; L, left; MD, mean difference; R, right; SMD, standard mean difference; WM, white matter.

cellular causes of any progressive anatomic MRI changes in schizophrenia is sparse, although there is a general agreement that the absence of gliosis indicates that widespread cell death is not the underlying cause. Whether more subtle forms of programmed cell death (apoptosis), loss of neuropil, or neurochemical perturbations are important requires further postmortem investigation. Neuropsychological investigation in a large patient sample above 65 years of age has demonstrated a further reduction of neurocognitive abilities beyond what would be expected from aging (74), although most longitudinal studies of neurocognitive function in schizophrenia have not documented similar changes over time (75–79). Clearly, more longitudinal imaging studies in schizophrenia are required, but these should concentrate on trying to identify clinical and pathological correlates. The regional effect sizes and annualized rates of loss we provide should inform power calculations for these studies.

Regional white matter changes in schizophrenia have been identified in previous cross-sectional studies (80,81), and it has been suggested that ventricular enlargement is related to a reduction in white matter adjacent to the ventricles (82). At a functional

level, this has been explained in the context of the dysconnectivity hypothesis (83) because of abnormal synapse formation and plasticity (84). Whether white matter changes over time occur uniformly throughout the brain, perhaps as a result of genetic abnormalities in the protein pathways controlling myelination, or whether specific white matter tracts are affected (85) is unclear. A recent meta-analysis of cross-sectional diffusion-tensor magnetic resonance imaging studies in schizophrenia (86) identified changes in deep frontal and temporal white matter areas and suggested that the white matter changes in schizophrenia were regional rather than uniform. Neuropathological studies of schizophrenia have also detected regional abnormalities in white matter, including axonal atrophy and swelling of periaxonal oligodendrocyte processes especially in the frontal lobe (87). In this meta-analysis, we identified significant reductions in frontal, temporal, and parietal, but not global, white matter, suggesting that multifocal regional reductions may continue to occur over time. We note, however, that the 95% confidence intervals of these global and local estimates show large overlap and are therefore in keeping with each other statistically.

Confounding Factors and Methodological Issues

While it has been suggested that both neurodevelopmental deviance and progressive degenerative change could be possible (4,88,89), Weinberger and McClure (2) proposed that the findings being presented in longitudinal MRI studies were artifactual. A potential confounding factor of all neuroimaging studies in schizophrenia is the effect of antipsychotic medication, but establishing whether structural brain changes over time are a result of medication or the illness itself is challenging (3). Neuroimaging studies during the early phase of the illness are useful, because the confounding effects of chronicity and long-term medication can be minimized (90–92). In a recent systematic review, Moncrieff and Leo (93) investigated the possible role of antipsychotics in the genesis of brain volume abnormalities in schizophrenia, documenting that most longitudinal studies report gray matter volume decreases or ventricular volume increases during the course of drug treatment. Observations of coincident volume change and antipsychotic medication prescription do not, however, prove that loss of brain tissue is a direct consequence of the drug, even if the timing may suggest this. Until evidence from randomized controlled trials and neuromolecular studies investigating the pathophysiological basis of these findings emerge, we cannot be certain whether or to what extent the anatomical changes can be attributed to antipsychotic medication. Indeed, the fact that similar changes have been reported in unmedicated individuals as they develop schizophrenia argues against medication being entirely responsible (94). In our meta-analysis, among the 27 studies reviewed, none of the studies included purely antipsychotic-naïve schizophrenia patients, and such a study is desirable, even though it would be difficult and arguably unethical to conduct. Illness duration before initial MRI ranged from less than 1 year (53,66) to 18.7 years (64,65), but this was only apparently associated with heterogeneity concerning progression in the hippocampus. Furthermore, increasing age (and presumably increasing medication exposure) was associated with a reducing effect size.

Our stratification analyses comparing adult- and childhood-onset schizophrenia suggest that there may be differential effects in these subgroups. Given that only frontal gray matter was significantly reduced in the full meta-analysis of both groups combined and the small number of studies involved, these possibly differential effects by age at onset require very cautious interpretation and further study. Indeed, it should be noted that all the longitudinal studies in this review may suffer from cohort effects, given that older patients lived in a different time than young patients and may have experienced different approaches to their care. Even studies that included subjects across a large age range with a relatively short scan interval still suffer from such potential cohort effects.

Another possible explanation for heterogeneity between studies is gender. Female patients with schizophrenia are underrepresented in the literature, despite interest in the effects of gender in the pathophysiology of schizophrenia (95) and healthy aging populations (96). Although findings have not been consistent, several investigators have reported sex differences in brain morphology in schizophrenia (97,98). The absolute number of male subjects included in this meta-analysis was over two times greater than female subjects, and although two groups reported percentage change in volume over time data for female subjects and male subjects separately (50,51,66), the effects of gender could not be fully explored without individual patient data. Left-handed subjects are also underrepresented in the analysis, again, possibly contributing to increased heterogeneity of study results.

An important methodological consideration in follow-up MRI studies is the effect of technical scanner software upgrade and

changes in signal-to-noise ratio (99) on the reproducibility of brain volume data. Ideally, a longitudinal study should utilize high-resolution imaging techniques, thin slices, and no gaps between slices for more precise magnetic resonance morphometric volume measures (100). Methodological differences between research groups are a potential limitation in meta-analyses such as that reported here.

Strengths and Limitations of the Review

Despite several years of accumulated data on progressive structural brain change in people with schizophrenia and although several narrative reviews on this topic have been published (3,4,88,101–110), this review is the first to systematically and quantitatively meta-analyze progressive change data from schizophrenic and control subjects, including 32 different brain regions of interest. Narrative reviews tend to be limited by focusing on published studies and especially those that report statistically significant results. In this meta-analysis, each study is weighted according to the sample size, thus reducing the possibility of biased interpretation of the findings. While the selective publication of positive data is a potential limitation of this and all other meta-analyses, we found no evidence of publication bias. Our results are in keeping with and extend the findings of a previous meta-analysis that found evidence of progressive increases in the lateral ventricles but did not examine other regions of interest (111). Since our literature search, both positive (112) and negative (113) studies have been published. These studies are consistent with the results reported here and attest to the need for a comprehensive, quantitative review of the literature as a whole. The annualized rates of change we report should help to plan future studies.

Meta-analysis of region-of-interest studies, restricted to brain lobes and defined anatomical regions, constrains findings to large-scale changes in the brain. Analysis of voxel-based morphometry studies would complement this study, allowing the analysis of small-scale regional gray and white matter volume abnormalities not necessarily related to major subdivision in brain regions. It may well be the case that reductions of the magnitude identified here are very difficult to detect in small brain regions of interest such as the hippocampus and amygdala (4,107).

Conclusions

We reviewed 27 studies that used regional brain volume measurements to identify progressive changes in brain volume over time in patients with schizophrenia and control subjects. Meta-analyses revealed that schizophrenia is associated with significant declines in whole brain volume, whole brain gray matter, and frontal lobe volume over time, as well as increases in lateral ventricular volume compared with healthy control subjects. There was no evidence of progressive medial temporal lobe involvement in schizophrenia. The causes and clinical correlates of these changes should now be the focus of investigations.

AMM is supported by the Health Foundation through a Clinician Scientist Fellowship. SJW is supported by a Career Development Award from the National Health and Medical Research Council Australia and a National Alliance for Research on Schizophrenia and Depression Young Investigator Award. EB is supported by a Human Brain Project Grant from the National Institute of Biomedical Imaging and Bioengineering and the National Institute of Mental Health. SML was supported by a National Alliance for Research on Schizophrenia and Depression Senior Scientist Award at the time this work was done.

We are extremely grateful to the researchers who kindly provided the invaluable data needed for the meta-analysis (Profs/Drs. Anjene

Addington, Rachel Brans, Monte Buchsbaum, Wiepke Cahn, Liv Clasen, Wolfgang Fleischhacker, Peter Gochman, Deanna Greenstein, Ruben Gur, Beng-Choon Ho, Anthony James, Kiyoto Kasai, Georg Kemmler, Cédric Koolschijn, Robert McCarley, Serge Mitelman, Vicente Molina, Motoaki Nakamura, Yoshiro Okubo, Hilleke Hulshoff Pol, Monica Rais, Judith Rapoport, Santiago Reig, Tomoyuki Saijo, Martha Shenton, Neeltje van Haren, Lei Wang, and Alexandra Whitworth); Marshall Dozier of the University of Edinburgh for assistance in obtaining primary research articles; and Margaret MacDougall for statistical advice.

EB is employed half-time by the University of Cambridge and half-time by GlaxoSmithKline. All other authors reported no biomedical financial interests or potential conflicts of interest.

Supplementary material cited in this article is available online.

- Kraepelin E (1896, 1899): *Lehrbuch der Psychiatrie 5 and 6 Auflage*. Leipzig, Germany: Barth.
- Weinberger DR, McClure RK (2002): Neurotoxicity, neuroplasticity, and magnetic resonance imaging morphometry: What is happening in the schizophrenic brain? *Arch Gen Psychiatry* 59:553–558.
- van Haren NEM, Cahn W, Hulshoff Pol HE, Kahn RE (2008): Schizophrenia as a progressive brain disease. *Eur Psychiatry* 23:245–254.
- DeLisi LE (2008): The concept of progressive brain change in schizophrenia: Implications for understanding schizophrenia. *Schizophr Bull* 34:312–321.
- Haug JO (1962): Pneumoencephalographic studies in mental disease. *Acta Psychiatr Scand Suppl* 38:1–104.
- Kemali D, Maj M, Galderisi S, Milici N, Salvati A (1989): Ventricle-to-brain ratio in schizophrenia: A controlled follow-up study. *Biol Psychiatry* 26:756–759.
- Woods BT, Yurgelun-Todd D, Benes FM, Frankenburg FR, Pope HG Jr, McSparren J (1990): Progressive ventricular enlargement in schizophrenia: Comparison to bipolar affective disorder and correlation with clinical course. *Biol Psychiatry* 27:341–352.
- Degreef G, Ashtari M, Wu HW, Borenstein M, Geisler S, Lieberman J (1991): Follow up MRI study in first episode schizophrenia. *Schizophr Res* 5:204–206.
- Hoffman WF, Ballard L, Turner EH, Casey DE (1991): Three-year follow-up of older schizophrenics: Extrapyramidal syndromes, psychiatric symptoms, and ventricular brain ratio. *Biol Psychiatry* 30:913–926.
- Illowsky BP, Juliano DM, Bigelow LB, Weinberger DR (1988): Stability of CT scan findings in schizophrenia: Results of an 8 year follow-up study. *J Neurol Neurosurg, Psychiatry* 51:209–213.
- Jaskiw GE, Juliano DM, Goldberg TE, Hertzman M, Urow-Hamell E, Weinberger DR (1994): Cerebral ventricular enlargement in schizophreniform disorder does not progress. A seven year follow-up study. *Schizophr Res* 14:23–28.
- Nasrallah HA, Olson SC, McCalley-Whitters M, Chapman S, Jacoby CG (1986): Cerebral ventricular enlargement in schizophrenia. A preliminary follow-up study. *Arch Gen Psychiatry* 43:157–159.
- Sponheim SR, Iacono WG, Beiser M (1991): Stability of ventricular size after the onset of psychosis in schizophrenia. *Psychiatry Res* 40:21–29.
- Vita A, Giobbio GM, Dieci M, Garbarini M, Morganti C, Comazzi M, Invernizzi G (1994): Stability of cerebral ventricular size from the appearance of the first psychotic symptoms to the later diagnosis of schizophrenia. *Biol Psychiatry* 35:960–962.
- Vita A, Sacchetti E, Valvassori G, Cazzullo CL (1988): Brain morphology in schizophrenia: A 2- to 5-year CT scan follow-up study. *Acta Psychiatr Scand* 78:618–621.
- [No authors listed] (1991): Longitudinal perspectives on the pathophysiology of schizophrenia. Examining the neurodevelopmental versus neurodegenerative hypotheses. American College of Neuropsychopharmacology satellite meeting. San Juan, Puerto Rico, U.S.A., December 8, 1990. *Schizophr Res* 5:183–210.
- Weinberger DR (1987): Implications of normal brain development for the pathogenesis of schizophrenia. *Arch Gen Psychiatry* 44:660–669.
- Murray RM, Lewis SW (1987): Is schizophrenia a neurodevelopmental disorder? *Br Med J Clin Res Ed* 295:681–682.
- Rapoport JL, Addington AM, Frangou S, Psych MR (2005): The neurodevelopmental model of schizophrenia: Update 2005. *Mol Psychiatry* 10:434–449.
- Jaaro-Peled H, Hayashi-Takagi A, Seshadri S, Kamiya A, Brandon NJ, Sawa A (2009): Neurodevelopmental mechanisms of schizophrenia: Understanding disturbed postnatal brain maturation through neuregulin-1-ErbB4 and DISC1. *Trends Neurosci* 32:485–495.
- Cannon M, Jones PB, Murray RM (2002): Obstetric complications and schizophrenia: Historical and meta-analytic review. *Am J Psychiatry* 159:1080–1092.
- Jones PB, Rantakallio P, Hartikainen AL, Isohanni M, Sipilä P (1998): Schizophrenia as a long-term outcome of pregnancy, delivery, and perinatal complications: A 28-year follow-up of the 1966 North Finland general population birth cohort. *Am J Psychiatry* 155:355–364.
- Benes FM (1991): Evidence for neurodevelopment disturbances in anterior cingulate cortex of post-mortem schizophrenic brain. *Schizophr Res* 5:187–188.
- McGlashan TH, Hoffman RE (2000): Schizophrenia as a disorder of developmentally reduced synaptic connectivity. *Arch Gen Psychiatry* 57:637–648.
- Falkai P, Honer WG, David S, Bogerts B, Majtenyi C, Bayer TA (1999): No evidence for astrogliosis in brains of schizophrenic patients. A post-mortem study. *Neuropathol Appl Neurobiol* 25:48–53.
- Johnstone EC, Ebmeier KP, Miller P, Owens DG, Lawrie SM (2005): Predicting schizophrenia: Findings from the Edinburgh High-Risk Study. *Br J Psychiatry* 186:18–25.
- Lawrie SM, McIntosh AM, Hall J, Owens DG, Johnstone EC (2008): Brain structure and function changes during the development of schizophrenia: The evidence from studies of subjects at increased genetic risk. *Schizophr Bull* 34:330–340.
- Fornito A, Yung AR, Wood SJ, Phillips LJ, Nelson B, Cotton S, *et al.* (2008): Anatomic abnormalities of the anterior cingulate cortex before psychosis onset: An MRI study of ultra-high-risk individuals. *Biol Psychiatry* 64:758–765.
- DeLisi LE, Sakuma M, Tew W, Kushner M, Hoff AL, Grimson R (1997): Schizophrenia as a chronic active brain process: A study of progressive brain structural change subsequent to the onset of schizophrenia. *Psychiatry Res* 74:129–140.
- Saijo T, Abe T, Someya Y, Sassa T, Sudo Y, Suhara T, *et al.* (2001): Ten year progressive ventricular enlargement in schizophrenia: An MRI morphometrical study. *Psychiatry Clin Neurosci* 55:41–47.
- Cahn W, Hulshoff Pol HE, Lems EB, van Haren NE, Schnack HG, van der Linden JA, *et al.* (2002): Brain volume changes in first-episode schizophrenia: A 1-year follow-up study. *Arch Gen Psychiatry* 59:1002–1010.
- van Haren NE, Hulshoff Pol HE, Schnack HG, Cahn W, Brans R, Carati I, *et al.* (2008): Progressive brain volume loss in schizophrenia over the course of the illness: Evidence of maturational abnormalities in early adulthood. *Biol Psychiatry* 63:106–113.
- Rais M, Cahn W, Van Haren N, Schnack H, Caspers E, Hulshoff Pol H, Kahn R (2008): Excessive brain volume loss over time in cannabis-using first-episode schizophrenia patients. *Am J Psychiatry* 165:490–496.
- Lawrie SM, Abukmeil SS (1998): Brain abnormality in schizophrenia. A systematic and quantitative review of volumetric magnetic resonance imaging studies. *Br J Psychiatry* 172:110–120.
- Wright IC, Rabe-Hesketh S, Woodruff PW, David AS, Murray RM, Bullmore ET (2000): Meta-analysis of regional brain volumes in schizophrenia. *Am J Psychiatry* 157:16–25.
- Shenton ME, Dickey CC, Frumin M, McCarley RW (2001): A review of MRI findings in schizophrenia. *Schizophr Res* 49:1–52.
- Honea R, Crow TJ, Passingham D, Mackay CE (2005): Regional deficits in brain volume in schizophrenia: A meta-analysis of voxel-based morphometry studies. *Am J Psychiatry* 162:2233–2245.
- Steen RG, Mull C, McClure R, Hamer RM, Lieberman JA (2006): Brain volume in first-episode schizophrenia: Systematic review and meta-analysis of magnetic resonance imaging studies. *Br J Psychiatry* 188: 510–518.
- Vita A, De Peri L, Silenzi C, Dieci M (2006): Brain morphology in first-episode schizophrenia: A meta-analysis of quantitative magnetic resonance imaging studies. *Schizophr Res* 82:75–88.
- Ellison-Wright I, Glahn DC, Laird AR, Thelen SM, Bullmore E (2008): The anatomy of first-episode and chronic schizophrenia: An anatomical likelihood estimation meta-analysis. *Am J Psychiatry* 165:1015–1023.
- Chan RC, Di X, McAlonan GM, Gong QY (2011): Brain anatomical abnormalities in high-risk individuals, first-episode, and chronic schizophrenia: An activation likelihood estimation meta-analysis of illness progression. *Schizophr Bull* 37:177–188.

42. Borgwardt SJ, Dickey C, Hulshoff Pol H, Whitford TJ, DeLisi LE (2009): Workshop on defining the significance of progressive brain change in schizophrenia: December 12, 2008 American College of Neuropsychopharmacology (ACNP) all-day satellite, Scottsdale, Arizona. The rapporteurs' report. *Schizophr Res* 112:32–45.
43. DerSimonian R, Laird N (1986): Meta-analysis in clinical trials. *Control Clin Trials* 7:177–188.
44. Cooper H, Hedges LV (2004): *The Handbook of Research Synthesis*. New York: Russell Sage Foundation, 272–277.
45. Higgins JP, Thompson SG, Deeks JJ, Altman DG (2003): Measuring inconsistency in meta-analyses. *BMJ* 327:557–560.
46. Nair TR, Christensen JD, Kingsbury SJ, Kumar NG, Terry WM, Garver DL (1997): Progression of cerebroventricular enlargement and the subtyping of schizophrenia. *Psychiatry Res* 74:141–150.
47. Gur RE, Cowell P, Turetsky BL, Gallacher F, Cannon T, Bilker W, Gur RC (1998): A follow-up magnetic resonance imaging study of schizophrenia. Relationship of neuroanatomical changes to clinical and neurobehavioral measures. *Arch Gen Psychiatry* 55:145–152.
48. Rapoport JL, Giedd JN, Blumenthal J, Hamburger S, Jeffries N, Fernandez T, *et al.* (1999): Progressive cortical change during adolescence in childhood-onset schizophrenia. A longitudinal magnetic resonance imaging study. *Arch Gen Psychiatry* 56:649–654.
49. Wood SJ, Velakoulis D, Smith DJ, Bond D, Stuart GW, McGorry PD, *et al.* (2001): A longitudinal study of hippocampal volume in first episode psychosis and chronic schizophrenia. *Schizophr Res* 52:37–46.
50. James AC, Javaloyes A, James S, Smith DM (2002): Evidence for non-progressive changes in adolescent-onset schizophrenia: Follow-up magnetic resonance imaging study. *Br J Psychiatry* 180:339–344.
51. James AC, James S, Smith DM, Javaloyes A (2004): Cerebellar, prefrontal cortex, and thalamic volumes over two time points in adolescent-onset schizophrenia. *Am J Psychiatry* 161:1023–1029.
52. Ho BC, Andreasen NC, Nopoulos P, Arndt S, Magnotta V, Flaum M (2003): Progressive structural brain abnormalities and their relationship to clinical outcome: A longitudinal magnetic resonance imaging study early in schizophrenia. *Arch Gen Psychiatry* 60:585–594.
53. Kasai K, Shenton ME, Salisbury DF, Hirayasu Y, Lee CU, Ciszewski AA, *et al.* (2003): Progressive decrease of left superior temporal gyrus gray matter volume in patients with first-episode schizophrenia. *Am J Psychiatry* 160:156–164.
54. Keller A, Castellanos FX, Vaituzis AC, Jeffries NO, Giedd JN, Rapoport JL (2003): Progressive loss of cerebellar volume in childhood-onset schizophrenia. *Am J Psychiatry* 160:128–133.
55. Sporn AL, Greenstein DK, Gogtay N, Jeffries NO, Lenane M, Gochman P, *et al.* (2003): Progressive brain volume loss during adolescence in childhood-onset schizophrenia. *Am J Psychiatry* 160:2181–2189.
56. DeLisi LE, Sakuma M, Maurizio AM, Relja M, Hoff AL (2004): Cerebral ventricular change over the first 10 years after the onset of schizophrenia. *Psychiatry Res* 130:57–70.
57. Molina V, Reig S, Sanz J, Palomo T, Benito C, Sánchez J, *et al.* (2005): Increase in gray matter and decrease in white matter volumes in the cortex during treatment with atypical neuroleptics in schizophrenia. *Schizophr Res* 80:61–71.
58. Whitworth AB, Kemmler G, Honeder M, Kremser C, Felber S, Hausmann A, *et al.* (2005): Longitudinal volumetric MRI study in first- and multiple-episode male schizophrenia patients. *Psychiatry Res* 140:225–237.
59. Addington AM, Gornick MC, Shaw P, Seal J, Gogtay N, Greenstein D, *et al.* (2007): Neuregulin 1 (8p12) and childhood-onset schizophrenia: Susceptibility haplotypes for diagnosis and brain developmental trajectories. *Mol Psychiatry* 12:195–205.
60. Nakamura M, Salisbury DF, Hirayasu Y, Bouix S, Pohl KM, Yoshida T, *et al.* (2007): Neocortical gray matter volume in first-episode schizophrenia and first-episode affective psychosis: A cross-sectional and longitudinal MRI study. *Biol Psychiatry* 62:773–783.
61. Brans RG, van Haren NE, van Baal GC, Schnack HG, Kahn RS, Hulshoff Pol HE (2008): Heritability of changes in brain volume over time in twin pairs discordant for schizophrenia. *Arch Gen Psychiatry* 65:1259–1268.
62. Wang L, Mamah D, Harms MP, Karnik M, Price JL, Gado MH, *et al.* (2008): Progressive deformation of deep brain nuclei and hippocampal-amygdala formation in schizophrenia. *Biol Psychiatry* 64:1060–1068.
63. Koolschijn PC, van Haren NE, Bakker SC, Hoogendoorn ML, Pol HE, Kahn RS (2010): Effects of brain-derived neurotrophic factor Val66Met polymorphism on hippocampal volume change in schizophrenia. *Hippocampus* 20:1010–1017.
64. Mitelman SA, Canfield EL, Chu KW, Brickman AM, Shihabuddin L, Hazlett EA, Buchsbaum MS (2009): Poor outcome in chronic schizophrenia is associated with progressive loss of volume of the putamen. *Schizophr Res* 113:241–245.
65. Mitelman SA, Canfield EL, Newmark RE, Brickman AM, Torosjan Y, Chu KW, *et al.* (2009): Longitudinal assessment of gray and white matter in chronic schizophrenia: A combined diffusion-tensor and structural magnetic resonance imaging study. *Open Neuroimaging J* 3:31–47.
66. Reig S, Moreno C, Moreno D, Burdalo M, Janssen J, Parellada M, *et al.* (2009): Progression of brain volume changes in adolescent-onset psychosis. *Schizophr Bull* 35:233–243.
67. Yoshida T, McCarley RW, Nakamura M, Lee K, Koo MS, Bouix S, *et al.* (2009): A prospective longitudinal volumetric MRI study of superior temporal gyrus gray matter and amygdala-hippocampal complex in chronic schizophrenia. *Schizophr Res* 113:84–94.
68. Woods BT (1998): Is schizophrenia a progressive neurodevelopmental disorder? Toward a unitary pathogenetic mechanism. *Am J Psychiatry* 155:1661–1670.
69. Harrison PJ, Weinberger DR (2005): Schizophrenia genes, gene expression, and neuropathology: On the matter of their convergence. *Mol Psychiatry* 10:40–68.
70. Church SM, Cotter D, Bramon E, Murray RM (2002): Does schizophrenia result from developmental or degenerative processes? *J Neural Transm Suppl* 63:129–147.
71. Arnold SE, Franz BR, Gur RE, Shapiro RM, Moberg PJ, Trojanowski JQ (1995): Smaller neuron size in schizophrenia in hippocampal subfields that mediate cortical-hippocampal interactions. *Am J Psychiatry* 152:738–748.
72. Pakkenberg B (1990): Pronounced reduction of total neuron number in mediodorsal thalamic nucleus and nucleus accumbens in schizophrenics. *Arch Gen Psychiatry* 47:1023–1028.
73. Benes FM, McSparren J, Bird ED, San Giovanni JP, Vincent SL (1991): Deficits in small interneurons in prefrontal and cingulate cortices of schizophrenic and schizoaffective patients. *Arch Gen Psychiatry* 48:996–1001.
74. Harvey PD, Lombardi J, Leibman M, White L, Parrella M, Powchik P, Davidson M (1996): Cognitive impairment and negative symptoms in geriatric chronic schizophrenic patients: A follow-up study. *Schizophr Res* 22:223–231.
75. Rund BR (1998): A review of longitudinal studies of cognitive functions in schizophrenia patients. *Schizophr Bull* 24:425–435.
76. Stirling J, White C, Lewis S, Hopkins R, Tantam D, Huddy A, Montague L (2003): Neurocognitive function and outcome in first-episode schizophrenia: A 10-year follow-up of an epidemiological cohort. *Schizophr Res* 65:75–86.
77. Kurtz MM (2004): Neurocognitive impairment across lifespan in schizophrenia: An update. *Schizophr Res* 74:15–26.
78. Hoff AL, Svetina C, Shields G, Stewart J, DeLisi LE (2005): Ten year longitudinal study of neuropsychological functioning subsequent to a first episode of schizophrenia. *Schizophr Res* 78:27–34.
79. Andreasen NC, Moser DJ, O'Leary DS, Ho BC (2005): Longitudinal changes in neurocognition during first decade of schizophrenia illness. *Schizophr Bull* 31:348.
80. Kubicki M, Park H, Westin CF, Nestor PG, Mulkern RV, Maier SE, *et al.* (2005): DTI and MTR abnormalities in schizophrenia: Analysis of white matter integrity. *Neuroimage* 26:1109–1118.
81. Kanaan RA, Kim JS, Kaufmann WE, Pearlson GD, Barker GJ, McGuire PK (2005): Diffusion tensor imaging in schizophrenia. *Biol Psychiatry* 58:921–929.
82. Christensen J, Holcomb J, Garver DL (2004): State-related changes in cerebral white matter may underlie psychosis exacerbation. *Psychiatry Res* 130:71–78.
83. Friston K (2005): Disconnection and cognitive dysmetria in schizophrenia. *Am J Psychiatry* 162:429–432.
84. Stephan KE, Baldeweg T, Friston KJ (2006): Synaptic plasticity and dysconnection in schizophrenia. *Biol Psychiatry* 59:929–939.
85. Konrad A, Winterer G (2008): Disturbed structural connectivity in schizophrenia primary factor in pathology or epiphenomenon? *Schizophr Bull* 34:72–92.
86. Ellison-Wright I, Bullmore E (2009): Meta-analysis of diffusion tensor imaging studies in schizophrenia. *Schizophr Res* 108:3–10.

87. Uranova NA, Vostrikov VM, Vikhrevva OV, Zimina IS, Kolomeets NS, Orlovskaya DD (2007): The role of oligodendrocyte pathology in schizophrenia. *Int J Neuropsychopharmacol* 10:537–545.
88. Pantelis C, Yücel M, Wood SJ, Velakoulis D, Sun D, Berger G, *et al.* (2005): Structural brain imaging evidence for multiple pathological processes at different stages of brain development in schizophrenia. *Schizophr Bull* 31:672–696.
89. Lieberman JA (1999): Is schizophrenia a neurodegenerative disorder? A clinical and neurobiological perspective. *Biol Psychiatry* 46:729–739.
90. Joyal CC, Laakso MP, Tiihonen J, Syvalahti E, Vilkmann H, Laakso A, *et al.* (2003): The amygdala and schizophrenia: A volumetric magnetic resonance imaging study in first-episode, neuroleptic-naïve patients. *Biol Psychiatry* 54:1302–1304.
91. Spinks R, Nopoulos P, Ward J, Fuller R, Magnotta VA, Andreasen NC (2005): Globus pallidus volume is related to symptom severity in neuroleptic naïve patients with schizophrenia. *Schizophr Res* 73:229–233.
92. Upadhyaya AR, El-Sheikh R, MacMaster FP, Diwadkar VA, Keshavan MS (2007): Pituitary volume in neuroleptic-naïve schizophrenia: A structural MRI study. *Schizophr Res* 90:266–273.
93. Moncrieff J, Leo J (2010): A systematic review of the effects of antipsychotic drugs on brain volume. *Psychol Med* 40:1409–1422.
94. Job DE, Whalley HC, Johnstone EC, Lawrie SM (2005): Grey matter changes over time in high risk subjects developing schizophrenia. *Neuroimage* 25:1023–1030.
95. Tamminga CA (1997): Gender and schizophrenia. *J Clin Psychiatry* 58(suppl 15):33–37.
96. Coffey CE, Lucke JF, Saxton JA, Ratcliff G, Uritas LJ, Billig B, Bryan RN (1998): Sex differences in brain aging: A quantitative magnetic resonance imaging study. *Arch Neurol* 55:169–179.
97. Nopoulos P, Flaum M, Andreasen NC (1997): Sex differences in brain morphology in schizophrenia. *Am J Psychiatry* 154:1648–1654.
98. Fujiwara H, Shimizu M, Hirao K, Miyata J, Namiki C, Sawamoto N, *et al.* (2008): Female specific anterior cingulate abnormality and its association with empathic disability in schizophrenia. *Prog Neuropsychopharmacol Biol Psychiatry* 32:1728–1734.
99. Shuter B, Yeh IB, Graham S, Au C, Wang SC (2008): Reproducibility of brain tissue volumes in longitudinal studies: Effects of changes in signal-to-noise ratio and scanner software. *Neuroimage* 41:371–379.
100. Sun J, Maller JJ, Guo L, Fitzgerald PB (2009): Superior temporal gyrus volume change in schizophrenia: A review on region of interest volumetric studies. *Brain Res Rev* 61:14–32.
101. Anderson JE, O'Donnell BF, McCarley RW, Shenton ME (1998): Progressive changes in schizophrenia: Do they exist and what do they mean? *Restor Neurol Neurosci* 12:175–184.
102. Asami T, Narita H, Hirayasu Y (2004): [Progressive structural abnormalities in the brain of the schizophrenic]. *Seishin Shinkeigaku Zasshi* 106:987–996.
103. DeLisi LE, Szulc KU, Bertisch HC, Majcher M, Brown K (2006): Understanding structural brain changes in schizophrenia. *Dialogues Clin Neurosci* 8:71–78.
104. Csernansky JG (2007): Neurodegeneration in schizophrenia: Evidence from in vivo neuroimaging studies. *ScientificWorldJournal* 7:135–143.
105. Wood SJ, Pantelis C, Velakoulis D, Yücel M, Fornito A, McGorry PD (2008): Progressive changes in the development toward schizophrenia: Studies in subjects at increased symptomatic risk. *Schizophr Bull* 34:322–329.
106. Arango C, Moreno C, Martínez S, Parellada M, Desco M, Moreno D, *et al.* (2008): Longitudinal brain changes in early-onset psychosis. *Schizophr Bull* 34:341–353.
107. Hulshoff Pol HE, Kahn RS (2008): What happens after the first episode? A review of progressive brain changes in chronically ill patients with schizophrenia. *Schizophr Bull* 34:354–366.
108. Gross G, Huber G (2008): [Schizophrenia: Neurodevelopmental disorder or degenerative brain process?] *Fortschr Neurol Psychiatr* 76(suppl 1):S57–S62.
109. Rund BR (2009): Is schizophrenia a neurodegenerative disorder? *Nord J Psychiatry* 63:196–201.
110. Wood SJ, Pantelis C, Yung AR, Velakoulis D, McGorry PD (2009): Brain changes during the onset of schizophrenia: Implications for neurodevelopmental theories. *Med J Aust* 190(suppl 4):S10–S13.
111. Kempton MJ, Stahl D, Williams SC, DeLisi LE (2010): Progressive lateral ventricular enlargement in schizophrenia: A meta-analysis of longitudinal MRI studies. *Schizophr Res* 120:54–62.
112. Schaufelberger MS, Lappin JM, Duran FL, Rosa PG, Uchida RR, Santos LC, *et al.* (2010): Lack of progression of brain abnormalities in first-episode psychosis: A longitudinal magnetic resonance imaging study. *Psychol Med* 10:1–13.
113. Tomelleri L, Jogia J, Perlini C, Bellani M, Ferro A, Rambaldelli G, *et al.* (2009): Brain structural changes associated with chronicity and antipsychotic treatment in schizophrenia. *Eur Neuropsychopharmacol* 19:835–840.