

Original Research Article**A Prospective Randomised Control Trial to Study the Role of Intra-Peritoneal Instillation of Ropivacaine versus Normal Saline Irrigation in Reduction of Post-Operative Pain In Patients Undergoing Laparoscopic Cholecystectomy**

Pankaj S, Pankaj D (✉), Sushil M, Harnam S

Department of Surgery, Government Medical College/Rajindra Hospital, Patiala, Punjab, 147001 India.

Abstract

The study was done to compare the effect of intra-peritoneal instillation of ropivacaine versus normal saline irrigation on post operative abdominal pain and shoulder pain in laparoscopic cholecystectomy. Ninety patients with symptomatic gall stones disease undergoing laparoscopic cholecystectomy were randomized in three groups. In study group A (n=30 patients) 0.5% of 30 ml (150 mg) of ropivacaine was instilled at gall bladder bed, and in study group B (n=30) 0.9% of 25 – 30 ml/kg of normal saline irrigation was done at gall bladder bed and sub-diaphragmatic space or control group C (n=30) none of above two intervention was done. Pain abdomen is worse during first 24 hours after laparoscopic cholecystectomy. At 6 hours pain abdomen was significantly less in group A compared to group B ($p < .035$). At 12 hours pain abdomen was less in group A and group B compared to control group. Intensity of shoulder tip pain was almost similar in group A and group B. Group A experienced significantly reduced shoulder tip pain at 6 hours and 12 hours as compared to group C. Group B experienced less shoulder tip pain during first postoperative day as compared to control group. Intra-peritoneal instillation of ropivacaine is more effective than normal saline irrigation at early post-operative hours in reducing post-operative pain abdomen after laparoscopic cholecystectomy. However, intra-peritoneal instillation of ropivacaine and normal saline irrigation are comparable in its effect on shoulder tip pain.

Keywords: Laparoscopy, cholecystectomy, ropivacaine, pneumoperitoneum, pain**Correspondence:**Dr. Pankaj Dugg, Department of Surgery, Government Medical College/Rajindra Hospital, Patiala, Punjab, 147001 India. Tel: 919417388800 Fax: 911812651306 Email: pankajdugg84@gmail.com

Date of submission: 11 Feb, 2013

Date of acceptance: 20 Aug, 2013

Introduction

Langenbuch's open cholecystectomy is still considered as the gold standard for symptomatic cholelithiasis (1). In 1992 a NIH consensus conference decided that "laparoscopic cholecystectomy was treatment of choice for cholelithiasis" (2). The advantages of laparoscopic cholecystectomy compared to open cholecystectomy are reduced pain, better cosmetic outcome shorter hospital stay and early recovery (3) which is reflected by patient's earlier return to normal activities (4).

There is always a need for systematic prevention of pain before patient wakes up from anaesthesia as

postoperative pain is unpredictable (5). Thus, pain relief and patient comfort during the early postoperative period are important, as the need for analgesics may delay discharge. According to research reports, "many patients experience considerable pain after laparoscopic cholecystectomy and improvement in the analgesic technique is desirable" (6). Pain following laparoscopic cholecystectomy (LC) is multifactorial. Pain is differentiated into three components- visceral, abdominal wall, and referred pain to shoulder (7). Pain is worst in the first 24 hours with visceral pain being worst than abdominal wall pain. Pain could be due to distension induced neuropraxia of the phrenic nerves, acid in the peritoneal milieu during operation, or the residual intra abdominal gas

following laparoscopy, humidity of the gas, volume of the insufflated gas, size of the wound, trauma to the parietal peritoneum or presence of drains.

Eliminating the causes of pain has a clear advantage over symptomatic treatment using analgesic, a fact worth a good consideration especially with the post-operative sojourn at the hospital becoming shorter (8). Although laparoscopic cholecystectomy is not a pain-free procedure but it causes less pain than open cholecystectomy.

Different modalities have been proposed to relieve post operative pain after laparoscopy (9). These include NSAIDs/opioids, intra-peritoneal local anaesthetics, port site infiltration of local anaesthetics, intra-peritoneal saline, removal of insufflation gas/ gas drains, low pressure abdominal insufflations, acetazolamide administration, use of N₂O in place of CO₂.

Local anaesthetics are widely used, have a good safety profile and are available in long acting preparations. They provide the benefit of anaesthesia without the systemic side effects. Recently, the intra-operative use of local anaesthesia during laparoscopy has generated interest. This may be done by "reducing postoperative pain to the point that narcotic analgesics are not required" (10).

Ropivacaine is a long-acting amide-type local anaesthetic being used since last two decades. When ropivacaine is given intra-peritoneally its starts acting within 10-20 minutes, and duration of action last for 4-6 hours.

Sub-diaphragmatic instillation of 25-30 ml/kg of normal saline and its subsequent aspiration has shown to decrease visceral and shoulder tip pain and this is due to dilution of carbonic acid and displacement of sub-phrenic CO₂ (11).

Materials and Methods

The study was a prospective, randomized, controlled clinical trial. Participants were recruited at GMC\Rajindra hospital, Patiala, Punjab, India from August 1, 2011, through June 30, 2012. The study was performed after obtaining approval from the local ethical committee, and informed consent was obtained from all patients.

Ninety patients with symptomatic gall stones disease undergoing laparoscopic cholecystectomy were randomized in three groups by distributing three different colour cards among the patients equally.

Cards were picked up blindly by the resident doctor and distributed to the patients. The inclusion criteria were as follows: age between 16-70 years, symptomatic cholelithiasis, no clinical, biochemical or ultrasonographic evidence of common bile duct (CBD) stones. The exclusion criteria were as follows: hypersensitivity to ropivacaine, age below 16 years, acute cholecystitis, pregnancy, history of peritonitis. Laparoscopic cholecystectomy was performed with the patient in a slight reverse Trendelenburg position in accordance to the "American" variable in all the patients.

In group A, silicone catheter (epidural catheter) was inserted through the lateral trocar while performing direct vision of laproscope in such a manner that the tip of the catheter was placed in the bed of the gall bladder. Then 0.5% of 30 ml ropivacaine was instilled at gall bladder bed. In group B, peritoneal saline irrigation with 25 to 30 ml/kg body weight of saline at 37°C was done under right hemi diaphragm after completion of above procedure. Fluid is suctioned out after deflation of pneumoperitoneum. In group C no instillation was done either of normal saline or ropivacaine.

A drain was not used in any case. Antibiotic prophylaxis was attempted with three doses of a second-generation cephalosporin.

An independent nurse recorded the postoperative abdominal and shoulder tip pain at the 6th, 12th, 24th, and 48th hour after the operation according to patient's perception. The randomization was blind to both of them. Pain assessment was based on a 0 to 10 visual analogue scale (VAS, 0: no pain, 10: the worst imaginable pain). Preoperatively, the nurse introduced patients to the concept of a VAS scale. If the VAS score was above 3, an intramuscular (IM) injection of diclofenac 75 mg was applied. If pain was persistent, the diclofenac IM injection was repeated. Postoperative nausea was noted. The nausea was assessed by the patient's complaint and the need for the use of an antiemetic drug.

Parametric data were compared between groups by analysis of variances (ANOVA) and post-hoc testing. Nonparametric data were analyzed with Mann-Whitney Test and chi-square tests between groups. Statistical significance was assumed if $p < 0.05$.

Results

There was no difference found in the age, sex, of duration of the surgery between the three groups. Laparoscopic Cholecystectomy was performed in the study group A in three men and 27 women with a

mean age of 42 years (range 26 to 70), study group B five men and 25 women with a mean age of 42 years (range 24 to 60) and in the control group C group in three men and 27 women with a mean age of 41 years (range 21 to 60) (Table 1).

The laparoscopic procedure was completed successfully in all cases without any intra-operative complications or need of conversion to an open operation.

The mean duration of the operation was 46 minutes (range 35 to 65) in the study group A, 48 minutes in study group B, and 50 minutes (range 40 to 90) for LC and 40 minutes (range 30 to 70) for LIHR in the control group C.

In our study, average hospital stay was 1.57 days in group A, 1.70 days in group B and 1.57 days in group C, the difference was found to be insignificant.

The VAS score for pain abdomen in group A was significantly less compared to group B at 6 hours ($p < .035$), and compared group C was also significantly less at 6 hours ($p < .039$), 12 hours ($p < .001$) and 24 hours ($p < .001$).

The VAS score in group B compared to group C was significantly less at 6 hours ($p < .001$), 12 hours ($p < .001$) and 24 hours ($p < .003$).

Table 1: Patient demographic, surgical data, hospital stay

	Group A	Group B	Group C
Age (mean±SD)	42±11	42±10	41±10
Sex M/F	3/27	5/25	3/27
Duration of surgery (mean±SD)	48±12	50±11	40±13
Hospital stay (mean±SD)	1.57±0.67	1.7±0.65	1.57±0.62

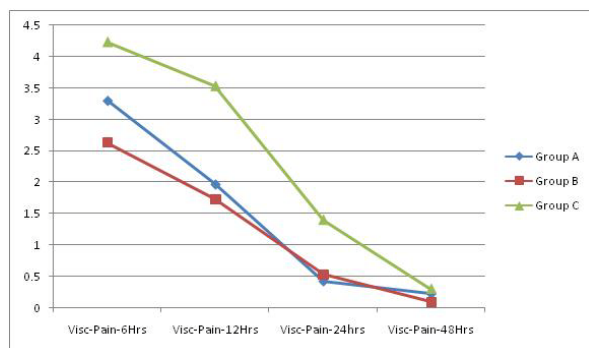


Figure 1: Comparison between the VAS Score for Visceral Pain

At 48 hours the VAS score was not significant ($P > 0.05$) (Table 2)

The VAS score for shoulder tip pain were comparable between study group A and study group B.

VAS score for group A compared to group C was significant at 6 hours ($P < 0.018$), whereas at 12 hours, 24 hours, and 48 hours it was insignificant ($p > .05$).

VAS score for group B compared to group C was significant at 6 hours ($P < 0.006$), and 12 hours ($P < 0.046$), whereas at 24 hours, and 48 hours it was insignificant ($p > .05$) (Table 3).

At 6 hours group A 10% patients, group B 20% patients and group C 63.33% patients were given analgesic injections. P value (< 0.0001) calculated was significant between group A and group C whereas p value ($< .001$) calculated between group B and group C was also significant.

At 12 hours group A 13.33% patients, group B 3.33% patients, and group C 36.66% patients were given analgesic injections. P value (0.076) calculated was insignificant between group A and group C, whereas p value ($< .002$) calculated between group B and group C was significant.

Table 2: Comparison between of VAS Score for Pain Abdomen

Time (Hours)	Significance(P Value)		
	Group A vs B	Group A vs C	Group B vs C
6hr	0.035	0.039	<0.001
12hr	0.448	0.001	<0.001
24hr	0.552	0.001	0.003
48hr	0.408	0.306	0.055

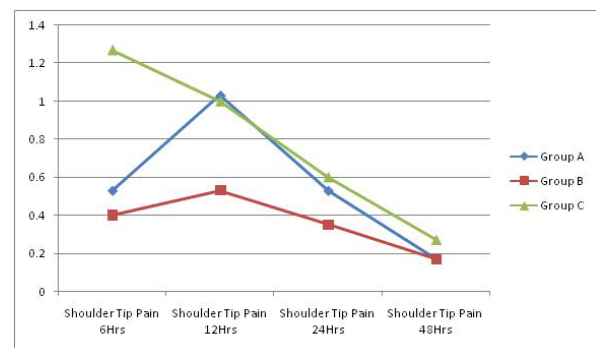


Figure 2: Comparison b/w the VAS Score for Shoulder Tip Pain

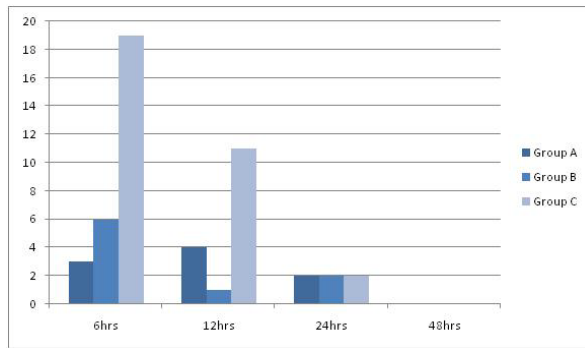


Figure 3: Frequency of Analgesic (No. of patients requiring analgesic)

At 24 hours in all three groups 6.66% of patients were given analgesic injections. At 48 hours none of the patients from any group were given analgesic injections (Table 4).

Discussion

Upper abdominal pain and shoulder pain after laparoscopic surgery may be transient or may persist for about three days (12) sometimes, it may cause more discomfort to the patient than the pain at the incision sites. In this study, both the intraperitoneal instillation of ropivacaine and normal saline irrigation interventions reduced the incidence and intensity of upper abdominal pain and shoulder pain after laparoscopic surgery.

Our study demonstrates that the intraperitoneal instillation of ropivacaine reduces abdominal pain and shoulder tip pain significantly after LC. The VAS score for pain abdomen in group A (ropivacaine group) was significantly less compared to group B (normal saline) at 6 hours ($p < .035$), and compared group C (control) was also significantly less at 6 hours ($p < .039$), 12 hours ($p < .001$) and 24 hours ($p < .001$) (Table 2). The VAS score for shoulder tip pain were comparable between study group A and study group B. The VAS score for group A compared to group C was significant at 6 hours ($p < 0.018$) (Table 3). The total analgesic injection demand was less in group A compared to control group C. At 6 hours analgesic requirement for group A patients compared to group C patients ($p < 0.0001$) was significant, whereas at 12 hours, 24 hours, 48 hours difference of analgesic requirement between group A and group C was insignificant (Table 4). The frequency of nausea in the early post-operative period in the study group A was less compared to control group but not significant.

Our results are in concordance with Gupta et al. (2002) who also found significant reduction in the visceral pain in patients receiving ropivacaine intermittently in

Table 3: Comparison of VAS Score for Shoulder Tip Pain

Time (hours)	Significance(P Value)		
	Group A vs B	Group A vs C	Group B vs C
6hr	0.865	0.018	0.006
12hr	0.248	0.576	0.046
24hr	0.396	0.671	0.643
48hr	1.000	0.479	0.479

gall bladder bed (13). Our study is also in concordance with various authors Labaille et al. (14), Trikoui et al. (15), Kucuk et al. (16), Memrdov et al. (17), Pavlidis et al. (18), Park et al. (19), who have found intra-peritoneal instillation of local anaesthesia decreases the visceral pain after laparoscopic surgery.

Our study is in disagreement with Bisgaard et al. (20) who failed to show any decrease in the visceral pain after intra-peritoneal instillation of ropivacaine. This could be due to reduced dosage used for intra-peritoneal instillation. Also, our study is in contrast to various studies who did not find any benefit of intra-peritoneal instillation of local anaesthesia to decrease pain after laparoscopic cholecystectomy (21,22).

This study with regard to decrease in shoulder tip pain in patients receiving intra-peritoneal instillation of ropivacaine is in accordance with previous studies conducted by Cha et al. (23) and Callesen et al. (24).

However, our study do not agree with studies of Pavlidis et al. (18) and Bisgaard et al. (20) which fail to show any decrease in the shoulder tip pain after intraperitoneal instillation of ropivacaine.

Instillation of local anaesthesia intra-abdominally showed mixed effect with approximately half of the studies proving to be beneficial. The reason for variation in their result is not known. However the difference may be due to enrolling of patients with acute cholecystitis in their study. In fact, it is possible in these cases the presences of acute inflammation may itself trigger neuronal sensation. Factors which may affect the benefit of intra-peritoneal instillation of local anaesthetic (LA): the site of instillation (sub-diaphragmatic or subhepatic or gall bladder bed), dose and the concentration of the LA used, pneumoperitoneum (volume pressure and temp of CO₂), volume of residual CO₂ (causing diaphragmatic irritation), spillage of bile and blood (may interfere with absorption), degree of non visceral pain (pain from incision site), post op analgesic regimen. It has been suggested that post operative pain is reduced if

Table 4: Frequency of Analgesic

Group	Number patients requiring analgesics				
	N	6hr	12hr	24hr	48hr
A	30(100%)	3(10.0%)	4(13.33%)	2 (6.66%)	0 (0%)
B	30(100%)	6(20.0%)	1(3.33%)	2(6.66%)	0 (0%)
C	30(100%)	19(63.33%)	11(36.66%)	2 (6.66%)	0 (0%)

suppression of central neuronal sensitization by intra peritoneal LA occur before nociceptive stimuli have triggered the activation of pathway. Intra-peritoneal instillation of LA may trigger other mechanism that can relieve post-operative pain besides the modulation of central hyper-excitability. LA may also have anti-inflammatory effect on peripheral nociceptors which would relieve primary hyperalgesia (25).

The plasma concentration of ropivacaine was not measured as we believed our concentration was non toxic, this consideration is supported by this and previous clinical trial (25).

The outcome of this study also shows that irrigation with normal saline 25-30ml/kg significantly reduces the abdominal pain as well as the shoulder tip pain compared to the control group C. The VAS score for pain abdomen in group B compared to group C was significantly less at 6 hours ($p < .001$), 12 hours ($p < .001$) and 24 hours ($p < .003$). Compared to group A, group B patients experienced more pain at 6 hours ($p < 0.035$), but the pain were comparable at 12 hours, 24 hours, and 48 hours. The shoulder tip pain is significantly reduced with normal saline irrigation compared to the control group at 6 hours ($P < 0.006$) and 12 hours ($P < 0.046$), whereas at 24 hours, and 48 hours it was insignificant ($p > .05$). The total analgesic injection demand was less in group B compared to control group C. Analgesic requirement for group B patients compared to group C patients at 6hours ($p < 0.001$) and 12 hours ($p < 0.002$) was significantly different, whereas at 24 hours, 48 hours difference was insignificant. The frequency of nausea in the early post-operative period in the study group B was same compared to control group.

Our results are in concordance with Tsimoyiannis et al. (11) who used 25-30ml/kg of normal saline to irrigate the peritoneal cavity until liver was covered. They concluded that post-operative pain was reduced significantly in groups in which normal saline irrigation was done with either normal saline left behind or suctioned or a sub-hepatic drain is placed. Tsai et al. (26), Pappas-Gogos et al. (27) and Kim et al. (28), also showed similar results in their study.

Barczynski et al. (29) concluded that patients treated with low-pressure pneumoperitoneum, and the data also showed that normal saline irrigation significantly reduced the incidence and intensity of shoulder pain after laparoscopic cholecystectomy at 12 and 24 hours (pain scores: 3.0 for the control group vs. 2.5 for the INSI group [$P = .01$] and 1.29 vs. 0.75 [$P = .04$], respectively).

In our study, convention-pressure pneumoperitoneum was used. Consistent with previous studies, a significant reduction in intensity and frequency of laparoscopy-induced pain was seen 24 hours postoperatively ($P < .001$ and $P = .001$, respectively) (26).

Carbon dioxide insufflation constitutes the commonest means of achieving pneumoperitoneum. Carbon dioxide readily dissolves in water and forms carbonic acid. Carbonic acid is then absorbed into the intravascular space and contacts red blood cells, which contain carbonic anhydrase that transforms carbonic acid into bicarbonate. The bicarbonate thus formed is converted back into carbon dioxide in lungs and is expelled. Peritoneal irritation by carbonic acid which is formed by reaction between CO_2 and water and the creation of space between liver and diaphragm by residual pneumoperitoneum has been implicated for visceral and shoulder tip pain (26). As a physiologic buffer system, normal saline facilitates the dissipation of carbon dioxide in the abdominal cavity, thus preventing diaphragmatic irritation and lessening postoperative upper abdominal and shoulder pain. The effect of normal saline is long lasting, continuous, and physiological until the normal saline is absorbed. Therefore, normal saline would be effective to reduce upper abdominal and shoulder pain.

The amount of normal saline used was 1000 mL, which has been reported to be safe, consistent with previous studies, the patients in the normal saline group in this study did not have complications. The absence of a statistical difference in flatulence-relief time among the three groups in this study suggested that this extra fluid (1000 mL) may not prolong ileus. In fact, studies have attempted to verify the kinetics of

intraperitoneal fluid absorption for preventing postoperative adhesions. It is estimated that intraperitoneal absorption is approximately 30 to 60 mL/h; therefore, there would be fewer or no problems with fluid shifts (26).

Conclusion

Our study demonstrated both intraperitoneal instillation of ropivacaine and normal saline irrigation interventions reduced the incidence and intensity of upper abdominal pain and shoulder pain, however intra-peritoneal instillation of ropivacaine is more effective than normal saline irrigation at early post-operative hours in reducing post-operative pain abdomen after laparoscopic cholecystectomy.

References

1. Cuschieri A, Dubois F, Mouiel J et al. The european experience with laparoscopic cholecystectomy. *AM J Surg* 1991; 161(3): 385-387.
2. De U. Evolution of cholecystectomy: A tribute to Carl August Langenbuch. *Ind J Surg* 2004; 66(2): 97-100.
3. Lahmann B, Adrales GL, Mastrangelo MJ, Schwartz RW. Laparoscopic cholecystectomy-technical considerations. *Curr Surg* 2002; 59(1): 55-58.
4. Zucker KA, Bailey RW, Flowers J. Laparoscopic management of acute and chronic cholecystitis. *Surg Clin North Am* 1991; 72(5): 1045-67.
5. Gupta R, Bogra J, Kothari N, Kohli M. Postoperative analgesia with intraperitoneal fentanyl and bupivacaine: a randomized control trial. *Canadian Journal on Medicine* 2010;1(1):1-11.
6. Soper NJ, Stockman PT, Dunnegan DL, Ashley SW. Laparoscopic Cholecystectomy. The new 'gold standard'? *Arch Surg* 1992; 127(8): 917-921.
7. Joris J, Thiry E, Paris P, Weerts J, Lamy M. Pain after laparoscopic cholecystectomy: characteristics and effect of intraperitoneal bupivacaine. *Anesth Analg* 1995; 81(2): 379-384.
8. Pier A, Benedic M, Mann B, Buck V. Post laparoscopic pain syndrome. Results of a prospective, randomized study. *Chirurg* 1994; 65(3): 200-208.
9. Willis VL, Hunt DR. Pain after laparoscopic cholecystectomy. *Br J Surg* 2000; 87(3): 273-284.
10. Szem JW, Hydo L, Barie PS. A double-blinded evaluation of intraperitoneal bupivacaine vs saline for the reduction of post operative pain and nausea after laparoscopic cholecystectomy. *Surg Endosc* 1996; 10(1): 44-48.
11. Tsimoyiannis EC, Siakas P, Tassis A, Lekkas ET, Tzourou H, Kambili M. Intraperitoneal normal saline infusion for postoperative pain after laparoscopic cholecystectomy. *World J Surg* 1998; 22(8): 824-828.
12. Dixon JB, Reuben Y, Halket C, O'Brien PE. Shoulder pain is a common problem following laparoscopic adjustable gastric band surgery. *Obes Surg* 2005; 15(8): 1111-1117.
13. Gupta A, Thorn SE, Axelsson K, et al. Postoperative pain relief using intermittent injections of 0.5% ropivacaine through a catheter after laparoscopic cholecystectomy. *Anesth Analg* 2002; 95(2): 450-456.
14. Labaille T, Mazoit JX, Paqueron X, Franco D, Benhamou D. The clinical efficacy and pharmacokinetics of intraperitoneal ropivacaine for laparoscopic cholecystectomy. *Anesth Analg* 2002; 94(1): 100-105.
15. Trikoupi A, Papavramidis T, Kyurdzhieva E, Kesisoglou I, Vasilakos D. Acute and Chronic Pain Management: Intraperitoneal administration of ropivacaine during laparoscopic cholecystectomy: 14AP12-5. *Eur J Anaesthesiol* 2010; 27(47): 222.
16. Kucuk C, Kadiogullari N, Canoler O, Savlı S. A placebo-controlled comparison of bupivacaine and ropivacaine instillation for preventing postoperative pain after laparoscopic cholecystectomy. *Surg Today* 2007; 37(5): 396-400.
17. Memedrov C, Menteş O, Şimşek A, et al. Comparison of analgesic effects of intraperitoneal lornoxicam and ropivacaine administration in laparoscopic cholecystectomy. *Trakya Univ Tip Fak Derg* 2010; 27(2): 142-149.

18. Pavlidis TE, Atmatzidis KS, Papaziogas BT, Makris JG, Lazaridis CN, Papaziogas TB. The effect of preincisional periportal infiltration with ropivacaine in pain relief after laparoscopic procedures: a prospective, randomized controlled trial. *JSLs* 2003; 7(4): 305-310.
19. Park YH, Kang H, Woo YC, et al. The effect of intraperitoneal ropivacaine on pain after laparoscopic colectomy: a prospective randomized controlled trial. *J Surg Res* 2011; 171(1): 94-100.
20. Bisgaard T, Klarskov B, Kristiansen VB, et al. Multi-Regional Local Anesthetic Infiltration During Laparoscopic Cholecystectomy in Patients Receiving Prophylactic Multi-Modal Analgesia: A Randomized, Double-Blinded, Placebo-Controlled Study. *Anesth Analg* 1999; 89(4): 1017-1024.
21. Rademaker BM, Kalkman CJ, Odoom JA, de Wit L, Ringers J. Intraperitoneal local anaesthesia after laparoscopic cholecystectomy: effect on postoperative pain metabolic responses and lung function. *Br J Anaesth* 1994; 72(3): 263-266.
22. Scheinin B, Kellokumpu I, Lindgren L, Haglund C, Rosenberg PH. Effect of intraperitoneal bupivacaine on pain after Laparoscopic Cholecystectomy. *Acta Anaesthesiol Scand* 1995; 39(2): 195-198.
23. Cha SM, Kang H, Baek CW, et al. Peritrocal and intraperitoneal ropivacaine for laparoscopic cholecystectomy: a prospective, randomized, double-blind controlled trial. *J Surg Res* 2012; 175(2): 251-258.
24. Callesen T, Hjort D, Mogensen T, et al. Combined field block and i.p. instillation of ropivacaine for pain management after laparoscopic sterilization. *Br J Anaesth* 1999; 82(4): 586-590.
25. Hemidia M, Abbas DN, Hosny HA, Al-Korashy SA. Analgesic efficacy of intraperitoneal ropivacaine or combined with paracetamol for laparoscopic cholecystectomy. *Tanta Medical Sciences Journal* 2006; 1(4):140-149.
26. Tsai HW, Chen YJ, Ho CM, et al. Maneuvers to Decrease Laparoscopy-Induced Shoulder and Upper Abdominal Pain A Randomized Controlled Study. *Arch Surg* 2011; 146(12): 1360-1366.
27. Pappas-Gogos G, Tsimogiannis KE, Zikos N, Nikas K, Manataki A, Tsimoyiannis EC. Preincisional and intraperitoneal ropivacaine plus normal saline infusion for postoperative pain relief after laparoscopic cholecystectomy: A randomized double-blind controlled trial. *Surg Endosc* 2008; 22(9): 2036-2045.
28. Kim TH, Kang H, Park JS, Chang IT, Park SG. Intraperitoneal Ropivacaine Instillation for Postoperative Pain Relief after Laparoscopic Cholecystectomy. *J Korean Surg Soc* 2010; 79: 130-136.
29. Barczynski M, Herman RM. Low-pressure pneumoperitoneum combined with intraperitoneal saline washout for reduction of pain after laparoscopic cholecystectomy. *Surg Endosc* 2003; 18(9): 1368-1373.