

# Circulation

JOURNAL OF THE AMERICAN HEART ASSOCIATION



## **Intravascular Ultrasound Evidence for Coarctation Causing Symptomatic Renal Artery Stenosis**

Trude C. Leertouwer, Elma J. Gussenhoven, Lukas C. van Dijk, Jeroen A. van Essen, Jan Honkoop, Jaap Deinum and Peter M. T. Pattynama

*Circulation* 1999;99:2976-2978

Circulation is published by the American Heart Association, 7272 Greenville Avenue, Dallas, TX 75214

Copyright © 1999 American Heart Association. All rights reserved. Print ISSN: 0009-7322. Online ISSN: 1524-4539

The online version of this article, along with updated information and services, is located on the World Wide Web at:

<http://circ.ahajournals.org/cgi/content/full/99/23/2976>

Subscriptions: Information about subscribing to *Circulation* is online at <http://circ.ahajournals.org/subscriptions/>

Permissions: Permissions & Rights Desk, Lippincott Williams & Wilkins, 351 West Camden Street, Baltimore, MD 21202-2436. Phone 410-5280-4050. Fax: 410-528-8550. Email: [journalpermissions@lww.com](mailto:journalpermissions@lww.com)

Reprints: Information about reprints can be found online at <http://www.lww.com/static/html/reprints.html>

# Intravascular Ultrasound Evidence for Coarctation Causing Symptomatic Renal Artery Stenosis

Trude C. Leertouwer, MSc; Elma J. Gussenhoven, MD;  
Lukas C. van Dijk, MD; Jeroen A. van Essen, MD; Jan Honkoop, BSc;  
Jaap Deinum, MD; Peter M.T. Pattynama, MD

**Background**—A recent study of human cadaveric renal arteries revealed that renal artery narrowing could be due not only to atherosclerotic plaque compensated for by adaptive remodeling, but also to hitherto undescribed focal narrowing of an otherwise normal renal arterial wall (ie, coarctation). The present study investigated whether vessel coarctation could be identified in patients with symptomatic renal artery stenosis (RAS).

**Methods and Results**—Consecutive symptomatic patients with angiographically proven atherosclerotic RAS who were referred for stent placement were studied by 30-MHz intravascular ultrasound before intervention (n=18) or after predilatation (n=18). Analysis included assessment of the media-bounded area and plaque area (PLA) at the most stenotic site and at a distal reference site (most distal cross-section in the main renal artery with normal appearance). Coarctation was considered present whenever the target/reference media-bounded area was  $\leq 85\%$ . Before intervention, coarctation was observed in 9 of 18 patients and adaptive remodeling in 9 of 18 patients. Coarctation lesions had a significantly smaller PLA than adaptive remodeled lesions ( $P=0.001$ ). Similarly, despite predilatation, coarctation was seen in 8 of 18 patients who had significantly smaller PLAs ( $P=0.008$ ) when compared with those patients who had adaptive remodeled lesions. No differences in severity of RAS or angiographic or clinical parameters were observed.

**Conclusions**—Low-plaque coarctation may cause a considerable proportion of symptomatic RAS, which is angiographically and clinically indistinguishable from plaque-rich RAS. (*Circulation*. 1999;99:2976-2978.)

**Key Words:** renal artery ■ stenosis ■ hypertension ■ ultrasonography, interventional

It is generally accepted that atherosclerotic plaque accumulation is the principal cause of renal artery stenosis (RAS).<sup>1,2</sup> A recent intravascular ultrasound (IVUS) study in human renal arteries obtained at autopsy, however, suggested an alternative cause of RAS.<sup>3</sup> In that study, we observed that in 60% of the specimens, plaque accumulation, with or without compensatory vessel enlargement (ie, adaptive remodeling), caused lumen narrowing. This phenomenon was first described by Glagov et al<sup>4</sup> and, subsequently, by others.<sup>5,6</sup> In the remaining 40% of the specimens, however, focal narrowing of the renal artery wall with little or no plaque was observed. Here, we propose the term "coarctation" to describe the latter condition (*Dorland's Medical Dictionary* defines coarctation as "a condition of stricture or contraction").

If this condition is present in vivo, it might cause hemodynamically significant RAS. However, to the best of our knowledge, renal artery coarctation has not been described before in vivo, especially not in patients with atherosclerotic renal vascular disease. The first aim of the present study was, therefore, to establish whether renal artery coarctation could be identified as a contributing factor to RAS in symptomatic

patients with angiographically proven RAS. The second aim was to identify angiographic and/or clinical variables that might be predictive for the distinguishing lesions.

## Methods

Between September of 1996 and March of 1999, we studied 48 consecutive patients (16 women and 32 men aged  $59 \pm 9$  years [mean  $\pm$  SD]) with hypertension and/or renal function impairment and atherosclerotic RAS who were referred for percutaneous transluminal stent placement guided by IVUS. Previous angiograms had revealed  $>50\%$  diameter stenosis in all patients. The Local Committee of Human Research approved the investigation. Patients were included in the study after informed consent was obtained.

Revascularization was performed via the femoral approach. The stenosis was crossed with a 5F selective catheter in combination with 0.035-in hydrophilic guidewire (Terumo). The hydrophilic wire was exchanged for a 0.020-in stiff guidewire with a flexible tip (Boston Scientific) for guiding the IVUS catheter, the angioplasty balloon, and the balloon-expandable stent. A 30-MHz mechanical IVUS imaging system was used with 4.3F catheters ("Princeps", EndoSonics).<sup>8</sup> The IVUS catheter was positioned distally from the stenosis in the first major side branch. Real-time cross-sectional images of the renal artery wall obtained during slow pullback of the IVUS catheter

Received February 2, 1999; revision received April 6, 1999; accepted April 20, 1999.

From the Departments of Radiology (T.C.L., L.C.v.D., P.M.T.P.), Internal Medicine (T.C.L., J.D.), and Cardiology (E.J.G., J.A.v.E., J.H.), the Erasmus University Medical Center, Rotterdam, and the Interuniversity Cardiology Institute (E.J.G., J.A.v.E.), The Netherlands.

Correspondence to Elma J. Gussenhoven, MD, Erasmus University Rotterdam (Ee 2312), Dr. Molewaterplein 50, 3000 DR Rotterdam, The Netherlands. E-mail leertouwer@tch.fgg.eur.nl

© 1999 American Heart Association, Inc.

*Circulation* is available at <http://www.circulationaha.org>

were displayed on a monitor and stored on S-VHS videotape for off-line analysis.

### Image Analysis

From each renal artery, multiple IVUS cross-sections were quantitatively analyzed to select the target site and a reference site for further analysis. The target site was the IVUS cross-section with the smallest lumen area. The reference site was the most distal cross-section in the renal artery truncus with a normal appearance. Analysis included assessment of lumen area (LA), media-bounded area (MBA), plaque area (PLA), and percentage area stenosis. LA was defined as the area encompassed by the inner boundary of the intimal surface. MBA was defined as the native vessel area bounded by the external elastic lamina. PLA was calculated by subtracting LA from MBA. Percentage area stenosis was calculated as the LA at the target site divided by the LA at the reference site.

The MBA at the target site was expressed as a percentage of the MBA at the reference site. A relative MBA of >85% at the target site indicated a similar or larger MBA ("adaptive remodeling" group), and a relative MBA of  $\leq 85\%$  at the target site indicated a smaller MBA than at the reference site ("coarctation" group). On the basis of our previous observation that renal artery tapering does not occur,<sup>3</sup> we used a 15%-tolerance interval to define a smaller MBA to be on the conservative side. We assessed whether the conclusions of the quantitative analysis, which were performed by 2 independent observers (T.C.L. and J.A.v.E.), were consistent for the observers individually. Mean values of the 2 observers are given.

### Statistical Analysis

The 2 groups were compared with regard to the MBA and PLA at the target and reference sites, relative MBA, and percentage area stenosis. Student's *t* tests were used at the  $P < 0.05$  significance level. Interobserver variability for quantitative IVUS measurements was quantified by regression analysis and a coefficient of variation, which was defined as the standard deviation of the paired difference divided by the mean of the absolute value. Multivariate logistic regression analysis was performed to predict the presence of either of the 2 lesions.

A logistic regression model was fitted using angiographic and clinical parameters as the independent variables. Angiographically, a distinction was made between ostial and truncal lesions.<sup>9</sup> Dependence on the following clinical characteristics was assessed: age, sex, signs and symptoms of atherosclerotic vascular disease (angina pectoris, intermittent claudication, cerebrovascular accident, or vascular surgery), onset of hypertension (<1, 1 to 2, 2 to 5, or >5 years), smoking history (ever or never), obesity (body mass index  $\geq 25$  kg/m<sup>2</sup>), serum creatinine concentration, and hypercholesterolemia (serum cholesterol level >6.5 mmol/L or use of cholesterol-lowering agents). In addition, we assessed whether any differences were found in the initial technical success rate or the 3-month clinical results (systolic and diastolic blood pressure, number of antihypertensive drugs, and serum creatinine level) between the 2 groups.

### Results

IVUS images were obtained in 18 patients before intervention and in 18 other patients after predilatation with an angioplasty balloon 5 or 6 mm in diameter. In the remaining 12 patients, the interventionist did not use IVUS before stent placement.

Quantitative IVUS data for the group studied before intervention are given in the Table. Nine of 18 patients showed the coarctation phenomenon, with an MBA at the target site of  $24.0 \pm 5.1$  mm<sup>2</sup>, which was significantly smaller than that in the adaptive remodeling group ( $33.9 \pm 6.8$  mm<sup>2</sup>,  $P = 0.003$ ; Figure). PLA in the coarctation group ( $13.9 \pm 4.4$  mm<sup>2</sup>) was also significantly smaller than in the adaptive remodeling group ( $23.7 \pm 6.1$  mm<sup>2</sup>;  $P = 0.001$ ). Quantitative parameters at the reference site and the degree of

### Quantitative Cross-Sectional Intravascular Ultrasound Data of Renal Arteries Before Intervention (n=18) and After Predilatation (n=18)

	Adaptive Remodeling Group	Coarctation Group	P
Before intervention	n=9	n=9	
Target			
MBA, mm <sup>2</sup>	33.9±6.8	24.0±5.1	0.003
PLA, mm <sup>2</sup>	23.7±6.1	13.9±4.4	0.001
Reference			
MBA, mm <sup>2</sup>	33.5±7.6	33.9±3.8	NS
PLA, mm <sup>2</sup>	7.9±2.0	7.8±1.4	NS
MBA target/reference, %	103±13	71±11	<0.001
Area stenosis target/reference, %	61.2±19.7	61.4±19.3	NS
After predilatation	n=10	n=8	
Target			
MBA, mm <sup>2</sup>	43.0±12.4	24.1±10.6	0.004
PLA, mm <sup>2</sup>	28.2±13.0	12.3±8.0	0.008
Reference			
MBA, mm <sup>2</sup>	33.2±6.3	35.2±17.1	NS
PLA, mm <sup>2</sup>	7.8±1.9	6.9±2.8	NS
MBA target/reference, %	130±31	70±10	<0.001
Area stenosis target/reference, %	42.5±18.0	52.1±17.3	NS

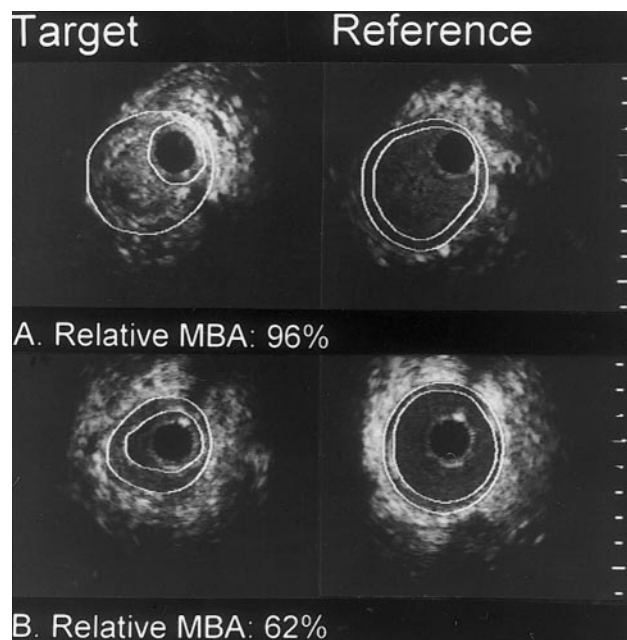
Renal arteries are divided into the adaptive remodeling and coarctation groups according to the relative MBA at the target site (>85% and  $\leq 85\%$ , respectively). Values are mean  $\pm$  SD and represent the averaged results of the 2 independent observers. NS indicates not significant.

area stenosis were not significantly different between the 2 groups. Similar results were found in the 18 patients studied after predilatation (Table).

The 2 observers showed good observer agreement with regard to the IVUS measurements, with a high correlation coefficient ( $r = 0.98$ ; observer 2 =  $0.98 \times$  observer 1 +  $0.64$  mm<sup>2</sup>) and an overall coefficient of variation of 10.7%. The conclusions were consistent for each observer individually. Multivariate regression analysis did not reveal any angiographic or clinical parameter predictive for either adaptive remodeling or coarctation; no differences were encountered in initial technical success and 3-month clinical outcome between the 2 groups.

### Discussion

The conventional concept of development and progression of atherosclerotic RAS is the accumulation of plaque, with or without compensatory vessel enlargement (ie, adaptive remodeling). The current findings suggest an alternative mechanism of symptomatic RAS, characterized by focal narrowing of the renal artery wall and little plaque (ie, coarctation). The latter phenomenon was responsible for symptomatic RAS in 50% of patients, a prevalence of coarctation similar to that previously seen in our autopsy study.<sup>3</sup> Coarctation could be identified even after balloon dilatation in 44% of the patients. The present study is the first in which coarctation as a cause of RAS was evidenced clinically. It is noteworthy that 32 years ago, McCormack et al<sup>10</sup> described a proportion of histologic RAS with "arterial spasm fixed by accumulation of



IVUS cross-sections obtained from renal arteries before intervention showing adaptive remodeling (A) and coarctation (B) types of renal artery stenosis. Left panels represent target sites, and right panels indicate reference sites. Cross-sections are contour-traced, facilitating recognition of LA (inner contour) and MBA (outer contour). Note relatively small media-bounded area and little plaque seen in coarctation stenosis (B). Calibration=1 mm; black circle=catheter.

collagen,” which may reflect the coarctation seen in the present study. In our previous autopsy study in which we combined IVUS with histologic analysis, however, coarctation was not associated with specific histologic characteristics. Mintz et al<sup>11</sup> described de novo stenotic lesions in coronary arteries that were characterized by inadequate remodeling and less plaque than expected. One might postulate that these coronary lesions are similar to the coarctation lesions in renal arteries seen in the present study.

The pathogenesis of coarctation RAS obviously remains speculative at this stage. Abdominal aortic coarctation, with or without involvement of the renal arteries, may be related to renal artery coarctation but, as with fibromuscular dysplasia, Takayasu’s arteritis, and neurofibromatosis, this is a relatively rare cause of RAS that commonly involves younger patients. In the present study, angiographic and clinical data were similar for both the adaptive remodeling and the coarctation groups. In the coronary artery study of Mintz et al,<sup>11</sup> a significant association was found between inadequate remodeling lesions and the extent of lesion calcium. This led the authors to postulate that inadequate remodeling was a manifestation of advanced atherosclerosis. In the present study in renal arteries, however, only small, incidental speckles of calcium were present, both in the adaptive remodeling and the coarctation groups. This, together with the fact that coarctation was also evident in human cadaveric renal arteries without plaque accumulation, suggests that in renal arteries, coarctation is a non-plaque-determined phenomenon, possibly related to an early rather than a late stage of atherosclerosis or perhaps not even related to atherosclerosis at all.

### Clinical Implications

The heterogeneity of atherosclerotic RAS, as shown in the present study, may have important clinical implications. Plaque-focused treatment by means of intravascular radiation therapy or plaque-lowering agents could be of minor importance for coarctation RAS. In addition, renal artery revascularization by either balloon angioplasty or stent placement is clinically successful in only part of the patient population treated.<sup>12</sup> Currently, which parameters determine the outcome of revascularization is insufficiently known. Whether the type of RAS determines the outcome of intervention is a question that will be investigated in future studies.

A limitation of our study was that IVUS images were not obtained in all 48 patients. This may have resulted in a selection bias; the prevalence of coarctation RAS as presented here must, therefore, be interpreted with caution.

### Acknowledgments

We thank Johanna L. Bosch, Department of Biostatistics, for performing the multivariate analysis and Teun Rijdsdijk for the photographic work. This project was supported by grants from the Revolving Fund (1996-26) of the Erasmus University Medical Center, Rotterdam, and Cordis (a Johnson & Johnson Company).

### References

- Holley KE, Hunt JC, Brown AL, Kincaid OW, Sheps SG. Renal artery stenosis: a clinical-pathologic study in normotensive and hypertensive patients. *Am J Med.* 1964;37:14–22.
- Schwartz CJ, White TA. Stenosis of the renal artery: an unselected necropsy study. *BMJ.* 1964;2:1415–1421.
- Leertouwer TC, Gussenhoven EJ, van Jaarsveld BC, van Overhagen H, Bom N, Man in ‘t Veld AJ. In vitro validation, with histology, of intravascular ultrasound in renal arteries. *J Hypertens.* 1999;17:271–277.
- Glagov S, Weisenberg E, Zarins CK, Stankunavicius R, Kolettis GJ. Compensatory enlargement of human atherosclerotic coronary arteries. *N Engl J Med.* 1987;316:1371–1375.
- Pasterkamp G, Borst C, Post MJ, Mali WP, Wensing PJ, Gussenhoven EJ, Hillen B. Atherosclerotic arterial remodeling in the superficial femoral artery: individual variation in local compensatory enlargement response. *Circulation.* 1996;93:1818–1825.
- Berglund H, Luo H, Nishioka T, Fishbein MC, Eigler NL, Tabak SW, Siegel RJ. Highly localized arterial remodeling in patients with coronary atherosclerosis: an intravascular ultrasound study. *Circulation.* 1997;96:1470–1476.
- Dorland’s Illustrated Medical Dictionary.* 28th ed. Philadelphia, Pa: WB Saunders Co; 1994.
- Bom N, ten Hoff H, Lancee CT, Gussenhoven WJ, Bosch JG. Early and recent intraluminal ultrasound devices. *Int J Cardiac Imaging.* 1989;4:79–88.
- Kaatee R, Beek FJ, Verschuyel EJ, van de Ven PJ, Beutler JJ, van Schaik JP, Mali WP. Atherosclerotic renal artery stenosis: ostial or truncal? *Radiology.* 1996;199:637–640.
- McCormack LJ, Poutasse EF, Meaney TF, Noto TJ Jr, Dustan HP. A pathologic-arteriographic correlation of renal arterial disease. *Am Heart J.* 1966;72:188–198.
- Mintz GS, Kent KM, Pichard AD, Satler LF, Popma JJ, Leon MB. Contribution of inadequate arterial remodeling to the development of focal coronary artery stenoses: an intravascular ultrasound study. *Circulation.* 1997;95:1791–1798.
- Blum U, Krumme B, Flugel P, Gabelmann A, Lehnert T, Buitrago-Tellez C, Schollmeyer P, Langer M. Treatment of ostial renal-artery stenoses with vascular endoprotheses after angiographic unsuccessful balloon angioplasty. *N Engl J Med.* 1997;336:459–465.