

# Circulation

JOURNAL OF THE AMERICAN HEART ASSOCIATION



## **Positive Geometric Vascular Remodeling Is Seen After Catheter-Based Radiation Followed by Conventional Stent Implantation but Not After Radioactive Stent Implantation**

I. Patrick Kay, Manel Sabaté, Marco A. Costa, Ken Kozuma, Mariano Albertal, Willem J. van der Giessen, Alexander J. Wardeh, Jurgen M. R. Ligthart, Veronique M. A. Coen, Peter C. Levendag and Patrick W. Serruys

*Circulation* 2000;102;1434-1439

Circulation is published by the American Heart Association, 7272 Greenville Avenue, Dallas, TX 75214

Copyright © 2000 American Heart Association. All rights reserved. Print ISSN: 0009-7322. Online ISSN: 1524-4539

The online version of this article, along with updated information and services, is located on the World Wide Web at:

<http://circ.ahajournals.org/cgi/content/full/102/12/1434>

Subscriptions: Information about subscribing to *Circulation* is online at  
<http://circ.ahajournals.org/subscriptions/>

Permissions: Permissions & Rights Desk, Lippincott Williams & Wilkins, 351 West Camden Street, Baltimore, MD 21202-2436. Phone 410-5280-4050. Fax: 410-528-8550. Email:  
[journalpermissions@lww.com](mailto:journalpermissions@lww.com)

Reprints: Information about reprints can be found online at  
<http://www.lww.com/static/html/reprints.html>

# Positive Geometric Vascular Remodeling Is Seen After Catheter-Based Radiation Followed by Conventional Stent Implantation but Not After Radioactive Stent Implantation

I. Patrick Kay, MBChB; Manel Sabaté, MD; Marco A. Costa, MD; Ken Kozuma, MD; Mariano Albertal, MD; Willem J. van der Giessen, MD, PhD; Alexander J. Wardeh, MD; Jurgen M.R. Ligthart, BSc; Veronique M.A. Coen, MD; Peter C. Levendag, MD, PhD; Patrick W. Serruys, MD, PhD

**Background**—Recent reports demonstrate that intracoronary radiation affects not only neointimal formation but also vascular remodeling. Radioactive stents and catheter-based techniques deliver radiation in different ways, suggesting that different patterns of remodeling after each technique may be expected.

**Methods and Results**—We analyzed remodeling in 18 patients after conventional stent implantation, 16 patients after low-activity radioactive stent implantation, 16 patients after higher activity radioactive stent implantation, and, finally, 17 patients who underwent catheter-based radiation followed by conventional stent implantation. Intravascular ultrasound with 3D reconstruction was used after stent implantation and at the 6-month follow-up to assess remodeling within the stent margins and at its edges. Preprocedural characteristics were similar between groups. In-stent neointimal hyperplasia (NIH) was inhibited by high-activity radioactive stent implantation (NIH 9.0 mm<sup>3</sup>) and by catheter-based radiation followed by conventional stent implantation (NIH 6.9 mm<sup>3</sup>) compared with low-activity radioactive stent implantation (NIH 21.2 mm<sup>3</sup>) and conventional stent implantation (NIH 20.8 mm<sup>3</sup>) ( $P=0.008$ ). No difference in plaque or total vessel volume was seen behind the stent in the conventional, low-activity, or high-activity stent implantation groups. However, significant increases in plaque behind the stent (15%) and in total vessel volume (8%) were seen in the group that underwent catheter-based radiation followed by conventional stent implantation. All 4 groups demonstrated significant late lumen loss at the stent edges; however, edge restenosis was seen only in the group subjected to high-activity stent implantation and appeared to be due to an increase in plaque and, to a lesser degree, to negative remodeling.

**Conclusions**—Distinct differences in the patterns of remodeling exist between conventional, radioactive, and catheter-based radiotherapy with stenting. (*Circulation*. 2000;102:1434-1439.)

**Key Words:** stents ■ remodeling ■ radioisotopes ■ angioplasty ■ ultrasonics

In our enthusiasm to control vessel recoil and remodeling after balloon angioplasty (BA), stent implantation has become increasingly popular. With conventional stenting, we have eliminated recoil and remodeling as components of the restenotic process. However, this has been at the cost of exacerbating neointimal proliferation secondary to chronic vessel wall irritation, leading to in-stent restenosis.<sup>1,2</sup>

Intracoronary radiation has been developed in an attempt to decrease restenosis after BA and stent implantation. Two parallel technologies, one using radioactive stents<sup>3-7</sup> and the other using catheter-based radiation,<sup>8-10</sup> have been the subject of both animal and human studies. Given the different dose rates and total doses delivered by each method, one may

intuitively expect different patterns of remodeling subsequent to each approach.

Whereas the effect of catheter-based radiation after BA on vascular remodeling has been described,<sup>11</sup> the response of the arterial wall to catheter-based radiation and subsequent stent implantation has not been described. Preliminary studies have reported the effect at the stent edge after radioactive stent implantation.<sup>4</sup> However, these reports did not encompass the response behind the stent in the arterial wall.

The aim of the present study was to describe the response of the coronary artery to radiation and stenting by examining the stent and its edges after radioactive stent implantation and also after catheter-based radiation with stent implantation.

Received December 30, 1999; revision received April 12, 2000; accepted April 14, 2000.  
From the Thoraxcenter (I.P.K., M.S., M.A.C., K.K., M.A., W.J.v.d.G., A.J.W., J.M.R.L., P.W.S.) and the Daniel den Hoed Cancer Center (V.M.A.C., P.C.L.), Rotterdam, the Netherlands.

Correspondence to P.W. Serruys, MD, PhD, FACC, FESC, Professor of Interventional Cardiology, Department of Interventional Cardiology, Bd 418, Thoraxcenter, Academisch Ziekenhuis Rotterdam, PO Box 1738, Dr. Molewaterplein 40, 3000 DR Rotterdam, Netherlands. E-mail serruys@card.azr.nl  
© 2000 American Heart Association, Inc.

**TABLE 1. Clinical Characteristics**

	Groups			
	C	LA	HA	CBS
Patients, n	18	16	15	17
Age, y	58 (42–76)	60 (43–74)	59 (42–75)	57 (45–74)
Male, %	70	66	70	60
Prior MI, %	40	40	45	40
Unstable angina, %	60	50	65	55
Smoking, %	40	55	40	40
Hypercholesterolemia, %	60	62	65	55
Family history, %	33	42	30	40
Hypertension, %	40	42	30	33
Diabetes, %	5	5	10	6

Age values are mean (range). MI indicates myocardial infarction.

**Methods**

**Patient Selection**

We analyzed geometric vascular remodeling in 4 groups of patients: (1) LA group, those who had undergone implantation of <sup>32</sup>P-emitting radioactive stents at activity levels of 0.75 to 1.5 μCi (Isostent Inc); (2) HA group, those who had undergone implantation of <sup>32</sup>P radioactive stents at activity levels of 6.0 to 12 μCi (Isostent Inc); (3) CBS group, those who had undergone conventional stent implantation after suboptimal BA (clinically significant dissection or residual stenosis >30%) and catheter-based radiation; and (4) C group, those who had undergone conventional stent implantation after suboptimal BA .

Stents analyzed were from patients with single–native-vessel coronary artery disease, normal left ventricular function, and objective evidence of ischemia. All groups were matched for patient baseline characteristics, vessel size, lesion, and stent length. Stents placed in the ostial position or adjacent to major side branches, such that the stent edges were unable to be analyzed, were excluded from analysis. Only patients who had completed 6-month angiographic and intravascular ultrasound (IVUS) follow-up were included.

**Implantation Technique**

The same group of cardiologists, using a similar technique, implanted all stents. Predilation of the lesion was performed, followed

by stent implantation with use of either a premounted stent or the Johnson & Johnson delivery system (Johnson & Johnson Interventional Systems Co). A balloon shorter than the stent was then selected, and high-pressure balloon inflation was performed within the stent to ensure good stent apposition. Intravascular ultrasound was used to ensure optimal stent deployment.

**Medication**

Patients received 250 mg aspirin and 10 000 IU heparin at the initiation of the procedure, and the activated clotting time was maintained at >300 seconds. All patients received aspirin (80 mg daily) indefinitely and ticlopidine (250 mg BID) for 2 weeks (C group) or clopidogrel (75 mg daily) for 12 weeks (LA, HA, and CBS groups) after stent implantation.

**Radioactive Stents**

The BX stent (Isostent Inc) was the only radioactive stent implanted in this trial. It was 15 mm in length and available in diameters of 3.0 and 3.5 mm. The BX stent was made radioactive by <sup>32</sup>P. The initial activity of the stents was measured; thereafter, it was calculated at the date on which the activity had decreased to 0.75 to 1.5 μCi or 6 to 12 μCi, levels suitable for implantation.

**Catheter-Based Radiation Delivery System**

The Beta-Cath System (Novoste Corp) was used to deliver localized β-radiation (<sup>90</sup>Sr/<sup>90</sup>Y) to a depth of 2 mm from the center of the

**TABLE 2. Procedural Characteristics**

	Groups			
	C	LA	HA	CBS
Vessels, n				
LAD	10	9	9	9
LCx	4	3	3	4
RCA	4	4	3	4
Lesion length, mm	9.6±3.3	12.1±3.8	10.1±3.3	11.9±4
Stent length, mm	14.6±3.8	15.0	15.0	15.2±4.1
Balloon length after implantation, mm	14.8±3.4	14.4±2.8	14.1±2.6	15.1±3.6
Final balloon size, mm	3.2±0.4	3.1±0.6	3.4±0.5	3.2±0.5
Max inflation pressure 1	11.5±2.4	11.6±2.6	10.2±2.8	12.2±2.6
Max inflation pressure 2	14.6±3.2	15.2±2.4	15.8±1.7	15.4±3.3
Balloon-to-artery ratio	1.04±0.05	1.12±0.06	1.10±0.06	1.12±0.05

Values are mean±SD. LAD indicates left anterior descending coronary artery; LCx, left circumflex coronary artery; RCA, right coronary artery; Max inflation pressure 1, balloon at time of stent implantation; and Max inflation pressure 2, balloon inflation within stent.

**TABLE 3. Volumes for Edge Proximal and Distal to Stent (10-mm Length)**

Group	Edge, mm <sup>3</sup>					
	LV		TVV		Plaque	
	Post	F/UP	Post	F/UP	Post	F/UP
C	67.7±18.9	58.3±19.3*	124.4±32.6	116.5±34.1*	56.7±22.6	58.2±23.1
LA	75.2±39.0	67.3±34.4*	126.6±58.0	116.4±49.0*	51.4±24.5	49.1±21.0
HA	74.9±23.0	63.0±23.7*	126.2±44.9	117.6±46.2*	51.3±16.4	54.6±16.1
CBS	72.6±27.7	61.1±26.3*	133.2±48.5	138.9±46.5†	60.6±26.1	77.8±28.6†

Values are mean±SD. Post indicates baseline; F/UP, follow-up.

\* $P<0.05$  vs Post (within-group comparison); † $P<0.05$  for between-group comparison (ANOVA).

source at the site of coronary intervention. The device consisted of 3 components: (1) the transfer device that stored the radiation source train and allowed the positioning of these sources within the catheter; (2) the delivery catheter, which was a 5F multilumen over-the-wire noncentered catheter that used saline solution to send and return the radiation source train; and (3) the radiation source train, which consisted of a series of 12 independent cylindrical seeds that contained the radioisotope <sup>90</sup>Sr sources and was bordered by 2 gold radiopaque markers separated by 30 mm. Other device and procedural details have been previously published by this group.<sup>11</sup>

## Definitions

### Stent Edges

Stent edges were defined as those volumes axially 5 mm proximal and distal to the final stent strut. An edge restenosis was defined as an angiographic restenosis >50% at 6-month follow-up located at either stent edge. An edge effect was defined as any stent-edge rearrowing.

Patients with balloon-injured edges that failed to receive radiation in the catheter-based radiation group were excluded. In other words, no stents implanted in areas of geographical miss were included in the present study.

### IVUS Image Acquisition Analysis

After the final balloon inflation and administration of intracoronary nitrates, ECG-gated IVUS pullback was performed. This was repeated at the 6-month follow-up.

The segment subjected to 3D reconstruction was examined with a mechanical IVUS system (ClearView, CVIS) with a sheath-based IVUS catheter incorporating a 30-MHz single-element transducer rotating at 1800 rpm. The IVUS transducer was withdrawn through the stationary imaging sheath by an ECG-triggered pullback device with a stepping motor.<sup>12</sup> IVUS images coinciding with the peak of the R wave, which eliminates the artifacts caused by the movement of the heart during the cardiac cycle, were acquired. After each image acquisition, the transducer was withdrawn 0.2 mm to acquire the next image coincident with the R wave. The ECG-gated image

acquisition and digitization was performed by a workstation designed for the 3D reconstruction of echocardiographic images<sup>12</sup> (EchoScan, Tomtec). A Microsoft Windows-based contour detection program, developed at the Thoraxcenter, Rotterdam, was used for the automated 3D analysis of up to 200 IVUS images.<sup>13</sup> The feasibility, reproducibility, and interobserver and intraobserver variability of this system have been previously validated in clinical protocols.<sup>11</sup>

### Quantitative IVUS Analysis

At the stent edges, the area encompassed by the lumen-intima and media-adventitia boundaries defined the luminal volume (LV) and the total vessel volume (TVV), respectively. The difference between LV and TVV defined the plaque volume. TVV, stent volume, neointimal hyperplasia (NIH), plaque behind the stent (TVV–stent volume), and LV were obtained within the axial boundaries of the stent.

The assessment of TVV in stented patients has previously been reported.<sup>14</sup> Although in the previous report the delineation of TVV was not possible in some patients because of stent shadowing, in the present study the delineation of the TVV boundary was possible in all stented patients. When the TVV boundary was not visible in a single cross-sectional view, the computer extrapolated it from the contours of the previous and subsequent cross sections. In addition, the use of 3D reconstruction with multiple longitudinal views facilitates the visualization of vessel structures outside the stent.

### Statistical Analysis

Quantitative data are presented as mean±SD. Volumetric data derived from the 3D reconstruction of the IVUS imaging were compared immediately after treatment and at follow-up by the 2-tailed paired Student *t* test. Comparison between groups was performed by 1-way ANOVA. A value of  $P<0.05$  was considered statistically significant.

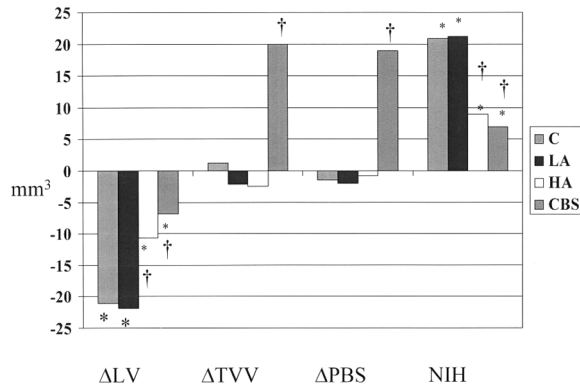
The Medical Ethical Committee of the University Hospital Rotterdam approved the study, and all patients provided written informed consent before the procedure.

**TABLE 4. Volumes for Stent**

Group	Stent, mm <sup>3</sup>						
	LV		TVV		PBS		NIH
	Post	F/UP	Post	F/UP	Post	F/UP	
C	113.9±29.7	92.8±28.7*	256.1±73.2	257.3±67.4	142.2±54.1	143.7±49.4	20.8±11.5
LA	127.3±42.6	105.5±40.1*	266.6±96.5	264.5±98.3	139.3±59.1	137.8±63.7	21.2±12.1
HA	122.4±20.0	111.7±24.3*	267.8±66.9	265.3±65.1	145.4±49.1	144.6±45.3	9.0±8.6†
CBS	128.6±41.3	121.8±41.6*	258.9±73.6	278.0±89.8*	130.3±34.2	149.3±49.8*	6.9±6.6†

Values are mean±SD. Post indicates baseline; F/UP, follow-up; and PBS, plaque behind the stent. No significant difference between groups was seen at baseline (Post).

\* $P<0.05$  vs Post (within-group comparison); † $P<0.05$  for between-group comparison (ANOVA).



**Figure 1.** Remodeling within margins of stent. PBS indicates plaque behind the stent. \* $P < 0.05$  for values immediately after treatment vs follow-up; † $P < 0.05$  for values between groups.

**Results**

**Baseline Characteristics**

Eighteen patients were enrolled in the conventional group (C group), 16 patients were enrolled in both the 0.75- to 1.5- $\mu$ Ci and the 6.0- to 12- $\mu$ Ci radioactive stent groups (LA and HA groups, respectively), and 17 patients were enrolled in the group subjected to catheter-based radiation plus a stent (CBS group). In the C group, 10 ACS Multi-Link (Guidant Corp) and 8 NIR (new intravascular rigid-flex stent; Boston Scientific/Scimed) stents were implanted, and in the CBS group, 8 NIR and 9 ACS Multi-Link stents were implanted. Baseline characteristics are similar between all groups and are described in Table 1. Lesion and procedural characteristics are described in Table 2. No statistically significant differences were seen between groups in the parameters described in Table 2. Comparisons of volumetric data measured at the stent edges and within the margins of the stent are presented in Tables 3 and 4.

**In-Stent Inhibition of NIH**

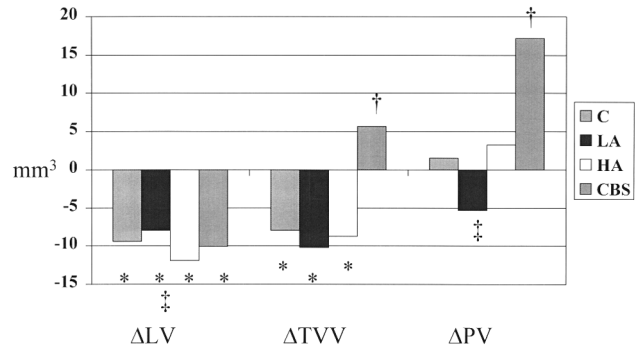
Intrastent NIH was decreased after high-activity radioactive stent implantation and catheter-based radiation followed by conventional stent implantation ( $P = 0.008$ ). Lower activity radioactive stents had an effect similar to that of conventional stent implantation (see Table 4 and Figure 1).

**Behind Stent**

The C, LA, and HA groups demonstrated an absence of remodeling behind the stent, with no significant changes in TVV or plaque volumes. This is in contrast to the CBS group, which demonstrated a significant increase in plaque (immediately after treatment versus follow-up, 15%;  $P = 0.002$ ) and an increase in TVV (after treatment versus follow-up, 8%;  $P = 0.003$ ). Intergroup comparison showed that this change was significant (Table 4,  $P = 0.01$ ). Further comparisons of changes within and between groups are demonstrated in Figure 1. No chronic recoil of the stent was seen in any group.

**Stent Edge**

No significant difference between groups was seen at baseline (after stent implantation). All groups demonstrated late lumen loss at the stent edges. At the stent edges, remodeling



**Figure 2.** Changes in volumes at stent edge. PV indicates plaque volume. \* $P < 0.05$  for values immediately after treatment vs follow-up; † $P < 0.05$  for values between groups; and ‡ $P = NS$  for  $\Delta LV$  (all groups) and  $\Delta PV$  (C, LA, and HA groups).

is similar in the C and LA groups. In these groups, there is evidence of a decrease in TVV, with little change in plaque as a cause of late lumen loss (Figure 2). In the HA group, a target segment restenosis (angiographically  $> 50\%$ ) was observed in 7 patients at the stent edges. This was more common at the proximal edge (in 6 of 7 patients). The major mechanism of such a restenosis appears to be due to an increase in plaque at the stent edge. In nonrestenotic patients, the edge effect appears to be due to a decrease in TVV and, to a lesser degree, an increase in plaque (Figure 3).

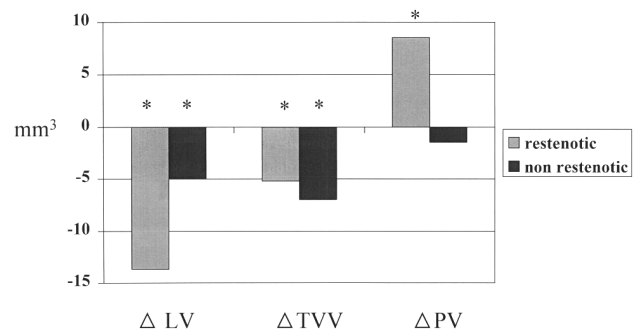
In the CBS group, the edge effect is largely due to an increase in plaque, with no negative remodeling seen ( $P = 0.045$  for plaque increase in CBS versus LA, HA, and C groups). No patient with edge restenosis after catheter-based radiation was seen in our series of patients.

**Stent Activity and Dose Prescribed**

Mean stent activity at implantation (LA group) was  $1.1 \pm 0.3$   $\mu$ Ci. Mean stent activity at implantation (HA group) was  $8.6 \pm 1.6$   $\mu$ Ci. For the CBS group, the mean dose prescribed was  $16.7 \pm 2.0$  Gy.

**Discussion**

The development of NIH within the stent witnessed at the 6-month follow-up is well appreciated<sup>15</sup>; however, the



**Figure 3.** High-activity (6.0- to 12.0- $\mu$ Ci) stents. Restenotic edges are compared with nonrestenotic edges.  $\Delta$  indicates change in volume (immediately after treatment vs follow-up). \* $P < 0.05$  for values immediately after treatment vs follow-up. Note greater lumen loss seen in restenotic group. This loss was caused by increase in plaque ( $P < 0.05$ ) and a less profound decrease in TVV ( $P < 0.05$ ).  $\Delta TVV$  is similar in both groups.

changes that occur at the stent edges or indeed behind the stent struts have not been the focus of attention until recently.<sup>4</sup> The present study is the first to describe the difference in vascular remodeling seen after radioactive stent implantation and catheter-based radiation plus stenting with the use of modern conventional stents as a benchmark. The key findings are as follows: (1) The degree of inhibition of NIH was similar in the HA and CBS groups. (2) There was no significant remodeling behind the stent after conventional or radioactive stent implantation; however, the CBS group demonstrated an increase in plaque behind the stent and in TVV. (3) At the stent edge, 3 patterns of remodeling are seen at the 6-month follow-up: first, a shrinkage in TVV and LV was noted in the C and LA groups. These 2 subgroups were not associated with stent edge restenosis in this series. After high-activity stent implantation, a pattern similar to conventional and low-activity stent implantation is seen in those edges that remain nonrestenotic; however, in the restenotic edges, plaque increase is the major contributor to lumen loss. In the CBS group, a lumen loss similar to that found in the other groups is seen; however, this occurs secondary to a relatively greater increase in plaque, without loss in TVV.

### Neointimal Hyperplasia

In the present study, neointimal formation was inhibited after higher dose radioactive stent implantation and after catheter-based radiation plus stenting. The present study is in contrast to the recent study by Carter et al,<sup>16</sup> who used <sup>32</sup>P stents in the porcine model, but is in keeping with earlier studies of Hehrlein et al,<sup>6</sup> who used the rabbit model, and recent reports by Albiero et al,<sup>4</sup> who noted a dose-dependent inhibition of NIH.

### Mechanism of Remodeling Behind the Stent

#### *Catheter-Based Radiation*

After conventional and radioactive stent implantation, little positive or negative remodeling is witnessed behind the stent. In stark contrast to this is the increase in plaque behind the stent and TVV seen after catheter-based radiation and stenting. Part of the key to understanding this process may be acquired from understanding the healing process after BA. Wilcox and colleagues<sup>17,18</sup> describe the presence of early proliferation of myofibroblasts expressing contractile proteins in the adventitia surrounding the porcine coronary artery after BA. Tracing studies have indicated that the same cells migrate and form part of the neointima. Wilcox and colleagues hypothesize that the adventitial myofibroblasts constrict the artery at the angioplasty site in much the same way as myofibroblasts participate in scar retraction in dermal healing. The source of these myofibroblasts may be distant to the immediate site of injury, including pericardial, adipose, and intramyocardial layers.<sup>19</sup>

Radiation treatment of porcine coronary arteries after BA upregulates p21 synthesis in adventitial cells, especially myofibroblasts. Such induction is dose dependent and is sustained for at least 7 days after radiation. Additionally, radiation inhibits the expression of growth factors, reduces the proliferation of adventitial myofibroblasts, and decreases the production of  $\alpha$ -actin by the adventitial myofibroblasts,

preventing the formation of the myofibroblast scar around the angioplasty site and negative vascular remodeling.<sup>17,20</sup> Data from Fareh and et al<sup>21</sup> suggest that inhibition of migration but not of cellular proliferation may occur at lower doses of radiation. Therefore, cells may remain in situ, unable to migrate but able to grow in the presence of a weakened external elastic membrane. After 1 week, the effect of the radiation diminishes, and cellular proliferation, possibly as a reaction to the presence of the stent, continues behind the stent in the context of positive vascular remodeling. In our cohort of patients, no cases of stent malapposition were seen at follow-up, although our group has described this as a risk of ongoing positive vascular remodeling.<sup>22,23</sup> A further concept to be explored is that relating to the sharp drop-off in radiation seen with the  $\beta$ -radiation source, which may cause underdosing deep in the adventitia and geographical miss<sup>24</sup> in a radial sense rather than the more commonly described longitudinal sense.

#### *Radioactive Stent*

The objective of using the radioactive stent is not to neutralize myofibroblasts in the adventitia; it is the prevention of the migration and invasion of myofibroblasts from the adventitia through the stent struts and into the lumen. As is seen in the HA group, this is accomplished by the continuous and low dose rate provided by the radioactive stent. Because of the range of the "radioactive fence" created, adventitial cells remain intact without upregulation of growth factors and inhibition of contractile proteins. Consequently, no remodeling is seen behind the radioactive stent at either activity level.

#### *Edge Remodeling*

Hoffmann et al<sup>15</sup> have previously described negative remodeling at the stent edge after conventional stent implantation. In the present study, we have been able to precisely describe the decrease in TVV as the dominant contributor to nonrestenotic lumen loss at the stent edge. Recent reports on radioactive stents suggest that the edge effect and edge restenosis may be due to an increase in plaque at the edge and to a component of negative remodeling as one moves axially from the stent.<sup>4</sup> The contributing factors to radioactive stent edge restenosis have been discussed in detail recently by Serruys and Kay.<sup>25</sup>

It may be argued that stent-edge restenosis was not seen in the CBS group because no individuals with geographical miss were evaluated. However, our objective in the present study was to analyze the vascular response to appropriately applied catheter-based radiation, which necessitates the exclusion of all those in whom injury was not covered by radiation. Recent reports have suggested that the combination of suboptimal low-dose radiation and injury may make individuals with geographical miss vulnerable to edge restenosis.<sup>26</sup>

### Study Limitations

This was a retrospective nonrandomized study of individuals who had completed 6 months of follow-up and in whom IVUS examination was possible. Individuals who had a total occlusion or in whom the IVUS catheter could not be passed under acceptable clinical circumstances were not included.

No edge restenosis was seen in the CBS group, unlike the HA group; however, both the CBS and the HA groups reflected the larger parent populations from which they were selected in all other features.

The dosimetry (catheter-based) described in the present study relates to prescribed doses only and does not necessarily reflect the dose delivered 2 mm from the source in the adventitia. Description of dosimetry is beyond the scope of the present study; however, previous work by the authors (Sabaté et al<sup>27</sup>), who used a similar radiation source and study population, suggests that delivered dose, residual plaque burden, and tissue composition play a fundamental role on the volumetric outcome at 6 months of follow-up after catheter-based  $\beta$ -radiation therapy and BA.

## Conclusions

Distinct differences in the patterns of remodeling exist between conventional, radioactive, and catheter-based radiotherapy with stenting. Users of radiation need to be alerted to edge restenosis seen after higher activity radioactive stent implantation and positive remodeling behind the stent seen after catheter-based radiation and stenting. Radiation, whether it be catheter or stent-based, has forced the interventional community to look closely not only at effective inhibition of intimal proliferation but also at the adverse response of the artery to the combination of injury and radiation.

## Acknowledgments

Dr Kay was supported by the National Heart Foundation of New Zealand and the Ian Gordon Mackenzie Scholarship, University of Otago, Dunedin, New Zealand. The Wenckebach award was made to Dr Serruys by the Dutch Heart Foundation and is used for brachytherapy research in the catheterization laboratory. We would like to thank Dr Josiah N. Wilcox of Emory University, Atlanta, Ga, for his valuable comments and criticism.

## References

1. Farb A, Sangiorgi G, Carter AJ, et al. Pathology of acute and chronic coronary stenting in humans. *Circulation*. 1999;99:44–52.
2. Murphy JG, Schwartz RS, Edwards WD, et al. Percutaneous polymeric stents in porcine coronary arteries: initial experience with polyethylene terephthalate stents. *Circulation*. 1992;86:1596–1604.
3. Wardeh AJ, Kay IP, Sabaté M, et al.  $\beta$ -Particle-emitting radioactive stent implantation: a safety and feasibility study. *Circulation*. 1999;100:1684–1689.
4. Albiero R, Adamian M, Corvaja N, et al. Radioactive <sup>32</sup>P  $\beta$ -particle emitting BX stent implantation in patients with coronary artery disease: a serial IVUS analysis of the 'candy wrapper' pattern of restenosis. *Eur Heart J*. 1999;20:408. Abstract.
5. Laird JR, Carter AJ, Kufs WM, et al. Inhibition of neointimal proliferation with low-dose irradiation from a  $\beta$ -particle-emitting stent. *Circulation*. 1996;93:529–536.
6. Hehrlein C, Stintz M, Kinscherf R, et al. Pure  $\beta$ -particle-emitting stents inhibit neointima formation in rabbits. *Circulation*. 1996;93:641–645.
7. Carter AJ, Laird JR, Bailey LR, et al. Effects of endovascular radiation from a  $\beta$ -particle-emitting stent in a porcine coronary restenosis model: a dose-response study. *Circulation*. 1996;94:2364–2368.
8. King SB III, Williams DO, Chogule P, et al. Endovascular  $\beta$ -radiation to reduce restenosis after coronary balloon angioplasty: results of the Beta Energy Restenosis Trial (BERT). *Circulation*. 1998;97:2025–2030.
9. Condado JA, Waksman R, Gurdziel O, et al. Long-term angiographic and clinical outcome after percutaneous transluminal coronary angioplasty and intracoronary radiation therapy in humans. *Circulation*. 1997;96:727–732.
10. Teirstein PS, Massullo V, Jani S, et al. Catheter-based radiotherapy to inhibit restenosis after coronary stenting. *N Engl J Med*. 1997;336:1697–1703.
11. Sabaté M, Serruys PW, van der Giessen WJ, et al. Geometric vascular remodeling after balloon angioplasty and  $\beta$ -radiation therapy: a three-dimensional intravascular ultrasound study. *Circulation*. 1999;100:1182–1188.
12. von Birgelen C, Mintz GS, Nicosia A, et al. Electrocardiogram-gated intravascular ultrasound image acquisition after coronary stent deployment facilitates on-line three-dimensional reconstruction and automated lumen quantification. *J Am Coll Cardiol*. 1997;30:436–443.
13. von Birgelen C, Di Mario C, Li W, et al. Morphometric analysis in three-dimensional intracoronary ultrasound: an in vitro and in vivo study performed with a novel system for the contour detection of lumen and plaque. *Am Heart J*. 1996;132:516–527.
14. Prati F, Di Mario C, Moussa I, et al. In-stent neointimal proliferation correlates with the amount of residual plaque burden outside the stent: an intravascular ultrasound study. *Circulation*. 1999;99:1011–1014.
15. Hoffmann R, Mintz GS, Dussaillant GR, et al. Patterns and mechanism of in-stent restenosis: a serial intravascular ultrasound study. *Circulation*. 1996;94:1247–1254.
16. Carter AJ, Scott D, Bailey L, et al. Dose-response effects in an atherosclerotic porcine coronary model. *Circulation*. 1999;100:1548–1554.
17. Wilcox JN, Nakahara K. Perivascular proliferative responses after angioplasty leading to post angioplasty restenosis. In: *Vascular Brachytherapy: New Perspectives*. London, UK: Remedica; 1999.
18. Scott NA, Ross CR, Dunn B, et al. Identification of a potential role for the adventitia in vascular lesion formation after balloon stretch injury of porcine coronary arteries. *Circulation*. 1996;93:2178–2187.
19. Nakahara K, Okamoto E, Galis ZS, et al. Adventitial expression of MMP-1, MMP-2, TIMP-1 and TIMP-2 during vascular remodeling after angioplasty of porcine coronary arteries. *Circulation*. 1999;100(suppl I):I-700. Abstract.
20. Wang H, Griendling KK, Scott NA, et al. Intravascular radiation inhibits cell proliferation and vascular remodeling after angioplasty by increasing the expression of P21 in adventitial myofibroblasts. *Circulation*. 1999;100(suppl I):I-700. Abstract.
21. Fareh J, Martel R, Kermani P, et al. Cellular effects of  $\beta$ -particle delivery on vascular smooth muscle cells and endothelial cells: a dose-response study. *Circulation*. 1999;99:1477–1484.
22. Sabaté M, van der Giessen WJ, Deshpande NV, et al. Late thrombotic occlusion of a malapposed stent 10 months after intracoronary brachytherapy. *Int J Cardiovasc Interv*. 1999;2:55–59.
23. Kozuma K, Costa MA, Sabate M, et al. Late stent malapposition occurring after intracoronary beta-irradiation detected by intravascular ultrasound. *J Invasive Cardiol*. 1999;11:651–655.
24. Paterson R. *The Treatment of Malignant Disease by Radiotherapy*. 2nd ed. London, UK: Edward Arnold Publishers; 1963.
25. Serruys PW, Kay IP. I like the candy, I hate the wrapper: the <sup>32</sup>P radioactive stent. *Circulation*. 2000;101:3–7.
26. Sabaté M, Costa MA, Kozuma K, et al. Geographical miss: a cause of treatment failure in radio-oncology applied to intracoronary radiation therapy. *Circulation*. 2000;101:2467–2471.
27. Sabaté M, Marijnissen JPA, Carlier SG, et al. Residual plaque burden, delivered dose, and tissue composition predict 6-month outcome after balloon angioplasty and  $\beta$ -radiation therapy. *Circulation*. 2000;101:2472–2477.