



## Improved identification of viable myocardium using second harmonic imaging during dobutamine stress echocardiography

F B Sozzi, D Poldermans, J J Bax, A Elhendy, E C Vourvouri, R Valkema, J De Sutter, A F L Schinkel, A Borghetti and J R T C Roelandt

*Heart* 2001;86:672-678  
doi:10.1136/heart.86.6.672

---

Updated information and services can be found at:  
<http://heart.bmj.com/cgi/content/full/86/6/672>

---

*These include:*

### References

This article cites 26 articles, 8 of which can be accessed free at:  
<http://heart.bmj.com/cgi/content/full/86/6/672#BIBL>

2 online articles that cite this article can be accessed at:  
<http://heart.bmj.com/cgi/content/full/86/6/672#otherarticles>

### Rapid responses

You can respond to this article at:  
<http://heart.bmj.com/cgi/eletter-submit/86/6/672>

### Email alerting service

Receive free email alerts when new articles cite this article - sign up in the box at the top right corner of the article

---

### Topic collections

Articles on similar topics can be found in the following collections

[Other imaging techniques](#) (1497 articles)  
[Ischemic heart disease](#) (2091 articles)

---

### Notes

---

To order reprints of this article go to:  
<http://www.bmjournals.com/cgi/reprintform>

To subscribe to *Heart* go to:  
<http://www.bmjournals.com/subscriptions/>

# Improved identification of viable myocardium using second harmonic imaging during dobutamine stress echocardiography

F B Sozzi, D Poldermans, J J Bax, A Elhendy, E C Vourvouri, R Valkema, J De Sutter, A F L Schinkel, A Borghetti, J R T C Roelandt

## Abstract

**Objective**—To determine whether, compared with fundamental imaging, second harmonic imaging can improve the accuracy of dobutamine stress echocardiography for identifying viable myocardium, using nuclear imaging as a reference.

**Patients**—30 patients with chronic left ventricular dysfunction (mean (SD) age, 60 (8) years; 22 men).

**Methods**—Dobutamine stress echocardiography was carried out in all patients using both fundamental and second harmonic imaging. All patients underwent dual isotope simultaneous acquisition single photon emission computed tomography (DISA-SPECT) with <sup>99m</sup>technetium-tetrofosmin/<sup>18</sup>F-fluorodeoxyglucose on a separate day. Myocardial viability was considered present by dobutamine stress echocardiography when segments with severe dysfunction showed a biphasic sustained improvement or an ischaemic response. Viability criteria on DISA-SPECT were normal or mildly reduced perfusion and metabolism, or perfusion/metabolism mismatch.

**Results**—Using fundamental imaging, 330 segments showed severe dysfunction at baseline; 144 (44%) were considered viable. The agreement between dobutamine stress echocardiography by fundamental imaging and DISA-SPECT was 78%,  $\kappa = 0.56$ . Using second harmonic imaging, 288 segments showed severe dysfunction; 138 (48%) were viable. The agreement between dobutamine stress echocardiography and DISA-SPECT was significantly better when second harmonic imaging was used (89%,  $\kappa = 0.77$ ,  $p = 0.001$  *v* fundamental imaging).

**Conclusions**—Second harmonic imaging applied during dobutamine stress echocardiography increases the agreement with DISA-SPECT for detecting myocardial viability.

(Heart 2001;86:672-678)

Keywords: dobutamine stress echocardiography; second harmonic imaging; <sup>18</sup>F-fluorodeoxyglucose imaging; myocardial viability

In patients with severe left ventricular dysfunction, myocardial revascularisation reduces heart failure symptoms and improves long term survival. There is a relation between the amount of viable tissue and the expected benefit of revascularisation.<sup>1,2</sup> Various tests are available and can broadly be divided into two groups—nuclear testing and stress echocardiography. Single photon emission computed tomography (SPECT) with either <sup>201</sup>thallium or <sup>99m</sup>technetium labelled agents evaluates myocardial perfusion, which is dependent on cell membrane integrity and active cellular uptake. Positron emission tomography evaluates myocardial metabolism and allows the detection of metabolic activity in the hypoperfused myocardium.<sup>3-6</sup>

Nuclear imaging techniques are more sensitive than dobutamine stress echocardiography for detecting viability.<sup>4,7,8</sup> This is probably because nuclear imaging techniques are based on the detection of the integrity of the cell membrane and of preserved perfusion and metabolism (structural viability), whereas dobutamine stress echocardiography relies on the assessment of preserved contractile reserve (functional viability).<sup>8</sup> Dysfunctional myocardium that has suffered more profound ultrastructural damage will probably lose contractile reserve but can still

show intact cell membrane integrity and preserved perfusion and metabolism.<sup>9,10</sup> Despite this physiological explanation for the discrepancy between the tests, technical limitations may also be responsible for the discordance, owing to the suboptimal segmental endocardial border definition, present in at least 30% of patients evaluated by echocardiography using fundamental imaging.<sup>11-15</sup>

Our aim in this study was to determine whether second harmonic imaging can improve the accuracy of dobutamine stress echocardiography for identifying viable myocardium compared with fundamental imaging, using a dual isotope (<sup>99m</sup>technetium, tetrofosmin and <sup>18</sup>F-fluorodeoxyglucose) simultaneous acquisition (DISA) method as a reference.<sup>16</sup>

## Methods

### PATIENTS

Thirty patients underwent both dobutamine stress echocardiography and DISA-SPECT for evaluation of myocardial viability. The tests were performed in a random order within one week. All patients underwent coronary angiography within three months of the two tests. Patients were referred to our imaging laboratory for evaluation of myocardial viability and were not selected on the basis of echocardiographic or nuclear imaging quality. The

Thoraxcenter,  
Erasmus Medical  
Centre, Dr  
Molewaterplein 40,  
3015 GD Rotterdam,  
Netherlands  
F B Sozzi  
D Poldermans  
J J Bax  
A Elhendy  
E C Vourvouri  
R Valkema  
J De Sutter  
A F L Schinkel  
J R T C Roelandt

Department of  
Medicine, Nephrology  
and Health Science,  
Parma University,  
Italy  
A Borghetti

Correspondence to:  
Dr Poldermans  
poldermans@hkd.azr.nl

Accepted 8 August 2001

Table 1 Clinical and angiographic characteristics of the study population

Characteristic (n=30)	n (%)
Sex (male)	22 (73)
Age (years)	60 (8)*
Ejection fraction	37.7 (15.3)*
History of angina pectoris	26 (87)
Previous myocardial infarction	28 (93)
Anterior	15 (50)
Inferior	13 (43)
Hypertension	2 (7)
Hypercholesterolaemia	22 (73)
Diabetes mellitus	4 (13)
Smoking	10 (33)
β Blockers	20 (67)
Calcium channels blockers	9 (30)
Previous coronary artery bypass	10 (33)
Previous PTCA	7 (23)
Significant coronary artery disease	30 (100)
One vessel disease	13 (43)
Two vessel disease	10 (34)
Three vessel disease	7 (23)

\*Mean (SD).

PTCA, percutaneous transluminal coronary angioplasty.

characteristics of the patients are given in table 1. The local medical ethics committee approved the study protocol and all patients gave informed consent to undergo the test.

#### DOBUTAMINE STRESS TEST

After baseline echocardiography, dobutamine was infused at a starting dose of 5 µg/kg/min for five minutes, followed by 10 µg/kg/min for five minutes (low dose stage). The dobutamine dose was increased by 10 µg/kg/min every three minutes up to a maximum dose of 40 µg/kg/min. Atropine (up to 2 mg) was given intravenously at the end of the last stage if the target heart rate was not achieved. End points of the test were: achievement of target heart rate (85% of the maximum heart rate predicted for age); maximum dose of dobutamine and atropine; extensive new wall motion abnormalities; > 2 mV down sloping ST segment depression measured 80 ms from the J point compared with baseline; hypertension (blood pressure > 240/120 mm Hg), a decrease in systolic blood pressure of > 40 mm Hg compared with rest, significant arrhythmias, or any intolerable adverse effect considered to be the result of dobutamine or atropine. Metoprolol (1–5 mg) was used intravenously to reverse the side effects of dobutamine.

#### ECHOCARDIOGRAPHIC IMAGING

Imaging was achieved with a Hewlett-Packard Sonos 5500 ultrasonographic system (Hewlett-Packard Inc, Andover, Massachusetts, USA). We used a transducer operating at fundamental frequencies of 1.8 or 2.1 MHz and collecting second harmonic frequencies at 3.6 MHz or 4.2 MHz. Fundamental and second harmonic images were obtained at rest, at low dose dobutamine infusion, and at peak dose dobutamine infusion. The images were continuously recorded on videotape, and for both types of imaging they were also digitised. Assessment of the images was based both on the digitised images displayed in a cineloop format and on a review of the images recorded on the videotape.

#### ECHOCARDIOGRAPHIC ANALYSIS

Two independent reviewers, blinded to the DISA-SPECT and angiographic data, randomly analysed fundamental imaging and second harmonic imaging studies. In case of disagreement, a majority decision was achieved by a third investigator. For segmental analysis of left ventricular function, a 16 segment model was used, as suggested by the American Society of Echocardiography.<sup>17</sup> Each segment was scored for endocardial visualisation as follows: 0, not visualised; 1, poorly visualised; 2, well visualised. Wall motion was scored at baseline, at low dose dobutamine infusion, and at peak stress. Each segment was scored using a five point scale: 1, normal; 2, mild hypokinesis; 3, severe hypokinesis; 4, akinesis; 5, dyskinesis. Four different patterns were defined in segments with severe baseline dysfunction (wall motion score > 2):

**Biphasic response**—Improvement of wall motion during low dose (either at 5 or 10 µg/kg/min), followed by worsening of wall motion during high dose dobutamine.

**Worsening**—Deterioration of wall motion during low or high dose dobutamine (ischaemic response).

**Sustained improvement**—Continuous improvement at low and high dose dobutamine (without deterioration of wall motion).

**No change**—Absence of improvement or worsening during the entire test.

Dysfunctional segments showing a biphasic, sustained, or ischaemic response were classified as viable, whereas segments with unchanged wall motion were considered non-viable. Myocardial viability was considered absent if akinetic segments became dyskinetic during dobutamine stress echocardiography, as shown previously.<sup>18</sup>

#### DISA-SPECT IMAGING

Patients received an intravenous dose of 600 MBq <sup>99m</sup>Tc-tetrofosmin to evaluate resting regional perfusion. To enhance cardiac uptake of <sup>18</sup>F-fluorodeoxyglucose, the patients received an oral dose of 500 mg of acipimox (Byk, Netherlands) orally, followed by a carbohydrate enriched meal. Acipimox is a potent nicotinic acid derivative that reduces plasma levels of free fatty acids and stimulates cardiac glucose (and <sup>18</sup>F-fluorodeoxyglucose) uptake. This meal stimulates endogenous insulin release, thereby further promoting cardiac glucose (and <sup>18</sup>F-fluorodeoxyglucose) uptake. <sup>18</sup>F-Fluorodeoxyglucose (185 MBq) was injected 60 minutes after the meal. A 45 minute period was allowed after the injection for myocardial <sup>18</sup>F-fluorodeoxyglucose uptake, followed by the dual isotope simultaneous acquisition SPECT. Data acquisition was performed with a triple head gamma camera system (Picker Prism 3000 XP, Cleveland, Ohio, USA) equipped with 511 keV collimators. The energies were centred on the 140 keV photon peak of <sup>99m</sup>Tc-tetrofosmin with a 15% window and on the 511 keV photon peak of <sup>18</sup>F-fluorodeoxyglucose with a 15% window. Imaging was performed over 360° (120 sectors of 3°) with a total imaging time of 32 minutes.

Data were stored in a  $64 \times 64$ , 16 bit matrix. The raw scintigraphic data were reconstructed by filtered back projection using a Butterworth filter (cut off frequency at 0.17 cycle/pixel, of order 3.5). No attenuation correction was employed. Further reconstruction yielded standard long and short axis projections perpendicular to the heart axis. Reconstructed slices were 6 mm in all projections.

#### DISA-SPECT ANALYSIS

The left ventricle was divided into 16 segments (matching the echocardiographic segments). Segmental activities were adjusted to peak myocardial activity. Segments were divided into four categories (assessed visually with the assistance of normalised tracer activity): normal tracer uptake ( $> 75\%$  activity), mildly reduced tracer uptake (50–75% activity), severely reduced tracer uptake ( $< 50\%$  activity), or absent tracer uptake. The perfusion and  $^{18}\text{F}$ -fluorodeoxyglucose short axis slices were adjusted to peak myocardial activity (100%).

The dysfunctional segments (identified at resting echocardiography) were considered viable if these showed normal perfusion and normal  $^{18}\text{F}$ -fluorodeoxyglucose uptake (normal activity), mildly reduced perfusion and mildly reduced  $^{18}\text{F}$ -fluorodeoxyglucose uptake (matched activity), or severely reduced/absent perfusion with increased  $^{18}\text{F}$ -fluorodeoxyglucose uptake (mismatch).<sup>16</sup> Segments with reduced/absent perfusion and concomitant severely reduced  $^{18}\text{F}$ -fluorodeoxyglucose uptake were classified as non-viable.

#### CORONARY ANGIOGRAPHY

Coronary angiography was done within three months of dobutamine stress echocardiography in all patients. Significant coronary artery disease was defined as a diameter stenosis  $\geq 70\%$  in one or more major epicardial artery by quantitative analysis.<sup>19</sup>

The anterior, apical, septal, and anteroseptal segments were assigned to the left anterior descending coronary artery. The posterior and lateral segments were assigned to the left circumflex coronary artery. The inferior and basal septal segments were assigned to the right coronary artery. The apical lateral segment was considered to be an overlap segment between the left anterior descending and the left circumflex coronary artery. The apical inferior segment was considered to be an overlap segment between the left anterior descending and the right coronary artery. Overlap segments were assigned to the regions with concomitant abnormality.<sup>20</sup>

#### STATISTICAL ANALYSIS

Continuous variables are expressed as mean values (SD). Comparison of continuous variables was performed with the Student's *t* test. Comparison of proportions was performed with the  $\chi^2$  test. Sensitivity and specificity were presented with the corresponding 95% confidence interval (CI). A probability value  $p < 0.05$  was considered significant.

The agreements between DISA-SPECT and dobutamine stress echocardiography with fundamental imaging and second harmonic imaging were defined as the percentage of concordant diagnoses and were also assessed by calculating the  $\kappa$  value:  $\kappa$  values between 0.75 and 1 were considered to show good agreement, those between 0.40 and 0.75 to show moderate agreement, and those between 0 and 0.40 to show poor agreement.

## Results

No significant change in the patients' symptoms or the clinical status occurred between the nuclear and echocardiographic studies.

#### HAEMODYNAMIC DATA OF DOBUTAMINE STRESS TEST

Dobutamine-atropine induced a significant increase in heart rate (70 (15) beats/min at rest to 131 (11) beats/min at peak stress,  $p < 0.001$ ), systolic blood pressure (125 (16) *v* 129 (24) mm Hg,  $p < 0.05$ ) and rate-pressure product (9432 (2870) to 16375 (6600),  $p < 0.001$ ). Test end points were target heart rate in 27 patients (90%), maximum dose of dobutamine and atropine in one patient (3%), and angina in two patients (7%). No significant arrhythmias or severe hypotension (decrease systolic blood pressure  $> 40$  mm Hg compared with rest) occurred during the test.

#### DISA-SPECT

In the 30 patients, 480 segments were analysed. Normal perfusion and  $^{18}\text{F}$ -fluorodeoxyglucose uptake were observed in 222 segments (46%). Mildly reduced perfusion and  $^{18}\text{F}$ -fluorodeoxyglucose uptake were observed in 80 segments (17%). A mismatch pattern was found in 37 segments (8%). The remaining 141 segments (29%) had a matched reduction in both perfusion and metabolism and were classified as non-viable.

#### DOBUTAMINE STRESS ECHOCARDIOGRAPHY: BASELINE CHARACTERISTICS

In all, 480 myocardial segments were analysed. At baseline there was a higher prevalence of segments with an invisible border (score = 0) using fundamental imaging than using second harmonic imaging (31 (12.7%) *v* 12 (10.2%),  $p = 0.005$ ). Analysis of wall motion score by fundamental imaging at baseline showed 330 severely dysfunctional segments (73%), of which 181 (55%) were akinetic/dyskinetic. Analysis of wall motion score by second harmonic imaging showed 288 dysfunctional segments (61%;  $p < 0.001$  *v* fundamental imaging), of which 153 (53%) were akinetic/dyskinetic ( $p = 0.02$  *v* fundamental imaging).

The mean number (SD) of severely dysfunctional segments per patient was 10.9 (3.5) with fundamental imaging and 9.8 (3.2) with second harmonic imaging.

Figure 1 represents the different myocardial patterns during dobutamine stress echocardiography with fundamental imaging and second harmonic imaging in severe dysfunctional segments at baseline (wall motion score  $> 2$ ).

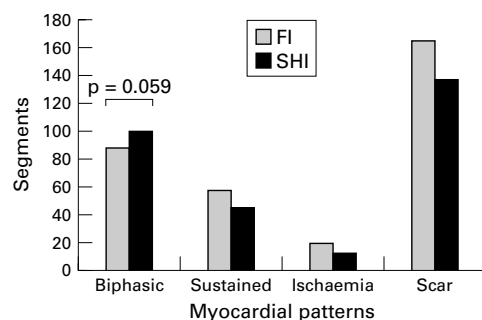


Figure 1 Different myocardial patterns during dobutamine stress echocardiography (DSE) by the use of fundamental imaging (FI) and second harmonic imaging (SHI).

#### AGREEMENT BETWEEN DISA-SPECT AND DOBUTAMINE STRESS ECHOCARDIOGRAPHY WITH FUNDAMENTAL IMAGING AND SECOND HARMONIC IMAGING

##### Fundamental imaging

With fundamental imaging, there were 330 segments with severe baseline dyssynergy. Of these, 144 (44%) were considered viable by both echocardiography and DISA-SPECT, whereas 113 of the dysfunctional segments (34%) were non-viable with both the techniques. The agreement between dobutamine stress echocardiography by fundamental imaging and DISA-SPECT on the presence of viability in severe dysfunctional segments was 78% ( $\kappa = 0.56$ ), as shown in fig 2.

The agreement between fundamental imaging and DISA-SPECT on the presence of

		SPECT	
		Viable	Non-viable
DSE FI	Viable	144	19
	Non-viable	54	113

Dysfunctional segments: 330  
Agreement DSE with FI v SPECT: 78%  
 $\kappa = 0.56$

		SPECT	
		Viable	Non-viable
DSE SHI	Viable	138	13
	Non-viable	20	117

Dysfunctional segments: 288  
Agreement DSE with FI v SPECT: 89%  
 $\kappa = 0.77$

Figure 2 Agreement between DISA-SPECT and dobutamine stress echocardiography (DSE), using fundamental imaging (FI) and second harmonic imaging (SHI), on the presence of myocardial viability in segments with wall motion score  $> 2$  (severe hypokinesis, akinesis, or dyskinesis).

viability in akinetic/dyskinetic segments was 80% ( $\kappa = 0.59$ ) (fig 3).

##### Second harmonic imaging

With second harmonic imaging, there were 288 segments with severe baseline dyssynergy. Of these, 138 (48%) were viable with DISA-SPECT, whereas 117 (41%) were non-viable with both techniques. The agreement between second harmonic imaging and DISA-SPECT for the dysfunctional segments was 89% ( $\kappa = 0.77$ ) ( $p = 0.001$  v fundamental imaging).

The agreement between second harmonic imaging and DISA-SPECT on the presence of viability in akinetic/dyskinetic segments was 86% ( $\kappa = 0.72$ ) (fig 3).

#### ACCURACY OF FUNDAMENTAL IMAGING AND SECOND HARMONIC IMAGING FOR DETECTING MYOCARDIAL VIABILITY

Using DISA-SPECT as the gold standard, we determined the ability of dobutamine stress echocardiography to detect viable tissue using fundamental imaging and second harmonic imaging. Dobutamine stress echocardiography with fundamental imaging revealed signs of viable tissue in 163 dysfunctional segments (49%). This resulted in sensitivity for detecting myocardial viability of 73% (144/198), with a specificity of 86% (113/132) and an accuracy of 78% (257/330).

When second harmonic imaging was used, the number of viable segments was 151 (52%). A significant improvement was obtained in

		SPECT	
		Viable	Non-viable
DSE FI	Viable	60	16
	Non-viable	20	85

Akinetic/dyskinetic segments: 181  
Agreement DSE with FI v SPECT: 80%  
 $\kappa = 0.59$

		SPECT	
		Viable	Non-viable
DSE SHI	Viable	54	15
	Non-viable	6	78

Akinetic/dyskinetic segments: 153  
Agreement DSE with FI v SPECT: 86%  
 $\kappa = 0.72$

Figure 3 Agreement between DISA-SPECT and dobutamine stress echocardiography (DSE), using fundamental imaging (FI) and second harmonic imaging (SHI), on the presence of myocardial viability in segments with wall motion score  $> 3$  (akinesis or dyskinesis).

Table 2 Comparison of the accuracy between fundamental and second harmonic imaging during dobutamine stress echocardiography for the detection of myocardial viability

Variable	Fundamental imaging (n (%))	95% CI	Second harmonic imaging (n (%))	95% CI	p Value
Sensitivity for dysfunctional segments*	73% (144/198)	68 to 78	87% (138/158)	83 to 91	0.001
Specificity for dysfunctional segments*	86% (113/132)	82 to 89	90% (117/130)	86 to 94	0.40
Accuracy for dysfunctional segments*	78% (257/330)	73 to 82	89% (255/288)	85 to 92	0.001
Sensitivity for akinetic/dyskinetic segments**	75% (60/80)	68 to 82	90% (54/60)	85 to 95	0.06
Specificity for akinetic/dyskinetic segments**	84% (85/101)	78 to 90	84% (78/93)	78 to 90	0.90
Accuracy for akinetic/dyskinetic segments**	80% (145/181)	74 to 86	86% (132/153)	81 to 92	0.20

\*Wall motion score > 2; \*\*wall motion score > 3.  
CI, confidence interval.

sensitivity (87% (138/158),  $p = 0.001$  *v* fundamental imaging), and the accuracy was 88% (255/288) ( $p = 0.001$  *v* fundamental imaging), whereas the specificity was similar at 90% (117/130) ( $p = 0.4$  *v* fundamental imaging) (table 2).

Twelve segments were not visualised on dobutamine stress echocardiography with second harmonic imaging. Of these, eight were non-viable on DISA-SPECT, two had normal perfusion and normal metabolism, one had mildly reduced perfusion and mildly reduced metabolism, and one had absent perfusion and increased metabolism.

In patients on  $\beta$  blocker treatment (20 patients), the agreement between dobutamine stress echocardiography with fundamental imaging and DISA-SPECT was 77% ( $\kappa = 0.53$ ). The agreement between dobutamine stress echocardiography with second harmonic imaging and DISA-SPECT was 88% ( $\kappa = 0.77$ ).

Myocardial segments were evaluated according to the different vascular territories. The sensitivity for detecting myocardial viability in the region of the left anterior descending, left circumflex, and right coronary arteries is shown in table 3. A significant improvement occurred in the territory of the left anterior descending coronary artery when second harmonic imaging was used.

Myocardial viability was also assessed on an individual patient basis. Patients were considered to have viable myocardium and to be candidates for revascularisation when four or more dysfunctional segments showed viability by dobutamine stress echocardiography.<sup>21</sup> According to this approach, 24 patients were classified as having viable myocardium with both fundamental imaging and second harmonic imaging, five patients (17%) were classified as

having non-viable myocardium by fundamental imaging and viable myocardium by second harmonic imaging, and one patient (3%) was classified as having viable myocardium on fundamental imaging and non-viable myocardium on second harmonic imaging.

## Discussion

In this study we showed that the use of second harmonic imaging during dobutamine stress echocardiography improved the accuracy of the detection of viable myocardium in patients with severe left ventricular dysfunction compared with fundamental imaging, DISA-SPECT being used as a reference method. Compared with fundamental imaging, the agreement between dobutamine stress echocardiography and DISA-SPECT on viability assessment increased significantly from 78% ( $\kappa = 0.56$ ) to 89% ( $\kappa = 0.77$ ) when second harmonic imaging was used ( $p = 0.001$ ).

Although the use of combined low/high dose dobutamine echocardiography has improved the accuracy of dobutamine stress echocardiography for detecting viability,<sup>21, 22</sup> there remains some discordance between dobutamine echocardiography and nuclear imaging.<sup>23-25</sup>

Previous studies have shown that <sup>201</sup>thallium classified a significantly higher percentage of segments as viable compared with dobutamine stress echocardiography.<sup>7, 24</sup> A similar discrepancy was observed when <sup>18</sup>F-fluorodeoxyglucose imaging with positron emission tomography or SPECT was compared with dobutamine stress echocardiography.<sup>3-5</sup> Thus the nuclear techniques appear to be more sensitive for detecting viable myocardium, probably because the detection of myocardial viability by these techniques requires a lesser grade of cellular integrity than is needed to elicit a contractile response during dobutamine echocardiography. From a pathophysiological point of view, this discrepancy can be explained by the fact that more severely damaged myocardium (with less viable tissue and more fibrosis) may still show perfusion and glucose utilisation but has lost contractile reserve.<sup>9</sup>

Technical factors may also contribute to the discrepancy between dobutamine stress echocardiography and nuclear imaging. Dobutamine stress echocardiography is influenced by imaging quality to a greater extent than nuclear techniques. A suboptimal acoustic window may interfere with an accurate conclusion regarding the presence or absence of viable myocardium. In fact, a technically difficult transthoracic visualisation reduces the

Table 3 Sensitivity and specificity of fundamental and second harmonic imaging and agreement with nuclear studies in the three coronary territories

Regional arteries	Fundamental imaging	95% CI	Second harmonic imaging	95% CI	p Value
<b>LAD coronary artery</b>					
Agreement ( $\kappa$ value)	81% (0.56)		87% (0.69)		0.10
Sensitivity	84% (122/146)	79 to 89	93% (134/144)	90 to 97	0.02
Specificity	75% (47/63)	68 to 81	74% (49/66)	68 to 80	0.90
<b>LCx coronary artery</b>					
Agreement ( $\kappa$ value)	87% (0.54)		91% (0.63)		0.40
Sensitivity	89% (114/128)	84 to 94	96% (121/126)	93 to 99	0.06
Specificity	73% (16/22)	65 to 80	63% (15/24)	55 to 70	0.70
<b>Right coronary artery</b>					
Agreement ( $\kappa$ value)	80% (0.60)		88% (0.74)		0.10
Sensitivity	76% (53/70)	68 to 83	88% (64/73)	82 to 94	0.10
Specificity	86% (43/50)	80 to 92	87% (41/47)	81 to 93	0.90

LAD, left anterior descending; LCx, left circumflex.

accuracy of the prediction of improvement in left ventricular function after revascularisation. In a recent study by Dalla Vecchia and colleagues,<sup>26</sup> 18 patients with chronic coronary artery disease referred for surgical revascularisation were evaluated with dobutamine stress echocardiography and dobutamine stress radionuclide ventriculography. The agreement between these two techniques in predicting improvement of function after revascularisation was suboptimal. This was mainly because dobutamine stress echocardiography was less sensitive, indicating underestimation of viable tissue. However, when patients with optimal visualisation of the endocardial border were analysed separately, the sensitivity of dobutamine stress echocardiography increased significantly. These results clearly show how the lack of adequate endocardial border visualisation can lead to an underestimation of myocardial viability.

The recent introduction of second harmonic imaging has improved image quality by facilitating endocardial border detection. Previous data have shown that second harmonic imaging improves visualisation of endocardial borders both at rest and during dobutamine stress echocardiography.<sup>13</sup> It has also been found that second harmonic imaging is superior for detection of coronary artery disease,<sup>27</sup> but its influence on viability assessment has not yet been evaluated.

In this population of patients with ischaemic left ventricular dysfunction, we evaluated myocardial viability with a nuclear technique (DISA-SPECT) and dobutamine stress echocardiography, comparing both fundamental imaging and second harmonic imaging. In dysfunctional segments, when using fundamental imaging there was an evident discrepancy between dobutamine stress echocardiography and DISA-SPECT imaging (agreement 78%,  $\kappa = 0.56$ ). Second harmonic imaging increased the agreement between the two methods significantly (to 89%,  $\kappa = 0.77$ ). The improvement in sensitivity obtained with second harmonic imaging in dysfunctional segments mainly reflected a reduction in the number of segments that were viable on SPECT and non-viable on dobutamine stress echocardiography. This was particularly related to better visualisation of the biphasic response (fig 1), owing to better endocardial border visualisation.

The dobutamine stress echocardiography studies were also analysed on an individual patient basis. Using the four segment cut off level (allowing optimal identification of patients who will benefit from revascularisation),<sup>21</sup> a difference between fundamental imaging and second harmonic imaging was obtained in six patients. Five of these were classified as non-viable by fundamental imaging but viable by second harmonic imaging. Thus a substantial number of patients would have been denied revascularisation based on fundamental imaging.

Considering the three vascular territories, we found a significant improvement in the sensitivity in segments subtended by the left anterior

descending coronary artery (table 3). These results are in line with previous work focusing on the detection of coronary artery disease using dobutamine stress echocardiography and second harmonic imaging. In fact, the well known phenomenon of endocardial "dropout" is most often encountered in the lateral and anterior walls (apical view).<sup>11-15</sup>

#### STUDY LIMITATIONS

This study used nuclear imaging as a reference to define myocardial viability rather than improvement in function. Thus the impact of the use of second harmonic imaging on the improvement of the ability of dobutamine stress echocardiography for predicting functional recovery after revascularisation needs further evaluation.

The interval of three months between dobutamine stress echocardiography and angiography can be considered relatively long. However, the clinical course of all these patients was stable within this period.

#### CONCLUSIONS

Compared with fundamental imaging, second harmonic imaging improves the agreement between dobutamine stress echocardiography and DISA-SPECT for detecting myocardial viability in patients with ischaemic left ventricular dysfunction.

- Schwaiger M, Melin J. Cardiological applications of nuclear medicine. *Lancet* 1999;354:661-6.
- Rahimtoola SH. Importance of diagnosing hibernating myocardium: how and in whom? *J Am Coll Cardiol* 1997;30:1701-6.
- Matsunari I, Boning G, Ziegler SI, et al. Attenuation-corrected <sup>99m</sup>Tc-Tetrofosmin single-photon emission comparison with positron emission tomography using <sup>18</sup>F-fluorodeoxyglucose. *J Am Coll Cardiol* 1998;32:927-35.
- Cornel JH, Bax JJ, Elhendy A, et al. Agreement and disagreement between "metabolic viability" and "contractile reserve" in akinetic myocardium. *J Nucl Cardiol* 1999;6:383-8.
- Bax JJ, Cornel JH, Visser FC, et al. Prediction of improvement of contractile function in patients with ischemic ventricular dysfunction after revascularization by fluorine-<sup>18</sup>fluorodeoxyglucose single photon-emission computed tomography. *J Am Coll Cardiol* 1997;30:377-83.
- Dilsizian V, Bonow RO. Current diagnostic techniques of assessing myocardial viability in hibernating and stunned myocardium. *Circulation* 1993;87:1-20.
- Panza JA, Dilsizian V, Laurienzo JM, et al. Relation between thallium uptake and contractile response to dobutamine. Implication regarding myocardial viability in patients with chronic coronary artery disease and left ventricular dysfunction. *Circulation* 1995;91:990-8.
- Bax JJ, Poldermans D, Elhendy A, et al. Sensitivity, specificity and predictive accuracies of various non-invasive techniques for detecting hibernating myocardium. *Curr Probl Cardiol* 2001;26:141-86.
- Pagano D, Townsend JN, Parums DV, et al. Hibernating myocardium: morphological correlates of inotropic stimulation and glucose uptake. *Heart* 2000;83:456-61.
- Nagueh SF, Mikati I, Weilbaecher D, et al. Relation of the contractile reserve of hibernating myocardium to myocardial structure in humans. *Circulation* 1999;100:490-6.
- Kasprzak JD, Paalnick B, Ten Cate FJ, et al. Comparison of native and contrast-enhanced harmonic echocardiography for visualization of left ventricular endocardial border. *Am J Cardiol* 1999;83:211-17.
- Spencer KT, Bednarz J, Rafter PG, et al. Use of harmonic imaging without echocardiographic contrast to improve two-dimensional image quality. *Am J Cardiol* 1998;82:794-9.
- Sozzi FB, Poldermans D, Bax JJ, et al. Does second harmonic imaging improve left ventricle endocardial border identification at higher heart rate during dobutamine stress echocardiography? *J Am Soc Echocardiogr* 2000;13:1019-24.
- Caidahl K, Kazzam E, Lidberg J, et al. New concept in echocardiography: harmonic imaging of tissue without use of contrast agent. *Lancet* 1998;352:1264-70.
- Senior R, Soman P, Khattar RS, et al. Improved endocardial visualization with second harmonic imaging compared with fundamental two-dimensional echocardiographic imaging. *Am Heart J* 1999;138:163-8.

- 16 Rambaldi R, Poldermans D, Bax JJ, et al. Dobutamine stress echocardiography and technetium-99m-tetrofosmin/fluorine 18-fluorodeoxyglucose single-photon emission computed tomography and influence of resting ejection fraction to assess myocardial viability in patients with severe left ventricular dysfunction and healed myocardial infarction. *Am J Cardiol* 1999;**84**:130-4.
- 17 Shiller NB, Shah PM, Crawford M, et al. Recommendations of quantitation of the left ventricle by two-dimensional echocardiography. American Society of Echocardiography committee on standards, subcommittee on quantitation of two-dimensional echocardiograms. *J Am Soc Echocardiogr* 1989;**2**:358-67.
- 18 Elhendy A, Cornel JH, Roelandt JR, et al. Akinesis becoming dyskinesia during dobutamine stress echocardiography. A predictor of poor functional recovery after surgical revascularization. *Chest* 1996;**110**:155-8.
- 19 Baptista J, Arnese M, Roelandt JRTC, et al. Quantitative coronary angiography in the estimation of the functional significance of coronary stenosis: correlations with dobutamine-atropine stress test. *J Am Coll Cardiol* 1994;**23**:1434-9.
- 20 Elhendy A, van Domburg RT, Bax JJ, et al. Optimal criteria for the diagnosis of coronary artery disease by dobutamine stress echocardiography. *Am J Cardiol* 1998;**82**:1339-44.
- 21 Bax JJ, Poldermans D, Elhendy A, et al. Improvement of left ventricular ejection fraction, heart failure symptoms and prognosis after revascularization in patients with chronic coronary artery disease and viable myocardium detected by dobutamine stress echocardiography. *J Am Coll Cardiol* 1999;**34**:163-9.
- 22 Cornel JH, Bax JJ, Elhendy A, et al. Biphasic response to dobutamine predicts improvement of global left ventricular function after surgical revascularization in patients with stable coronary artery disease: implications of time course of recovery on diagnostic accuracy. *J Am Coll Cardiol* 1998;**31**:1002-10.
- 23 Arnese M, Cornel JH, Salustri A, et al. Prediction of improvement of regional left ventricular function after surgical revascularization. A comparison of low-dose dobutamine echocardiography with <sup>201</sup>Tl single-photon emission computed tomography. *Circulation* 1995;**91**:2748-52.
- 24 Qureshi U, Nagueh SF, Afridi I, et al. Dobutamine echocardiography and quantitative rest-redistribution <sup>201</sup>Tl tomography in myocardial hibernation. *Circulation* 1997;**95**:626-35.
- 25 Elhendy A, Trocino G, Salustri A, et al. Low-dose dobutamine echocardiography and rest-redistribution thallium-201 tomography in the assessment of spontaneous recovery of left ventricular function after recent myocardial infarction. *Am Heart J* 1996;**131**:1088-96.
- 26 Dalla Vecchia L, Storti T, Cogliati C, et al. Comparison of low-dose dobutamine ventriculography with low-dose dobutamine echocardiography for predicting regional improvement in left ventricular function after coronary artery bypass. *Am J Cardiol* 2000;**86**:371-4.
- 27 Franke A, Hoffmann R, Kühl HP, et al. Non-contrast second harmonic imaging improves interobserver agreement and accuracy of dobutamine stress echocardiography in patients with impaired image quality. *Heart* 2000;**83**:133-40.

---

## Electronic pages

---

### eHEART: [www.heartjnl.com](http://www.heartjnl.com)

The following electronic only articles are published in conjunction with this issue of *Heart* (see also p 648).

#### **HLA-B27 positive juvenile arthritis with cardiac involvement preceding sacroiliac joint changes**

*S J Lee, H Y Im, W C Schueller*

While cardiovascular disease develops in up to 50% of adult patients with ankylosing spondylitis, it is very uncommon in its juvenile counterpart. Regarding the early stage of the disease, before onset of sacroiliac joint changes, only two cases with aortic incompetence have been published while reports of mitral valve involvement are not available. A 13 year old boy is described with an HLA-B27 positive asymmetric oligoarthritis and enthesitis, without back pain or radiographic evidence of sacroiliitis. Echocardiography showed an echogenic structure measuring 8 × 15 × 20 mm at the fibrous continuity between the aortic and mitral valves extending through a false tendon into an echogenic thickened posterior papillary muscle, causing a grade II aortic and grade I/II mitral regurgitation. Short term corticosteroid and long term non-steroidal anti-inflammatory drug and disease modifying antirheumatic

drug treatments efficiently controlled the symptoms. The cardiac findings remained unchanged during a follow up of 20 months. Careful cardiac evaluation appears to be mandatory even in these young patients.

(*Heart* 2001;**86**:e19) [www.heartjnl.com/cgi/content/full/86/6/e19](http://www.heartjnl.com/cgi/content/full/86/6/e19)

#### **Radiation induced valvulitis with late leaflet rupture**

*N M Katz, A W Hall, M D Cerqueira*

Various cardiac sequelae of mediastinal irradiation have been reported, from pericarditis to conduction defects. Despite the potentially fatal nature of some of these abnormalities, many may present with few or no symptoms. In this case report, the patient, who had received 4000 rads to the mediastinum 24 years previously, presented with worsening shortness of breath and two episodes of lightheadedness. Subsequently, he was found to have aortic valve rupture associated with fibrosis. A review of the literature indicates that valve rupture is a novel consequence of mediastinal radiation.

(*Heart* 2001;**86**:e20) [www.heartjnl.com/cgi/content/full/86/6/e20](http://www.heartjnl.com/cgi/content/full/86/6/e20)