

CLINICAL ASPECTS OF FLEXOR TENDON HEALING

J. C. van der Meulen,

Afd. Plastische en Reconstructieve Chirurgie, Academisch Ziekenhuis, Rotterdam-Dijkzigt, Rotterdam 3002, The Netherlands.

Consideration of the clinical aspects of tendon healing calls first for an evaluation of the role of the different structures involved.

THE ROLE OF THE TENDON ITSELF.

We know that healing of a tendon wound takes place by an invasion of fibroblasts from the surrounding tissues; the tendon itself has no intrinsic healing capacity. It was Potenza (1962) who proved that a traumatic suture of the tendons within their sheath is followed by disintegration of the synovia and the formation of granulation tissue. The tissue invades the tendon at those places where its surface is wounded and forms new collagen which restores its continuity. As soon as this scar tissue matures, the adhesions become looser and the integrity of the sheath is repaired. Potenza (1963) also observed that when contact between the tendon and its sheath is made impossible by the introduction of polyethylene tubes or millipore, healing of the tendon wound is postponed until granulation tissue has invaded the tube from its end and reached the wound along the surface of the tendon. However, trauma is not always restricted to a loss of continuity; circulatory loss may also occur and the consequences of deprivation of a tendon's blood supply force us to study the role of its circulation during healing.

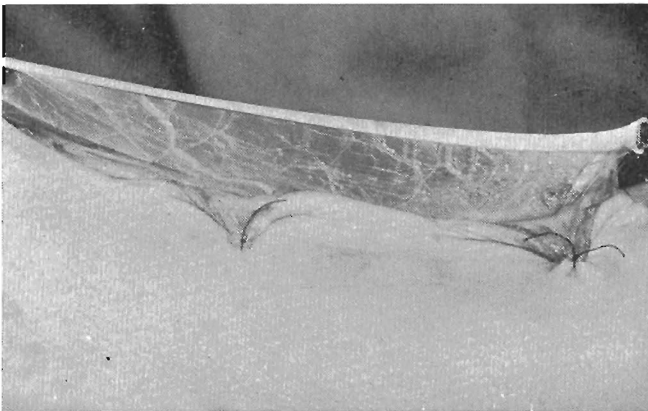


Fig. 1. Palmaris tendon with mesotenon. (By permission of the Editor and publishers of the British Journal of Plastic Surgery).

THE ROLE OF THE BLOOD CIRCULATORY SYSTEM.

The main vessels supplying a tendon reach it through the mesotenon (Fig. 1) which within the digital flexor sheaths is condensed into vincula. The muscular

origin of the tendon and its periosteal insertion add little to the circulation in the tendon; a tendon freed from its bed must therefore be considered a free graft. Clinically, free tendon grafts can survive transplantation. How ? Tendon is a relatively inert structure metabolically (Birdsell et al., 1966) and the cells may remain alive until revascularisation occurs. However even should the cells die they are rapidly replaced as new blood vessels enter the graft, a phenomenon which also takes place in cell free tendon homografts (Seiffert, 1967).

It has long been known that revascularisation of a tendon takes place between the tendon graft and the surrounding tissues (Braithwaite and Brockis, 1951-52; Skoog and Persson, 1954; Potenza, 1962). Peacock (1965) regards this process as indispensable for ultimate survival. Revascularisation of a tendon within a sheath evidently can be effected in different ways. Firstly, the source of revascularisation may be outside the sheath; in the case of a ruptured tendon all of us have observed the phenomenon of granulation tissue which creeps over the surface of a coiled-up tendon while no adhesions between tendon and sheath are to be found. Remnants of vincula within the sheath are a second source and the tendon sheath itself may under some circumstances provide a third. The tendon not only receives blood from different sources, blood may enter the tendon in different ways.

Smith and Conway (1965) showed that revascularisation of a tendon within an intact undamaged sheath occurs by anastomosis of the vessels in the mesotenon with capillary outgrowths from tissues outside the sheath and from the vincula inside. In the absence of a sheath, the tendon is revascularised by anastomotic links with vessels from the surrounding tissues.

THE ROLE OF THE PERITENDINOUS TISSUES.

The nature of the peritendinous tissues depends on the absence or presence of a tendon sheath (Fig. 2); in its absence the tendon is surrounded by paratenon and in its presence by synovia. No vascular connections between the paratenon and the tendon or the synovia and tendon exist.

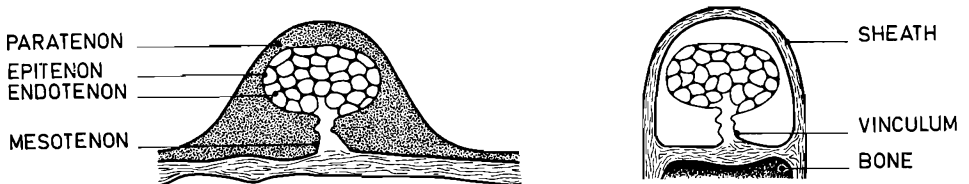


Fig. 2. Different nature of structures surrounding the tendon.

Lindsay and Birch (1964) using injections of ^3H -thymidine found that fibroblasts appear to migrate across a bridge formed by the merging of tendons and sheath in areas of inflammation. Their observations indicate that the formation of adhesions between the tendon and the sheath is either caused by an injury which

allows granulation tissue to bridge the gap between tendon and sheath or stimulated by metabolic products from the tendon itself. Nature confronts us with a problem which it is impossible to solve by technical means alone: we want to restore the circulation of a tendon and at the same time we want to prevent adhesions from forming. As always we cannot have our cake and eat it.

FACTORS AFFECTING FULL RESTORATION OF FUNCTION

Although most important, the process of healing itself is not the only factor affecting restoration of function. The prognosis depends on many other factors which for the sake of simplicity are divided into factors beyond and factors under control.

FACTORS BEYOND CONTROL

Age is probably a factor because circulation within the tendon diminishes with age. As a consequence more adhesions will be needed to transport the necessary amount of blood.

Race may affect the restoration of function because of the different types of scar formation in coloured and non-coloured people.

Sex is mentioned because our personal results with the use of certain procedures in adult females seem to be worse than in adult males.

Constitution cannot be dismissed because good results in short massive hands are more difficult to achieve than in long slender hands.

Mentality is listed since cooperation of the patient in the process of rehabilitation is important.

Excursion of the tendon deserves attention because a tendon with a range of motion of 4 cm will need longer adhesions than one with a shorter range of motion.

The nature of the injury should finally be considered. It makes a great deal of difference where the tendon is severed, inside No Man's Land or outside. Inside No Man's Land the range of movement is completely dependent on the quality of the adhesions since the surrounding tissues are immobile. Outside the tendon sheath the range of movement also depends on the mobility of the surrounding tissues (Fig. 3). It also makes a difference whether one, both or none

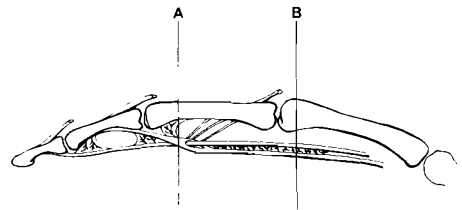
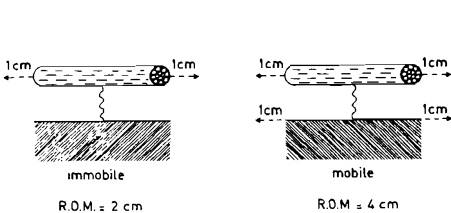


Fig. 4. Adhesion formation may be influenced by different levels of the tendon lesion, i.e. near to vincula or halfway between 2 sources of blood supply.

Fig. 3. The range of motion (R.O.M.) of a tendon also depends on the mobility of the surrounding tissues.

of the digital arteries are cut since revascularisation will need more or less adhesion formation. It probably also makes a difference at what level the tendon is cut, near to a vinculum or halfway between 2 sources of blood supply (Fig. 4).

FACTORS UNDER CONTROL

Handling of tissues. Any tendon wound creates adhesion formation; so does a tendon suture. This is why in my opinion preference should be given to a few interrupted sutures to approximate the tendon stumps. Due to the process of healing which functions like an anchor such an anastomosis tolerates distracting forces provided the following precautions are taken. Within the tendon sheath it is to be supported by a blocking needle and outside the sheath it is to be reinforced by suturing of the paratenon which functions as a splint and allows independent mobility of the tendon. Since the tendon anastomosis cannot be made without sutures it is essential to use material which is as inert as possible: stainless steel or monofilament nylon. Let us never forget that the excursion of a tendon is just as long as the shortest adhesion permits it to be.

Choice of donor tendon. Since a tendon which is deprived of its circulation becomes a graft it stands to reason that some relationship will exist between the diameter of the graft and its chances of survival. The palmaris longus tendon is my favourite graft. When not available the extensor tendons of the 3rd or 4th toe are the second choice.

Method of repair. In addition to tendon suture and free tendon grafting, restoration of continuity in No Man's Land may be achieved by a variety of transpositional repair are ideal, and this means a minimum of trauma to the neurovas-

tendon transposition

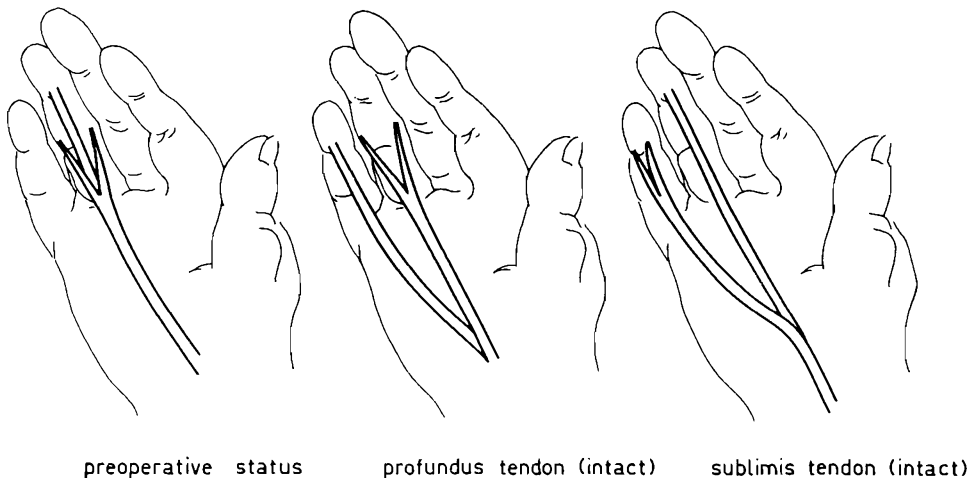
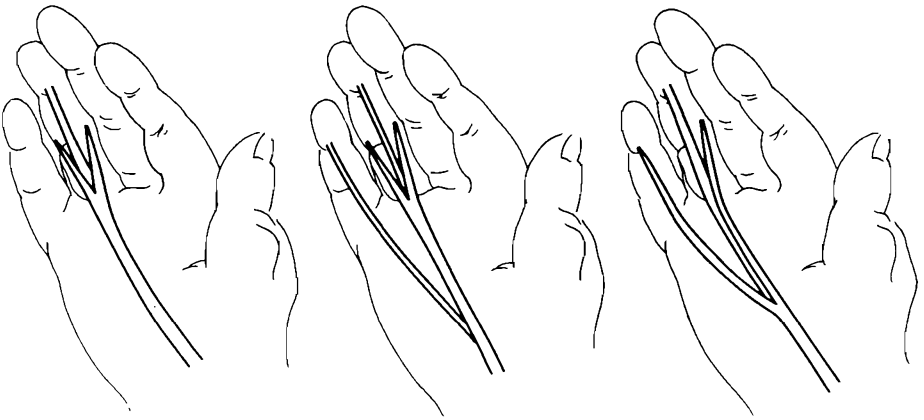


Fig. 5. Tendon transposition I. The intact profundus or sublimis tendon of an adjacent finger is transposed.

tendon transposition



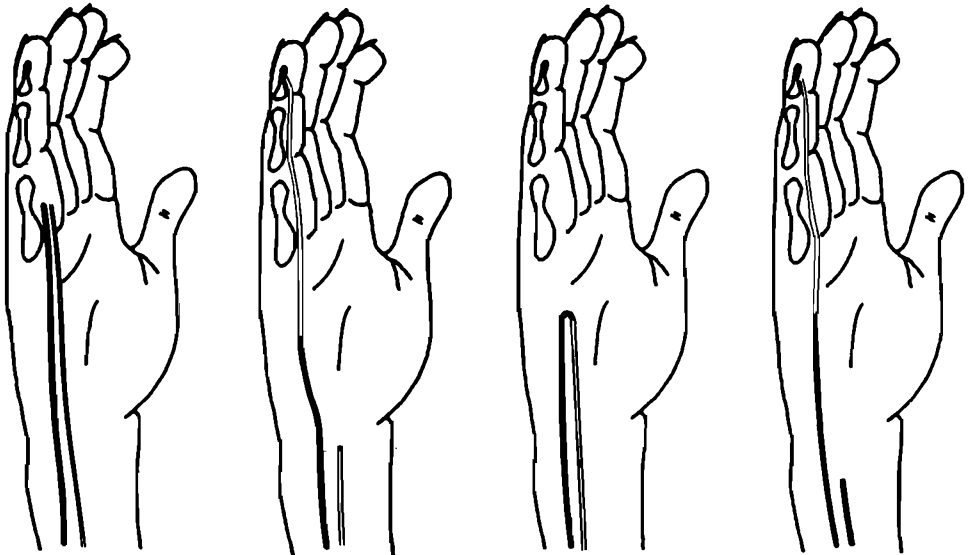
preoperative status

profundus tendon (split)

sublimis tendon (split)

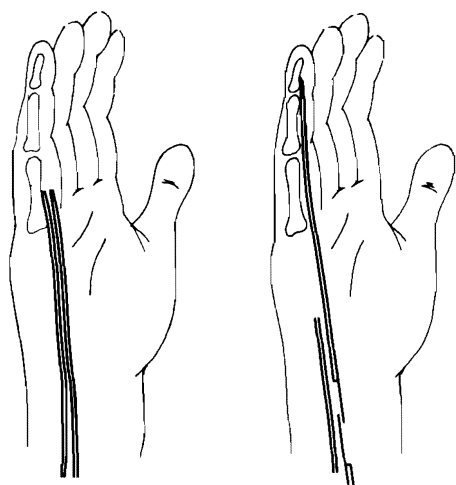
Fig. 6. Tendon transposition II. The split profundus or sublimis tendon of an adjacent finger is transposed.

cular bundles and the tendon sheath, it is possible to achieve excellent results with any of these methods. However, the prognosis becomes worse if the conditions are less than ideal. Revascularisation is essential for success with any technique and to make this as rapid as possible the mesotenon should always be preserved (Smith and Conway, 1965) while parts of the tendon sheath may sition and interposition techniques shown in figures 5 - 9. If the conditions for



TENDON INTERPOSITION (DIRECT).

TENDON INTERPOSITION (INDIRECT).



tendon plasty

Fig. 7. Tendon interposition (Direct). The sublimis tendon is cut in the wrist region and used to cover the profundus defect after advancement.

Fig. 8. Tendon interposition (Indirect) The stumps of the sublimis and profundus tendons are anastomosed as a first stage. At a second stage the sublimis tendon is severed proximally and transposed to close the defect.

Fig. 9. Tendonplasty. The sublimis tendon is lengthened in the wrist and advanced to close the defect.

be resected to bring the tendon into contact with more richly vascular tissue. The most significant innovation in recent years in flexor tendon grafting in badly scarred hands has been the preformation of an intact sheath. Although Mayer and Ransohoff tried to do so with celloidin tubes in 1936, the material was insufficiently inert and it was not until the introduction of the silicone rubbers that significant success was obtained (Bassett and Carroll, 1963; Hunter, 1965; Gaisford et al., 1966; Nicolle, 1969). The Silastic "spacers" are more commonly used passively since active spacers sutured to both tendon ends are liable to rupture (Hunter and Salisbury, 1970). The distal end of the rod is fixed at the insertion of the profundus tendon with 1 or 2 wire sutures. The proximal end overlaps the proximal stump of the tendon by several centimetres. Two or 3 months later when the tissues have softened and the maximum passive range has been obtained, the rod is replaced by a tendon graft (van der Meulen, 1971). Geldmacher (1969) demonstrated that the amount of traction required to pull a tendon graft out of a sheath induced by a Silastic spacer is 9 to 10 times less than the amount required when such a spacer is not used. Geldmacher's conclusion that the indications for tendon repair in the hand with the use of Silastic spacers may well be appreciably extended, is entirely in agreement with my experience. Only a few adhesions sufficient for survival of the graft occur and these mature more rapidly (Nicolle).

Rehabilitation. Rehabilitation starts with the immobilisation of the finger after tendon repair. Since flexor forces are stronger than the extending forces it seems wise to take advantage of this. The position in which we immobilise the finger is: metacarpophalangeal joints in flexion, proximal interphalangeal and distal interphalangeal joint in extension. This position is maintained with a plaster of Paris splint (Fig. 10).

After removal of the splint, extension of the metacarpophalangeal joint will

help the proximal interphalangeal and distal interphalangeal joints to flex. Whenever necessary, additional physiotherapy is given to promote relaxation

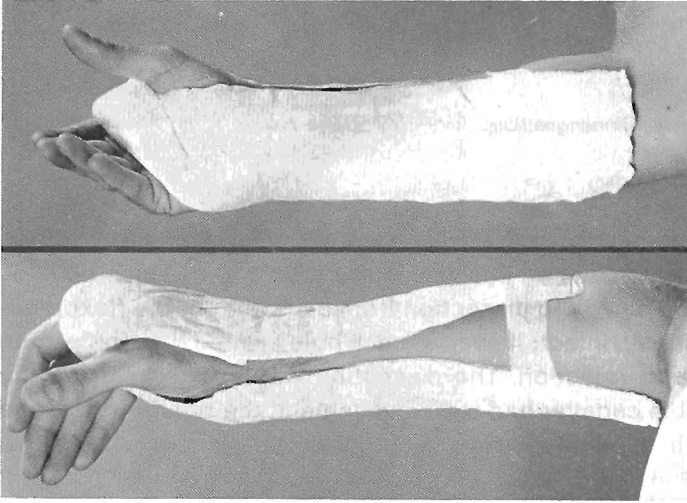


Fig. 10. Plaster of Paris splint most suitable to obtain "position of rest".

and remodelling of the adhesions between the tendon and the surrounding tissues.

REFERENCES

- Bassett, C. A. L. and Carroll, R. E. (1963) Formation of tendon sheath by silicone rod implant. *Journal of Bone and Joint Surgery*, 45A, 884.
- Birdsell, D. C., Tustanoff, E. R. and Lindsay, W. K. (1966) Collagen production in regenerating tendon. *Plastic and Reconstructive Surgery*, 37, 504.
- Braithwaite, F. and Brockis, J. G. (1951-52) The vascularisation of a tendon graft. *British Journal of Plastic Surgery*, 4, 130.
- Gaisford, J. C., Hanna, D. C. and Richardson, G. S. (1966) Tendon grafting, a suggested technique. *Plastic and Reconstructive Surgery* 38, 302.
- Geldmacher, J. (1969) Die zweizeitige freie Beugesehnen-transplantation. *Handchirurgie*, 3, 109.
- Hunter, J. M. (1965) Artificial tendons. *American Journal of Surgery*, 109, 325.
- Hunter, J. M. and Salisbury, R. E. (1970) Use of gliding artificial implants to produce tendon sheaths. *Plastic and Reconstructive Surgery*, 45, 564.
- Lindsay, W. K. and Birch, J. R. (1964) The fibroblast in flexor tendon healing. *Plastic and Reconstructive Surgery*, 34, 223.
- Mayer, L. and Ransohoff, N. (1936) Reconstruction of the digital tendon sheath. *Journal of Bone and Joint Surgery*, 18, 607.
- Nicolle, F. V. (1969) A Silastic tendon prosthesis as an adjunct to flexor tendon grafting: An experimental and clinical evaluation. *British Journal of Plastic Surgery*, 22, 224.
- Peacock, E. E. (1965) Physiology of tendon repair. *American Journal of Surgery*, 109, 283.
- Potenza, A. D. (1963) Critical evaluation of flexor tendon healing and adhesion formation within artificial digital sheaths. *Journal of Bone and Joint Surgery*, 45A, 1217.
- Potenza, A. D. (1962) Tendon healing within the flexor digital sheath in the dog. *Journal of Bone and Joint Surgery* 44A, 49.
- Seiffert, K. E. (1967) *Biologische Grundlagen der homologen Transplantation konservierter Bindegewebe*. Hefte Unfallheilkunde, 93, Berlin, Heidelberg, New York: Springer.
- Skoog, T. and Persson, B. H. (1954) An experimental study of the early healing of tendons. *Plastic and Reconstructive Surgery*, 13, 384.
- Smith, J. W. and Conway, H. (1966) La dynamique du glissement des tendons normaux et greffes. *Revue de Chirurgie Orthopedique et Reparatrice de l'Appareil Moteur*, 52, 185.
- Smith, J. W. and Conway, H. (1965) Blood supply of tendons. *American Journal of Surgery*, 109, 272.
- Van der Meulen, J. C. (1971) Silastic spacers in tendon grafting. *British Journal of Plastic Surgery*, 24, 166.