

# The sacroiliac part of the iliolumbar ligament

A. L. POOL-GOUDZWAARD<sup>1,3</sup>, G. J. KLEINRENSINK<sup>1</sup>, C. J. SNIJDERS<sup>2</sup>, C. ENTIUS<sup>1</sup>  
AND R. STOECKART<sup>1</sup>

*Departments of <sup>1</sup>Anatomy and <sup>2</sup>Biomedical Physics and Technology, Erasmus University Rotterdam, and <sup>3</sup>Medical Center Impact Zoetermeer, The Netherlands*

*(Accepted 26 April 2000)*

---

## ABSTRACT

The iliolumbar ligament has been described as the most important ligament for restraining movement at the lumbosacral junction. In addition, it may play an important role in restraining movement in the sacroiliac joints. To help understand its presumed restraining effect, the anatomy of the ligament and its orientation with respect to the sacroiliac joints were studied in 17 cadavers. Specific dissection showed the existence of several distinct parts of the iliolumbar ligament, among which is a sacroiliac part. This sacroiliac part originates on the sacrum and blends with the interosseous sacroiliac ligaments. Together with the ventral part of the iliolumbar ligament it inserts on the medial part of the iliac crest, separate from the interosseous sacroiliac ligaments. Its existence is verified by magnetic resonance imaging and by cryosectioning of the pelvis in the coronal and transverse plane. Fibre direction, length, width, thickness and orientation of the sacroiliac part of the iliolumbar ligament are described. It is mainly oriented in the coronal plane, perpendicular to the sacroiliac joint. The existence of this sacroiliac part of the iliolumbar ligament supports the assumption that the iliolumbar ligament has a direct restraining effect on movement in the sacroiliac joints.

*Key words:* Biomechanics; sacroiliac joint; low back pain.

---

## INTRODUCTION

In the literature the iliolumbar ligament (IL) is described as a biomechanically important ligament for the lumbopelvic region; it extends from the transverse processes of the 4th and 5th lumbar vertebrae to the iliac crest (Leong et al. 1987; Chow et al. 1989; Yamamoto et al. 1989, 1990). Furthermore Sims & Moorman (1996) mention the IL as an important primary source of low back pain. This is plausible since immunohistochemically the presence of a multitude of mechanoreceptors and nociceptors has been shown in the lumbar posterior ligaments (Bogduk, 1983; Korkala et al. 1985; Yahia et al. 1988; Rhalmi et al. 1993). It is postulated that the innervation of the IL is similar to that of other posterior lumbar ligaments (Sims & Moorman, 1996). Several biomechanical studies emphasise the importance of the IL, on the one hand, in restraining flexion, extension and lateral bending of L5 on SI (Leong et al. 1987; Yamamoto et al. 1989, 1990) and on

the other in maintaining torsional stability of the lumbosacral junction (Chow et al. 1989). This concept supports the study by Pun et al. (1987) showing the presence of the IL in rhesus monkeys and its absence in quadrupeds with a more horizontal spine. In addition to this restraining function, Luk et al. (1986) suggested that in man the IL could play a role in locking the sacrum between the iliac bones. In other words the IL might also restrain movement in the SI joint. To analyse whether this holds true and, if so, which movements of the sacrum and iliac bones can be restrained, first the topographic anatomy of the ligament and its orientation with respect to the SI joint have to be clarified since the literature is confusing.

The IL has been described as consisting of 1 (Maigne & Maigne, 1991), 2 (Moore, 1980; Luk et al. 1986; Uthoff, 1993; Hanson & Sonesson, 1994; Basadonna et al. 1996; Rucco et al. 1996), 3 (Williams & Warwick, 1980), 4 (O'Rahilly, 1986), or even 5 separate bands (Bogduk & Twomey, 1987). Most

authors have described the origin of the IL at the transverse processes of L5 (O’Rahilly, 1986; Moore, 1980; Williams & Warwick, 1980; Luk et al. 1986; Leong et al. 1987; Bogduk & Twomey, 1987; Chow et al. 1989; Yamamoto et al. 1989, 1990; Maigne & Maigne, 1991; Uhthoff, 1993; Hanson & Sonesson, 1994; Basadonna et al. 1996; Rucco et al. 1996; Willard, 1997) and occasionally L4 (O’Rahilly, 1986; Moore 1980; Williams & Warwick, 1980; Bogduk & Twomey, 1987; Leong et al. 1987; Chow et al. 1989; Yamamoto et al. 1989, 1990; Uhthoff, 1993; Willard, 1997). In all studies the insertion of the IL is described as being on the iliac crest and the ventral, upper part of the iliac tuberosity. In some textbooks attachments of the IL to the anterior layer of the thoracolumbar fascia are described (Moore, 1980; Williams & Warwick, 1980; O’Rahilly, 1986). According to O’Rahilly (1986) and confirmed by Willard (1995), some fibres of the IL blend with the intertransverse ligaments between L5-S1 and L4-L5 and blend with the interosseous SI ligaments. Frazer (1948) had earlier described fibres of the IL passing to the 1st sacral vertebra although detailed descriptions of length, width and thickness are lacking. The aim of the present study is to confirm whether a part of the IL can be defined as a sacroiliac ligament. If so, its fibre direction, length, thickness, width and orientation are of interest.

MATERIALS AND METHODS

In 10 female and 7 male cadavers (aged 72–86 y) skin, fat and muscles were removed by blunt dissection keeping all ligamentous structures intact. All attachments of the IL were analysed. After detailed description, the transverse processes of L5 were carefully removed keeping fibres belonging to the sacroiliac part of the IL (SIPIL) intact. The attachments of these fibres were exposed and documented. By a calibrated scale, the length, thickness and width

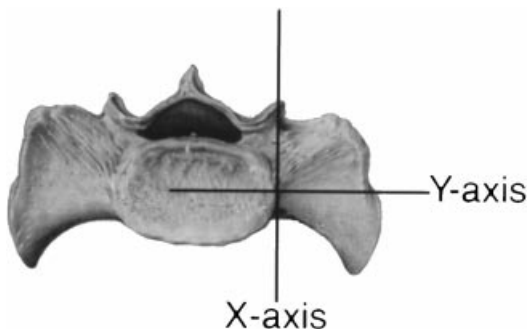

Fig. 1. The coordinate system at the base of the sacrum in the transverse plane.

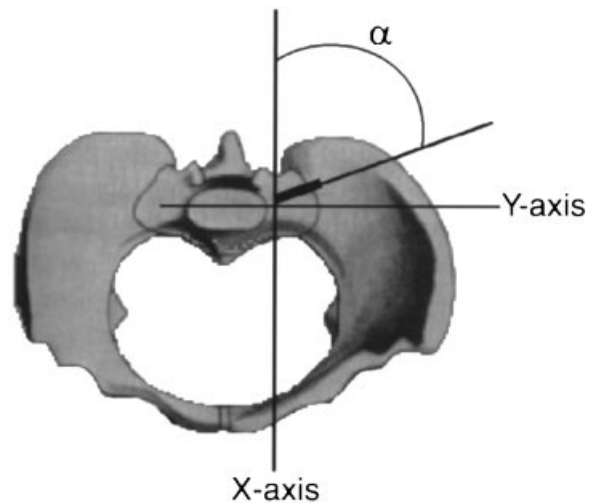


Fig. 2.  $\alpha$ , angle of the sacroiliac part of the iliolumbar ligament (SIPIL) in the transverse plane.

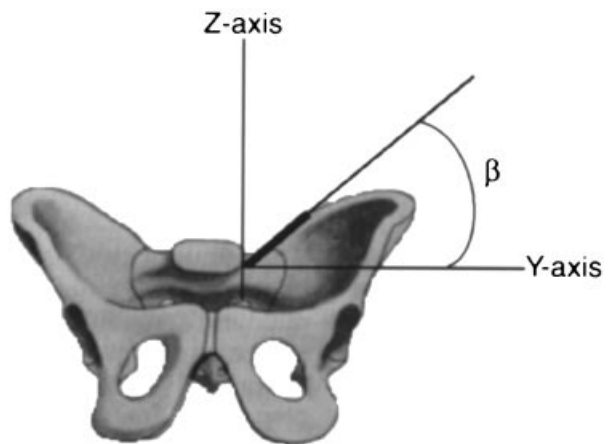


Fig. 3.  $\beta$ , angle of the sacroiliac part of the iliolumbar ligament (SIPIL) in the coronal plane.

of these fibres were measured. In the transverse plane, an imaginary coordinate system was placed at the base of the sacrum (see Fig. 1). Two angles were measured: the angle  $\alpha$  between the fibres of the SIPIL and the X-axis in the transverse plane (Fig. 2) and the angle  $\beta$  between the fibres of the SIPIL and the Y-axis in the coronal plane (Fig. 3). Magnetic resonance imaging (MRI) (Philips gyro scan T10-NT) was used to verify the existence of a SIPIL in the coronal and transverse plane. Cryosectioning was performed (2 mm) in the same plane as the MRI. An independent *t* test was used to test the differences between men and women in height, width, thickness and orientation of the SIPIL.

RESULTS

In its entirety the IL is a fan shaped structure, consisting of various parts, highly variable in number

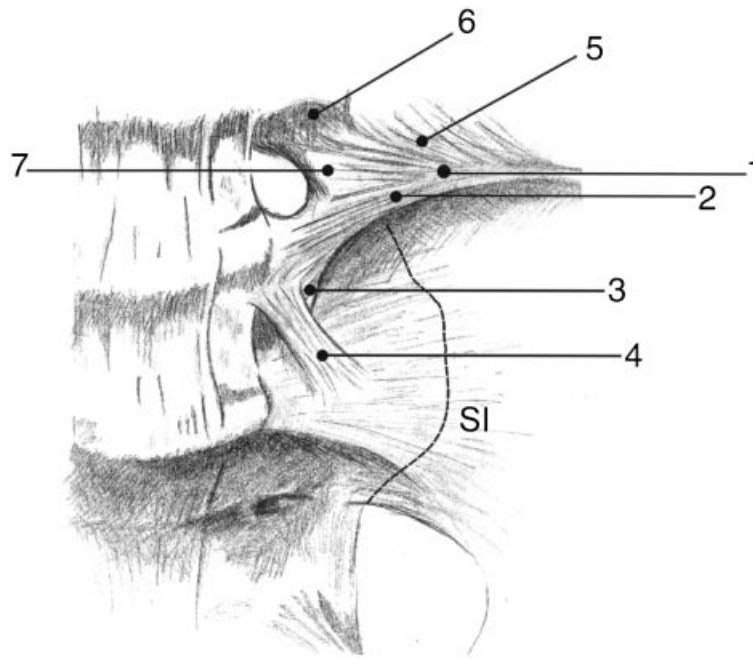


Fig. 4. Caudoventral view of the ligamentous structures in the lumbosacral region with the iliolumbar ligament consisting of the following fibres and bands: (1) dorsal band; (2) ventral band; (3) sacroiliac part of the iliolumbar ligament (SIPIL); (4) lumbosacral band; (5) fusion of the dorsal band with the deepest layer of the thoracolumbar fascia or the fascia of quadratus lumborum; (6) attachment of the iliolumbar ligament to the transverse process of L4; (7) fusion of the iliolumbar ligament with the intertransverse ligaments between L4-L5. SI, approximate site of the sacroiliac joint (interrupted line).

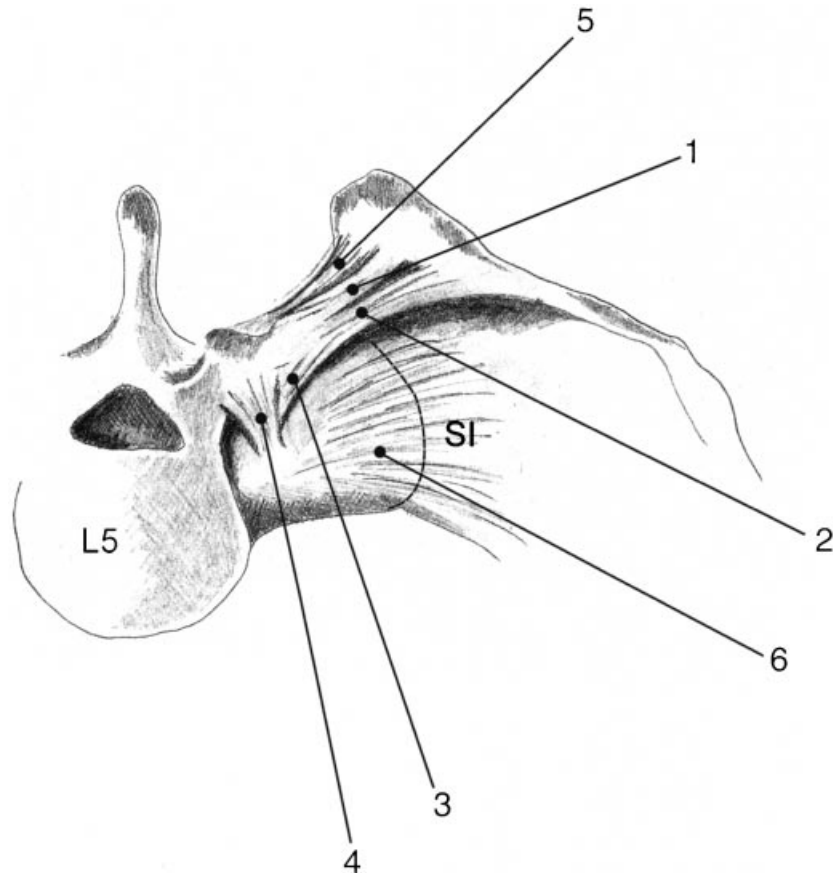


Fig. 5. Cranial view of the ligamentous structures in the lumbosacral region with the iliolumbar ligament consisting of the following fibres and bands: (1) dorsal band; (2) ventral band; (3) sacroiliac part of the iliolumbar ligament (SIPIL); (4) lumbosacral band; (5) dorsal sacroiliac ligaments; (6) ventral sacroiliac ligaments. SI, approximate site of the sacroiliac joint (interrupted line); L5, 5th lumbar vertebra.

Table. Dimensions and orientations (with standard deviations) of the SIPIL in women and men

	Women (n = 10)	Men (n = 7)
Dimensions (mm)		
Length	31.0 (5.6)	30.5 (5.6)
Width	12.7 (4.6)	14.5 (4.1)
Thickness	1.6 (0.5)	1.5 (0.4)
Orientation (degrees)		
Angle $\alpha$	77.9 (4.9)	83.7 (3.6)
Angle $\beta$	50.2 (6.8)	52.1 (7.2)

and form. Although the several parts blend together, some ‘bands’ and parts can be distinguished. The following were seen in all specimens (n = 34).

1. A dorsal band originating from the tip of the transverse process of L5, inserting on the cranial part of the iliac tuberosity below the medial part of the origin of the quadratus lumborum muscle and on the medial part of the iliac crest (Figs 4, 5).
2. A direct attachment of the dorsal band to the deep ventral layer of the thoracolumbar fascia or to the fascia of quadratus lumborum (Fig. 4).
3. A ventral band originating from the ventrocaudal

part of the transverse process of L5 (Fig. 4) and in 3 specimens also from the caudal aspect of the endplate of the vertebral body of L5. The insertion is at the ventrocranial part of the iliac tuberosity on the sacropelvic surface.

4. A lumbosacral band originating from the ventrolateral aspect of the vertebral body of L5 and ventromedial part of the transverse processes and inserting at the most ventrolateral part of the base of the sacrum, near the SI joint. These fibres blend with the ventral SI ligaments (Fig. 4).

5. A sacroiliac part (SIPIL), originating from the cranial surface of the ala of the sacrum directly caudal to the transverse process of L5 and inserting at the ventromedial part of the iliac tuberosity, together with the ventral band (Fig. 4). See Table for details on length, thickness, width and orientation in women and men, Figure 6 for MRI and Figures 7 and 8 for cryosectioned slices.

6. Fibres of the SIPIL merging with the thin intertransverse ligament of L5-S1 (Fig. 4).

7. Fibres of the SIPIL merging with the interosseous SI ligaments. The craniolateral part of the SIPIL is separated from the interosseous ligaments by fatty tissue (Fig. 6).

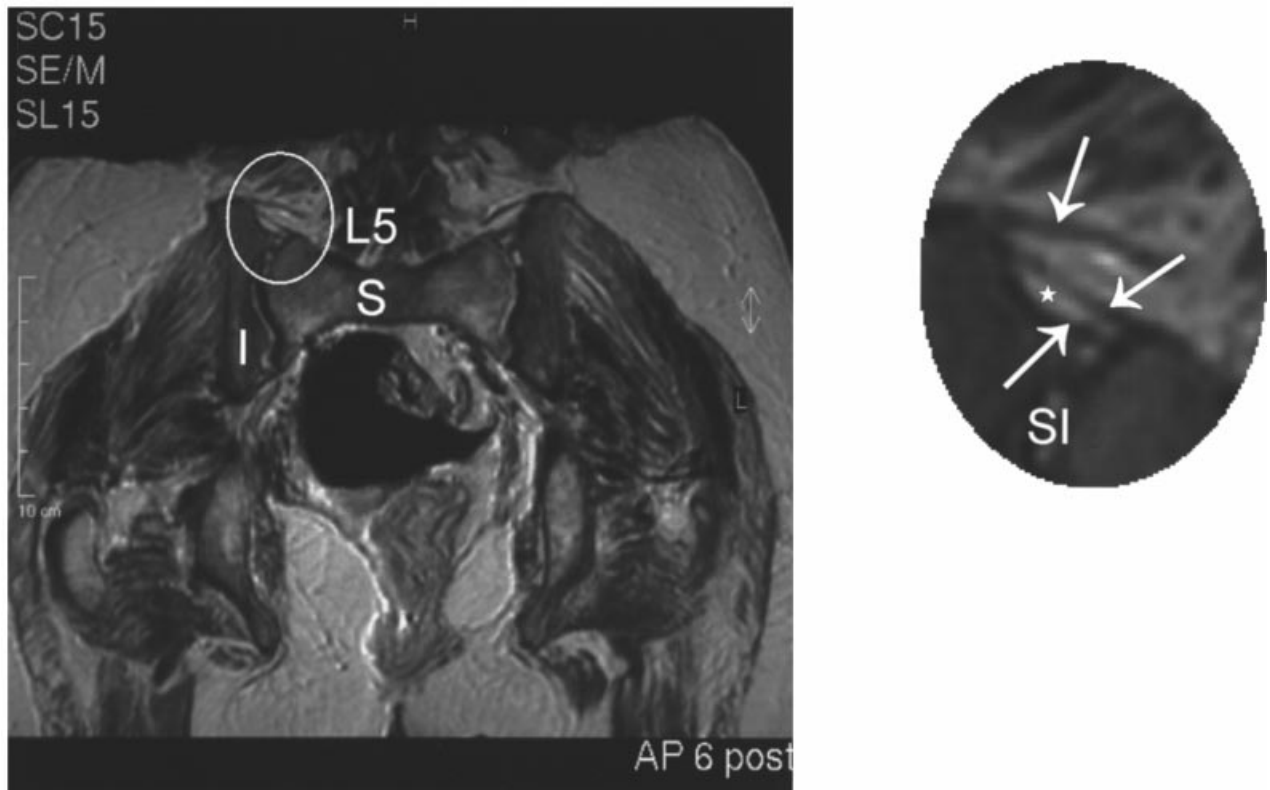


Fig. 6. MRI in the coronal plane of the lumbosacral area of the same slice as in Fig. 7. Note the separation of the craniolateral part of the SIPIL (middle arrow) and the interosseous SI ligaments (lower arrow) by fat (asterisk). The upper arrow (see inset) indicates the ventral band of the iliolumbar ligament. S, sacrum; I, ilium; SI, sacroiliac joint; L5, 5th lumbar vertebra.

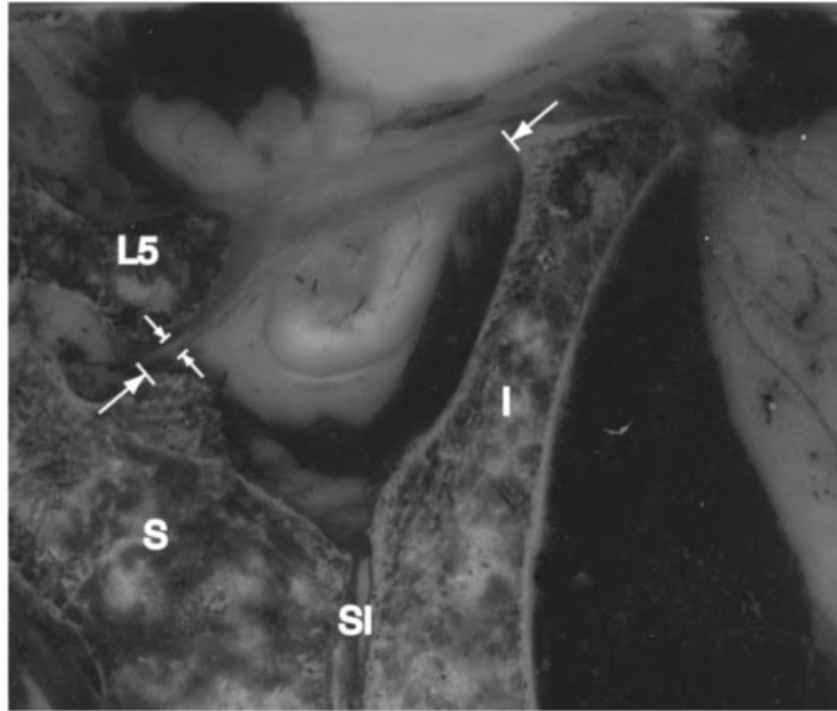


Fig. 7. Cryosectioned slice in the coronal plane of a part of the pelvis on the left side. I, ilium; S, sacrum; SI, sacroiliac joint; L5, 5th lumbar vertebra. The SIPIL is demarcated by the arrows.

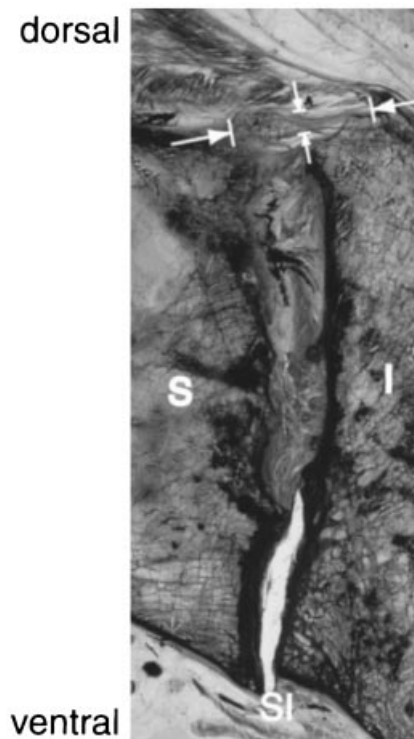


Fig. 8. Cryosectioned slice in the transverse plane of a part of the pelvis on the left side showing the SIPIL (between white arrows).

In 10 specimens, the IL had an attachment bilaterally to the ventrocaudal aspect of the transverse process of L4. In these specimens, fibres of the

iliolumbar ligament blended with the intertransverse ligaments between L4-L5 (Fig. 4).

In all specimens the following muscles were attached to the IL.

1. Muscle fibres of the erector spinae attached to the dorsal aspect of the IL, although these fibres could easily be removed by scraping.
2. The most medial muscle fibres of the iliacus attached to the caudal part of the ventral band of the IL.
3. The most medial muscle fibres of quadratus lumborum, mainly deriving from L4 and L5, attached to the most lateral part of the dorsal band of the IL.

#### DISCUSSION

In all specimens we found fibres originating from the ala of the sacrum and inserting onto the medial aspect of the iliac crest. Since the site of insertion of these fibres is just beneath that of the ventral band of the IL and since these fibres are separated from the interosseous SI ligaments by fat, we designate these fibres as a distinct sacroiliac part of the IL, the SIPIL. The SIPIL can be considered as the 'sacral head' of the ventral band. The origin of this part is at the same site on the sacrum as that of the interosseous SI ligaments. Our findings on the SIPIL are an extension

of the work of Frazer (1948), O'Rahilly (1986) and Willard (1995). Frazer (1948) described fibres of the IL passing to the transverse tubercle of the 1st sacral vertebra and the bone in front of this. O'Rahilly (1986) described the dorsal and ventral band extending from the transverse process of L5 to the sacrum and ilium while Willard (1995) described a part of the IL blending inferiorly with the interosseous ligaments of the SI joint. The attachment of a part of the IL to the sacrum suggests a role for the IL in restraining movement in the SI joint. However, as yet no biomechanical studies are available to support such an assumption.

The SIPIL is mainly oriented in the coronal plane, perpendicular to the SI joint. The direct restraining effect of the SIPIL can thus be expected in the coronal plane, providing resistance to an outward movement of the cranial part of the ilium with respect to the sacrum. A restraining effect of the SIPIL on movement of the sacrum in the sagittal plane (nutation and counternutation) can hardly be expected. Although the SIPIL blends with the intertransverse ligament of L5-S1, a direct influence of the SIPIL on the movement of L5-S1 is not likely either, since the fibres which blend with the intertransverse ligaments are thin and membranous. However, since a multitude of mechanoreceptors and nociceptors are present in the IL, this connection could be of importance in monitoring the motion of the lumbosacral junction.

The dimensions and orientations of the SIPIL are about the same in men and women. Angle  $\alpha$  tends to be somewhat larger in men than in women, but the difference is not statistically significant (see Table). The minor differences may be due to the sexual dimorphism of the adult pelvis, since in women the iliac blades are relatively vertical and do not extend as far upwards as in men (Williams & Warwick, 1980).

This study shows the existence of 7 parts to the IL. Although highly variable in number and form, major parts could be identified in all specimens. The numerous insertions and fibre directions suggest a diversity of biomechanical functions for the IL. This diversity is not acknowledged by authors describing 1 (Maigne & Maigne, 1991) or 2 separate bands of the IL (Moore, 1980; Luk et al. 1986; Hanson & Sonesson, 1994; Basadonna et al. 1996; Rucco et al. 1996). Several biomechanical studies have shown the importance of the IL in restraining motion at the lumbosacral joint and providing torsional stability of the lumbosacral junction (Leong et al. 1987; Chow et al. 1989; Yamamoto et al. 1989, 1990). However, these authors do not mention the connections of the IL to L4 or to the base of the sacrum. These connections

imply a more diverse role of the IL than previously described but biomechanical studies are needed to confirm the importance of the IL in stabilising the SI joint and L4-L5.

#### ACKNOWLEDGEMENTS

The authors thank J. M. A Mens and A. Vleeming for their advice.

#### REFERENCES

- BASADONNA PT, GASPARINI D, RUCCO V (1996) Iliolumbar ligament insertions. In vivo anatomic study. *Spine* **21**, 2313–2316.
- BOGDUK N (1983) The innervation of the lumbar spine. *Spine* **8**, 264–267.
- BOGDUK N, TWOMEY LT (1987) *Clinical Anatomy of the Lumbar Spine*. Melbourne: Churchill Livingstone.
- CHOW DHK, LUK KDK, LEONG JCY, WOO CW (1989) Torsional stability of the lumbosacral junctions. Significance of the iliolumbar ligament. *Spine* **14**, 611–615.
- FRAZER JE (1948) *The Anatomy of the Human Skeleton*. London: J&A Churchill.
- HANSON P, SONESSON B (1994) The anatomy of the iliolumbar ligament. *Archives of Physical Medical Rehabilitation* **75**, 1242–1246.
- KORKALA O, GRONBALD M, LIESI P, KARAHARJU E (1985) Immunohistochemical demonstration of nociceptors in the ligamentous structures of the lumbar spine. *Spine* **10**, 156–157.
- LEONG JCY, LUK DK, CHOW DHK, WOO CW (1987) The biomechanical functions of the iliolumbar ligament in maintaining stability of the lumbosacral junction. *Spine* **12**, 669–671.
- LUK KD, HO HC, LEONG JC (1986) The iliolumbar ligament. A study of its anatomy, development and clinical significance. *Journal of Bone and Joint Surgery* **68B**, 197–200.
- MAIGNE JY, MAIGNE R (1991) Trigger point of the posterior iliac crest: painful iliolumbar ligament insertion or cutaneous dorsal ramus pain? An anatomic study. *Archives of Physical Medicine and Rehabilitation* **72**, 734–737.
- MOORE KL (1980) *Clinically Oriented Anatomy*. Baltimore: Williams & Wilkins.
- O'RAHILLY R (1986) *Anatomy. A Regional Study of Human Structure*. Philadelphia: WB Saunders.
- PUN WK, LUK KD, LEONG JC (1987) Influence of the erect posture on the development of the lumbosacral region—a comparative study on the lumbosacral junction of the monkey, dog, rabbit and rat. *Surgery, Radiology and Anatomy* **9**, 69–73.
- RHALMI S, YAHIA LH, NEWMAN N, ISLER M (1993) Immunohistochemical study of nerves in lumbar spine ligaments. *Spine* **18**, 264–267.
- RUCCO V, BASADONNA PT, GASPARINI D (1996) Anatomy of the iliolumbar ligament. A review of its anatomy and a magnetic resonance study. *American Journal of Physical Medicine and Rehabilitation* **75**, 451–455.
- SIMS JA, MOORMAN SJ (1996) The role of the iliolumbar ligament in low back pain. *Medical Hypothesis* **46**, 511–515.
- UHTHOFF HK (1993) Prenatal development of the iliolumbar ligament. *Journal of Bone and Joint Surgery* **75B**, 93–95.
- WILLIAMS PL, WARWICK R (eds) (1980) *Gray's Anatomy*, 36th edn, p. 447. Edinburgh: Churchill Livingstone.
- WILLARD FH (1997) The muscular, ligamentous and neural structure of the low back and its relation to back pain. In

- Movement, Stability & Low Back Pain, the Essential Role of the Pelvis* (ed. Vleeming A, Mooney V, Dorman T, Snijders CJ, Stoeckart R), pp. 3–37. Edinburgh: Churchill Livingstone.
- YAHIA LH, NEWMAN N, RIVARD CH (1988) Neurohistology of lumbar spinal ligaments. *Acta Orthopaedica Scandinavica* **59**, 508–512.
- YAMAMOTO I, PANJABI MM, CRISCO T, OXLAND TR (1989) Three dimensional movements of the whole lumbar spine and lumbosacral joint. *Spine* **14**, 1256–1260.
- YAMAMOTO I, PANJABI M, OXLAND TR, CRISCO JJ (1990) The role of the iliolumbar ligament in the lumbosacral junction. *Spine* **15**, 1138–1141.