

[¹²³I]Metaiodobenzylguanidine and [¹¹¹In]Octreotide Uptake in Benign and Malignant Pheochromocytomas*

ERWIN VAN DER HARST, WOUTER W. DE HERDER, HAJO A. BRUINING, H. JAAP BONJER, RONALD R. DE KRIJGER, STEVEN W. J. LAMBERTS, ANTON H. VAN DE MEIRACKER, FRANS BOOMSMA, THEO STIJNEN, ERIC P. KRENNING, FRED T. BOSMAN, AND DIK J. KWEKKEBOOM

Departments of Surgery (E.v.d.H., H.A.B., H.J.B.), Internal Medicine III (W.W.d.H., S.W.J.L., A.H.v.d.M., F.B., E.P.K.), Pathology (R.R.d.K.), Biostatistics (T.S.), and Nuclear Medicine (E.P.K., D.J.K.), Erasmus University Hospital, 3000 CA Rotterdam, The Netherlands; and Department of Pathology, University Hospital of Lausanne (F.T.B.), Lausanne, Switzerland

ABSTRACT

Selecting the appropriate approach for resection and follow-up of pheochromocytomas (PCCs) is highly dependent upon reliable localization and exclusion of multifocal, bilateral, or metastatic disease. Metaiodobenzylguanidine (MIBG) scintigraphy was developed for functional localization of catecholamine-secreting tissues. Somatostatin receptor imaging (SRI) has a high sensitivity for localizing head and neck paragangliomas, but studies of intraabdominal PCCs are rare. In this study we review our experience of [¹²³I]MIBG and SRI, performed since 1983 and 1989, respectively, in the work-up of primary and recurrent PCCs. Scintigraphic results were correlated with catecholamine secretion, size and site, malignancy, associated tumor syndromes, and morphological features.

[¹²³I]MIBG scans were performed in a total of 75 patients, in 70 cases before resection of primary PCCs and in 5 cases because of recurrent disease. Ninety-one PCCs were resected. The overall detection rates were 83.3% and 89.8% for PCCs larger than 1.0 cm. Multifocal disease was detected in 4 patients with [¹²³I]MIBG. [¹²³I]MIBG uptake correlated with greater size of PCC ($r = 0.33$; $P = 0.008$) and greater concentration of plasma epinephrine ($r = 0.32$; $P =$

0.006). [¹²³I]MIBG-negative PCCs ($n = 14$) had significantly ($P = 0.01$) smaller diameters than [¹²³I]MIBG-positive tumors. Furthermore, [¹²³I]MIBG uptake was significantly higher in unilateral ($P = 0.02$), benign ($P = 0.02$), sporadic ($P = 0.02$), intraadrenal ($P = 0.02$), and capsular invasive ($P = 0.03$) PCCs than in bilateral, malignant, MEN2A/2B-related, extraadrenal, and noninvasive PCCs, respectively. The detection rate of SRI was only 25% (8 of 32) for primary benign PCCs. In 14 patients metastases occurred, which were effectively visualized with [¹²³I]MIBG in 8 of 14 cases. SRI was able to detect metastases in 7 of 8 cases, including 3 [¹²³I]MIBG-negative metastatic cases. In addition, [¹²³I]MIBG and SRI detected 2 recurrences.

In conclusion, [¹²³I]MIBG uptake is correlated with the size, epinephrine production, and site of PCCs. Its role in bilateral and MEN2A/2B-related PCCs seems limited. In cases of recurrent elevation of catecholamines, localization of metastases and/or recurrence should be attempted with [¹²³I]MIBG scintigraphy. In suspicious metastatic PCCs, SRI might be considered to supplement [¹²³I]MIBG scintigraphy. (*J Clin Endocrinol Metab* 86: 685–693, 2001)

DURING THE LAST 2 decades, management of pheochromocytomas (PCCs), catecholamine-secreting tumors arising from chromaffin cells of the sympatho-adrenal system, has substantially changed. The traditional concept of proper PCC surgery (1, 2), involving an extensive exploratory laparotomy to exclude occult foci in the contralateral adrenal gland or the retroperitoneal space, has gradually become a matter of debate (3, 4). With the introduction of less invasive procedures for resection of PCCs, such as unilateral approaches through a flank incision (3, 5), laparoscopy (6, 7), or retroperitoneoscopy (8, 9), accurate preoperative localization has become more important. Selecting the appropriate surgical approach, however, is highly dependent upon reliable exclusion of multifocal, bilateral, or metastatic disease.

PCCs can occur in association with several hereditary tumor syndromes. Gene mutations responsible for Von Hippel-Lindau disease (VHL) (10) and multiple endocrine neoplasia type 2A/2B (MEN2A/2B) (11, 12) can be identified, and detection of carriers of these syndromes has become possible. Improvements in detection techniques for catecholamines and emphasis on screening for hereditary cases have increased early stage diagnosis of PCCs and its preceding medullary hyperplasia. The radiopharmaceutical agent [¹³¹I]metaiodobenzylguanidine ([¹³¹I]MIBG), a guanethidine analog that is stored in sympatho-adrenal tissues, was developed for adrenal scintigraphy (13, 14). Recently, in a large European multicenter study, the sensitivity of [¹³¹I]MIBG ($n = 160$) to detect PCCs was 81% (4).

Improvements in scintigraphic procedures may reduce false negative results. Labeling MIBG with ¹²³I instead of ¹³¹I yielded superior imaging quality (15–17). However, 12.5% of PCCs still remained undetected in the largest published series to date ($n = 24$ PCCs in 120 patients) (18). One could speculate that structural and functional differences in PCCs are responsible for diminished [¹²³I]MIBG uptake in different tumor types. However, potential clinical and morphological features that could influence [¹²³I]MIBG uptake in PCCs have

Received May 5, 2000. Revision received July 26, 2000. Rerevision received October 9, 2000. Accepted November 2, 2000.

Address all correspondence and requests for reprints to: Erwin van der Harst, M.D., Department of Surgery, Erasmus University Hospital, Rotterdam, P.O. Box 2040, 3000 CA Rotterdam, The Netherlands. E-mail: evanderharst@hotmail.com.

* This work was supported by a grant from the Jan Dekkerstichting en Dr Ludgardina Bouwmanstichting (Muiderberg, The Netherlands) and Stichting De Drie Lichten (Hilversum, The Netherlands).

been poorly studied. An alternative approach, somatostatin receptor imaging (SRI), using [^{111}In -diethylenetriaminopentaacetic acid (DTPA) 0]octreotide (Octreoscan; Mallinckrodt Medical B.V., Petten, The Netherlands), was found to have a sensitivity of over 90% for localizing nonfunctional head and neck paragangliomas (19, 20). This prompted us to also use SRI for abdominal PCCs.

In this study we review our experience of preoperative [^{123}I]MIBG and SRI performed in the diagnostic work-up of PCC patients. Scintigraphic results were correlated with catecholamine secretion, size and site of the tumors, malignancy, associated tumor syndromes, and morphological features of resected PCCs to define subgroups of patients in whom these scintigraphic techniques might be of use.

Subjects and Methods

Subjects

Between 1983 and 1999 one or more preoperative [^{123}I]MIBG scans were performed in 70 patients. In 5 additional patients only postoperative [^{123}I]MIBG scans were available because of suspected recurrence. Patient characteristics are summarized in Table 1. These 75 patients underwent surgery (or autopsy in 3 patients) for a total of 91 PCCs. In 3 PCC patients, it was decided not to operate, but to palliate with phenoxybenzamine and α -methyl-paratyrosine, because of great age (in 2 sporadic patients) and widely metastasized medullary thyroid carcinoma in a MEN2A patient. Autopsy revealed 2 unilateral PCCs in the sporadic patients and a bilateral PCC in the MEN2A patient. Endoscopic resection, which has become available in our institute since 1995 (9), was performed in 11 unilateral and 2 bilateral cases.

Indications for preoperative [^{123}I]MIBG studies included elevation of basal plasma catecholamines in 65 cases, harboring 76 PCCs. In 5 cases/8 PCCs, basal catecholamine levels were normal, but preoperative [^{123}I]MIBG scans were performed because of suggestive symptoms in 2 MEN2A cases, 1 MEN2B case, and 2 patients with incidentaloma. Basal plasma concentrations of norepinephrine (median, 20.44 nmol/L; range, 0.68–151.32; normal, <3.55 nmol/L), epinephrine (median, 3.62 nmol/L; range, 0.05–60.45; normal, <0.55 nmol/L), and dopamine (median, 1.06 nmol/L; range, 0.11–328.53; normal, <0.65 nmol/L) were measured by high performance liquid chromatography with electrochemical or fluorometric detection (21). Only cases with histologically confirmed intraabdominal PCCs were included in this study. The median tumor diameter of resected PCCs was 4.3 cm (range, <0.1–15 cm). Resected adrenal glands of MEN2A/2B cases harboring tumor nodules less than 1 cm, which are usually referred to as (micronodular) medullary hyperplasia, were also included in the study group. Malignant PCCs were defined as metastasized tumors at the time of diagnosis or during follow-

up. Metastases were defined as the presence of tumor at sites where chromaffin tissue is not normally found.

[^{123}I]MIBG scintigraphy

Whole body (from head to pelvis) planar images or spot views were obtained 24 h after injection of 370 MBq [^{123}I]MIBG. Spot views of the upper abdomen were obtained after 48 h. Studies performed in patients taking labetalol ($n = 3$) were excluded from the study. However, 10 days after labetalol treatment was interrupted, scans were repeated in two of three patients taking this medicine, and these studies were, therefore, included. No other agent known to interact with MIBG uptake (sympathomimetics, adrenergic blocking agents) was taken by any of the patients. [^{123}I]MIBG studies were subsequently reviewed by the same experienced investigator (D.J.K.), who was unaware of catecholamine levels and other clinical information. Uptake intensity was rated according to the method described by Mozley and co-workers (18). Uptake was scored 0 if no uptake was present. Scores of 1, 2, and 3 represent tumor uptake less than, equal to, and more than reference [^{123}I]MIBG activity in the liver. These uptake results were correlated with clinical characteristics, secretion patterns, morphology, and tumor behavior.

SRI

SRI was performed using the commercially available somatostatin analog [^{111}In -DTPA] p-Phe^1 -octreotide (Mallinckrodt, Inc., Petten, The Netherlands). [^{111}In -DTPA] p-Phe^1 -octreotide (210–400 MBq) was injected in 28 patients. Planar images were obtained with a double head or large field of view camera 24 and 48 h after injection. Single photon emission computed tomography images were available for all patients. We used a simple yes or no system for definition of tumor visualization. The two subsequent scans were compared. Any accumulation of radioactivity at abnormal sites was considered to represent somatostatin receptor binding if it was visible on both scans.

PCCs

Tumor site (intraadrenal or extraadrenal) and the largest tumor axis were taken from the pathology reports. Histopathology of primary tumors and metastases was reviewed by one experienced pathologist (F.T.B.) and served as the gold standard for correlation with imaging results. Capsular invasion was scored negative if the capsule was intact or positive when tumor cells, mostly wedge shaped, invaded into or through the capsule. Vasoinvasion was scored either negative if absent or positive if invasion into the intratumoral, capsular, or surrounding vessels was present. In addition, tumor degeneration was scored when intratumoral necrosis, hemorrhage, or cysts were present.

Statistical analysis

The χ^2 test was used for comparing nominal variables (categorical variables without ordering) between groups. For quantifying associations between variables, Spearman's nonparametric correlation coefficient was used. The Mann-Whitney U test (for two groups) was performed to compare ordinal variables (categorical variables with ordering) or continuous variables that were not normally distributed. $P < 0.05$ was considered significant.

Results

Preoperative [^{123}I]MIBG scans

Table 2 summarizes uptake results of 70 preoperative [^{123}I]MIBG scans. Overall, grade 3 uptake was found in 61 of 84 tumors (72.6%). Uptake equally intense as the activity in the liver (grade 2) was found in an additional 9 PCCs. Therefore, if [^{123}I]MIBG uptake equal to or greater than 2 defines positive detection, the overall detection rate of PCCs of all sizes was 83.3% (70 of 84). Fourteen PCCs (16.7%) that were resected in 12 patients, however, had either grade 0 or 1 uptake and therefore remained undetected by [^{123}I]MIBG scintigraphy. Interestingly, 12 of 14 false negative PCCs ei-

TABLE 1. Patient and tumor characteristics

Feature	No.
Patients (male/female)	75 (34/41)
Sporadic	54
MEN2A	11
MEN2B	1
VHL	3
Neurofibromatosis	6
Procedures (unilateral/bilateral)	76 (61/15)
(Thoraco-)laparotomy	55 (43/12)
Flank incision	5 (5/0)
Endoscopic resection	13 (11/2)
Autopsy	3 (2/1)
PCCs (intra-/extraadrenal)	91 (80/11)
Diameter >1 cm	76 (65/11)
Diameter <1 cm	15 (15/0)
Malignancy	14 patients
Disease free interval [median (range)]	37 months (0–156)
Mortality	9/14
Survival [median (range)]	68 months (0–167)

TABLE 2. [¹²³I]MIBG uptake of 70 scans performed before resection of 84 PCCs

[¹²³ I]MIBG uptake	Pheochromocytomas		Total
	Unilateral	Bilateral	
PCC-side			
Grade 3	47/58 (81.0)	14/26 (53.8)	61/84 (72.6)
Grade 2	4/58 (6.9)	5/26 (19.2)	9/84 (10.7)
Grade 1	1/58 (1.7)	3/26 (11.5)	4/84 (4.8)
Grade 0	6/58 (10.3)	4/26 (15.4)	10/84 (11.9)
Unaffected side			
Grade 3	1/58 (1.7)		1/58 (1.7)
Grade 2	0/0 (0.0)		0/0 (0.0)
Grade 1	4/58 (6.9)		4/58 (6.9)
Grade 0	53/58 (91.4)		53/58 (91.4)

Percentages are in parentheses.

ther proved to be malignant (n = 4 PCCs) or were resected in early stages from patients with hereditary tumor syndromes (n = 8 PCCs).

Undetected PCCs had a significantly (P = 0.01) smaller tumor diameter (median, 2.9 cm; range, <0.1 to 14.0 cm) than those with uptake grade 2 or 3 (median diameter, 4.7 cm; range, <0.1 to 15.0 cm). Considering only PCCs with tumor diameters larger than 1 cm, the detection rate of [¹²³I]MIBG scintigraphy increased to 89.8% (62 of 69). Of 15 tumors with diameters less than 1 cm (all but 1 resected from familial cases), tumor detection was MIBG⁺/CT⁺ (computerized tomography) in 2 cases, MIBG⁺/CT⁻ in 6 cases, MIBG⁻/CT⁺ in 5 cases, and MIBG⁻/CT⁻ in 2 cases. Therefore, 2 early staged PCCs from MEN2A and MEN2B patients remained undetected by all imaging modalities, but were resected anyway, as bilateral adrenalectomy was routinely performed. Unexpectedly, carotid body glomus tumors, representing multifocal disease, were detected on 4 preoperative whole body [¹²³I]MIBG scans.

Computed tomography (CT) scans were obtained in all patients and were able to localize 78 of 84 (93%) PCCs. Overall, discordant CT/[¹²³I]MIBG localization results were present in 19 PCCs; i.e. 6 tumors, all smaller than 1 cm, remained undetected by CT, but were detected by [¹²³I]MIBG scintigraphy, whereas CT detected 13 tumors not imaged by [¹²³I]MIBG scintigraphy. There was only 1 presumed false positive [¹²³I]MIBG localization with grade 3 uptake and none with grade 2 uptake. This patient, who has VHL syndrome, had grade 3 [¹²³I]MIBG hot spots in both adrenal glands. CT, however, only revealed a unilateral adrenal mass. Considering the implications of life-long hormonal replacement in this patient, who was severely neurologically disabled due to a cerebellar hemangioblastoma, it was decided to resect only the largest adrenal gland. To date, plasma catecholamine levels remain within the normal range.

Correlation of [¹²³I]MIBG uptake with other clinical variables

[¹²³I]MIBG uptake was significantly correlated with the largest diameter of the resected PCCs (r = 0.33; P = 0.008). With regard to functional parameters, only plasma epinephrine levels (r = 0.32; P = 0.006) showed a significant correlation with [¹²³I]MIBG-uptake (Fig. 1). Plasma norepinephrine (r = 0.09; P = 0.45), dopamine (r = 0.13; P = 0.28), and

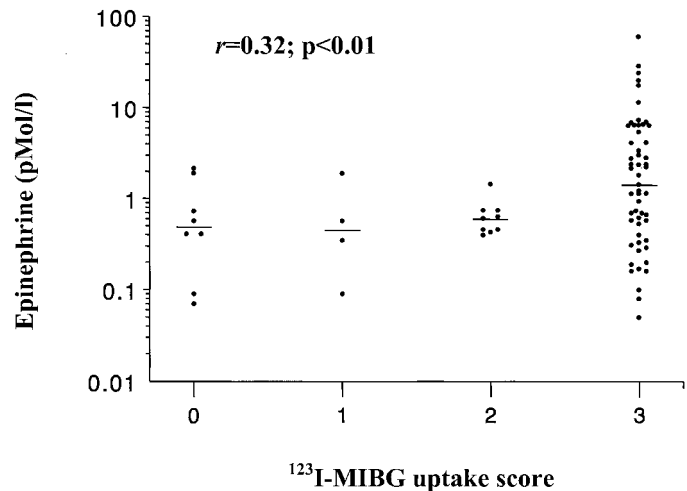


FIG. 1. Plasma epinephrine levels (note: logarithmic concentrations are depicted) of PCCs with various [¹²³I]MIBG uptake levels. Median levels are indicated by horizontal lines.

TABLE 3. Statistical comparison of preoperative [¹²³I]MIBG uptake (n = 70 preoperative studies) in 84 primary PCCs performed in 70 patients

	Mean [¹²³ I]MIBG uptake of primary PCC		
	Yes	No	P value ^a
MEN2A/2B (n = 11/1 patients)	2.00	2.56	0.03
Bilaterality (n = 13 patients)	2.11	2.57	0.02
Extra-adrenal site (n = 9 patients)	1.55	2.55	0.02
Malignancy (n = 9 patients)	1.55	2.51	0.02
Capsular invasion (n = 51 PCCs)	2.40	2.60	0.18
Angioinvasion (n = 21 PCCs)	2.76	2.42	0.14
Necrosis (n = 30 PCCs)	2.28	2.49	0.74
Hemorrhage (n = 27 PCCs)	2.73	2.49	0.30

^a The Mann-Whitney U test was used for statistical comparison of [¹²³I]MIBG uptake between resected PCCs from patients with clinicopathological features.

urinary levels of vanillylmandelic acid (r = 0.14; P = 0.36), normetanephrine (r = 0.22; P = 0.45), and metanephrine (r = 0.25; P = 0.37) were not associated with [¹²³I]MIBG uptake.

PCC features and [¹²³I]MIBG uptake (Table 3)

The [¹²³I]MIBG uptake score was significantly lower in the primary PCCs that subsequently proved to be malignant than in nonmetastasizing tumors. Furthermore, the [¹²³I]MIBG uptake score was significantly higher in unilateral, intraadrenal, and sporadic (non-MEN2) tumors than in bilateral, extraadrenal, and MEN2A/2B-related PCCs. The microscopic presence of capsular invasion, angioinvasion, necrosis, or hemorrhage, which was found in 51 of 84, 21 of 84, 30 of 84, and 27 of 84 PCCs, respectively, was not significantly correlated with [¹²³I]MIBG uptake.

SRI for benign and malignant PCCs

SRI for localization of the primary tumor or its metastases was performed in a total of 28 patients before resection of 37 PCCs. In the benign group, only 25% (8 of 32) of the tumors could be detected with SRI. All of these had been detected

with [¹²³I]MIBG scintigraphy. Eighteen benign PCCs that were negative on SRI were successfully visualized with [¹²³I]MIBG. Both SRI and [¹²³I]MIBG studies were negative in 6 benign PCCs.

Table 4 summarizes the results of all malignant (patients 1–14) and recurrent (patients 15 and 16) cases. Preoperatively, all 5 malignant PCCs were successfully localized with SRI. Among these 5 malignant PCCs, 2 tumors (patients 10 and 11) were negative with [¹²³I]MIBG scans. Postoperatively, in 7 of 8 patients metastases were visualized with SRI. SRI was significantly more successful in localizing primary malignant tumors ($P = 0.003$) and PCC metastases ($P < 0.0005$) than in detecting primary benign PCCs. In all 14 malignant cases 1 or more postoperative [¹²³I]MIBG scans were performed. The primary indication for scintigraphy in these was the recurrence of elevated catecholamines after initial normalization in 8 of 14 cases. In the other 6 cases, metastases were already present at laparotomy for the primary tumor. The median disease-free interval was 36.7 months (range, 0–156 months). In 8 malignant cases (cases 1, 3–6, 8, 9, and 13) metastases were effectively visualized with [¹²³I]MIBG. However in 6 malignant cases (cases 2, 7, 10–12, and 14), metastases could not be localized by [¹²³I]MIBG, but in 3 cases they were visualized by SRI (cases 2, 10, and 11). In all cases with positive SRI and [¹²³I]MIBG, SRI detected more metastasis sites than [¹²³I]MIBG imaging. Figure 2 shows typical SRI and [¹²³I]MIBG images of metastatic sites in patient 3. Of interest is patient 7, who was operated upon because of positive [¹²³I]MIBG and SRI scans indicating an extraadrenal PCC. Four years later, retroperitoneal metastases and a nonfunctional recurrence in the same region where the tumor was formerly resected were detected on a CT scan. Both [¹²³I]MIBG imaging and SRI were now negative. Diagnosis could only be established by fine needle aspiration.

There were two benign recurrences detected by [¹²³I]MIBG imaging. In case 15, a patient with MEN2A, both adrenal glands had been resected previously, but PCC still recurred in remnant adrenal gland tissue. In case 16 a PCC recurred in the contralateral gland. This patient suffered from Proteus syndrome, a rare and highly variable congenital hamartomatous condition, comprising asymmetrical overgrowth of different parts of the body. It is characterized by hyperplastic lesions of connective tissue, vascular malformations, linear verrucous epidermal nevi, and hyperostoses. This syndrome has been rarely reported in association with PCC (22).

Discussion

Since the first report in 1979 (13) and the first clinical study in 1981 (23), [¹³¹I]MIBG imaging has been well established as a localizing tool and a functional marker of catecholamine-secreting tissue. Initially, most centers used [¹³¹I]MIBG as the PCC-seeking radiopharmaceutical agent. However, shortly after the publication of promising reports in 1981 (24, 25), we consistently employed [¹²³I]MIBG scintigraphy in patients suspected of having PCC. In this large single institutional series we evaluated the scintigraphic results for localizing primary tumor sites, multifocal locations, recurrences, and metastases of 91 intraabdominal, histologically proven PCCs. In a subset of these patients the use of SRI was ad-

ditionally studied. [¹²³I]MIBG uptake was significantly correlated with tumor size and epinephrine production and was significantly greater in benign, sporadic, intraadrenal, and unilateral tumors. [¹²³I]MIBG imaging was shown to be complementary to CT. Four multifocal PCC localizations were detected preoperatively, and metastases were found in 8 patients. SRI was not very helpful as a localizing tool for the primary tumor. It was, however, useful in detecting metastases, particularly in [¹²³I]MIBG-negative cases.

Anatomical and functional imaging techniques of primary PCCs

Once the biochemical diagnosis has been made, exact anatomical localization of the tumor(s) is mandatory, because of the variable locations of PCCs. Anatomical localization can be achieved by CT or magnetic resonance (MR) imaging. CT scanning is the most widely available and is less expensive; therefore, as in our hospital, it is the localizing tool of first choice in most centers (2, 3). Optimal CT imaging of PCCs consists of pre- and postcontrast thin collimation spiral scanning of the abdomen. Successful detection has been reported in 80–95% of unilateral PCCs (4, 26). No radiation or iv contrast media are required in MR studies, which is the preferred procedure if PCC occurs during pregnancy. Due to their hypervascularity, PCCs are hyperintense and accurately detected (85–95%) on T2-weighted MR images (4, 26, 27). However, in the light of health care costs, availability, and investigation time, neither CT nor MR is easily adapted for imaging of the entire sympatho-adrenal system (from head to pelvis) for localization or exclusion of extraadrenal or multifocal PCCs. For this purpose whole body MIBG scintigraphy serves as a supplement to these anatomical localization techniques. Therefore, we prefer [¹²³I]MIBG scintigraphy as an initial imaging modality to subsequently direct CT imaging to regions that show increased uptake. In contrast to CT imaging, MIBG scans are not hampered by metal clips, which are commonly used during abdominal surgery. Furthermore, it adds functional information to the anatomical imaging techniques. As an analog of guanethidine, an adrenergic blocking agent with high affinity for the adrenal medulla and adrenergic nerves, storage of MIBG takes place in the catecholamine-containing neurosecretory granules (27–30). Early studies have validated [¹³¹I]MIBG scintigraphy as a useful localizing technique for intra- and extraadrenal PCCs, with a high specificity of greater than 95%. However, considerable false negative rates have been reported, ranging from 13% in studies performed at the University of Michigan (31, 32), to 19% in a large French multicenter study (4), to almost 25% in other centers in the United States (33) and Japan (34). This urged us to use [¹²³I]MIBG as the PCC-seeking radiopharmaceutical agent, because it has some advantages over [¹³¹I]MIBG. Approximately 20 times higher diagnostic doses can be administered, because of the shorter half-life of [¹²³I]MIBG and the greater γ -camera efficiency with the 159-keV ¹²³I photon compared with the 364-keV ¹³¹I photon used in [¹²³I]MIBG and [¹³¹I]MIBG scintigraphies, respectively. This improves photon flux and yields clearer delineation of tumors (16, 35). Published series using ¹²³I labeling, however, have been of limited size, at

TABLE 4. Postoperative [¹²³I]MIBG and octreotide scans in 14 malignant PCCs and 2 benign recurrences

Patient no.	Site Spor/Fam/Multi	Age (yr) at diagnosis	Disease-free interval (months)	Postop. ↑ CATS (fold increase)	Uptake primary PCC	Uptake metastases	Location metastases	Treatment	Outcome
Distant metastases									
1	Bilat IA Spor	53 (1979)	72	NE (11×) EPI (5×)		MIBG gr 3	Bone, pleural, bone marrow	[¹³¹ I]MIBG (1985; progression), RT, phenoxybenzamine, α-methyl-paratyrosine Chemotherapy, RT	D.O.D. 1985
2	L EA (pararenal) Spor	39 (1982)	120	NE (7×) DA (43)	MIBG gr 0	MIBG gr 0 Octreo+	Bone, lung, RP MED		D.O.D. 1986
3	L EA (pararenal) Spor	53 (1982)	156	NE (8×) EPI (5×) DA (20×)		MIBG gr 3 Octreo+	Bone, lung, RP	1 × 1550 mBq [¹³¹ I]MIBG, RT Phenoxybenzamine	Alive with disease
4	EA (Zuckerkindl) Spor	23 (1984)	36	NE (8×) DA (40×)		MIBG gr 3 Octreo+	Bone, RP	Octreotide (1989; progression), chemotherapy, RT, phenoxybenzamine	D.O.D. 1989
5	L IA Spor	65 (1985)	0	NE (9×) DA (2×)		MIBG gr 3 Octreo+	Bone, liver, RP, MED	5500 MBq [¹³¹ I]MIBG (1985; progression), palliative RT	D.O.D. 1986
6	R IA Spor	48 (1989)	60	NE (6×)	MIBG gr 2	MIBG gr 3	Lung, RP	3 × ¹³¹ I-MIBG (1985; progression), chemotherapy Palliative RT	D.O.D. 1996
7	L EA (pararenal) Spor	64 (1991)	48	None	MIBG gr 3 Octreo+	MIBG gr 0 Octreo-	RP		D.O.D. 1995
8	Zuckerkindl Multi	27 (1994)	0	NE (17×) DA (2×)	MIBG gr 3 Octreo+	MIBG gr 3 Octreo+	Bone, lung, RP MED	[¹¹¹ In]Octreotide (1995; progression) chemotherapy, phenoxybenzamine/propranolol 2 × [¹³¹ I]MIBG	D.O.D. 1996
9	R EA (pararenal) Spor	58 (1995)	0	Normal	MIBG gr 3	MIBG gr 3	RP		Remission
10	R IA Spor	42 (1997)	24	NE (320×) EPI (5×) DA (3×)	MIBG gr 0 Octreo+	MIBG gr 0 Octreo+	Liver, RP	[¹¹¹ In]Octreotide (1999) Phenoxybenzamine	D.O.D. 2000
11	Liver Spor	42 (1998)	0	NE (2×)	MIBG gr 0 Octreo+	MIBG gr 0 Octreo+	Lung	Phenoxybenzamine	Alive with disease
Locoregional metastases									
12	Bladder Spor	41 (1986)	0	NE (1.5×)	MIBG gr 0	MIBG: gr 0	RP (locoregional)	Phenoxybenzamine	D.O.D. 1992
13	R EA (pararenal) Multi	25 (1991)	0	None	MIBG gr 3 Octreo+	MIBG gr 3 Octreo+	RP		Lost of F.U.
14	Bilat IA VHL	31 (1983)	0	Normal		MIBG: no sign of recurrence	RP (locoregional)		Alive, no sign of recurrence
Benign recurrence									
15	R IA 1959 L IA 1966	17 (1959)	288	NE (2×)	1990: MIBG gr 3 Octreo-				Alive
16	R REC 1990 L IA 1994 L IA 1999	13 (1994)	51	NE (1.3×)	1994: R MIBG gr 2; L gr 0 1999: L MIBG gr 1 Octreo-				Alive

CAT, Catecholamine; DA, dopamine; D.O.D., died of disease; EA, extraadrenal; EPI, epinephrine; IA, intraadrenal; L, left; MED, mediastinal; NE, norepinephrine; R, right; REC, locoregional recurrence; RP, retroperitoneal; RT, radiotherapy; Spor, sporadic.

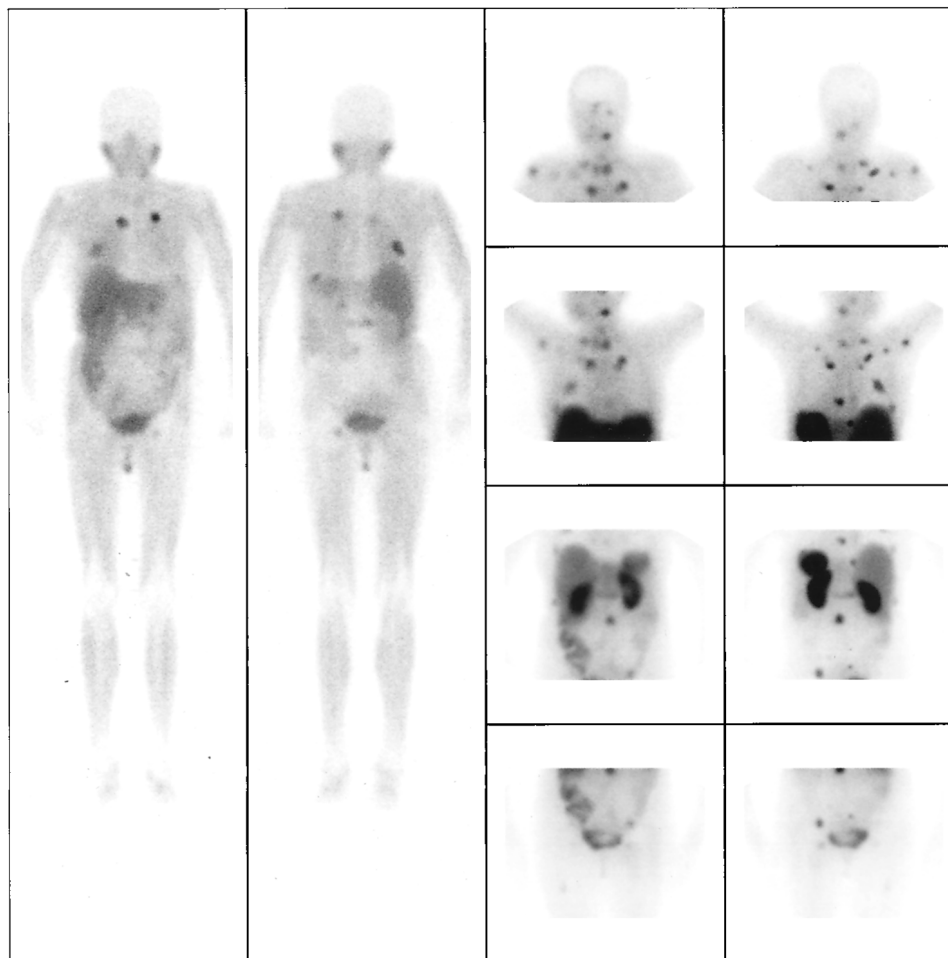


FIG. 2. [^{123}I]MIBG scan (left columns, anterior and posterior, respectively) and SRI (right columns, anterior and posterior) in case 3 (see Table 4). Uptake of [^{123}I]MIBG is shown in some metastases, but pathology is found in more sites (mostly skeletal) with SRI. Normal uptake in salivary glands, liver, bowel, and urine bladder is seen with [^{123}I]MIBG; normal uptake in liver, spleen, kidneys, bowel, and urine bladder is seen with SRI.

least partly due to the fact that [^{123}I]MIBG is not commercially available in the United States (36). In a large series using [^{123}I]MIBG scintigraphy, uptake was grade 2 or 3 in 22 of 24 (91.7%) of adrenal PCCs (18). In our series this percentage was slightly smaller. This may be due to the fact that 31% of PCCs (26 of 84) were resected from patients with bilateral adrenal disease, whereas in the above-mentioned series only 1 bilateral PCC was included.

In contrast to our findings, higher frequencies of increased [^{123}I]MIBG uptake in the normal, nonpathological adrenal gland have been reported in PCC patients (16, 18). In a preliminary study by Lynn and co-workers (16) in only 14 patients with PCCs, contralateral visualization of a presumably normal adrenal gland was found in 8 patients. In a study by Mosley and co-workers (18), visualization of the normal, nonpathological adrenal gland with [^{123}I]MIBG was found in 5 of 22 (23%) patients using unilateral PCC. However, neither study provided follow-up data on these scan-positive patients. Therefore, it cannot be excluded that increased uptake in otherwise normal adrenal glands might have reflected the presence of small PCCs or adrenal medullary hyperplasia. Also, the designs of both studies were different from ours. The study by Lynn and co-workers (16) was designed to compare [^{123}I]MIBG and [^{131}I]MIBG scanning in PCCs, and Mosley *et al.* (18) performed a screening study for PCCs in 120 patients with labile hypertension. Therefore, this latter study

comprised mainly subjects without PCCs (91 of 120 subjects), whereas all patients had PCCs in our study.

[^{123}I]MIBG scintigraphy in familial and/or bilateral PCCs

As our hospital serves as a tertiary referral center for endocrine disorders, there is an overrepresentation of hereditary, bilateral PCCs. As a result of genetic counseling, these cases have been referred for surgery at earlier stages than their sporadic counterparts. Furthermore, we have been rather liberal in the histopathological designation of the term PCC. We did not reserve this term solely for macroscopic tumor nodules (>1 cm), but have also used the term for microscopic nests of PCC cells. Not surprisingly, the sensitivity of [^{123}I]MIBG scintigraphy was significantly lower in bilateral and MEN2A/2B-related PCCs. This is in agreement with the results of other studies, which reported successful [^{131}I]MIBG detection of bilateral lesions in only 62% of cases (4). Therefore, referral bias is probably the cause of the substantially lower detection rate in our series. Although arbitrary, others (37) have proposed to differentiate between true PCC (tumors >1 cm) and nodular medullary hyperplasia (tumor nodules <1 cm), which represents the PCC precursor in the adrenal medulla in MEN2A and MEN2B patients (38) and sporadic (39, 40) cases. If 1 cm is selected as a cut-off point for the discrimination between hyperplasia and true

PCC, grade 2 or 3 uptake is found in 89.8% of tumors. This figure appears to provide the proper perspective on the successful detection rate of $[^{123}\text{I}]\text{MIBG}$ scintigraphy. In the present study a statistically significant correlation was found between PCC size and accumulation of $[^{123}\text{I}]\text{MIBG}$. This had already been established for $[^{131}\text{I}]\text{MIBG}$ scintigraphy (31), but not for $[^{123}\text{I}]\text{MIBG}$ (18). For years, our policy in MEN2A/2B-related PCCs has been bilateral adrenalectomy even in the presence of a unilateral mass on preoperative imaging. In the present series 15 adrenal glands were resected for microscopic PCC or medullary hyperplasia, defined according to the previously mentioned criteria. Seven of these hyperplastic glands, containing only microscopic nests of PCC cells (so-called Zellballen), remained undetected by $[^{123}\text{I}]\text{MIBG}$ scintigraphy. Hence, the role of $[^{123}\text{I}]\text{MIBG}$ scintigraphy in early detection of adrenomedullary hyperplasia seems to be limited. In general, this technique is not advocated if preventive bilateral adrenalectomy is the therapeutic policy of first choice in MEN2A/2B patients (41). Considering MEN2A/2B cases presenting with unilateral adrenal mass, some experts favor a more conservative policy of unilateral resection and close follow-up of the contralateral adrenal gland (42). With the introduction of endoscopic resection, which is safe and relatively simple and decreases operative morbidity, we favor this more conservative approach (7, 9). However, this approach will have important implications for follow-up investigations. $[^{123}\text{I}]\text{MIBG}$ may additionally detect other neuroendocrine tumors, such as medullary thyroid carcinoma, leading to confusing postoperative scanning results in multiendocrinopathies such as MEN2A/2B and VHL (43). Metastases of medullary thyroid carcinoma were more or less unexpectedly detected in 3 MEN2A patients with paroxysmal symptoms after bilateral adrenalectomy (data not shown in *Results*).

$[^{123}\text{I}]\text{MIBG}$ uptake in relation to secretory profile of PCCs

We found a significant correlation between epinephrine plasma levels and $[^{123}\text{I}]\text{MIBG}$ uptake in the resected tumors. However, the clinical significance of this finding seems limited, as there was considerable overlap of plasma epinephrine values among the groups (Fig. 1). Others have been unable to find a proportional correlation between $[^{123}\text{I}]\text{MIBG}$ (15, 18) and $[^{131}\text{I}]\text{MIBG}$ (31, 44) uptake and plasma or urinary catecholamine levels. $[^{123}\text{I}]\text{MIBG}$ uptake, however, was found to be strongly dependent on catecholamine storage capacity, quantitated by the number of neurosecretory granules (15). Like norepinephrine, MIBG follows the uptake 1 pathway into these hormone storage vesicles (30). Like others (45), we have encountered eight cases with only microscopic PCCs with almost normal catecholamine secretion levels that showed grade 3 $[^{123}\text{I}]\text{MIBG}$ uptake. Therefore, MIBG uptake appears to better represent storage than basal secretion of catecholamines (15). Compared with patients harboring small tumors, higher hormone levels may be found in patients with large tumors; therefore, plasma epinephrine levels may not exhibit an independent predictive value for $[^{123}\text{I}]\text{MIBG}$ uptake. However, Eisenhofer and co-workers (46) were unable to find a correlation between plasma catecholamines and size, as increased metabolism of cat-

echolamines into metanephrines occurs within larger tumors (through catechol-*O*-methyltransferase). Moreover, others have shown that not size but intratumoral hemorrhage and cystic necrosis are correlated with the paroxysmal release of stored catecholamines from some PCCs (47). Not surprisingly, these degenerative features are not associated with increased $[^{123}\text{I}]\text{MIBG}$ uptake.

SRI for adrenal PCCs

Encouraged by the high sensitivity of SRI in localizing head and neck paragangliomas (19, 48), we also performed SRI in a subset of patients with adrenal PCCs. However, successful detection was only achieved in 25% of the benign PCCs. As opposed to SRI for head and neck paragangliomas, imaging of adrenal PCCs seems to be seriously hampered by physiological uptake in the kidney (20). Therefore, based upon the present study, performing SRI for localization of primary PCCs is not advised. Possibly, newer somatostatin analogs might accumulate more specifically in catecholamine-secreting tumors (49, 50).

$[^{123}\text{I}]\text{MIBG}$ scintigraphy and SRI for ectopic and malignant PCCs

Up to 20% of PCCs is of extraadrenal origin, which are frequently multicentric and more likely to be malignant than those found within the adrenal gland (51). Conflicting data exist in the literature regarding the usefulness of MIBG scanning of functional extraadrenal PCCs. In agreement with results from the present study, MIBG uptake has been found to be significantly less in extraadrenal than in adrenal PCCs (4, 18). On the other hand, one of the reported advantages of MIBG whole body studies is its ability to detect multicentric or metastatic disease, which both occur more frequently in extraadrenal PCCs (45). Similar to the diminished accumulation in extraadrenal tumors, malignant PCCs also appear to have less affinity toward $[^{123}\text{I}]\text{MIBG}$ (51). In 4 of 12 patients with distant metastases, $[^{123}\text{I}]\text{MIBG}$ scintigraphy did not visualize these lesions. For detection of bone metastases, bone scintigraphy may sometimes be useful (53). In $[^{123}\text{I}]\text{MIBG}$ -negative metastases, we and others (29, 54–59) found the role of SRI to be complementary to that of $[^{123}\text{I}]\text{MIBG}$ scanning. In the present series SRI was able to localize 5 of 5 malignant PCCs and metastases in 7 of 8 patients, including 3 patients in whom $[^{123}\text{I}]\text{MIBG}$ scans were negative. These results seem to indicate that SRI is more sensitive in detecting metastatic PCCs than in localizing benign tumors (57). In a series of 12 malignant PCCs, 44% of PCC metastases were localized by SRI (56). Although autoradiographic (60) and immunohistochemical (61) studies have characterized different somatostatin receptor subtypes in PCCs, the therapeutic effects of octreotide in benign (62) and malignant PCCs (57) have been disappointing. In our series we have treated 3 patients with ^{111}In -labeled octreotide. All have shown progression of disease while being treated. Possibly, yttrium-labeled octreotide (63, 64) might be more useful in these cases.

Beierwaltes and co-workers advocate performing standard follow-up MIBG investigations after excision of the primary PCC (65). A routine postoperative MIBG scan might potentially detect metastatic disease, as it seems likely that

small deposits of PCC tissue in the near proximity of the main tumor are not revealed as long as the main tumor is *in situ*. In the group of benign tumors we performed 30 postoperative [¹²³I]MIBG scans after resection of the PCCs (data not shown in *Results*). In all but 2 cases, postoperative catecholamine levels were within the normal range at the time of imaging. These 2 cases (Table 4: patients 15 and 16) were subsequently operated upon for PCC recurrence. In addition, in 1 VHL and 2 neurofibromatosis patients, grade 2 contralateral hot spots were detected after unilateral adrenalectomy. To date, recurrence of increased concentrations of catecholamines has not occurred.

We conclude that the uptake of [¹²³I]MIBG is correlated with the size and epinephrine production of PCCs. Furthermore, [¹²³I]MIBG uptake is higher in sporadic, benign, intraadrenal, and unilateral PCCs, than in hereditary, malignant, extraadrenal, and bilateral PCCs, respectively. For functional characterization of catecholamine-secreting foci, whole body [¹²³I]MIBG scintigraphy has a complementary role to anatomical localization techniques. However, as patients with familial predisposition are commonly referred and operated in earlier stages of disease, the role of [¹²³I]MIBG scintigraphy in bilateral and MEN2A/2B-related PCCs seems to be limited. In cases of recurrent elevation of catecholamines, localization of metastases and/or recurrence should be attempted with [¹²³I]MIBG scintigraphy. In suspicious metastatic PCCs, SRI might be considered to supplement [¹²³I]MIBG scintigraphy.

Acknowledgments

We thank Ms. M. Seijbel and Mrs. S. van Belle for expert secretarial assistance.

References

- Remine WH, Chong GC, van Heerden JA, Sheps SG, Harrion EG. 1974 Current management of pheochromocytoma. *Ann Surg.* 179:740-748.
- van Heerden JA, Sheps SG, Hamberger B, Sheedy PF, Poston JG, Remine WH. 1982 Pheochromocytoma: current status and changing trends. *Surgery.* 91:367-373.
- Cullen ML, Staren E, Straus A, et al. 1985 Pheochromocytoma: operative strategy. *Surgery.* 98:927-930.
- Jalil ND, Pattou FN, Combemale F, et al. 1998 Effectiveness and limits of pre-operative imaging studies for the localisation of pheochromocytomas and paragangliomas: a review of 282 cases. *Eur J Surg.* 164:23-28.
- Bruining HA, Lamberts SWJ, Ong EG, van Seyen AJ. 1984 Results of adrenalectomy with various surgical approaches in the treatment of different diseases of the adrenal glands. *Surg Gynecol Obstet.* 158:367-369.
- Gagner M, Lacroix A, Prinz RA, et al. 1993 Early experience with laparoscopic approach for adrenalectomy. *Surgery.* 114:1120-1125.
- Bonjer HJ, Lange JF, Kazemier G, de Herder WW, Steyerberg EW, Bruining HA. 1997 Comparison of three techniques for adrenalectomy. *Br J Surg.* 84:679-682.
- Mercan S, Seven R, Ozarmagan S, Tezelman S. 1995 Endoscopic retroperitoneal adrenalectomy. *Surgery.* 118:1071-1076.
- Bonjer HJ, van der Harst E, Steyerberg EW, et al. 1998 Retroperitoneal adrenalectomy: open or endoscopic? *World J Surg.* 22:1246-1249.
- Latif F, Tory K, Gnarr J, et al. 1993 Identification of the von Hippel-Lindau disease tumor suppressor gene. *Science.* 260:1317-1320.
- Donis Keller H, Dou S, Chi D, et al. 1993 Mutations in the RET proto-oncogene are associated with MEN 2A and FMTC. *Hum Mol Genet.* 2:851-856.
- Mulligan LM, Kwok JB, Healey CS, et al. 1993 Germ-line mutations of the RET proto-oncogene in multiple endocrine neoplasia type 2A. *Nature.* 363:458-460.
- Wieland DM, Swanson DP, Brown LE, Beierwaltes WH. 1979 Imaging the adrenal medulla with an I-131-labeled antiadrenergic agent. *J Nucl Med.* 20:155-158.
- Morales JO, Beierwaltes WH, Counsel RE, Meier DH. 1967 The concentration of radioactivity from labeled epinephrine and its precursors in the dog adrenal medulla. *J Nucl Med.* 8:800-809.
- Bomanji J, Levison DA, Flatman WD, et al. 1987 Uptake of iodine-123 MIBG by pheochromocytomas, paragangliomas, and neuroblastomas: a histopathological comparison. *J Nucl Med.* 28:973-978.
- Lynn MD, Shapiro B, Sisson JC, et al. 1985 Pheochromocytoma and the normal adrenal medulla: improved visualization with I-123 MIBG scintigraphy. *Radiology.* 155:789-792.
- Bomanji J, Conry BG, Britton KE, Reznick RH. 1988 Imaging neural crest tumors with ¹²³I-metaiodobenzylguanidine and x-ray computed tomography: a comparative study. *Clin Radiol.* 39:506.
- Mozley PD, Kim CK, Moshin J, Gosfield E, Alavi A. 1994 The efficacy of iodine-123-MIBG as a screening test for pheochromocytoma. *J Nucl Med.* 35:1138-1144.
- Kwekkeboom DJ, van Urk H, Pauw BK, et al. 1993 Octreotide scintigraphy for the detection of paragangliomas. *J Nucl Med.* 34:873-878.
- Krenning EP, Kwekkeboom DJ, Pauwels S, Kvols LK, Reubi JC. 1995 Somatostatin receptor scintigraphy. In: Freeman LM, ed. *Nuclear medicine annual 1995.* New York: Raven Press; 1-50.
- van der Hoorn FAJ, Boomsma F, Man in't Veld AJ, Schalekamp MADH. 1989 Determination of catecholamines in human plasma by high performance liquid chromatography: comparison between a new method with fluorescence detection and an established method with electrochemical detection. *J Chromatogr.* 487:17-28.
- Schnakenburg KV, Muller M, Dorner K, Harms D, Schwarze EW. 1976 Congenital hemihypertrophy and malignant giant pheochromocytoma: a previously undescribed coincidence. *Eur J Pediatr.* 122:263-273.
- Sisson JC, Frager MS, Valk TW. 1981 Scintigraphic localization of pheochromocytoma. *N Engl J Med.* 305:12-17.
- Swanson DP, Carey JE, Brown LE. Human absorbed dose calculations for iodine 131 and iodine 123-labeled metaiodobenzylguanidine (MIBG): a potential myocardial and adrenal medulla imaging agent [Abstract]. *Proc of the 3rd Int Radiopharmaceutical Dosimetry Symp.* 1981; 213-224.
- Wieland DM, Brown LE, Tobes MC. 1981 Imaging the primate adrenal medulla with ¹²³I and ¹³¹I metaiodobenzylguanidine: concise communication. *J Nucl Med.* 22:358-364.
- Pattou FN, Combemale FP, Poirrette JF, et al. 1996 Questionability of the benefits of routine laparotomy as the surgical approach for pheochromocytomas and abdominal paragangliomas. *Surgery.* 120:1006-1011.
- van Gils AP, Falke TH, van Erkel AR, et al. MR imaging and MIBG scintigraphy of pheochromocytomas and extraadrenal functioning paragangliomas. *Radiographics.* 11:27-57.
- Wieland DM, Wu J, Brown LE. 1980 Radiolabeled adrenergic neuron-blocking agents: Adrenomedullary imaging with ¹³¹Iodobenzylguanidine. *J Nucl Med.* 21:349-353.
- Hoefnagel CA. 1995 MIBG and radiolabeled octreotide in neuroendocrine tumors. *Q J Nucl Med.* 39:137-139.
- Tobes MC, Jacques S, Wieland DM. 1985 Effect of uptake one inhibitors on the uptake of norepinephrine and metaiodobenzylguanidine. *J Nucl Med.* 26:897-907.
- Nguyen HH, Proye CA, Carnaille B, Combemale F, Pattou FN, Huglo D. 1999 Tumour size: the only predictive factor for ¹³¹I MIBG uptake in pheochromocytoma and paraganglioma. *Aust N Z J Surg.* 5:353.
- Shapiro B, Copp JE, Sisson JC. 1985 Iodine-131 metaiodobenzylguanidine for the localization of suspected pheochromocytoma. Experience in 400 cases. *J Nucl Med.* 26:576-585.
- Swensen SJ, Brown ML, Sheps SG, et al. 1985 Use of ¹³¹I]MIBG scintigraphy in the evaluation of suspected pheochromocytoma. *Mayo Clin Proc.* 60:299-304.
- Koizumi M, Endo K, Sakahara H, et al. 1986 Computed tomography and ¹³¹I]MIBG scintigraphy in the diagnosis of pheochromocytoma. *Acta Radiol [Diagn] (Stockh).* 27:305-309.
- Furuta N, Kiyota H, Yoshigoe F, Hasegawa N, Ohishi Y. 1999 Diagnosis of pheochromocytoma using [¹²³I]- compared with [¹³¹I]-etaiodobenzylguanidine scintigraphy. *Int J Urol.* 6:119-124.
- Sisson JC, Shulkin BL. 1999 Nuclear medicine imaging of pheochromocytoma and neuroblastoma. *Q J Nucl Med.* 43:217-223.
- Webb TA, Sheps SG, Carney JA. 1980 Differences between sporadic pheochromocytoma and pheochromocytoma in multiple endocrine neoplasia. *Am J Surg Pathol.* 4:121-126.
- Carney JA, Sizemore GW, Sheps SG. 1976 Adrenal medullary disease in multiple endocrine neoplasia, type 2. *Am J Clin Pathol.* 66:279-290.
- Kurihara K, Mizuseki K, Kondo T, Ohoka H, Mannami M, Kawai K. 1990 Adrenal medullary hyperplasia. Hyperplasia-pheochromocytoma sequence. *Acta Pathol Jpn.* 40:683-686.
- Qupty G, Ishay A, Peretz H, Dharan M, Kaufman N, Luboshitzky R. 1999 Pheochromocytoma due to unilateral adrenal medullary hyperplasia. *Clin Endocrinol (Oxf).* 47:613-617.
- Gough IR, Thompson NW, Shapiro B, Sisson JC. 1985 Limitations of ¹³¹I]MIBG scintigraphy in locating pheochromocytomas. *Surgery.* 98:115-120.
- Lairmore TC, Ball DW, Baylin SB, Wells SA. 1993 Management of pheochromocytomas in patients with multiple endocrine neoplasia type 2 syndromes. *Ann Surg.* 217:595-601.
- Sisson JC, Shapiro B, Beierwaltes WH, Copp JE. 1984 Locating pheochromocytomas, paragangliomas, and neuroblastomas: a histopathological comparison. *J Nucl Med.* 28:973-978.

- mocytomas by scintigraphy using ¹³¹I-metaiodobenzylguanidine. *Cancer*. 34:86–92.
44. **Shapiro B, Sisson JC, Lloyd R, Nakajo M, Satterlee W, Beierwaltes WH.** 1984 Malignant pheochromocytoma: clinical, biochemical and scintigraphic characterization. *Clin Endocrinol (Oxf)*. 20:189–203.
 45. **Maurea S, Lastoria S, Cuocolo A, Celentano L, Salvatore M.** 1995 The diagnosis of nonfunctioning pheochromocytoma. The role of I-123 MIBG imaging. *Clin Nucl Med*. 20:22–24.
 46. **Eisenhofer G, Keiser HR, Friberg P, et al.** 1998 Plasma metanephrines are markers of pheochromocytoma produced by catechol-*O*-methyltransferase within tumors. *J Clin Endocrinol Metab*. 83:2175–2185.
 47. **Ito Y, Obara T, Yamashita T, Kanbe M, Iihara M.** 1996 Pheochromocytomas: tendency to degenerate and cause paroxysmal hypertension. *World J Surg*. 20:923–926.
 48. **Lamberts SW, Reubi JC, Krenning EP.** 1993 Validation of somatostatin receptor scintigraphy in the localization of neuroendocrine tumors. *Acta Oncol*. 32:167–170.
 49. **de Jong M, Breeman WAP, Bakker WH, et al.** 1998 Comparison of ¹¹¹In-labelled somatostatin analogues for tumor scintigraphy and radionuclide therapy. *Cancer Res*. 58:437–441.
 50. **Krenning EP, de Jong M, Kooij PPM, et al.** 1999 Radiolabeled somatostatin analogue(s) for peptide receptor scintigraphy and radionuclide therapy. *Ann Oncol*. 10:523–529.
 51. **Whalen RK, Althausen AF, Daniels GH.** 1992 Extra-adrenal pheochromocytoma. *J Urol*. 147:1–10.
 52. **Stumvoll M, Fritsche A, Pickert A, Overkamp D.** 1997 Features of malignancy in a benign pheochromocytoma. *Horm Res*. 48:135–136.
 53. **Lynn MD, Braunstein EM, Wahl RL, Shapiro B, Gross MD, Rabbani R.** 1986 Bone metastases in pheochromocytoma: comparative studies of efficacy of imaging. *Radiology*. 160:701–706.
 54. **Tenenbaum F, Lumbroso J, Schlumberger M, et al.** 1995 Comparison of radiolabeled octreotide and meta-iodobenzylguanidine (MIBG) scintigraphy in malignant pheochromocytoma. *J Nucl Med*. 36:1–6.
 55. **Steinert H, Lehnert H, Bockisch A, Beyer J, Hahn K.** 1993 Detection of malignant pheochromocytoma tumor sites by ¹¹¹In-octreotide scintigraphy. *Eur J Nucl Med*. 20:843.
 56. **Kopf D, Bockisch A, Steinert H, et al.** 1997 Octreotide scintigraphy and catecholamine response to an octreotide challenge in malignant pheochromocytoma. *Clin Endocrinol (Oxf)*. 46:39–44.
 57. **Maurea S, Lastoria S, Caraco C, et al.** 1996 The role of radiolabeled somatostatin analogs in adrenal imaging. *Nucl Med Biol*. 23:677–680.
 58. **Limouris GS, Giannakopoulos V, Stavraka A, Toubanakis N, Vlahos L.** 1997 Comparison of In-111 pentetreotide, Tc-99m (V)DMSA and I-123 MIBG scintigraphy in neural crest tumors. *Anticancer Res*. 17:1589–1592.
 59. **Lastoria S, Maurea S, Vergara E, et al.** 1995 Comparison of labeled MIBG and somatostatin analogs in imaging neuroendocrine tumors. *Q J Nucl Med*. 39:145–149.
 60. **Epelbaum J, Bertherat J, Prevost G, et al.** 1995 Molecular and pharmacological characterization of somatostatin receptor subtypes in adrenal, extra-adrenal, and malignant pheochromocytomas. *J Clin Endocrinol Metab*. 80:1837–1844.
 61. **Hofland LJ, Liu Q, Van Koetsveld PM, et al.** 1999 Immunohistochemical detection of somatostatin receptor subtypes sst1 and sst2A in human somatostatin receptor positive tumors. *J Clin Endocrinol Metab*. 84:775–780.
 62. **Plouin PF, Bertherat J, Chatellier G, et al.** 1995 Short-term effects of octreotide on blood pressure and plasma catecholamines and neuropeptide Y levels in patients with pheochromocytoma: a placebo-controlled trial. *Clin Endocrinol (Oxf)*. 42:289–294.
 63. **Otte A, Herrmann R, Heppeler A, et al.** 1999 Yttrium-90 DOTATOC: first clinical results. *Eur J Nucl Med*. 26:1439–1447.
 64. **Otte A, Mueller-Brand J, Dellas S, Nitzsche EU, Herrmann R, Maecke HR.** 1998 Yttrium-90-labelled somatostatin-analogue for cancer treatment. *Lancet*. 351:417–418.
 65. **Beierwaltes WH.** 1987 Update on basic research and clinical experience with metaiodobenzylguanidine. *Med Pediatr Oncol*. 15:163–169.