

ON THE LE FORT III OSTEOTOMY

Erik Nout

The research presented in this thesis was done at:

The department of Oral and Maxillofacial Surgery of the Erasmus University Medical Centre Rotterdam.

The Craniofacial Unit of the Sophia Children’s Hospital, Erasmus University Medical Centre Rotterdam.

The department of Medical Informatics, Faculty of Medicine, Erasmus University Medical Centre Rotterdam.

Financial support for this thesis was provided by:



J.E. Jurriaanse
Stichting



Printed by: Optima Grafische Communicatie, Rotterdam, The Netherlands.

Cover design: Optima Grafische Communicatie, Rotterdam, The Netherlands and E. Nout using Dolphin

Imaging 3D software. Editing by Drs. B.W.J. Mickers.



ISBN: 978-90-8559-081-1

All the images and photographs used in this thesis are of actual patients of the studies. Written consent was obtained from each patient prior to the inclusion of their images and photographs in this thesis.

©2010 E. Nout. All rights reserved. No part of this publication may be reproduced, stored in a retrieval system, or transmitted, in any form or by any means, electronic, mechanical, photocopying, recording, or otherwise, without the prior permission in writing from the proprietor.

ON THE LE FORT III OSTEOTOMY

OVER DE LE FORT III OSTEOTOMIE

Proefschrift

ter verkrijging van de graad van doctor aan de
Erasmus Universiteit Rotterdam
op gezag van de rector magnificus

Prof.dr. H.G. Schmidt

en volgens besluit van het College voor Promoties.

De openbare verdediging zal plaatsvinden op
vrijdag 19 november 2010 om 11.30 uur

door

Erik Nout

geboren te Terneuzen



PROMOTIECOMMISSIE

Promotor Prof.dr. K.G.H. Van der Wal

Overige leden Prof.dr. L. Feenstra
 Prof.dr. S.E.R. Hovius
 Prof.dr. D. Tibboel

Copromotoren Dr. J.F. Veenland
 Dr. E.B. Wolvius

AANVULLENDE LEDEN GROTE COMMISSIE

Prof.dr. A.F. Ayoub

Prof.dr. H.P.M. Freihofer

PARANYMFEN

Drs. F.F.M. Meijler

Drs. P.J.T.S. van Winterswijk

Drummers don't write - or at least, that's what everybody believes.

~Tony Williams

Saskia

"Als jij thuis bent, is thuisblijven mijn hobby."

~Herman Brusselmans

CONTENTS

List of Abbreviations		XI
Prologue and aim of the study		1
Part I	General introduction	13
Chapter 1	Advancement of the midface, from conventional Le Fort III osteotomy to Le Fort III distraction: review of the literature <i>Int J Oral Maxillofac Surg. 2008 Sep;37(9):781-9 Invited review</i>	15
Part II	Fundamental studies	39
Chapter 2	Orbital change following Le Fort III advancement in syndromic craniosynostosis: quantitative evaluation of orbital volume, infra-orbital rim and globe position <i>J Craniomaxillofac Surg, submitted</i>	41
Chapter 3	Three dimensional airway changes after Le Fort III advancement in syndromic craniosynostosis patients <i>Plast Reconstr Surg. 2010 Aug;126(2):564-71</i>	57
Part III	Clinical studies	73
Chapter 4a	Upper airway changes in syndromic craniosynostosis patients following midface or monobloc advancement: correlation between volume changes and respiratory outcome <i>J Craniomaxillofac Surg, submitted</i>	75
Chapter 4b	Obstructive sleep apnea in children with syndromic craniosynostosis: long-term respiratory outcome of midface advancement <i>Int J Oral Maxillofac Surg. 2010 Feb;39(2):115-21</i>	89

Chapter 5	Orthognathic surgery following LF III or monobloc advancement <i>Int J Oral Maxillofac Surg, submitted</i>	105
Chapter 6	Complications in maxillary distraction using the RED II device: a retrospective analysis of 21 patients <i>Int J Oral Maxillofac Surg. 2006 Oct;35(10):897-902</i>	119
Part IV	Auxillary study	135
Chapter 7	Internal carotid dissection after Le Fort III distraction in Apert syndrome: a case report <i>J Craniomaxillofac Surg. 2010 Mar 18. [Epub ahead of print]</i>	137
Part V	General Discussion	151
Chapter 8	General discussion and conclusions	153
Chapter 9	Epilogue and future perspectives	163
	Summary	169
	Dutch summary (Nederlandse samenvatting)	177
	PhD Portfolio	185
	Acknowledgement (Dankwoord)	191

ABBREVIATIONS

2D	two-dimensional
3D	three-dimensional
A	A-point
AHI	apnea-hypopnea index
ANB	sella-nasion-subspinale-sella-nasion-supramentale angle
ANS	anterior nasal spine
BSSO	bilateral sagittal split osteotomy
CFD	craniofacial dysostosis
CLAP	cleft-lip-alveolus-palate
CPAP	continuous positive airway pressure
CT	computed tomography
CTA	CT-angiography
DO	distraction osteogenesis
ICC	intra-class correlation coefficient
ICP	intracranial pressure
LF	Le Fort
LSCC	lateral semicircular canal
MB	monobloc
Na	Nasion
NMD	nasomaxillary dysplasia
NPA	nasopharyngeal airway
NPT	nasopharyngeal tube
ODI	oxygen-desaturation index
OR	orbital roof
OSAS	obstructive sleep apnea syndrome
PAS	pharyngeal airway space
PSG	polysomnography
RED	rigid external distractor
RSP	röntgen schedel profiel foto
S	sella turcica
SARME	surgically assisted rapid maxillary expansion
SCS	syndromic craniosynostosis
sd	standard deviation

VO vestibular orientation

VR virtual reality

Prologue and aim of the study

E. Nout

THE STARTING POINT

Although presently the LF III osteotomy is applied in many craniofacial centres around the world, the preceding surgical evolution is characterized by a history of careful gradual extension of established surgical techniques adapted from early orthognathic interventions.⁴ Considering the origin of orthognathic surgery, osteotomies were initially conducted as access-surgery. Von Langenbeck described the use of horizontal osteotomies for the first time in 1859 and used this technique in 1861 in a patient to resect an osteoplastic maxilla.^{14, 15} His pioneering efforts were followed by colleagues all over the world, which led to the development of various modifications and new techniques.^{5, 8, 16, 21, 22, 25} Later, Cheever developed horizontal osteotomy-techniques to temporarily bring the entire maxilla down to increase visibility of the nasopharyngeal area to make it possible to resect local tumours (**figure 1**).⁵ displacement, and subsequent replacement and reunion of the superior maxillary bone. In his efforts of depressing the maxilla to expose the operating field, Cheever founded the downfracture-technique and most likely was the first to report direct interosseous wiring for maxillary fixation. In 1893, Lanz published a maxillary approach to reach the pituitary fossa.¹⁶ For this purpose, it was necessary to expand the osteotomy-lines in a sagittal way as well, making it possible to retract the two maxilla halves. To provide enough access, Lanz cut the upper lip in the midline. Later, in 1898, Partsch modified the Lanz technique by using an intraoral incision instead of the radical extraoral incision.²¹ In 1901 Rene Le Fort published his cadaver-studies in which he exerted blunt forces from various intensities and directions on human skulls to detect 'natural' fracture

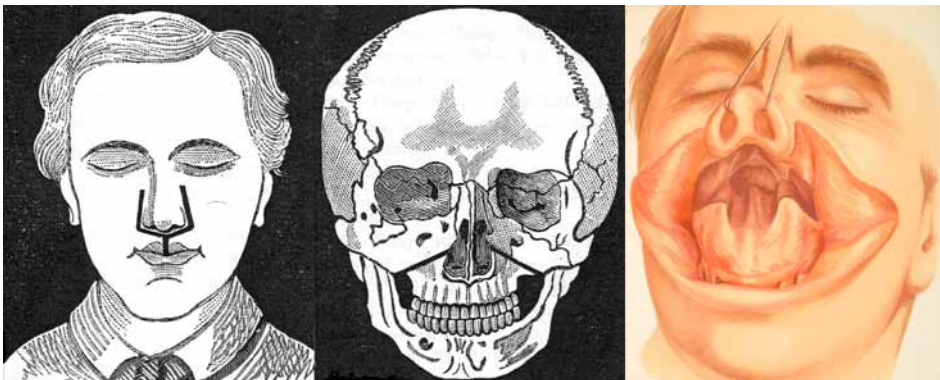


Figure 1: Cutaneous incisions (left), osteotomies (middle) and intraoperative view (right) of Cheever's operation.

lines (**figure 2**).³⁰ His work gave rise to a system of classifying facial fractures, the LF I, II and III fractures. In spite of the fact that the system represents an oversimplification of maxillary fractures, the work of Rene Le Fort formed the basis for the development of craniofacial surgery; his work inspired surgeons throughout the world to start correcting malpositions of the midface. In 1921, Cohn-Stock performed the first anterior maxillary osteotomy to maxillary protrusion in two cases, making him the first one to describe the LF I osteotomy for the correction of midface deformities.⁶ He mobilized the anterior maxilla en-bloc in two separate sessions, in this way minimizing the risk of major complications (such as bleeding, necrosis and loss of teeth). His approach is the starting point for the development of new techniques as demonstrated by the work of Wassmund (**figure 3**). In 1927, Wassmund successfully managed to perform a LF I osteotomy to correct an open bite in one session, being the first one to use the LF I technique for an orthognathic indication.³¹ Besides the contribution of Wassmund, other modifications on the technique of Cohn-Stock have been described.^{9, 10, 12, 33} Major contributions to the development of the LF I osteotomy came from Axhausen in 1934, who performed the first total osteotomy of the maxilla with immediate repositioning.¹ Later, Schuchardt pioneered in separating the maxilla from the pterygoid bone in 1942 to increase the advancement and ease of movement of the maxilla.²³ By applying orthopaedic forces onto the maxilla repositioning was accomplished, but relapse occurred frequently. Research from that point on focused on finding ways to reduce the relapse.^{2, 7, 24, 32} Obwegeser, in 1965, introduced a surgical method in which

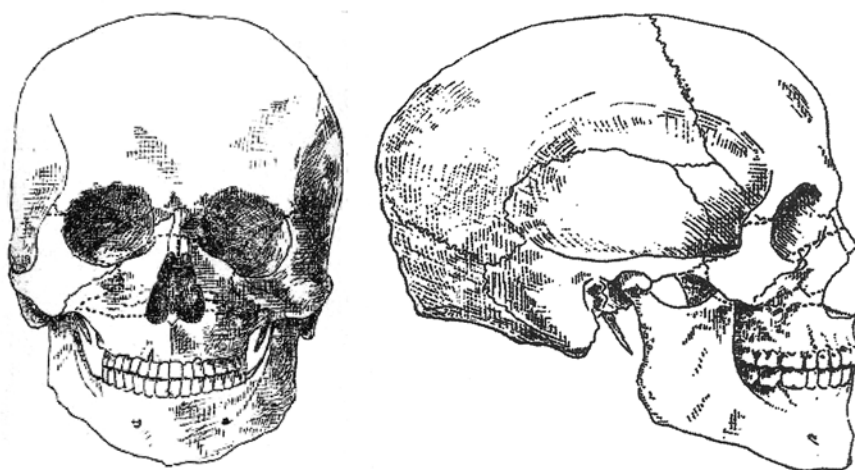


Figure 2: Le Fort's 'great lines of weakness' in the face and the fragments which they circumscribe in frontal (left) and sagittal (right) view.

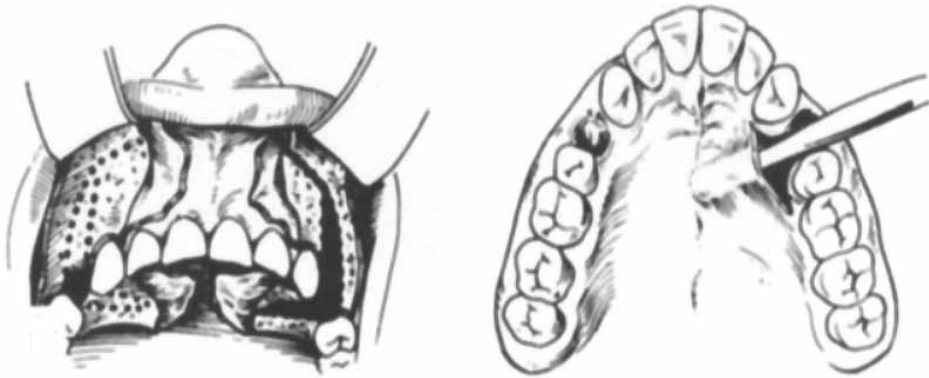


Figure 3: Wassmund's procedure for the correction of maxillary protrusion.

he completely mobilized the maxilla, rendering tension-free repositioning without the former tissue-resistance.¹⁷ Furthermore, he reported a simultaneous mobilization of the upper and lower jaw in 1970: the bimaxillary osteotomy, a major breakthrough in craniofacial surgery.¹⁸ It is because of Obwegesers' extensive descriptions of surgical techniques on the LF I level and the experimental and anatomical studies from Bell that the LF I operation has become a standard procedure in modern craniofacial surgery.^{3, 17, 19} As the experience with the LF I osteotomy grew, variations on this modality were developed, such as the high LF I and Kuffner osteotomy.¹³ These osteotomies were indicated in patients with dish-face deformities to correct the entire midface instead of solely correcting malocclusions. Patients with SCS suffer from severe midface hypoplasia due to intrinsic factors causing synostosis of the cranial sutures. In order to treat these patients, with the increased surgical experience in treatment of trauma of the midface during World War II, alteration of the aforementioned osteotomies were carried out based on the traditional fracture patterns described by Rene Le Fort. Mobilization of the midface at LF III level was first carried out in 1950 to correct a case with prognathism and exorbitism.¹¹ Since then, many surgeons have suggested improvements on the surgical technique. The French surgeon Paul Tessier has turned these previous case-based reports into routine research by advocating his experience in large patient numbers (**figure 4**).²⁶⁻²⁹ Furthermore, Tessier's ongoing fascination in the surgical treatment of craniosynostosis syndromes inspired him to expand his surgical craniofacial inventions even further. He started to perform advancement of the midface (LF III level) simultaneous with frontal bone advancement in adult patients.²⁷ As these interventions require a transcranial approach (craniectomy), these surgeries

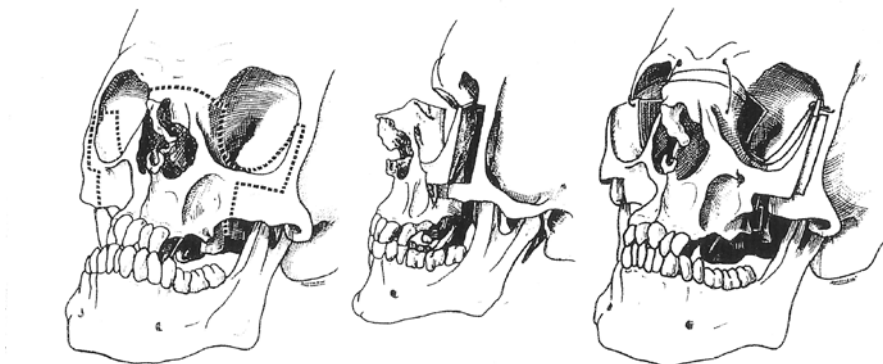


Figure 4: Tessier's LF III advancement through a subcranial approach. On the left the lines of osteotomy are depicted. In the middle the situation after advancement of the midface is visualised and on the right fixation of the segment by wires and bone grafts is shown.

were in collaboration with a neurosurgeon. However, due to the inability of the adult brain to expand into the retrofrontal "dead space", inadequate re-vascularisation of the frontal bone led to sequestration and infection of the frontal bone segment in four patients. As a result this approach was abandoned. In 1978 Ortiz-Monasterio et al. renewed the interest by publishing their experiences on the MB intervention plus advancement and reshaping of the frontal area in five children and two adults with Crouzon's disease to correct class III malocclusion as well as exorbitism (**figure 5**).²⁰ Their results were satisfactory besides partial resorption of the frontal bone in one adult patient. Ortiz-Monasterio et al. stated that the preferred age of performing this intervention is around five years. Based on these promising results Tessier began to use the procedure again, now in children, with satisfying results. Due to Tessier's excellent research and ongoing reports concerning the surgical technique, the LF III and MB osteotomy became standardized and accepted worldwide as a treatment modality for midface hypoplasia in selected patients.

THIS THESIS

Although the LF III advancement is a common treatment modality, several aspects remain unclear or inconclusive. As patients with SCS are rare, publications are often limited to small numbers or case reports instead of analyzing large patient numbers.

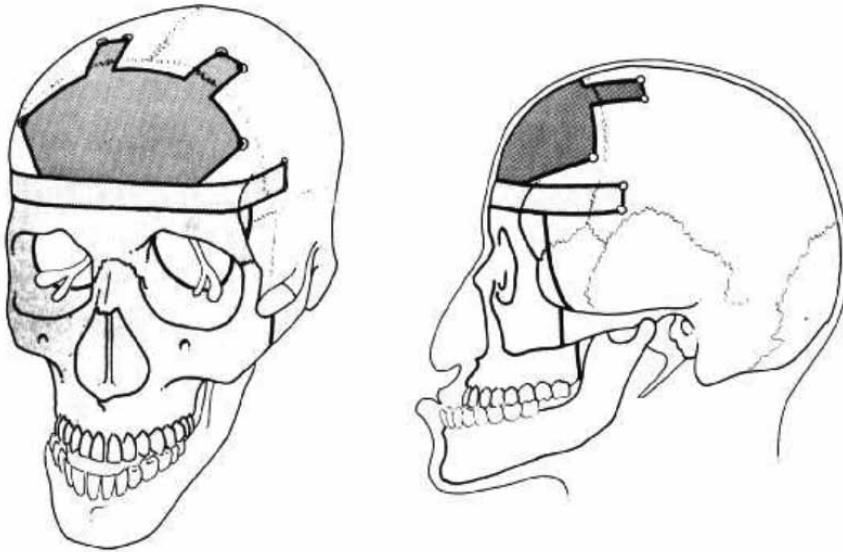


Figure 5: The one-piece orbito-facial bloc according to Ortiz-Monasterio.

Therefore, distorted/biased ideas concerning the optimal treatment protocol for these complex patients are likely to occur. The aims of this thesis are threefold. First, we hope to gain insight in the anatomical changes that are induced by LF III advancement at the level of the orbits and upper airway. Second, we aim to evaluate the clinical effects of the induced anatomical changes with respect to the respiratory and orthognathic outcome. Third, we aim to define the limits of the technique by analyzing complications. In this thesis we tried to address these multiple aspects associated with midface advancement in the relatively large patient cohort of the craniofacial unit of the Erasmus Medical Centre Rotterdam, Sophia Childrens Hospital Rotterdam by sharing our experience in the treatment of patients with SCS. This thesis is divided into five parts, and contains one invited review, six original articles and one case-report.

In part I the general introduction is incorporated, describing the development of the LF III osteotomy.

A review of the literature addresses the history of the LF III osteotomy and the initiation of LF III DO (chapter one). Fundamental questions concerning the indication, timing, stability, growth and relapse of LF III advancement are reviewed. The conventional LF III osteotomy is weighted against the more recent reports about LF III DO. The (dis-)advantages of both internal and external distractors are compared.

Part II addresses the quantification of effects of LF III advancement on the anatomy of SCS patients relating to two indications for LF III advancement: exorbitism and OSAS. An absolute indication to perform the LF III advancement in patients with SCS is severe exorbitism that can threaten the eye. Clinical studies have observed an anterior movement of the infra-orbital rim after LF III advancement, but there are no reports of fundamental studies regarding this subject. Therefore, the influence of LF III advancement on orbital volume and position of the infra-orbital rim and globe was investigated (chapter two). A reference frame was developed and also evaluated which allowed for inter-patient comparisons.

OSAS is a highly prevalent disease and is characterized by recurrent episodes of upper airway obstructions and nocturnal oxygen desaturations. Due to the serious clinical consequences, OSAS requires treatment (chapter one). The aetiology of the compromised airway patency in patients with OSAS is complex and known to be multifactorial. Among others, airway patency is known to be dependent of the difference between extra- and intraluminal pressure, the intraluminal pressure drop, length and radius of the airway and the nature of the airflow (laminar or turbulent flow). Anatomic factors, such as (adeno-)tonsillar hypertrophy, enlarged tongue, increased peripharyngeal fat and decreased dilator muscle quantity due to obesity, retroposition of the mandible and/or hyoid bone, resulting in a relative large tongue base volume have been shown to decrease the airway patency. Patients with SCS are often prone to severe OSAS due to the syndrome-related severe midface hypoplasia; therefore severe OSAS is one of the pressing indications to perform LF III advancement. In general, clinically the LF III advancement in SCS patients shows a positive influence on the outcome of OSAS. In literature, these outcomes have been linked to enlargement of the upper airway. For now, it is unclear to what extent LF III advancement influences the intrinsic upper airway volume. In order to contribute to comprehend more of the aetiology of OSAS, the upper airway volumes in SCS patients before and after LF III advancement were evaluated and correlated to the degree of advancement of the midface (chapter three). A 3D segmentation method was developed to measure upper airway volumes using CT-scan data and this was applied to the patient cohort. Chapter three also addresses the evaluation of this new method, which was used in the clinical studies of this thesis.

In part III, four clinical studies are presented dealing with OSAS, orthognathic outcome and complications respectively.

Concerning the severity of OSAS in SCS patients, functional and physical impairment is likely to occur (chapter one). To assess the outcome of OSAS after midface advancement, two studies were carried out. To assess the correlation between midface advancement and the short-term postoperative change in respiratory outcome a clinical retrospective study was undertaken and described in chapter 4a. In this study, the pre- and postoperative respiratory measurements of ten SCS patients were evaluated after LF I, LF III and MB advancement. In chapter 4b the long-term outcome of OSAS after midface advancement is retrospectively evaluated in eleven SCS patients. Also predictive factors of respiratory outcome are identified in these SCS patients. Does midface advancement decrease OSAS on the short and/or long term?

Debate exists whether LF III or MB advancement can be looked upon as a definite orthognathic procedure. In chapter five, a retrospective analysis was performed of all SCS patients who underwent either LF III or MB advancement in a ten-year time frame. The incidence of additional orthognathic surgery was scored and retrospectively evaluated. Is midface advancement a definite treatment or is additional orthognathic surgery indicated?

In chapter six a retrospective clinical evaluation of SCS patients was performed that focuses on the problems and complications of the use of the haloframe as external distraction device for LF III advancement. Based on the outcomes of the analysis, recommendations were formulated to reduce the incidence of complications associated with the use of haloframes in SCS patients. Can halo-related complications be prevented?

Part IV consists of a sole case report that describes a lethal outcome after LF III osteotomy and positioning of internal and external distraction devices in a patient with Apert syndrome (chapter seven). Due to the importance of this case report, it was decided to incorporate this finding in the present thesis. The surgical complications of LF procedures in patients with complex SCS are discussed. Recommendations are given to, hopefully, avoid these complications.

Finally, in Part V, chapter eight comprises the general discussion of this thesis. In chapter nine the work is evaluated and recommendations concerning future research are postulated.

REFERENCES

1. Axhausen G. Zur Behandlung veralteter disloziert verheilte Oberkieferbrüche. Dtsch Zahn-, Mund- u Kieferheilk 1934: 1: 334.
2. Axhausen G. [Problems and results of surgical orthodontology.] Aufgaben und Leistungen der operativen Kieferorthopädie. Fortschr Kieferorthop 1952: 13: 24-36.
3. Bell WH. Revascularization and bone healing after anterior maxillary osteotomy: a study using adult rhesus monkeys. J Oral Surg 1969: 27: 249-255.
4. Brouns JJA. Thesis: Osteotomies of the midfacial skeleton. 1992.
5. Cheefer D. Nasopharyngeal polypus, attached to the basilar process of occipital and body of the sphenoid bone successfully removed by a section, displacement, and subsequent replacement and reunion of the superior maxillary bone. Boston Med Surg J 1867: 8: 162.
6. Cohn-Stock G. Die chirurgische Immediatregulierung der Kiefer, speziell die chirurgische Behandlung der Prognathie. Viertelj schr Zahnheilk 1921: 3: 320.
7. Converse JM, Shapiro HH. Treatment of developmental malformations of the jaws. Plast Reconstr Surg 1952: 10: 473-510.
8. Cunningham G. Methode sofortiger Regulierung von anomalen Zahnstellungen. Österr Vjschr Zahnheilkd 1894: 19: 455.
9. Cupar I. [Surgical treatment of alterations in form and position of the maxilla.] Die chirurgische Behandlung der Form- und Stellungsveränderungen des Oberkiefers. Osterr Z Stomatol 1954: 51: 565-577.
10. Epker BN. A modified anterior maxillary osteotomy. J Maxillofac Surg 1977: 5: 35-38.
11. Gillies H, Harrison SH. Operative correction by osteotomy of recessed malar maxillary compound in a case of oxycephaly. Br J Plast Surg 1950: 3: 123-127.
12. Kole H. Surgical operations on the alveolar ridge to correct occlusal abnormalities. Oral Surg Oral Med Oral Pathol 1959: 12: 515-529 concl.
13. Kufner J. Four-year experience with major maxillary osteotomy for retrusion. J Oral Surg 1971: 29: 549-553.
14. Langenbeck B. Beitrag zur Osteoplastik – Die osteoplastische Resektion des Oberkiefers. Götschen A (Hrsg) Deutsche Klinik. Reimer, Berlin, 1859.
15. Langenbeck B. Die Uranoplastik. Arch Klin Chir 1861: 2: 252.
16. Lanz O. Osteoplastische Resektion beider Oberkiefer nach Kocher. In: Lucke R, Vogel (ed). Deutsche Zeitschrift für Chirurgie. Leipzig, 1893.
17. Obwegeser H. [Surgery of the Maxilla for the Correction of Prognathism.] Eingriffe Am Oberkiefer Zur Korrektur Des Progenen Zustandsbildes. SSO Schweiz Monatsschr Zahnheilkd 1965: 75: 365-374.
18. Obwegeser H. [The one time forward movement of the maxilla and backward movement of the mandible for the correction of extreme prognathism] Die einzeitige Vorbewegung des Oberkiefers und Ruckbewegung des Unterkiefers zur Korrektur der extremen "Progenie". SSO Schweiz Monatsschr Zahnheilkd 1970: 80: 547-556.
19. Obwegeser HL. Surgical correction of small or retrodisplaced maxillae. The "dish-face" deformity. Plast Reconstr Surg 1969: 43: 351-365.
20. Ortiz-Monasterio F, del Campo AF, Carrillo A. Advancement of the orbits and the midface in one piece, combined with frontal repositioning, for the correction of Crouzon's deformities. Plast Reconstr Surg 1978: 61: 507-516.
21. Partsch C. Eine neue Methode temporärer Gaumen-Resektion. Arch Klin Chir 1898: 57: 847.

22. Pincus W. Beitrag zur Klinik und Chirurgie des Nasen-Rachenraumes. Arch Klin Chir 1907: 82: 110.
23. Schuchardt K. Ein Beitrag zur chirurgischen Kieferorthopädie unter Berücksichtigung ihrer Bedeutung für die Behandlung angeborener und erworbener Kieferdeformitäten bei Soldaten. Dtsch Zahn-, Mund- u Kieferheilk 1942: 9: 73.
24. Schuchardt K. [Surgery as an aid to orthodontics.] Die Chirurgie als Helferin der Kieferorthopädie. Fortschr Kieferorthop 1954: 15: 1-25.
25. Talbot W. A case of double resection of the mandible. Dent Cosmos 1896: 49: 1002.
26. Tessier P. [Total facial osteotomy. Crouzon's syndrome, Apert's syndrome: oxycephaly, scaphocephaly, turriccephaly] Osteotomies totales de la face. Syndrome de Crouzon, syndrome d'Apert: oxycephalies, scaphocephalies, turriccephalies. Ann Chir Plast 1967: 12: 273-286.
27. Tessier P. The definitive plastic surgical treatment of the severe facial deformities of craniofacial dysostosis. Crouzon's and Apert's diseases. Plast Reconstr Surg 1971: 48: 419-442.
28. Tessier P. Relationship of craniostenoses to craniofacial dysostoses, and to faciostenoses: a study with therapeutic implications. Plast Reconstr Surg 1971: 48: 224-237.
29. Tessier P. Total osteotomy of the middle third of the face for faciostenosis or for sequelae of Le Fort 3 fractures. Plast Reconstr Surg 1971: 48: 533-541.
30. Tessier P. The classic reprint. Experimental study of fractures of the upper jaw. I and II. Rene Le Fort, M.D. Plast Reconstr Surg 1972: 50: 497-506 contd.
31. Wassmund M. Chirurgie des Mundes und der Kiefer. Leipzig: Meusser, 1935: 282.
32. Willmar K. On Le Fort I osteotomy; A follow-up study of 106 operated patients with maxillofacial deformity. Scand J Plast Reconstr Surg 1974: 12: suppl 12:11-68.
33. Wunderer S. Die Prognathieoperation mittels frontal gestieltem Maxillafragment. Österreich Z Stomatol 1962: 59: 98.

distraction

LF

Maxillary



Review

Craniofacial Midface

Part I

General Introduction

Chapter 1

Advancement of the midface, from conventional Le Fort III osteotomy to Le Fort III distraction: review of the literature

E. Nout¹

L.L.M. Cesteleyn¹

K.G.H. van der Wal¹

L.N.A. van Adrichem²

I.M.J. Mathijssen²

E.B. Wolvius¹

¹Department of Oral and Maxillofacial Surgery, Erasmus University
Medical Centre Rotterdam

²Department of Plastic and Reconstructive Surgery, Erasmus
University Medical Centre Rotterdam

Published

Int J Oral Maxillofac Surg. 2008 Sep;37(9):781-9 Invited review

ABSTRACT

Since its introduction in about 1950, the LF III procedure has become a widely accepted treatment for correction of midface hypoplasia and related functional and esthetic problems. As long-term surgical experience grows and improvements are made in technique, equipment and peri-operative care, the number of LF III procedures performed worldwide is increasing. A number of fundamental questions concerning the technique remain unclear, and large and/or conclusive studies are lacking owing to the relative rarity of severe midface hypoplasia. This literature review aims to address problems, such as the indication field, timing of surgery, rate of relapse and the use of DO. An overview of the history and technique of LF III osteotomy and distraction is provided, together with a comprehensive review of the available clinical data.

INTRODUCTION

Since Rene Le Fort published his landmark studies on fractures of the human skull in 1901⁹³, the Le Fort classification has been generally accepted and shown to be indispensable in craniofacial surgery. Today, mobilization of the midface is performed along the principles set down more than a century ago. The classic LF III osteotomy, derived from this classification and described by Tessier, has been applied to craniofacial patients since 1967⁸⁹. Initially, LF III osteotomy was limited to the correction of functional and esthetical problems in patients with severe forms of CFD syndromes, mainly owing to the intra-operative strain and the probability of relapse and serious postoperative complications. Today, with increased surgical experience, improved pediatric anesthesiology, broader indication-range, the introduction of distraction osteogenesis in craniofacial surgery and more clinical data reflecting long-term evaluation, the number of LF III osteotomies and distractions performed increases. Owing to the rarity of patients with CFD, their numbers in clinical studies are small. By reviewing clinical data on LF III osteotomies and distractions the aim is to provide more insight into problems related to indications, surgical technique and relapse.

HISTORY

Conventional LF III osteotomy

Owing to the increasing success and experience achieved with LF I osteotomy, attention in the 1950s was turned to developing surgical techniques to cope with hypoplastic midface and/or aberrant skull shapes, such as those seen in patients with CFD syndromes. In this respect Gillies' reports were breaking new ground. In 1941, as a military surgeon Gillies performed a refracture of a badly healed traumatic LF III fracture³². Nine years after this initial attempt, he pioneered LF III osteotomy in a patient with oxycephaly³¹. The indication of this procedure was marked prognathism and exophthalmus. He mobilized the entire midface, achieved rigid fixation with intermaxillary wiring and maintained this for 5 weeks. Although the operation was successful and esthetically beneficial, considerable relapse, resulting scars overlying the nasomaxillar and frontomalar junctions and damage to the lacrimal apparatus was noted. Paul Tessier, a French plastic surgeon, operated on 35 patients with various CFD syndromes and standardized the procedures for surgical treatment of many

types of deformities^{89-92, 94}. His aims were to restore a normal projection of the facial mass and to re-establish normal dental occlusion; to increase the vertical dimensions of the face; and to correct exorbitism. He stated that reasons for craniofacial surgery could be functional, morphological or psychological. Besides these techniques and recommendations, he also formulated warnings after he encountered complications. Concerning the LF III procedure Tessier described three basic procedures in which the operative risk is reduced to a minimum: the LF III-Tessier I⁸⁹, LF III-Tessier II^{90, 91} and LF III-Tessier III procedures^{70, 80}. These three types of osteotomies are similar and display only small variations with respect to the lateral orbital wall.

In 1969, Obwegeser published an overview of various Le Fort-fracture operations, including the combination of a LF III and a LF I osteotomy in one operation and a modified LF III technique excluding the nasal bones, the "butterfly osteotomy"^{69, 9}. With the suggested techniques it became possible to correct unequal dysmorphia of the upper and lower half of the facial skeleton. Obwegeser suggested opening of the maxillary arch simultaneous with the combination-osteotomy, in case widening of the LF I segment might be necessary to correct the dysmorphia. In 1971, Converse et al. reported another modification, the "tripartite osteotomy", a surgical technique which divides the entire midface in three segments: one central nasomaxillary segment and two orbitozygomatico segments, each separately mobile in a sagittal as well as a transverse or vertical direction¹⁸. All these modifications aimed to give more remodeling options and thus better esthetic results. Important research into combination osteotomies, together with bimaxillary corrections, was continued by Freihofner among others²⁷.

The basic LF III operation is now established, although minor modifications on the surgical technique are still being reported^{23, 49, 59, 66}.

History of DO

In 1993, Cohen et al. were the first to apply the DO technique to the midface in a 4-month-old boy with unilateral craniofacial microsomia and anophthalmia¹⁷. In their report they used a buried (intraoral) system of miniature distraction devices that permitted maxillary, orbital, and mandibular distraction on the LF III level. Since then, several reports have been published dealing with DO on the LF III level^{2, 7, 11, 13, 15, 38, 48, 75}. As experience grew with the technique, research has focused on developing new internal and external devices and optimizing DO protocols. An overview is provided in the Surgical technique section below.

INDICATIONS

Advancement of the midface on the LF III level is indicated in those syndromes that include midface hypoplasia involving the nasal and zygomatic complex and bony orbits, for example the Crouzon, Apert and Pfeiffer syndromes⁷⁸ (**figure 1**). Midface hypoplasia presents with several clinical problems, most notably at the level of the airway, orbits, occlusion and facial esthetics with their associated psychosocial problems. CFD patients are at high risk for upper airway obstruction and undetected OSAS. Almost 50% of CFD patients will develop OSAS and need airway intervention at some time^{6, 40, 74}. OSAS can be treated pharmacologically, non-surgically (nocturnal oxygen, CPAP, NPT) or surgically depending on its severity and cause^{1, 39}. The standard surgical procedure to alleviate severe and/or acute airway obstruction is tracheostomy, which is used in 17-50 % of CFD patients^{72, 83}.

Major complications occur in nearly 7% of all pediatric tracheostomy procedures in the early postoperative phase and in nearly 5% of procedures in the late postoperative phase⁸⁷. CFD patients are also at higher risk for other airway abnormalities, notably tracheal cartilaginous sleeve, laryngomalacia, tracheomalacia, and bron-

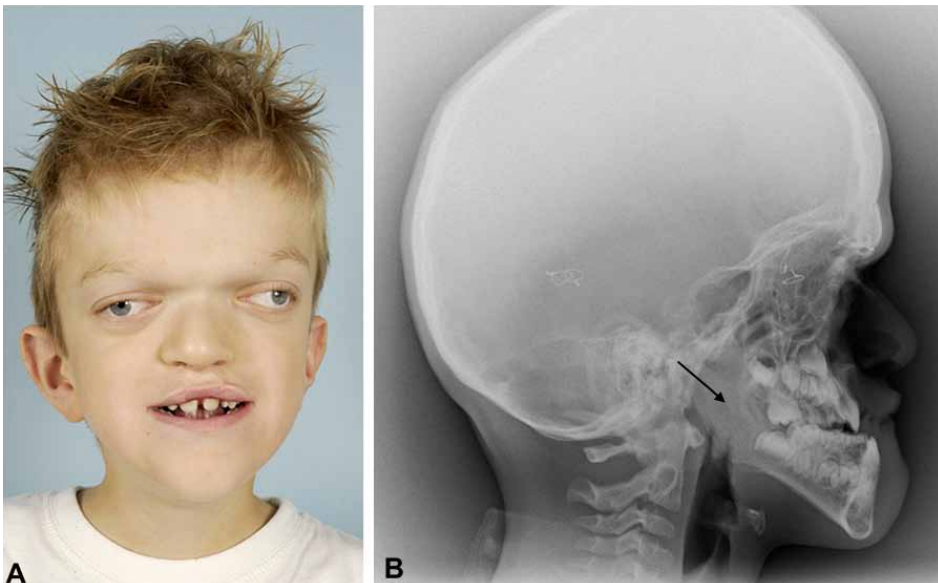


Figure 1: (A) An 8-year-old patient with Pfeiffer syndrome, which involves synostosis of the lambdoid and coronal sutures, hypoplastic shallow orbits and midface hypoplasia. (B) On the lateral radiograph no airway is detected in the nasopharynx (arrow).

chomolacia⁸³. The complication rate in CFD patients is estimated to be even higher. Timely advancement of the midface with minimal intra-operative strain, enlarging the nasopharynx and the palatopharyngeal space, can allow faster decannulation⁶. Decreasing the duration of endotracheal intubation improves the patient's quality of life and reduces long-term endotracheal intubation-related morbidity. In contrast to adults with OSAS, children often manifest a pattern of persistent partial airway obstruction during sleep, leading to obstructive hypoventilation, rather than cyclical, discrete obstructive apneas, making the disease difficult to spot^{36, 96}. In the infant, leaving OSAS untreated may result in failure to thrive, feeding difficulties, recurrent infections, disturbed cognitive functions, developmental delay, cor pulmonale or infant sudden death⁶⁷.

Clinical findings suggest that frequent desaturations, changes in blood pressure and cerebral perfusion may cause deterioration of vision³⁷. A close association between OSAS and raised ICP has been suggested³⁷. The authors' CFD protocol includes that all patients with clinical signs of OSAS are screened for raised ICP by the consulting ophthalmologist. In case of papilledema, a sign for raised ICP, the surgical plan is adjusted according to the neurosurgical indication⁵⁶.

One of the most prominent clinical features of CFD is the ocular proptosis with corneal distortion, leading to ocular (sub-)luxation in the most severe cases. Functional loss of vision at the causal orbital level can be due to papilledema as a result of cranial overpressure, corneal exposure and/or amblyopia. Papilledema occurs in 10-15 % of untreated CFD patients^{47, 88}. Corneal exposure, in conjunction with an affected lacrimal apparatus and inefficient tear film can lead to anatomical loss of vision due to exposure keratitis, keratoconjunctivitis sicca and infection leading to corneal ulceration and cataract. Major visual impairment is due to amblyopia. Strong risk factors for amblyopia include strabismus, hypermetropia, astigmatism and anisometropia which are more prevalent in CFD-patients than in the non-affected population⁸⁸.

Achieving a balanced, esthetically pleasing appearance is the major factor in determining the surgical outcome satisfaction of the patient, family and surgeon. Several studies have mentioned the negative impact of facial distortion on the mother-child attachment, which occurs during the first year of life⁴. As this bond is a major influence on the infant's early psychosocial development, some authors have advocated surgery in infancy for esthetic and psychosocial reasons⁵⁸. Recent comparative studies in patients with cleft palate have since shown no long-term dif-

ference in mother-child attachment in children with affected facial appearance and controls at 24 months of age, making esthetics an elective rather than a pressing indication for surgery⁵⁵.

Timing of surgery

Posnick wrote in 1997: "The current approach to the correction of the deformities associated with CFD is to stage the reconstruction to coincide with facial growth patterns, visceral function, and psychosocial development"⁷⁷. Facial growth occurs in 2 distinct periods; during the first 6-7 years of life, craniofacial growth is mostly determined by growth of brain, eyes and nasal cartilage, leading to sutural growth. After the age of 7 years, growth occurs because of bony surface deposition or apposition, development of the maxillary alveolar process and enlargement of the nasal cavity⁷⁹. As stated and reviewed below, the CFD patient shows little, if any, maxillary growth during the period of craniofacial growth and development, whether operated or unoperated. No detrimental or beneficial effect of surgery on subsequent growth was seen with CFD patients. The LF III procedure should not be postponed in order not to compromise the inherent growth potential through scarring, as there is minimal inherent growth potential in the CFD midface. One should be aware that repeated surgery is necessary to overcome OSAS, which carries a higher risk of complications. In summary, midface advancement can be scheduled in the first years of life for absolute indications, such as OSAS or severe exorbitism. If the patient is only mildly afflicted, elective surgery can be postponed until skeletal maturity has been reached after puberty and it can then be performed for relative functional and esthetic reasons. The surgeon should always allow for an individual, patient-based approach towards the best possible treatment.

MIDFACE DISTRACTION

Conventional procedure versus DO

DO can achieve advancements exceeding the advancement of the conventional procedure 2- to 3-fold^{11, 14, 23}. This is because DO can overcome the natural soft-tissue resistance by means of gradual stretching and accommodation, generating new soft-tissue (histiogenesis) simultaneously with skeletal augmentation. Some authors consider that relapse rates are lower because of this (see Relapse section

below)^{24, 34, 42, 63, 98}. Application of external distraction devices allows for a better vector control, making traction more effective and precise^{45, 97}. DO is associated with decreased operative and postoperative morbidity^{46, 63, 73, 86}. Eliminating the use of bone grafts for stabilization purposes also eliminated donor site morbidity^{11, 12, 63}. Operation time is reduced, blood loss is lowered, postoperative pain is less and the hospital stay is shorter which also reduces costs. Morbidity might also be lower because of the lesser degree of undercorrection and the lower relapse rate, often eliminating the need for a second surgical procedure²⁴. Disadvantages associated with the DO technique mainly involve material-related complications, the need for high patient compliance and the high psychological impact of the treatment, which can lead to difficulties when treating children^{29, 85}. Also the need for a second surgical procedure to remove the distractor (in particular with intraoral devices) is a disadvantage. DO can also provoke pseudorelapse when patients undergo surgery in early childhood⁷³. The main advantages of the traditional technique are the absence of a distraction device (and thus the associated complications, prolonged distraction period and high patient compliance) and the requirement for a second surgical procedure to remove the device²⁴.

SURGICAL TECHNIQUE

Surgical technique

LF III osteotomy is performed following exposure of the frontotemporal skull, lateral orbital region, nasion, zygomatic arch, and the zygomatic body via a coronal incision. The anterior surface of the maxillary antrum can be approached through the gingivobuccal sulcus. Osteotomies, following the LF III – Tessier III design, are then made through the frontozygomatic suture, floor of the orbit, and the nasion using a reciprocating saw (**figure 2**). A cephalo-osteotome is used to separate the vomer and ethmoid from the cranial base in the midline. The pterygomaxillary junction is separated either from the bicoronal approach or the gingivobuccal access. Rowe forceps are then used to mobilize the LF III segment including an maxillary acrylic plate to prevent unwanted fracture of the maxilla (**figure 3**)²¹. Mobilization of the midface is a very extensive procedure, carrying with it a high degree of morbidity in blood loss. Surgeons have sought less invasive techniques to limit morbidity. The greatest advance has been the advent of DO, eliminating the need for immediate advance-

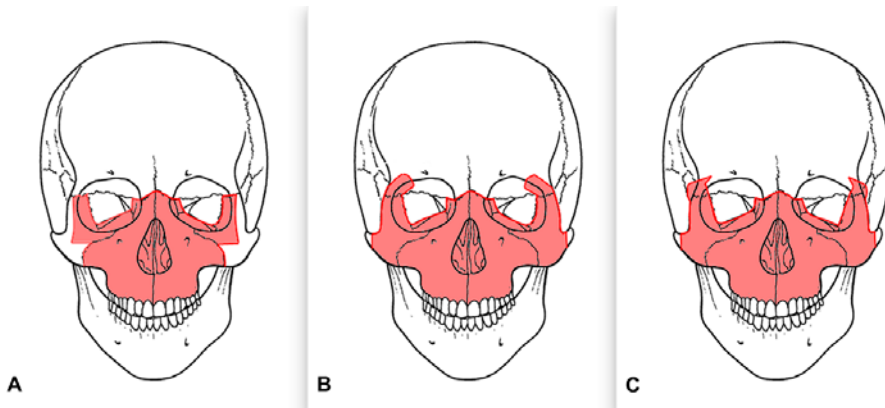


Figure 2: Design of LF III osteotomy according to (A) Tessier I, (B) II and (C) III, with minor variations at the lateral orbital wall.

ment, graft harvesting and immediate internal stabilization. Schulten et al. combined the use of an internal and external distractor, called the “push-pull technique”, to better control the distraction process and force vectors⁸². In their experience, the use of both types of distractors simultaneously allows for the advantages of both devices, while the disadvantages are not additive. Combining sagittal and transverse distraction devices is also possible and is called ‘multidirectional DO’. Ueki et al. performed this technique in a patient with Crouzon syndrome by using both a RED system and hyrax expansion screw in the maxilla⁹⁵.

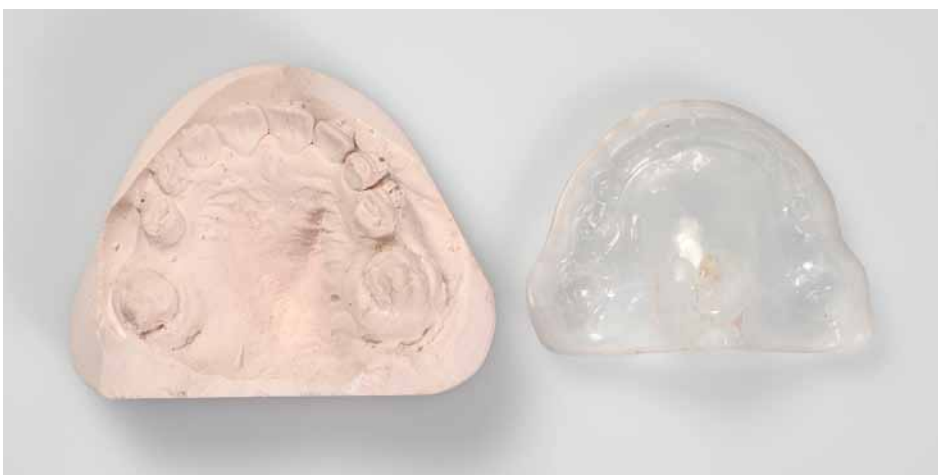

Figure 3: To prevent unwanted fracture a maxillary acrylic plate is used during mobilization of the midface.

Denny et al. developed 'rotational advancement'. After standard LF III osteotomy and full mobilization of the midface, an internal distractor is fixated to the zygomatic arch, with only one screw in the anterior plate which acts as a pivot. A hinge plate is fixed across the fronto-zygomatic osteotomy, and a single axial plate is fixed across the nasofrontal osteotomy, which bends with distraction. The objective is to achieve a differential advancement with enough advancement at the occlusal level to establish class I occlusion and an acceptable esthetic facial contour and profile in cases where there is an unequal severity of retrusion at the orbital, nasal root, malar and maxillary alveolar ridge level²⁰. Trials have been undertaken to limit incisions by using an endoscopic technique⁵³ and to lower morbidity by using ultrasound osteotomes in craniofacial surgery⁵. Following experimental animal studies by Staffenberg et al. and McCarthy^{61, 84}, Pellerin et al. and Liu et al. performed midface advancement in children aged 6-12 years by applying distraction force to the midface with a midfacial pin but without osteotomy^{54, 71}. Computer-aided surgical simulation is now being used in the fully virtual pre-operative planning of complex mid-facial deformities³⁰.

Distraction devices

Distraction devices are extraoral or intraoral devices, and many advantages and disadvantages of both types have been recorded. Of the extraoral distraction devices, two haloframes are commercially available (External Midface Distractor, manufactured by Synthes, Oberdorf, Switzerland and Rigid External Distractor, manufactured by Martin, Tuttlingen, Germany). Both have similar advantages: the ability to control and modify the vectors of force during the distraction period, the central distribution of forces, easy application and removal of the device and employability in case of thin cortical zygomatic bone segments^{23, 35, 51}. The disadvantages of the two haloframes include patient discomfort (psychosocial as well as physical), halo-related complications (traumatic injuries, scarring, pin loosening) and the need for an upper dental arch to fix the oral splint^{26, 68, 81}. However, with only bony anchorage parasally, at the aperture piriformis and in the zygomatic region the mobilized segment can be brought forward successfully (**figure 4**)^{51, 54, 60}. In order to minimize halo-related complications with external distractors, the authors advise taking a CT-scan of the cranium preoperatively to detect any possible bony defects⁶⁸.

Several internal devices have been reported. Most consist of two bilaterally placed, bone-attached, standardized or customized plates that can be extended during

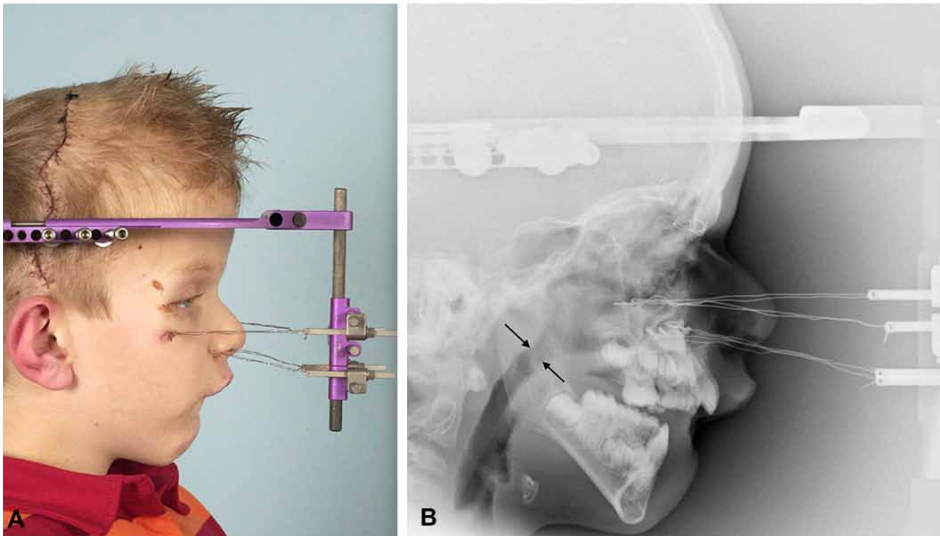


Figure 4: (A) The mobilized midface is at the zygomatic region and paranasally bony anchored to the RED system. (B) At the end of distraction the midface is 20 mm advanced. Note the increase of pharyngeal volume (arrows) compared with the preoperative situation (see fig. 1B).

DO. Advantages of these are their smaller size, better patient acceptance (esthetic as well as physical), independence of the presence of an upper dental arch and lesser major complication rates^{14, 35, 42}. Disadvantages include the need for a second intervention to remove the device, the impossibility of adjusting vectors of force during DO, possible fracture of the zygomatico-maxillary junction in case of thin cortical bone, technical difficulties in placing the two devices bilaterally parallel and applying lateral forces onto the midfacial complex (which undesirably extend the concavity of the advanced midfacial segment) instead of forces with a central action^{11, 23, 41}.

Cohen et al. have introduced biodegradable plates for internal distractors¹⁶, but a second (minor) surgical procedure is still necessary to remove the distractor screw and cable-drive. Burstein et al. designed a one-stage internal biodegradable device¹⁰. No long-term follow-up studies with internal biodegradable devices on the LF III level have yet been published.

Only two reports have been published in which external and internal distractors were compared^{23, 35}. Gosain et al. consider the RED system as a viable alternative to internal distraction systems, preferably to be used in older patients. Fearon considers the external system to be superior to internal distraction devices when performing LF III DO. Both authors report both systems yield stable long-term results.

Complications related to the LF III osteotomy

Minor and major complications have been reported with the LF III osteotomy^{28,62,25, 33}. Minor complications include cutting the infra-orbital nerve, ptosis, strabismus, partial anosmia, fracturing of zygoma during mobilization, partial exposure of the nasal bone graft and localized infections/abscesses of the surgical area. Major complications include respiratory distress requiring tracheotomy, gastric stress ulcer development, infection of ventriculo-atrial shunt, generalized infection, subgaleal hematoma, cerebro-spinal fluid leakage and fistula and visual loss after retro-orbital hemorrhage. In one case-report lethal intracranial arterial bleeding was described following a skull base fracture due to perioperative maneuvers (most likely pterygoidmaxillary dysjunction and downfracture manipulation)⁵⁷.

Complications related to DO

Concerning the DO procedure several authors report no or only a minimal risk of complications in midfacial distraction^{7, 60, 63, 81}. A systematic review by Swennen et al. however showed that DO on the midfacial and cranial level was associated with a considerable level of complications; in 96 patients, 25 complications occurred⁸⁶. This is supported by a recent report from the authors' group in which a substantial number of complications in DO on the midfacial level using an extraoral distraction device were recorded⁶⁸. Complications mainly constitute mechanical problems with the distraction device (pin loosening, frame migrations, traumatic injuries, intracranial migration of halo-fixation pins^{8, 52, 68}), technical difficulties (including fracture of the zygomaticomaxillary junction³⁵, intraoperative fragment disjunction⁴¹ and problems with maxillary splint attachment to the teeth), localized or pin-site skin infections, problems with advancement (less or asymmetrical advancement) and severe infections requiring hospitalization.

Fearon was the first to compare the two techniques in two retrospective studies^{23, 24}. He concluded that the incidence of complications and length of hospital stay were lower in the distraction-groups, while advancements were significantly higher in these groups. Sleep apnea was more successfully corrected by means of DO. According to Fearon, DO should be able to prevent a second distraction procedure. Fearon recommended the use of DO on the midfacial level in younger patients with more severe retrusions of the midface, which need greater advancements than can be achieved by using the conventional method. Nevertheless, the conventional

procedure is recommended in patients who need moderate advancement (8-10 mm) and who have completed growth^{42, 73}.

RELAPSE

Conventional LF III and DO

Long-term follow-up studies on the LF III osteotomy that include a substantial number of patients are rare. Considering the various studies available, the authors conclude that the standard LF III procedure provides a relatively stable postoperative position of the midface^{22,28,43, 44,62,64,73}.

Relapse, when it occurred, could be attributed either to inadequate postoperative fixation leading to backward rotation of the midface at the level of the orbits or to 'pseudorelapse', defined as relapse at the occlusal plane because of normal mandibular growth combined with decreased maxillary growth. Pseudorelapse is observed in patients who were operated on in childhood and can be corrected successfully by a LF I procedure after skeletal maturity. Studies agree that the conventional LF III advancement procedure, renders stable results with regard to the position of the skeletal midfacial segment, irrespective of the various cephalometrical landmarks and analyses used by the different authors^{43, 62, 64}.

Since the introduction of the DO technique on the midfacial level in 1993, only a few reports have been published dealing with its long-term stability^{11, 23, 24}. All these studies report minimal or no relapse in conjunction with DO of the midface. In contrast with conventional osteotomy, no statements are made in these reports about post-operative retention. The authors' CFD-protocol includes a one-year retention phase using night-time face-mask traction.

Responding to a questionnaire, 31 % of craniofacial surgeons reported relapse of the midface with DO in their practice⁶⁵. It is unknown whether this observed relapse was assessed subjectively or objectively. Most respondents encountered relapse within the first six months after finishing DO.

Postsurgical growth

There are contrasting views about postsurgical growth of the midface portion. When considering postsurgical growth it is essential to consider the presurgical/normal growth potential of CFD patients. Bachmayer et al. established the growth potential

of 52 unoperated CFD patients, 6-15 years of age, by measuring horizontal as well as vertical growth³. Horizontal growth was measured as the horizontal distance from basion to A-point. Their findings indicate that the horizontal growth of CFD patients is about 0.7 mm/yr. Kreiborg et al. and Meazzini et al. attribute the measured growth to the posterior cranial base, and state that measurements of the midfacial horizontal growth in these patients towards the anterior cranial base (sella-nasion line) showed no sagittal displacements of A-point; they conclude that sagittal growth in unoperated CFD patients is negligible^{50,64}. Significant vertical growth was measured in these patient groups, irrespective of the use of different cephalometric tracing methods. Bachmayer reports a vertical lengthening of ANS towards the true horizontal, and both Meazzini et al. and Kreiborg et al. report a discrepancy between the anterior and posterior vertical lengthening. A greater increase in the distance from ANS to the anterior cranial base was found, when compared with the distance of the posterior occlusal point to the anterior cranial base. As horizontal growth turns out to be nil, vertical growth seems to be preserved in unoperated CFD patients, stressing the importance of considering sagittal growth in its distinct components.

Considering presurgical growth data, a further deterioration of craniofacial growth in CFD patients is not expected. Several authors report some postsurgical sagittal growth of the midface, but do not differentiate between horizontal and vertical growth^{19, 22, 43, 50}. Some vertical growth is to be expected, whether the patients undergo surgery or not, owing to remodeling and appositional growth rather than to sutural growth⁵⁰. Fearon compared postsurgical growth between conventional and distracted LF III patients²⁴. No horizontal (anterior) growth and prolonged significant vertical growth was measured in either group; no differences in postoperative growth potential were observed between distracted and non-distracted patients. Fearon concludes that the observed deterioration of growth in CFD patients is more likely a result of the intrinsic syndromic features rather than a result of surgery.

DISCUSSION

It is inadvisable to propose any rigid surgical approach due to the widely varying phenotype of the CFD patient. However, the authors would like to present some basic principles to consider.

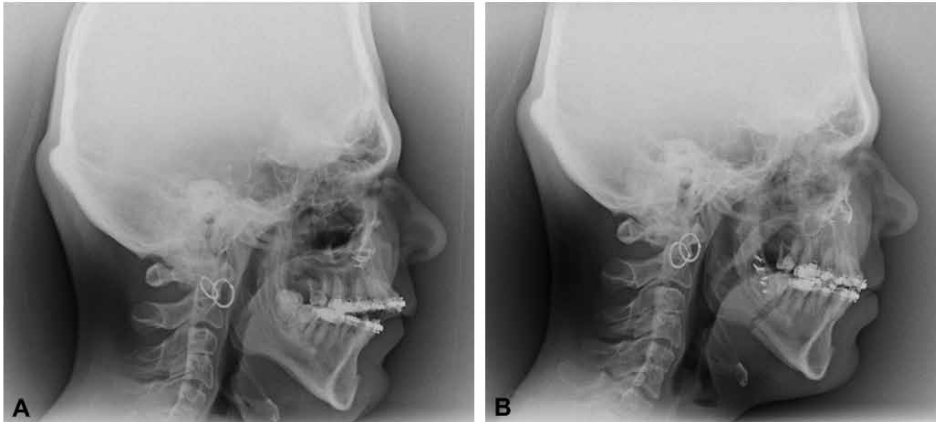


Figure 5: (A) In a patient with Apert syndrome a major open bite occurred after LF III distraction. (B) The open bite was corrected with a LF I and BSSO.

Patients with severe CFD, who need a DO surgical procedure before the age of skeletal maturity, have clearly benefited from the advanced techniques^{11, 23, 24, 56}. Using conventional osteotomy beyond this age of skeletal maturity gives the advantage of a shorter treatment period and higher patient comfort as well as the possibility to correct an unequal retrusion of midface at the same time with a combined LF III-LF I procedure. Maxillary hypoplasia typically results in an Angle class III malocclusion with an anterior open bite. The degree of growth deficiency at the orbital and the maxillary occlusal level are rarely uniform in all three planes. As well as an LF III osteotomy, an additional LF I osteotomy is often necessary to achieve an intermaxillary relation enabling stable occlusion (**figure 5**)⁷⁶. The degree of primary advancement is determined by the retrusion of the upper midface (as determined by the position of the nasion towards the skull base) and not the retrusion on the occlusal level. An additional LF I is preferably performed in the same procedure in case of skeletal maturity. Otherwise a LF I, sometimes even in combination with a mandibular osteotomy, is performed in a second surgical procedure, but in the authors' opinion always after the age of skeletal maturity to prevent relapse and optimize the treatment outcome. Close cooperation with the orthodontist of the craniofacial team is mandatory to plan the surgery with pre- and postoperative orthodontic treatment; patients should be seen together in the peri-operative phase.

There is no consensus on the growth potential of the midface after surgery. Therefore decisions and timing of surgery before skeletal maturity should be strictly

bound by the indications. Absolute indications for surgery are OSAS and ocular proptosis with corneal distortion as a result of orbital deficiency. Younger patients are generally treated with DO to achieve the greater advancement and overcorrection they need in order to correct the OSAS effectively and compensate for future restricted growth. Little information is available regarding the impact of the clinical signs of OSAS and abnormal outcomes of the PSG in CFD patients. It is unclear how aggressive one should be with the diagnosis of even mild OSAS in order to prevent irreversible damage. It is also unclear how much advancement is necessary to correct the OSAS. With endoscopy and CT-scanning the upper airway can be monitored more precisely and airway pressures and volumes can be measured. These outcomes could be linked to the results of the PSG. With improved imaging techniques, the size and shape of the distraction segment can be investigated, giving insight into the long-term stability of the segment in relation to the surrounding tissues.

The authors recently observed growth retardation of the mandible and functional pharynx problems contributing possibly to the persistent OSAS, despite considerable advancement of the midface with DO, in patients with Apert and Crouzon syndromes. Endoscopy of the upper airway respiratory tract, i.e. nasopharyngoscopy, is advised before midface-advancement to monitor all possible levels of obstruction. In a large prospective study of CFD patients the relation between OSAS and raised ICP is being investigated in the authors' Craniofacial Centre in an attempt to elucidate the pathophysiological pathway of OSAS leading to raised ICP and/or vice versa.

REFERENCES

1. Clinical practice guideline: diagnosis and management of childhood obstructive sleep apnea syndrome. *Pediatrics* 2002; 109: 704-712.
2. Alonso N, Munhoz AM, Fogaca W, Ferreira MC. Midfacial advancement by bone distraction for treatment of craniofacial deformities. *J Craniofac Surg* 1998; 9: 114-118; discussion 119-122.
3. Bachmayer DI, Ross RB, Munro IR. Maxillary growth following LeFort III advancement surgery in Crouzon, Apert, and Pfeiffer syndromes. *Am J Orthod Dentofacial Orthop* 1986; 90: 420-430.
4. Barden RC, Ford ME, Jensen AG, Rogers-Salyer M, Salyer KE. Effects of craniofacial deformity in infancy on the quality of mother-infant interactions. *Child Dev* 1989; 60: 819-824.
5. Beziat JL, Bera JC, Lavandier B, Gleizal A. Ultrasonic osteotomy as a new technique in craniomaxillofacial surgery. *Int J Oral Maxillofac Surg* 2007; 36: 493-500.
6. Boston M, Rutter MJ. Current airway management in craniofacial anomalies. *Curr Opin Otolaryngol Head Neck Surg* 2003; 11: 428-432.
7. Britto JA, Evans RD, Hayward RD, Jones BM. Maxillary distraction osteogenesis in Pfeiffer's syndrome: urgent ocular protection by gradual midfacial skeletal advancement. *Br J Plast Surg* 1998; 51: 343-349.
8. Brown R, Higuera S, Boyd V, Taylor T, Hollier LH, Jr. Intracranial migration of a halo pin during distraction osteogenesis for maxillary hypoplasia: case report and literature review. *J Oral Maxillofac Surg* 2006; 64: 130-135.
9. Brusati R, Sesenna E, Raffaini M. On the feasibility of intraoral maxillo-malar osteotomy. *J Craniomaxillofac Surg* 1989; 17: 110-115.
10. Burstein FD, Williams JK, Hudgins R, Graham L, Teague G, Paschal M, Simms C. Single-stage craniofacial distraction using resorbable devices. *J Craniofac Surg* 2002; 13: 776-782.
11. Cedars MG, Linck DL, 2nd, Chin M, Toth BA. Advancement of the midface using distraction techniques. *Plast Reconstr Surg* 1999; 103: 429-441.
12. Cheung LK, Lo J. Distraction of Le Fort II osteotomy by intraoral distractor: a case report. *J Oral Maxillofac Surg* 2006; 64: 856-860.
13. Chin M, Toth BA. Distraction osteogenesis in maxillofacial surgery using internal devices: review of five cases. *J Oral Maxillofac Surg* 1996; 54: 45-53; discussion 54.
14. Chin M, Toth BA. Le Fort III advancement with gradual distraction using internal devices. *Plast Reconstr Surg* 1997; 100: 819-830; discussion 831-812.
15. Cohen SR, Burstein FD, Stewart MB, Rathburn MA. Maxillary-midface distraction in children with cleft lip and palate: a preliminary report. *Plast Reconstr Surg* 1997; 99: 1421-1428.
16. Cohen SR, Holmes RE. Internal Le Fort III distraction with biodegradable devices. *J Craniofac Surg* 2001; 12: 264-272.
17. Cohen SR, Rutrick RE, Burstein FD. Distraction osteogenesis of the human craniofacial skeleton: initial experience with new distraction system. *J Craniofac Surg* 1995; 6: 368-374.
18. Converse JM, Telsey D. The tripartite osteotomy of the mid-face for orbital expansion and correction of the deformity in craniostenosis. *Br J Plast Surg* 1971; 24: 365-374.
19. David DJ, Sheen R. Surgical correction of Crouzon syndrome. *Plast Reconstr Surg* 1990; 85: 344-354.
20. Denny AD, Kalantarian B, Hanson PR. Rotation advancement of the midface by distraction osteogenesis. *Plast Reconstr Surg* 2003; 111: 1789-1799; discussion 1800-1783.

21. Dolan RW. Facial Plastic, Reconstructive, and Trauma Surgery. New York: Marcel Dekker, 2003.
22. Epker BN, Wolford LM. Middle-third facial osteotomies: their use in the correction of congenital dentofacial and craniofacial deformities. *J Oral Surg* 1976; 34: 324-342.
23. Fearon JA. The Le Fort III osteotomy: to distract or not to distract? *Plast Reconstr Surg* 2001; 107: 1091-1103; discussion 1104-1096.
24. Fearon JA. Halo distraction of the Le Fort III in syndromic craniosynostosis: a long-term assessment. *Plast Reconstr Surg* 2005; 115: 1524-1536.
25. Fearon JA, Whitaker LA. Complications with facial advancement: a comparison between the Le Fort III and monobloc advancements. *Plast Reconstr Surg* 1993; 91: 990-995.
26. Figueroa AA, Polley JW, Ko EW. Maxillary distraction for the management of cleft maxillary hypoplasia with a rigid external distraction system. *Semin Orthod* 1999; 5: 46-51.
27. Freihofer HP. Latitude and limitation of midface movements. *Br J Oral Maxillofac Surg* 1984; 22: 393-413.
28. Freihofer HP, Jr. Results after midface-osteotomies. *J Maxillofac Surg* 1973; 1: 30-36.
29. Gateno J, Teichgraeber JF, Xia JJ. Three-dimensional surgical planning for maxillary and midface distraction osteogenesis. *J Craniofac Surg* 2003; 14: 833-839.
30. Gateno J, Xia JJ, Teichgraeber JF, Christensen AM, Lemoine JJ, Liebschner MA, Gliddon MJ, Briggs ME. Clinical feasibility of computer-aided surgical simulation (CASS) in the treatment of complex cranio-maxillofacial deformities. *J Oral Maxillofac Surg* 2007; 65: 728-734.
31. Gillies H, Harrison SH. Operative correction by osteotomy of recessed malar maxillary compound in a case of oxycephaly. *Br J Plast Surg* 1950; 3: 123-127.
32. Gillies H, Millard R. The principles and art of plastic surgery. Boston: Little, Bown & Co., 1957.
33. Giroto JA, Davidson J, Wheatly M, Redett R, Muehlberger T, Robertson B, Zinreich J, Iliff N, Miller N, Manson PN. Blindness as a complication of Le Fort osteotomies: role of atypical fracture patterns and distortion of the optic canal. *Plast Reconstr Surg* 1998; 102: 1409-1421; discussion 1422-1403.
34. Gosain AK. Distraction osteogenesis of the craniofacial skeleton. *Plast Reconstr Surg* 2001; 107: 278-280.
35. Gosain AK, Santoro TD, Havlik RJ, Cohen SR, Holmes RE. Midface distraction following Le Fort III and monobloc osteotomies: problems and solutions. *Plast Reconstr Surg* 2002; 109: 1797-1808.
36. Guilleminault C, Lee JH, Chan A. Pediatric obstructive sleep apnea syndrome. *Arch Pediatr Adolesc Med* 2005; 159: 775-785.
37. Hayward R. Venous hypertension and craniosynostosis. *Childs Nerv Syst* 2005; 21: 880-888.
38. Hierl T, Hemprich A. Callus distraction of the midface in the severely atrophied maxilla--a case report. *Cleft Palate Craniofac J* 1999; 36: 457-461.
39. Hoeve HL, Joosten KF, van den Berg S. Management of obstructive sleep apnea syndrome in children with craniofacial malformation. *Int J Pediatr Otorhinolaryngol* 1999; 49 Suppl 1: S59-61.
40. Hoeve LJ, Pijpers M, Joosten KF. OSAS in craniofacial syndromes: an unsolved problem. *Int J Pediatr Otorhinolaryngol* 2003; 67 Suppl 1: S111-113.
41. Holmes AD, Wright GW, Meara JG, Heggie AA, Probert TC. LeFort III internal distraction in syndromic craniosynostosis. *J Craniofac Surg* 2002; 13: 262-272.

42. Iannetti G, Fadda T, Agrillo A, Poladas G, Iannetti G, Filiaci F. LeFort III advancement with and without osteogenesis distraction. *J Craniofac Surg* 2006; 17: 536-543.
43. Kaban LB, Conover M, Mulliken JB. Midface position after Le Fort III advancement: a long-term follow-up study. *Cleft Palate J* 1986; 23 Suppl 1: 75-77.
44. Kaban LB, West B, Conover M, Will L, Mulliken JB, Murray JE. Midface position after LeFort III advancement. *Plast Reconstr Surg* 1984; 73: 758-767.
45. Kessler P, Kloss F, Hirschfelder U, Neukam FW, Wiltfang J. [Distraction osteogenesis in the midface. Indications, technique and first long-term results]. *Schweiz Monatsschr Zahnmed* 2003; 113: 677-692.
46. Kessler P, Wiltfang J, Schultze-Mosgau S, Hirschfelder U, Neukam FW. Distraction osteogenesis of the maxilla and midface using a subcutaneous device: report of four cases. *Br J Oral Maxillofac Surg* 2001; 39: 13-21.
47. Khan SH, Nischal KK, Dean F, Hayward RD, Walker J. Visual outcomes and amblyogenic risk factors in craniosynostotic syndromes: a review of 141 cases. *Br J Ophthalmol* 2003; 87: 999-1003.
48. Klein C. [Midfacial callus distraction in a patient with Crouzon syndrome] *Mittelgesichtsdistraction bei einem Patienten mit Crouzon-Syndrom. Mund Kiefer Gesichtschir* 1998; 2 Suppl 1: S52-57.
49. Kobus KF. New osteotomies for midface advancement in patients with crouzon syndrome. *J Craniofac Surg* 2006; 17: 957-961.
50. Kreiborg S, Aduss H. Pre- and postsurgical facial growth in patients with Crouzon's and Apert's syndromes. *Cleft Palate J* 1986; 23 Suppl 1: 78-90.
51. Kubler A, Zoller J. [Trans-facial distraction of the facial skull at the LeFort III level]. *Mund Kiefer Gesichtschir* 2002; 6: 153-157.
52. Le BT, Eyre JM, Wehby MC, Wheatley MJ. Intracranial migration of halo fixation pins: a complication of using an extraoral distraction device. *Cleft Palate Craniofac J* 2001; 38: 401-404.
53. Levine JP, Rowe NM, Bradley JP, Williams JK, Mackool RJ, Longaker MT, McCarthy JG. The combination of endoscopy and distraction osteogenesis in the development of a canine midface advancement model. *J Craniofac Surg* 1998; 9: 423-432.
54. Liu C, Hou M, Liang L, Huang X, Zhang T, Zhang H, Ma X, Song R. Sutural distraction osteogenesis (SDO) versus osteotomy distraction osteogenesis (ODO) for midfacial advancement: a new technique and primary clinical report. *J Craniofac Surg* 2005; 16: 537-548.
55. Maris CL, Endriga MC, Speltz ML, Jones K, DeKlyen M. Are infants with orofacial clefts at risk for insecure mother-child attachments? *Cleft Palate Craniofac J* 2000; 37: 257-265.
56. Mathijssen I, Arnaud E, Marchac D, Mireau E, Morisseau-Durand MP, Guerin P, Renier D. Respiratory outcome of mid-face advancement with distraction: a comparison between Le Fort III and frontofacial monobloc. *J Craniofac Surg* 2006; 17: 880-882.
57. Matsumoto K, Nakanishi H, Seike T, Koizumi Y, Hirabayashi S. Intracranial hemorrhage resulting from skull base fracture as a complication of Le Fort III osteotomy. *J Craniofac Surg* 2003; 14: 545-548.
58. Matthews D. Craniofacial surgery--indications, assessment and complications. *Br J Plast Surg* 1979; 32: 96-105.
59. Mavili ME, Tuncbilek G. Seesaw modification of the lateral orbital wall in Le Fort III osteotomy. *Cleft Palate Craniofac J* 2004; 41: 579-583.

60. Mavili ME, Tuncbilek G, Vargel I. Rigid external distraction of the midface with direct wiring of the distraction unit in patients with craniofacial dysplasia. *J Craniofac Surg* 2003; 14: 783-785.
61. McCarthy JG. Sutural Expansion Osteogenesis for Management of the Bony-Tissue Defect in Cleft Palate Repair: Experimental Studies in Dogs. *Plast Reconstr Surg* 2000; 105: 2026-2027.
62. McCarthy JG, La Trenta GS, Breitbart AS, Grayson BH, Bookstein FL. The Le Fort III advancement osteotomy in the child under 7 years of age. *Plast Reconstr Surg* 1990; 86: 633-646; discussion 647-639.
63. McCarthy JG, Stelnicki EJ, Mehrara BJ, Longaker MT. Distraction osteogenesis of the craniofacial skeleton. *Plast Reconstr Surg* 2001; 107: 1812-1827.
64. Meazzini MC, Mazzoleni F, Caronni E, Bozzetti A. Le Fort III advancement osteotomy in the growing child affected by Crouzon's and Apert's syndromes: presurgical and postsurgical growth. *J Craniofac Surg* 2005; 16: 369-377.
65. Mofid MM, Manson PN, Robertson BC, Tufaro AP, Elias JJ, Vander Kolk CA. Craniofacial distraction osteogenesis: a review of 3278 cases. *Plast Reconstr Surg* 2001; 108: 1103-1114; discussion 1115-1107.
66. Narayan D, Persing JA. Modified Le Fort III osteotomy in adult Crouzon disease. *J Craniofac Surg* 1998; 9: 481-485; discussion 486-487.
67. Nixon GM, Kermack AS, McGregor CD, Davis GM, Manoukian JJ, Brown KA, Brouillette RT. Sleep and breathing on the first night after adenotonsillectomy for obstructive sleep apnea. *Pediatr Pulmonol* 2005; 39: 332-338.
68. Nout E, Wolvius EB, van Adrichem LN, Ongkosuwito EM, van der Wal KG. Complications in maxillary distraction using the RED II device: a retrospective analysis of 21 patients. *Int J Oral Maxillofac Surg* 2006; 35: 897-902.
69. Obwegeser HL. Surgical correction of small or retrodisplaced maxillae. The "dish-face" deformity. *Plast Reconstr Surg* 1969; 43: 351-365.
70. Ortiz-Monasterio F, del Campo AF, Carrillo A. Advancement of the orbits and the midface in one piece, combined with frontal repositioning, for the correction of Crouzon's deformities. *Plast Reconstr Surg* 1978; 61: 507-516.
71. Pellerin P, Capon-Desgardin N, Martinot-Duquennoy V, Vinchon M, Dhellemmes P. [Mid-facial distraction without osteotomy with a trans-facial pin. Report of 4 clinical cases]. *Ann Chir Plast Esthet* 2001; 46: 277-284.
72. Perkins JA, Sie KC, Milczuk H, Richardson MA. Airway management in children with craniofacial anomalies. *Cleft Palate Craniofac J* 1997; 34: 135-140.
73. Phillips JH, George AK, Tompson B. Le Fort III osteotomy or distraction osteogenesis imperfecta: your choice. *Plast Reconstr Surg* 2006; 117: 1255-1260.
74. Pijpers M, Poels PJ, Vaandrager JM, de Hoog M, van den Berg S, Hoeve HJ, Joosten KF. Undiagnosed obstructive sleep apnea syndrome in children with syndromal craniofacial synostosis. *J Craniofac Surg* 2004; 15: 670-674.
75. Polley JW, Figueroa AA, Charbel FT, Berkowitz R, Reisberg D, Cohen M. Monobloc cranio-maxillofacial distraction osteogenesis in a newborn with severe craniofacial synostosis: a preliminary report. *J Craniofac Surg* 1995; 6: 421-423.
76. Posnick JC. The craniofacial dysostosis syndromes. Current reconstructive strategies. *Clin Plast Surg* 1994; 21: 585-598.

77. Posnick JC. The craniofacial dysostosis syndromes. Staging of reconstruction and management of secondary deformities. *Clin Plast Surg* 1997; 24: 429-446.
78. Posnick JC, Ruiz RL. The craniofacial dysostosis syndromes: current surgical thinking and future directions. *Cleft Palate Craniofac J* 2000; 37: 433.
79. Ranly DM. Craniofacial growth. *Dent Clin North Am* 2000; 44: 457-470, v.
80. Raulo Y, Tessier P. Fronto-facial advancement for Crouzon's and Apert's syndromes. *Scand J Plast Reconstr Surg* 1981; 15: 245-250.
81. Riediger D, Poukens JM. Le Fort III osteotomy: a new internal positioned distractor. *J Oral Maxillofac Surg* 2003; 61: 882-889.
82. Schulten A, Lim AA, Bruun RA, Hayes C, Mulliken JB, Padwa BL. Combined push-pull distraction for correction of syndromic midfacial hypoplasia. *J Oral Maxillofac Surg* 2006; 64: 23-30.
83. Sculerati N, Gottlieb MD, Zimble MS, Chibbaro PD, McCarthy JG. Airway management in children with major craniofacial anomalies. *Laryngoscope* 1998; 108: 1806-1812.
84. Staffenberg DA, Wood RJ, McCarthy JG, Grayson BH, Glasberg SB. Midface distraction advancement in the canine without osteotomies. *Ann Plast Surg* 1995; 34: 512-517.
85. Suhr MA, Kreusch T. Technical considerations in distraction osteogenesis. *Int J Oral Maxillofac Surg* 2004; 33: 89-94.
86. Swennen G, Schliephake H, Dempf R, Schierle H, Malevez C. Craniofacial distraction osteogenesis: a review of the literature: Part 1: clinical studies. *Int J Oral Maxillofac Surg* 2001; 30: 89-103.
87. Tantinikorn W, Alper CM, Bluestone CD, Casselbrant ML. Outcome in pediatric tracheotomy. *Am J Otolaryngol* 2003; 24: 131-137.
88. Tay T, Martin F, Rowe N, Johnson K, Poole M, Tan K, Kennedy I, Gianoutsos M. Prevalence and causes of visual impairment in craniosynostotic syndromes. *Clin Experiment Ophthalmol* 2006; 34: 434-440.
89. Tessier P. [Total facial osteotomy. Crouzon's syndrome, Apert's syndrome: oxycephaly, scaphocephaly, turriccephaly] Osteotomies totales de la face. Syndrome de Crouzon, syndrome d'Apert: oxycephalies, scaphocephalies, turriccephalies. *Ann Chir Plast* 1967; 12: 273-286.
90. Tessier P. The definitive plastic surgical treatment of the severe facial deformities of craniofacial dysostosis. Crouzon's and Apert's diseases. *Plast Reconstr Surg* 1971; 48: 419-442.
91. Tessier P. Relationship of craniostenoses to craniofacial dysostoses, and to faciostenoses: a study with therapeutic implications. *Plast Reconstr Surg* 1971; 48: 224-237.
92. Tessier P. Total osteotomy of the middle third of the face for faciostenosis or for sequelae of Le Fort 3 fractures. *Plast Reconstr Surg* 1971; 48: 533-541.
93. Tessier P. The classic reprint. Experimental study of fractures of the upper jaw. I and II. *Rene Le Fort, M.D. Plast Reconstr Surg* 1972; 50: 497-506 contd.
94. Tessier P, Guiot G, Rougerie J, Delbet JP, Pastoriza J. [Cranio-naso-orbito-facial osteotomies. Hypertelorism] Osteotomies cranio-naso-orbito-faciales. Hypertelorisme. *Ann Chir Plast* 1967; 12: 103-118.
95. Ueki K, Marukawa K, Nakagawa K, Yamamoto E. Multidirectional distraction osteogenesis for Crouzon syndrome: technical note. *Int J Oral Maxillofac Surg* 2005; 34: 82-84.
96. Ward SL, Marcus CL. Obstructive sleep apnea in infants and young children. *J Clin Neurophysiol* 1996; 13: 198-207.

97. Weingart D, Roser M, Lantos P. [Mid-face distraction after LeFort III osteotomy in craniofacial dysmorphism]. *Mund Kiefer Gesichtschir* 2001; 5: 221-226.
98. Wiltfang J, Hirschfelder U, Neukam FW, Kessler P. Long-term results of distraction osteogenesis of the maxilla and midface. *Br J Oral Maxillofac Surg* 2002; 40: 473-479.

Orbital
infra-orbital
Distraction
OSAS
Craniosynostosis
volume
Midface
rim
globe
position
osteogenesis
Airway
exorbitism
Advancement

Part II

Fundamental studies

Chapter 2

Orbital change following Le Fort III advancement in syndromic craniosynostosis: quantitative evaluation of orbital volume, infra-orbital rim and globe position

E. Nout¹

J.S. van Bezooijen¹

M.J. Koudstaal¹

J.F. Veenland^{2,3}

W.C.J. Hop⁴

E.B. Wolvius¹

K.G.H. van der Wal¹

¹Department of Oral and Maxillofacial Surgery - Erasmus University
Medical Centre Rotterdam, The Netherlands

²Department of Medical Informatics - Faculty of Medicine, Erasmus
University Medical Centre Rotterdam, The Netherlands

³Department of Radiology – Erasmus University Medical Centre
Rotterdam, The Netherlands

⁴Department of Biostatistics – Faculty of Medicine, Erasmus
University Medical Centre Rotterdam, The Netherlands

Submitted

J Craniomaxillofac Surg

ABSTRACT

For patients with SCS suffering from shallow orbits due to midface hypoplasia, LF III advancement is a possible treatment modality. This study evaluates the influence of LF III advancement on orbital volume, position of the infra-orbital rim and globe.

In pre- and postoperative CT-scans of eighteen SCS patients, segmentation of the left and right orbit was performed and the infra-orbital rim and globe were marked. By superimposing the pre- and postoperative scan and by creating a reference coordinate system, movements of the infra-orbital rim and globe were evaluated. Orbital volume increased significantly with 27.2% for the left and 28.4% for the right orbit. A significant anterior movement of the left infra-orbital rim of 12.0 mm (sd 4.2) and right infra-orbital rim of 12.8 mm (sd 4.9) were found. A significant medial movement of 1.7 mm (sd 2.2) of the left globe and 1.5 mm (sd 1.9) of the right globe were found. There was a significant correlation between anterior infra-orbital rim movement and orbital volume gain.

Significant orbital volume gain has been demonstrated following LF III advancement. The position of the infra-orbital rim was significantly transferred anteriorly, whereas the globe position remained relatively unaffected.

INTRODUCTION

In patients with SCS, severe OSAS, raised ICP and globe (sub)luxation, are all absolute indications for surgical treatment. In these cases, LF III or MB advancement is often performed at a young age.¹⁹

Subluxation of the globe threatens the eye, causing exposure keratitis, mechanical lagophthalmos, corneal ulcers and risk of impaired vision and even loss of the eye.^{9, 14} SCS patients may have small orbital volumes compared to non-syndromic patients.⁸ Clinically, midface advancement is likely to increase the orbital volume by advancement of the infra-orbital rim and diminishes associated pathology.^{5, 9, 20} Fitzgerald et al. investigated globe movement after MB advancement by using CT-scan data.¹² They found significant forward movement of the globe after MB DO. There have been no fundamental reports concerning the influence of LF III advancement on orbital volume and the position of the infra-orbital rim and globe. Since osteotomy lines are made through the lateral orbital wall, standard Hertel measurements cannot be used. The purpose of this retrospective study was to measure the influence of LF III advancement on the orbital volume, infra-orbital rim and globe position using CT-scan data.

MATERIALS AND METHODS

Patients

All SCS patients who underwent LF III advancement in the Erasmus University Medical Centre between 2003 and 2009 were evaluated. Patients were included when the pre- and postoperative CT-scan were available for analysis.

CT-scans

The CT-scans were made in a supine position using the same scanner (Emotion 6, Siemens, Munich, Germany) and had a slice thickness of 1.25 mm. Sedation, was used when indicated.

Surgical procedure

Via a coronal approach the frontotemporal skull, lateral orbital region, nasal region, zygomatic arch and body are exposed. Osteotomies, following the LF III – Tessier III

design (**figure 1**), are made through the frontozygomatic suture, floor of the orbit, and the nasal bone, using a reciprocating saw and osteotomes. A cephalo-osteotome is used to separate the vomer and ethmoid from the cranial base in the midline. The pterygomaxillary junction is separated either from the coronal approach or through a gingivobuccal access. Rowe's forceps are used to mobilize the LF III segment. In case of a conventional LF III osteotomy the midface segment is advanced as much as needed and fixated using osteosynthesis plates and screws. In case of LF III DO, the internal or external distractors are applied and tested before closure of the wounds. After distraction and consolidation, the distractors were removed.

LF III distraction protocol

All patients were hospitalized for seven days regardless of age. The first 24 hours after surgery the patients stayed at the intensive care unit. DO was initiated after 1 week. The rate of distraction was 1 mm per day in 2 daily activations. The duration of DO depended on the desired advancement. During the distraction period, vector modifications took place when necessary in patients treated with an external distractor. In all patients a consolidation period of three months after distraction was respected. Postsurgically, all patients were seen in an outpatient clinic.

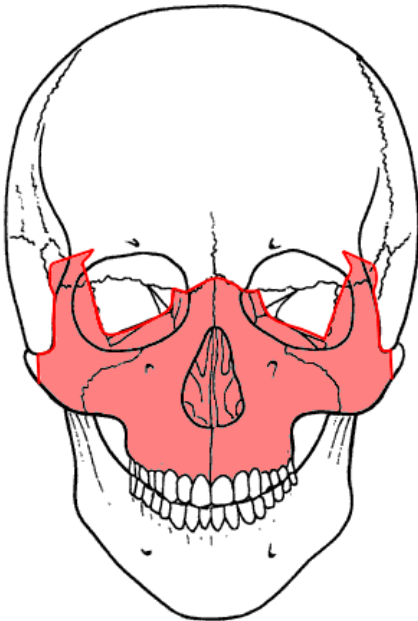


Figure 1: Schematic drawing of osteotomy lines according to LF III - Tessier III design as used in the patient cohort.

Data- analysis

Orbital volume

The software program MevisLab (Version 2.0, Mevis Medical Solutions AG, Bremen) was used to import and analyze the CT-scans by means of a custom-designed tool. On each sagittal slice of the CT-scan, the boundaries of each orbit were manually outlined resulting in a left and right orbital mask. To facilitate the segmentation, a threshold of 400 Hounsfield Units for bony structures was used. In all slices, the anterior boundary was defined as a straight line from the most antero-cranial point of the infra-orbital rim to the most antero-caudal point of the supra-orbital rim. The medial, lateral, superior and inferior boundaries were dictated by the bony structures of the orbit. In case of bony interruptions (eg. orbital foramina), a perpendicular straight line was drawn between the most nearby bony boundaries (**figure 2**). In all patients, the volume of the orbital masks was computed pre- and postoperatively for both the left and right orbit.

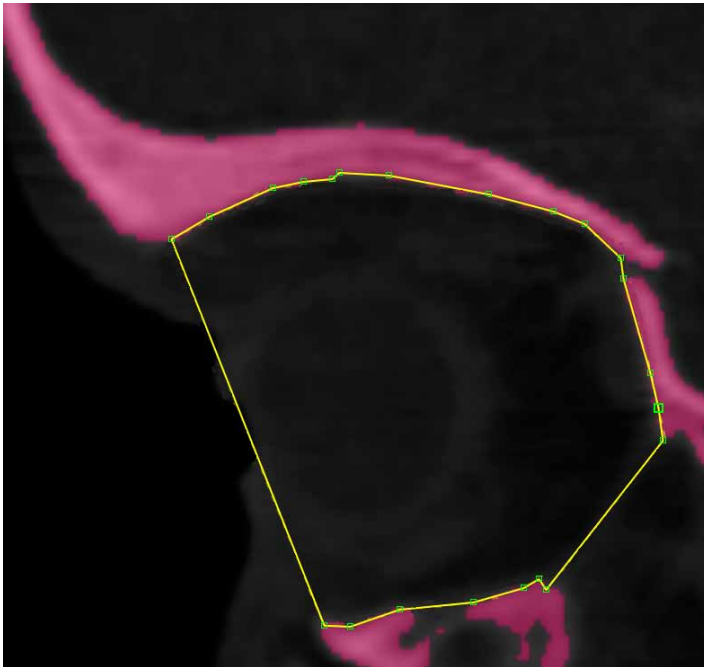


Figure 2: The anterior boundary defined as a straight line from the most antero-cranial point of the infra-orbital rim to the most antero-caudal point of the supra-orbital rim is depicted in a sagittal CT-slice. Furthermore, bony interruptions of the orbit are evident. A perpendicular straight line was manually drawn between the most nearby bony boundaries.

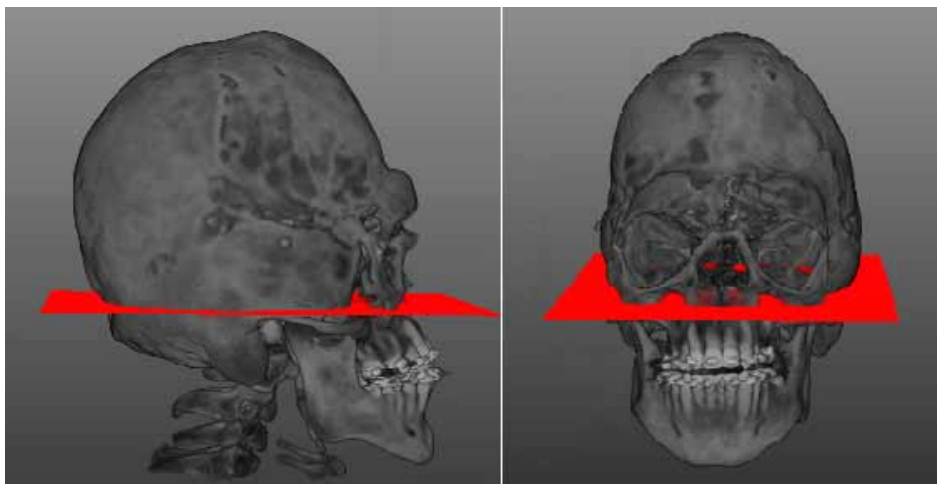


Figure 3: Three-dimensional reconstruction of the bony skull of one of the subjects in sagittal and frontal view, visualizing the horizontal plane (red) created by means of the three reference points.

Infra-orbital rim and globe movement

The same software program was used to measure infra-orbital rim and globe movement. In order to be able to quantify the movement of structures independent of the position of the patient in the CT-scan, three reference planes were defined in the pre-treatment scan. First a horizontal plane (**figure 3**) was defined using the most lateral points of the left and right LSCC and the most anterior point of the right LSCC as reference points (**figure 4**). The transverse plane was defined by the left and right LSCC and oriented perpendicular to the horizontal plane. The sagittal plane was oriented perpendicular to the horizontal and transverse plane. By translating the planes to the centre of S a coordinate system was created in which S was defined to be (0,0,0) expressed in x,y and z coordinates.

By precisely superimposing the postoperative scan on the preoperative scan in sagittal, transverse and axial orientations, the best match was found and saved (**figure 5**). The reference planes defined in the pre-treatment scans were used in the post-treatment scans. To be able to compare the movement of the infra-orbital rim and globe pre- and post-treatment, two landmarks were defined in each orbit: the most anterior point of the infra-orbital rim and the centre of the eye-globe. By comparing the x-, y- and z-coordinates of these points pre- and post-operatively, the movement of these landmarks in three dimensions could be analyzed.

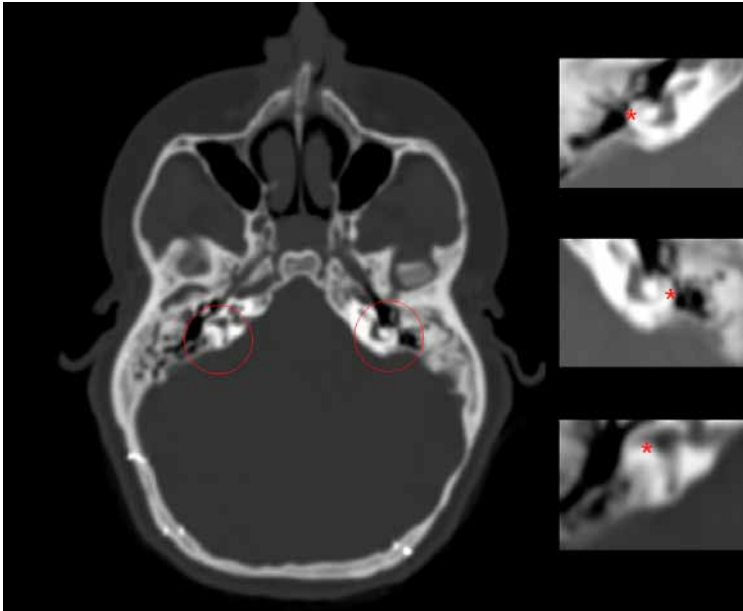


Figure 4: Axial slice of one of the patients in which the anatomical localization of the lateral semi-circular canals (LSCC) is visualized (red circles). In the depicted slice, only the left LSCC can be fully visualised; the right LSCC is only partially visible. A detailed view of the right LSCC is depicted on the right in the uppermost figure. In the middle figure the left LSCC is detailed. The red asterisks in these figures represent the most lateral points of the LSCC. In the bottom figure the most anterior part of the right LSCC is detailed (red asterisk).

To evaluate the influence of LF III advancement on the orbital volume, the infra-orbital rim and the anterior movements of the globe were compared pre- and postoperatively.

All measurements were performed by one observer. To determine the reproducibility of our analysis method, a second observer independently performed all measurements in five randomly selected patients of the study group.

Statistical analysis

SPSS for Windows XP (Version 15.0, SPSS Inc., Chicago, USA) was used to analyze the data. With the ICC the inter-observer reliability was calculated. The pre- and post-operative CT data were analyzed by means of the paired samples t-test. A p-value < 0.05 (two-tailed) was considered to be statistically significant. A correlative statistical analysis using Spearman's correlation coefficient (r_s) was performed for the orbital volume gain and anterior infra-orbital rim movement.

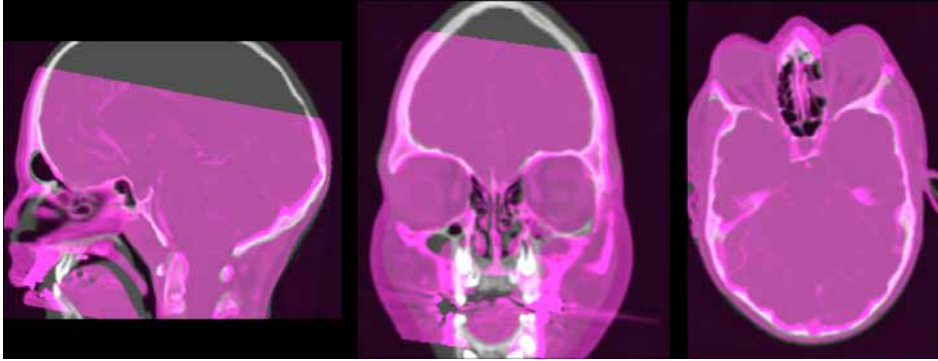


Figure 5: Example of a CT-scan of one of the subjects in sagittal, transverse and axial view. In grey the preoperative scan is visualized; in pink the postoperative scan is depicted. Manually, the postoperative scan was superimposed on the preoperative scan. The best match was found and saved and used for analysis.

RESULTS

Reliability

The inter-observer agreement with respect to the orbital volume measurements was evident (ICC 0.9). Also for the globe and infra-orbital rim movement the inter-observer agreements were evident; the ICC ranged from 0.86 to 0.98.

Patients

An overview of patient data is provided in **table 1**. Of a total of 27 patients operated between 2003 and 2009, eighteen SCS patients were included (nine females and nine males) with Crouzon (four females, five males), Apert (five females, two males) and Pfeiffer syndrome (two males). Absolute indications for LF III advancement in this study-group were: OSAS (four patients) and threatened eye (four patients). All eighteen patients had relative indications due to severe midfacial hypoplasia and associated class III malocclusion. Seventeen patients underwent LF III DO with external (fifteen patients) or internal distractors (two patients). One patient underwent a conventional LF III osteotomy. The average age at time of LF III advancement was 14.7 years (sd 4.7 years). The average time interval between LF III advancement and the preoperative CT-scan was 7.8 months (sd 7.7 months). Postoperatively, this time-interval was 7.2 months (sd 4.8 months).

Table 1: Patient data.

Patient number	Sex	Syndrome	Indication	Intervention	Age at time of surgery (years)
1	male	Apert	OSAS	LF III external DO	16.0
2	female	Apert	Midface hypoplasia	LF III external DO	20.1
3	female	Apert	Midface hypoplasia	LF III external DO	15.1
4	male	Apert	Exorbitism	LF III external DO	18.3
5	female	Apert	Midface hypoplasia	LF III external DO	19.2
6	female	Apert	Midface hypoplasia	Conventional LF III	24.3
7	female	Apert	Midface hypoplasia	LF III external DO	13.8
8	female	Crouzon	Exorbitism	LF III external DO	16.8
9	female	Crouzon	OSAS	LF III internal DO	16.3
10	male	Crouzon	OSAS	LF III external DO	13.4
11	male	Crouzon	Midface hypoplasia	LF III external DO	13.6
12	male	Crouzon	Exorbitism	LF III external DO	8.2
13	female	Crouzon	Midface hypoplasia	LF III external DO	18.8
14	female	Crouzon	OSAS	LF III external DO	9.5
15	male	Crouzon	Midface hypoplasia	LF III external DO	10.6
16	male	Crouzon	Midface hypoplasia	LF III internal DO	8.9
17	male	Pfeiffer	Midface hypoplasia	LF III external DO	14.1
18	male	Pfeiffer	Exorbitism	LF III external DO	7.4

Orbital volume

The average preoperative orbital volume was 25.7 cm³ (sd 3.0) and postoperative 32.6 cm³ (sd 4.4) for the left orbit. The average orbital volume was 25.5 cm³ (sd 2.7) preoperatively and 32.6 cm³ (sd 3.6) postoperatively for the right orbit. After LF III advancement, the orbital volume increased significantly ($p < 0.001$) with 27.2 % for the left orbit and 28.4 % for the right orbit. There was no statistically significant difference between the preoperative ($p = 0.56$) and postoperative left and right orbital volume ($p = 0.955$).

Infra-orbital rim and globe movement

Data are summarized in **table 2**. On both sides, the anterior ($p < 0.001$) and the medial movement (left, $p=0.031$; right $p=0.014$) of the infra-orbital rim was statistically significant. For the globes, only the medial movement was statistically significant (left, $p= 0.005$; right, $p = 0.004$). There were no statistically significant differences between the left and right globe measurements and left and right infra-orbital rim

Table 2: Globe and infra-orbital rim movement in the study group.

	Medial movement mean (sd) in mm	Anterior movement mean (sd) in mm	Caudal movement mean (sd) in mm
Left Globe	1.7* (2.2)	0.6 (1.8)	0.8 (3.0)
Right Globe	1.5* (1.9)	0.8 (2.5)	1.0*(2.2)
Left Rim	1.5* (2.8)	12.0* (4.2)	0.5 (5.2)
Right Rim	1.6* (2.5)	12.8* (4.9)	0.7 (3.8)

Significant movements were marked with an asterisk (*). Mean and sd are depicted.

movement ($p > 0.05$). A significant difference between the pre- and postoperative anterior position of the globe and infra-orbital rim was demonstrated (**figure 6**).

Correlation between orbital volume and globe movement

There was a statistically significant correlation between the anterior infra-orbital rim movement and the orbital volume gain (left: $r_s = 0.498$ and $p = 0.035$; right: $r_s = 0.642$ and $p = 0.018$).

DISCUSSION

Orbital volume measurements are frequently reported with regard to enophthalmus and orbital trauma. Since 1985 different orbital volume measuring techniques are being described using 3D CT imaging.^{2-4, 8, 11, 13, 15, 18, 22} In a number of studies, the strong correlation of these measurements with skull measurements is shown.^{1, 8, 10} Although accurate, these methods require much time and expertise and the techniques are based on estimation.^{8, 10, 15} Since the anatomical boundaries of the bony orbit are complex, manual segmentation of data-sets is necessary. Moreover since the intrinsic anatomy of the orbit is distorted due to syndromic factors and previous surgical intervention, assumptions need to be made about the anatomical boundaries by the observer. Therefore the anterior boundary of the orbits needs to be defined. Where some studies defined the anterior limit by a line joining the zygomaticofrontal processes^{6, 25}, we choose to define the anterior boundary of the bony orbit as a straight line from the most antero-cranial point of the infra-orbital rim to the most antero-caudal point of the supra-orbital rim in every (sagittal) CT-slice. Strict definitions were formulated concerning bony interruptions of the orbit. The ICC of our measurements showed that the chosen method was highly reproducible.

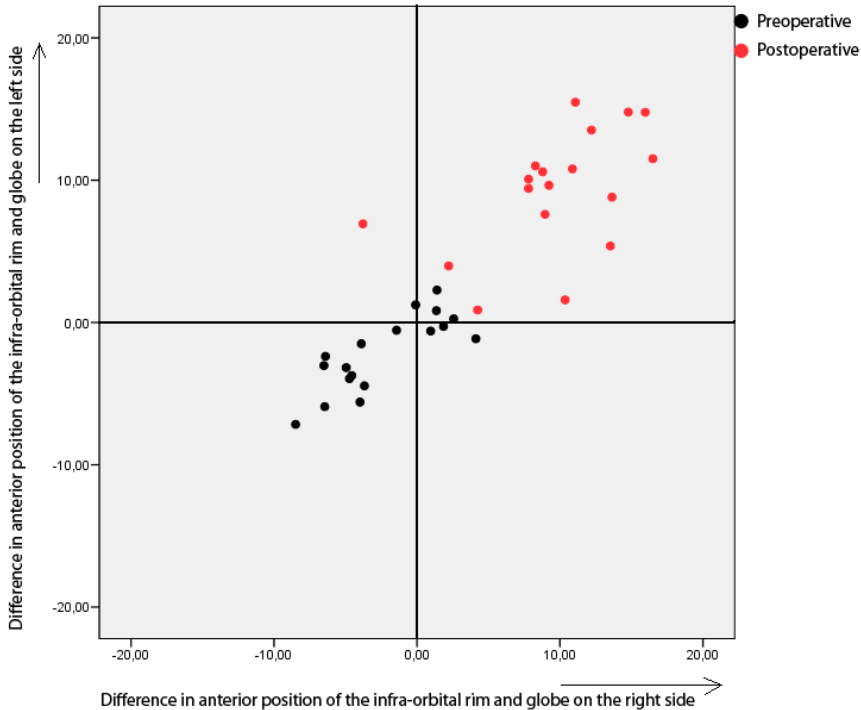


Figure 6: Scatter plot representing the difference in the anterior position of the infra-orbital rim and globe on the right side (x-axis) and the difference in the anterior position of the infra-orbital rim and globe on the left side (y-axis). The black dots represent the preoperative data and the red dots represent the postoperative data. Statistical analysis showed a significant difference between the pre- and postoperative position of the infra-orbital rim and globe.

To the best of our knowledge, orbital volume changes after LF III advancement have not yet been evaluated in SCS patients. Bentley et al. investigated orbital volume changes of SCS patients not older than 36 months after fronto-orbital advancement, using semi-automatic segmentation comparable to our technique.² Numerous studies have reported a wide range of normal values of orbital volumes, which ranged from 21 ml to 30 ml; on average orbital volumes tend to be somewhat higher in males than in females.^{10, 13, 15, 16, 18, 22} Consistent with the findings of Bentley et al., normal orbital volumes were found in the present study preoperatively. After LF III advancement a significant orbital volume gain was found of 27.8 percent. Considering the above findings, the infra-orbital rim and globe movements were analyzed. Several studies measured globe position in healthy persons, SCS patients, Graves patients or patients with ophthalmic problems.^{7, 17, 21, 23} In these studies,

generally, a line was drawn between the most anterior points of the lateral orbital rims, using an axial CT-slice at midglobe level. To determine globe position, the perpendicular distance from the inter-zygomatic line to the posterior margin of the globe was measured pre- and postoperatively. Imaginably, some miscalculations are likely to occur as this two-dimensional method does not account for differences in head position. Besides this, the lateral orbital rim in SCS patients is osteotomized during LF III advancement and therefore not suitable as a reference point.

We developed a 3D method to be able to evaluate globe and infra-orbital rim position in three dimensions. The LSCCs were chosen to be used to create a horizontal plane in VO with a reliable reproducibility. The LSCC of the inner ear has a constant relation to gravity and is unaffected by abnormal or asymmetric growth and disease.²⁴ In skulls of SCS patients, the horizontal plane in VO provides a complete set of three-dimensional directions. This VO allows precise measurements using 3D CT-scans in SCS patients with an asymmetric skull-shape and anatomical anomalies of the skull base which renders standard landmarks and reference lines unsuitable. To compare the outcomes of the infra-orbital rim and globe movements between patients irrespective of the position of the head in the CT-scanner, three reference planes were created. To the best of our knowledge, there have been no other reports concerning the evaluation of infra-orbital rim and globe position after LF III advancement using a 3D-CT method. One study observed the globe movement in SCS patients after MB advancement. Fitzgerald et al. measured globe movement by using several anatomical landmarks and a reference frame. However, the construction of the reference frame from the landmarks is not clear, and therefore the results are difficult to interpret. Fitzgerald et al. reported a forward movement of the osseous structures and both globes.¹² We found a statistically significant anterior and medial movement of the infra-orbital rim, whereas the globe remained almost in the same position despite a slight medial movement. Both in our study and in the study of Fitzgerald et al., no clinical evaluation of the eye was performed. Considering the significant anterior movement of the globe as observed by Fitzgerald et al., it is evident the optical nerve is stretched in a non-physiological manner. To evaluate the influence of LF III advancement on the shallow orbits, a significant positive correlation between the orbital volume gain and anterior movement of the infra-orbital rim was observed. Furthermore, a significant difference between the pre- and postoperative anterior position of the infra-orbital rim and globe was demonstrated, as illustrated in **figure 6**. Preoperatively, the globe is situated anterior

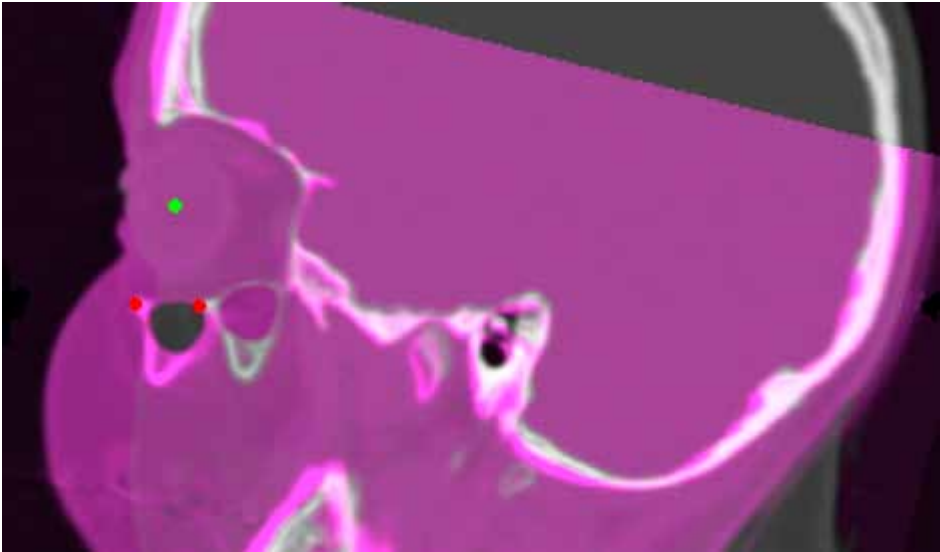


Figure 7: Sagittal slice of the CT-scan of one of the subjects. Both the pre- (gray colored) and post-operative (pink colored) CT-scans are depicted. The red dots mark the most anterior point of the infra-orbital rim pre- and postoperatively. The green dot marks the centre of the globe.

of the infra-orbital rim while postoperatively the globe is situated posterior of the infra-orbital rim (**figure 7**). Together, these results provide insight into the effect of LF III advancement on the increase of orbital volume following LF III advancement. The method used gives a realistic insight into the orbital changes after LF III advancement. However, thinner CT-slices may enhance accuracy. Furthermore, the standard treatment protocol should include a pre-and postoperative CT-scan at a fixed/standardized time-interval. In this respect, superimposition of pre- and postoperative CT-scans will be more accurate when there is less growth in between the pre-and postoperative CT-scan. Future research will focus on 3D visualization and quantification of the changes after LF III advancement on both skeletal and soft tissue level. The reported reference frame may be useful as a tool for preoperative planning and post-operative evaluation of the degree of LF III advancement.

Conclusion

This study demonstrates a significant orbital volume gain and anterior movement of the infra-orbital rim following LF III advancement. The position of the globe was relatively unchanged.

REFERENCES

1. Acer N, Sahin B, Ergur H, Basaloglu H, Ceri NG. Stereological estimation of the orbital volume: a criterion standard study. *J Craniofac Surg* 2009; 20: 921-925.
2. Bentley RP, Sgouros S, Natarajan K, Dover MS, Hockley AD. Changes in orbital volume during childhood in cases of craniosynostosis. *J Neurosurg* 2002; 96: 747-754.
3. Bite U, Jackson IT, Forbes GS, Gehring DG. Orbital volume measurements in enophthalmos using three-dimensional CT imaging. *Plast Reconstr Surg* 1985; 75: 502-508.
4. Carr M, Posnick JC, Pron G, Armstrong D. Cranio-orbito-zygomatic measurements from standard CT scans in unoperated Crouzon and Apert infants: comparison with normal controls. *Cleft Palate Craniofac J* 1992; 29: 129-136.
5. Cedars MG, Linck DL, 2nd, Chin M, Toth BA. Advancement of the midface using distraction techniques. *Plast Reconstr Surg* 1999; 103: 429-441.
6. Charteris DG, Chan CH, Whitehouse RW, Noble JL. Orbital volume measurement in the management of pure blowout fractures of the orbital floor. *Br J Ophthalmol* 1993; 77: 100-102.
7. Chen YS, Tsai TH, Wu ML, Chang KC, Lin TW. Evaluation of age-related intraorbital fat herniation through computed tomography. *Plast Reconstr Surg* 2008; 122: 1191-1198.
8. Cooper WC. A method for volume determination of the orbit and its contents by high resolution axial tomography and quantitative digital image analysis. *Trans Am Ophthalmol Soc* 1985; 83: 546-609.
9. Cruz AA, Akaishi PM, Arnaud E, Marchac D, Renier D. Exorbitism correction of faciocraniosynostoses by monobloc frontofacial advancement with distraction osteogenesis. *J Craniofac Surg* 2007; 18: 355-360.
10. Devenci M, Ozturk S, Sengezer M, Pabuscu Y. Measurement of orbital volume by a 3-dimensional software program: an experimental study. *J Oral Maxillofac Surg* 2000; 58: 645-648.
11. Fan X, Li J, Zhu J, Li H, Zhang D. Computer-assisted orbital volume measurement in the surgical correction of late enophthalmos caused by blowout fractures. *Ophthal Plast Reconstr Surg* 2003; 19: 207-211.
12. Fitzgerald O'Connor EJ, Marucci DD, Jeelani NO, Witherow H, Richards R, Dunaway DJ, Hayward RD. Ocular advancement in monobloc distraction. *Plast Reconstr Surg* 2009; 123: 1570-1577.
13. Furuta M. Measurement of orbital volume by computed tomography: especially on the growth of the orbit. *Jpn J Ophthalmol* 2001; 45: 600-606.
14. Khong JJ, Anderson P, Gray TL, Hammerton M, Selva D, David D. Ophthalmic findings in Apert's syndrome after craniofacial surgery: twenty-nine years' experience. *Ophthalmology* 2006; 113: 347-352.
15. Koppel DA, Foy RH, McCaul JA, Logan J, Hadley DM, Ayoub A. The reliability of "Analyze" software in measuring orbital volume utilizing CT-derived data. *J Craniomaxillofac Surg* 2003; 31: 88-91.
16. Kwon J, Barrera JE, Most SP. Comparative computation of orbital volume from axial and coronal CT using three-dimensional image analysis. *Ophthal Plast Reconstr Surg*; 26: 26-29.
17. Lee JS, Lim DW, Lee SH, Oum BS, Kim HJ, Lee HJ. Normative measurements of Korean orbital structures revealed by computerized tomography. *Acta ophthalmologica Scandinavica* 2001; 79: 197-200.

18. Manson PN, Grivas A, Rosenbaum A, Vannier M, Zinreich J, Iliff N. Studies on enophthalmos: II. The measurement of orbital injuries and their treatment by quantitative computed tomography. *Plast Reconstr Surg* 1986; 77: 203-214.
19. Marchac D, Renier D, Broumand S. Timing of treatment for craniosynostosis and facio-craniosynostosis: a 20-year experience. *British journal of plastic surgery* 1994; 47: 211-222.
20. Ortiz-Monasterio F, del Campo AF, Carrillo A. Advancement of the orbits and the midface in one piece, combined with frontal repositioning, for the correction of Crouzon's deformities. *Plast Reconstr Surg* 1978; 61: 507-516.
21. Ozgen A, Ariyurek M. Normative measurements of orbital structures using CT. *Ajr* 1998; 170: 1093-1096.
22. Schuknecht B, Carls F, Valavanis A, Sailer HF. CT assessment of orbital volume in late post-traumatic enophthalmos. *Neuroradiology* 1996; 38: 470-475.
23. Sheikh M, Abalkhail S, Doi SA, Al-Shoumer KA. Normal measurement of orbital structures: implications for the assessment of Graves' ophthalmopathy. *Australasian radiology* 2007; 51: 253-256.
24. Vinchon M, Pellerin P, Pertuzon B, Fenart R, Dhellemmes P. Vestibular orientation for craniofacial surgery: application to the management of unicoronal synostosis. *Childs Nerv Syst* 2007; 23: 1403-1409.
25. Whitehouse RW, Batterbury M, Jackson A, Noble JL. Prediction of enophthalmos by computed tomography after 'blow out' orbital fracture. *Br J Ophthalmol* 1994; 78: 618-620.

Chapter 3

Three dimensional airway changes after Le Fort III advancement in syndromic craniosynostosis patients

E. Nout¹

F.P. Bouw¹

J.F. Veenland^{2,3}

W.C.J. Hop⁴

K.G.H. van der Wal¹

I.M.J. Mathijssen⁵

E.B. Wolvius¹

¹Department of Oral and Maxillofacial Surgery - Erasmus University
Medical Centre Rotterdam, The Netherlands

²Department of Medical Informatics - Faculty of Medicine, Erasmus
University Medical Centre Rotterdam, The Netherlands

³Department of Radiology – Erasmus University Medical Centre
Rotterdam, The Netherlands

⁴Department of Biostatistics – Faculty of Medicine, Erasmus
University Medical Centre Rotterdam, The Netherlands

⁵Department of Plastic and Reconstructive Surgery - Erasmus
University Medical Centre Rotterdam, The Netherlands

Published

Plast Reconstr Surg. 2010 Aug;126(2):564-71

ABSTRACT

Background

To investigate the changes of upper airway volume in SCS patients following LF III advancement, CT-scans were analyzed and related to the amount of advancement.

Methods

In this retrospective study, the preoperative and postoperative CT scans of nineteen patients with SCS who underwent LF III advancement were analyzed. In four cases, preoperative PSG demonstrated OSAS. The airway was segmented using a semi-automatic region growing method with a fixed Hounsfield threshold value. Airway volumes of hypopharynx and oropharynx (compartment A) and nasopharynx and nasal cavity (compartment B) were analyzed separately, as was the total airway volume. Advancement of the midface was recorded using lateral skull radiographs. Data were analyzed for all patients together and for patients with Crouzon/Pfeiffer and Apert syndromes separately.

Results

Airway volume increased significantly in compartment A (20 %; $p = 0.044$) and compartment B (48 %; $p < 0.001$), as did total airway volume (37 %; $p < 0.001$) in the total study group. No significant differences in volume changes were found comparing Apert with Crouzon/Pfeiffer patients. No distinct relation could be found between advancement of the midface and volume gain in both the total study group and in Apert and Crouzon/Pfeiffer patient groups separately. Postoperative PSG showed significant improvement of OSAS in all 4 patients.

Conclusions

A significant improvement of the upper airway after LF III advancement in SCS patients is demonstrated. No distinct relation could be observed between advancement and airway volume changes.

INTRODUCTION

Midface hypoplasia is an important 3D skeletal defect that is commonly seen in patients with SCS, such as Crouzon, Apert and Pfeiffer syndrome. This midface hypoplasia may give rise to OSAS, ocular proptosis, and class III malocclusion including a transverse maxillary hypoplasia and esthetic facial disharmony. In addition, there is strong evidence for an association between OSAS and raised ICP in these SCS patients.¹⁹ Although the primary aim of the midface advancement for SCS patients with OSAS is to increase airway patency, it remains unclear to what extent the LF III advancement increases the airway volume on the nasopharyngeal, oropharyngeal and hypopharyngeal levels.

Traditionally, in nonsyndromic orthognathic patients airway volume measurements were conducted using plain lateral skull radiographs.^{1, 6-9, 13, 15, 20} By identifying anatomical landmarks, distances were calculated and used to describe pharyngeal depth and posterior airway space in the antero-posterior dimension. By this means, changes in both upper and lower airway space have been investigated extensively and correlated with the outcome of OSAS measurements after orthognathic surgery.^{9, 13, 15} Using the same method, Ishii et al. reported an improvement of nasopharyngeal airway volume after LF III advancement in SCS patients.¹⁰ Commensurable results were obtained by Flores et al., who found a significant increase in nasopharyngeal and velopharyngeal airway after LF III DO.⁵ Recently, Degerliyurt et al. and Fairburn et al. have used both sagittal and transverse slices of CT-scans to enhance accuracy in non-syndromic patients.²⁻⁴ With the progression of digital postprocessing techniques, 3D segmentation of the airway has become possible, enhancing accuracy even further.²²

The purpose of the current study was to evaluate the changes of airway volume in SCS patients after LF III advancement by analyzing preoperative and postoperative CT-scans with an airway volume segmentation technique. Additionally, preoperative and postoperative cephalograms of all these patients were analyzed to evaluate a possible correlation between the amount of horizontal and vertical advancement and the changes of the upper airway volume.

MATERIALS AND METHODS

Patients

In this retrospective study, nineteen patients were reviewed (ten female patients and nine male patients) with Apert syndrome (five female patients and two male patients), Crouzon syndrome (six female patients and three male patients), and Pfeiffer syndrome (three male patients). Because of genetic similarity between Crouzon and Pfeiffer patients, we chose to consider these patients with proven non-Apert FGFR2 mutations as one entity and refer to these patients as Crouzon/Pfeiffer. Indications for LF III osteotomy in this study-group were OSAS (four patients: two moderate OSAS and two severe OSAS based on preoperative PSG), exorbitism (four patients) and class III malocclusion (all patients). Patients were included when both preoperative and postoperative CT-scans (after completion of distraction and consolidation period) and lateral skull radiographs were available. Patients who required endotracheal intubation during the scanning process were excluded. Between 2003 and 2008, eighteen patients underwent LF III DO with external (sixteen patients) or internal distractors (two patients), and one patient underwent a conventional LF III osteotomy. The average age at time of surgery was 14.6 years (sd 4.3 years). Postoperatively, all patients were seen in an outpatient clinic on a weekly basis.

LF III distraction protocol

A latency period of seven days postoperatively was applied to all patients irrespective of age or degree of advancement. Distraction rate was 1 mm/day. Distraction was continued for a varying period depending on the desired correction. Vector modifications took place during distraction when necessary. After distraction, a consolidation period of three months was respected in all patients, during which the distractors were retained.

CT scans and lateral skull radiographs

Preoperative scans were obtained on average seven months (sd 5 months) before surgery. Postoperative scans were obtained on average six months (sd 3 months) after surgery. All scans were obtained in Sophia Children's Hospital using the same scanner (Emotion 6; Siemens, Munich, Germany) with a fixed slice thickness of 1.25 mm. Sedation was indicated in some cases during scanning and depended on the patient's cooperation and age. All scans were obtained in supine position.

Preoperative lateral skull radiographs were obtained on average four months (sd 4 months) before surgery. Postoperative lateral skull radiographs were obtained on average seven months (sd 4 months) after surgery. All lateral skull radiographs were obtained in Sophia Children's Hospital in the upright position with the jaws in centric occlusion using the same calibrated device (Orthophos Plus DS; Sirona, Salzburg, Austria).

Data-analysis

The software program MevisLab (MeVis Medical Solutions AG, Bremen, Germany) was used to import and analyze the CT-scans by means of a custom-designed tool. First, by manually masking for each scan in each slice the maxillary, ethmoidal, frontal and sphenoidal sinuses and the oral cavity (posterior boundary defined by a transverse plane from the uvula to the tongue base), the inactive respiratory airways were excluded (**figure 1**). Hereafter, two compartments were marked according to predefined strict anatomical boundaries (**figure 2**). Compartment A, containing the hypopharynx and oropharynx, was defined to range from the lower part of the hyoid bone to half the length of the uvula visualized in midsagittal view. Compartment B, containing nasopharynx and nasal cavity, was defined to range cranial from compartment A to the most cranial point of the nasal cavity. Separately, both compartments were segmented using a semiautomatic region growing method with a fixed Houn-

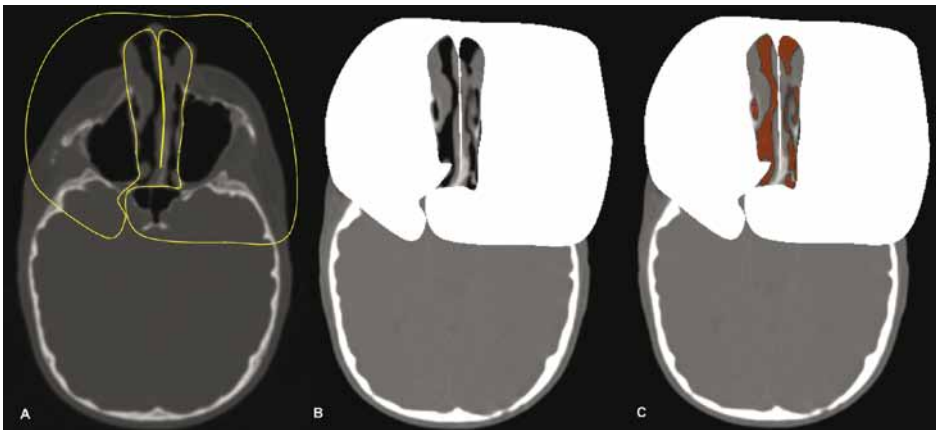


Figure 1: Example of the step-by-step exclusion of paranasal sinuses. (A) By manually creating a contour in each slice, (B) a mask can be computed. (C) By segmentation of the selected areas, indicated by placing seeding points, and use of a semiautomatic region growing method with a fixed Hounsfield threshold value, volumes can be computed for areas of interest. Exclusion of the oral cavity took place in a similar way.

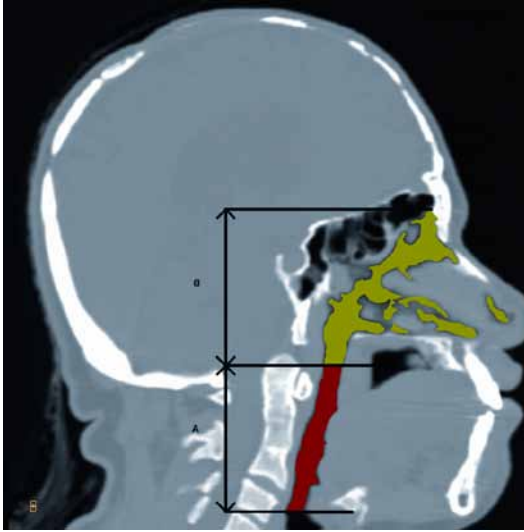


Figure 2: CT-scan in mid-sagittal view. The three lines mark the boundaries of compartments A and B. The upper line marks the most cranial point of the nasal cavity, the middle line runs half the length of the uvula, and the lower line marks the most caudal point of the hyoid bone. The part of the airway that represents compartment A is marked in red, whereas compartment B is marked in green. All paranasal sinuses and the oral cavity were excluded manually.

sfield threshold value. The same threshold was used for all datasets. The volume of the segmented compartments was computed preoperatively and postoperatively. By adding the two volumes of compartment A and B, a total volume was calculated preoperatively and postoperatively. To determine the interobserver variability of the volume measurements, a second operator performed the manual masking of ten randomly selected patients of the study group, independent of the first operator. The lateral skull radiographs were all traced by hand. On each lateral skull radiograph S, RO, Na and A were identified. By drawing a line through A parallel to the line S-Na and a line through S perpendicular to the line S-Na, an intersection was created and labeled J. To determine horizontal advancement, distance J-A was measured on preoperative and postoperative lateral skull radiographs. To determine the vertical advancement, distance S-J was measured preoperatively and postoperatively. As another parameter representing horizontal advancement, the angle between the lines S-OR and A-OR was measured preoperatively and postoperatively (**figure 3**). All lateral skull radiographs were traced independently by two operators and the average of the measurements of the operators were used for statistical evaluations. For both volume and advancement, preoperative and postoperative data were compared and differences were calculated for each patient.

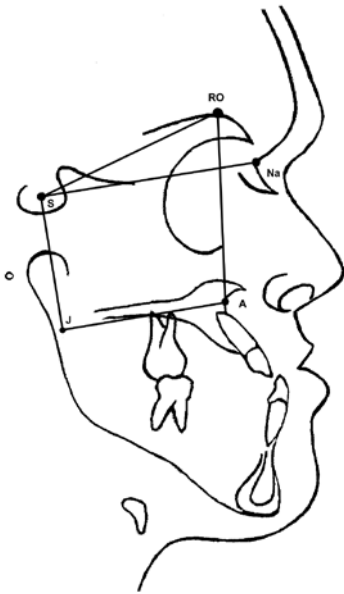


Figure 3: Cephalogram of a patient with Pfeiffer syndrome. To determine the degree of horizontal advancement the angle was measured between the lines S-RO and RO-A. Also, the horizontal and vertical movement was measured by the distance A-J and S-J, respectively.

Statistical analysis

All data were analyzed using SPSS for Windows XP (Version 15.0; SPSS, Inc., Chicago, Ill, USA). Interobserver reliability was qualified with use of the ICC. The paired t-test was used to compare the preoperative and postoperative CT data. Concerning the volumetric changes, the mean and sd were calculated for all compartments. Volumetric changes were expressed as percentages of the preoperative airway volumes. Correlation coefficients given are Spearman rank correlations (r_s). In addition, the Spearman's rank correlation coefficient was also used to evaluate the correlation between the horizontal advancement expressed as degrees and the horizontal advancement expressed as millimeters. To analyze the differences between Apert and Crouzon/Pfeiffer syndromes, independent samples t-test was conducted to evaluate differences between these two patient groups. A value of $p < 0.05$ (two-tailed) was considered to be statistically significant.

RESULTS

Patient data are summarized in **tables 1 and 2**. Interobserver agreement with respect to volume measurements was excellent (ICC > 0.99). For the cephalometric analysis

Table 1: Overview of volume changes according to compartment and patient group.

	Compartment A	Compartment B	Total Volume
Total Group	19.7 (39.5)*	47.8 (28.0)*	37.4 (20.7)*
Apert	27.2 (36.7)*	37.0 (22.5)*	31.1 (13.2)*
Crouzon/Pfeiffer	15.2 (42.0)	54.1 (29.7)*	41.1 (23.8)*

The 'compartment' columns represent the changes in postoperative volume compared to the preoperative volume expressed as a percentage. Data shown are means (sd).

* $p < 0.05$

of the lateral skull radiographs the interobserver agreement was moderate (ICC 0.65). The horizontal advancement in degrees correlated with the horizontal advancement in mm ($r_s = 0.46$, $p = 0.049$).

Total study group

Airway volume in compartment A increased with a mean of 20 % (sd 39.5 %, $p = 0.044$). Airway volume in compartment B improved with a mean of 48 % (sd 28.0 %, $p < 0.001$) and the total volume improved with a mean of 37 % (sd 20.7 %, $p < 0.001$) (figure 4).

The mean horizontal movement of the midface was 13.2 mm (sd 4.7) and 12.4 degrees (sd 5.4). The mean vertical movement was 6.7 mm (sd 4.6).

Both horizontal and vertical movement of the midface measured in mm and the volume-gain of each compartment did not reveal statistically significant correlations (all $p > 0.48$). In contrast, a significant correlation was found between the horizontal advancement of the midface measured in degrees and the volume gain of compartment B ($r_s = 0.61$, $p = 0.006$).

Postoperative PSG showed significant improvement of OSAS in all four patients, with residual mild OSAS in three and absence of breathing difficulties in one.

Table 2: Overview of advancement according to patient group.

	Degrees	A-hor	A-vert
Total Group	12.4 (5.4)	13.2 (4.7)	6.7 (4.6)
Apert	9.6 (3.4)	11.1 (4.7)	6.4 (5.9)
Crouzon/Pfeiffer	14.1 (5.7)	14.5 (4.4)	6.9 (3.7)

The 'degrees' column represents the horizontal advancement expressed in degrees. The column 'A-hor' and 'A-vert' represent the horizontal advancement and vertical advancement expressed in mm respectively. Data shown are means (sd).

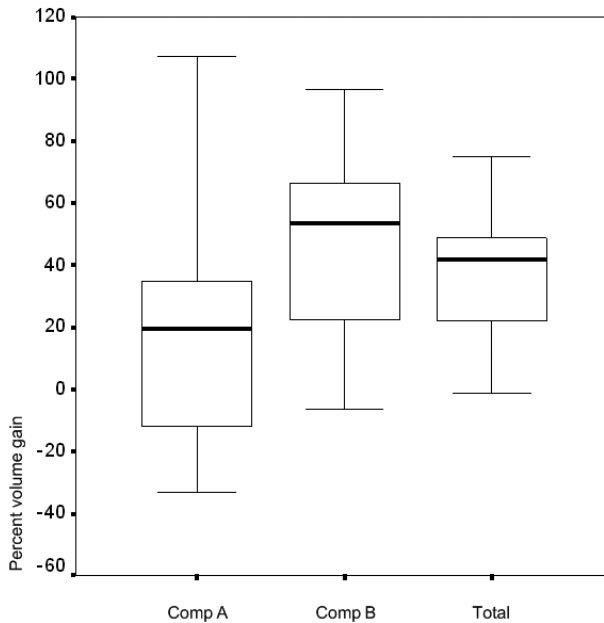


Figure 4: Box plot of the post-operative volume gains expressed as percentage of the preoperative volumes according to the three compartments in the total patient group. Minimum, maximum and median value (bold line) are visualized. The box represents the interquartile range.

Apert's and Crouzon/Pfeiffer's syndrome

In patients with Apert syndrome, for all three compartments a significant volume gain was found. On average airway volume in compartment A increased with 27 % (sd 36.7 %; $p = 0.009$), in compartment B with 37 % (sd 22.5 %; $p = 0.012$). Total volume increased with 31 % (sd 13.2 %; $p = 0.003$). In Crouzon/Pfeiffer patients, significant postoperative volume gains were restricted to compartment B (54 %; sd 29.7 %; $p = 0.002$) and total volume (41 %; sd 23.8 %; $p = 0.001$). When comparing the average volume gains between the Apert and Crouzon/Pfeiffer groups, no significant differences were found (all $p > 0.205$). When correlating the horizontal and vertical movement of the midface to the volumetric airway changes, no significant relation for patients with Apert syndrome was observed. In Crouzon/Pfeiffer patients a significant positive correlation ($r_s = 0.813$; $p = 0.001$) was found between the horizontal advancement of the midface measured in degrees and the volume gain in compartment B. In contrast, in the Crouzon/Pfeiffer subgroup no significant correlation was found with respect to volume changes and advancement of the midface expressed in mm.

DISCUSSION

Various studies on nonsyndromic patients with class III skeletal deformities have used conventional lateral cephalograms to study airway volume.^{1, 6-9, 13, 15, 20} To investigate airway volume following surgery more precisely, segmentation of the airway using CT data can be performed. An optimal threshold for the air/soft-tissue separation can be defined and used in a region growing algorithm, resulting in 3D airway volumes. Concerning maxillofacial application of airway measurement techniques, effects of bimaxillary, mandibular setback and mandibular advancement have been evaluated in syndromic and non-syndromic patients (**table 3**).^{3, 12, 17, 18}

With regard to the LF III advancement in syndromic patients, Xu et al. reported a mean increase of 64% in upper airway volume.²² In the current study, a significant volume gain of the nasopharynx and nasal cavity of 48% after LF III advancement was demonstrated (**figure 5**). Unfortunately, only the abstract of this purely Chinese

Table 3: Overview of maxillofacial application of airway measurement techniques in orthognathic surgery.

Author	Year	Patients	Evaluation	Technique	Airway Volume
Kawamata et al.	2000	13 non-syndromal patients	Mandibular setback	Measurements of changes of frontal and lateral width of the pharyngeal airway on CT scans = one dimensional	Narrowing of the pharyngeal airway
Degerliyurt et al.	2009	47 non-syndromal patients	Mandibular setback and maxillary advancement combined with mandibular setback	Measurements of areas on individual CT-slices = two-dimensional	Reduction of oro- and hypopharynx after both procedures
Rachmiel et al.	2005	12 patients with severe hypoplastic mandibles	Mandibular advancement	Quantification of airway volumes after extraction of a selected area from CT scans = three-dimensional	Increase of the upper airway volume
Perlyn et al.	2002	4 syndromal patients	Mandibular advancement	quantification of airway volumes after extraction of a selected area from CT scans = three-dimensional	Increase of the upper airway volume

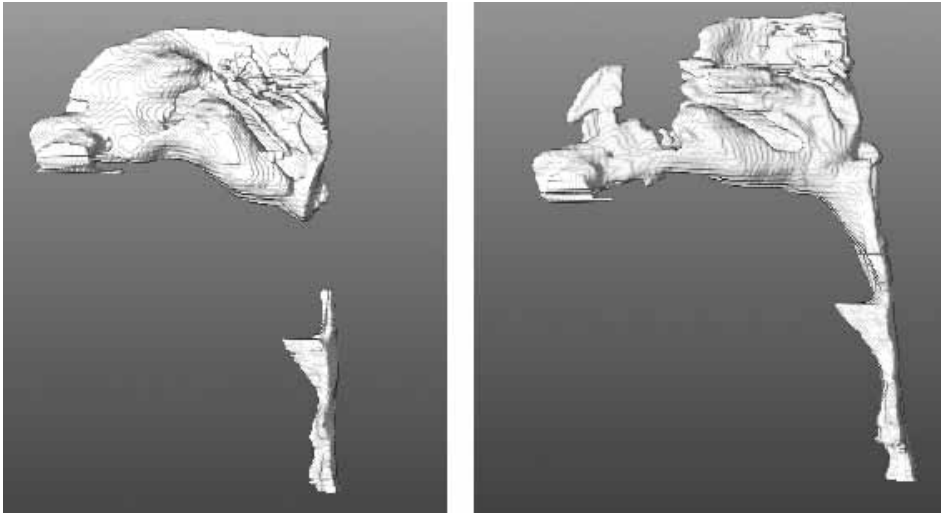


Figure 5: Example of a preoperative (left) and postoperative (right) airway segmentation of a Crouzon patient, showing evident postoperative volume gain also at the level of the oropharynx and hypopharynx following midface distraction. In this patient, a total collapse of the nasopharyngeal airway in supine position is apparent. Also the fanciful shape of the airway can be observed.

report is available in English. By segmentation of the upper airway, we calculated airway volumes of the complete upper airway. With this method, we were able to analyze the complex anatomy of the complete upper airway in a detailed way with a high reproducibility.

Kreiborg et al. conducted a comparative 3D analysis of CT-scans in Apert and Crouzon syndromes.¹⁴ In Apert syndrome, the posterior nasopharyngeal wall seemed to be more curved when compared with the relatively more vertical posterior nasopharyngeal wall in Crouzon patients. In the current study, in both patient groups, a significant overall airway-volume gain was found. However, most likely due to small patient numbers, no significant differences could be revealed between the two patient groups. Concerning the difficulties with landmark identification on cephalograms in syndromic patients, we chose to use the skull base as a control. Like Kreiborg et al., we evaluated the degree of horizontal advancement after LF III surgery by choosing reproducible, clearly identifiable landmarks.¹⁴ Because Na is mobilized during surgery, we also chose to evaluate horizontal advancement by choosing RO and S as stationary reference points. In addition, we used goniometry to verify horizontal advancement. Unfortunately, as interobserver agreement was moderate, landmark identification is difficult in SCS patients. More ideally, lateral

cephalograms might be extracted from CT-scans and 3D cephalometry could be helpful, but only applicable after validation.¹¹

In this study, the correlation between vertical movement and postoperative volume was not significant in the total group or in either subgroups. The 3D visualizations of the segmented airways showed that the shape of the upper airway was remarkably irregular (**figure 5**). This irregularity is probably associated with the complex anatomical variations of the skull base as is frequently observed in SCS patients.¹⁴ This may account for an unpredictable change of upper airway volume following midface advancement. Most likely, because of complex anatomy of the airway in these SCS patients, clearly, no 1:1 relation between advancement and increase of postoperative airway volume can be assumed. Furthermore, our measurements represent a static reflection of a dynamic environment. Midface advancement does reduce the preexisting airway obstruction in those patients with OSAS through repositioning of anatomical structures, which may be more important than pure volume increase of the airways.

The limitations of extrapolating the outcomes of the 2D measurements from lateral radiographs toward possible 3D volume changes have been discussed extensively.¹¹ The main limitation is lack of understanding and visualization of a 3D problem because of overlapping structures. In SCS patients with OSAS, a 3D visualization method would be preferred to provide insight into the complex anatomy of the airway.

A few centres have reported computer-assisted in vivo imaging, to evaluate the effect of therapeutic interventions on the upper airway.^{17, 18, 21, 23} These reports are more significant for their methodology than their results because of the small number of patients. Several factors may influence the outcomes. First, patients are measured twice with a certain time-period in between. In our study group the mean period between preoperative and postoperative CT-scans was 13 months. Imaginably, some growth might be responsible for a part of the increase in volume of the airway. However, an arrest of midface growth in SCS patients is likely to occur.¹⁶ Second, as the airway is covered by a lining mucosa and submucosa, the thickness of this mucosa and submucosa may vary depending on the health state of the patient. Third, the manual segmentation process of excluding inactive air-holding cavities can lead to a certain interobserver and intraobserver variability, although analysis of the interobserver variability revealed that the method we used was highly reproducible. However, we advocate standardization of CT-scanning

preoperatively and postoperatively with regard to position of the head and health state of the upper airway thereby minimizing measurement errors.

Currently, research is underway to link the outcome of the volume measurements to the results of PSG. Although preliminary, improvement of the OSAS in four patients indicates that a positive influence following midface advancement is expected. By implementing the volume measurements in the treatment protocol, we hope to gain more insight into the pathophysiology of OSAS and contribute to the evolution of treatment options.

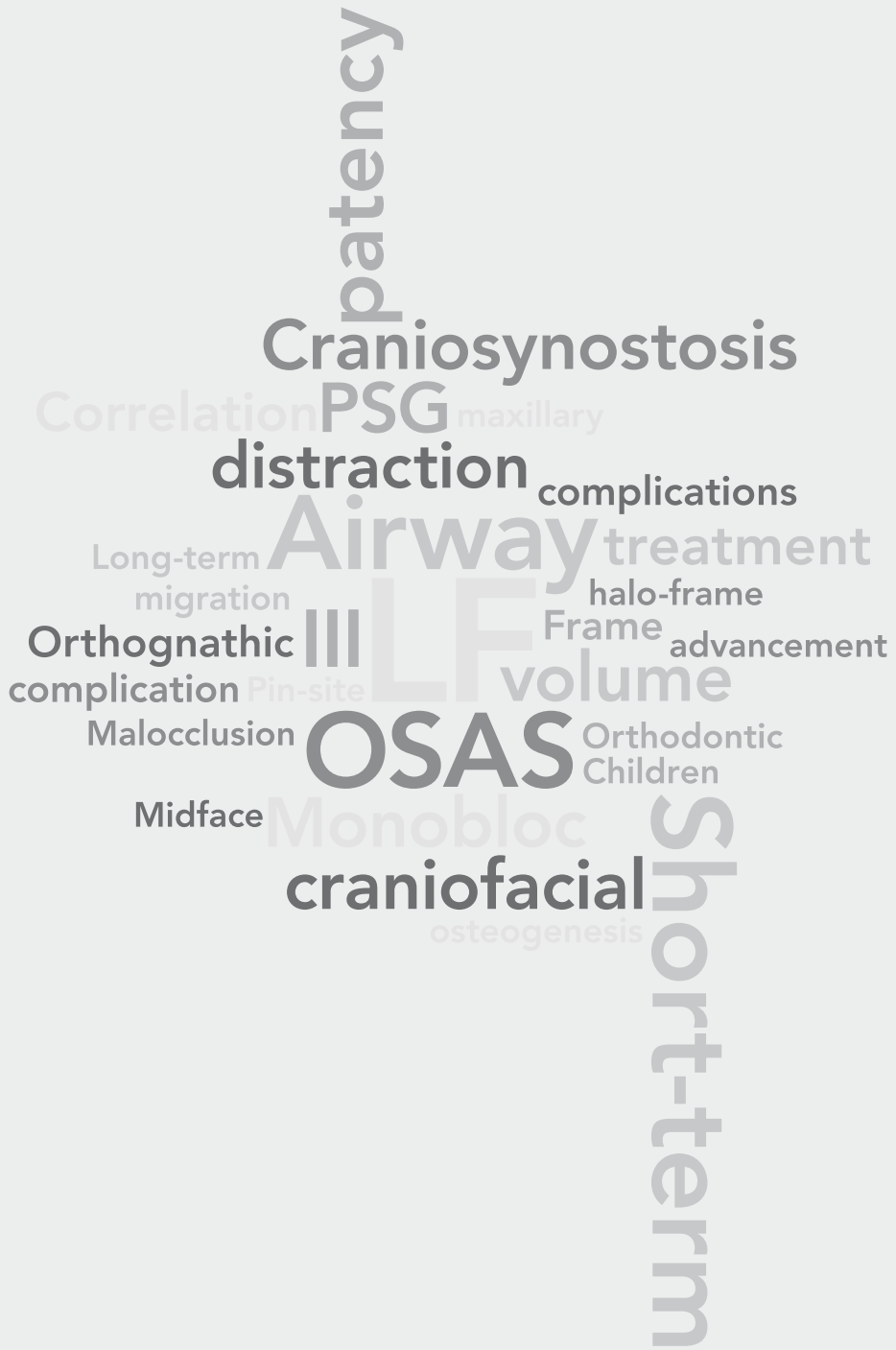
Conclusions

A significant improvement of the upper airway after LF III advancement in SCS patients is demonstrated at the level of nasopharynx/nasal cavity and also, to a lesser extent, on the level of oro-/hypopharynx. No distinct relationship could be observed between advancement and airway volume changes. Postoperative PSG showed significant improvement of OSAS in all four patients. Further software development of postprocessing of digital medical imaging data, including 3D cephalometry, together with uniform protocols, probably will improve the CT volume measurements. This might further unravel the impact of LF III advancement on airway volume and finally the outcomes of the OSAS studies.

REFERENCES

1. Chen F, Terada K, Hua Y, Saito I. Effects of bimaxillary surgery and mandibular setback surgery on pharyngeal airway measurements in patients with Class III skeletal deformities. *Am J Orthod Dentofacial Orthop* 2007; 131: 372-377.
2. Degerliyurt K, Ueki K, Hashiba Y, Marukawa K, Nakagawa K, Yamamoto E. A comparative CT evaluation of pharyngeal airway changes in class III patients receiving bimaxillary surgery or mandibular setback surgery. *Oral Surg Oral Med Oral Pathol Oral Radiol Endod* 2008; 105: 495-502.
3. Degerliyurt K, Ueki K, Hashiba Y, Marukawa K, Simsek B, Okabe K, Nakagawa K, Yamamoto E. The effect of mandibular setback or two-jaws surgery on pharyngeal airway among different genders. *Int J Oral Maxillofac Surg* 2009; 38: 647-652.
4. Fairburn SC, Waite PD, Vilos G, Harding SM, Bernreuter W, Cure J, Cherala S. Three-dimensional changes in upper airways of patients with obstructive sleep apnea following maxillomandibular advancement. *J Oral Maxillofac Surg* 2007; 65: 6-12.
5. Flores RL, Shetye PR, Zeitler D, Bernstein J, Wang E, Grayson BH, McCarthy JG. Airway changes following Le Fort III distraction osteogenesis for syndromic craniosynostosis: a clinical and cephalometric study. *Plast Reconstr Surg* 2009; 124: 590-601.
6. Goncalves JR, Buschang PH, Goncalves DG, Wolford LM. Postsurgical stability of oropharyngeal airway changes following counter-clockwise maxillo-mandibular advancement surgery. *J Oral Maxillofac Surg* 2006; 64: 755-762.
7. Greco JM, Froberg U, Van Sickels JE. Long-term airway space changes after mandibular setback using bilateral sagittal split osteotomy. *Int J Oral Maxillofac Surg* 1990; 19: 103-105.
8. Guven O, Saracoglu U. Changes in pharyngeal airway space and hyoid bone positions after body osteotomies and sagittal split ramus osteotomies. *J Craniofac Surg* 2005; 16: 23-30.
9. Hochban W, Schurmann R, Brandenburg U, Conradt R. Mandibular setback for surgical correction of mandibular hyperplasia--does it provoke sleep-related breathing disorders? *Int J Oral Maxillofac Surg* 1996; 25: 333-338.
10. Ishii K, Kaloust S, Ousterhout DK, Vargervik K. Airway changes after Le Fort III osteotomy in craniosynostosis syndromes. *J Craniofac Surg* 1996; 7: 363-370; discussion P-371.
11. Kamiishi H, Miyasato Y, Kosaka M. Development of the 3D-cephalogram: a technical note. *J Craniomaxillofac Surg* 2007; 35: 258-260.
12. Kawamata A, Fujishita M, Arijii Y, Arijii E. Three-dimensional computed tomographic evaluation of morphologic airway changes after mandibular setback osteotomy for prognathism. *Oral Surg Oral Med Oral Pathol Oral Radiol Endod* 2000; 89: 278-287.
13. Kitagawara K, Kobayashi T, Goto H, Yokobayashi T, Kitamura N, Saito C. Effects of mandibular setback surgery on oropharyngeal airway and arterial oxygen saturation. *Int J Oral Maxillofac Surg* 2008; 37: 328-333.
14. Kreiborg S, Marsh JL, Cohen MM, Jr., Liversage M, Pedersen H, Skovby F, Borgesen SE, Vannier MW. Comparative three-dimensional analysis of CT-scans of the calvaria and cranial base in Apert and Crouzon syndromes. *J Craniomaxillofac Surg* 1993; 21: 181-188.
15. Li KK, Guilleminault C, Riley RW, Powell NB. Obstructive sleep apnea and maxillomandibular advancement: an assessment of airway changes using radiographic and nasopharyngoscopic examinations. *J Oral Maxillofac Surg* 2002; 60: 526-530; discussion 531.

16. Nout E, Cesteley LL, van der Wal KG, van Adrichem LN, Mathijssen IM, Wolvius EB. Advancement of the midface, from conventional Le Fort III osteotomy to Le Fort III distraction: review of the literature. *Int J Oral Maxillofac Surg* 2008; 37: 781-789.
17. Perlyn CA, Schmelzer RE, Sutera SP, Kane AA, Govier D, Marsh JL. Effect of distraction osteogenesis of the mandible on upper airway volume and resistance in children with micrognathia. *Plast Reconstr Surg* 2002; 109: 1809-1818.
18. Rachmiel A, Aizenbud D, Pillar G, Srouji S, Peled M. Bilateral mandibular distraction for patients with compromised airway analyzed by three-dimensional CT. *Int J Oral Maxillofac Surg* 2005; 34: 9-18.
19. Thompson DN, Harkness W, Jones B, Gonzalez S, Andar U, Hayward R. Subdural intracranial pressure monitoring in craniosynostosis: its role in surgical management. *Childs Nerv Syst* 1995; 11: 269-275.
20. Wenzel A, Williams S, Ritzau M. Changes in head posture and nasopharyngeal airway following surgical correction of mandibular prognathism. *Eur J Orthod* 1989; 11: 37-42.
21. Xu HS, Mu XZ, Yu ZY, Feng SZ, Han JY, Zhang DS. [Changes of different section area at different parts of upper-airway after Le Fort III osteotomy]. *Zhonghua Zheng Xing Wai Ke Za Zhi* 2008; 24: 181-183.
22. Xu HS, Mu XZ, Yu ZY, Feng SZ, Han JY, Zhang DS. [Experience of midfacial distraction osteogenesis in upper airway stenosis]. *Zhonghua Wai Ke Za Zhi* 2008; 46: 577-580.
23. Yu CC, Hsiao HD, Lee LC, Yao CM, Chen NH, Wang CJ, Chen YR. Computational fluid dynamic study on obstructive sleep apnea syndrome treated with maxillomandibular advancement. *J Craniofac Surg* 2009; 20: 426-430.



Part III

Clinical studies

Chapter 4a

Upper airway changes in syndromic craniosynostosis patients following midface or monobloc advancement: correlation between volume changes and respiratory outcome

E. Nout¹, N. Bannink², M.J. Koudstaal¹, J.F. Veenland^{3,4}, K.F.M. Joosten⁵, R.M.L. Poublon⁶, K.G.H. van der Wal¹, I.M.J. Mathijssen², E.B. Wolvius¹

¹Department of Oral and Maxillofacial Surgery - Erasmus University Medical Centre Rotterdam, Sophia's Children's Hospital, The Netherlands

²Department of Plastic and Reconstructive Surgery - Erasmus University Medical Centre Rotterdam, Sophia's Children's Hospital, The Netherlands

³Department of Medical Informatics - Faculty of Medicine, Erasmus University Medical Centre Rotterdam, The Netherlands

⁴Department of Radiology - Erasmus University Medical Centre Rotterdam, The Netherlands

⁵Department of Pediatrics – Erasmus University Medical Centre Rotterdam, Sophia's Children's Hospital, The Netherlands

⁶Department of Otorhinolaryngology and Head and Neck Surgery – Erasmus University Medical Centre Rotterdam, Sophia's Children's Hospital, The Netherlands

Submitted

J Craniomaxillofac Surg

ABSTRACT

Background

In SCS patients, respiratory insufficiency may be a pressing indication to surgically increase the patency of the upper airway by midface or MB advancement. In the present study the volume changes of the upper airway and the respiratory outcome following midface or MB advancement in SCS patients are evaluated and correlated.

Materials and Methods

CT scans of ten SCS patients who underwent LF I (one patient), III (five patients) or MB advancement (four patients), between 2003 and 2009, were analyzed. Pre- and postoperatively, the airway volume was measured using a semi-automatic region growing method. Respiratory data were correlated to the volume measurements.

Results

In nine patients the outcome of upper airway volume measurements correlated well to the respiratory outcome. Three of these patients showed a minimal airway volume gain or even volume loss, while no respiratory improvement was found. In one MB patient an evident improvement of the respiratory outcome without an evident volume gain of the upper airway was found.

Conclusions

The majority of patients with LF III advancement showed respiratory improvement, which for the greater part correlated to the results of the volume analysis. In MB patients the respiratory outcomes and volume measurements were less obvious. Pre-operative endoscopy of the upper airway is advocated to identify the level of obstruction in patients with residual OSAS.

INTRODUCTION

Patients with SCS often present with elevated ICP, OSAS, severe exorbitism, Class III malocclusion and esthetic problems. In conformance with our protocol, children with Apert, Crouzon or Pfeiffer syndrome with signs of raised ICP are primarily considered for posterior cranial vault expansion at the age of six to nine months. Patients presenting with severe OSAS and/or exorbitism, are candidates for MB or LF III advancement. The timing of midface advancement is dictated by the indication.

In SCS patients almost 50% of the cases present with OSAS.⁹ Obstruction may occur at various levels, although midface hypoplasia resulting in a distorted NPA is a common feature.^{9, 15} A positive correlation between OSAS and raised ICP has been reported.⁷ In selected cases, OSAS is considered to be an indication for midface advancement on LF I, II, and III level and MB advancement. Recent research from our group has shown that advancement of the midface on LF III level in SCS patients significantly increases the airway volume of the nasal cavity, naso-, oro- and hypopharynx.^{2, 16} The prominent increase of airway volume was detected at the level of nasal cavity and nasopharynx. Nelson et al. have shown that LF III DO reduces airway obstruction in SCS patients.¹⁴ Although the aim of midface advancement for SCS patients with OSAS is to resolve the breathing problems, it remains unclear to what extent an increase in airway volume improves the dynamics of breathing in SCS patients. In this study, 3D volumetric changes after midface and MB advancement were evaluated, by analyzing pre- and postoperative CT scans from SCS patients. Respiratory outcome was evaluated using PSG and clinical evaluation and correlated to the volumetric airway changes.

MATERIALS AND METHODS

Patients

Patients with Apert, Pfeiffer or Crouzon syndrome, who underwent midface or MB advancement between 2003 and 2009, were retrospectively identified. Patients were included in the study, when both pre- and postoperative respiratory data and CT-scans were available.

Distraction protocol

A latency period of seven days was applied in all patients. The distraction rate was one mm per day for midface advancement and 0.5 mm per day for MB advancement. Vector modifications (only possible with the external devices) were performed when necessary. A consolidation period of three months for the LF III and six months for the MB was respected.

CT-scans

All scans were made in Sophia Children's Hospital using the same scanner (Emotion 6, Siemens, Munich, Germany) with a fixed slice thickness of 1.25 mm. General anaesthesia was indicated in two cases (patient nr eight and ten) depending on the patient's cooperation and age. All scans were made in a supine position.

Data-analysis

The software program (MevisLab, MeVis Medical Solutions AG, Bremen) was used to import and analyze the CT-scans by means of a custom-designed tool. By manually masking for each scan in each slice the maxillary, ethmoidal, frontal, sphenoidal sinuses and the oral cavity (posterior boundary defined by a transverse plane from the uvula to the tongue base), the inactive respiratory airways were excluded (**figure 1**). Two compartments were marked according to predefined strict anatomical boundaries. Compartment A, containing hypopharynx and oropharynx, ranged from the lower part of the hyoid bone to halfway the length of the uvula visualised in midsagittal view. Compartment B, containing nasopharynx and nasal cavity, ranged cranial from compartment A to the most cranial point of the nasal cavity. Both compartments were segmented using a semi-automatic region growing method with a fixed Hounsfield threshold value. The volumes of the segmented compartments were computed pre- and postoperatively. By adding the two volumes A and B, a total volume was calculated pre- and postoperatively. Previous research from our group has shown that the method used was highly reproducible.¹⁶

Respiratory outcome

The respiratory outcome was assessed after evaluating the outcome of PSG together with clinical evaluation of the patient. In patients with a tracheal canula, PSG data were not recorded.

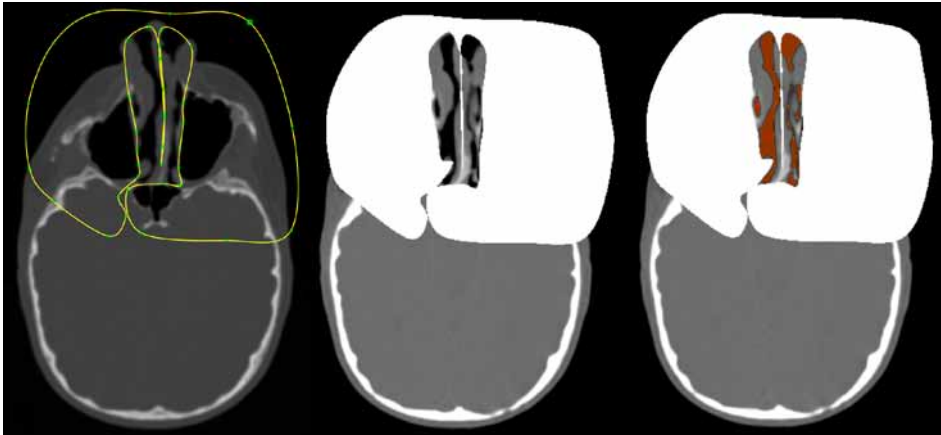


Figure 1: Example representing the step-by-step exclusion of paranasal sinuses. By manually creating a contour in each slice (left), a mask can be computed (middle). By segmentation of the selected areas, indicated by placing seeding points (right), and use of a semi-automatic region growing method with a fixed Hounsfield threshold value, volumes can be computed for areas of interest. Exclusion of the oral cavity took place in a similar way.

PSG

PSG was performed ambulatory or during admission to the hospital. In patients with a tracheostomy due to severe OSAS requiring immediate airway intervention, no PSG could be recorded. The analysis was expressed in AHI, the number of apneas (absence of airflow for more than two breaths) and hypopneas (reduction of $\geq 50\%$ in nasal flow signal amplitude) per hour and an ODI, representing the number of desaturations ($\geq 4\%$ decrease with respect to the baseline) per hour. For all indices a score < 1 is considered to be normal, between one and five is defined as mild, between six and 25 as moderate and over 25 as severe OSAS.⁸ By recording both nasal flow and thoracic movements, central apneas could be distinguished from obstructive apneas. Manual analysis of the recordings was performed to exclude central apneas.

Clinical evaluation

All patients were seen in the outpatient clinic by the multidisciplinary craniofacial team pre- and postoperatively. During the postoperative visits the effects of surgery and OSAS therapy are assessed by clinical evaluation. Based upon this evaluation, decisions are being made concerning further treatment.

RESULTS

Patient data are summarized in **table 1 and 2**. In total 27 LF III, one LF I and five MB advancements were performed during the study period of which 23 patients had insufficient data for analysis; this left ten patients to include in the study: five patients underwent LF III DO, one patient LF I DO and four patients MB DO. LF III patients were operated at an average age of 15.2 years (sd 4). Unfortunately, due to irregularities in nasal flow, in some patients AHI's could not be scored. Except for the cannulated patients, pre- and postoperative ODI's were recorded in all patients. Besides OSAS (eight patients), indications in this patient cohort for LF III advancement were severe midface hypoplasia (all patients) and exorbitism (one patient). Raised ICP was considered an indication for MB advancement. The MB patients were operated at an average age of 8.4 years (sd 10.2). The LF I patient underwent surgery at age twenty. Preoperative scans were obtained on average nine months (sd 11.5 months) before surgery. Postoperative scans were obtained on average seven months (sd 4 months) after surgery. In two patients (number eight and ten) general anaesthesia was indicated during scanning. Insufflation was performed using the present trachea-cannula. Preoperative PSGs were obtained on average 10.6 months (sd 13.4 months) before surgery. Postoperative PSGs were obtained on average 19.5 months (sd 20.3 months) after surgery. Patients one, eight and ten were diagnosed as severe OSAS because of tracheostomy-dependency.

Respiratory outcome

Six patients showed an improvement of the PSG of at least one category, in two patients the OSAS was completely resolved. Four patients showed no improvement of the PSG, of which two patients were still dependent on the tracheostomy. In three LF III patients with residual mild or moderate OSAS, a stable situation was achieved with the use of nasal glucocorticosteroid application in two (patients two and three) and without any medication in one (patient six).

Airway volume versus respiratory outcome

Increased airway volume and matching improved respiratory outcome

If upper airway volumes increased on the level of the nasopharynx and nasal cavity, a similar improvement of the PSG measurements was noted in six patients (four LF III

Table 1: Overview of the patient cohort with respect to the upper airway volume measurements.

Patient nr	Syndrome	Age at surgery (yrs)	Preoperative airway volume oro-/hypopharynx (mm ³)	Postoperative airway volume oro-/hypopharynx (mm ³)	Volume gain oro-/hypopharynx (%)	Preoperative airway volume nasal cavity and nasopharynx (mm ³)	Postoperative airway volume nasal cavity and nasopharynx (mm ³)	Volume gain nasal cavity and nasopharynx (%)	Total volume gain (%)
LF I									
1	Crouzon	19.4	6.4	7.9	23.5	35.9	33.2	-7.7	-3.0
LF III									
2	Apert	12.1	13.3	14.8	11.2	20.1	32.9	63.4	42.6
3	Apert	10.4	4.6	5.5	19.3	13.1	19.5	48.8	41.1
4	Crouzon	16.2	9.2	6.0	-34.8	19.7	20.7	5.0	-7.7
5	Crouzon	16.5	4.7	5.1	7.1	15.7	26.3	67.5	53.4
6	Crouzon	20.7	3.7	6.1	65.1	20.1	32.7	62.2	62.6
MB									
7	Apert	23.2	15.1	10.8	-28.3	20.8	38.7	91.3	41.0
*8	Apert	1.5	0.8	0.7	-18.7	1.1	1.1	0.0	-7.7
9	Crouzon	7.2	10.2	4.0	-60.7	7.2	20.2	180.0	38.9
*10	Crouzon	1.7	2.2	2.3	3.9	3.4	3.2	-3.9	-0.8

The columns with volume gains represent the postoperative volume gain or loss expressed as a percentage of the preoperative airway volume. Data marked with an asterisk represent the patients that were insufflated via the tracheal tube during scanning.

Table 2: Overview of the patient cohort with respect to PSG data.

Patient nr	Syndrome	Pre-operative canula	Pre-operative CPAP	OSAS pre-operative	ODI pre-operative	AHI pre-operative	Post-operative canula	Post-operative CPAP	OSAS post-operative	ODI post-operative	AHI post-operative
LF I											
1	Crouzon	Yes	No	severe	n.r.	n.r.	Yes	No	severe	n.r.	n.r.
LF III											
2	Apert	No	No	moderate	18	n.r.	No	No	mild	1.9	1.2
3	Apert	No	No	severe	32	40	No	No	mild	8.5	8
4	Crouzon	No	Yes	moderate/severe	25	n.r.	No	Yes	moderate	22	26
5	Crouzon	No	No	mild	1.5	0	No	No	no	0	0.5
6	Crouzon	No	Yes	severe	56	66	No	No	mild	3.3	5.5
MB											
7	Apert	No	No	moderate	13.9	8	No	No	moderate	6.5	3.2
*8	Apert	Yes	No	severe	n.r.	n.r.	Yes	No	severe	n.r.	n.r.
9	Crouzon	No	No	moderate	7	n.r.	No	No	no	0.7	0.6
*10	Crouzon	Yes	No	severe	n.r.	n.r.	No	Yes	mild	3.8	n.r.

ODI's are expressed categorical and as numeric values. AHI's are expressed as numeric values only. In case AHI's were not recorded, n.r. is depicted. Data marked with an asterisk represent the patients that were insufflated via the tracheal tube during scanning.

patients, number two, three, five, six and two MB patients, number seven and nine). In patient number seven, advancement revealed a significant volume gain on the level of nasal cavity and nasopharynx while only a slight improvement in the PSG measurements was observed. Endoscopy of the upper airway revealed a deviation of the nasal septum and an obstruction at the level of the hypopharynx. A BSSO was performed to advance the mandible and simultaneously correct the nasal septum. A postoperative PSG revealed an ODI of 0.8, while postoperative volume measurements showed an upper airway volume gain of 50.1% at the level of the hypo-/oropharynx, while at the level of the nasal cavity and oropharynx the upper airway volume remained nearly unchanged (-2.7%).

Unchanged airway volume and respiratory outcome

In three patients (one LF I patient (number one), one LF III patient (number four) and one MB patient (number eight)) the upper airway volume measurements showed only a minimal volume gain or even volume loss, while the respiratory outcome revealed no change. Patient one had a congenital tracheal stenosis with a cartilaginous sleeve which resulted in an irreversible obstruction of the upper airway for which tracheostomy was performed and a permanent tracheal canula was placed. There was persistent OSAS following MB advancement. LF I advancement was performed to achieve class I occlusion. The patient is still dependent on the tracheal canula. In patient four, who is still dependent upon CPAP after LF III, the postoperative endoscopy revealed an obstruction at the level of the hypopharynx. Patient eight was insufflated during scanning via the tracheal canula. Despite the absence of airway volume gain, an evident advancement of the midface was clinically noted after MB advancement. Pre- and postoperatively the patient is tracheostomy-dependent.

Discrepancy between airway volume and respiratory outcome

In one MB patient (patient number ten) a discrepancy was observed between the respiratory outcome and the volume measurements. In this patient, the advancement did not result in upper airway volume gain while a distinct improvement of the respiratory status was observed. Analysis of the pre- and postoperative radiographs and clinical images showed only a minimal advancement of the MB segment in this patient. Postoperative decannulation caused nocturnal deoxygenations to around 90 %; it was decided to start CPAP. Despite nocturnal CPAP, moderate OSAS persisted. Naso- and hypopharyngeal endoscopy revealed a narrow pharynx. To widen

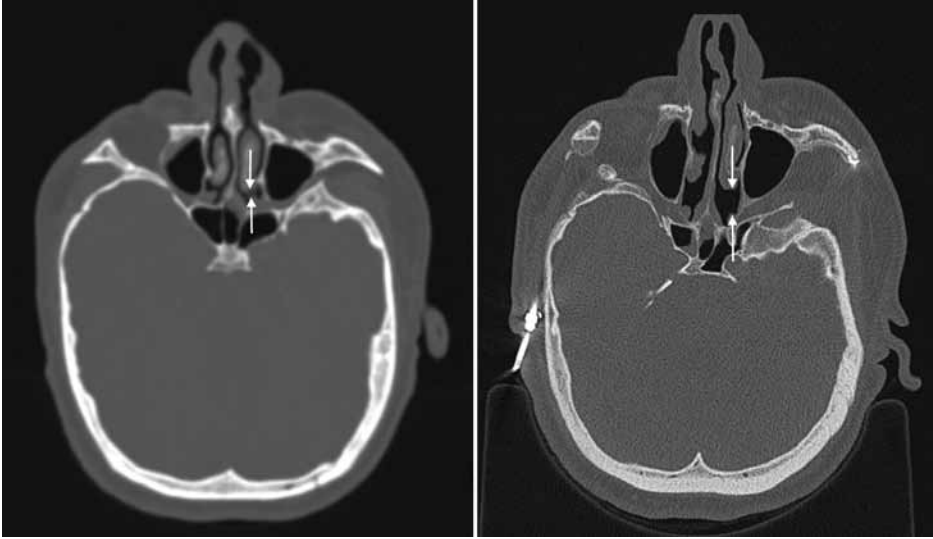


Figure 2: Pre- (left) and postoperative (right) axial slice at comparable levels of a patient with Apert syndrome. In this patient monobloc distraction was performed with internal distractors. A significant upper airway volume gain is visualized (white arrows).

the pharyngeal space an adenotonsillectomy was performed which, most likely, was responsible for the respiratory improvement.

DISCUSSION

In general, a significant decrease of OSAS is found after LF III and MB advancement.^{1, 3-5, 10-14} In nine subjects of the study cohort the outcomes of the upper airway volume measurements correlated to the respiratory outcome. Interestingly, four of the five LF III patients showed an increase of the upper airway volume and simultaneous improvement of the PSG measurements, whereas in the MB group only two of the four patients showed comparable results (**figure 2**) which might be due to the younger age of three of the four children in the MB group compared to the LF group. Considering the CT-scans of the two MB patients with endotracheal canulas (patient number eight and ten) who were insufflated during scanning, the collapse of the airway is evident both pre- and postoperatively (**figure 3**). Hypothetically, insufflation of air via the tracheal canula might cause a collapse of the upper airway cranial of the tracheal canula. This is supported by the findings of Fricke et al., who measured a significant decrease in volume of the naso- and hypopharyngeal airway in children with tracheostomy

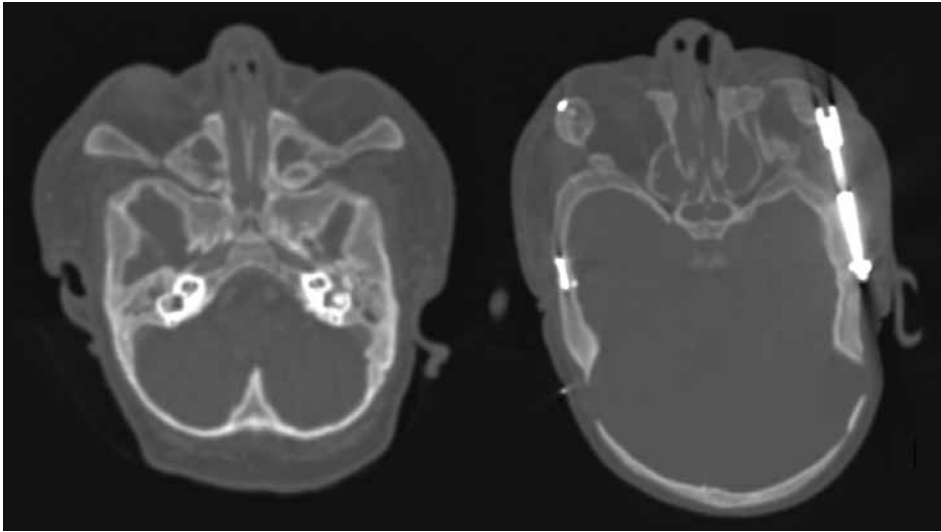


Figure 3: Pre- (left) and postoperative (right) axial slice at different levels of a patient with Crozon syndrome. In this patient monobloc distraction was performed with internal distractors. This patient was anesthetized and insufflated via the tracheal canula during scanning. In both slices the collapse of the airway is evident.

tubes after uncapping the tubes.⁶ Imaginably, in these patients requiring insufflation during scanning, the compliance of the airway is higher due to breathing through the tube instead of the upper airway. This may lead to increased collapsibility of the upper airway regardless of anatomical factors. In these patients, advancement of the forehead and midface might not overcome this enhanced collapsibility although the anatomical factors are sufficiently (over-)corrected.

Concerning the outcomes of OSAS after LF III advancement, several studies have been published of which only a few have evaluated the airway changes using cephalometrics.^{1, 3-5, 10-14} However, to the best of our knowledge, only one study has been published in which the OSAS outcomes were correlated to 3D airway changes after LF III advancement.¹⁷ In the present study, 50 % of the study group did not show enough respiratory improvement after midface or MB advancement to be independent of tracheostomy or CPAP or were in need of additional surgical treatment. This can be explained by the multifactorial etiology of OSAS. Despite advancement of the midface and creating airway volume, the patency of the upper airway is dependent on the nature of the airflow (turbulent or lamellar flow), velocity of the airflow and pressure gradient among others. The influence of midface advancement on these parameters is still unknown. In general, we recommend

pre-operative naso-endoscopy, nasopharyngoscopy and hypopharyngoscopy to identify the level of airway obstructions and incorporate the findings in the treatment plan. In case of anatomical airway obstruction and resistance to non-surgical interventions, additional orthognathic surgery or septal surgery might be indicated to reduce OSAS. The outcome of volume-measurements should be considered together with the state of the patient during scanning; was the patient awake or was insufflation necessary?

This retrospective study has limitations. Ideally, there was a fixed time interval between the pre- and postoperative CT-scans and PSG measurements. Unfortunately, the analysis of the pre- and postoperative time interval showed a considerable standard deviation, which varied between the pre- and postoperative CT-scans and PSG measurements. In addition no data were available concerning intraluminal pressure and airflow. Moreover concerning the PSG measurements only a portion of the patients had both ODI and AHI analyzed while ODI measurements were solely conducted and used as an OSAS-indicator in the majority of patients. By measuring ODI, sole deoxygenations are scored and used for the definition of OSAS whereas the AHI is based on deoxygenations followed by apneas; AHI represents a more strict definition of OSAS. In the present study the ODI's correlated well to the AHI's. Despite a good interobserver agreement, upper airway volume measurements are known to contain some errors.^{2, 16}

In conclusion, the majority of patients showed an improvement of the respiratory outcome after LF III advancement, which for the greater part, correlated to the results of the 3D volume measurements. In MB patients the correlation between the outcome of volume measurements and the respiratory outcomes were less obvious. Prior to (mid-)face advancement, naso-endoscopy, naso-pharyngoscopy and hypopharyngoscopy are advocated to identify the level of obstruction. Airway volume measurements may aid to gain insight in the complex mechanisms underlying the etiology of OSAS on level of the airway. Acquisition of airway pressure and airway flow data, i.e. airway resistance measurements, may aid in interpreting the respiratory outcomes. Long-term follow-up is needed to monitor the course of OSAS, especially in patients undergoing MB advancement at young age to elucidate the mechanisms of OSAS.

REFERENCES

1. Arnaud E, Marchac D, Renier D. Reduction of morbidity of the frontofacial monobloc advancement in children by the use of internal distraction. *Plast Reconstr Surg* 2007; 120: 1009-1026.
2. Bannink N, Nout E, Wolvius EB, Hoeve HL, Joosten KF, Mathijssen IM. Obstructive sleep apnea in children with syndromic craniosynostosis: long-term respiratory outcome of midface advancement. *Int J Oral Maxillofac Surg* 2010; 39: 115-121.
3. Elwood ET, Burstein FD, Graham L, Williams JK, Paschal M. Midface distraction to alleviate upper airway obstruction in achondroplastic dwarfs. *Cleft Palate Craniofac J* 2003; 40: 100-103.
4. Fearon JA. Halo distraction of the Le Fort III in syndromic craniosynostosis: a long-term assessment. *Plast Reconstr Surg* 2005; 115: 1524-1536.
5. Flores RL, Shetye PR, Zeitler D, Bernstein J, Wang E, Grayson BH, McCarthy JG. Airway changes following Le Fort III distraction osteogenesis for syndromic craniosynostosis: a clinical and cephalometric study. *Plast Reconstr Surg* 2009; 124: 590-601.
6. Fricke BL, Abbott MB, Donnelly LF, Dardzinski BJ, Poe SA, Kalra M, Amin RS, Cotton RT. Upper airway volume segmentation analysis using cine MRI findings in children with tracheostomy tubes. *Korean J Radiol* 2007; 8: 506-511.
7. Gonzalez S, Hayward R, Jones B, Lane R. Upper airway obstruction and raised intracranial pressure in children with craniosynostosis. *Eur Respir J* 1997; 10: 367-375.
8. Guilleminault C, Pelayo R, Clerk A, Leger D, Bocian RC. Home nasal continuous positive airway pressure in infants with sleep-disordered breathing. *J Pediatr* 1995; 127: 905-912.
9. Hoeve LJ, Pijpers M, Joosten KF. OSAS in craniofacial syndromes: an unsolved problem. *International journal of pediatric otorhinolaryngology* 2003; 67 Suppl 1: S111-113.
10. Holmes AD, Wright GW, Meara JG, Heggie AA, Probert TC. LeFort III internal distraction in syndromic craniosynostosis. *J Craniofac Surg* 2002; 13: 262-272.
11. Mathijssen I, Arnaud E, Marchac D, Mireau E, Morisseau-Durand MP, Guerin P, Renier D. Respiratory outcome of midface advancement with distraction: a comparison between Le Fort III and frontofacial monobloc. *J Craniofac Surg* 2006; 17: 642-644.
12. Meling TR, Due-Tonnessen BJ, Hogevoid HE, Skjeltved P, Arctander K. Monobloc distraction osteogenesis in pediatric patients with severe syndromal craniosynostosis. *J Craniofac Surg* 2004; 15: 990-1000; discussion 1001.
13. Meling TR, Hans-Erik H, Per S, Due-Tonnessen BJ. Le Fort III distraction osteogenesis in syndromal craniosynostosis. *J Craniofac Surg* 2006; 17: 28-39.
14. Nelson TE, Mulliken JB, Padwa BL. Effect of midfacial distraction on the obstructed airway in patients with syndromic bilateral coronal synostosis. *J Oral Maxillofac Surg* 2008; 66: 2318-2321.
15. Nixon GM, Kermack AS, McGregor CD, Davis GM, Manoukian JJ, Brown KA, Brouillette RT. Sleep and breathing on the first night after adenotonsillectomy for obstructive sleep apnea. *Pediatric pulmonology* 2005; 39: 332-338.
16. Nout E, Bouw FP, Veenland JF, Hop WC, Van der Wal KG, Mathijssen IM, Wolvius EB. Three-Dimensional Airway Changes after Le Fort III Advancement in Syndromic Craniosynostosis Patients. *Plast Reconstr Surg* 2010; 126: 564-571.
17. Xu H, Yu Z, Mu X. The assessment of midface distraction osteogenesis in treatment of upper airway obstruction. *The Journal of craniofacial surgery* 2009; 20 Suppl 2: 1876-1881.

Chapter 4b

Obstructive sleep apnea in children with syndromic craniosynostosis: long- term respiratory outcome of midface advancement

N. Bannink¹

E. Nout²

E.B. Wolvius²

H.L.J. Hoeve³

K.F.M. Joosten⁴

I.M.J. Mathijssen¹

¹ Department of Plastic and Reconstructive Surgery - Erasmus University Medical Centre Rotterdam, Sophia's Children's Hospital, The Netherlands

²Department of Oral and Maxillofacial Surgery - Erasmus University Medical Centre Rotterdam, The Netherlands

³Department of Otorhinolaryngology and Head and Neck Surgery - Erasmus University Medical Centre Rotterdam, Sophia's Children's Hospital, The Netherlands

⁴Department of Pediatrics – Erasmus University Medical Centre Rotterdam, Sophia's Children's Hospital, The Netherlands

Published

Int J Oral Maxillofac Surg. 2010 Feb;39(2):115-21

ABSTRACT

Almost 50% of patients with Apert, Crouzon or Pfeiffer syndrome develop OSAS, mainly due to midface hypoplasia. Midface advancement is often the treatment of choice, but the few papers on long-term outcome report mixed results. This paper aimed to assess the long-term respiratory outcome of midface advancement in syndromic craniosynostosis with OSAS and to determine factors contributing to its efficacy. A retrospective study was performed on eleven patients with moderate or severe OSAS, requiring oxygen, CPAP, or tracheostomy. Clinical symptoms, results of PSG, endoscopy and 3D upper airway volumes before and after midface advancement were reviewed. Midface advancement decreased the OSAS in the short term in six patients and was ineffective in five. In all patients without respiratory effect or with relapse, endoscopy showed obstruction of the rhino- or hypopharynx. The volume measurements supported the clinical and endoscopic outcome. Despite midface advancement, long-term dependence on, or indication for, CPAP or tracheostomy was maintained in five of eleven patients. Pharyngeal collapse appeared to play a role in OSAS. Endoscopy before midface advancement is recommended to identify airway obstruction that may interfere with respiratory improvement after midface advancement.

INTRODUCTION

Craniosynostosis is a congenital disorder affecting in one in 2500 births; it is characterized by the premature fusion of calvarial sutures. This fusion restricts normal growth of the skull, brain, and face, and necessitates surgical correction. In about 40% of cases it is part of a syndrome such as the Apert, Crouzon, Pfeiffer, Muenke or Saethre-Chotzen syndrome.¹¹ Almost 50% of children with Apert, Crouzon or Pfeiffer syndrome develop OSAS, mainly during the first 6 years of life.^{9, 13, 18} These patients are at risk for OSAS due to midface hypoplasia, but other factors such as adenotonsillar hypertrophy and mandibular hypoplasia may be involved as well.^{8, 13} According to its severity and cause, OSAS can be treated pharmacologically, surgically (e.g. with adenotonsillectomy, midface advancement or tracheostomy), or non-surgically (e.g. with nocturnal oxygen or CPAP).^{1, 8} If OSAS is not treated sufficiently, disturbed sleep patterns may result in major physical and functional impairment, for instance failure to thrive, recurrent infections, disturbed cognitive functions, delayed development, cor pulmonale or sudden death.¹⁶ As midface hypoplasia is the main cause of OSAS in syndromic craniosynostosis, midface advancement appears to be the treatment of choice.¹⁷

In the long-term, mixed respiratory results were reported following midface advancement in patients with syndromic craniosynostosis.¹⁵ It is unclear how long and to which level the improvement in breathing lasts, and which factors are predictors of respiratory outcome. To assess the respiratory outcome of midface advancement for moderate to severe OSAS and to determine predictive factors, the authors carried out a retrospective study in patients suffering from Apert, Crouzon or Pfeiffer syndrome.

MATERIAL AND METHODS

Study group

Over 100 patients with Apert, Crouzon and Pfeiffer syndrome have been treated at the Dutch Craniofacial Centre since 1983. For this study, the authors were only interested in the fourteen patients with moderate or severe OSAS, requiring treatment with nocturnal oxygen, CPAP, NPT, or tracheostomy, who presented between 1987 and 2006. Their records were analyzed for clinical symptoms of OSAS, results of

PSG and endoscopy of the upper airways, and the different treatment modalities for OSAS. CT-scans were used to measure the airway volume before and after midface advancement. For this case series, sufficient data and follow-up were available in eleven patients.

Obstructive sleep apnea

The clinical symptoms of OSAS scored were snoring, difficulty in breathing, apnea during sleep, perspiration, and daytime sleepiness. PSG was carried out ambulatory or during admission to hospital and the following criteria for analysis were used. Apnea was defined as absence of airflow for more than two breaths and hypopnea as reduction by $\geq 50\%$ in nasal flow signal amplitude for more than two breaths. The analysis was expressed in an AHI, the number of obstructive apneas in combination with hypopneas followed by desaturation per hour, and an ODI, the number of desaturations ($\geq 4\%$ decrease with respect to the baseline) per hour. A score < 1 is considered to be normal, one to five is defined as mild OSAS, six to 25 as moderate OSAS, and > 25 as severe OSAS.^{6, 7, 19, 20}

Respiratory outcome of midface advancement

The timing, type and outcome of the following interventions were evaluated: oxygen, NPT, CPAP, adenotomy and tonsillectomy, tracheostomy and midface advancement. The different interventions in each patient were added to evaluate the total number of procedures carried out to improve the breathing. The efficacy of treating OSAS was determined on the basis of clinical symptoms and PSG before and after midface advancement. Midface advancement was considered to be effective on respiration, in the short term, if oxygen, CPAP, NPT or tracheostomy were discontinued within one year after midface advancement. Also a categorical decrease of the ODI/AHI measurements after midface advancement was considered to be effective. Relapse of OSAS was defined as the need for respiratory support again. Long-term effectiveness was defined as independence of respiratory support at least two years after midface advancement.

Endoscopy of the upper airway

Endoscopies were carried out under general anaesthesia in a supine position. In two patients an additional endoscopy was carried out at the outpatient clinic in a sitting

position. The endoscopies were carried out to identify the possible level of obstruction including anatomical malformations in the rhino- and hypopharynx.

Volume measurements of the upper airway

A software program (MevisLab) was used to import and analyze the upper airway with CT scans by means of a custom-designed tool. Preoperative and postoperative scans were analyzed on transverse slices. The maxillary, ethmoidal, frontal and sphenoidal sinuses, concha bullosa and the oral cavity were manually excluded. The respiratory active air-holding cavities were segmented using semi-automatic region growing. The volumes of two separate anatomically defined areas were measured in mm³, taking the scale into consideration: nasal cavity and nasopharynx (defined to range from the most caudal point of the frontal sinus to the cranial point where the soft palate transformed into the uvula); and oro- and hypopharynx (ranged from the most cranial point where the soft palate transformed into the uvula, to the most caudal point of the hyoid bone). The total volume was calculated by adding the volumes of the two areas. All patients were scanned according to a protocol, using the same CT scan, and the thickness of the transverse slices was similar.

Statistical analysis

The results were analyzed using SPSS 14.0 for Windows 2000. All numbers are expressed as median and range.

RESULTS

Eleven patients with Apert (three patients), Crouzon (six patients) or Pfeiffer (two patients) syndrome who had moderate or severe OSAS, requiring treatment with nocturnal oxygen, CPAP, NPT, or tracheostomy, were included. Four of the eleven patients were boys (36%), aged 14.9 years (range 4.1– 23.1 years). All patients had midface hypoplasia. Six of the eleven patients underwent PSG before the start of treatment for OSAS; this showed moderate OSAS in three patients and severe OSAS in three (median ODI 25, range ten to 66). In the other patients, no PSG was performed due to the severity of the respiratory distress at presentation, which necessitated instant airway management, namely intubation or insertion of a tracheostomy. Airway treatment after diagnosis of OSAS involved tracheostomy in four patients, oxygen in three,

CPAP or NPT in three, and MB with NPT in one. All patients underwent a midface advancement with distraction followed by a control PSG; in three a MB was performed; and in eight a LF III. In ten of the eleven patients, an endoscopy of the upper airway was performed to identify the level of obstruction; this was done preoperatively in five, postoperatively in one, and both in four. In four patients, a CT-scan carried out before and after midface advancement was available. After advancing the midface for at least twenty mm the occlusion was corrected from class III to class II with overcorrection in all patients (**figure 1**). Clinically, a sufficient advancement of the midface was achieved in all patients. Final adjustment of the level of occlusion is performed in patients aged eighteen or older. So far, an additional LF I has been performed in two patients, no patient underwent mandibular correction. The follow-up time after midface advancement was 3.5 years (range 2.4–11.4 years, mean 5.7 years).

Respiratory outcome of midface advancement

The follow-up of the eleven OSAS patients at different ages is shown in **figure 2**. The respiratory outcome of each treatment option was considered. Adenotomy and tonsillectomy had a temporary beneficial effect on respiration in one of five patients, and no effect in four. In six of the seven patients, oxygen and CPAP or NPT were effective in bridging time to the midface advancement. In the other patient, tracheostomy was required despite MB and NPT. Midface advancements were carried out in three different modes: MB with and without distraction, and LF III with distraction. The patients with moderate or severe OSAS underwent a median number of five (range two to eight) invasive or non-invasive treatment procedures to improve their breathing.

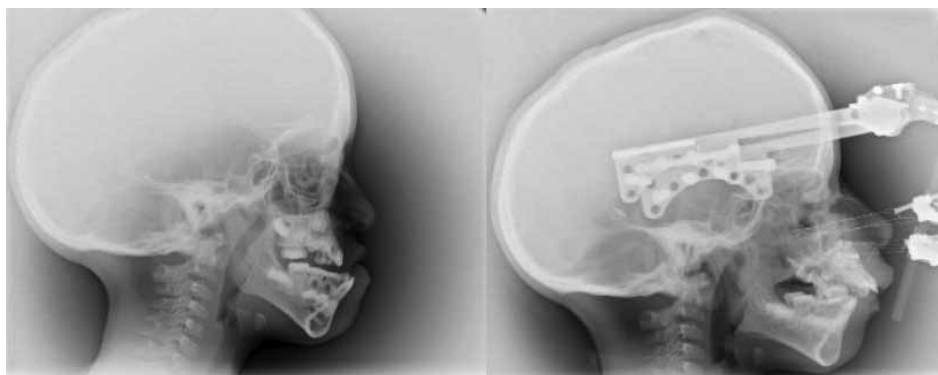


Figure 1: Sufficient correction was achieved in all patients; after advancing the midface for 20 mm the occlusion changed from class III to class II including the overcorrection.

Table 1: Respiratory outcome of midface advancement in the short-term.

Treatment	Number of treatments	Effect	Insufficient effect
MB without distraction	3	1	2
MB with distraction	3	2	1
LF III with distraction	8	4	4
Total view (N patients)	14 (11)	7 (6)	7 (5)

Midface advancement in the short term had a good or improved respiratory outcome in six patients (patients one, two, eight, ten, eleven and patient nine, respectively), and was unsatisfactory in five (patients three, four, five, six and seven) (**table 1**). In two patients (patients one and eleven) OSAS relapsed. In the long term, four of the eleven patients (patients three, four, six and seven) were still dependent on CPAP (2.5, 8.1 and 8.2 years after advancement) or tracheostomy (10.6 years) in spite of a surgically successful midface advancement and one (patient eleven) had severe OSAS without treatment (following a parental decision).

Endoscopy and volume measurements of the upper airway

Anatomical malformations of the rhino- and hypopharynx were a common feature in nearly all patients, causing a functional obstruction at this level. Only one patient did not have this feature and had a good respiratory outcome after midface advancement. All patients had a narrow nasal cavity. The volumes of the upper airway on CT-scan before and after midface advancement were calculated in patients one, four, six and eight (**table 2**). In **figure 3** the changes in these volumes are shown. In patient one the CT-scan four months post-surgery showed an increase in airway volume (1.4 times), mostly in the region nasal cavity and nasopharynx (1.6 times). One year after midface

Table 2: Measurements of airway volume on CT-scan before and 4 months and/or 1 year after midface advancement in mm³.

Patient	Nasal cavity and rhinopharynx			Oro- and hypopharynx			Total airway volume		
	Before	After 1	After 2	Before	After 1	After 2	Before	After 1	After 2
1	20.1	32.8	33.5	13.2	14.7	9.6	33.3	47.6	43.1
4	35.9	33.1		6.4	7.9		42.3	41.0	
6	19.6	20.3		9.1	6.2		28.8	26.5	
8	20.1	32.6		3.6	6.0		23.8	38.7	

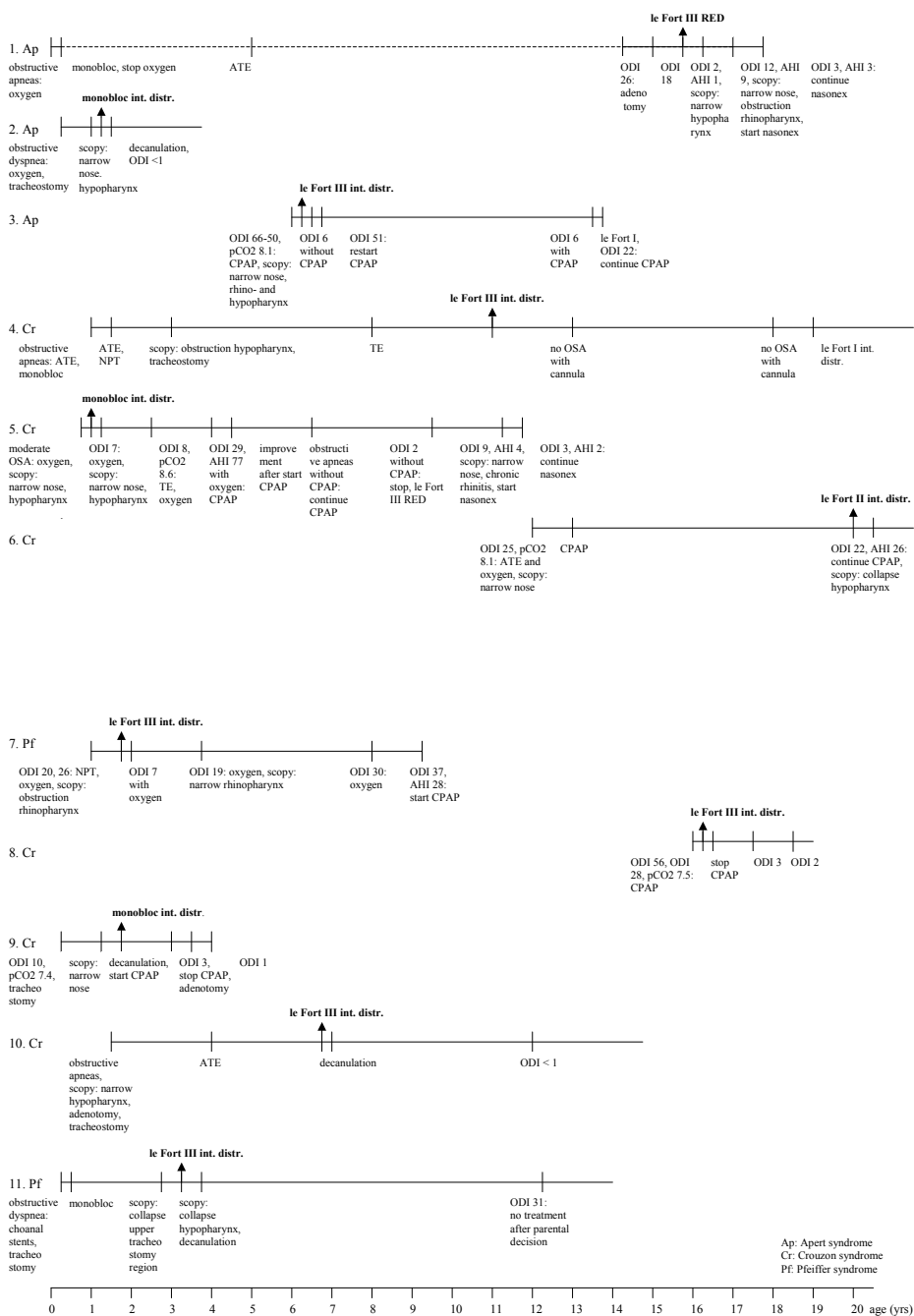
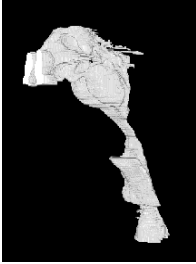

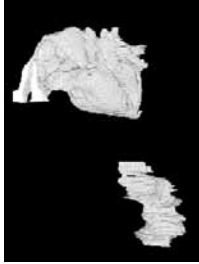
Figure 2: Follow-up of OSAS in eleven patients at different ages.

Patient 1

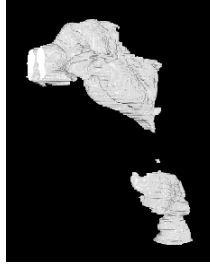
Before



After

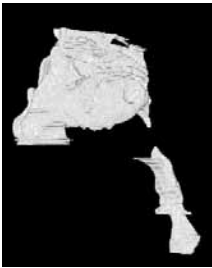

After 2

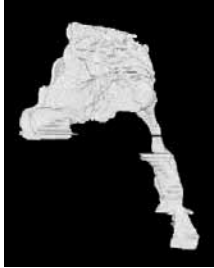


Patient 4

Before

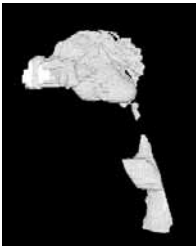

After

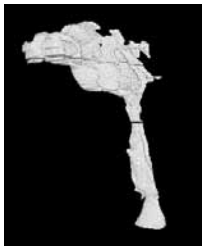

Patient 6

Before

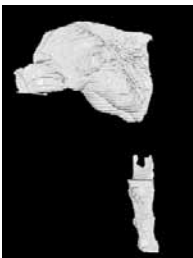


After



Patient 8

Before



After




Figure 3: Volume measurements of the upper airway before and after midface advancement.

advancement the CT-scan illustrated the narrow hypopharynx seen with endoscopy, with a volume decrease in the region oro- and hypopharynx (0.7 times). The CT-scans of patient four, made seven months before and one year after midface advancement, showed no increase in the total volume of the upper airway. The volume of the oro- and hypopharynx increased 1.2 times. Patient six showed no change in total volume of the upper airway four months after midface advancement in comparison with one year before, which matches the clinical presentation. After midface advancement the nasal cavity and nasopharynx volume increased, but the oro- and hypopharynx region was 0.7 of the volume before. In patient eight, with a good clinical result, the volume of the upper airway increased by a factor of 1.6, thirteen months after midface advancement in comparison with three months before. The volume of the nasal cavity and nasopharynx increased 1.6 times and the volume of the oro- and hypopharynx was 1.7 times larger.

DISCUSSION

On a young age, adenotonsillectomy is the easy accessible treatment for children with OSAS, as adenotonsillar hypertrophy is an important cause of OSAS.^{5, 20} In this study, in patients suffering from Apert, Crouzon or Pfeiffer syndrome with moderate or severe OSAS, neither tonsillectomy nor adenotomy had a significant effect on respiration. In patients with SCS, midface hypoplasia is generally considered to be the major cause of upper airway obstruction.¹³ All children in this study also had midface hypoplasia. Although, midface advancement seemed to be a good treatment modality for compromised airways at the level of the midface, in this study only six of eleven patients (55%) had a favourable effect in the short term after MB or LF III with distraction.^{13, 14} Witherow et al. found an improvement in all patients suffering from Apert, Crouzon or Pfeiffer syndrome with abnormal PSG after MB with external distraction.²¹ Of the fourteen patients with severe OSAS, treated with tracheostomy or CPAP, OSAS was resolved after surgery in six (43%). The other eight patients remained dependent on tracheostomy or CPAP. The mean follow-up was 24 months.²¹ Arnaud et al. showed a respiratory improvement measured by oxygen level in fourteen of sixteen patients with Apert, Crouzon or Pfeiffer syndromes after MB with internal distraction.² In the severe cases, closure of tracheostomy was possible in four of six (67%). In one patient a tracheostomy was needed six months after removal

of distractors because of relapse of OSAS. The mean follow-up after surgery was 2.5 years.² Nelson et al. studied eighteen patients with syndromic bilateral coronal synostosis and OSAS, in fifteen of them a tracheostomy or CPAP was required before midface advancement.¹⁵ After midface advancement, five patients were decanulated and in six CPAP was discontinued (73%). The mean time of follow-up was 3.2 years. In these three studies, midface advancement did not result in good respiratory outcome in all (similar to the present study). These studies and the present one showed that respiratory outcome after midface advancement in SCS patients who need it the most is not as successful as is generally thought. Inclusion of patients with mild OSAS in other studies has given the impression that midface advancement with distraction gives a guaranteed improvement of OSAS.

Endoscopy of the upper airway can show the level of obstruction and the dynamic influence of breathing. However, it is well known that endoscopy can be influenced by the position of the patient. In the four patients with persistent OSAS after advancement and in the patient with a relapse of OSAS an obstruction of the rhino- or hypopharynx was seen. In Apert, Crouzon and Pfeiffer syndrome, the anatomy of the upper airway is different and there seems to be a dynamic function problem regarding the airway, possibly related to the anatomical anomalies caused by the mutation of the fibroblast growth factor receptor.¹¹ The nasal cavity is narrow in all patients; this is common in these syndromes. Collapse of the pharynx is a dynamic problem that may or may not improve with midface advancement since many factors influence the airway patency of which airway volume is only one. In the non-responders, the pharyngeal walls collapsed with each breath, and resulted in an airway obstruction. So the advancement could not overcome the tendency of the pharyngeal walls to collapse. The changes in airway volume on CT-scan after midface advancement were similar to the results of endoscopy, and thus seem to illustrate the dynamic situation of the airway, including the level of obstruction. An improvement of airway volume on CT correlated with a good respiratory outcome. The authors consider that the degree of functional obstruction of the rhino- or hypopharynx correlates with respiratory outcome after midface advancement: a mild tendency for collapse can be overcome with midface advancement. This hypothesis could not be substantiated in this retrospective analysis.

Measurement of airway volume on CT scan has some limitations, in particular the difficulty of manually defining the borders of the nasal cavity because of anatomical anomalies. A cold can affect the thickness of the (sub)mucosa and the size of

the tonsils, and the position and respiration state of the patient in the CT scan can influence the volume of the airway at the moment of scanning. The influence of growth in volume changes is not likely in patients with SCS since they have growth retardation of the maxilla and restriction of normal transverse growth of the mandible, possibly secondary to cranial base abnormalities.^{3,4} Previous studies on airway changes after advancement were based on tracing of cephalograms.^{10,12} Ishii et al. studying sixteen patients with Apert or Crouzon syndrome found an improvement on cephalogram in the nasopharyngeal airway after LF III osteotomy, but no change in hypopharyngeal airway was found.¹⁰ In twelve 'normal' adults who underwent maxillary and mandibular advancement for OSAS Li et al. found an increase in the airway dimension after surgery measured by cephalometric imaging.¹² Fiberoptic nasopharyngoscopy with the Müller maneuver (take a breath while the mouth is closed and the nostrils are plugged) showed a decrease in collapsibility of the upper airway, mostly the lateral pharyngeal wall. They suggested a reduction of the thickness of the muscular wall. Mandibular advancement seemed to be needed to enlarge the pharyngeal airway. In the present study group no mandibular advancement was carried out. Mandibular advancement is generally not considered in children with SCS to treat their OSAS, although this may be an option in patients with disappointing results following midface advancement and remaining obstruction at the hypopharynx.

This study showed that moderate or severe OSAS in children with SCS is a major problem and difficult to treat. It is not only directly correlated with midface hypoplasia. Endoscopy showed anomalies at different levels throughout the upper airway. Dynamic pharyngeal collapse can affect the respiratory outcome of midface advancement; endoscopy of the upper airway before midface advancement may predict respiratory improvement. It may be possible to treat obstructions at another level with other procedures, such as widening of the palate to enlarge the nose and mandibular advancement to create more space at the level of the hypopharynx. Long-term follow-up is important because OSAS may relapse.

To implement these findings and to improve the prognostic information on respiratory outcome after midface advancement, the authors recommend performing an endoscopy of the upper airway before midface advancement to identify all levels of obstruction (also stated by Nelson et al.).¹⁵ Treatment of OSAS will then be better focussed on its cause. The volume measurements of the upper airway will be

continued in further research as a tool to investigate the effect of midface advancement on airway volume and to specify the level of largest gain on respiration. In conclusion, despite midface advancement, long-term dependence on, or indication for, CPAP or tracheostomy was maintained in five of eleven patients in whom Apert, Crouzon or Pfeiffer syndrome was combined with moderate or severe OSAS. In the patients with persistence of OSAS despite optimal surgical treatment, pharyngeal collapse appeared to play a role in obstruction of the airway. Endoscopy makes it possible to identify a static or dynamic airway obstruction that may interfere with respiratory improvement, enabling a prediction of respiratory improvement and treatment to be adapted to the specific level of obstruction. Long-term follow-up is needed because of the chance of relapse.

REFERENCES

1. Clinical practice guideline: diagnosis and management of childhood obstructive sleep apnea syndrome. *Pediatrics* 2002; 109: 704-712.
2. Arnaud E, Marchac D, Renier D. Reduction of morbidity of the frontofacial monobloc advancement in children by the use of internal distraction. *Plast Reconstr Surg* 2007; 120: 1009-1026.
3. Boutros S, Shetye PR, Ghali S, Carter CR, McCarthy JG, Grayson BH. Morphology and growth of the mandible in Crouzon, Apert, and Pfeiffer syndromes. *J Craniofac Surg* 2007; 18: 146-150.
4. Firmin F, Coccato PJ, Converse JM. Cephalometric analysis in diagnosis and treatment planning of craniofacial dysostoses. *Plast Reconstr Surg* 1974; 54: 300-311.
5. Goldberg S, Shatz A, Picard E, Wexler I, Schwartz S, Swed E, Zilber L, Kerem E. Endoscopic findings in children with obstructive sleep apnea: effects of age and hypotonia. *Pediatr Pulmonol* 2005; 40: 205-210.
6. Guilleminault C, Lee JH, Chan A. Pediatric obstructive sleep apnea syndrome. *Arch Pediatr Adolesc Med* 2005; 159: 775-785.
7. Guilleminault C, Pelayo R, Clerk A, Leger D, Bocian RC. Home nasal continuous positive airway pressure in infants with sleep-disordered breathing. *J Pediatr* 1995; 127: 905-912.
8. Hoeve HL, Joosten KF, van den Berg S. Management of obstructive sleep apnea syndrome in children with craniofacial malformation. *Int J Pediatr Otorhinolaryngol* 1999; 49 Suppl 1: S59-61.
9. Hoeve LJ, Pijpers M, Joosten KF. OSAS in craniofacial syndromes: an unsolved problem. *Int J Pediatr Otorhinolaryngol* 2003; 67 Suppl 1: S111-113.
10. Ishii K, Kaloust S, Ousterhout DK, Vargervik K. Airway changes after Le Fort III osteotomy in craniosynostosis syndromes. *J Craniofac Surg* 1996; 7: 363-370; discussion P-371.
11. Lajeunie E, Heuertz S, El Ghouzzi V, Martinovic J, Renier D, Le Merrer M, Bonaventure J. Mutation screening in patients with syndromic craniosynostoses indicates that a limited number of recurrent FGFR2 mutations accounts for severe forms of Pfeiffer syndrome. *Eur J Hum Genet* 2006; 14: 289-298.
12. Li KK, Guilleminault C, Riley RW, Powell NB. Obstructive sleep apnea and maxillomandibular advancement: an assessment of airway changes using radiographic and nasopharyngoscopic examinations. *J Oral Maxillofac Surg* 2002; 60: 526-530; discussion 531.
13. Lo LJ, Chen YR. Airway obstruction in severe syndromic craniosynostosis. *Ann Plast Surg* 1999; 43: 258-264.
14. Mathijssen I, Arnaud E, Marchac D, Mireau E, Morisseau-Durand MP, Guerin P, Renier D. Respiratory outcome of mid-face advancement with distraction: a comparison between Le Fort III and frontofacial monobloc. *J Craniofac Surg* 2006; 17: 880-882.
15. Nelson TE, Mulliken JB, Padwa BL. Effect of midfacial distraction on the obstructed airway in patients with syndromic bilateral coronal synostosis. *J Oral Maxillofac Surg* 2008; 66: 2318-2321.
16. Nixon GM, Brouillette RT. Sleep . 8: paediatric obstructive sleep apnoea. *Thorax* 2005; 60: 511-516.
17. Nout E, Cesteleyn LL, van der Wal KG, van Adrichem LN, Mathijssen IM, Wolvius EB. Advancement of the midface, from conventional Le Fort III osteotomy to Le Fort III distraction: review of the literature. *Int J Oral Maxillofac Surg* 2008; 37: 781-789.

18. Pijpers M, Poels PJ, Vaandrager JM, de Hoog M, van den Berg S, Hoeve HJ, Joosten KF. Undiagnosed obstructive sleep apnea syndrome in children with syndromal craniofacial synostosis. *J Craniofac Surg* 2004; 15: 670-674.
19. Poels PJ, Schilder AG, van den Berg S, Hoes AW, Joosten KF. Evaluation of a new device for home cardiorespiratory recording in children. *Arch Otolaryngol Head Neck Surg* 2003; 129: 1281-1284.
20. Ward SL, Marcus CL. Obstructive sleep apnea in infants and young children. *J Clin Neurophysiol* 1996; 13: 198-207.
21. Witherow H, Dunaway D, Evans R, Nischal KK, Shipster C, Pereira V, Hearst D, White M, Jones BM, Hayward R. Functional outcomes in monobloc advancement by distraction using the rigid external distractor device. *Plast Reconstr Surg* 2008; 121: 1311-1322.

Chapter 5

Additional orthognathic surgery following Le Fort III and Monobloc advancement

E. Nout

M.J. Koudstaal

E.B. Wolvius

K.G.H. van der Wal

Department of Oral and Maxillofacial Surgery - Erasmus University

Medical Centre Rotterdam, The Netherlands

Submitted

Int J Oral Maxillofac Surg

ABSTRACT

Severe midface hypoplasia in patients with various craniofacial anomalies can be corrected with LF III or MB advancement. Often additional corrective orthognathic surgery is indicated to achieve Class I occlusion and normal inter-jaw relationship. The purpose of this study was to evaluate incidence and surgical indications of secondary orthognathic surgery following LFIII/MB advancement.

The total study group consisted of 41 patients: 36 patients with LF III advancement and five patients with MB advancement. Seven patients underwent additional orthognathic surgery. Of the resulting eighteen non-operated patients older than eighteen years of age at the end of follow-up, Class I occlusion was observed in eleven patients. In the remaining patients malocclusions were dentally compensated with orthodontic treatment. None of the patients was scheduled for additional orthognathic surgery due to the absence of functional complaints and/or resistance to additional surgery.

LF III and MB advancement aim to correct the skeletal deformities on level of zygoma, orbits, nasal area and forehead. However, Class I occlusion is frequently not achieved. Therefore, additional orthognathic surgery is often indicated in patients undergoing LF III or MB advancement. Naso-endoscopic analysis of the upper airway and the outcomes of sleep studies may influence the orthognathic treatment plan.

INTRODUCTION

Midface hypoplasia in SCS patients and non-syndromic patients can be associated with upper airway obstruction, ocular proptosis, Class III malocclusion and facial distortion leading to psychosocial problems¹³. In addition there seems to be a relation between OSAS and raised ICP¹⁴. Ideally, LF III and MB advancement is planned when skeletal maturity is reached. However, in cases with OSAS, raised ICP and ocular related pathology (inability of complete eyelid closure, (sub-)luxation) surgical intervention can not be postponed until skeletal maturity. Since the focus of this early surgery is concentrated on this acute pathology, relative indications, such as Class III malocclusion and facial esthetic disharmony, may not be corrected. In addition, literature reports a severely diminished intrinsic horizontal growth potential of the midface in SCS patients regardless of surgery^{6, 9, 12}. Imaginably continuing growth of the mandible may cause pseudorelapse. Therefore some degree of overcorrection in growing patients is advised. Nevertheless, correction of the deformity on the occlusal level may not be treated with LF III or MB advancement. Frequently, additional orthognathic surgery is indicated at a later stage. Various suggestions are reported in literature^{2, 6, 10, 12}. However, no clinical guidelines exist regarding the ideal timing and planning of these surgical procedures and the related orthodontic treatment. The aim of this retrospective study is to report the experience with additional orthognathic surgery as the final procedure to achieve a functional inter-jaw relationship and a Class I occlusion following LF III and MB advancement.

MATERIALS AND METHODS

Patients

The study group consisted of 41 patients with cleft and various craniofacial anomalies. All patients who underwent LF III or MB advancement between 1999 and 2009 were included. A total of 38 SCS patients (sixteen Apert syndromes, seventeen Crouzon syndromes and five Pfeiffer syndromes) were reviewed of whom 33 patients underwent LF III advancement and five patients underwent MB advancement. In the LF III group two patients with frontonasal dysplasia and one patient with a bilateral cleft-lip-alveolus-palate and a median cleft were included. Of all the patients, seven underwent a conventional LF III osteotomy; 29 patients underwent LF III DO proce-

ture and all MB patients underwent DO. In one patient who underwent LF III DO and one who underwent conventional LF III osteotomy, simultaneous with the LF III osteotomy, a LF I osteotomy was performed. DO was performed using either internal (fourteen patients, including all MB patients) or external distractors (twenty patients). The Marchac-Arnaud distraction system (KLS Martin, Tuttlingen, Germany) was used for internal DO. External DO was achieved using the RED II halo frame (KLS Martin, Tuttlingen, Germany) or external midface distractor (Synthes, Solothurn, Switzerland).

Indications for primary surgery

Indications were classified as absolute or relative. Absolute indications were moderate or severe OSAS (ODI > five and/or patients requiring tracheostomy), raised ICP and exorbitism including persistent exposure keratitis and (sub-)luxation of the globe. Relative indications were impaired esthetical appearance, exorbitism without clinical significance, Class III malocclusion and psychosocial considerations.

LF III and MB distraction protocol

A latency period of seven days postoperatively was applied to all patients regardless of age or degree of advancement. Distraction rate was one mm per day for the LF III distraction and 0.5 mm for the MB distraction. Distraction time was based on the desired advancement. For the LF III patients vector modifications took place during distraction to correct asymmetry and unfavourable direction of distraction. Distraction was terminated when a normal malar and nasal projection was achieved and exorbitism was corrected. After LF III distraction a consolidation period of three months was respected in all patients. The internal devices in the MB distraction cases were removed after six months of consolidation.

Indications for the secondary orthognathic surgery

Indications for additional orthognathic surgery were assessed by means of clinical evaluation of the occlusion and profile and cephalometric analysis using standardized lateral skull radiographs. Clinical examination was performed by an orthodontist and a maxillofacial surgeon. In case of residual OSAS, naso-endoscopic examination was performed by an otolaryngologist to identify the level of upper airway obstruction. Indications for additional orthognathic surgery were frontal open bite, Class II or III malocclusion, transverse discrepancy, evident crowding and residual OSAS.

Data collection

Patient-data were retrospectively collected from the patients' medical records. Indications, age at primary operation, age at secondary orthognathic surgery (if performed) and interval between primary and secondary surgery was evaluated. In all patients completion of skeletal growth was defined at the age of eighteen.

RESULTS

Data are summarized in **table 1**. In the total group the mean age at operation was 13.9 years (sd 6.0). The mean age was 14.5 years (sd 5.3) in the LF III group and 9.2 years (sd 8.8) in the MB patients. The patients with an absolute indication (n = 21) were on average operated at a younger age (mean 11.1, sd 6.4 years) compared to patients operated because of a relative indication (n = 20, mean = 16.8, sd 3.8). In the total patient cohort seventeen (thirteen LF III patients and four MB patients) of the 41 patients (41.5 %) were younger than eighteen years at the end of the follow-up period. The mean follow-up period was 4.8 years (sd 3.0).

Additional orthognathic surgery

Seven patients underwent additional orthognathic surgery (**table 1**). In the total group the mean age at additional orthognathic surgery was 19.6 years (sd 2.4). Both over- and undercorrection at the occlusal level was noted. In case of Class III malocclusion LF I advancement was the treatment of choice (three patients). In two cases of overcorrection, bimaxillary correction was planned. In one patient, mandibular advancement was indicated to correct the deformity. In the LF III group, three patients underwent a LF I osteotomy, two patients underwent bimaxillary advancement and one patient underwent SARME. In the MB group one patient underwent a SARME before the MB and a BSSO after the MB. In this patient endoscopy of the upper airway revealed obstructions at the level of the base of the tongue and at the deviated nasal septum. A nasal septum correction was performed simultaneously with the BSSO and removal of the internal MB distractors.

Additional orthognathic surgery was performed on average 34 months (sd 34.9) after primary surgery. Three patients with initial surgery before the age of eighteen underwent additional orthognathic surgery; four patients with initial surgery after the age of eighteen underwent additional orthognathic surgery.

Table 1: Overview of patient cohort subdivided according to surgical intervention and craniofacial anomaly.

Patient	Syndrome	Indication for primary surgery	Age at time of primary surgery (years)	Orthognathic surgery
LF III				
1	Apert	absolute	16	
2	Apert	absolute	12	
3	Apert	relative	20	
4	Apert	relative	15	
5	Apert	relative	18	
6	Apert	relative	19	Bimaxillary advancement
7	Apert	absolute	7	SARME
8	Apert	relative	24	
9	Apert	absolute	14	
10	Apert	absolute	19	LF I
11	Apert	relative	16	LF I
12	Apert	absolute	12	
13	Apert	relative	19	
14	Crouzon	relative	17	
15	Crouzon	relative	15	LF I
16	Crouzon	absolute	11	
17	Crouzon	absolute	16	
18	Crouzon	absolute	13	
19	Crouzon	relative	14	
20	Crouzon	relative	8	
21	Crouzon	absolute	6	
*22	Crouzon	absolute	3	
23	Crouzon	relative	19	Bimaxillary advancement
24	Crouzon	absolute	11	
25	Crouzon	relative	8	
26	Crouzon	relative	18	
27	Crouzon	relative	18	
*28	Crouzon	absolute	21	
*29	Pfeiffer	relative	18	
30	Pfeiffer	relative	14	
*31	Pfeiffer	absolute	7	
*32	Pfeiffer	absolute	1	
33	Pfeiffer	relative	20	
*34	NMD	relative	17	
*35	NMD	relative	19	
36	CLAP	absolute	18	
MB				
1	Apert	absolute	23	BSSO + nasal septum correction
2	Apert	absolute	2	
3	Apert	absolute	12	
4	Crouzon	absolute	7	
5	Crouzon	absolute	2	

All patients underwent DO except for the patients marked with an asterisk who underwent conventional LF III osteotomy. Young age = patient younger than 18 years

Indication for orthognathic surgery	Age at time of orthognathic surgery (years)	Age at end of follow-up (years)	No orthognathic surgery performed at the end of this study due to
		20	Class II comp; open bite
		17	Young age
		25	Class II comp; open bite
		19	Class III comp; open bite
		22	Class I
Class II	20	23	-
Crowding maxilla	15	16	-
		27	Class I
		15	Young age
Class III	19	23	-
Class III	20	27	-
		19	Class III comp
		27	Class I
		23	Class I
Class III	21	22	-
		16	Young age
		21	Class III comp
		17	Young age
		17	Young age
		10	Young age
		16	Young age
		15	Young age
Class II	19	21	-
		11	Young age
		10	Young age
		23	Class I
		27	Class III; open bite
		24	Class I
		25	Class I
		19	Class II; open bite
		11	Young age
		11	Young age
		26	Class I
		19	Class I; open bite
		30	Class I
		22	Class I; open bite
Class II	23	24	-
		3	Young age
		12	Young age
		11	Young age
		5	Young age

Clinical evaluation of the resulting eighteen non-operated patients who were older than eighteen years of age at the end of the follow-up period, revealed Class I occlusion in eleven patients. Of the remaining patients, three patients showed Class II malocclusion and four patients showed Class III malocclusion. By means of orthodontic treatment, all malocclusions were dentally compensated. In addition, five patients showed a frontal open bite and two patients showed a bilateral open bite. Nevertheless none of these patients was scheduled for additional orthognathic surgery due to the absence of functional complaints and resistance to additional surgery.

DISCUSSION

In the multidisciplinary treatment of patients with SCS and other non-syndromic patients, LF III or MB advancement is often the treatment of choice to address the problems emerging from marked retrusion of the midface. In case of absolute indications, surgery is often performed at a young age. The focus of this surgery is to resolve OSAS, raised ICP or severe exophthalmus. The timing of surgery is dictated by the onset of functional problems¹³. Due to a diminished syndrome-related intrinsic anterior growth potential of the midface, little forward growth is likely to be expected postsurgically^{1,6,9,12}. This, together with the unaffected growth of the mandible, might cause (pseudo-)relapse at an older age requiring additional (orthognathic) surgery. Furthermore, a substantial risk of recurrent OSAS is present. One should realise that cases with pressing indications in which LF III or MB DO is performed at a very young age, run the risk of residual raised ICP or OSAS during growth. In these cases often a second LF III or MB advancement is indicated, which is unfavourable. Where, in cases of raised ICP in the young patient, fronto-orbital advancement was advocated, the treatment protocol in our craniofacial centre is the posterior vault expansion. Fronto-orbital advancement negatively influences the patients' aesthetics and hinders possible additional LF III or MB interventions.

To minimize the risk of additional orthognathic surgery, we try to advance the midface or MB segment in young patients as much forward as possible. Long-term studies report little or no relapse after both conventional LF III osteotomy and LF III DO, rendering both procedures to be stable^{4,6,8,11,12}. DO in these cases is the treatment of choice to allow for these large advances. In case of OSAS the midface

or MB segment is advanced forward until the OSAS is corrected. With regard to MB advancement, a comparative study showed less relapse and greater advancement in patients undergoing MB DO compared to the conventional MB advancement after a two year follow-up². Also MB DO is associated with less morbidity^{2, 5, 7}. In SCS patients with severe midface concavity or flattening, facial bipartition advancement using DO should be considered. This provides the surgeon the opportunity to advance the central portion of the face more than the lateral sides thereby 'unflattening' this otherwise characteristic stigma of the syndrome¹⁵. Additionally, this manoeuvre could result in relative higher increase of upper airway volume than with the traditional midface advancement. Literature reports stable results using both external and internal distractors^{3, 5, 15}. By widening the maxilla with facial bipartition, additional SARME might be prevented in the future and less postoperative open bite may occur.

In the study group seven patients needed additional orthognathic surgery. Of these, three patients underwent LF III advancement before completion of growth. In the study group seventeen patients did not complete growth during the course of this study. Imaginably, some of these seventeen patients might need additional orthognathic surgery later in life. Theoretically, the three patients who underwent MB advancement, aged two (two patients) and seven, are especially prone to additional surgery. Therefore, no exact percentages can be reported in this study.

Four patients (three LF III patients and one MB patient) underwent additional orthognathic surgery at maturity to achieve Class I occlusion. In one patient additional mandibular advancement and nasal septum correction was indicated to treat the residual OSAS at the level of the oro-/hypopharynx and nasal cavity respectively (**figure 1**). In a patient with the preoperative diagnosis of severe OSAS, postoperative endoscopy revealed an additional obstruction of the upper airway at the level of the oro-/hypopharynx causing residual OSAS (**figure 2**). Ideally, this obstruction should have been identified before the primary surgery. The advancement of the midface could have been attuned to the additional mandibular advancement needed to alleviate the obstruction at the level of the oro-/hypopharynx. During the LF III and MB procedures the nasal septum is osteotomized, which may result in septum deviation and upper airway obstruction. Endoscopic screening by an experienced otolaryngologist in OSAS cases to identify the level of upper airway obstruction is advocated. Endoscopic analysis of the upper airway may indeed influence the orthognathic treatment plan. Consequently, this analysis together

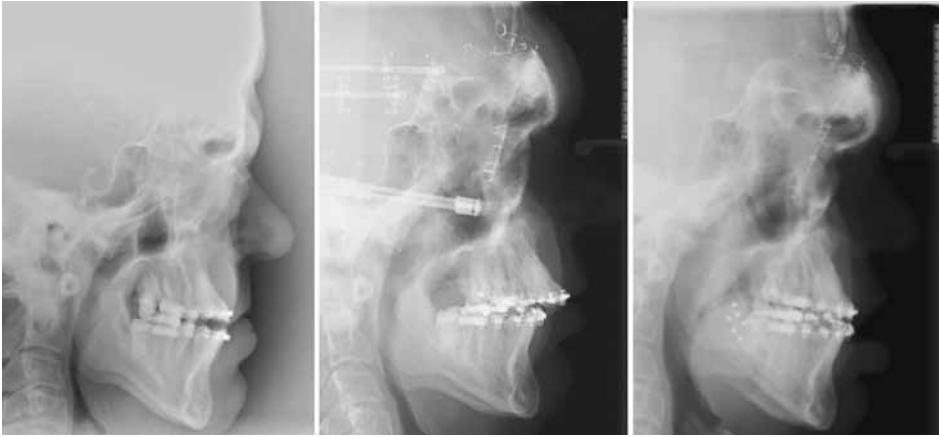

Figure 1: On the left side the preoperative lateral skull radiograph is depicted of a patient with Apert syndrome in which the midface hypoplasia is evident. The middle picture reflects the lateral skull radiograph after monobloc advancement with the distractors still in situ; residual OSAS at the level of the oro-/hypopharynx and nasal cavity was revealed by naso-endoscopy. Additional BSSO and nasal septum correction was indicated. The right lateral skull radiograph shows the postoperative situation.

with polysomnography should be a standard part of the preoperative orthognathic protocol.

Most of these cases where midface advancement is indicated after completion of growth, demonstrate that surgical correction focuses on correction of the deformity on the level of the orbits and zygoma. However, in a substantial number Class I occlusion was achieved simultaneously with the correction of the deformity of the midface. Imaginably, postoperatively Angle Class II or III occlusion may persist and might need correction after consolidation of the initial surgery. SCS patients,

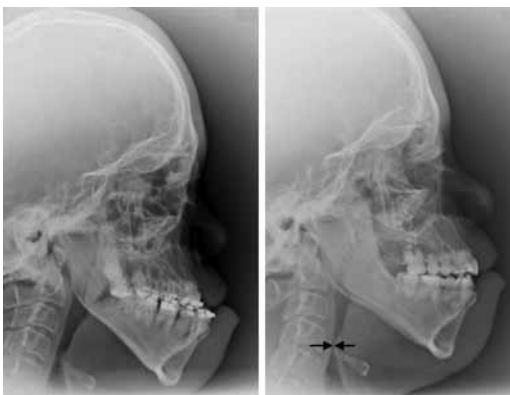


Figure 2: Lateral skull radiographs of a patient with Crouzon syndrome before (left) and after LF III DO (right). Endoscopy revealed residual OSAS on level of the oro-/hypopharynx which can be visualised in the right lateral skull radiograph (arrows).

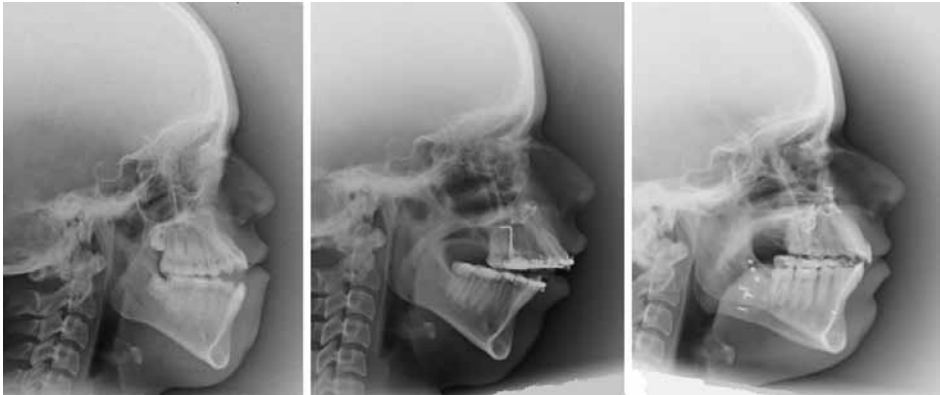

Figure 3: Patient with Crouzon syndrome with a considerable frontal open bite preoperatively (left). After LF III DO the frontal open bite becomes more evident and Class II malocclusion is present (middle). After LF I osteotomy with intrusion of the dorsal part of the maxilla together with a BSSO advancement, a stable Class I occlusion was attained (right).

especially Crouzon patients, are frequently associated with a frontal open bite that is likely to persist after LF III or MB advancement. In case of functional complaints an additional LF I osteotomy with intrusion of the dorsal part of the maxilla together with a BSSO advancement is the treatment of choice to correct the frontal open bite (**figure 3**). In case of a pronounced gummy smile, which can arise after LF III DO, the same modality can be used to reduce this. Besides this we managed to get acceptable results by combining LF III and I osteotomies in one patient with nasomaxillary dysplasia (conventional LF III and I osteotomies) and one patient with cleft-lip-alveolus-palate (LF III-I DO). This technique renders good results on the level of the midface and at the same time allows correction of the occlusion.

A substantial number of patients with SCS are characterized by a varying degree of mental retardation, for example patients with Apert syndrome (fourteen patients in this study group). Mental retardation can be associated with diminished coping abilities and compliance. These problems often give rise to a suboptimal end result of the initial treatment. In these cases, additional orthognathic surgery, although often indicated, might not be performed. In these patients any correction of the facial disharmony can be looked upon as improvement of the preoperative situation. In conclusion, LF III and MB advancement aim to correct the deformities on level of zygoma, orbits and nasal areas respectively. Frequently Class I occlusion is not achieved. This makes LF III and MB advancement indefinite procedures, especially when performed during early childhood. Therefore, additional orthognathic surgery

is often indicated in patients undergoing LF III or MB advancement. Endoscopy of the upper airway and continuing sleep studies in patients with persistent OSAS are advised. The outcomes of these studies may influence the orthognathic treatment. Long-term follow-up studies are necessary to determine the exact incidence of additional orthognathic surgery after midface or MB advancement.

REFERENCES

1. Bachmayer DI, Ross RB, Munro IR. Maxillary growth following LeFort III advancement surgery in Crouzon, Apert, and Pfeiffer syndromes. *Am J Orthod Dentofacial Orthop* 1986; 90: 420-430.
2. Bradley JP, Gabbay JS, Taub PJ, Heller JB, O'Hara CM, Benhaim P, Kawamoto HK, Jr. Monobloc advancement by distraction osteogenesis decreases morbidity and relapse. *Plast Reconstr Surg* 2006; 118: 1585-1597.
3. Bradley JP, Levitt A, Nguyen J, Raposo CE, Jarrahy R, Katchikian HV, Kawamoto HK. Roman arch, keystone fixation for facial bipartition with monobloc distraction. *Plast Reconstr Surg* 2008; 122: 1514-1523.
4. Cedars MG, Linck DL, 2nd, Chin M, Toth BA. Advancement of the midface using distraction techniques. *Plast Reconstr Surg* 1999; 103: 429-441.
5. Cohen SR, Boydston W, Hudgins R, Burstein FD. Monobloc and facial bipartition distraction with internal devices. *J Craniofac Surg* 1999; 10: 244-251.
6. Fearon JA. Halo distraction of the Le Fort III in syndromic craniosynostosis: a long-term assessment. *Plast Reconstr Surg* 2005; 115: 1524-1536.
7. Gosain AK, Santoro TD, Havlik RJ, Cohen SR, Holmes RE. Midface distraction following Le Fort III and monobloc osteotomies: problems and solutions. *Plast Reconstr Surg* 2002; 109: 1797-1808.
8. Kaban LB, Conover M, Mulliken JB. Midface position after Le Fort III advancement: a long-term follow-up study. *Cleft Palate J* 1986; 23 Suppl 1: 75-77.
9. Kreiborg S, Aduss H. Pre- and postsurgical facial growth in patients with Crouzon's and Apert's syndromes. *Cleft Palate J* 1986; 23 Suppl 1: 78-90.
10. Marchac D, Renier D, Broumand S. Timing of treatment for craniosynostosis and facio-craniosynostosis: a 20-year experience. *Br J Plast Surg* 1994; 47: 211-222.
11. McCarthy JG, La Trenta GS, Breitbart AS, Grayson BH, Bookstein FL. The Le Fort III advancement osteotomy in the child under 7 years of age. *Plast Reconstr Surg* 1990; 86: 633-646; discussion 647-639.
12. Meazzini MC, Mazzoleni F, Caronni E, Bozzetti A. Le Fort III advancement osteotomy in the growing child affected by Crouzon's and Apert's syndromes: presurgical and postsurgical growth. *J Craniofac Surg* 2005; 16: 369-377.
13. Nout E, Cesteley N, van der Wal KG, van Adrichem LN, Mathijssen IM, Wolvius EB. Advancement of the midface, from conventional Le Fort III osteotomy to Le Fort III distraction: review of the literature. *Int J Oral Maxillofac Surg* 2008; 37: 781-789.
14. Peter L, Jacob M, Krolak-Salmon P, Petitjean T, Bastuji H, Grange JD, Vighetto A. Prevalence of papilloedema in patients with sleep apnoea syndrome: a prospective study. *J Sleep Res* 2007; 16: 313-318.
15. Ponniah AJ, Witherow H, Richards R, Evans R, Hayward R, Dunaway D. Three-dimensional image analysis of facial skeletal changes after monobloc and bipartition distraction. *Plast Reconstr Surg* 2008; 122: 225-231.

Chapter 6

Complications in maxillary distraction using the RED II device: a retrospective analysis of 21 patients

E. Nout¹

E.B. Wolvius¹

L.N.A. van Adrichem²

E.M. Ongkosuwito³

K.G.H. van der Wal¹

¹Department of Oral and Maxillofacial Surgery - Erasmus University
Medical Centre Rotterdam

²Department of Plastic and Reconstructive Surgery - Erasmus
University Medical Centre Rotterdam

³Department of Orthodontics, Sophia Childrens Hospital - Erasmus
University Medical Centre Rotterdam

Published

Int J Oral Maxillofac Surg. 2006 Oct;35(10):897-902

ABSTRACT

Rigid external DO in the treatment of midface hypoplasia has been shown to be effective and safe, but there have been several case reports on complications. Here is presented an overview of the complications in a series of 21 patients with various craniofacial anomalies. All patients were treated using RED II device after LF I or III osteotomy. Distraction started one week postoperatively and continued until Class I occlusion was achieved; it was then continued to include a fifteen percent overcorrection. All data were collected and categorized retrospectively from the patients' files. After a mean period of distraction of 34 days, 42 complications were reported in six different categories. Pin loosening (42.9 %) and frame migrations (28.6 %) were the most common complications. Of the frame migrations 25% were traumatic. Intracranial penetration of one fixation pin occurred during removal of the RED II device in one patient. From these results it can be deduced that application of the RED II device is associated with a substantial number of specific complications that mainly concern the pins of the halo-frame. The stability of the device is discussed as the distraction distance achieved was less than expected.

INTRODUCTION

In 1997, Polley and Figueroa introduced the RED device (KLS Martin, Tuttlingen - Germany) for the treatment of severe maxillary hypoplasia¹⁸. This device consists of a halo-frame attached to the skull, which exerts traction on the osteotomized maxilla via a tooth-borne intraoral splint and/or bone-borne fixation (**figure 1**). Since its introduction and recent modification, the RED device has shown to be an effective means of treatment in midfacial deficiencies^{5, 12, 19}. Advantages of the device include better vector control, unlimited distraction distance, effective traction, precise positioning, predictable results, distraction on LF I and III levels in the same procedure, and easy application and removal of the frame^{5, 6, 8, 11, 12, 19, 24}.

Since the widespread application of halo-frames in neurosurgical and orthopedic patients, complications associated with the use of these devices have been reported^{1, 3, 4, 7, 17, 22}. The forces exerted by the halo-frame on the skull are different in craniofacial applications compared with neurosurgical or orthopedic indications/patients. In addition, craniofacial patients form a heterogenous group, with various bone thickness, structure and skull deformities often due to previously performed cranioplasties. As neurosurgical or orthopedic application of halo-frames cannot be compared with craniofacial application, the need for assessment of the complica-

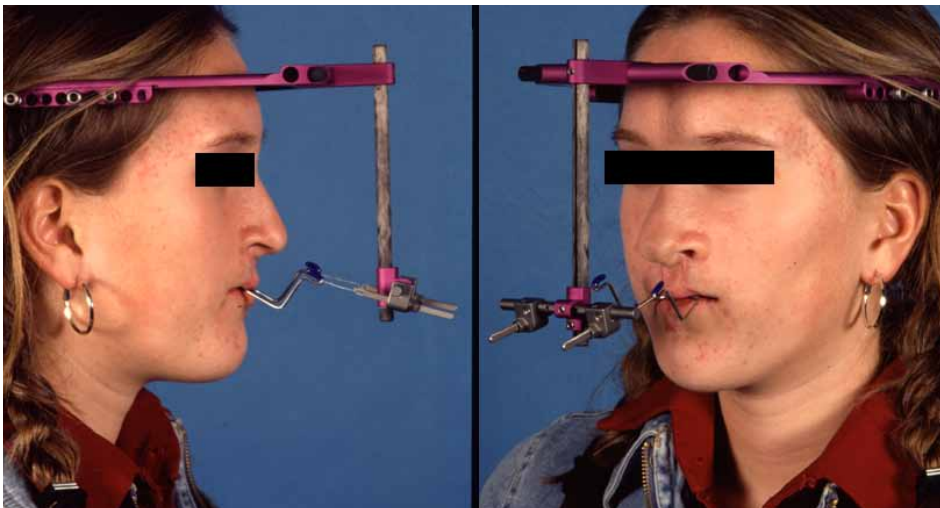


Figure 1: Fixation of the halo-frame of the RED II system parallel to the Frankfurter horizontal Plane. This cleft patient underwent a LF I osteotomy. Traction is exerted via an intraoral splint fixed onto the maxillary molars.

tions in the latter group is needed. Until now, only case reports have described complications of the RED system and no extensive series have been reported^{2, 5, 12, 13, 20, 21, 23}. In this study the halo-related complications of using the RED II device in a series of 21 craniofacial patients are analysed and discussed.

MATERIALS AND METHODS

Patients

Between December 2001 and January 2006, 21 patients, of which thirteen were males and eight females, were operated. All patients showed severe midfacial hypoplasia based on various anomalies (see **table 1**). Age at time of operation ranged between eleven and 35 years (mean seventeen years).

Preoperative management

Before surgery, an orthodontist treated the patients for a varying period of time. A preoperatively custom-made intraoral appliance was fixed onto the maxillary dentition. A CT-scan of the cranium was made to detect any possible bony defects. A standardized lateral X-ray was made to calculate the advancement necessary to achieve a stable angle Class I occlusion.

Perioperative procedure

Under general anesthesia, a LF I or LF III osteotomy was performed and the RED II device (KLS Martin, Tuttlingen, Germany) was placed. For fixation of the halo-frame to the cranium a variable number of three to five screws were inserted on each side of the skull. The RED frame was positioned parallel to the Frankfurter horizontal plane (**figure 1**).

Postoperative management

For all patients, distraction was performed according to the following distraction protocol.

1. Latency period

A postoperative latency period of seven days was applied to all patients irrespective of age or degree of advancement.

Table 1: Overview of minor complications for each patient.

Patient	Syndrome	Overjet	ANB	Operation	Frame migration	Pain pinsite	Pin loosening	Skin Infection	Scarring	Other	Specification/Remarks
1	CLAP left	11.9	14.5	LF I	2	1	1	1	1	0	1 traumatic and 1 atraumatic frame migration
2	Pfeiffer	25.6	12.6	LF III	1	0	1	0	0	0	
3	Dubowitz	13.2	9.6	LF I	1	0	1	1	0	0	
4	CLAP duplex	20.0	9.8	LF I	1	1	0	0	0	0	
5	Palatoschisis	15.8	17.0	LF I	0	0	1	0	0	0	
6	CLAP duplex	8.0	10.0	LF I	0	0	0	0	0	0	
7	CLAP duplex	12.8	5.6	LF I	0	0	1	0	0	0	
8	Midface hypoplasia	16.0	5.1	LF I	0	0	1	0	0	2	Headache frontal region Pin penetration during removal
9	Pfeiffer	10.8	8.2	LF III	1	1	1	0	0	0	
10	Apert	15.0	14.6	LF III	0	0	1	0	0	0	
11	Crouzon	10.9	3.5	LF III	1	0	1	0	0	1	Severe motivation problems Traumatic frame migration
12	Crouzon	9.1	12.6	LF III	1	0	1	0	1	0	
13	Van der Woude	10.0	1.5	LF I	0	0	1	0	0	0	
14	Apert	10.7	7.0	LF III	0	0	1	0	0	0	
15	Midface hypoplasia	14.2	22.1	LF III	1	0	1	0	0	1	Decubitis of the skin of the forehead
16	Apert	11.0	11.0	LF III	0	0	1	0	0	0	
17	Apert	11.3	13.0	LF III	0	0	1	0	0	0	
18	Pfeiffer	19.6	0.3	LF III	1	0	0	0	0	0	
19	Apert	13.1	9.0	LF III	1	0	1	0	0	0	
20	Crouzon	22.4	13.4	LF III	0	0	1	1	0	0	
21	Apert	6.8	7.3	LF III	1	0	1	0	0	0	Traumatic frame migration
Total					12	3	18	3	2	4	42
Percentage (%)					28.6	7.1	42.9	7.1	4.8	9.5	100
P-Value LF I vs LF III					0.96	0.36	0.36	0.36	0.75	0.63	

2. Distraction rate

Distraction rate was one mm per day.

3. Rhythm

Patients had to manually activate the screws twice daily at home after intensive instruction from the treating specialist. Normally, turning of the activation screws was performed once in the morning and once in the evening.

4. Duration of distraction

Distraction was continued for a varying period of time depending on the desired correction, i.e. the correction radiographically calculated to achieve a stable angle Class I occlusion with a sagittal overbite of zero plus an extra fifteen percent of this calculated advancement¹⁰. Patients were seen in an outpatient clinic on a weekly basis. Vector modifications took place during distraction when necessary.

5. Consolidation

There was a consolidation period of eight to twelve weeks. Removal of the RED II device took place under local anaesthesia, after which class III elastic traction was continued for three months. A postoperative lateral standardized X-ray was made to evaluate the distraction distance.

Data collection

Patient-data were collected from medical records retrospectively. All complications were logged on a spreadsheet and categorized by an independent specialist. Complications were scored at each postoperative contact with the patient and ranked in seven different categories (**table 1**).

Frame migration was considered to be present when the position of the halo-frame was different from the immediate postoperative position. Pain at pin-sites was scored only when the patient complained of it. Pin loosening was assessed by the maxillofacial surgeon and defined as one or more halo fixation pins that could be freely twisted without resistance or tip visibility at the edge of the skin. A score of 1 was given when pin loosening was observed during one or more postoperative contacts. Skin infections were diagnosed by local cellulitis at one or more pin-tips. Scarring was defined as one or more dermal marks left on the skin after healing of

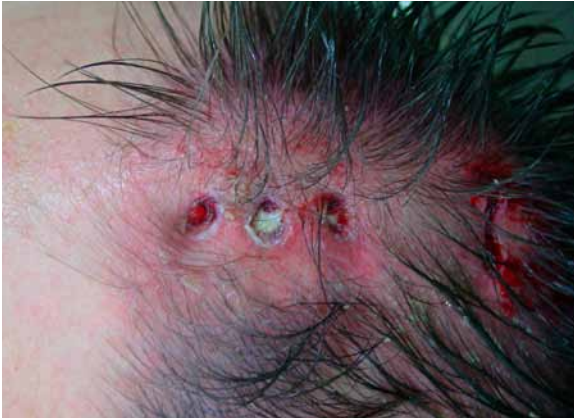

Figure 2: Perioperative view of extensive scarring after traumatic frame migration due to a fall, which required surgical removal of the halo-frame.

(traumatic) pin wounds. The category 'others' was used for any complication that did not fall in one of the previous categories.

Distraction distance was calculated cephalometrically by comparing preoperative and postoperative incisor's overjet and ANB on standardized lateral X-rays. Statistical analysis was performed using the Student's t-test.

RESULTS

Mean distraction distance was 13.7 mm overjet (± 4.8) and 9.9 degrees ANB (± 5.2). Distraction was performed for an average of 34 (± 18.7) days (range 14 - 99); the RED II device was in place for a mean of 84 (± 24.0) days (range 56 - 147). There was a mean follow-up of 452 (± 312) days (range 75 - 1199) after removal of the halo-frame. An overview of the complications is given in **table 1**.

In 21 patients, 42 complications have been identified in six different categories, and most (92.9 %) were directly pin-related. Decubitis of the skin of the forehead, seen in one patient, made early removal of the frame necessary. Early removal was also necessary in another patient because of severe motivation problems. Three of all frame migrations (25%) were traumatic. No fractures of the skull were seen after traumatic frame migrations, although in one case operative removal of the halo frame was necessary after frame migration due to a fall (**figure 2**).

Statistical comparison of complications between LF I and LF III patients showed no significant differences (**table 1**).

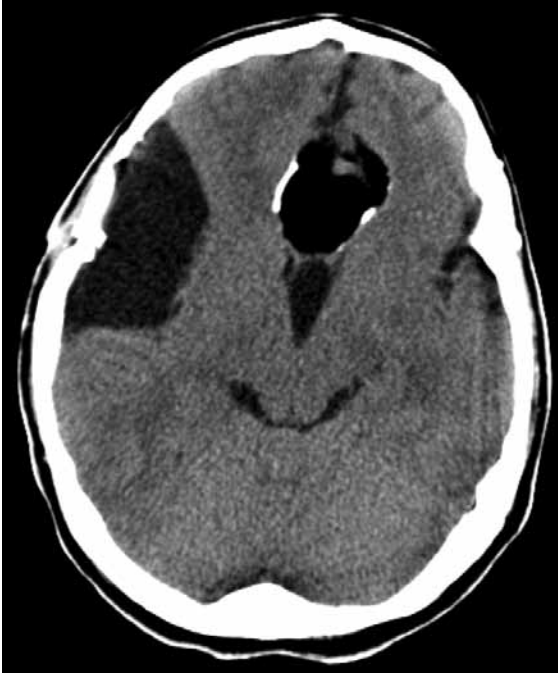

Figure 3: CT-scan after intracranial migration of one fixation pin during removal of the halo-frame. A large arachnoid cyst is seen lying directly under the local bone defect.

In one patient, a severe complication of intracranial penetration of a fixation pin occurred during removal of the halo-frame. This was accompanied by a cracking noise and cerebrospinal fluid leakage. The patient was admitted to hospital, and a CT-scan revealed a local fracture of the skull and communication with the arachnoid space where a large arachnoid cyst was present (**figure 3**). A lumbar puncture revealed meningitis with *Klebsiella pneumoniae*, which was treated clinically with broad-spectrum antibiotics intravenously for three weeks. Recovery was total without any rest symptoms²³.

DISCUSSION

DO of the craniofacial region was introduced in 1992 by McCarthy et al. for lengthening of the hypoplastic mandible¹⁵. Since then, this technique has been widely used for the treatment of various CFD, including orbital and maxillary deformities. DO of the midface can be achieved by using an intraoral as well as an extra-oral device. There is a definite preference for extraoral devices because of the ease of application, greater

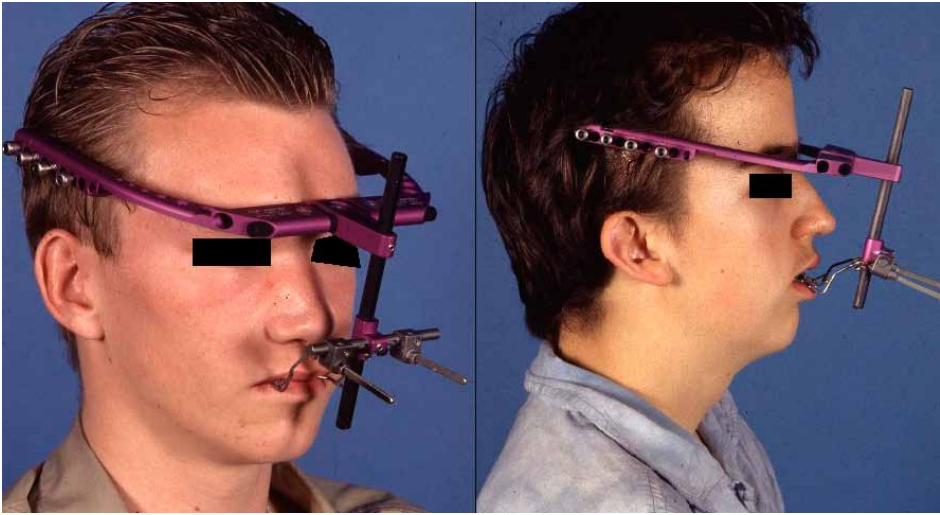


Figure 4: Two patients revealing atraumatic frame migrations due to pin loosening.

loads that can be applied, the greater advancement possible, and optimal vector control⁹; also, a second surgical procedure is not required to remove the distractor. From the neurosurgical and orthopedic literature, it is well-known that application of halo-frames can cause considerable complications. Garfin et al. were the first to identify complications related to the use of the halo external skeletal-fixation device⁷. They found that most complications are related to pin-sites: pin-loosening in 36 % of patients, pin-site infection in 20 %, pressure sores under either a plastic vest or a plaster cast in eleven percent, nerve injury in two percent, dural penetration in one percent, dysphagia in two percent, cosmetically disfiguring scars in nine percent, and severe pin discomfort in eighteen percent. Further research showed that the incidences of these complications are even higher in children^{1, 4}. By contrast, no information about incidence rates of complications in craniofacial patients is available. This is remarkable since this patient category might be even more prone to developing complications. In this series pin loosening was the most frequently occurring complication and resulted in non-traumatic frame migration in the majority of cases (**figure 4**). This seems to be in line with the research by Garfin et al.⁷ although the high incidence of frame migration (28.6%) is remarkable. Instability of the frame during the distraction period craniofacial patients might impair DO and thus functional and esthetic outcome.

Although the present study categorized complications in a smaller more specific patient cohort, great differences in complication rates can be observed. Relatively few patients complained about pain at pin sites, pressure sores and scarring when compared to the study of Garfin et al⁷. No dysphagia was scored in our series. As most of our patients were children, even higher complication rates might have been expected.

The present data also indicate that the achieved distraction distance does not match the distance that is expected from daily manual activation of the screws of the spindle unit. Distraction distance in vivo seems to lag behind the desired distraction rate of one mm per day. Several factors might contribute to this finding. Firstly, some patients seemed to be unreliable in turning the screws of the spindle unit daily, despite elaborate instructions given to each patient. The problems during postoperative follow-up were as follows: 1) turning of the screws of the spindle unit to the wrong side, 2) forgetting daily turning of the screws and 3) avoidance of daily turning due to pain when activating the spindle unit. Secondly, RED-related factors also contribute, the RED II device being not as stable and rigid as expected. Some distraction distance was initially lost because of traction on the threads that attach the spindle unit to the intraoral splint and/or bone born hooks, despite pre-operative stretching of the threads. The amount of play in the system is also likely to contribute; the frame itself as well as the extensions of the intraoral splint may contain some stretch. A certain amount of distraction will stretch the wires before any bony advancement occurs. The high rate of frame migrations and loosening of cranial fixation screws questions the rigidity of attachment of the device to the skull. There is no consensus yet in literature on how much force can be used to tighten the cranial fixation pins without inducing intracranial penetration¹⁶. Increasing the torque of each fixation pin does not seem to be an option for increasing frame stability. To spread the force needed for stability and lower the required torque of each fixation pin, Mavili et al. suggested an increase in the number of cranial fixation pins¹⁴.

Three traumatic frame migrations occurred in our series from various causes. Early intervention by the treating specialist allowed repositioning of the frames and correction of the vector, avoiding disturbance of the distraction process as much as possible. This had no effect on the final outcome.

These findings above suggest that much more control could be gained by daily turning of the spindle unit and cranial fixation screws by the treating specialist,



Figure 5: Example of setscrew placed between the tips of the RED II device to withstand possible collapse during removal of the halo-frame.

thereby maintaining adequate vector control and allowing early intervention. Although inconvenient for the patient and parents, the incidence of frame migration as well as of other minor complications could be significantly reduced.

Recently, psychological problems with halo devices have been reported²⁰. In the present series, early removal of the halo-frame was necessary in one patient because of severe motivation problems. By reducing the incidence of minor complications a short distraction period is maintained that could limit the psychological impact. The protocol was also adjusted for this purpose. Preoperatively, every patient and their parents are screened and informed about the treatment by a social worker and/or psychologist of the craniofacial team.

Intracranial penetration of one of the cranial fixation screws during removal of the halo-frame is described, causing meningitis with *Klebsiella pneumonia*²³. Probably, the total force exerted on the skull by the halo-frame was applied to this one fixation pin during removal. A setscrew was developed for use during removal of the frame to withstand these possible forces (**figure 5**). In patients who have undergone cranioplasty for correction of craniosynostosis, large bone defects in the skull can be found²¹. These patients seem to be at high risk for developing severe complica-

tions when considering the use of a halo-frame. Great attention should be paid to the placement of the pins. A preoperative CT-scan is essential for identifying possible defects in the skull and underlying pathology²⁵.

The RED II device is a reliable method of achieving DO of the midface but, in contrast to previous studies a substantial number of complications were encountered in this series^{6, 8, 18, 19, 24}. By implementation of the suggested changes, the authors are confident that it will be possible to reduce the incidence of such complications. Further research is necessary to establish the objective stability of the RED II system *in vivo*.

REFERENCES

1. Baum JA, Hanley EN, Jr., Pulekines J. Comparison of halo complications in adults and children. *Spine* 1989; 14: 251-252.
2. Brown R, Higuera S, Boyd V, Taylor T, Hollier LH, Jr. Intracranial migration of a halo pin during distraction osteogenesis for maxillary hypoplasia: case report and literature review. *J Oral Maxillofac Surg* 2006; 64: 130-135.
3. Celli P, Palatinsky E. Brain abscess as a complication of cranial traction. *Surg Neurol* 1985; 23: 594-596.
4. Dormans JP, Criscitiello AA, Drummond DS, Davidson RS. Complications in children managed with immobilization in a halo vest. *J Bone Joint Surg Am* 1995; 77: 1370-1373.
5. Fearon JA. The Le Fort III osteotomy: to distract or not to distract? *Plast Reconstr Surg* 2001; 107: 1091-1103; discussion 1104-1096.
6. Figueroa AA, Polley JW. Management of severe cleft maxillary deficiency with distraction osteogenesis: procedure and results. *Am J Orthod Dentofacial Orthop* 1999; 115: 1-12.
7. Garfin SR, Botte MJ, Waters RL, Nickel VL. Complications in the use of the halo fixation device. *J Bone Joint Surg Am* 1986; 68: 320-325.
8. Harada K, Baba Y, Ohyama K, Enomoto S. Maxillary distraction osteogenesis for cleft lip and palate children using an external, adjustable, rigid distraction device: a report of 2 cases. *J Oral Maxillofac Surg* 2001; 59: 1492-1496.
9. Haug RH, Nuveen EJ, Barber JE, Storoe W. An in vitro evaluation of distractors used for osteogenesis. *Oral Surg Oral Med Oral Pathol Oral Radiol Endod* 1998; 86: 648-659.
10. Hierl T, Klisch N, Kloppel R, Hemprich A. [Distraction osteogenesis in the treatment of severe midfacial hypoplasia] Therapie ausgeprägter Mittelgesichtsrucklagen mit Hilfe der Distractionsosteogenese. *Mund Kiefer Gesichtschir* 2003; 7: 7-13.
11. Kessler P, Kloss F, Hirschfelder U, Neukam FW, Wiltfang J. [Distraction osteogenesis in the midface. Indications, technique and first long-term results] Osteodistraction im Mittelgesicht. Indikationen, Technik und erste Langzeitergebnisse. *Schweiz Monatsschr Zahnmed* 2003; 113: 677-692.
12. Krimmel M, Cornelius CP, Roser M, Bacher M, Reinert S. External distraction of the maxilla in patients with craniofacial dysplasia. *J Craniofac Surg* 2001; 12: 458-463.
13. Le BT, Eyre JM, Wehby MC, Wheatley MJ. Intracranial migration of halo fixation pins: a complication of using an extraoral distraction device. *Cleft Palate Craniofac J* 2001; 38: 401-404.
14. Mavili ME, Vargel I, Tuncbilek G. Stoppers in RED II distraction device: is it possible to prevent pin migration? *J Craniofac Surg* 2004; 15: 377-383.
15. McCarthy JG, Schreiber J, Karp N, Thorne CH, Grayson BH. Lengthening the human mandible by gradual distraction. *Plast Reconstr Surg* 1992; 89: 1-8; discussion 9-10.
16. Mubarak SJ, Camp JF, Vuletich W, Wenger DR, Garfin SR. Halo application in the infant. *J Pediatr Orthop* 1989; 9: 612-614.
17. Papagelopoulos PJ, Sapkas GS, Kateros KT, Papadakis SA, Vlamis JA, Falagas ME. Halo pin intracranial penetration and epidural abscess in a patient with a previous cranioplasty: case report and review of the literature. *Spine* 2001; 26: E463-467.
18. Polley JW, Figueroa AA. Management of severe maxillary deficiency in childhood and adolescence through distraction osteogenesis with an external, adjustable, rigid distraction device. *J Craniofac Surg* 1997; 8: 181-185; discussion 186.

19. Polley JW, Figueroa AA. Rigid external distraction: its application in cleft maxillary deformities. *Plast Reconstr Surg* 1998; 102: 1360-1372; discussion 1373-1364.
20. Primrose AC, Broadfoot E, Diner PA, Molina F, Moos KF, Ayoub AF. Patients' responses to distraction osteogenesis: a multi-centre study. *Int J Oral Maxillofac Surg* 2005; 34: 238-242.
21. Rieger J, Jackson IT, Topf JS, Audet B. Traumatic cranial injury sustained from a fall on the rigid external distraction device. *J Craniofac Surg* 2001; 12: 237-241.
22. Tindall GT, Flanagan JF, Nashold BS, Jr. Brain abscess and osteomyelitis following skull traction. A report of three cases. *Arch Surg* 1959; 79: 638-641.
23. van der Meulen J, Wolvius E, van der Wal K, Prah B, Vaandrager M. Prevention of halo pin complications in post-cranioplasty patients. *J Craniomaxillofac Surg* 2005; 33: 145-149.
24. Weingart D, Roser M, Lantos P. [Mid-face distraction after LeFort III osteotomy in craniofacial dysmorphism] Mittelgesichtsdistraction nach LeFort-III-Osteotomie bei kraniofazialen Dysmorphien. *Mund Kiefer Gesichtschir* 2001; 5: 221-226.
25. Wong WB, Haynes RJ. Osteology of the pediatric skull. Considerations of halo pin placement. *Spine* 1994; 19: 1451-1454.

Carotid
Apert
Cerebral
dissection
midface
distraction
Complication

Part IV

Auxillary study

Chapter 7

Internal carotid dissection after Le Fort III distraction in Apert syndrome: a case report

E. Nout¹

I.M.J. Mathijssen²

J.J.N.M. van der Meulen²

M. C. van Veelen³

A.H. J. Koning⁴

M.H. Lequin⁵

E.B. Wolvius¹

¹Department of Oral and Maxillofacial Surgery - Erasmus University
Medical Centre Rotterdam, The Netherlands

²Department of Plastic and Reconstructive surgery - Erasmus
University Medical Centre Rotterdam, The Netherlands

³Department of Neurosurgery - Erasmus University Medical Centre
Rotterdam, The Netherlands

⁴Department of Bioinformatics, Faculty of Medicine - Erasmus
University Medical Centre Rotterdam, The Netherlands

⁵Department of Radiology - Erasmus University Medical Centre
Rotterdam, The Netherlands

Published

J Craniomaxillofac Surg. 2010 Mar 18. [Epub ahead of print]

ABSTRACT

A ten-year-old girl with Apert syndrome underwent a LF III osteotomy with the positioning of internal and external distraction devices. The operation was straightforward with no intraoperative complications. Very soon after completion of surgery an anisocoria (unilateral dilatation of a pupil) was noticed. This was followed by intracranial oedema which was fatal. The aetiology was dissection of the right internal carotid artery. The complications of LF osteotomies are discussed regarding patients with complex SCS and midface hypoplasia, such as Apert syndrome.

INTRODUCTION

The midface osteotomies and distractions have become common procedures. The reported rate of complications is low. Most have been described with the LF I osteotomy including haemorrhage, arteriovenous fistula, and ophthalmic symptoms, of which blindness is the most severe^{2, 6, 8, 12, 15, 21}. Of all midface procedures the LF I is the most popular and best documented.

Few complications have been described with the LF osteotomies and distractions performed at a higher level, such as the LF II and III^{4, 10, 14, 16, 18}. This is surprising as LF III distraction in a patient with SCS including midface hypoplasia is a major operation which occasionally involves serious co-morbidity.

A review of the current literature of this journal produced only one case report and one oral presentation pertaining to complications with the LF III osteotomy, both reporting only halo-pin related complications^{19, 22}.

We present the case of a ten-year-old girl with Apert syndrome, in which a LF III osteotomy with the placing of internal and external distraction devices was complicated by fatal intracranial oedema as a result of internal carotid artery dissection. The complications of LF procedures are discussed including the role of performing this surgery in patients with complex SCS and midface hypoplasia such as Apert syndrome.

CASE REPORT

A ten-year-old girl with Apert syndrome including midface hypoplasia, class III malocclusion and mild exorbitism had a LF III distraction (**figure 1**). Previously the patient had a tracheostomy at the age of thirteen months because of severe OSAS. After a MB-distraction at the age of fifteen months she was decanulated at the age of nineteen months. Following this there were no clinical signs of OSAS and PSG prior to the LF III demonstrated no OSAS (ODI < 1). The preoperative CT-scan showed normal sized ventricles and subdural space.

After an uncomplicated LF III osteotomy bilateral internal midface distractors (Marchac devices, Martin Medizin Tuttingen, Germany) were positioned with a few millimetres of distraction and the RED-II (Martin Medizin Tuttingen, Germany) was applied. Total operation time was 3 and a half hours, with a blood loss of 1.5 litres.

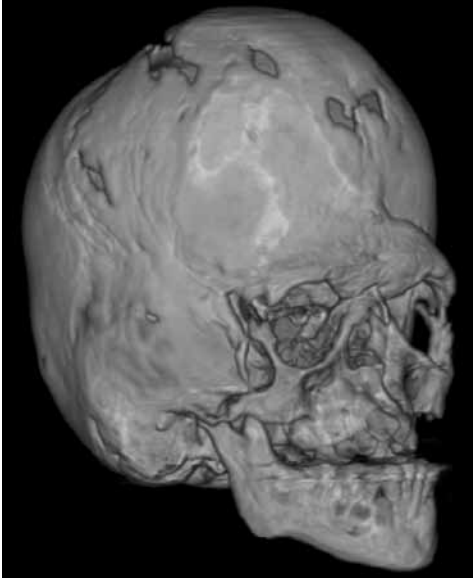


Figure 1: Preoperative 3D CT-scan of ten-year-old patient with Apert syndrome in which a LF III distraction with internal and external devices was planned.

Near the end of the operation, a drop of blood pressure and a tachycardia was noticed, with rapid normalisation. At the end of the operation an anisocoria was noticed. A CT-scan revealed a subdural haemorrhage in the right parietal region, a cerebral midline shift to the left, a hypodense right hemisphere and uncal herniation (**figure 2**). The parietal subdural haemorrhage itself appeared too small to

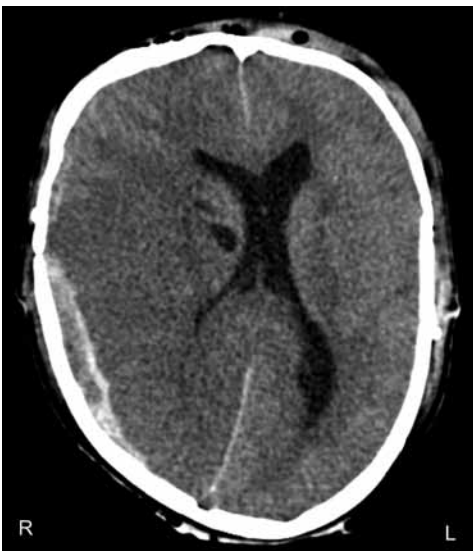

Figure 2: The first postoperative CT-scan revealed subdural haemorrhage on the right parietal side, a cerebral midline shift to the left, a swollen, hypodense right hemisphere and uncal herniation.

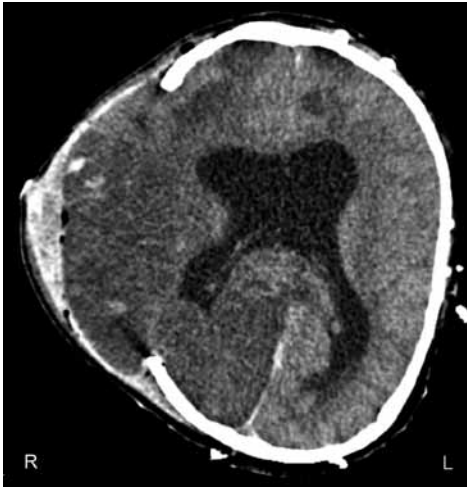


Figure 3: The follow-up CT-scan demonstrated an increasing hypodensity of the right hemisphere, suggestive for ischemia, an increase of the cerebral midline shift and a complete compression of the peripheral liquor space.

explain the severe midline shift. Direct neurosurgical intervention was initiated with decompression and the removal of all distraction devices. Two puncture wounds of the dura were found at the site of the internal distractor, without sign of bleeding. After opening the dura, a large swelling of the cortex with decreased vascularisation was noticed. There was significant loss of clotted and fresh blood in the temporo-occipital, temporal and frontal areas. The boneflap was buried subcutaneously in the abdomen and a transposition flap of the scalp was performed to cover the exposed brain. A total of 6 litres of blood was lost.

At the end of the procedure an ICP monitoring device was inserted. The ICP at this stage was 34 mm Hg (normal value: seven to fifteen mm Hg). A CT-scan demonstrated increasing hypodensity of the right hemisphere, suggestive of ischemia, an increase of the cerebral midline shift and a complete compression of the peripheral subdural space (**figure 3**). Although the neurosurgeon added an external drain, the ICP increased to 50 mm Hg.

To investigate the possible cause of the brain ischemia, CTA was performed (**figure 4**). As an adjunct to the CTA, we used the V-Scope volume rendering application in the Erasmus MC I-Space, an immersive VR system, to provide interactive, 3D images of the CTA. Research has shown that there is additional value in using such a system when studying small details and measuring structures in 3D datasets³. The CTA demonstrated that there was abnormal calibre of the right internal carotid artery. This was diagnosed as a vascular dissection (**figure 5**). The left internal carotid artery was normal.

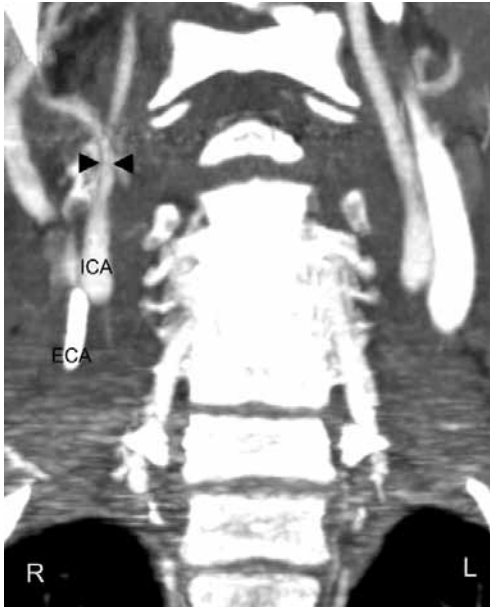

Figure 4: CTA demonstrated a change in calibre of the right internal carotid artery (arrows). This finding is consistent with a dissection. The left internal carotid artery is normal. ICA = internal carotid artery; ECA = external carotid artery.

In hindsight, hypodense areas, probably old lacunar infarcts with parenchymal loss in the distribution of the right medial cerebral artery could already be seen on a CT-scan carried out at 16 months of age, following the MB distraction, which unfortunately were previously unrecorded. These infarcts were not present on the first CT-scan, prior to the MB.

Unfortunately, due to progressive extensive cerebral oedema the patient died four days after surgery. Postmortem investigation revealed no fracture of the base of the skull and no problems related to the external and internal distraction devices. No further exploration of the carotid arteries was undertaken.

DISCUSSION

The LF III osteotomy with DO is a widely practiced technique to correct midface hypoplasia in patients with SCS, such as Apert, Crouzon and Pfeiffer syndrome. Various complications have been described with this procedure, but the incidence seems to be low and appears to be mostly related to the distraction devices and not to the osteotomy itself¹⁶. Matsumoto et al. described a patient with Crouzon syndrome in which a LF III distraction was performed with the positioning of a RED-II device in

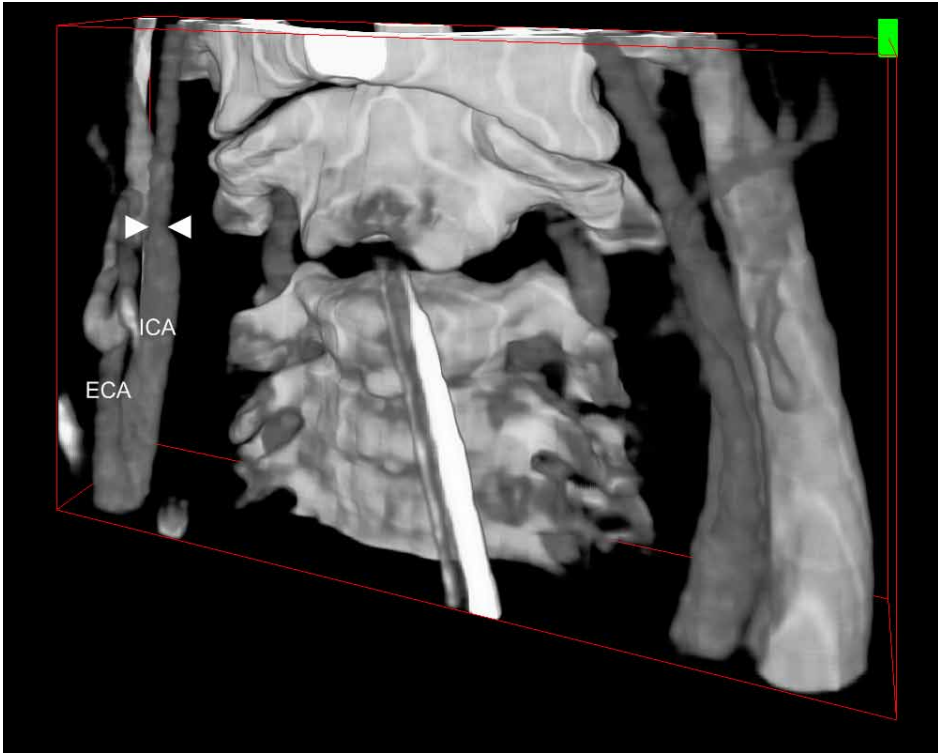

Figure 5: 3D image of the CTA dataset demonstrating the calibre difference between the left and right carotid artery. A marked constriction in the right carotid artery is visible (arrows). ICA = internal carotid artery; ECA = external carotid artery.

whom a lethal haemorrhage occurred from the right posterior maxillary region, most likely resulting from a skull base fracture of the middle cranial fossa¹⁴. Pterygoid maxillary dysjunction and down fracture manipulation was suggested as the most important aetiological factor. These two factors probably result in a vector of force that pushes the pterygoid plates posteriorly. Subsequently, the force is transferred to the skull base through the sphenoid bone. In patients with congenital craniofacial anomalies, such as Apert, Crouzon and Pfeiffer syndrome, besides craniosynostosis and midface hypoplasia, an abnormal skull base can be found²⁰. When studying the preoperative CT-scans surgeons should pay attention to the individual anatomical appearance of the skull base to enable them to carefully assess the approach to the pterygomaxillary separation. Several technical improvements of this maneuver have been described, but at present most surgeons probably perform the dysjunction with a thin slightly curved LF osteotome. In our craniofacial centre, the correct position of

the tip of the osteotome for dysjunction in the LF III procedure is first checked intraorally with a finger. The osteotome is inserted from above, via the temporal fossa, and not from an intraoral approach. The surgeon feels the tip of the osteotome submucosally coming palatally through the bone somewhere around the junction of the hard and soft palate. With this antero-medial direction posterior-superior compression of the pterygoid process is avoided. An alternative approach, utilising a right-angled oscillating saw and an endoscopic approach for pterygomaxillary dysjunction has been described⁵. Another critical step and possible pitfall in performing a LF III osteotomy in syndromic patients, is the position of the anterior cranial fossa in relation to the nasal bone through which an osteotomy is to be planned. This close relationship is demonstrated on the axial slice of the preoperative CT scan of an 8-year-old patient with Crouzon syndrome (**figure 6**).

In our centre one of the last surgical steps of LF III osteotomy is the median osteotomy through the nasal septum starting from the osteotomy line through the nasofrontal suture pointing posterior-caudally towards the middle of the most posterior part of the maxilla. This vector must be corrected for an abnormal anteriorly located anterior cranial fossa.

In the patient we present a dramatic cascade of events followed a LF III distraction, probably as a result of a dissection of the right internal carotid artery as diagnosed from the CTA. To our knowledge this complication has not been described earlier. Although most carotid artery dissections in children are spontaneous and are associated with considerable morbidity, in some case reports it is associated with a traumatic event¹¹.

Keil et al. reported the case of an eight-year-old boy who suffered an internal carotid artery dissection following intraoral soft tissue trauma⁹. He developed a cerebral infarction in the vascular territory of the left middle cerebral artery. The patient survived after decompression hemicraniectomy with ICP measurements, but after five weeks the patient was still hemiparetic and aphasic.

Even chiropractic manipulation of the neck may cause a traumatic carotid dissection as has been described in an adult patient^{7,9}.

A LF III down fracture is a major soft tissue trauma in the head and neck region. Given the MB distraction that was carried out ten years earlier, the LF III down fracture was probably even more traumatic, since the last procedure was carried out in area of scar tissue. In addition, the first MB procedure seems to have caused a similar vascular incident, given the hypodensities on the postoperative CT-scan.

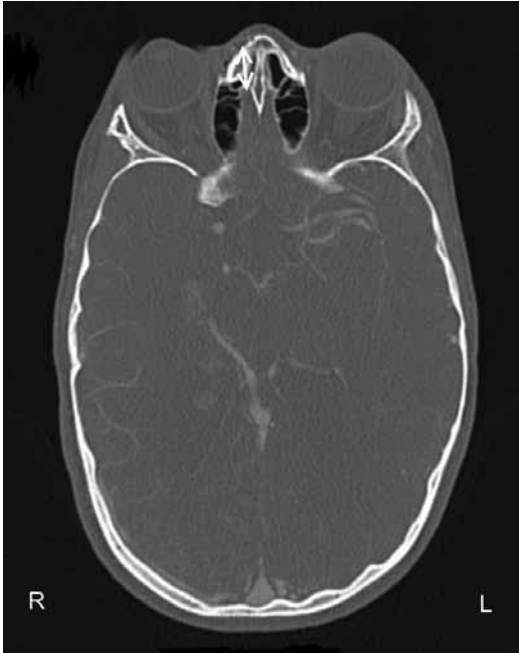

Figure 6: CT-scan of an 8-year old patient with Crouzon syndrome with a relative short distance from the planned osteotomy line through the nasofrontal suture towards the anterior cranial fossa (arrow).

At that time, no postoperative neurological changes were noticed in the patient, and thus no particular attention was paid to the findings on the scan. In hindsight, this should possibly have been considered as a warning sign of potential complications following further surgery.

Another possible aetiological co-factor for the complication in this case is that this type of surgery was performed in a patient with Apert syndrome. Marucci et al. analysed a group of 24 cases of Apert syndrome¹³. It was concluded that there was a high incidence of raised ICP, which can first occur at any age up to five years and may recur despite initial successful treatment. Causes of raised ICP include craniocerebral disproportion, venous hypertension, upper airway obstruction from midface hypoplasia, and hydrocephalus. In a retrospective study on 84 patients with Apert, Crouzon, or Pfeiffer syndrome, the prevalence of papilloedema, as a sign of raised ICP was found to be high, not only before cranial decompression but also after cranial vault expansion¹. As a consequence, it should be borne in mind that the intracranial mechanisms in Apert syndrome to compensate for a relative minor raise of ICP, i.e. due to surgery, are probably limited, especially in case of a swelling or a relatively small hematoma. Other reports on Apert syndrome seem to concentrate on intracranial anomalies detected by imaging studies. Quintero-Rivera

et al. found ventriculomegaly in 76 % of the 30 patients with Apert syndrome ¹⁷. Dissection of the internal carotid artery in Apert syndrome has never been reported. At present all patients with SCS who are candidates for midface procedures in our craniofacial centre are analyzed with CTA. We hope to gain more insight in the intra- and extracranial abnormalities in these complex patients. This can enable us to inform our patients more accurately about possible operative risks.

Finally, several reports have mentioned considerable problems using distraction devices, both internally and externally ^{4, 10, 14, 16, 18}. Accidental head injury and intracranial migration of halo pins have been described giving rise to serious complications. In addition, the quality of the bony skull in patients with craniofacial anomalies is often compromised due to earlier cranioplasties. In our case no problems with the distraction devices could be observed postmortem.

Conclusion

The LF III distraction is a major extracranial procedure and may result in devastating intracranial complications. For surgical planning preoperative CTA is justified in order to identify possible vascular anomalies, especially in patients with Apert syndrome. Haemodynamic and neurosurgical parameters should be carefully monitored, with special emphasis on ICP, in order to guide the patient safe through surgery and the initial postoperative period. The management of these patients should be multidisciplinary and focused in specialised centres.

REFERENCES

1. Bannink N, Joosten KF, van Veelen ML, Bartels MC, Tasker RC, van Adrichem LN, van der Meulen JJ, Vaandrager JM, de Jong TH, Mathijssen IM. Papilledema in patients with Apert, Crouzon, and Pfeiffer syndrome: prevalence, efficacy of treatment, and risk factors. *J Craniofac Surg* 2008; 19: 121-127.
2. Bendor-Samuel R, Chen YR, Chen PK. Unusual complications of the Le Fort I osteotomy. *Plast Reconstr Surg* 1995; 96: 1289-1296; discussion 1297.
3. Bol Raap G, Koning AH, Scohy TV, ten Harkel AD, Meijboom FJ, Kappetein AP, van der Spek PJ, Bogers AJ. Virtual reality 3D echocardiography in the assessment of tricuspid valve function after surgical closure of ventricular septal defect. *Cardiovasc Ultrasound* 2007; 5: 8.
4. Brown R, Higuera S, Boyd V, Taylor T, Hollier LH, Jr. Intracranial migration of a halo pin during distraction osteogenesis for maxillary hypoplasia: case report and literature review. *J Oral Maxillofac Surg* 2006; 64: 130-135.
5. Chen YR, Fisher, D.M. Discussion. Blindness as a complication of Le Fort osteotomies: role of atypical fracture patterns and distortion of the optic canal. *Plast Reconstr Surg* 1998; 102: 1422-1423.
6. Cruz AA, dos Santos AC. Blindness after Le Fort I osteotomy: a possible complication associated with pterygomaxillary separation. *J Craniomaxillofac Surg* 2006; 34: 210-216.
7. Gamer D, Schuster A, Aicher K, Apfelstedt-Sylla E. [Horner's syndrome in dissection of the carotid artery after chiropractic manipulation]. *Klinische Monatsblätter für Augenheilkunde* 2002; 219: 673-676.
8. Giroto JA, Davidson J, Wheatly M, Redett R, Muehlberger T, Robertson B, Zinreich J, Iloff N, Miller N, Manson PN. Blindness as a complication of Le Fort osteotomies: role of atypical fracture patterns and distortion of the optic canal. *Plast Reconstr Surg* 1998; 102: 1409-1421; discussion 1422-1403.
9. Keil T, Deeg KH, Lenhart M, Mirzai S, Heesen M. [Carotid artery dissection with cerebral infarction after soft tissue trauma in the pharyngeal region]. *Der Anaesthetist* 2006; 55: 1266-1270.
10. Le BT, Eyre JM, Wehby MC, Wheatley MJ. Intracranial migration of halo fixation pins: a complication of using an extraoral distraction device. *Cleft Palate Craniofac J* 2001; 38: 401-404.
11. Lequin MH, Peeters EA, Holscher HC, de Krijger R, Govaert P. Arterial infarction caused by carotid artery dissection in the neonate. *Eur J Paediatr Neurol* 2004; 8: 155-160.
12. Lo LJ, Hung KF, Chen YR. Blindness as a complication of Le Fort I osteotomy for maxillary distraction. *Plast Reconstr Surg* 2002; 109: 688-698; discussion 699-700.
13. Marucci DD, Dunaway DJ, Jones BM, Hayward RD. Raised intracranial pressure in Apert syndrome. *Plast Reconstr Surg* 2008; 122: 1162-1168; discussion 1169-1170.
14. Matsumoto K, Nakanishi H, Seike T, Koizumi Y, Hirabayashi S. Intracranial hemorrhage resulting from skull base fracture as a complication of Le Fort III osteotomy. *J Craniofac Surg* 2003; 14: 545-548.
15. Morris DE, Lo LJ, Margulis A. Pitfalls in orthognathic surgery: avoidance and management of complications. *Clin Plast Surg* 2007; 34: e17-29.
16. Nout E, Wolvius EB, van Adrichem LN, Ongkosuwito EM, van der Wal KG. Complications in maxillary distraction using the RED II device: a retrospective analysis of 21 patients. *Int J Oral Maxillofac Surg* 2006; 35: 897-902.

17. Quintero-Rivera F, Robson CD, Reiss RE, Levine D, Benson CB, Mulliken JB, Kimonis VE. Intracranial anomalies detected by imaging studies in 30 patients with Apert syndrome. *American journal of medical genetics* 2006; 140: 1337-1338.
18. Rieger J, Jackson IT, Topf JS, Audet B. Traumatic cranial injury sustained from a fall on the rigid external distraction device. *J Craniofac Surg* 2001; 12: 237-241.
19. Spinelli G GL, Raffaini M, Giannini D. O.136 Complications concerning the Le Fort III facial osteo-distraction *Journal of Cranio-Maxillofacial Surgery* 2006; 34: 39.
20. Tokumaru AM, Barkovich AJ, Ciricillo SF, Edwards MS. Skull base and calvarial deformities: association with intracranial changes in craniofacial syndromes. *AJNR Am J Neuroradiol* 1996; 17: 619-630.
21. Tung TC, Chen YR, Bendor-Samuel R. Surgical complications of the Le Fort I osteotomy--a retrospective review of 146 cases. *Changgeng Yi Xue Za Zhi* 1995; 18: 102-107.
22. van der Meulen J, Wolvius E, van der Wal K, Prahel B, Vaandrager M. Prevention of halo pin complications in post-cranioplasty patients. *J Craniomaxillofac Surg* 2005; 33: 145-149.

conclusions
Planning
Follow-up
Dynamic
Long-term
outcome
OSAS
epilogue
discussion
Hypertelorism
Prospective
study
Cephalometry
research
Orthognathic
Facial
Overcorrection
future
Complications
bipartition
Exorbitism
measurements

Part V

General Discussion

Chapter 8

General discussion and conclusions

E. Nout

In this thesis several aspects of the LF III osteotomy have been investigated. More specifically, this thesis addresses fundamental effects on exorbitism and OSAS, which are both pressing indications to perform a LF III advancement. Concerning the respiratory outcome, the influence of LF III advancement on the short- and long-term is assessed. In addition, the orthognathic outcome following midface advancement is addressed. Complications associated with LF III advancement have been inventoried, rendering recommendations for prevention of treatment-associated complications. These subjects will be discussed separately using the results from the studies described in the previous chapters.

EXORBITISM

Severe exorbitism is a pressing indication to perform advancement of the midface in SCS patients. The shallow orbits are associated with the typical syndrome-related midface hypoplasia leading to the high incidence of exorbitism in these patients. Exorbitism can pose a threat to the eye itself, by predisposing patients to exposure keratitis, mechanical lagophthalmos, corneal ulcers and loss of vision. By advancing the midface, the infra-orbital and/or supra-orbital rim (MB) is transferred anteriorly to reduce the shallow orbits. Clinically, reduction of exorbitism has been objectified. In chapter two, the position of the infra-orbital rim and globe was evaluated together with the change of orbital volume after midface advancement in eighteen SCS patients. For this purpose, a reference coordinate system was developed enabling inter-patient comparisons independent of differences in head position between the CT-scans. The results showed that the infra-orbital rim was significantly transferred anteriorly. Although no significant anterior movement of the globe could be observed; both globes did move slightly medially. In addition, the orbital volume increased significantly after LF III advancement and this correlated with the anterior movement of the infra-orbital rim. These findings indicate that after LF III advancement the infra-orbital rim is transferred anteriorly, leaving the globe in place, leading to an evident volume gain of the bony orbits.

OSAS

A review of the literature revealed a high prevalence of OSAS in SCS patients (chapter one). In general, OSAS in children carries a higher risk of obstructive hypoventilation when compared to adults. Due to the severe midface hypoplasia, SCS patients are often prone to severe OSAS. Depending on the severity, OSAS can be treated surgically or non-surgically. Examples of non-surgical treatment modalities are local glucocorticoid application, nocturnal oxygen supplementation, nasopharyngeal tube, mandibular reposition appliance and CPAP. Examples of surgical treatment are adenotonsillectomy, tracheostomy and craniofacial surgery, such as LF III and MB advancement. Clinically, the LF III advancement shows a positive influence on the outcome of OSAS. OSAS seems related to a compromised airway patency. Several factors can influence the patency of the airway. The upper airway volume is one of the factors that is known to influence the patency of the upper airway. A quantification method was introduced in chapter three to investigate the change in airway volume due to LF III advancement. Overall, upper airway volume increased after LF III advancement, particularly on the level of the nasal cavity and nasopharynx. Interestingly, in the patient cohort described in chapter three, no correlation could be found between the degree of advancement and the upper airway volume gain. Two possible explanations are postulated. In the first place, by careful examination of the 3D visualizations of the segmented airways of the subjects, we found that the shape of the airway was remarkably irregular. The shape of the airway was nothing like the 'hollow tube' one might expect it to be. The complex anatomical irregularities of the base of the skull in SCS patients may account for the unpredictable pattern of airway volume change following midface advancement. Secondly, two different measurements are compared: a 2D advancement measurement performed on a projection radiograph, and a 3D volume measurement performed on a CT-dataset. The ICC of our volume measurement was very high, whereas the 2D advancement measurement has a limited reproducibility.

In chapter four, the short-term and long-term effects of LF III advancement are described. The changes in respiratory outcome were correlated to the changes in upper airway volume measurements (chapter 4a). In most cases midface advancement resulted in an improvement of OSAS. However, in a substantial number of cases residual OSAS was present in spite of a significant upper airway volume gain on level of the nasopharynx and nasal cavity. In these patients, other levels of obstruction

could be identified. In chapter 4a, obstructions on the level of hypopharynx, nasal cavity and nasopharynx could be effectively corrected by mandibular advancement, nasal septum correction and adenotonsillectomy respectively. Besides this, it is likely that volume gain of the upper airway may not be sufficient to overcome the decreased patency of the upper airway in all patients with OSAS. Other factors, such as for example pressure gradient drop, length of the airway and the ratio between peripharyngeal fat and dilator muscle quantity in the pharyngeal walls are not affected by midface advancement and require other treatments.

In order to determine the outcome of midface advancement after several years and assess the outcome of patients with less severe preoperative OSAS-scores, the study described in chapter 4b was undertaken. In this study also non-responders to midface advancement were identified. In these non-responders, endoscopy of the upper airway showed a collapse of the pharyngeal walls, nasal septum deviation and an obstruction at the level of the hypopharynx. After surgical intervention by means of a nasal septum correction and BSSO, a marked improvement of OSAS was found. Severe or moderate forms of OSAS not only seem to be caused by midface hypoplasia; dynamic pharyngeal wall collapse and nasal or pharyngeal obstructions seem to attribute as well to the outcome of OSAS.

Besides endoscopy of the upper airway and PSG measurements, upper airway volume measurements can act as an extra non-invasive tool to evaluate the effect of midface advancement since the degree of advancement does not reflect the intrinsic airway volume gain. However, one should be aware that the upper airway volume gain does not reflect the improvement of the upper airway patency. In case of evident volume gain of the upper airway following midface advancement but with a persistent diagnosis of OSAS, other levels of obstruction must be identified. Preoperative endoscopy of the upper airway is advised to identify the exact level of obstruction in SCS patients with OSAS. The treatment plan can be adjusted to the endoscopic outcome and to avoid overtreatment.

ORTHOGNATHIC OUTCOME

Fearon advocated that LF III distraction osteogenesis allows for enough advancement to overcome an extra LF III osteotomy after cessation of growth.¹ Depending on the indication, LF III advancement aims to either reduce exorbitism, OSAS, correct the

occlusion or change the patients' appearance. Frequently a stable class I occlusion is not achieved. To achieve a functional class I interjaw relationship, many authors report additional orthognathic surgery. Retrospective evaluation of 41 SCS patients, undergoing either LF III or MB advancement, revealed that seven patients underwent additional orthognathic surgery (chapter five). Imaginably this number will increase as seventeen patients were younger than eighteen years at the end of follow-up. Furthermore, in the patients older than eighteen years of age at the end of follow-up, 39% of these patients did not have a class I occlusion. In conclusion, the minority of patients underwent additional orthognathic surgery, although the majority of patients had an indication to undergo this surgery. Most likely, due to patient factors this was not performed.

COMPLICATIONS

With the introduction of DO in cranio-facial surgery, the degree of advancement was greatly expanded. DO also eliminated donor site morbidity. Several authors reported lower relapse rates, reduced operation time, reduced blood loss, hospital stay and postoperative pain. Although the advantages of DO are exuberantly reported in literature, disadvantages are also worth mentioning.

While working with external distraction in SCS patients, some serious complications were encountered. It was decided to score the halo-related complications in the SCS patient cohort (chapter six), especially since halo-related complications have been frequently reported in the neurosurgical and orthopaedic literature. Analysis revealed that pin loosening was the most common complication. However one potential life-threatening complication occurred. Traumatic intracranial migration of one of the halo-fixation pins occurred during removal of the halo-frame, most likely due to intra-device strain and syndrome-related anomalies of the calvarial bones. Besides device-related complications also osteotomy-related complications are possible. In a Crouzon patient a lethal haemorrhage of the posterior maxillary region has been described. In this thesis, lethal dissection of the internal carotid artery was reported in a patient with Apert syndrome (chapter seven). Thus both device- and patient-related factors should be taken into account when planning these extensive procedures. To minimize complications one should always consider the patient's history as previous surgery causes scar tissue formation that might cause unwanted

fracture lines during the actual down fracture procedure. Furthermore, previous cranioplasty can leave bony defects in the skull. Syndrome-specific characteristics should be taken into account since SCS patients are associated with an abnormal skull base when compared to non-syndromic individuals. Especially Apert patients are associated with a high incidence of raised ICP, intracranial anomalies and vascular anomalies. Possibly vascular anomalies might be present in these patients as well. A preoperative CTA is advised to detect these vascular anomalies. The surgical technique should be adjusted according to the anatomy of each individual. To minimize the risk of intracranial pin migration during the removal of a halo frame a setscrew was developed. In patients with large bony defects one might consider the use of internal distractors instead of the halo frame. Titanium mesh-plates, positioned directly at the bone underneath the pin sites, can be indicated to support the frame. To increase the chance of a successful distraction and consolidation period, a patient compliance is mandatory. Pre-operative psychological screening is advised. Especially in adolescents (patients between twelve and seventeen years) the halo frame can be stressful and expectations of the patients regarding the final outcome might not be realistic. In these complex patients standardized treatment protocols should be adopted with care.

REFERENCES

1. Fearon JA. Halo distraction of the Le Fort III in syndromic craniosynostosis: a long-term assessment. *Plast Reconstr Surg* 2005; 115: 1524-1536.

Chapter 9

Epilogue and future perspectives

E.Nout

This chapter discusses the limitations of the current study and questions that could not be answered. Future perspectives are presented.

EXORBITISM

In chapter two the results from our fundamental study indicated that after LF III advancement the orbital volume increased, the position of the infra-orbital rim moved anteriorly and the position of the globe was nearly stable except for a slight medial movement. A reference frame was designed to allow for these measurements. The inter-observer correlation of this method appeared to be acceptable. Future research therefore will focus on applying this method in patients undergoing MB and facial bipartition. Besides evaluating orbital position and infra-orbital rim position, this method can be used to evaluate the movement of the LF III or MB segment by marking anatomical landmarks defining the boundaries of the segment. In this way relapse after midface advancement might be monitored more precisely in three dimensions. In a prospective study, this technique may serve as a tool to relate the anatomical changes induced by LF III to the clinical extent of exorbitism and quantify the effect of (secondary) orbital reconstruction including correction of enophthalmus, surgical correction of Graves orbitopathy, and ophthalmic surgery. A prospective study will be initiated to evaluate the influence of strabismus surgery on the globe position.

OSAS

OSAS is known to have a complex aetiology. By evaluating the upper airway volume changes after surgical intervention and the long-term respiratory outcome, more insight is gained in the aetiology of OSAS. However, due to the rarity of SCS, patient numbers in all three studies are small. Therefore it seems that the findings should be interpreted with care.

In chapter three, the effect of midface advancement on the upper airway volume was evaluated and a positive correlation was found. No correlation was found between the upper airway volume gain and the degree of midface advancement. Since the reproducibility of the advancement measurement is limited compared to the volume measurement, more sophisticated measurements of the advancement

are called for, e.g. 3D cephalometry. As this technique was recently introduced, we cannot present any comparative data as of yet. Future research will focus on this topic.

In chapters 4a and 4b we reported on the respiratory outcome and correlation between the upper airway volume changes and PSG data after LF III and MB advancement on the short and long term respectively. These two studies are characterized by the limitations associated with retrospective analyses. From the initial patient cohort only a small number of SCS patients had sufficient data to be included and/or met the inclusion criteria. From the included patients the age range was quite disparate. The standard deviation of the pre- and postoperative CT-scans and PSG's varied. Ideally, evaluation should have taken place in a larger, more uniform patient cohort according to a more strict protocol. In addition, the data should be correlated with the degree of advancement of the midfacial segment as well. Future research will be initiated with strict protocols.

Although the ICC of the upper airway volume measurements showed to be acceptable (chapter three), the calculated upper airway volumes can only indicate the airway volume at a given time. OSAS is known to be a dynamic process that manifests during sleep. The static reflection that was observed might therefore not be representative. In addition, the upper airway volume measurements are influenced by difficulties in defining the anatomical borders of the upper airway in the CT-scan, which is dependent on the quality of the CT-scan and can be adversely influenced by artefacts due to movement during scanning. By attuning scanning time and contrast, these artefacts might be reduced as well as the patients' exposure to radiation. Also the ongoing development of multi-slice CT-scans may aid in reducing scanning time while maintaining high quality images. In the near future upper airway volume measurements will use data from higher-sliced CT-scans.

Another factor that influences the volume measurements is the thickness of the upper airway lining mucosa and submucosa, which varies with the state of health of the subjects. In conclusion, multiple CT-scans of the upper airway should ideally be made during sleep to gain insight in dynamic processes of OSAS. For now, this is not realistic. Perhaps in the future modalities will be developed to observe the dynamic anatomical changes during sleep in patients with OSAS.

As mentioned before, it seems like the contribution of enlargement of the upper airway is only partial responsible for the improvement of the respiratory outcome of OSAS patients. OSAS is known to have a complex multifactorial etiology which

is associated with the decreased patency of the upper airway. Future research will focus on evaluating the influence of midface advancement on factors such as intraluminal pressure and airflow dynamics. The outcomes of these studies should be incorporated in the above findings to gain more insight in the etiology of OSAS.

ORTHOGNATHIC OUTCOME

Although chapter five constitutes a substantial number of patients, 41.5 % of the patients of this cohort were younger than eighteen years at the end of follow-up. Ideally, all patients were over eighteen years of age at the end of the study period. Some underestimation of the indications for additional orthognathic surgery in the present cohort is likely to have occurred. Therefore it seems sensible to re-evaluate the present cohort when all patients have completed growth.

Regarding the indication for additional orthognathic surgery, a substantial number of patients who did complete growth, showed evident malocclusions and were not scheduled for orthognathic surgery. Most likely patient factors are to blame. In some of these cases it was chosen to orthodontically compensate for the malocclusions. Incorporation of orthodontic therapy in the software planning will give insight in the whole treatment plan.

The cohort consisted of two patients who underwent LF I osteotomy together with a conventional LF III osteotomy. This technique managed to overcome additional orthognathic surgery in these patients. Future research should focus on evaluation of this technique using segmental DO.

The results of the studies described in chapters three and four indicate that following midface advancement upper airway volume significantly increases, but in a substantial number of patients the OSAS persists. It is unknown to what extent the midface needs to be advanced to overcome OSAS in every single patient. In order to maximize the treatment outcome, the conducted craniofacial protocol signifies overcorrection of midface advancement to account for future growth and increase the chance for long-term reduction of OSAS. As a result, this is likely to create an increased sagittal overbite at level of the occlusion and/or creates a gummy smile. To correct this, additional orthognathic surgery is indicated after completion of growth. In case of residual OSAS due to an obstruction on level of the hypopharynx, mandibular advancement can be performed to treat both the hypopharyngeal ob-

struction and the sagittal overbite. Future 3D virtual planning of the primary LF III distraction and secondary orthognathic surgical procedures to correct malocclusion might improve final outcome.

COMPLICATIONS

In chapters six and seven, the complications encountered in SCS patients were evaluated. Recommendations regarding prevention of these complications were formulated. It may seem worthwhile to evaluate these suggestions in a retrospective article constituting a greater patient cohort by setting up multi-centre studies. A prospective study will be initiated to observe the incidence of treatment-related complications after implementation of the recommendations described in chapters six and seven. Chapter six focused on the problems that were encountered during the postoperative phase, while chapter seven discusses the importance of the preoperative work-up. Both studies advocate a preoperative CT-scan; more specifically a CTA is advised to detect vascular anomalies. By identifying calvarial bone defects on the CT-scan, the (im-)possibility of the placement of a halo-plate can be pre-operatively evaluated. In addition, future research will evaluate the use of a perioperative magnetic resonance image to observe the presence of Arnold-Chiari malformations and its relation with MB/LF III distraction.

Summary

In this thesis, fundamental and clinical studies are described with respect to the effects of LF III advancement. The aim was to gain more insight in the anatomical orbital changes after LF III advancement and to assess whether LF III advancement can overcome OSAS and can be looked upon as a definite treatment. We share our experience regarding additional orthognathic surgery and complications associated with LF III external halo-distraction and LF III surgery. To address these aspects, this thesis is divided into four parts containing one or more original publications.

Part I is the general introduction.

In chapter one a review of the literature is presented. Since its introduction in about 1950, the LF III procedure has become a widely accepted treatment for correction of midface hypoplasia and related functional and aesthetic problems. As the surgical experience grew, improvements were made in technique, equipment and perioperative care, leading to an increase of the number of LF III procedures performed worldwide. A number of fundamental questions concerning the technique remain unclear, and large, conclusive studies are lacking owing to the rarity of the malformation. The literature review aims to address problems, such as the indication field, timing of surgery, relapse rate and the use of distraction osteogenesis. An overview of the history, the surgical technique and distraction of the LF III osteotomy is provided, together with a comprehensive review of the available clinical data. In conclusion, there are still indications for a conventional LF III osteotomy despite the DO technique. No consensus exists on the post-surgical growth of the midface and fundamental studies are lacking concerning absolute indications to perform LF III advancement, such as OSAS and exorbitism. Since 2006 several studies have been conducted in order to elucidate these deficits.

Part II contains two fundamental studies that were carried out to quantify the anatomical changes due to LF III advancement: we studied the orbital changes and upper airway volume changes respectively.

In chapter two, the influence of LF III advancement on orbital volume, position of the infra-orbital rim and globe were evaluated. In pre- and postoperative CT-scans of eighteen SCS patients, segmentation of the left and right orbit was performed and the infra-orbital rim and globe were marked. By superimposing the pre- and postoperative scan and by creating a reference coordinate system, movements of the infra-orbital rim and globe were evaluated. Postoperatively, the

orbital volume increased significantly with 27.2% for the left and 28.4% for the right orbit. Significant anterior movement of the left infra-orbital rim of 12.0 mm and right infra-orbital rim of 12.8 mm was found. Small significant medial movements of 1.7 mm of the left globe and 1.5 mm of the right globe were found, whereas no significant anterior movement was found. There was a significant correlation between anterior infra-orbital rim movement and orbital volume gain. In conclusion, we demonstrated a significant orbital volume gain and a significant anterior movement of the infra-orbital rim following LF III advancement. The position of the globe remained relatively unaffected.

In chapter three, the pre- and postoperative CT scans of nineteen patients with SCS who underwent LF III advancement were analysed retrospectively. The airway was segmented using a semi-automatic region growing method with a fixed Hounsfield threshold value. Airway-volumes of hypo- and oropharynx (compartment A) and nasopharynx and nasal cavity (compartment B) were analyzed separately, as well as the total airway volume. Advancement of the midface was recorded using lateral skull radiographs. Data was analyzed for all patients together and for patients with Apert and Crouzon/Pfeiffer syndromes separately. Airway volume increased significantly in compartment A, B and in the total airway volume in the total study group. No significant differences in volume changes were found comparing Apert with Crouzon/Pfeiffer patients. No distinct relation could be found between the degree of advancement of the midface and volume gain in both the total study group and in Apert and Crouzon/Pfeiffer patient groups separately. In conclusion, a significant improvement of the upper airway after LF III advancement in SCS patients is demonstrated. No distinct relation could be observed between the amount of advancement and airway volume changes. Based on the evident airway volume gains found in this study, it was decided to perform clinical studies in SCS patients with OSAS (chapters 4a and 4b).

Part III focuses on the clinical consequences of LF III advancement. In four clinical studies the long-term outcome of OSAS and the correlation between volume gain of the upper airway and the outcome of OSAS measurements, the long-term outcome regarding the need for additional orthognathic surgery and complications using external DO, are evaluated respectively.

In chapter 4a, the volume changes of the upper airway and the outcomes of PSG measurements following midface or MB advancement in SCS patients were

evaluated and correlated. Pre- and postoperative CT scans of ten SCS patients with OSAS who underwent LF I (one patient), III (five patients) or MB advancement (four patients), between 2003 and 2009, were analyzed. The airway was segmented using a semi-automatic region growing method with a fixed Hounsfield threshold value. Pre- and postoperative PSG data were correlated to the volume measurements. In eight patients (six LF patients and two MB patients) the outcome of upper airway volume measurements correlated well to the PSG measurements. In three of these patients (one LF I patient, one LF III patient and one MB) upper airway volume measurements showed only a minimal volume gain or even volume loss, with the PSG measurements revealing no improvement. In one MB patient a discrepancy was observed; evident improvement of the PSG measurements without evident volume gain of the upper airway. The majority of patients with LF III advancement showed an improvement of the PSG measurements that for the greater part correlated to the results of the volume analysis. In MB patients this correlation between the volume measurements and PSG outcomes was less obvious. By interpreting the individual clinical situation, PSG measurements and CT-scans, the findings were explicable for each individual patient. Preoperative endoscopy of the upper airway is advocated to identify the level of obstruction in patients with residual OSAS.

In chapter 4b, the long-term respiratory outcome of midface advancement in syndromic craniosynostosis with OSAS was assessed and factors contributing to its efficacy were determined. A retrospective study was performed on eleven patients with moderate or severe OSAS, requiring oxygen, CPAP, or tracheostomy. Clinical symptoms, results of PSG, endoscopy and digital volume measurement of the upper airways on CT scan before and after midface advancement were reviewed. Midface advancement had a good respiratory outcome in the short term in six patients and was ineffective in five. In all patients without respiratory effect or with relapse, endoscopy showed obstruction of the rhino- or hypopharynx. The volume measurements supported the clinical and endoscopic outcome. Despite midface advancement, long-term dependence on, or indication for, CPAP or tracheostomy was maintained in five of eleven patients. Pharyngeal collapse appeared to play a role in OSAS. Endoscopy before midface advancement is recommended to identify airway obstruction that may interfere with respiratory improvement after midface advancement.

In chapter five, the incidence and surgical indications of secondary orthognathic surgery following LF III/MB advancement were evaluated. LF III and MB advance-

ment aim to correct the skeletal deformities on level of zygoma, orbits, nasal area and forehead. However, Class I occlusion is frequently not achieved. Therefore, additional orthognathic surgery is often indicated in patients undergoing LF III or MB advancement. The total study group consisted of 41 patients: 36 patients with LF III advancement and five patients with MB advancement. Seven patients underwent additional orthognathic surgery. Of the resulting eighteen non-operated patients older than eighteen years of age at the end of follow-up, Class I occlusion was observed in eleven patients. In the remaining seven patients malocclusions were dentally compensated by orthodontic treatment. Endoscopic analysis of the upper airway and the outcomes of sleep studies may reveal obstructions causing residual OSAS. These outcomes may influence the orthognathic treatment plan.

Chapter six presents an overview of the complications in a series of 21 patients with various craniofacial anomalies. All patients were treated using the RED II device after LF I or III osteotomy. Distraction started one week postoperatively and continued until a Class I occlusion was achieved; including a fifteen percent overcorrection. All data was collected and categorized retrospectively from the patients' files. After a mean period of distraction of 34 days, 42 complications were reported in six different categories. Pin loosening (42.9%) and frame migrations (28.6%) were the most common complications. Of the frame migrations, 25% were traumatic. Intracranial penetration of one fixation pin occurred during removal of the RED II device in one patient. From these results it can be deduced that application of the RED II device is associated with a substantial number of complications that mainly concern the pins of the halo-frame. The stability of the device is discussed since the distraction distance achieved was less than expected.

Part IV consists of a sole case report that describes a lethal outcome after LF III osteotomy in a patient with Apert syndrome (chapter seven). A ten-year-old girl with Apert syndrome underwent a LF III osteotomy with positioning of internal and external distraction devices. The operation was straightforward without intraoperative complications. Shortly after the end of surgery an anisocoria was noticed. This was followed by fatal intracranial oedema. Dissection of the right internal carotid artery was diagnosed to be the aetiological factor for the death. The complications of LF osteotomies are discussed regarding patients with complex syndromic craniosynostosis and midface hypoplasia, such as Apert syndrome.

Part V includes the general discussion and conclusions (chapter eight) and the epilogue and future perspectives (chapter nine).

In chapter eight the different topics are discussed by combining the outcomes of the individual studies. Regarding exorbitism, the outcome of our study was clear. Whereas other authors found a significant anterior movement of the globe after MB advancement, no anterior movement of the globe was found after LF III advancement. The globe position remained stable while the infra-orbital rim moved significantly anterior.

With respect to OSAS, the fundamental study showed an evident volume gain of the upper airway after LF III advancement, while clinically not all patients benefited from this upper airway volume gain. It was concluded that besides the midfacial hypoplasia associated with SCS, also dynamic pharyngeal wall collapse and nasal or pharyngeal obstructions seem to attribute to the outcome of OSAS. Therefore upper airway volume measurements can be used to evaluate the effect of the midface advancement. In cases showing an evident volume gain after LF III advancement with mild improvement of the PSG outcomes, endoscopy of the upper airway is indicated to identify the level of obstruction. The treatment plan should be based on these outcomes.

Long-term outcome after LF III advancement shows that LF II advancement effectively corrects the midfacial deformity, but frequently leaves a imbalanced inter-jaw relationship. Although a substantial number of subjects have an indication for additional orthognathic surgery, only a few patients underwent these procedures. Most likely, patient factors are to blame.

With respect to complications, it was concluded that both distraction device-related and osteotomy-related complications occur. By specific measures (use of setscrew during removal of the haloframe; pre-operative (angio-)CT in selected cases), careful consideration of the patient's medical history and evaluating compliance by an psychologist, complications may be reduced and treatment outcomes can be optimized. Finally, in chapter nine, the limitations of the studies that are carried out are discussed and recommendations for future research are formulated. Topics that are discussed are the implementation of 3D cephalometry, defining a more strict protocol for SCS patients based on the outcomes of this thesis, the use of 3D reference frames to analyze segmental movements and long-term (prospective and retrospective) follow-up studies to illustrate the outcome of OSAS and additional orthognathic surgery.

**Dutch summary
(Nederlandse samenvatting)**

In dit proefschrift wordt een aantal fundamentele en klinische studies beschreven die handelen over de gevolgen van het vooruitplaatsen van het middengezicht door middel van een LF III osteotomie. Het doel van deze studies was om meer inzicht te verwerven in de anatomische veranderingen die plaatsvinden na een LF III osteotomie en te bepalen in hoeverre deze ingreep het obstructief slaap apneu syndroom kan verbeteren. Ten slotte werd er gekeken naar de lange-termijn uitkomsten en geassocieerde complicaties. Om al deze aspecten inzichtelijk te kunnen behandelen is gekozen voor een opdeling van de artikelen in een viertal delen, die ieder één of meer artikelen bevatten over één van bovenstaande onderwerpen.

Deel I is de algemene inleiding

In hoofdstuk één wordt een literatuuroverzicht gegeven. Al sinds de jaren 1950 is de LF III osteotomie een algemeen geaccepteerde behandelmodaliteit voor correctie van hypoplasie van het middengezicht en aanverwante esthetische en functionele problemen. Naarmate de ervaring met de LF III osteotomie toeneemt, ontstaan tevens verbeteringen van de chirurgische techniek, apparatuur en de peri-operatieve zorg. Door al deze verbeteringen wordt de LF III osteotomie wereldwijd steeds frequenter routinematig toegepast. Daarentegen zijn er ook een aantal aspecten nog onduidelijk en is er ten gevolge van de relatief zeldzame patiëntenpopulatie een tekort aan grote goed opgezette studies om deze aspecten te bestuderen. In het literatuuroverzicht zullen indicatiestelling, timing, het optreden van recidief en het gebruik van distractie osteogenese bij de LF III osteotomie worden besproken. Verder wordt een overzicht gegeven van de geschiedenis en techniek van de conventionele LF III osteotomie en de LF III distractie osteogenese, tezamen met een literatuuroverzicht van de beschikbare klinische gegevens. Concluderend kan worden gesteld dat er nog steeds een indicatiegebied bestaat voor de conventionele LF III osteotomie ondanks de opmars van de LF III DO. Verder lijkt er in de literatuur geen consensus te bestaan over de postchirurgische groei van het middengezicht en lijken fundamentele studies te ontbreken om uitspraken te kunnen doen over absolute indicaties waarvoor een LF III osteotomie aangewezen is, zoals OSAS en exorbitisme. Sinds 2006 werden dan ook een aantal studies geïnitieerd om deze hiaten te kunnen dichten.

Deel II bevat een tweetal fundamentele studies die verricht werden om de orbitale veranderingen en de volumeveranderingen van de bovenste luchtweg die optreden na een LF III osteotomie te kunnen analyseren.

In hoofdstuk twee werd de invloed van de LF III osteotomie onderzocht op het volume van de orbita en de positieverandering van de infra-orbitale rand en de oogbol. Hiervoor werden de CT-scans geanalyseerd van achttien patiënten met verschillende vormen van syndromale craniosynostose waarbij segmentatie van de linker en rechter orbita werd verricht en de infra-orbitale rand en het midden van de oogbol gemarkeerd werd zowel pre- als postoperatief. Door de pre- en postoperatieve CT-scan zorgvuldig over elkaar heen te leggen en een referentievlak te definiëren, konden de bewegingen van de oogbol en infra-orbitale rand in drie dimensies inzichtelijk worden gemaakt en worden gemeten. Hierbij bleek dat het orbitavolume met 27.2 % toenam aan de linkerkzijde en met 28.4 % aan de rechterzijde. Tevens werd er een significante voorwaartse verplaatsing gemeten van de infra-orbitale rand van twaalf mm links en 12.8 mm rechts. Verder werd er een significante mediale verplaatsing gemeten van de oogbol van 1.7 mm links en 1.5 mm rechts. Er bestond een significante relatie tussen de voorwaartse verplaatsing van de infra-orbitale rand en de toename van het orbita volume. Concluderend kan dan ook worden gesteld dat na LF III osteotomie het orbita volume toeneemt en de infra-orbitale rand naar anterior verplaatst, terwijl de oogbol nauwelijks van positie verandert.

In hoofdstuk drie worden de resultaten beschreven van een studie waarbij aan de hand van CT-scans het volume van de bovenste luchtweg pre- en postoperatief kon worden bepaald bij een groep van negentien patiënten met verschillende vormen van syndromale craniosynostose. Deze volumeveranderingen werden gerelateerd aan de voorwaartse verplaatsing van het middegezicht, hetgeen op RSP's kon worden bepaald. Zowel op niveau van de hypo-, oro- en nasopharynx, evenals op niveau van de neusholte nam het volume van de bovenste luchtweg significant toe. Er konden geen verschillen tussen de verschillende syndromale patiëntengroepen vastgesteld worden; tevens was er geen correlatie tussen de mate van voorwaartse verplaatsing van het middegezicht en de gemeten toename van het bovenste luchtwegvolume. Om de invloed van de postoperatieve volumetoename en OSAS-scores te objectiveren, werd besloten tot een klinische studie (hoofdstuk zes).

In deel III wordt een viertal klinische studies beschreven.

In hoofdstuk 4a worden de volumeveranderingen van de bovenste luchtweg en PSG metingen voor en na LF III en MB osteotomie vergeleken en gecorreleerd bij patiënten met syndromale craniosynostose. Hiertoe werden de pre- en postoperatieve CT-scans van tien patiënten met syndromale craniosynostose gesegmenteerd volgens een semi-automatische methode waarbij een vaste Hounsfield drempelwaarde werd gehanteerd. De pre- en postoperatieve PSG data werden aan de uitkomsten van de volumemetingen gecorreleerd. Bij acht patiënten werd een goede correlatie gezien tussen de volumemetingen en de PSG's. Van deze acht patiënten hadden drie patiënten slechts een minimale volumeverandering van de bovenste luchtweg in combinatie met een nagenoeg onveranderde PSG. Bij één patiënt die een MB osteotomie had ondergaan, werd een discrepantie gevonden tussen de uitkomsten van de PSG en de volumemetingen; er werd een forse verbetering van de PSG vastgesteld, terwijl er geen evidente postoperatieve volumeverandering van de bovenste luchtweg werd gemeten. Echter, de meerderheid van de patiënten met een LF III osteotomie vertoonde een verbetering van de postoperatieve PSG de welke voor de meeste patiënten goed correleerde met de postoperatieve volumeveranderingen van de bovenste luchtweg. Voor de MB patiënten was deze correlatie minder duidelijk. Door van alle patiënten de individuele klinische situatie, PSG data en volumemetingen te combineren, konden voor iedere individuele patiënt de resultaten verklaard worden. Preoperatieve endoscopie van de bovenste luchtweg wordt geadviseerd om het niveau van de obstructie vast te stellen bij patiënten met rest-OSAS.

Hoofdstuk 4b belicht de uitkomsten van een retrospectieve studie gericht op de lange termijn uitkomsten van OSAS metingen na het naar voren verplaatsen van het middegezicht in 11 patiënten met syndromale craniosynostose. Deze patiënten hadden allen matige tot ernstige vormen van OSAS waarvoor zuurstof, danwel CPAP of tracheotomie nodig was. Van deze patiënten werden de klinische symptomen, de resultaten van polysomnografie, endoscopie en digitale volume metingen van de bovenste luchtweg geanalyseerd voor en na LF III osteotomie. Hieruit bleek dat zes patiënten een goede OSAS-score hadden kort na de operatie en vijf patiënten weinig tot geen verbetering lieten zien. In deze patiënten zonder verbetering liet endoscopie een obstructie zien van de bovenste luchtweg op niveau van de rhino- of hypopharynx. De volumemetingen correleerden hierbij met de klinische bevindingen. Ondanks het voorwaarts verplaatsen van het middegezicht, waren

vijf patiënten postoperatief nog afhankelijk van CPAP danwel een tracheotomie. Concluderend kan dan ook gesteld worden dat collaps van de pharynx een rol kan spelen bij de aetiologie van OSAS. Endoscopie van de bovenste luchtweg wordt geadviseerd voor LF III osteotomie om eventuele luchtweg obstructies te identificeren.

In hoofdstuk vijf worden de incidentie en chirurgische indicaties voor secundaire orthognathische chirurgie na LF III of MB osteotomie geëvalueerd. De totale studiegroep bestond hierbij uit 41 patiënten, waarvan 36 patiënten een LF III osteotomie en vijf patiënten een MB osteotomie hadden ondergaan. Zeven patiënten uit de studiegroep ondergingen secundaire orthognathische chirurgie. Van achttien patiënten die aan het einde van de studieperiode ouder waren dan achttien jaar en geen secundaire orthognathische chirurgie hadden ondergaan, hadden elf patiënten een klasse I occlusie. In de meerderheid van de patiënten kon de aanwezige malocclusie orthodontisch gecompenseerd worden. Secundaire orthognathische chirurgie vond niet plaats vanwege het afwezig zijn van functionele klachten, danwel omdat de patiënt geen additionele chirurgie meer wilde. Concluderend kan dan ook gesteld worden dat LF III en MB osteotomieën erop gericht zijn de problemen op niveau van het bovenste deel van het aangezicht of middengezicht te corrigeren en dat Klasse I occlusie hierbij vaak niet bereikt wordt. Hoewel additionele orthognathische chirurgie dus frequent aangewezen is, vindt het vaak niet plaats. Endoscopie van de bovenste luchtweg en analyse van de uitkomsten van slaapstudies worden geadviseerd.

In hoofdstuk zes wordt een klinische studie beschreven die de complicaties gerelateerd aan het gebruik van een haloframe analyseert bij 21 patiënten met syndromale craniosynostose bij het gebruik van een haloframe. Alle patiënten werden behandeld met een RED na een LF I of LF III osteotomie. Distractie werd één week postoperatief gestart en gecontinueerd totdat Klasse I occlusie was bereikt; hierna werd nog zo'n vijftien procent overgecorrigeerd. Na een gemiddelde distractieperiode van 34 dagen werden 42 complicaties gevonden die in zes categorieën konden worden verdeeld. De meest voorkomende complicaties hierbij waren het losgaan van de pinnen van het distractiesysteem (42.9 %) en migraties van het haloframe (28.6 %). Van alle frame-migraties was ongeveer 25 % ten gevolge van een trauma. Bij één patiënt trad een intracranieële penetratie van een pin van het distractiesysteem op tijdens het verwijderen van de distractor. Concluderend kan dan ook worden gesteld dat het gebruik van een haloframe niet zonder risico's is

en dat de meeste complicaties gerelateerd zijn aan de schroeven van het haloframe. Aangezien de distractieafstand minder was dan verwacht op basis van de afstand waarover de schroeven werden uitgedraaid, wordt in dit hoofdstuk tevens de rigiditeit van het RED-systeem bediscussieerd.

Deel IV bestaat uit een casus beschrijving van een patiënt met het syndroom van Apert die na een LF III osteotomie is overleden (hoofdstuk zeven). Een tien jaar oud meisje met het syndroom van Apert onderging een LF III osteotomie, waarbij interne en externe distractoren werden aangebracht ten behoeve van distractie osteogenese. Het verloop van de ingreep was zonder complicaties, totdat na afloop van de ingreep een anisocorie werd opgemerkt. Hierna trad er een fataal intracranieel oedeem op. Als oorzaak werd retrospectief dissectie van de arteria carotis interna vastgesteld. De complicaties van LF osteotomieën bij patiënten met syndromale craniosynostose worden bediscussieerd.

Deel V bevat de algemene discussie en conclusies (hoofdstuk acht) en de epiloog en aanbevelingen voor toekomstig onderzoek (hoofdstuk negen).

In hoofdstuk acht worden de verschillende hoofdonderwerpen bediscussieerd door de resultaten van de diverse studies te combineren. Met betrekking tot exorbitisme kan gesteld worden dat na een LF III osteotomie een duidelijke voorwaartse verplaatsing van de infra-orbitale rand plaatsvindt tezamen met een significante volume toename van de orbita. De oogbol blijft nagenoeg in dezelfde positie staan. Met betrekking tot OSAS kan gesteld worden dat er na LF III osteotomie bij het merendeel van de patiënten een toename van het volume van de bovenste luchtweg optreedt. Echter, niet alle patiënten lijken hier voordeel van te ondervinden. Er werd dan ook geconcludeerd dat behalve de hypoplasie van het middegezicht, ook het collaberen van de pharyngeale wand en nasale of pharyngeale obstructies een rol spelen bij het tot stand komen van OSAS. Volumemetingen van de bovenste luchtweg lijken gebruikt te kunnen worden om het effect van LF III osteotomie in te schatten. In die gevallen waarin er sprake is van een duidelijke volumetoename van de bovenste luchtweg na LF III osteotomie terwijl de PSG weinig winst laat zien, zijn naso-endoscopie en hypopharyngoscopie geïndiceerd om het niveau van de obstructie vast te stellen. Het behandelplan kan hierop dan worden gebaseerd.

Met betrekking tot de lange termijn resultaten van de LF III osteotomie, kan gesteld worden dat het erop lijkt dat de LF III osteotomie een adequate behandeling is voor de hypoplasie van het middegezicht. Echter, een malocclusie lijkt postoperatief frequent aanwezig te zijn. Hoewel een flink aantal patiënten wel een indicatie heeft om deze malocclusie te corrigeren door middel van additionele orthognathische chirurgie, komt de overgrote meerderheid hier niet meer aan toe. Hoogstwaarschijnlijk zijn patiëntfactoren hier debet aan.

Ten aanzien van de complicaties kan de conclusie worden getrokken dat zowel complicaties optreden die verband houden met de ingreep zelf als met de externe distractor. Door specifieke maatregelen/voorzorgen te nemen, het nauwkeurig bestuderen van de voorgeschiedenis en de medewerking van de patiënt vooraf door een psycholoog te laten nagaan, is er een reële kans op vermindering van het aantal complicaties en optimalisatie van het behandelresultaat.

Tenslotte worden in hoofdstuk negen de tekortkomingen van de verschillende studies besproken en worden aanbevelingen gedaan voor toekomstig onderzoek. Onderwerpen hierbij zijn: de implementatie van 3D cephalometrie, het definiëren van een strikter protocol voor de behandeling van SCS patiënten, het gebruik van een 3D referentie frame om segmentale bewegingen te kunnen onderzoeken en lange termijn studies om het verloop van OSAS inzichtelijk te maken en een betere inschatting van de incidentie van additionele orthognathische chirurgie te kunnen maken.

PhD portfolio

COURSES

- 2008 Hoofd-hals anatomie, Erasmus Universiteit Rotterdam
- 2008 Basiscursus Heelkunde Specialismen, Nederlandse Vereniging voor Heelkunde
- 2009 Traumatologie van het aangezicht, Universitair Medisch Centrum Groningen
- 2009 Training course: Basic Life Support en Automatische Externe Defibrillator, Erasmus Medisch Centrum Rotterdam
- 2009 Module Gezondheidsrecht, Desiderius School, Erasmus Universiteit Rotterdam
- 2009 AO-principles course: craniomaxillofacial, Oisterwijk
- 2009 KIO Speciële Oncologie, Universitair Medisch Centrum Utrecht
- 2009 KIO Orofaciale pijn en Mandibulaire Bewegingsstoornissen, Universitair Medisch Centrum Groningen
- 2010 KIO Pre-prothetische en pre-implantologische chirurgie, Universitair Medisch Centrum Leiden
- 2010 Cursus Hoofdzaken, NVMKA, Ermelo

CONFERENCES

Oral presentations

- 2006 Complications in maxillary distraction using the RED II device: a retrospective analysis of 21 patients. Voorjaarsvergadering NVMKA, Zeist
- 2008 Aangezichtsspleten: een beschrijving van twee zeldzame casus. Najaarsvergadering NVMKA, Eindhoven
- 2009 Volumeveranderingen van de bovenste luchtweg na Le Fort III advancement bij patiënten met syndromale craniosynostose. Najaarsvergadering NVMKA, Groenekan
- 2010 On the Le Fort III Osteotomy: influence on upper airway volume, orbital volume and position of globe and infra-orbital rim. Refereeravond afdeling Plastische en reconstructieve chirurgie, ErasmusMC
- 2010 Orbital change following Le Fort III advancement in syndromic craniosynostosis: quantitative evaluation of orbital volume, infra-orbital rim and globe

position. 20th Congress of the European Association for Cranio-maxillo-facial surgery, Brugge, Belgium

TEACHING ACTIVITIES

- 2003 Training medical students, anatomy abdomen
 2009 Supervising Master's theses Frederik Bouw
 2010 Supervising Master's theses Sun-Jine van Bezooijen

LIST OF PUBLICATIONS

Nout E, Bouw FP, Veenland JF, Hop WC, van der Wal KG, Mathijssen IM, Wolvius EB. Three-Dimensional Airway Changes after Le Fort III Advancement in Syndromic Craniosynostosis Patients. *Plast Reconstr Surg.* 2010 Aug;126(2):564-71.
 PMID: 20679838

Nout E, Mathijssen IM, van der Meulen JJ, van Veelen ML, Koning AH, Lequin MH, Wolvius EB. Internal carotid dissection after Le Fort III distraction in Apert syndrome: A case report. *J Craniomaxillofac Surg.* 2010 Mar 18. [Epub ahead of print]
 PMID: 20303281

Bannink N, **Nout E**, Wolvius EB, Hoeve HL, Joosten KF, Mathijssen IM. Obstructive sleep apnea in children with syndromic craniosynostosis: long-term respiratory outcome of midface advancement. *Int J Oral Maxillofac Surg.* 2010 Feb;39(2):115-21. Epub 2010 Jan 6.
 PMID: 20056390

Bouw FP, **Nout E**. A baby with a white lesion in the upper jaw. *Ned Tijdschr Geneeskd.* 2009;153:A231.
 PMID: 19930732

Nout E, Cesteley LL, van der Wal KG, van Adrichem LN, Mathijssen IM, Wolvius EB. Advancement of the midface, from conventional Le Fort III osteotomy to Le Fort III

distraction: review of the literature. *Int J Oral Maxillofac Surg*. 2008 Sep;37(9):781-9. Epub 2008 May 19. Review.

PMID: 18486452

Van Winterswijk PJ, **Nout E**. Tissue Engineering and Wound Healing: An Overview of the Past, Present and Future. *Wounds*. 2007 Oct;issue 10. Review.

Lange JF, Komen N, Akkerman G, **Nout E**, Horstmanshoff H, Schlesinger F, Bonjer J, Kleinrensink GJ. Riolan's arch: confusing, misnomer, and obsolete. A literature survey of the connection(s) between the superior and inferior mesenteric arteries. *Am J Surg*. 2007 Jun;193(6):742-8. Review.

PMID: 17512289

Nout E, Lange JF, Salu NE, Wijsmuller AR, Hop WC, Goossens RH, Sniijders CJ, Jeekel J, Kleinrensink GJ. Creep behavior of commonly used suture materials in abdominal wall surgery. *J Surg Res*. 2007 Mar;138(1):51-5. Epub 2006 Nov 29.

PMID: 17137599

Nout E, Wolvius EB, van Adrichem LN, Ongkosuwito EM, van der Wal KG. Complications in maxillary distraction using the RED II device: a retrospective analysis of 21 patients. *Int J Oral Maxillofac Surg*. 2006 Oct;35(10):897-902. Epub 2006 Sep 27.

PMID: 17008053

Nout E, Lincke CR. Diagnosis image (262). A newborn baby with unilateral ptosis. *Ned Tijdschr Geneeskd*. 2006 Feb 18;150(7):373.

PMID: 16523800

Derom A, **Nout E**. Treatment of femoral pseudoaneurysms with endograft in high-risk patients. *Eur J Vasc Endovasc Surg*. 2005 Dec;30(6):644-7. Epub 2005 Jul 14.

PMID: 16023388

Acknowledgement (Dankwoord)

I can no other answer make, but, thanks, and thanks.

~William Shakespeare

Ondanks dat op de voorzijde van dit proefschrift slechts één naam staat, wil ik benadrukken dat velen aan de tot standkoming van dit werk hebben bijgedragen. Op deze plaats wil ik iedereen die, op welke manier dan ook, betrokken is geweest, hartelijk danken!

Erik .

