

**SOMATOSTATIN RECEPTOR SCINTIGRAPHY
IN MALIGNANT LYMPHOMA**

The support of this thesis by Mallinckrodt Medical BV, Roche, Janssen-Cilag, Amgen, Wyeth and Pfizer is gratefully acknowledged.

© P.J. Lugtenburg, Rotterdam, the Netherlands, 2001

ISBN 90-7701720-8

Printed by Optima Grafische Communicatie, Rotterdam

Somatostatin Receptor Scintigraphy
in Malignant Lymphoma

Somatostatine receptor scintigrafie
in maligne lymfomen

Proefschrift

ter verkrijging van de graad van doctor aan de Erasmus Universiteit Rotterdam
op gezag van de Rector Magnificus Prof.dr.ir. J.H. van Bommel
en volgens besluit van het College voor Promoties

De openbare verdediging zal plaatsvinden op
woensdag 28 november 2001 om 13.45 uur

door

Pieterrella Johanna Lugtenburg

geboren te Rotterdam

Promotiecommissie

Promotoren: Prof.dr. B. Löwenberg
Prof.dr. E.P. Krenning

Overige leden: Prof.dr. A. Hagenbeek
Prof.dr. P.C. Huijgens
Prof.dr. S.W.J. Lamberts

'We don't see things as they are, we see them as we are'.

(Anaïs Nin)

Voor Ineke en Deborah

CONTENTS

Abbreviations		9
Chapter 1	Introduction	
1.1	Malignant lymphomas	13
1.2	Staging of Hodgkin's disease and non-Hodgkin's lymphoma	17
1.3	Conventional imaging techniques	19
1.4	Gallium scintigraphy	20
1.5	FDG-PET scintigraphy	22
1.6	Somatostatin and somatostatin receptor scintigraphy	23
1.7	Aim of the study	27
1.8	References	28
Chapter 2	Somatostatin receptor scintigraphy in the initial staging of Hodgkin's disease <i>Br J Haematol 93: 96-103, 1996</i>	39
Chapter 3	Somatostatin receptor scintigraphy in cutaneous malignant lymphomas <i>J Am Acad Dermatol 34: 985-993, 1996</i>	57
Chapter 4	Somatostatin receptor scintigraphy useful in stage I-II Hodgkin's disease: more extended disease identified <i>Br J Haematol 112: 936-944, 2001</i>	73
Chapter 5	Somatostatin receptor scintigraphy in the initial staging of low-grade non-Hodgkin's lymphomas <i>J Nucl Med 42: 222-229, 2001</i>	93

Chapter 6	Somatostatin receptor scintigraphy in the initial staging of intermediate- and high-grade non-Hodgkin's lymphomas <i>Haematol J in press</i>	113
Chapter 7	Summary and general discussion	
7.1	Place of SS-R scintigraphy in the staging of Hodgkin's disease	137
7.2	Place of SS-R scintigraphy in the staging of non-Hodgkin's lymphoma	138
7.3	Future issues in imaging Hodgkin's disease and non-Hodgkin's lymphoma	139
7.4	New developments in SS-R imaging	141
7.5	SS-R imaging as a guide in targeted treatment	143
7.6	References	144
	Samenvatting	149
	List of publications	152
	Dankwoord	154
	Curriculum Vitae	156

Abbreviations

Bq	Becquerel
CBCL	Cutaneous B-cell lymphoma
CT	Computed tomography
CTCL	Cutaneous T-cell lymphoma
DTPA	Diethylenetriaminopentaacetic acid
FDG	2-[¹⁸ F]-fluoro-2-deoxy-D-glucose
Ga	Gallium
GH	Growth hormone
HD	Hodgkin's disease
hSSTR	Human somatostatin receptor
mCi	Millicuries
MRI	Magnetic resonance imaging
NHL	Non-Hodgkin's lymphoma
PET	Positron emission tomography
SPECT	Single photon emission computed tomography
SS	Somatostatin
SS-R	Somatostatin receptor
TSH	Thyroid stimulating hormone

CHAPTER 1

Introduction

The prognosis of patients with malignant lymphomas has improved over the last 30 years. Besides from improvements in therapy the better outcome of these patients has resulted also from the introduction of better diagnostic techniques detecting involved sites. Diagnostic radiology plays an essential role in assessing the extent of disease. Imaging studies are also important in assessing the response to treatment, evaluating complications of treatment and demonstrating relapse of disease. Imaging techniques that are frequently used include: conventional frontal and lateral chest radiographs, computed tomography (CT) scanning, ultrasound and magnetic resonance imaging (MRI). The choice of the techniques preferably used is based on patterns of dissemination of the disease and the diagnostic accuracy of the test in terms of sensitivity and specificity. However, factors such as patient acceptance, availability of expertise and equipment and cost may also play a role. Accurate staging and re-staging is critical to the selection of treatment in the interest of improved outcomes.

1.1 Malignant lymphomas

Currently, about 2500 new cases of malignant lymphomas per annum occur in the Netherlands. Approximately 80% of cases are non-Hodgkin's lymphomas (NHL) and the other cases are Hodgkin's disease (HD) (1). There are considerable differences between HD and NHL as regards pathogenesis, pathobiology, clinical presentation, response to therapy and prognosis.

In economically advantaged populations the incidence of HD peaks in the third decade of life and at 65-75 years. The diagnosis is usually made following the pathological examination of an excised lymph node. The diagnosis of classical HD is established through the identification of Hodgkin's cells, either by histopathology or histopathology combined with immunohistochemical studies, in the appropriate cellular milieu. According to the World Health Organization classification classical HD can be subdivided in four histologic subtypes (2) (Table 1).

Table 1. WHO classification of Hodgkin's lymphoma (Hodgkin's disease)

Nodular lymphocyte-predominant Hodgkin's lymphoma
Classical Hodgkin's lymphoma
Nodular sclerosis Hodgkin's lymphoma
Lymphocyte-rich classical Hodgkin's lymphoma
Mixed cellularity Hodgkin's lymphoma
Lymphocyte depletion Hodgkin's lymphoma

The nodular sclerosis subtype is most common, accounting for more than two-thirds of all cases in Western populations. The mixed cellularity subtype comprises approximately 30% of cases. The lymphocyte-rich and lymphocyte depletion subtypes are seen relatively infrequently. In addition, nodular lymphocyte-predominant HD has distinct biologic, histologic and clinical features. Most patients present with localized peripheral disease often in the neck (3). The majority of patients with the nodular sclerosis subtype of HD present with disease above the diaphragm and mediastinal involvement (3). HD appears to begin at a certain localized lymphoid site and clinically progresses to involve adjacent lymphoid tissues before disseminating to distant nonadjacent sites and organs. Noncontiguous spread and hematologic distribution are more common with recurrent disease (4). As the prognosis of HD gets worse at more progressive stages of the disease, treatment of HD is largely determined by disease extent. Patients with limited disease (stages I and II) may be effectively treated with regional radiotherapy alone. However, in 30% of cases the disease may recur (5). These patients usually relapse in previously unirradiated sites (6,7). Therefore, nowadays in patients with limited disease prognostic factors are used to identify patients at higher risk for relapse and these are no longer treated with local (radio)therapy alone (6,8). Patients with advanced disease (stages III and IV) are treated with systemic chemotherapy (9). The majority (50-90%) of patients with HD become long term disease free survivors (9,10).

The incidence of NHL increases from the fifth decade of age onwards. The diagnosis is made following the histopathologic, immunologic and sometimes molecular examination of a tissue biopsy. Several pathological classification systems have been proposed for the classification of NHL. In Europe during the last decennium the "Kiel-classification" has been used by most pathologists and in the USA the "Working Formulation" (11,12). The Working Formulation defines three prognostic groups that are designated as: low-grade, intermediate-grade and high-grade histologies (Table 2). In 1994 the "Revised European-American Lymphoma (REAL) classification for lymphoid neoplasms has been proposed (13). In the REAL classification molecular and cytogenetic features are taken into account in addition to histopathologic and immunohistochemic information. The REAL classification makes a clear distinction between histological or cytological grade and clinical aggressiveness. Histological grade is based on cell and nuclear size, density of nuclear chromatin and the proliferation fraction as assessed by the number of mitotic figures or the proliferation fraction determined by Ki-67 staining. By and large, histological grade correlates with clinical aggressiveness but this is not always the case. Mantle cell lymphoma is histologically low grade but clinically aggressive, as are some T-cell lymphomas as angioimmunoblastic T-cell lymphoma.

Table 2. The National Cancer Institute Working Formulation**Low grade**

- A Malignant lymphoma, small lymphocytic
consistent with CLL
plasmacytoid
- B Malignant lymphoma, follicular. Predominantly small cleaved cell
diffuse areas
sclerosis
- C Malignant lymphoma, follicular. Mixed, small cleaved and large cell
diffuse areas
sclerosis

Intermediate grade

- D Malignant lymphoma, follicular. Predominantly large cell
diffuse areas
sclerosis
- E Malignant lymphoma, diffuse. Small cleaved cell
sclerosis
- F Malignant lymphoma, diffuse. Mixed small and large cell
epithelioid cell component
sclerosis
- G Malignant lymphoma, diffuse. Large cell
cleaved cell
non-cleaved cell
sclerosis

High grade

- H Malignant lymphoma. Large cell immunoblastic
plasmacytoid
clear cell
polymorphous
epithelioid cell component
- I Malignant lymphoma. Lymphoblastic
convoluted cell
non-convoluted cell
- J Malignant lymphoma. Small non-cleaved cell
Burkitt's
follicular areas

Miscellaneous

- Composite
Mycosis fungoides
Histiocytic
Extramedullary plasmacytoma
Unclassifiable
Other

Both the Working Formulation and Kiel-classification stressed the fundamental importance of 'grade', although using the term in a different sense, in determining treatment. The REAL classification instead lays stress on the disease entity (13,14). In Table 3 distinct lymphoma entities are listed according to their clinical aggressiveness.

Table 3. Lymphoma entities according to the REAL classification categorized according to clinical behavior

Highly aggressive
Lymphoblastic lymphoma
Burkitt's lymphoma
Aggressive
Diffuse large B-cell lymphoma
Angioimmunoblastic T-cell lymphoma
Anaplastic large cell (CD 30+) lymphoma (Mantle cell lymphoma)
Indolent
Small lymphocytic lymphoma
Lymphoplasmacytoid lymphoma/immunocytoma
Follicle center lymphoma, follicular
Marginal zone B-cell lymphoma, incl. MALT lymphoma
Mycosis fungoides

However, it is important to realize that many of these lymphoma entities have a range of morphologic grade and clinical aggressiveness. Examples are the follicle center lymphomas, but also the mucosa-associated lymphoid tissue (MALT)-type lymphomas, angiocentric lymphomas and even mantle cell lymphomas can apparently have relatively lower and higher grade types (13). The course of NHL is less dependent on disease extent, but more on the histological subtype and grade of malignancy. The large majority of patients with indolent or low-grade NHL have disseminated disease at diagnosis. Bone marrow involvement is characteristic. In general the disease presents as a slowly progressive disorder. The median survival has been estimated at about 8 years (15). When determining a therapeutic plan, it is first important to identify those patients with localized disease (stages I and II) potentially eligible for regional irradiation. Long-term disease-free survival may be achieved in approximately half of such patients following radiotherapy (16,17). Therefore, in case of staging patients with indolent NHL it is important to identify the small proportion of patients with truly localized disease. The aggressive NHL respond well to chemotherapy, however the more advanced stages have a high tendency for recurrence. In patients with aggressive NHL it appears useful to distinguish between stages I and stages II-IV disease. The majority of patients (80-90%)

with clinical stage I disease can be treated effectively with short-course combination chemotherapy with or without radiotherapy (18-20). The treatment of choice for patients with more advanced disease is combination chemotherapy and overall approximately 30% of adults up to the age of 60 years will survive free of disease at the long term (21,22).

1.2 Staging of Hodgkin's disease and non-Hodgkin's lymphoma

Once the diagnosis of malignant lymphoma has been established the extent of the disease has to be determined and clinical staging is undertaken. Since 1971 the Ann Arbor staging classification has been applied (23). It was formulated to provide a system, which would allow for decisions on treatment choice in patients at initial presentation. The specifications of the Ann Arbor classification are given in Table 4.

Table 4. The Ann Arbor staging classification

Stage I	Involvement of a single lymph node region (I) or single extralymphatic organ or site (I _E)	
Stage II	Involvement of 2 or more lymph node regions on the same side of the diaphragm (II) or localized involvement of extralymphatic organ or site and of 1 or more lymph node regions on the same side of the diaphragm (II _E)	
Stage III	Involvement of lymph node regions on both sides of the diaphragm (III), which may also be accompanied by localized involvement of extralymphatic organ or site (III _E) or by involvement of the spleen (III _S), or both (III _{SE})	
Stage IV	Diffuse or disseminated involvement of 1 or more extralymphatic organs or tissues with or without associated lymph node involvement	
Symptoms	A	Asymptomatic
	B	Unexplained fever with temperatures above 38°C Night sweats Unexplained weight loss of more than 10% of body weight in the previous 6 months

The classification was originally introduced for the staging of HD and was based on the concept that HD initially spreads in a predictable fashion towards contiguous lymph node chains. In the following twenty years new features of prognostic importance have been recognized, e.g. "bulk" of mediastinal involvement, number of nodal areas involved and other clinical features, i.e. age, sex, B-symptoms and erythrocyte sedimentation rate (6,24-27). Subsequently, new imaging techniques like CT scanning and MRI became

available and were introduced into routine staging. In 1988 a meeting was organized in the Cotswolds, England, to update the Ann Arbor classification and account for the use of imaging techniques such as CT scanning (28). Details of the Cotswold meeting recommendations for clinical imaging criteria are given in Table 5.

Table 5. The Cotswold meeting recommendations for clinical imaging criteria

CT scan	Lymph nodes of more than 1.5 cm cross-sectional diameter are unequivocally abnormal on CT scanning
Spleen	Involvement requires unequivocal palpable splenomegaly alone, or equivocal palpable splenomegaly with radiological confirmation of either enlargement or multiple focal defects which are neither cystic nor vascular
Liver	Multiple focal defects which are neither cystic nor vascular noted with at least two imaging techniques
Lung	Radiological evidence of parenchymal involvement in the absence of other likely causes especially infection
Bulk	A node or nodal mass must be 10 cm or greater to be recorded as 'bulky'

Whereas in HD the prognosis is distinctly worse with each progressive stage of disease, and treatment approach depends on disease extent, this is not as clearly true in NHL. Prognosis of NHL depends on the histopathologic subtype and certain clinical parameters, rather than stage of dissemination. Thus, the Ann Arbor classification is clinically less useful in patients with NHL. In NHL various prognostic factors have been applied. The International Non-Hodgkin's Lymphomas Prognostic Factors Project (1993) reported a predictive model for aggressive NHL (29). On the basis of age, stage, serum lactate dehydrogenase (LDH) levels, performance status and number of extranodal disease sites, four distinct risk groups have been identified with variable predicted five-year survival rates. The international prognostic index and age-adjusted international prognostic index are significantly more accurate in predicting long-term survival than the Ann Arbor classification (29). In low-grade lymphomas the international prognostic index also expresses prognostic value (30,31). Despite the shortcomings of the Ann Arbor classification, it is a convenient method for defining and reporting the disease extent and thus the Ann Arbor classification remains the most commonly used staging system for both HD and NHL.

1.3 Conventional imaging techniques

For the initial clinical staging of malignant lymphomas a detailed history, complete physical examination, bone marrow aspiration and/or biopsy and several imaging studies are generally recommended (28,32). Nowadays, most centers perform chest radiographs and CT scans of the thorax, abdomen and pelvis, using intravenous contrast whenever necessary and with images at 1.0 cm intervals. Sometimes additional imaging techniques are applied as well. These may include ultrasound scanning of the neck and/or abdomen and MRI. In case of specific symptoms or physical signs special investigations and imaging studies may be performed to confirm clinical involvement at a given site e.g., radionuclide bone scanning, barium studies and endoscopies.

The most common clinical presentation of malignant lymphomas is an asymptomatic enlarged lymph node, often located in the neck. Studies reporting on diagnosis of peripheral lymphadenopathy in patients with malignant lymphoma have been scarce. Two studies showed that in 10-18% of lymphoma cases more pathologic lymph nodes were detected with ultrasound scanning, following physical examination (33,34). Imaging of the neck with ultrasound or CT scanning is increasingly being employed.

Intrathoracic disease at presentation is more often seen in patients with HD than in NHL. Frontal posteroanterior and lateral chest radiographs are generally done in patients with newly diagnosed malignant lymphoma. Various studies have shown that CT scans of the thorax clearly reveals disease at sites that, even in retrospect, are not revealed on conventional chest radiographs (35-37). Importantly, based on the added information provided by the CT scans treatment choice was modified in up to 60% of patients (36,37). Lymph node sites that are readily demonstrated on CT scans and difficult to evaluate on chest radiography, include the subcarinal, cardiophrenic angle and internal mammary lymph node groups. In addition, CT scans have a greater accuracy in detecting lung parenchymal abnormalities, pericardial involvement and chest wall involvement. CT scanning currently represents the standard for chest imaging in patients with malignant lymphoma. MRI may be useful in specific situations, such as assessment of chest wall invasion (38).

Based on laparotomy evaluations, approximately 35% of patients with HD have subdiaphragmatic involvement (39). Abdominal disease is more frequent in NHL. Prior to the introduction of CT scanning, lymphangiography has been the method of choice to determine the presence of subdiaphragmatic disease. Abnormal distortion of the lymph node architecture due to replacement provides a positive sign of tumor involvement and this feature is an advantage of lymphangiography. Based on direct comparisons with staging laparotomy data, lymphangiography shows a slightly improved sensitivity and

specificity as compared to CT when evaluating retroperitoneal lymph nodes (40-42). Nevertheless, lymphangiography is no longer commonly employed, as CT scanning is considerably easier to perform and less labor intensive. CT diagnosis of lymphadenopathy is based on detection of lymph nodes > 1.0 cm in short-axis measurements. Other imaging techniques, such as ultrasound and MRI similarly rely on lymph node size criteria. Data on the accuracy of CT for evaluating subdiaphragmatic lymph nodes and organ involvement are limited (40,42,43). Published results have been obtained with CT scanners that were used in the late 1970s and early 1980s. Updated analyses of the value of the more advanced CT scanners that provide higher spatial resolution are not yet available. CT scanning has been estimated to perform at low sensitivity for detecting positive lymph nodes in the upper abdomen (38%-80%), spleen (15%-33%) and liver (19%-25%) (Table 6) (40,42,43).

Table 6. Abdominal CT scanning in Hodgkin's disease
Gold standard: histologic diagnosis based on laparotomy

First-named author	Ref.	Patient no.	Sensitivity	Sensitivity
			para-aortic nodes	spleen
			%	%
Jonsson	(43)	42	80	31
Castellino	(40)	121	65	33
Mansfield	(42)	87	38	15

Organ size appears a poor criterion for liver and spleen involvement, unless the enlargements of liver or spleen are marked. CT, MRI and ultrasound can also reveal focal deposits of lymphoma that are 1.0 cm in size or larger. However, in most instances, dissemination to the liver and spleen results in one or more subcentimeter deposits of lymphoma that are difficult if not impossible to detect with current cross-sectional imaging techniques.

1.4 Gallium scintigraphy

In 1969 Edwards and Hayes were the first to report gallium (^{67}Ga) uptake in patients with HD (44). The mechanism of this tumor uptake is incompletely understood, however it reflects metabolic activity and tumor viability (45,46). Gallium scintigraphy is not generally used in staging and restaging of HD and NHL. This is in part due to the variability of techniques used for gallium imaging. The usefulness of gallium studies depends on optimal equipment and technique (47). The recommended dose of ^{67}Ga in adults is at least 8 to 10 mCi. Single-photon emission computed tomographic (SPECT) imaging of thorax and abdomen and delayed studies are essential (48,49). This makes the procedure expensive and time consuming. Literature data regarding the use of gallium

scanning for the initial staging of patients with malignant lymphomas, using high dose ^{67}Ga , SPECT imaging and modern equipment are scarce (Table 7) (48-54).

Table 7. Gallium scintigraphy studies in the initial staging of malignant lymphoma

First-named author (ref)	Study	Patient no.	Patient group	Sensitivity above diaphragm %	Sensitivity below diaphragm %	Sensitivity per site overall %	Sensitivity per patient %
Tumeh (48)	R	40	HD NHL	96	85	NA	NA
Front (49)	R	77	HD NHL	88	79	85	NA
Hagemeister (50)	R	41	HD	64	31	51	NA
Larcos (51)	R	46	HD NHL	NA	NA	67	NA
Waxman (52)	P	36	HD NHL	NA	NA	61	89
Ben-Haim (53)	R	40	LG-NHL	68	72	69	80
Gallamini (54)	R	48	LG-NHL	NA	NA	41	50

R, retrospective; P, prospective; HD, Hodgkin's disease; NHL, non-Hodgkin's lymphoma; LG-NHL, low-grade non-Hodgkin's lymphoma; NA, not applicable.

Most studies are retrospective and the numbers of patients in those studies have been small. As regards the evaluation of abdominal lymph nodes and viscera, a low sensitivity ranging from 31%-85% has been reported for gallium scintigraphy (48-50). The visualisation of abdominal pathology is hampered by the high uptake of the radionuclide in the liver, spleen and intestines. For supradiaphragmatic sites the sensitivity and specificity of gallium imaging may range from 64%-96% (48-50,53). The overall sensitivity of CT scanning is better than that of gallium scintigraphy (49,52-55). Therefore, the use of gallium scintigraphy as an initial staging procedure has not become established general practice.

Masses that remain after treatment for lymphoma constitute a common and difficult diagnostic problem. With careful restaging by chest radiography and CT, many patients have residual masses after therapy (56-58). In many cases such residual masses consist of residual fibrotic tissue with no active lymphoma, whereas in other cases active residual disease may still be present. Recently, some reports have stressed the potential usefulness of SPECT gallium scanning to discriminate between active residual tumor and benign fibrous tissue. Several studies using SPECT gallium scans after therapy for aggressive

NHL have demonstrated some effectiveness in the use of this technique (57,59,60). In one study the predictive value of a positive posttreatment gallium scan was significantly higher (73%) than that of a positive CT (35%) (59). In another study the predictive value of CT and SPECT gallium scanning in the disease-free survival of patients receiving high-dose chemotherapy and autologous stem-cell transplantation for NHL was evaluated (60). In patients with diffuse aggressive NHL SPECT gallium scanning was highly predictive of eventual outcome and was more predictive than the CT scan results. However, for patients with follicular NHL the addition of SPECT gallium scanning to CT scanning did not add substantially to the evaluation of transplant outcome (60). Gallium imaging is less efficacious in intra-abdominal tumors and indolent NHL. Thus its value in monitoring the response to therapy and in follow-up in these cases is limited (53,54). The role of posttreatment gallium scans in the routine management of Hodgkin's disease remains unclear. The technique is particularly useful for evaluating mediastinal sites, but less for the evaluation of the abdomen. A positive gallium scan after therapy, although unusual in patients with Hodgkin's disease, should be considered a manifestation of gross residual disease and resistance to treatment (55,58,61-64). A negative posttreatment scan, although clearly more favorable than a positive scan, was reported not highly predictive of cure in patients with stage III to IV disease (63,64). These results suggest that the apparent excellent predictive value of a negative posttreatment study that has been reported in series of mostly stage I to II patients may be due to the fact that so few patients with early-stage disease relapse (59,62).

1.5 FDG-PET scintigraphy

Positron emission tomography (PET) is a form of computed tomography that produces images of biochemical and physiological processes in tissue. Tumors are visualized as areas of increased uptake of the tracer. PET with 2- ^{18}F -fluoro-2-deoxy-D-glucose (FDG) produces images of regional tissue glycolytic activity. Malignant tissues exhibit increased rates of glycolysis. Whole-body FDG-PET generates tomographic images of the entire patient and show the distribution of FDG throughout the body.

FDG imaging in lymphoma was first reported in 1987 by Paul, who demonstrated high FDG uptake in 4 NHL patients (65). The recent literature contains several publications where whole-body FDG-PET has been used for the staging of malignant lymphoma. Few studies have compared FDG-PET with other imaging modalities, notably CT, for the staging of primary untreated malignant lymphoma. Moog et al prospectively evaluated the accuracy of FDG-PET and CT in detecting nodal and extranodal involvement in 141 patients with HD and NHL (66,67). They reported that FDG-PET is more accurate than

CT in nodal and extranodal staging of lymphoma. FDG-PET permitted the detection of additional lesions and changes in staging levels in 16% of patients with extranodal involvement and in 8% of patients with nodal disease. These results are in agreement with those of several other studies showing an equivalent or superior diagnostic efficiency of FDG-PET in staging patients with lymphoma prior to therapy, when compared to CT (68-70). In a retrospective study in 96 patients with NHL Spaepen et al investigated the value of FDG-PET in detecting residual disease (71). The authors concluded that persistent uptake after first-line chemotherapy in NHL was highly predictive of residual or recurrent disease. Data from other studies indicate that whole-body FDG-PET has higher diagnostic and prognostic value than classical CT scan imaging for posttreatment evaluation in HD as well as in NHL (69,70,72). In conclusion, whole-body FDG-PET is a very promising imaging modality in patients with malignant lymphoma. A practical problem of FDG-PET is its poor availability in some European countries. Further multicenter prospective studies are needed to determine its full potential for imaging of lymphoma.

1.6 Somatostatin and somatostatin receptor scintigraphy

Somatostatin (SS) was originally discovered as a hypothalamic neurohormone that inhibited growth hormone (GH) secretion. It was subsequently demonstrated that SS is a widely distributed peptide in both the central and peripheral nervous system and in various peripheral tissues throughout the body. In mammals, two forms of bioactive peptides, somatostatin 14 and somatostatin 28, are produced by tissue-specific proteolytic processing of a common precursor. SS acts on various targets including the cerebral cortex, pituitary, gut, endocrine and exocrine pancreas, thyroid and adrenals. SS has many different biological activities. It may act as a neurotransmitter (acting within the central nervous system), a neurohormone (inhibiting the release of the pituitary hormones GH and TSH), a classical hormone (secreted by the D-cells of the pancreatic islets into the portal vein) or a paracrine factor (mediating the influence of the D-cells on the A- and B-cells of the pancreatic islets). Its hormonal actions include the inhibition of the release of growth hormone, insulin, glucagon, gastrin, serotonin and calcitonin (73,74). The effects of SS are achieved following binding to and activation of high-affinity receptors, located with different densities in the SS target tissues. SS receptors (SS-Rs) are structurally related membrane glycoproteins. At this moment, five distinct genes for five subtypes of the human SS-R (hSSTR1-hSSTR5) have been cloned and pharmacologically characterized (75-78).

These SS-R subtypes belong to a superfamily of receptors with seven transmembrane-spanning domains (Figure 1). All subtypes mediate their effects via inhibition of adenylyl cyclase activity (79). All five SS-Rs bind to SS-14 and SS-28 with high affinity (Table 8).

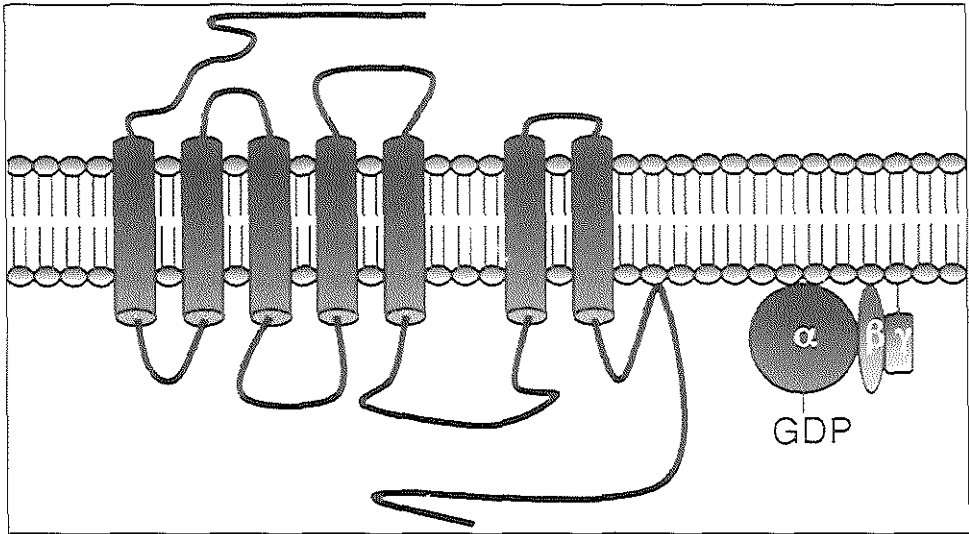


Figure 1 G protein-coupled receptor with seven transmembrane-spanning domains.

Table 8. Properties of human somatostatin receptor subtypes 1-5

	Somatostatin receptor				
	Subtype 1	Subtype 2	Subtype 3	Subtype 4	Subtype 5
Chromosomal location	14	17	22	20	16
Selectivity of somatostatin analogs					
Somatostatin 14	+	+	+	+	+
Somatostatin 28	+	+	+	-	+
Octreotide	-	+	±	-	+

The therapeutic use of SS is limited by its multiple actions and short plasma half-life of 2-3 minutes, requiring the cumbersome administration by continuous infusion for any clinical application. Therefore, studies have been initiated with the purpose of designing and synthesizing SS analogs with selective enhanced and prolonged activities. The SS analog octreotide was synthesized by the group of Bauer et al (80). Octreotide has a half-life of 90-120 minutes when administered subcutaneously. Octreotide binds with high affinity to subtype 2 (hSSTR2) and subtype 5 (hSSTR5). The analog has a relatively low

affinity to hSSTR3 and shows no significant binding to hSSTR1 and hSSTR4 (Table 8) (77,78,81,82).

SS-Rs are expressed in normal as well as tumor tissues. A variety of human malignant tumors express SS-Rs (83). SS-Rs have been found in most tumors originating from physiological SS-R positive tissues, i.e. pituitary tumors (84,85), endocrine gastro-enteropancreatic tumors (86-88), and brain tumors (89-91), including meningiomas, astrocytomas and neuroblastomas. SS-Rs are also expressed in tumors originating from several other organs, i.e. medullary thyroid carcinomas (92,93), breast carcinomas (94,95), renal cell carcinomas (96) and paragangliomas (97). Most SS-R positive tumors are well differentiated or have neuroendocrine features.

In 1987 peptide receptor scintigraphy using radiolabeled analogs of SS was introduced for tumor imaging (98,99). SS-R bearing neuroendocrine tumors could be visualized after intravenous administration of radioiodinated analogs of SS (98-100). However, [^{123}I -Tyr 3]-octreotide has several drawbacks for in vivo scintigraphy (101). ^{123}I of high specific activity is expensive and not readily available worldwide. Radiolabeling and purification is time consuming, the physical half-life of the radionuclide is short and there is a rapid clearance from the blood resulting in a short effective residence time for accumulation in tumor tissue. Moreover, substantial accumulation of radioactivity is seen in the intestines, since [^{123}I -Tyr 3]-octreotide is mainly cleared via the liver and biliary system. This makes the interpretation of planar- and SPECT images of the upper abdomen difficult. By and large these problems can be circumvented by substituting ^{123}I with ^{111}In bound to a chelated SS-analog (Figure 2).

[^{111}In -DTPA-D-Phe 1]-octreotide (^{111}In -pentetretotide) has certain notable advantages: easy preparation, general availability and appropriate half-life. Because of the longer half-life in the circulation of ^{111}In -pentetretotide the tumor tissue is exposed to the radionuclide for longer times, which improves gamma camera imaging 24 hours after injection. Moreover, because of its mainly renal clearance, faecal excretion of radioactivity amounts to only a few percent of the administered dose (102). Therefore, ^{111}In -pentetretotide is very suitable for use in planar imaging and SPECT of the abdomen. This is especially of importance for the localization of tumors in the upper abdomen, which are obscured by radioactivity from other organs, e.g. kidney, spleen and liver. The clinical value of ^{111}In -pentetretotide scintigraphy (SS-R scintigraphy) in the visualization of neuroendocrine tumors has been confirmed by various groups of investigators (103-109).

SS-Rs are also present on cells derived from several hematological malignancies (110-112). SS binding sites have been detected on acute lymphoblastic leukemia and acute myeloid leukemia (113). Activated lymphocytes and leukemic cells express SS-Rs of

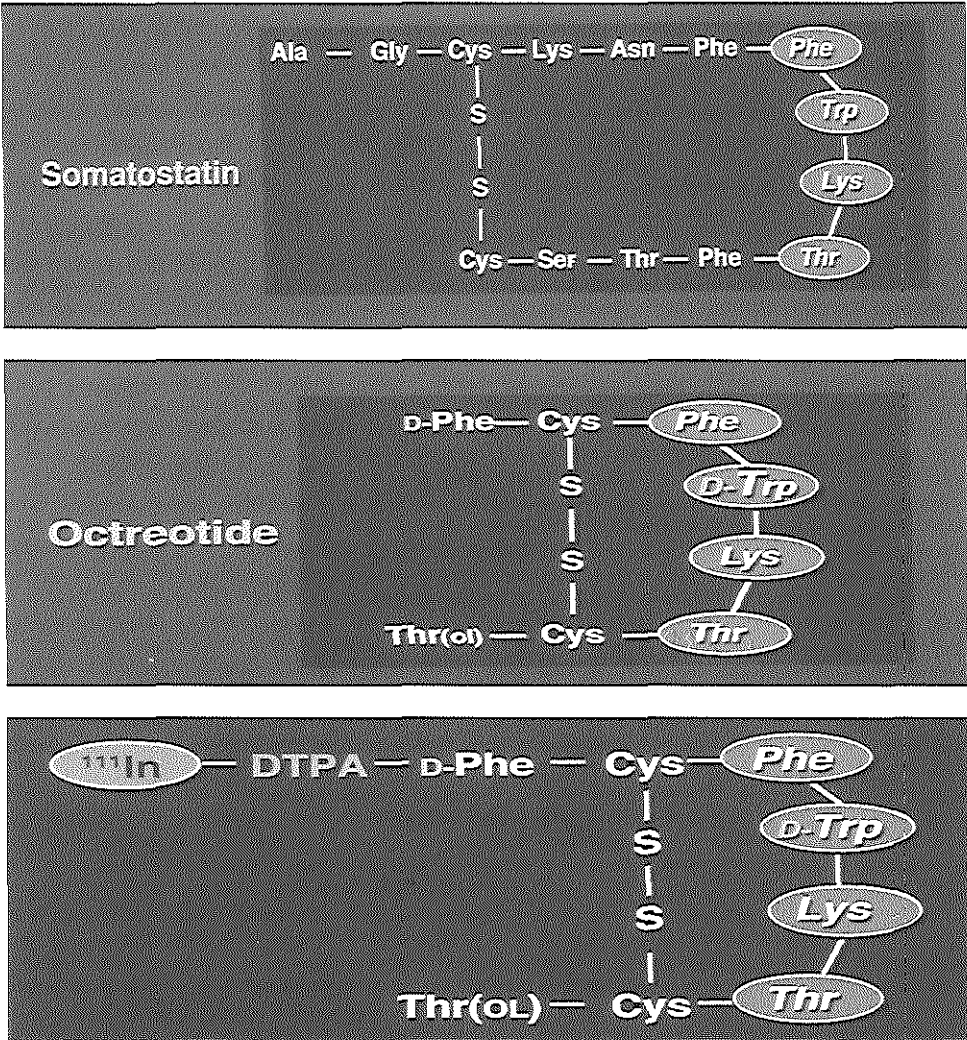


Figure 2 Chemical structures of somatostatin, octreotide and [¹¹¹In-DTPA-D-Phe¹]-octreotide.

high affinity, which suggests that SS-R expression is related to biological function of these cells (110-112). Many studies have demonstrated that SS has a modulatory effect on the immune system. SS and its receptors are expressed in human lymphoid organs and can regulate various immune functions including lymphocyte proliferation, immunoglobulin synthesis, and cytokine production (112). These findings have led us to explore whether it was possible to visualize NHL and HD in vivo. In a study in 10 patients with histologically proven malignant lymphoma SS-R scintigraphy was performed as part of the staging procedure. In all patients the lymphoma localizations that

were apparent following conventional evaluation could be confirmed by SS-R scintigraphy. Furthermore, in four patients additional lymphoma localizations were found through SS-R scintigraphy. In order to verify that indeed SS-R expressing lymphoma tissue was visualized, in four cases tissue biopsies were taken. Subsequent in vitro SS-R autoradiography confirmed that the hot spots on the scans indeed consisted of SS-R positive lymphoma tissue (114). The presence of SS-Rs on malignant cells of lymphoid origin was further demonstrated by Reubi et al (114,115), by use of in vitro SS-R autoradiography. SS-Rs were found in NHL of low-grade, intermediate-grade, and high-grade malignancy. In addition one tissue sample of HD was SS-R positive. In these tissue specimens, a low to moderate density of receptors was observed, but some NHL of high-grade malignancy expressed a high SS-R density.

1.7 Aim of the study

As discussed above, SS-Rs are expressed by malignant lymphomas at high frequency and it is possible to visualize these lymphomas with SS-R scintigraphy. Anatomical imaging studies, like CT or MRI, suffer from various shortcomings (see paragraph 1.3). Some groups have reported their experience with SS-R scintigraphy in malignant lymphoma (Table 9 and Table 10) (114,116-122).

Table 9. SS-R scintigraphy studies in Hodgkin's disease

First-named author	Ref.	Study	Patient no.	Therapy	Sensitivity per patient %	Sensitivity per site %
Bares	(116)	R	5	pre- and post therapy	NA	78
Van Hagen	(114)	P	2	pre therapy	100	100
Bong	(117)	P	9	pre- and post therapy	NA	91
Sarda	(118)	P	3	pre therapy	100	67
Lipp	(119)	P	11	pre- and post therapy	73	70
Goldsmith	(120)	P	2	pre therapy	100	100
Ivancevic	(121)	P	6	pre- and post therapy	57	57

R, retrospective; P, prospective; NA, not applicable.

However, the numbers of patients in these studies have been small and studies in previously untreated patient populations have been relatively scarce.

In this thesis we report on a series of studies that addressed the question of the clinical significance of SS-R scintigraphy in the staging of malignant lymphomas in a variety of clinical conditions.

Table 10. SS-R scintigraphy studies in non-Hodgkin's lymphoma

First-named author	Ref.	Study	Patient no.	Therapy	Sensitivity per patient %	Sensitivity per site %
Bares	(116)	R	13	pre- and post therapy	NA	63
Van Hagen	(114)	P	8	pre therapy	100	100
Bong	(117)	P	NA	pre- and post therapy	NA	37
Sarda	(118)	P	23	pre therapy	91	57
Lipp	(119)	P	23	pre- and post therapy	57	34
Goldsmith	(120)	P	5	NA	20	NA
Ivancevic	(121)	P	26	pre- and post therapy	85	38
Lipp	(122)	R	10	pre therapy	70	48

R, retrospective; P, prospective; NA, not applicable.

1.8 References

- 1 Visser O, Schouten LJ, Elbertse BJ. Lymfklierkanker: ziekte van Hodgkin en non-Hodgkin lymfoom. In: Feiten en fabels over kanker in Nederland. Vereniging van integrale kankercentra 46-49, 2000
- 2 Harris NL, Jaffe ES, Diebold J, Flandrin G, Muller-Hermelink HK, Vardiman J, Lister TA, Bloomfield CD. The World Health Organization classification of neoplastic diseases of the hematopoietic and lymphoid tissues. Report of the clinical advisory committee meeting, Airlie House, Virginia, November 1997. *Ann Oncol* 10: 1419-1432, 1999
- 3 Gupta RK, Gospodarowicz MK, Lister TA. Clinical evaluation and staging of Hodgkin's disease. In: Mauch PM, Armitage JO, Diehl V, Hoppe RT, Weiss LM eds. Hodgkin's disease. Philadelphia, Lippincott Williams and Wilkins. 223-240, 1999
- 4 Rosenberg SA, Kaplan HS. Evidence for an orderly progression in the spread of Hodgkin's disease. *Cancer Res* 26: 1225-1231, 1966
- 5 Gospodarowicz MK, Sutcliffe SB, Clark RM, Dembo AJ, Fitzpatrick MB, Munro AJ, Bergsagel DE, Patterson BJ, Tsang R, Chua T, Bush RS. Analysis of supradiaphragmatic clinical stage I and II Hodgkin's disease treated with radiation alone. *Int J Radiat Oncol Biol Phys* 22: 859-865, 1992
- 6 Tubiana M, Henry-Amar M, Carde P, Burgers P, Hayat M, van der Schueren E, Noordijk EM, Tanguy A, Meerwaldt JH, Thomas J, de Pauw B, Monconduit M, Cosset JM, Somers R. Toward comprehensive management tailored to prognostic factors of patients with clinical stages I and II in Hodgkin's disease. The EORTC Lymphoma Group controlled clinical trials: 1964-1987. *Blood* 73: 47-56, 1989
- 7 Tubiana M, Henry-Amar M, Hayat M, Burgers M, Qasim M, Somers R, Sizoo W, van der Schueren E. The EORTC treatment of early stages of Hodgkin's disease: the role of radiotherapy. *Int J Radiat Oncol Biol Phys* 10: 197-210, 1984

- 8 Mauch PM. Controversies in the management of early stage Hodgkin's disease. *Blood* 83: 318-329, 1994
- 9 Engert A, Wolf J, Diehl V. Treatment of advanced Hodgkin's lymphoma: standard and experimental approaches. *Semin Hematol* 36: 282-289, 1999
- 10 Advani RH, Horning SJ. Treatment of early-stage Hodgkin's disease. *Semin Hematol* 36: 270-281, 1999
- 11 Stansfeld AG, Diebold J, Kapanci Y, Kelenyi G, Lennert K, Mioduszewska O, Noel H, Rilke F, Sundstrom C, van Unnik JA, Wright DH. Updated Kiel classification for lymphomas. *Lancet* 1: 292-293, 1988
- 12 National Cancer Institute sponsored study of classification of non-Hodgkin's lymphomas: summary and description of a working formulation for clinical usage. The non-Hodgkin's lymphoma pathologic classification project. *Cancer* 49: 2112-2135, 1982
- 13 Harris NL, Jaffe ES, Stein H, Banks PM, Chan JK, Cleary ML, Delsol G, de Wolf-Peters C, Falini B, Gatter KC. A revised European-American classification of lymphoid neoplasms. *Blood* 84: 1361-1392, 1994
- 14 Isaacson PG. The current status of lymphoma classification. *Br J Haematol* 109: 258-266, 2000
- 15 Portlock CS. Management of the low-grade non-Hodgkin's lymphomas. *Semin Oncol* 17: 51-59, 1990
- 16 Besa PC, McLaughlin PW, Cox JD, Fuller LM. Long term assessment of patterns of treatment failure and survival in patients with stage I or II follicular lymphoma. *Cancer* 75: 2361-2367, 1995
- 17 Mac Manus MP, Hoppe RT. Is radiotherapy curative for stage I and II low-grade follicular lymphoma? Results of a long-term follow-up study of patients treated at Stanford University. *J Clin Oncol* 14: 1282-1290, 1996
- 18 Longo DL, Glatstein E, Duffey PL, Ihde DC, Hubbard SM, Fischer RI, Jaffe ES, Gilliom M, Young RC, DeVita Jr VT. Treatment of localized aggressive lymphomas with combination chemotherapy followed by involved-field radiation therapy. *J Clin Oncol* 7: 1295-1302, 1989
- 19 Tondini C, Zanini M, Lombardi F, Bengala C, Rocca A, Giardini R, Buzzoni R, Valagussa P, Bonnadonna G. Combined modality treatment with primary CHOP chemotherapy followed by locoregional irradiation in stage I or II histologically aggressive non-Hodgkin's lymphomas. *J Clin Oncol* 11: 720-725, 1993
- 20 Miller TP, Dahlberg S, Cassady JR, Adelstein DJ, Spier CM, Grogan TM, LeBlanc M, Carlin S, Chase E, Fisher RI. Chemotherapy alone compared with chemotherapy plus

- radiotherapy for localized intermediate- and high-grade non-Hodgkin's lymphoma. *N Engl J Med* 339: 21-26, 1998
- 21 Fischer RI, Gaynor ER, Dahlberg S, Oken MM, Grogan TM, Glick JH, Coltman CA Jr, Miller TP. Comparison of standard regimen (CHOP) with three intensive chemotherapy regimens for advanced non-Hodgkin's lymphoma. *N Engl J Med* 328: 1002-1006, 1993
- 22 Coltman CA, Dahlberg S, Jones SE. CHOP is curative in thirty percent of patients with large cell lymphoma: A twelve-year Southwest Oncology Group follow up. In: Skarin AT ed. *Advances in cancer chemotherapy*. New York, NY, Park Row 71-77, 1986
- 23 Carbone PP, Kaplan HS, Musshoff K, Smithers DW, Tubiana M. Report of the committee on Hodgkin's disease staging classification. *Cancer Res* 31: 1860-1861, 1971
- 24 Sutcliffe SB, Gospodarowicz MK, Bergsagel DE, Bush RS, Alison RE, Bean HA, Brown TC, Chua T, Clark RM, Curtis JE, Dembo AJ, Fitzpatrick PJ, Hasselback RH, Rideout DF, Sturgeon JF, Quirt I, Yeoh L, Peters MV. Prognostic groups for management of localized Hodgkin's disease. *J Clin Oncol* 3: 393-401, 1985
- 25 Tubiana M, Henry-Amar M, Hayat M, Burgers M, Qasim M, Somers R, Sizoo W, van der Schueren E. Prognostic significance of the number of involved areas in the early stages of Hodgkin's disease. *Cancer* 54: 885-894, 1984
- 26 Carde P, Burgers JM, Henry-Amar M, Hayat M, Sizoo W, van der Schueren E, Monconduit M, Noordijk EM, Lustman-Marechal J, Tanguy A, de Pauw B, Cosset JM, Cattan A, Schneider M, Thomas J, Meerwaldt JH, Somers R, Tubiana M. Clinical stages I and II Hodgkin's disease: a specifically tailored therapy according to prognostic factors. *J Clin Oncol* 6: 239-252, 1988
- 27 Carde P, Hagenbeek A, Hayat M, Monconduit M, Thomas J, Burgers MJ, Noordijk EM, Tanguy A, Meerwaldt JH, Le Fur R, Somers R, Kluin-Nelemans HC, Busson A, Breed WP, Bron D, Holdrinet A, Rutten EH, Michiels JJ, Regnier R, Debusscher L, Musella R, Fargeot P, Thyss A, Cattan A, Rigal-Huguet F, Roth S, Caillou B, Dupouy N, Henry-Amar M. Clinical staging versus laparotomy and combined modality with MOPP versus ABVD in early-stage Hodgkin's disease: the H6 twin randomized trials from the European Organization for Research and Treatment of Cancer Lymphoma Cooperative Group. *J Clin Oncol* 11: 2258-2272, 1993
- 28 Lister TA, Crowther D, Sutcliffe SB, Glatstein E, Canellos GP, Rosenberg SA, Coltman CA, Tubiana M. Report of a committee convened to discuss the evaluation and staging of patients with Hodgkin's disease: Cotswolds meeting. *J Clin Oncol* 7: 1630-1636, 1989
- 29 International Non-Hodgkin's Lymphomas Prognostic Factors Project (1993). A predictive model for aggressive non-Hodgkin's lymphoma. *N Engl J Med* 329: 987-994, 1993

- 30 Lopez-Guillermo A, Montserrat E, Bosch F, Terol MJ, Campo E, Rozman C. Applicability of the International Index for aggressive lymphomas to patients with low-grade lymphoma. *J Clin Oncol* 12: 1343-1348, 1994
- 31 Foussard C, Desablens B, Sensebe L, Francois S, Milpied N, Deconinck E, Delwail V, Dugay J, Lamy T, Ghandour C, Le Mevel A, Maissonneuve H, Casassus P, Colombat P. Is the International Prognostic Index for aggressive lymphomas useful for low-grade lymphoma patients? Applicability to stage III-IV patients. The GOELAMS Group, France. *Ann Oncol Suppl* 8: 49-52, 1997
- 32 Castellino RA. Diagnostic radiology. In: Canellos GP, Lister TA, Sklar JL. eds. *The lymphomas*. Philadelphia: WB Saunders, 187-206, 1998
- 33 Gerrits CJ, van Overhagen H, van Lom K, Adriaansen HJ, Löwenberg B. Ultrasound examination of pathological cervical lymph nodes in patients with non-Hodgkin's lymphomas and Hodgkin's disease. *Br J Haematol* 88: 626-628, 1994
- 34 Bruneton JN, Normand F, Balu-Maestro C, Kerboul P, Santini N, Thyss A, Schneider M. Lymphomatous superficial lymph nodes: US detection. *Radiology* 165: 233-235, 1987
- 35 Castellino RA, Blank N, Hoppe RT, Cho C. Hodgkin's disease: contributions of chest CT in the initial staging evaluation. *Radiology* 106: 603-605, 1986
- 36 Hopper KD, Diehl LF, Lesar M, Barnes M, Granger E, Baumann J. Hodgkin's disease: clinical utility of CT in initial staging and treatment. *Radiology* 169: 17-22, 1988
- 37 Zagoria RJ, Muss HB, Wolfsman NT, Choplin RH, Karstaedt N, Garovich MC. Computed tomography versus chest radiography: impact on management of patients with lymphoma. *Cancer Invest* 8: 357-364, 1990
- 38 Bergin CJ, Healy MV, Zincone GE, Castellino RA. MRI evaluation of chest wall involvement in malignant lymphoma. *J Comput Assist Tomogr* 14: 926-932, 1990
- 39 Mauch PM, Kalish LA, Kadin M, Coleman CN, Osteen R, Hellman S. Patterns of presentation of Hodgkin's disease. *Cancer* 71: 2062-2071, 1993
- 40 Castellino RA, Hoppe RT, Blank N, Young SW, Rosenberg SA, Kaplan HS. Computed tomography, lymphography, and staging laparotomy: correlations in initial staging of Hodgkin's disease. *AJR* 143: 37-41, 1984
- 41 Marglin S, Castellino RA. Lymphographic accuracy in 632 consecutive, previously untreated cases of Hodgkin's disease and non-Hodgkin's lymphoma. *Radiology* 140: 351-353, 1981
- 42 Mansfield CM, Fabian C, Jones S, van Slyck EJ, Grozea P, Morrison F, Miller TP, Seibert C, Ayyangar K. Comparison of lymphangiography and computed tomography scanning in evaluating abdominal disease in stages III and IV Hodgkin's disease. A Southwest Oncology Group study. *Cancer* 66: 2295-2299, 1990

- 43 Jonsson K, Karp W, Landberg T, Mortensson W, Tennvall J, Tylen U. Radiologic evaluation of subdiaphragmatic spread of Hodgkin's disease. *Acta Radiol Diagn (Stockh)* 24: 153-159, 1983
- 44 Edwards CL, Hayes RL. Tumor scanning with ^{67}Ga citrate. *J Nucl Med* 10: 103-105, 1969
- 45 Larson SM. Mechanism of localization of gallium-67 in tumors. *Semin Nucl Med* 8: 193-203, 1978
- 46 Iosilevsky G, Front D, Bettman L, Hardoff R, Ben-Arieh Y. Uptake of gallium-67 citrate and [$2\text{-}^3\text{H}$] deoxyglucose in the tumor model, following chemotherapy and radiotherapy. *J Nucl Med* 26: 278-282, 1985
- 47 Front D, Israel O. The role of Ga-67 scintigraphy in evaluating the results of therapy of lymphoma patients. *Semin Nucl Med* 25: 60-71, 1995
- 48 Tumeç SS, Rosenthal DS, Kaplan WD, English RJ, Holman BL. Lymphoma: evaluation with Ga-67 SPECT. *Radiology* 164: 111-114, 1987
- 49 Front D, Israel O, Epelbaum R, Ben Haim S, Even-Sapir E, Jerushalmi J, Kolodny GM, Robinson E. Ga-67 SPECT before and after treatment of lymphoma. *Radiology* 175: 515-519, 1990
- 50 Hagemeister FB, Fesus SM, Lamki LM, Haynie TP. Role of the gallium scan in Hodgkin's disease. *Cancer* 65: 1090-1096, 1990
- 51 Larcos G, Farlow DC, Antico VF, Gruenewald SM, Boyages J. The role of high dose 67-gallium scintigraphy in staging untreated patients with lymphoma. *Aust N Z J Med* 24: 5-8, 1994
- 52 Waxman AD, Eller D, Ashook G, Ramanna L, Brachman M, Heifetz L, McAndrews P, Bierman H, Taub R, Avedon M, Wall F. Comparison of Gallium-67-citrate and Thallium-201 scintigraphy in peripheral and intrathoracic lymphoma. *J Nucl Med* 37: 46-50, 1996
- 53 Ben-Haim S, Bar-Shalom R, Israel O, Haim N, Epelbaum R, Ben-Shachar M, Gaitini D, Kolodny GM, Front D. Utility of gallium-67 scintigraphy in low-grade non-Hodgkin's lymphoma. *J Clin Oncol* 14: 1936-1942, 1996
- 54 Gallamini A, Biggi A, Fruttero A, Pugno F, Cavallero G, Pregnò P, Grasso M, Farinelli C, Leone A, Gallo E. Revisiting the prognostic role of gallium scintigraphy in low-grade non-Hodgkin's lymphoma. *Eur J Nucl Med* 24: 1499-1506, 1997
- 55 Delcambre C, Reman O, Henry-Amar M, Peny AM, Macro M, Cheze S, Genot JY, Tanguy A, Switers O, Van HL, Couette JE, Leporrier M, Bardet S. Clinical relevance of gallium-67 scintigraphy in lymphoma before and after therapy. *Eur J Nucl Med* 27: 176-184, 2000
- 56 Radford JA, Cowan RA, Flanagan M, Dunn G, Crowther D, Johnson RJ, Eddleston B. The significance of residual mediastinal abnormality on the chest radiograph following treatment of Hodgkin's disease. *J Clin Oncol* 6: 940-946, 1988

- 57 Zinzani PL, Martelli M, Magagnoli M, Pescarmona E, Scaramucci L, Palombi F, Bendandi M, Martelli MP, Ascani S, Orcioni GF, Pileri SA, Mandelli F, Tura S. Treatment and clinical management of primary mediastinal large B-cell lymphoma with sclerosis: MACOP-B regimen and mediastinal radiotherapy monitored by ⁶⁷Gallium scan in 50 patients. *Blood* 94: 3289-3293, 1999
- 58 King SC, Reiman RJ, Prosnitz LR. Prognostic importance of restaging gallium scans following induction chemotherapy for advanced Hodgkin's disease. *J Clin Oncol* 12: 306-311, 1994
- 59 Front D, Ben-Haim S, Israel O, Epelbaum R, Haim N, Even-Sapir E, Kolodny GM, Robinson E. Lymphoma: predictive value of Ga-67 scintigraphy after treatment. *Radiology* 182: 359-363, 1992
- 60 Vose JM, Bierman PJ, Anderson JR, Harrison KA, Dalrymple GV, Byar K, Kessinger A, Armitage JO. Single-photon emission computed tomography gallium imaging versus computed tomography: predictive value in patients undergoing high-dose chemotherapy and autologous stem-cell transplantation for non-Hodgkin's lymphoma. *J Clin Oncol* 14: 2473-2479, 1996
- 61 Zinzani PL, Magagnoli M, Franchi R, Zompatori M, Frezza G, Galassi R, Gherlinzoni F, Bendandi M, Albertini P, Monetti N, Tura S. Diagnostic role of gallium scanning in the management of lymphoma with mediastinal involvement. *Haematologica* 84: 604-607, 1999
- 62 Wylie BR, Southee AE, Joshua DE, McLaughlin AF, Gibson J, Hutton BF, Morris JG, Kronenberg H. Gallium scanning in the management of mediastinal Hodgkin's disease. *Eur J Haematol* 42: 344-347, 1989
- 63 Cooper DL, Caride VJ, Zloty M, Germino J, Farber LR, Hoffer PB. Gallium scans in patients with mediastinal Hodgkin's disease treated with chemotherapy. *J Clin Oncol* 11: 1092-1098, 1993
- 64 Salloum E, Brandt DS, Caride VJ, Cornelius E, Zelterman D, Schubert W, Mannino T, Cooper DL. Gallium scans in the management of patients with Hodgkin's disease: a study of 101 patients. *J Clin Oncol* 15: 518-527, 1997
- 65 Paul R. Comparison of fluorine-18-2-fluorodeoxyglucose and gallium-67 citrate imaging for detection of lymphoma. *J Nucl Med* 28: 288-292, 1987
- 66 Moog F, Bangerter M, Diederichs CG, Guhlmann A, Kotzerke J, Merkle E, Kolokythas O, Herrmann F, Reske SN. Lymphoma: role of whole-body 2-deoxy-2-[F-18]fluoro-D-glucose (FDG) PET in nodal staging. *Radiology* 203: 795-800, 1997

- 67 Moog F, Bangerter M, Diederichs CG, Guhlmann A, Merkle E, Frickhofen N, Reske SN. Extranodal malignant lymphoma: detection with FDG PET versus CT. *Radiology* 206: 475-481, 1998
- 68 Jerusalem G, Warland V, Najjar F, Paulus P, Fassotte MF, Fillet G, Rigo P. Whole-body ^{18}F -FDG-PET for the evaluation of patients with Hodgkin's disease and non-Hodgkin's lymphoma. *Nucl Med Commun* 20: 13-20, 1999
- 69 Wiedmann E, Baican B, Hertel A, Baum RP, Chow KU, Knupp B, Adams S, Hör G, Hoelzer D, Mitrou PS. Positron emission tomography (PET) for staging and evaluation of response to treatment in patients with Hodgkin's disease. *Leuk Lymphoma* 34: 545-551, 1999
- 70 Kostakoglu L, Goldsmith SJ. Fluorine-18 fluorodeoxyglucose positron emission tomography in the staging and follow-up of lymphoma: is it time to shift gears? *Eur J Nucl Med* 27: 1564-1578, 2000
- 71 Spaepen K, Stroobants S, Dupont P, van Steenweghen S, Thomas J, Vandenberghe P, Vanuytsel L, Bormans G, Balzarini J, De Wolf-Peeters C, Mortelmans L, Verhoef G. Prognostic value of positron emission tomography (PET) with fluorine-18 fluorodeoxyglucose (^{18}F]FDG) after first-line chemotherapy in non-Hodgkin's lymphoma: is [^{18}F]FDG-PET a valid alternative to conventional diagnostic methods? *J Clin Oncol* 19: 414-419, 2001
- 72 Jerusalem G, Beguin Y, Fassotte MF, Najjar F, Paulus P, Rigo P, Fillet G. Whole-body positron emission tomography using ^{18}F -fluorodeoxyglucose for posttreatment evaluation in Hodgkin's disease and non-Hodgkin's lymphoma has higher diagnostic and prognostic value than classical computed tomography scan imaging. *Blood* 94: 429-433, 1999
- 73 Reichlin S. Somatostatin. *N Engl J Med* 309: 1495-1501, 1983
- 74 Reichlin S. Somatostatin. *N Engl J Med* 309: 1556-1563, 1983
- 75 Yamada Y, Post SR, Wang K, Tager HS, Bell GI, Seino S. Cloning and functional characterization of a family of human and mouse somatostatin receptors expressed in brain, gastrointestinal tract, and kidney. *Proc Natl Acad Sci USA* 89: 251-255, 1992
- 76 Yamada Y, Reisine T, Law SF, Ihara Y, Kubota A, Kagimoto S, Seino M, Seino Y, Bell GI, Seino S. Somatostatin receptors, an expanding gene family: cloning and functional characterization of human SSTR 3, a protein coupled to adenylyl cyclase. *Mol Endocrinol* 6: 2136-2142, 1992
- 77 Rohrer L, Raulf F, Bruns C, Buettner R, Hofstaedter F, Schule R. Cloning and characterization of a fourth human somatostatin receptor. *Proc Natl Acad Sci USA* 90: 4196-4200, 1993

- 78 Yamada Y, Kagimoto S, Kubota A, Yasuda K, Masuda K, Someya Y, Ihara Y, Li Q, Imura H, Seino S, Seino Y. Cloning, functional expression and pharmacological characterization of a fourth (hSSTR4) and a fifth (hSSTR5) human somatostatin receptor subtype. *Biochem Biophys Res Commun* 195: 844-852, 1993
- 79 Patel YC, Greenwood MT, Warszynska A, Panetta R, Srikant CB. All five cloned somatostatin receptors (hSSTR1-5) are functionally coupled to adenylyl cyclase. *Biochem Biophys Res Commun* 198: 605-612, 1994
- 80 Bauer W, Briner U, Doepfner W, Haller R, Huguenin R, Marbach P, Petcher TJ, Pless J. SMS 201-995: a very potent and selective octapeptide analogue of somatostatin with prolonged action. *Life Sci* 31: 1133-1140, 1982
- 81 Bell GI, Reisine T. Molecular biology of somatostatin receptors. *Trends Neurosci* 16: 34-38, 1993
- 82 Bruno JF, Berelowitz M. Somatostatin receptors: orphan that found family and function. *Mol Cell Neurosciences* 4: 307-309, 1993
- 83 Reubi JC, Krenning E, Lamberts SWJ, Kvols L. Somatostatin receptors in malignant tissues. *J Steroid Biochem Mol Biol* 37: 1073-1077, 1990
- 84 Reubi JC, Landolt AM. The growth hormone responses to octreotide correlate with adenoma somatostatin status. *J Clin Endocrinol Metab* 68: 844-850, 1989
- 85 Reubi JC, Heitz PU, Landolt AM. Visualization of somatostatin receptors and correlation with immunoreactive GH and PRL in human pituitary adenomas: evidence for different tumor subclasses. *J Clin Endocrinol Metab* 65: 65-73, 1987
- 86 Reubi JC, Kvols LK, Waser B, Nagorney DM, Heitz PU, Charboneau JW, Reading CC, Moertel C. Detection of somatostatin receptors in surgical and percutaneous needle biopsy samples of carcinoids and islet cell carcinomas. *Cancer Res* 50: 5969-5977, 1990
- 87 Reubi JC, Krenning E, Lamberts SWJ, Kvols L. In vitro detection of somatostatin receptors in human tumors. *Metabolism Suppl* 41: 104-110, 1992
- 88 Kimura N, Pilichowska M, Date F, Kimura I, Schindler M. Immunohistochemical expression of somatostatin type 2A receptor in neuroendocrine tumors. *Clin Cancer Res* 5: 3483-3487, 1999
- 89 Dutour A, Kumur U, Panetta R, Ouafik L, Fina F, Sasi R, Patel YC. Expression of somatostatin receptor subtypes in human brain tumors. *Int J Cancer* 76: 620-627, 1998
- 90 Reubi JC, Lang W, Maurer R, Koper JW, Lamberts SWJ. Distribution and biochemical characterization of somatostatin receptors in tumors of the human central nervous system. *Cancer Res* 47: 5758-5764, 1987

- 91 Reubi JC, Maurer R, Klijn JG, Stefanko SZ, Foekens JA, Blaauw G, Blankenstein MA, Lamberts SWJ. High incidence of somatostatin receptors in human meningiomas: biochemical characterization. *J Clin Endocrinol Metab* 63: 433-438, 1986
- 92 Reubi JC, Chayvialle JA, Franc B, Cohen R, Calmettes C, Modigliani E. Somatostatin receptors and somatostatin content in medullary thyroid carcinomas. *Lab Invest* 64: 567-573, 1991
- 93 Mato E, Matias-Guiu X, Chico A, Webb SM, Cabezas R, Berna L, de Leiva A. Somatostatin and somatostatin receptor subtype gene expression in medullary thyroid carcinoma. *J Clin Endocrinol Metab* 83: 2417-2420, 1998
- 94 Reubi JC, Waser B, Foekens JA, Klijn JG, Lamberts SWJ, Laissue J. Somatostatin receptor incidence and distribution in breast cancer using receptor autoradiography: relationship to EGF-receptor. *Int J Cancer* 46: 416-420, 1990
- 95 Van Eijck CHJ, Krenning EP, Bootsma A, Oei HY, van Pel R, Lindemans J, Jeekel J, Reubi JC, Lamberts SWJ. Somatostatin receptor scintigraphy in primary breast cancer. *Lancet* 343: 640-643, 1994
- 96 Reubi JC, Kvols L. Somatostatin receptors in human renal cell carcinomas. *Cancer Res* 52: 6074-6078, 1992
- 97 Reubi JC, Waser B, Khosla S, Kvols L, Goellner JR, Krenning E, Lamberts S. In vitro and in vivo detection of somatostatin receptors in pheochromocytomas and paragangliomas. *J Clin Endocrinol Metab* 74: 1082-1089, 1992
- 98 Krenning EP, Bakker WH, Breeman WAP, Koper JW, Kooij PPM, Ausema L, Lameris LS, Reubi JC, Lamberts SWJ. Localization of endocrine-related tumours with radioiodinated analogue of somatostatin. *Lancet* 1: 242-244, 1989
- 99 Bakker WH, Krenning EP, Breeman WAP, Koper JW, Kooij PPM, Reubi JC, Klijn JG, Visser TJ, Docter R, Lamberts SWJ. Receptor scintigraphy with a radioiodinated somatostatin analogue: radiolabeling, purification, biological activity and in vivo applications in animals. *J Nucl Med* 31: 1501-1509, 1990
- 100 Lamberts SWJ, Bakker WH, Reubi JC, Krenning EP. Somatostatin-receptor imaging in the localization of endocrine tumors. *N Engl J Med* 323: 1246-1249, 1990
- 101 Bakker WH, Krenning EP, Breeman WAP, Kooij PPM, Reubi JC, Koper JW, de Jong M, Lameris JS, Visser TJ, Lamberts SWJ. In vivo use of a radioiodinated somatostatin analogue: dynamics, metabolism and binding to somatostatin receptor-positive tumours in man. *J Nucl Med* 32: 1184-1189, 1991
- 102 Krenning EP, Bakker WH, Kooij PPM, Breeman WAP, Oei HY, de Jong M, Reubi JC, Visser TJ, Bruns C, Kwekkeboom DJ, Reijs AEM, van Hagen PM, Koper JW, Lamberts SWJ. Somatostatin receptor scintigraphy with [¹¹¹In-DTPA-D-Phe¹]-octreotide in man:

- metabolism, dosimetry and comparison with [¹²³I-Tyr³]-octreotide. *J Nucl Med* 33: 652-658, 1992
- 103 Krenning EP, Kwekkeboom DJ, Bakker WH, Breeman WAP, Kooij PPM, Oei HY, van Hagen M, Postema PTE, de Jong M, Reubi JC, Visser TJ, Reijs AEM, Hofland LJ, Koper JW, Lamberts SWJ. Somatostatin receptor scintigraphy with [¹¹¹In-DTPA-D-Phe¹]- and [¹²³I-Tyr³]-octreotide: the Rotterdam experience with more than 1000 patients. *Eur J Nucl Med* 20: 716-731, 1993
- 104 Kwekkeboom DJ, Krenning EP, Bakker WH, Oei HY, Kooij PP, Lamberts SWJ. Somatostatin analogue scintigraphy in carcinoid tumours. *Eur J Nucl Med* 20: 283-292, 1993
- 105 Oberg K. State of the art and future prospects in the management of neuroendocrine tumors. *Q J Nucl Med* 44: 3-12, 2000
- 106 Telischi FF, Bustillo A, Whiteman ML, Serafini AN, Reisberg MJ, Gomez-Marin O, Civantos FJ, Balkany TJ. Octreotide scintigraphy for the detection of paragangliomas. *Otolaryngol Head Neck Surg* 122: 358-362, 2000
- 107 Lebtahi R, Cadiot G, Mignon M, Le Guludec D. Somatostatin receptor scintigraphy: a first-line imaging modality for gastroenteropancreatic neuroendocrine tumors. *Gastroenterology* 115: 1025-1027, 1998
- 108 Krausz Y, Bar-Ziv J, de Jong RB, Ish-Shalom S, Chisin R, Shibley N, Glaser B. Somatostatin-receptor scintigraphy in the management of gastroenteropancreatic tumors. *Am J Gastroenterol* 93: 66-70, 1998
- 109 Krenning EP, Kooij PP, Pauwels S, Breeman WA, Postema PT, de Herder WW, Valkema R, Kwekkeboom DJ. Somatostatin receptor: scintigraphy and radionuclide therapy. *Digestion Suppl* 57: 57-61, 1996
- 110 Hiruma K, Koike T, Nakamura H, Sumida T, Maeda T, Tomioka H, Yoshida S, Fujita T. Somatostatin receptors on human lymphocytes and leukaemia cells. *Immunology* 71: 480-485, 1990
- 111 Nakamura H, Koike T, Hiruma K, Sato T, Tomioka H, Yoshida S. Identification of lymphoid cell lines bearing receptors for somatostatin. *Immunology* 62: 655-658, 1987
- 112 Van Hagen PM, Krenning EP, Kwekkeboom DJ, Reubi JC, van den Anker-Lugtenburg PJ, Löwenberg B, Lamberts SWJ. Somatostatin and the immune and hematopoietic system: a review. *Eur J Clin Invest* 24: 91-99, 1994
- 113 Santini V, Lamberts SWJ, Krenning EP, Backx B, Löwenberg B. Somatostatin and its cyclic octapeptide analog SMS 201-995 as inhibitors of proliferation of human acute lymphoblastic and acute myeloid leukemia. *Leuk Res* 19: 707-712, 1995

- 114 Van Hagen PM, Krenning EP, Reubi JC, Mulder AH, Bakker WH, Oei HY, Löwenberg B, Lamberts SWJ. Somatostatin analogue scintigraphy of malignant lymphomas. *Br J Haematol* 83: 75-79, 1993
- 115 Reubi JC, Waser B, van Hagen M, Lamberts SWJ, Krenning EP, Gebbers JO, Laissue JA. In vitro and in vivo detection of somatostatin receptors in human malignant lymphomas. *Int J Cancer* 50: 895-900, 1992
- 116 Bares R, Galonska P, Dempke W, Handt S, Büll U, Osieka R. Somatostatin receptor scintigraphy in malignant lymphoma: First results and comparison with glucose metabolism measured by positron-emission tomography. *Horm Metab Res Suppl* 27: 56-58, 1993
- 117 Bong SB, VanderLaan JG, Louwes H, Schuurman JJ. Clinical experience with somatostatin receptor imaging in lymphoma. *Sem Oncol Suppl* 21: 46-50, 1994
- 118 Sarda L, Duet M, Zini JM, Berolatti B, Benelhadj S, Tobelem G, Mundler O. Indium-111 pentetreotide scintigraphy in malignant lymphomas. *Eur J Nucl Med* 22: 1105-1109, 1995
- 119 Lipp RW, Silly H, Ranner G, Dobnig H, Passath A, Leb G, Krejs GJ. Radiolabeled octreotide for the demonstration of somatostatin receptors in malignant lymphoma and lymphadenopathy. *J Nucl Med* 36: 13-18, 1995
- 120 Goldsmith SJ, Macapinlac HA, O'Brien JP. Somatostatin-receptor imaging in lymphoma. *Sem Nucl Med* 25: 262-271, 1995
- 121 Ivancevic V, Wörmann B, Nauck C, Sandrock D, Munz DL, Hiddemann W, Emrich D. Somatostatin receptor scintigraphy in the staging of lymphomas. *Leuk Lymphoma* 26: 107-114, 1997
- 122 Lipp RW, Schnedl WJ, Aglas F, Ranner G, Beham-Schmid C, Leb G, Sill H. Visualization of non-Hodgkin's lymphoma by high dosed somatostatin receptor specific scintigraphy and extended single photon emission tomography. *Acta Med Austriaca* 26: 105-108, 1999

CHAPTER 2

Somatostatin receptor scintigraphy in the initial staging of Hodgkin's disease

P.J. van den Anker-Lugtenburg^{1,4}, E.P. Krenning^{2,3}, H.Y. Oei², M.P. Van Hagen³,
C.J.H. Gerrits¹, J.C. Reubi⁵, S.W.J. Lamberts³ and B. Löwenberg^{1,4}

¹Dept. of Hematology, University Hospital and Erasmus University Rotterdam

²Dept. of Nuclear Medicine, University Hospital and Erasmus University Rotterdam

³Dept. of Internal Medicine, University Hospital and Erasmus University Rotterdam

⁴Dept. of Hematology, Daniel den Hoed Cancer Center, Rotterdam
The Netherlands

⁵Institute of Pathology, University of Berne, Switzerland.

Br J Haematol 93: 96-103, 1996

Abstract

Somatostatin receptor scintigraphy has been successfully used in the visualization of a variety of neuroendocrine tumors. *In vitro* studies have shown that somatostatin receptors (SS-Rs) are present in human malignant lymphomas. We conducted a prospective study in 56 consecutive untreated patients with histologically proven Hodgkin's disease (HD) and compared the results of SS-R scintigraphy with physical and radiological examinations as initial evaluation. SS-R scintigraphy was positive in 55/56 (98%) patients at sites of documented disease. In 20 patients SS-R scintigraphy disclosed lymphoma localizations not revealed following procedures of conventional staging. As a result in 12 patients (21%) SS-R scintigraphy produced a change of stage and in seven patients (13%) the additional information obtained from SS-R scintigraphy led to a change of treatment. SS-R scintigraphy failed to visualize sites of HD in four patients, mainly in the abdominal area. In three patients a false-positive result was obtained. These data show that SS-R scintigraphy provides an imaging technique that appears to visualize tumors in most patients with HD and may be clinically useful in the management of these patients.

Introduction

Precise staging of the dissemination of the disease is critical in the treatment and prognosis of patients with Hodgkin's disease (HD). To determine the extent of the disease, several imaging techniques are currently employed, e.g. plain chest radiography, computed tomography (CT), sonography and lymphangiography (1). These techniques are also used to assess the response of the disease at different sites to treatment. Gallium scintigraphy is variably used in the work-up of patients with HD (2).

A variety of human neoplasms express somatostatin receptors (SS-Rs). SS-Rs have been found in neuroendocrine (3-5), breast (6,7) and brain tumors (8). In order to take advantage of SS-R tissue expression, radiolabeled somatostatin (SS) analogs have been applied to visualize SS-R positive tumors *in vivo* with a gamma camera. SS-R scintigraphy has proved clinically useful for refined tumor localization in patients with carcinoid tumors, pancreatic endocrine tumors and paragangliomas (9-12).

SS-Rs are expressed on the membranes of human lymphoid cells, including malignant lymphoma and HD (13), as has become apparent from autoradiography of tissue sections. There is as yet only limited experience with SS-R scintigraphy in patients with HD (14-17). We set out to evaluate SS-R scintigraphy as a potentially useful method for *in vivo* imaging of tumor deposits in patients with HD. Here we present the results of a prospective study in 56 newly diagnosed, previously untreated, patients with histologically proven HD.

Patients and methods

Patients

56 consecutive, newly diagnosed and previously untreated patients with histologically proven HD were enrolled in the study. The stage of the disease according to the Ann Arbor classification (18) was established by conventional methods, which included a physical examination, chest radiography, CT of chest, abdomen and pelvis, bone marrow biopsy, and occasionally lymphangiography. All patients had given informed consent to the study, which was approved by the ethics committee of the University Hospital Rotterdam.

Scintigraphy

SS-R scintigraphy was performed after intravenous injection of the radioactive labeled SS analog [$^{111}\text{In-DTPA-D-Phe}^1$]-octreotide (obtained from Mallinckrodt Medical BV, Petten, The Netherlands). The preparation of [$^{111}\text{In-DTPA-D-Phe}^1$]-octreotide, the dose administered (222 MBq) and the technique of scintigraphy with the gamma camera, as well as with single photon emission computed tomography (SPECT) have recently been described (10,19-22). Planar total body scintigraphy was performed 24 h post-injection with a large-field-view gamma camera (Counterbalance 3700 and ROTA II; Siemens Gammasonics, Erlangen, Germany) equipped with a medium-energy collimator. In all patients SPECT images of the upper abdomen were made. For both planar and SPECT scintigraphy, images with a long exposure time were obtained, e.g. 15 min for planar views. Repeated scintigraphy of the abdomen was performed 48 h post-injection when 24-h scintigraphy showed accumulation in the abdomen. In normal individuals a physiological accumulation of radioactivity may be seen at 24 h after intravenous administration of [$^{111}\text{In-DTPA-D-Phe}^1$]-octreotide in the pituitary and thyroid gland, the liver, spleen, kidneys, the urinary bladder and occasionally in the gallbladder. The presence of intestinal radioactivity (mainly in the colon at 24 h) is due to some hepatobiliary clearance of [$^{111}\text{In-DTPA-D-Phe}^1$]-octreotide and may be reduced following the use of laxatives (20,21). The SS-R scans were evaluated by two investigators at the same time without knowing patient identity or results of the conventional diagnostic work-up. Finally, the results of the SS-R scans and conventional diagnostic tests were compared by the study coordinator. In case of discrepancies additional radiodiagnostic investigations were scheduled before the beginning of treatment and, if practically possible, cytological or histological verification was sought. In nine patients SS-R scintigraphy was repeated after therapy. All patients were followed during and after treatment.

Autoradiography

In three patients SS-R autoradiography was performed on 10 micrometer thick cryostat

sections of the tumor samples, using a iodinated SS octapeptide analog [$^{125}\text{I-Tyr}^3$]-octreotide ($^{125}\text{I-204-090}$) as radioligand (3,4).

Results

The clinical characteristics of the 56 patients with HD in whom SS-R scintigraphy was performed are given in Table 1.

Table 1. Clinical features and SS-R scintigraphy results in 56 patients with HD

Age (yr)	
Median	33.1
Range	15-66
Sex	
Female	29 (52%)
Male	27 (48%)
Histologic subtype	
Lymphocyte predominance	4 (7%)
Nodular sclerosis	46 (82%)
Mixed cellularity	6 (11%)
Clinical stage*	
Stage I	11 (19%)
Stage II	29 (52%)
Stage III	7 (13%)
Stage IV	9 (16%)
SS-R scintigraphy results	
Positive	55 (98%)
Negative	1 (2%)

*based on physical examination and conventional staging methods.

SS-R scintigraphy indicated SS-R positivity at areas of documented active disease in 55 cases (98%). Two examples of SS-R scintigraphy of lymphoma localizations above the diaphragm are shown in Figure 1A (mediastinum) and Figure 1B (neck). In Figures 2A-C a SS-R scintigram of multiple para-aortic abdominal lymph nodes is shown.

Additional sites of HD revealed by SS-R scintigraphy (20 patients)

In 20 patients SS-R scintigraphy disclosed activity suggestive of lymphoma which had not been revealed following physical and radiological examination. Table 2 lists the additional sites of disease as suggested by SS-R scintigraphy in comparison with the results of conventional staging in these 20 patients. 27 additional SS-R positive sites of disease became

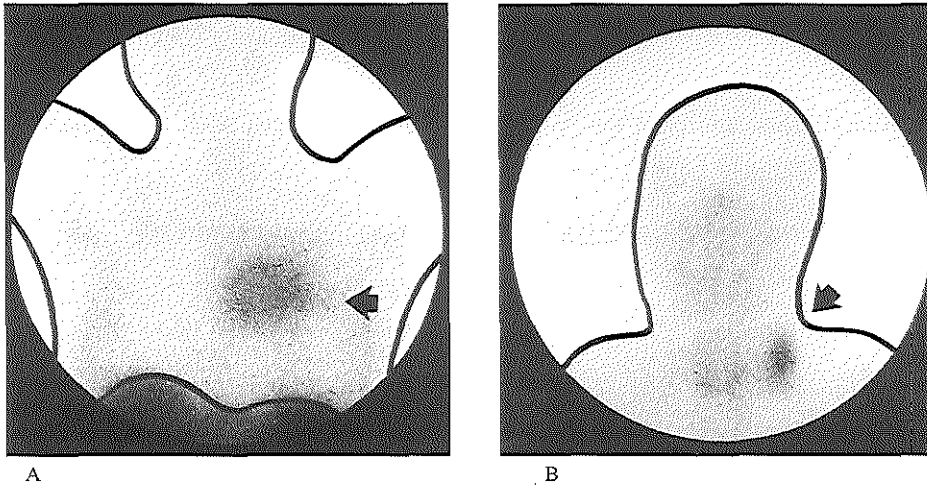


Figure 1

(A) Visualization of mediastinal lymph nodes (arrow) in a patient with stage IB HD, mixed cellularity, by SS-R scintigraphy at 24 h (anterior image of the thorax). On CT a large mediastinal mass of 11 x 9 cm was shown. In this patient normal accumulation of radioactivity in the thyroid, not seen on this image, was apparent on the anterior image of the head and neck. (B) SS-R scintigraphy reveals positive supraclavicular lymph nodes in the neck (arrow) at 24 h in a patient with stage IA HD, mixed cellularity (anterior image of the head and neck). Normal accumulation of radioactivity is seen in the pituitary and thyroid. On physical examination a lymph node of 3 cm diameter was palpated.

apparent in these 20 patients. Most new localizations were above the diaphragm, i.e. in the neck ($n = 12$ cases), mediastinum ($n = 3$), axilla ($n = 3$), infraclavicular area ($n = 1$) and lung ($n = 1$), but also in the para-aortic region ($n = 5$) and the inguinal area ($n = 2$). In patient 10, following the results of SS-R scintigraphy, we confirmed the presence of an abnormal lymph node in the neck on repeated palpation (1.5 cm diameter). In the same patient multiple small intrapulmonary "lesions" were seen on CT, which were read as possible Hodgkin localizations. The intrapulmonary lesions were negative on SS-R scintigraphy. After six cycles of chemotherapy no residual masses were seen. The radiographic intrapulmonary abnormalities that had been SS-R negative had not changed and were retrospectively interpreted as pre-existent abnormalities of unclear nature (follow-up time 2 years). In the majority of patients additional investigations were performed to verify the diagnosis at discrepant sites (see Table 2). The superiority of SS-R scintigraphy was confirmed in 12/20 patients, i.e. by repeated palpation ($n = 4$), subsequent radiodiagnostic tests ($n = 6$) and/or cytopathology ($n = 2$). In the latter 12 patients the physical and radiological abnormalities disappeared following cytotoxic treatment (Table 2, follow-up). In nine patients SS-R scintigraphy was repeated after

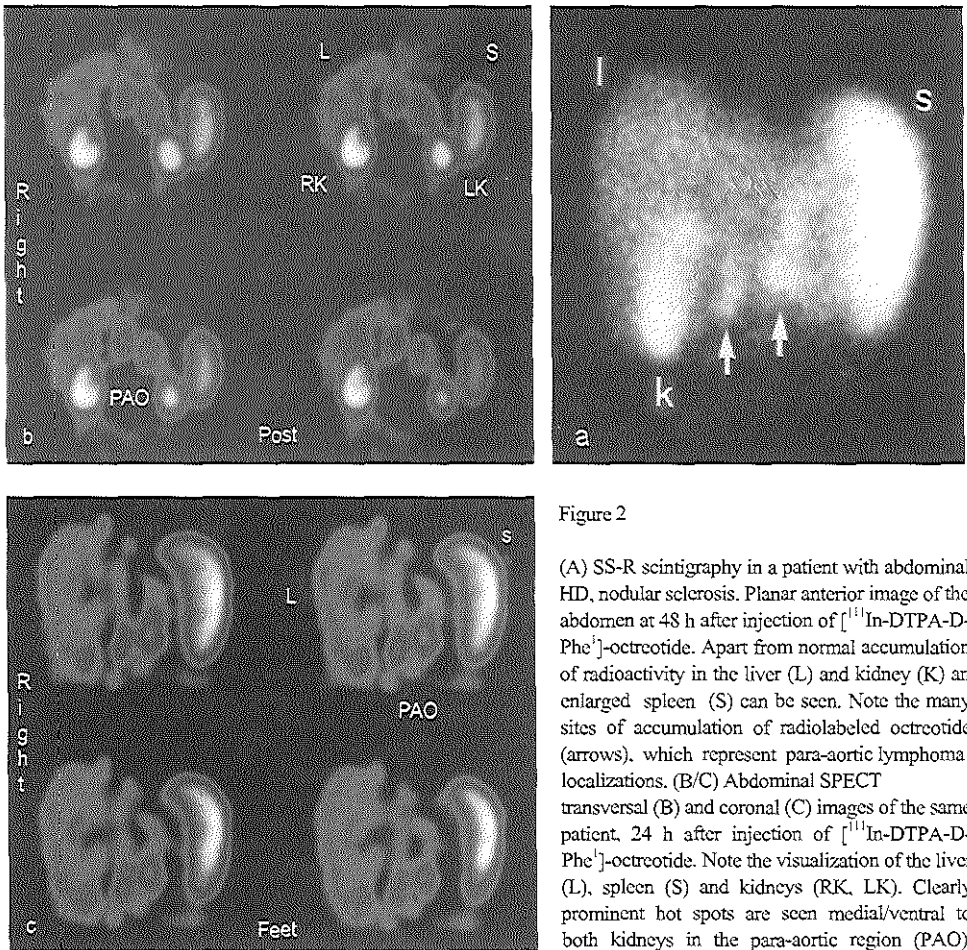


Figure 2

(A) SS-R scintigraphy in a patient with abdominal HD, nodular sclerosis. Planar anterior image of the abdomen at 48 h after injection of [^{111}In -DTPA-D-Phe 1]-octreotide. Apart from normal accumulation of radioactivity in the liver (L) and kidney (K) an enlarged spleen (S) can be seen. Note the many sites of accumulation of radiolabeled octreotide (arrows), which represent para-aortic lymphoma localizations. (B/C) Abdominal SPECT transversal (B) and coronal (C) images of the same patient, 24 h after injection of [^{111}In -DTPA-D-Phe 1]-octreotide. Note the visualization of the liver (L), spleen (S) and kidneys (RK, LK). Clearly prominent hot spots are seen medial/ventral to both kidneys in the para-aortic region (PAO).

successful chemotherapy and in all patients SS-R scintigraphy had become entirely negative (Table 2, repeated SS-R scintigraphy).

In 12 patients the discrepancies between SS-R scintigraphy and conventional staging procedures resulted in a change of Ann Arbor clinical stage. SS-R scintigraphy findings correctly upgraded the clinical stage in 11 cases and the clinical stage was correctly downgraded in one patient. As a result the treatment plan was altered in seven patients. In all seven patients the superiority of SS-R scintigraphy was supported by additional evidence.

Table 2. Additional sites of disease demonstrated following SS-R scintigraphy in 20/56 patients with HD: a comparison between SS-R scintigraphy and conventional staging methods

Pt	Additional sites of disease	Verification (+ = HD)	Repeated SS- R scintigraphy	Change clinical stage
2	Neck, para-aortic	+ CT, follow-up	ND	II → III
4	Neck	ND	ND	No
5	Neck	+ Cytology, follow-up	ND	No
6	Neck	+ Phys. exam., follow-up	ND	No
8	Neck, mediastinum	+ CT, follow-up	ND	I → II
10	Neck, lung negative	+ Phys. exam., follow-up	ND	IV → II
13	Para-aortic	+	Yes	II → III
14	Neck	ND	ND	No
17	Neck	+ Sonography, follow-up	ND	No
20	Mediastinum, axilla, lung	+	Yes	III → IV
25	Para-aortic	ND	ND	II → III
27	Infraclavicular	+ CT, follow-up	ND	I → II
28	Neck, mediastinum	+ CT, follow-up	ND	I → II
29	Neck	+	Yes	No
33	Neck, axilla, inguinal	+ Phys. exam., follow-up	Yes	No
35	Neck	+	Yes	I → II
44	Axilla	+ Phys. exam., follow-up	Yes	No
50	Para-aortic	+ CT, follow-up	Yes	II → III
52	Para-aortic	+	Yes	II → III
55	Inguinal	+ Histology, follow-up	Yes	II → III

ND, not done; Phys. exam., physical examination.

False-negative results of SS-R scintigraphy (four patients)

In four patients SS-R scintigraphy did not show localizations, which had become apparent following radiological methods (see Table 3). In patients 3, 7 and 26 enlarged abdominal para-aortic lymph nodes visualized on CT and lymphangiography were not apparent on SS-R scintigraphy images. The largest non-visualized lesion in the abdominal area had a diameter of 4.5 cm. In all three patients the enlarged para-aortic lymph nodes disappeared after treatment. In the fourth patient (no. 40), SS-R scintigraphy demonstrated a normal-sized spleen with a homogenous distribution of radioactivity, but CT and sonography showed a spleen of normal size with multiple hypodense areas, which disappeared following chemotherapy. In these four patients in whom SS-R scintigraphy missed certain localizations of HD, the clinical stage, if based on SS-R scintigraphy only, would have been underestimated in one individual.

Table 3. False-negative SS-R scintigraphy in 4/56 patients with HD: a comparison between SS-R scintigraphy and conventional staging methods

Pt	Sites of disease: conventional methods	Clinical stage: conventional methods	Sites of disease: SS-R scintigraphy	Clinical stage: SS-R scintigraphy
3	Left neck, mediastinum, lung, para-aortic	IV	Left neck, mediastinum, lung	IV
7	Left neck, mediastinum, para-aortic	III	Left neck, mediastinum	II
26	Mediastinum, para- aortic, spleen	III	Left neck, mediastinum, spleen	III
40	Mediastinum, para- aortic, left para-iliac, left inguinal, spleen	III	Mediastinum, para-aortic, left para-iliac, left inguinal	III

Spleen and abdominal lymph node involvement with HD

What about the performance of SS-R scintigraphy with regards to abdominal involvement with HD? The spleen was enlarged in seven patients according to CT and sonography. In five of these individuals multiple hypodense areas were also apparent (see Table 4). In all seven patients SS-R scintigraphy showed an enlarged spleen with a homogenous distribution of radioactivity. In an eighth patient (no. 40), where CT and sonography showed multiple hypodense areas in a normal-sized spleen, the spleen appeared normal on SS-R scintigraphy. Therefore, SS-R scintigraphy failed to demonstrate spleen involvement in one patient. Enlarged abdominal para-aortic lymph nodes were seen on CT and lymphangiography in eight patients, five of whom were also SS-R scintigraphy positive (see Table 4).

Table 4. Abdominal lymph node or spleen involvement in HD: a comparison between SS-R scintigraphy and conventional staging methods (CSM)

Sites of disease	SS-R scintigraphy = /CSM =	SS-R scintigraphy - /CSM +	SS-R scintigraphy + /CSM -
Para-aortic	5	3	5
Spleen	7	1	0
Total	12	4	5

SS-R scintigraphy, somatostatin receptor scintigraphy; CSM, conventional staging methods; SS-R scintigraphy =/CSM =: abnormalities visualized by SS-R scintigraphy and CSM; SS-R scintigraphy -/CSM +: abnormalities visualized only by CSM; SS-R scintigraphy +/CSM -: abnormalities visualized only by SS-R scintigraphy. Numbers indicate patients with para-aortic or spleen abnormalities that were evident on SS-R scintigraphy and CSM.

The smallest lymphoma within the abdomen demonstrated by SS-R scintigraphy had a diameter of approximately 2.0 cm. In five other patients para-aortic lymph nodes were visualized on SS-R scintigraphy that had not been detected on CT and lymphangiography. In three of these five patients the para-aortic SS-R positive lesions disappeared after chemotherapy. In the other two patients SS-R scintigraphy was not repeated. One patient had enlarged para-iliac lymph nodes on CT and these were also visualized by SS-R scintigraphy.

False-positive results of SS-R scintigraphy (three patients)

In three patients the positivity on SS-R scintigraphy on selected sites clearly was not related to localizations of HD (see Table 5).

Table 5. False-positive SS-R scintigraphy in 3/56 patients with HD: a comparison between SS-R scintigraphy and conventional staging methods

Pt	Sites of disease: conventional methods	Clinical stage: conventional methods	Sites of disease: SS-R scintigraphy	Reason false- positive SS-R scintigraphy
42	Right neck, left/right axilla, mediastinum	II	Right neck, left/right axilla, mediastinum, nasal region	Ethmoidal sinusitis
46	Left neck, mediastinum	II	Left neck, mediastinum, anterior iliac spine	Hematoma
49	Left/right neck, mediastinum	II	Left/right neck, mediastinum, nasal region	Common cold

In two patients accumulation of radioactivity was observed in the nasal region. A sinusitis in one patient and a common cold in the other patient had caused the positive scan. The third patient showed abnormal accumulation of radioactivity in the anterior iliac spine after a bone marrow biopsy at that site.

Further results of SS-R scintigraphy and SS-R autoradiography

In 28/55 SS-R positive patients the results of SS-R scintigraphy and conventional staging methods were concordant. The sites of disease and clinical stages are summarized in Table 6. The smallest lymph node identified by SS-R scintigraphy located in the neck had a diameter of 1.0 cm. The only patient with an entirely negative SS-R scintigraphy had stage IVB HD with lymph nodes in the axilla and an infiltrated bone marrow.

Finally, side effects were not noted in any of the patients following the administration of [¹¹¹In-DTPA-D-Phe¹]-octreotide for SS-R scintigraphy.

Table 6. Concordance between SS-R scintigraphy and conventional staging methods in 28/56 patients with HD

No. of patients	Sites of disease	Clinical stage
13	Neck, mediastinum	II
4	Neck	I
4	Neck, axilla, mediastinum	II
2	Mediastinum	I
1	Neck, bone marrow*	IV
1	Neck, axilla, mediastinum, para-aortic	III
1	Neck, mediastinum, para-aortic, spleen	III
1	Neck, mediastinum, lung	IV
1	Neck, axilla, inguinal, mediastinum, para-aortic, spleen, lung	IV

*bone marrow involvement not apparent on SS-R scintigraphy.

In three patients SS-R analysis was performed on surgically removed lymph nodes. Autoradiographic investigation confirmed the presence of specific SS-Rs in the tissue biopsies of malignant lymphoma in these individuals (Figures 3A-C). These lymph nodes were all positive *in vivo* on SS-R scintigraphy.

Discussion

The accuracy of staging is a cornerstone of the treatment of patients with HD. Clearly, current staging is still highly inadequate. For instance, stage I and II patients considered at high risk of failure are frequently treated with systemic chemotherapy. For this purpose, in stages I and II, clinical prognostic factors are employed to select between locoregional or systemic therapy. Following treatment it may be difficult to distinguish between persisting active HD or fibrotic abnormalities, e.g. in case of residual radiological mediastinal masses still apparent following chemotherapy.

In the present study we employed SS-R scintigraphy in 56 consecutive patients with histologically proven HD. Among these, 98% of the patients showed a positive SS-R scan. SS-R positive localizations were apparent at different sites of active disease above and below the diaphragm. Since the pathophysiological basis of SS-R scintigraphy staging bears no relationship with that of the other diagnostic imaging techniques, SS-R scintigraphy appears to provide an independent approach to the evaluation of the dissemination of HD. Therefore SS-R scintigraphy may add essential information to the results of the complete staging process. The discrepancies between the results of SS-R scintigraphy and conventional staging work-up as reported here support this. In only 28 patients was complete concordance apparent between SS-R scintigraphy and physical examination, X-ray examination, CT scanning and lymphangiography.

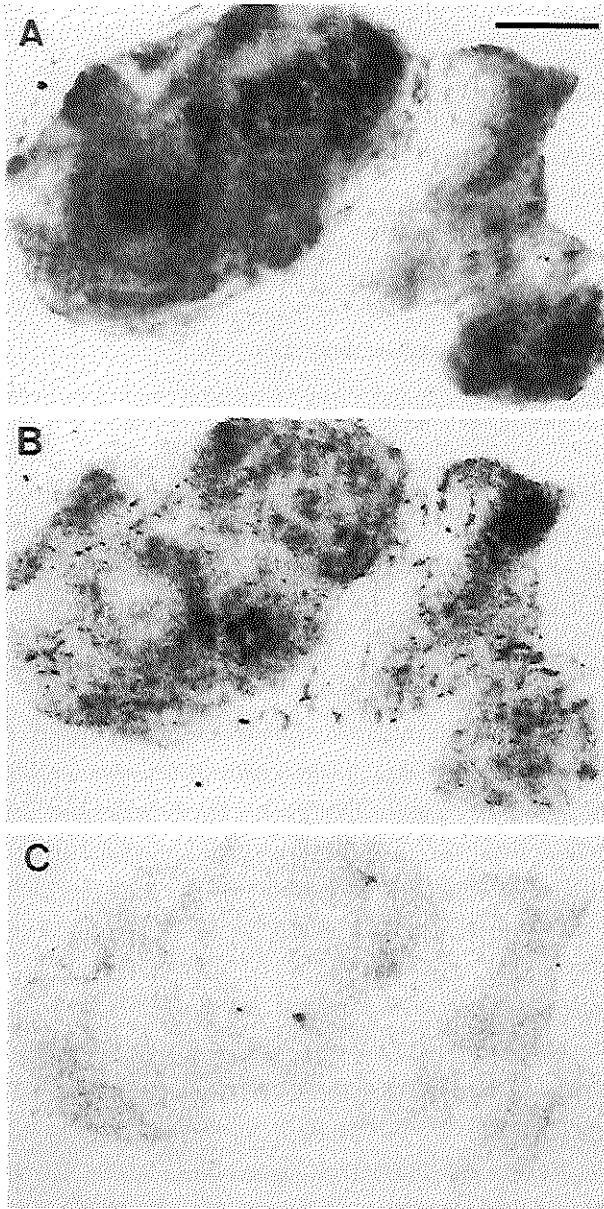


Figure 3

(A)
Somatostatin receptors in a case of Hodgkin's lymphoma. Haematoxylin-eosin-stained section. Bar = 1 mm.

(B)
Autoradiogram showing total binding of ^{125}I -[Tyr³]-octreotide.

(C)
Autoradiogram showing nonspecific binding of ^{125}I -[Tyr³]-octreotide (in presence of 10^{-6}M of unlabeled [Tyr³]-octreotide).

Autoradiography demonstrated the presence of SS-Rs in the lymphoma tissues surgically removed from three patients with HD. [^{111}In -DTPA-D-Phe¹]-octreotide and [^{125}I -Tyr³]-octreotide bind with high affinity and specificity to the same receptor (19). The identification of SS-Rs *in vitro* in biopsies from the lymph nodes with HD, confirms that the activity seen

in vivo actually represented SS-R positive tumor tissue. In patients with histologically proven HD, the tumors display SS-Rs of high enough affinity and density to apparently permit external imaging by the radiolabeled SS analog in most cases.

In 20 patients SS-R scintigraphy disclosed lesions not revealed following a variety of radiodiagnostic procedures. In most of these individuals additional investigations were undertaken in an effort to verify the diagnosis of HD at sites of discrepancy.

SS-R scintigraphy failed to demonstrate certain sites of HD in four cases and SS-R scintigraphy was entirely negative in one individual with extensive involvement of HD. In a significant proportion of cases the clinical stage as defined by conventional staging methods changed following consideration of the results of SS-R scintigraphy. In 11 cases of the entire series of 56 subjects the disease was upgraded to a higher stage. The additional information of SS-R scintigraphy resulted in a different choice of therapy in seven patients (13%).

As compared with conventional staging methods, SS-R imaging offers a number of distinct advantages. First, because the whole body is imaged, localizations in areas not under clinical suspicion can be evaluated, and therefore the full extent of the disease more accurately documented. Second, after treatment with chemo- or radiotherapy, residual or recurrent tumors of malignant lymphomas remain SS-R positive (13). SS-R scintigraphy may be potentially useful to assess remission and avoid 'over treatment' in patients in remission. SS-R scintigraphy may also be of use in the management of residual masses, including the notoriously difficult mediastinal localizations. Our preliminary experience in two patients with primary resistant HD gives some support that this may be true (data not shown). After six cycles of chemotherapy, a residual mass was seen on CT in the mediastinum in one patient and in the para-aortic region of the abdomen in the second. SS-R scintigraphy was positive in these areas in both patients. Histologic confirmation of active HD at the latter sites was obtained in both patients. We are presently investigating the role of SS-R scintigraphy in the evaluation of treatment response in patients with HD in a prospective study.

In the abdominal region SS-R scintigraphy (unlike conventional techniques) revealed para-aortic lymph nodes in five patients. A repeated SS-R scintigraphy after chemotherapy in three of these patients showed total disappearance of the lesions. In 12 cases there was complete agreement between the results of SS-R scintigraphy and conventional radiodiagnostic techniques in the detection of abdominal sites of HD. SS-R scintigraphy failed to detect abdominal HD in four patients. Para-aortic lymph nodes were missed in three patients and spleen involvement was not apparent on SS-R scintigraphy in one patient. Thus, all false-negative cases of our series were located in the abdomen. This problem was also seen in patients with carcinoid tumors where planar images of SS-R scintigraphy failed to detect some liver metastases (12). The visualization of abdominal lymphoma localizations with [^{111}In -DTPA-D-

Phe¹]-octreotide may be limited by a number of factors. The human spleen expresses high-affinity SS-Rs (23). Frequently lymphoma metastases in the spleen appear to accumulate a similar amount of radioactivity as does surrounding normal spleen tissue. After intravenous injection, [¹¹¹In-DTPA-D-Phe¹]-octreotide is rapidly cleared from the blood, predominantly excreted via the kidneys, and a minority of the isotope removed by hepatobiliary clearance (20). The hepatobiliary clearance results in hepatic and intestinal accumulation of radioactivity. The presence of intestinal radioactivity can usually be overcome by the use of laxatives. Nevertheless, in some patients radioactivity may remain in the colon and this may interfere with the detection of para-aortic lymph nodes. The physiological uptake of radioactivity in the liver, although less than in the spleen, may reduce optimal detection of liver involvement with SS-R positive tumors. Overprojection of radioactivity of the liver, spleen and kidneys can hide positive lesions in lymph nodes on the planar images. The use of SPECT images of the upper abdomen in part may overcome this problem and is therefore recommended for the localization of abnormal lymph nodes in the spleen and liver hilar areas. The same is true for the para-aortic region of the upper abdomen.

SS-R scintigraphy is not specific for visualizing tissue involved with HD. Granulomatous diseases, autoimmune diseases and neuroendocrine tumors may result in positive SS-R scintigraphy images as well (21,24). Obviously, therefore, SS-R scintigraphy cannot be used to diagnose malignant lymphoma. In this respect, SS-R scintigraphy shares the general limitations of most imaging techniques. In our study three false-positive results were seen. In two cases the positivity in the nasal region on the scan was caused by an infection; clinically, these two patients had a common cold. This transient accumulation in the nasal region during the typical season of epidemic common cold/influenza is a well-known pitfall in the correct interpretation of SS-R scintigraphy (21). The third patient showed accumulation of radioactivity in the pelvis after bone marrow biopsy. Clinically a large hematoma was apparent. Our accumulated experience in more than a thousand patients has taught us that radioactivity may accumulate at sites of recent operation.

In several centers gallium scintigraphy is used in the work-up of HD patients. Gallium scintigraphy is performed prior to therapy to provide information on the gallium avidity of the tumor at baseline. Current evidence would indicate that the sensitivity of gallium scintigraphy in the initial staging of patients with HD is in the order of 66-85% (25,26). The most important value of gallium scintigraphy is therefore not in the initial staging of patients with HD but rather in the evaluation of lymphoma after treatment (2). It would be of interest to compare SS-R scintigraphy and gallium scintigraphy in the staging of HD in future studies. In this age of financial restraint these imaging techniques should be cost-effective. In Rotterdam a prospective cost-effective study is currently in progress that includes ultrasonography, com-

puted tomography, gallium scintigraphy and SS-R scintigraphy.

In conclusion, SS-R scintigraphy provides a useful method of diagnostic evaluation of patients with HD. It is a relatively easy and harmless procedure. Obviously, further prospective studies in larger groups of patients, both pre- and post-treatment, will be needed to fully define its value and place in the management of patients with HD.

References

- 1 North LB, Jing BS. Imaging procedures. In Fuller L, ed. *Hodgkin's disease and non-Hodgkin's lymphomas in adults and children*. New York, NY: Raven 130-169, 1988
- 2 Front D, Israel O. The role of Ga-67 scintigraphy in evaluating the results of therapy in lymphoma patients. *Semin Nucl Med* 25: 60-71, 1995
- 3 Reubi JC, Heitz PU, Landolt AM. Visualization of somatostatin receptors and correlation with immunoreactive GH and PRL in human pituitary adenomas: evidence for different tumor subclasses. *J Clin Endocrinol Metab* 65: 65-73, 1987
- 4 Reubi JC, Kvols LK, Waser B, Nagorney DM, Heitz PU, Charboneau JW, Reading CC, Moertel C. Detection of somatostatin receptors in surgical and percutaneous needle biopsy samples of carcinoids and islet cell carcinomas. *Cancer Res* 50: 5959-5977, 1990
- 5 Reubi JC, Waser B, Sheppard M, Macaulay V. Somatostatin receptors are present in small-cell but not in non-small-cell primary lung carcinomas: relationship to EGF-receptors. *Int J Cancer* 45: 269-274, 1990
- 6 Reubi JC, Waser B, Foekens JA, Klijn JGM, Lamberts SWJ, Laissue J. Somatostatin receptor incidence and distribution in breast cancer using receptor autoradiography: relationship to EGF-receptors. *Int J Cancer* 46: 416-420, 1990
- 7 Van Eijck CHI, Krenning EP, Bootsma A, Yoe Oei H, van Pel R, Lindemans J, Jeekel J, Reubi JC, Lamberts SWJ. Somatostatin receptor scintigraphy in primary breast cancer. *Lancet* 343: 640-643, 1994
- 8 Reubi JC, Maurer R, Klijn JGM, Stefanko SZ, Foekens JA, Blaauw G, Blankenstein MA, Lamberts SWJ. High incidence of somatostatin receptors in human meningiomas: biochemical characterization. *J Clin Endocrinol Metab* 63: 433-438, 1986
- 9 Krenning EP, Bakker WH, Breeman WAP, Koper JW, Kooij PPM, Ausema L, Lameris JS, Reubi JC, Lamberts SWJ. Localization of endocrine-related tumours with radioiodinated analogue of somatostatin. *Lancet* 1: 242-244, 1989
- 10 Krenning EP, Kwekkeboom DJ, Lamberts SWJ, Pauwels S, Kvols L, Reubi JC. Somatostatin receptor scintigraphy. In: Freeman LM, ed. *Nuclear Medicine Annual*. New York, Raven Press 1-50, 1995

- 11 Lamberts SWJ, Bakker WH, Reubi JC, Krenning EP. Somatostatin-receptor imaging in the localization of endocrine tumors. *N Engl J Med* 323: 1246-1249, 1990
- 12 Kwekkeboom DJ, Krenning EP, Bakker WH, Yoe Oei H, Kooij PPM, Lamberts SWJ. Somatostatin analogue scintigraphy in carcinoid tumours. *Eur J Nucl Med* 20: 283-292, 1993
- 13 Reubi JC, Waser B, van Hagen M, Lamberts SWJ, Krenning EP, Gebbers JO, Laissue JA. In vitro and in vivo detection of somatostatin receptors in human malignant lymphomas. *Int J Cancer* 50: 895-900, 1992
- 14 Bares R, Galonska P, Dempke W, Handt S, Büll U, Osieka R. Somatostatin receptor scintigraphy in malignant lymphoma: first results and comparison with glucose metabolism measured by positron-emission tomography. *Horm Metab Res Suppl* 27: 56-58, 1993
- 15 Van Hagen PM, Krenning EP, Reubi JC, Mulder AH, Bakker WH, Yoe Oei H, Löwenberg B, Lamberts SWJ. Somatostatin analogue scintigraphy of malignant lymphomas. *Br J Haematol* 83: 75-79, 1993
- 16 Bong SB, VanderLaan JG, Louwes H, Schuurman JJ. Clinical experience with somatostatin receptor imaging in lymphoma. *Semin Oncol Suppl* 21: 46-50, 1994
- 17 Lipp RW, Silly H, Ranner G, Dobnig H, Passath A, Leb G, Krejs GJ. Radiolabeled octreotide for the demonstration of somatostatin receptors in malignant lymphoma and lymphadenopathy. *J Nucl Med* 36: 13-18, 1995
- 18 Carbone PP, Kaplan HS, Musshoff K, Smithers DW, Tubiana M. Report of the committee on Hodgkin's disease staging classification. *Cancer Res* 31: 1860-1861, 1971
- 19 Bakker WH, Albert R, Bruns C, Breeman WAP, Hofland LJ, Marbach P, Pless J, Koper JW, Lamberts SWJ, Visser TJ, Krenning EP. ^{111}In -[DTPA-D-Phe¹]-octreotide, a potential radiopharmaceutical for imaging of somatostatin receptor positive tumors: radiolabeling and in vitro validation. *Life Sci* 49: 1583-1591, 1991
- 20 Krenning EP, Bakker WH, Kooij PPM, Breeman WAP, Yoe Oei H, de Jong M, Reubi JC, Visser TJ, Bruns C, Kwekkeboom DJ, Reijs AEM, van Hagen PM, Koper JW, Lamberts SWJ. Somatostatin receptor scintigraphy with [^{111}In -DTPA-D-Phe¹]-octreotide in man: metabolism, dosimetry and comparison with [^{123}I -Tyr³]-octreotide. *J Nucl Med* 33: 652-658, 1992
- 21 Krenning EP, Kwekkeboom DJ, Bakker WH, Breeman WAP, Kooij PPM, Yoe Oei H, van Hagen M, Postema PTE, de Jong M, Reubi JC, Visser TJ, Reijs AEM, Hofland LJ, Koper JW, Lamberts SWJ. Somatostatin receptor scintigraphy with [^{111}In -DTPA-D-Phe¹] and [^{123}I -Tyr³]-octreotide: the Rotterdam experience with more than 1000 patients. *Eur J Nucl Med* 20: 716-731, 1993
- 22 Krenning EP, Kwekkeboom DJ, de Jong M, Visser TJ, Reubi JC, Bakker WH, Kooij PPM, Lamberts SWJ. Essentials of peptide receptor scintigraphy with emphasis on the somatostatin analog octreotide. *Semin Oncol* 21: 6-14, 1994

- 23 Reubi JC, Waser B, Horisberger U, Krenning E, Lamberts SWJ, Gebbers JO, Gersbach P, Laissue JA. In vitro autoradiographic and in vivo scintigraphic localization of somatostatin receptors in human lymphatic tissue. *Blood* 82: 2143-2151, 1993
- 24 Vanhagen PM, Krenning EP, Reubi JC, Kwekkeboom DJ, Bakker WH, Mulder AH, Laissue I, Hoogstede HC, Lamberts SWJ. Somatostatin analogue scintigraphy in granulomatous diseases. *Eur J Nucl Med* 21: 497-502, 1994
- 25 Front D, Israel O, Epelbaum R, Ben Haim S, Even-Sapir E, Jerushalmi J, Kolodny GM, Robinson E. Ga-67 SPECT before and after treatment of lymphoma. *Radiology* 175: 515-519, 1990
- 26 Hagemester FB, Fesus SM, Lamki LM, Haynie TP. Role of the gallium scan in Hodgkin's disease. *Cancer* 65: 1090-1096, 1990

CHAPTER 3

Somatostatin receptor scintigraphy in cutaneous malignant lymphomas

P.J. van den Anker-Lugtenburg¹, F. Heule², P.M. Vanhagen^{3,4}, Th. van Joost²,
H.Y. Oei⁵, B. Löwenberg¹, E.P. Krenning^{4,5}

¹Dept. of Hematology, University Hospital and Erasmus University Rotterdam

²Dept. of Dermato-Venereology, University Hospital and Erasmus University Rotterdam

³Dept. of Immunology, University Hospital and Erasmus University Rotterdam

⁴Dept. of Internal Medicine, University Hospital and Erasmus University Rotterdam

⁵Dept. of Nuclear Medicine, University Hospital and Erasmus University Rotterdam

The Netherlands

J Am Acad Dermatol 34: 985-993, 1996

Abstract

Lymphoid cells may express somatostatin receptors (SS-Rs) on their cell surface. Therefore radiolabeled somatostatin analogs may be used to visualize SS-R positive lymphoid neoplasms in vivo. Exact staging is the basis for treatment decisions in cutaneous malignant lymphoma. We considered the possibility that SS-R scintigraphy might offer a clinically useful method of diagnostic imaging in patients with cutaneous malignant lymphoma. We evaluated SS-R scintigraphy in comparison with conventional staging methods in the staging of cutaneous malignant lymphoma. We conducted a prospective study in 14 consecutive patients with histologically proven cutaneous malignant lymphoma. SS-R scintigraphy was compared with physical, radiologic, and bone marrow examinations. Lymph node excisions were performed in patients with palpable lymph nodes. SS-R scintigraphy was positive in the lymph nodes in all four patients with malignant lymph node infiltration and negative in the three patients with dermatopathic lymphadenopathy. In two patients, previously unsuspected lymphoma localizations were visualized by SS-R scintigraphy. In only three patients all skin lesions were visualized by SS-R scintigraphy; these three patients had not been treated with topical corticosteroids. SS-R scintigraphy failed to detect an adrenal mass in one patient and bone marrow infiltration in two patients. SS-R scintigraphy may help distinguish dermatopathic lymphadenopathy from malignant lymph node infiltration in patients with cutaneous malignant lymphoma.

Introduction

Primary cutaneous lymphomas represent a group of non-Hodgkin's lymphomas (NHL) with involvement of the skin. Cutaneous T-cell lymphomas (CTCLs) are more common than cutaneous B-cell lymphomas (CBCLs) (1). The most frequent type of CTCL is mycosis fungoides. Sézary syndrome occurs relatively rarely. CTCLs other than mycosis fungoides/Sézary syndrome represent approximately 30% of all CTCLs and are large-cell lymphomas with pleomorphic, immunoblastic, or anaplastic features (1). The malignant cell in mycosis fungoides and Sézary syndrome is a T lymphocyte, which expresses phenotypic and functional characteristics of helper/inducer T cells (2,3). The clinical expression of CTCL varies greatly. The disease is slowly progressive after a long initial phase and eventually may progress to involve lymph nodes, visceral organs, and peripheral blood or bone marrow (4,5).

Once the diagnosis of CTCL has been made the patient undergoes staging procedures to estimate the anatomic extent and localizations of the malignant process. The assessment of the extent is critical because the stage of disease is the most important prognostic

factor in patients with CTCL and may determine the choice of therapy (6-10). The role of diagnostic imaging in the staging of CTCL is not well established. Only a few reports describe the use of imaging modalities in the staging of CTCL (9,11-18).

Somatostatin is a peptide hormone consisting of 14 amino acids. It is present in the hypothalamus, the cerebral cortex, the brain stem, the gastrointestinal tract, and the pancreas. Somatostatin receptors (SS-Rs) have been found on normal human lymphoid tissues (19,20). High-affinity SS-Rs have been identified in NHLs with the use of in vitro receptor autoradiographic techniques (21,22). On the basis of these observations, the radiolabeled somatostatin analog [¹¹¹In-DTPA-D-Phe¹]-octreotide has been applied clinically to visualize NHLs in vivo, with no toxicity (21-24).

We describe the results of a prospective study comparing SS-R scintigraphy with conventional staging methods in 14 patients with CTCL and CBCL.

Patients and methods

Patients

Between 1991 and 1994, 14 consecutive patients with histologically proven CTCL (n = 11) and CBCL (n = 3) underwent staging evaluation. The stage of the disease was established by physical examination; whole body mapping of lesions; chest radiography; computed tomography (CT) of chest, abdomen, and pelvis; bone marrow aspiration and biopsy; and analysis of blood smears. CT scanning was performed with contiguous 10 mm axial sections after oral and intravenous administration of contrast material. Lymph node excisions were performed in patients with palpable lymph nodes.

Mycosis fungoides was staged according to a staging classification of Fuks (7,12), modified by the Dutch Cutaneous Lymphomas Working Group as follows: stage I: skin involvement only; stage II: skin and dermatopathic lymphadenopathy; stage III: skin and pathologic lymph nodes; stage IV: skin and visceral organ involvement. Every stage was subdivided into (a) limited plaques <10%, (b) generalized plaques >10%, (c) cutaneous tumors, and (d) generalized erythroderma.

The study had been approved by the Ethics Committee of the University Hospital Rotterdam.

Scintigraphy

SS-R scintigraphy was performed after intravenous injection of the radioactive-labeled somatostatin analog [¹¹¹In-DTPA-D-Phe¹]-octreotide (Mallinckrodt Medical BV, Petten, The Netherlands). The preparation of [¹¹¹In-DTPA-D-Phe¹]-octreotide, the dose administered (≥ 200 MBq), and the technique of scintigraphy with the gamma camera, as

well as with single photon emission computed tomography (SPECT) have recently been described (23,25). Planar total body scintigraphy was performed 24 h after injection with a large-field-of-view gamma camera (Counterbalance 3700 and ROTA II; Siemens Gammasonics, Erlangen, Germany) equipped with a medium-energy collimator. Repeated scintigrams were performed 48 h after injection when accumulation of radioactivity in the abdomen was observed on the 24-h scintigrams. In all patients SPECT images of the upper abdomen were made. In normal persons a physiologic accumulation of radioactivity may be seen in the pituitary and thyroid glands, liver, spleen, kidneys, urinary bladder, and occasionally in the gallbladder. The presence of intestinal radioactivity (mainly in the colon at 24 h) is caused by some hepatobiliary clearance of [^{111}In -DTPA-D-Phe 1]-octreotide and can be reduced by the use of laxatives (25,26). The scans were evaluated by two investigators (EPK and HYO) who did not know the identity of the patients or the results of the conventional staging procedures. Finally the results of SS-R scintigraphy and conventional diagnostic tests were compared by the study coordinator (PJvdAL). In case of discrepancies additional radiodiagnostic investigations were scheduled, and if practical and possible, histologic verification was attempted. All patients were observed during and after treatment. In three patients SS-R scintigraphy was repeated during follow-up.

Results

The clinical characteristics of the 14 patients with CTCL ($n = 11$) and CBCL ($n = 3$) in whom SS-R scintigraphy was performed are given in Table 1. Ten of 14 patients had been treated for long periods with topical corticosteroids.

Patients with CTCL

SS-R scintigraphy was positive in 5 of 11 patients with CTCL. The results of the comparison between the sites of disease demonstrated by SS-R scintigraphy and the conventional staging methods are summarized in Table 1.

Skin evaluation

CTCL was limited to the skin in 6 of 11 patients. In five of these six patients (i.e., two patients with pleomorphic CTCL [patients 1 and 2] and three patients with mycosis fungoides [patients 5, 6, and 11]), SS-R scintigraphy was negative. The skin lesions in these patients were macules or plaques. Patient 3 initially had limited plaques of 0.5 to 10 cm diameter on multiple sites of the skin. Only one of these lesions was visualized on SS-R scintigraphy.

Table 1. Clinical characteristics and comparison between somatostatin receptor scintigraphy and conventional staging methods in 14 patients with cutaneous malignant lymphoma

Pt no.	Sex/ Age (yr)	Diagnosis	Time between diagnosis and entry into study (mo)	Time after first symptoms (yr)	Previous treatment	Stage *	Disease sites by conventional methods	Disease sites by SS-R scintigraphy
1	F/67	CTCL: pleomorphic, medium/large	1	4.0	TC		Skin: macules on total skin and urticaria	Skin negative
2	F/84	CTCL: pleomorphic, small/medium	1	0.3	None		Skin: ulcers and plaques, erythema on legs	Skin negative
3	M/52	CTCL: pleomorphic, medium/large	2	2.0	PUVA TC		Skin: limited plaques DLA (axilla, inguinal)	Skin positive (only arm) DLA negative
4	M/58	CTCL: pleomorphic, medium/large	1	1.5	TC		Skin: erythroderma Lymph nodes (axilla, inguinal)	Skin negative Lymph nodes positive
5	F/54	CTCL: MF	1	8.0	TC	Ia	Skin: plaques	Skin negative
6	M/67	CTCL: MF	1	7.0	TC	Ib	Skin: plaques	Skin negative

7	M/66	CTCL: MF	45	9.0	TC UVB	IVb	Skin: ulcers and plaques DLA (neck, axilla, inguinal)	Skin negative DLA negative Synovia positive
8	F/61	CTCL: Sézary syndrome	1	5.5	TC		Skin: erythroderma Lymph nodes (inguinal) BM	Skin negative Lymph nodes positive BM negative
9	M/67	CTCL: MF	1	0.8	None	IVc	Skin: tumors Lymph nodes (inguinal) Adrenal region	Skin positive Lymph nodes positive Adrenal region negative
10	M/71	CTCL: MF	1	20	TC [†]	IId	Skin: erythroderma DLA (axilla, inguinal)	Skin negative DLA negative
11	F/58	CTCL: MF	1	1.0	TC	Ib	Skin: macules	Skin negative
12	F/76	CBCL	1	0.7	None		Skin: ulcers on leg and hips	Skin positive Mediastinum positive
13	M/67	CBCL	2	0.4	None [†]		Skin: nodule on neck	Skin positive
14	F/74	CBCL	2	1.0	TC, ILC		Skin: plaques around eye	Skin negative

BM, bone marrow; CBCL, cutaneous B-cell lymphoma; CTCL, cutaneous T-cell lymphoma; DLA, dermatopathic lymphadenopathy; F, female; ILC, intralesional corticosteroid; M, male; MF, mycosis fungoides; TC, topical corticosteroid; *staging according to the Dutch Cutaneous Lymphomas Working Group (modified from Fuks) (7,12); [†]concomitant disease actinic reticuloid treated with prednisone; [‡]concomitant disease dermatitis herpetiformis treated with dapson.

Five of 11 patients had CTCL in a more advanced stage. In only one of these patients were the skin lesions shown by SS-R scintigraphy. This patient (No. 9) had multiple, sharply margined, erythematous tumors on the skin of the face and back (Figure 1).

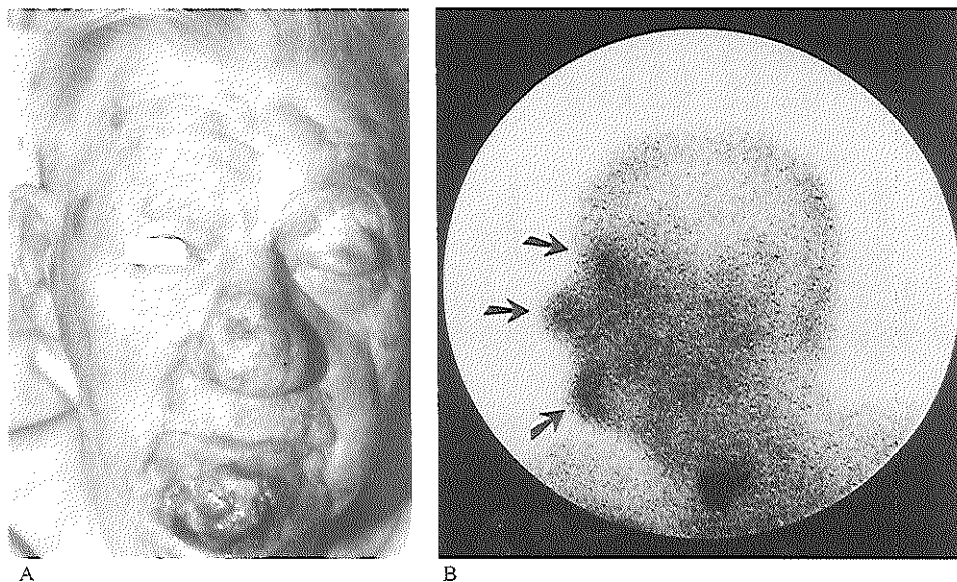


Figure 1

(A) Patient with mycosis fungoides, multiple tumors on face. (B) Same patient, left lateral planar view of head and neck. Normal accumulation of radioactivity in the thyroid. Skin tumors clearly visualized (arrows).

Lymph node evaluation

The results of physical examination, CT scanning, and SS-R scintigraphy in relation to lymph node histology are summarized in Table 2. In six patients, diseased lymph nodes of 1.5 to 3 cm in diameter were palpable at physical examination. Five of these patients had generalized lymphadenopathy. These enlarged lymph nodes were all apparent on CT scan. In three patients SS-R scintigraphy was negative in the lymph node areas (patients 3, 7, and 10). Lymph node excisional biopsy specimens in these three patients showed dermatopathic lymphadenopathy. SS-R scintigraphy was positive in the lymph node areas in the other three patients (patients 4, 8, and 9; Figure 2). The lymph node excisional biopsy specimens in these three patients confirmed the involvement of malignant lymphoma. The sensitivity and specificity of the CT scan for malignant lymph node infiltration were 100% and 67%, respectively. The sensitivity and specificity of SS-R scintigraphy for malignant lymph node infiltration were 100% and 100%, respectively.

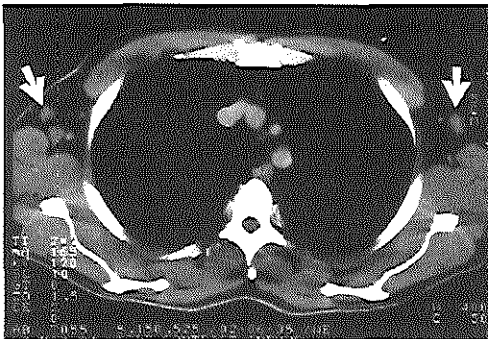In the 14 patients no lymphadenopathy in the thorax or abdomen was seen on CT scans of chest, abdomen, and pelvis or by SS-R scintigraphy.

Table 2. Results of physical examination, CT scan, and SS-R scintigraphy in relation with lymph node histologic findings in 14 patients with cutaneous malignant lymphoma

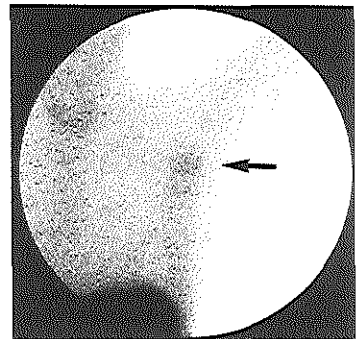
Patient no.	Physical examination lymph node diameter (cm)	CT scan lymph node diameter (cm)	SS-R scintigraphy lymph node areas	Lymph node histologic findings
1	3	3	Positive*	Malignant infiltration
2	Negative	Negative	Negative	ND
3	1.5	2	Negative	Dermatopathic lymphadenopathy
4	2-3	2-3	Positive	Malignant infiltration
5	Negative	Negative	Negative	ND
6	Negative	ND	Negative	ND
7	2	1.5-2	Negative	Dermatopathic lymphadenopathy
8	2-4	2-4	Positive	Malignant infiltration
9	2	1.8	Positive	Malignant infiltration
10	3	3	Negative	Dermatopathic lymphadenopathy
11	Negative	Negative	Negative	ND
12	Negative	Negative	Negative	ND
13	Negative	Negative	Negative	ND
14	Negative	Negative	Negative	ND

CT, computed tomography; ND, not done; SS-R, somatostatin receptor

*Result of SS-R scan during follow-up.



A



B

Figure 2

(A) CT scan of the thorax of patient with pleomorphic CTCL shows multiple enlarged lymph nodes (1.5 to 2 cm in diameter) in the axillary regions (arrows). Lymph node excision biopsy specimen showed malignant lymphoma infiltration. (B) Same patient, anterior planar thoracic image. Normal accumulation of radioactivity in the thyroid and spleen; abnormal accumulation in the axilla (arrow).

Organ evaluation

Dissemination of CTCL to visceral organs or bone marrow was seen in three patients. Patient 7 had a seronegative arthropathy affecting the hands and wrists. SS-R scintigraphy was positive in multiple joints (hands, wrists, elbows, knees, and ankles). A synovial biopsy specimen showed an infiltrate of lymphocytes (exclusively T lymphocytes) and plasma cells in a reactive pattern. T-cell receptor gene rearrangement analysis was performed on skin and synovial specimens, and identical clonal T-cell populations were detected in both (data not shown). Bone marrow infiltration with Sézary cells (15%) was seen in patient 8 but was not apparent on SS-R scintigraphy. CT scanning demonstrated a large adrenal mass (5 to 7 cm) in patient 9. Cytologic examination of a needle aspiration specimen of the adrenal mass confirmed infiltration with CTCL. SS-R scintigraphy was negative in this area.

SS-R scintigraphy during follow-up

In three patients with pleomorphic CTCL, SS-R scintigraphy was repeated during follow-up. Patient 1, with initially negative SS-R scanning, was treated with PUVA therapy. Sixteen months later progressive skin disease had developed as well as lymph node and bone marrow infiltration with CTCL. SS-R scintigraphy was positive in the peripheral lymph node areas, but remained negative in the skin and bone marrow. In patient 2 a complete remission was reached after CHOP chemotherapy. Eleven months later the skin disease recurred (ulcers and plaques). SS-R scintigraphy was again entirely negative. The skin disease in patient 3, originally showing positivity on SS-R scintigraphy, recurred (tumors at multiple sites) 8 months after PUVA therapy and local radiotherapy. On SS-R scintigraphy some skin lesions were positive and some were negative. The patient did not respond to different types of chemotherapy and local radiotherapy. SS-R scintigraphy performed a third time revealed all active skin lesions (tumors).

Patients with CBCL

SS-R scintigraphy was positive in two of three patients with CBCL (Table 1). The skin lesions were visualized by SS-R scintigraphy in two patients. In patient 12, SS-R scintigraphy also revealed a previously unsuspected localization in the mediastinum (Figure 3A). On roentgenography and CT of the thorax (Figure 3B) no abnormalities were seen. However, this patient had radiologic evidence of mediastinal lymphoma 6 months later. Mediastinal lymphoma involvement with pericardial infiltration was confirmed at autopsy. In patient 13 the accumulation of radioactivity in the neck

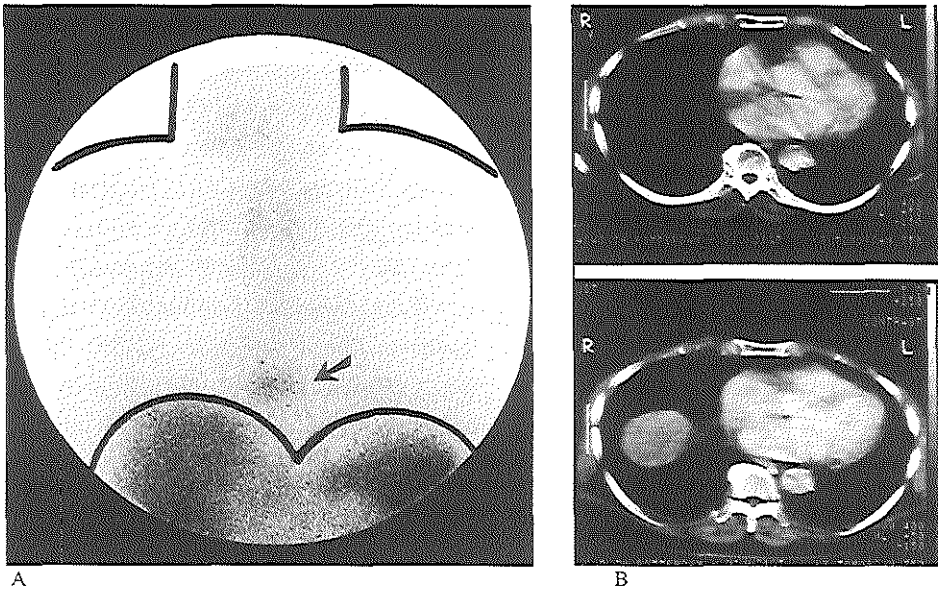


Figure 3

(A) Anterior thoracic planar image in patient with CBCL revealed previously unsuspected lymphoma in mediastinum (arrow). Normal uptake of labeled octreotide is seen in the thyroid, liver and spleen. (B) Same patient, CT scan of the thorax, no abnormalities were seen.

corresponded to a clinically evident skin nodule (2 cm) in the neck. SS-R scintigraphy was entirely negative in the third patient.

Side effects were not noted in any of the patients after the administration of [^{111}In -DTPA-D-Phe 1]-octreotide for SS-R scintigraphy.

Discussion

The prognosis and treatment of patients with CTCL depend on accurate staging. The staging system for CTCL considers the extent of skin involvement, presence of lymph node or visceral disease, and detection of abnormal cells in the peripheral blood. In autopsy series, more than 70% of patients with CTCL have extracutaneous lesions that may involve nearly any organ (6,27,28). Despite the high incidence of extracutaneous CTCL found at autopsy, clinically overt extracutaneous disease, other than that involving peripheral lymph nodes and blood, is uncommon.

In the present study, we employed SS-R scintigraphy in 11 patients with histologically proven CTCL and three patients with CBCL. Among these, eight showed a positive SS-R

scan. SS-R positive localizations were apparent at different sites of active disease in the skin and in extracutaneous disease.

Extracutaneous disease in CTCL is frequently found in lymph nodes. Histologic interpretation of lymph nodes in CTCL is sometimes difficult. Unlike the nodes in B-cell lymphomas, most often the nodal architecture is preserved and lymph nodes are rarely totally replaced by malignant T cells. Furthermore, patients with CTCL frequently have benign reactive lymphadenopathy or dermatopathic lymphadenopathy. In dermatopathic lymphadenopathy the paracortical T-cell zones may contain focal accumulations of atypical convoluted T lymphocytes. Southern blot analysis of the T-cell receptor gene has provided evidence of CTCL infiltration in dermatopathic lymph nodes (29,30). Patients with malignant lymph nodes tend to have a shorter survival than patients with dermatopathic lymphadenopathy (9,31). If malignant lymph node infiltration is apparent, patients are usually treated with systemic chemotherapy. This is in contrast to patients with dermatopathic lymphadenopathy to whom chemotherapy is less commonly given. Therefore it is common practice to perform lymph node excisions in patients with CTCL and peripheral enlarged lymph nodes. In our study seven patients initially had or later developed enlarged palpable axillary or inguinal lymph nodes. SS-R scintigraphy was positive in all four of these seven patients with malignant lymph node infiltration. All infiltrated lymph nodes were visualized by SS-R scintigraphy. The lymph node areas were negative on SS-R scintigraphy in the three patients with dermatopathic lymphadenopathy. CT does not allow differentiation between enlarged peripheral lymph nodes with histologic evidence of CTCL and nodes demonstrating dermatopathic lymphadenopathy. Although our series of patients is small, the results would suggest that in contrast to other imaging modalities SS-R scintigraphy may differentiate between malignant lymph node infiltration and dermatopathic lymphadenopathy in patients with CTCL. In patients with enlarged lymph nodes, a surgical lymph node excision might perhaps be avoided on the basis of SS-R scintigraphy results.

Another possible advantage of SS-R scintigraphy is that the whole body is imaged, so that localizations not under clinical suspicion can be evaluated. In two patients, previously unsuspected lymphoma localizations were revealed by SS-R scintigraphy, that is, in the mediastinum and multiple joints. Although in patient 7 only reactive T lymphocytes were seen in the synovial specimen, clonality of these T lymphocytes was demonstrated by T-cell receptor gene rearrangement analysis. By analogy with the demonstration of clonal T-cell lymphocytic infiltration in dermatopathic lymphadenopathy (29,30), the presence of clonal T lymphocytes alone in the synovia,

although not sufficient for the diagnosis of malignant infiltration with CTCL, is highly suggestive of the (pre)malignant character of the infiltrate.

On the other hand, SS-R scintigraphy failed to detect an adrenal mass and bone marrow infiltration. The adrenal mass may not have been detected by SS-R scintigraphy because of the physiologic uptake of the radioligand in the kidneys. This might have interfered with the detection of adrenal involvement, despite the use of SPECT. The reason that bone marrow infiltration was not revealed by SS-R scintigraphy is unclear. A locally low density of receptors and unknown local factors may be involved.

At first sight, SS-R scintigraphy appears of minor value in the confirmation of early skin disease in CTCL. The skin lesions were visualized in only two patients. In both patients the skin disease was in the tumor stage. Skin tumors usually develop at later stages. Only one of several plaques was detected by SS-R scintigraphy in patient 3. This skin lesion was the presenting lesion several years before mycosis fungoides was diagnosed. In the other patients no accumulation of radioactivity was seen in the plaques. We can only speculate as to the reason SS-R scintigraphy failed to visualize these thin lesions. One explanation might be that most of the patients had been treated for long periods with topical corticosteroids. Except for patient 3 in whom only one of several lesions was visualized by SS-R scintigraphy, none of the three other patients in whom the skin lesions were visualized had been treated with topical corticosteroids. The topical administration of corticosteroids might have influenced the SS-R expression on the tumor cells. Long-term exposure of rat pituitary tumor cells to glucocorticoids has been demonstrated to result in downregulation of somatostatin binding because of a decrease in the number of SS-Rs per cell (32). Dexamethasone treatment reduced the number of SS-Rs 2.5-fold in a rat pancreatic carcinoma cell line (33).

SS-R scintigraphy is not specific for visualizing tissues infiltrated with malignant lymphomas. Neuroendocrine tumors, granulomatous diseases, and autoimmune diseases may be visualized by SS-R scintigraphy as well (23). However, no false-positive results were seen in this study.

SS-R scintigraphy not only indicates the sites of involvement of a malignant process, but it also gives information on the expression of SS-Rs. Modest activity of somatostatin as a single agent has been demonstrated by Witzig et al (34) in low-grade NHL and CTCL. SS-R scintigraphy was not performed before or after treatment. It is tempting to postulate that patients who have tumors that are shown by SS-R scintigraphy will be most likely to respond to therapy with somatostatin or to radiotherapy with a somatostatin analog coupled to a β -emitting radionuclide.

SS-R scintigraphy appears to provide an independent approach to the evaluation of dissemination of CTCL and CBCL. Although further studies are necessary in a larger group of patients before definite conclusions can be made, our results suggest that SS-R scintigraphy may be able to distinguish dermatopathic lymphadenopathy from malignant lymph node infiltration in certain patients with CTCL and be useful in a complete staging work-up of patients with cutaneous malignant lymphomas.

References

- 1 Willemze R, Beljaards RC, Meijer CJLM. Classification of primary cutaneous T-cell lymphomas. *Histopathology* 24: 405-415, 1994
- 2 Broder S, Edelson RL, Lutzner MA, Nelson DL, MacDermott RP, Durm ME, Goldman CK, Meade BD, Waldmann TA. The Sézary syndrome: a malignant proliferation of helper T cells. *J Clin Invest* 58: 1297-1306, 1976
- 3 Kung PC, Berger CL, Goldstein G, LoGerfo P, Edelson RL. Cutaneous T cell lymphoma: characterization by monoclonal antibodies. *Blood* 57: 261-266, 1981
- 4 Bunn PA, Poesz BJ. Cutaneous T-cell lymphomas (mycosis fungoides and Sézary syndrome). In: Williams WJ, Beutler E, Erslev AJ, eds. *Hematology*. New York: McGraw-Hill, 1056-1066, 1983
- 5 Edelson RL. Cutaneous T cell lymphoma: mycosis fungoides, Sézary syndrome, and other variants. *J Am Acad Dermatol* 2: 89-106, 1980
- 6 Epstein EH, Levin DL, Croft JD Jr, Lutzner MA. Mycosis fungoides: survival, prognostic features, response to therapy and autopsy findings. *Medicine (Baltimore)* 51: 61-72, 1972
- 7 Fuks ZY, Bagshaw MA, Farber EM. Prognostic signs and the management of the mycosis fungoides. *Cancer* 32: 1385-1395, 1973
- 8 Levi JA, Wiernik PH. Management of mycosis fungoides, current status and future prospects. *Medicine (Baltimore)* 54: 73-78, 1975
- 9 Bunn PA Jr, Huberman MS, Whang-Peng J, Schechter GP, Guccion JG, Matthews MJ, Gazar AF, Dunnick NR, Fischmann AB, Ihde DC, Cohen MH, Fossieck B, Minna JD. Prospective staging evaluation of patients with cutaneous T-cell lymphomas: demonstration of a high frequency of extracutaneous dissemination. *Ann Intern Med* 93: 223-230, 1980
- 10 Green SB, Byar DP, Lamberg SI. Prognostic variables in mycosis fungoides. *Cancer* 47: 2671-2677, 1981
- 11 Fuks ZY, Castellino RA, Carmel JA, Farber EM, Bagshaw MA. Lymphography in mycosis fungoides. *Cancer* 34: 106-112, 1974

- 12 Hamminga L, Mulder JD, Evans C. Staging lymphography with respect to lymph node histology, treatment, and follow-up in patients with mycosis fungoides. *Cancer* 47: 692-697, 1981
- 13 Rosen ST, Gore R, Brennan J, Gordon LI, Variakojis D, Rosenbaum MM, Caro W, Roenigk HJ. Evaluation of computed tomography and radionuclide scanning in the staging of cutaneous T-cell lymphoma. *Arch Dermatol* 122: 884-886, 1986
- 14 Escovitz ES, Soulen RL, Van Scott EJ, Kalmanson JD, Barry WE. Mycosis fungoides: a lymphographic assessment. *Radiology* 112: 23-27, 1974
- 15 Shaperoo LG, Young SW. Mycosis fungoides: manifestations on computed tomography. *Radiology* 148: 202, 1983
- 16 Kulin PA, Marglin SI, Shuman WP, Chew DE, Olerud JE. Diagnostic imaging in the initial staging of mycosis fungoides and Sézary syndrome. *Arch Dermatol* 126: 914-918, 1990
- 17 Miketic LM, Chambers TP, Lembersky BC. Cutaneous T-cell lymphoma: value of CT in staging and determining prognosis. *Am J Roentgenol* 160: 1129-1132, 1993
- 18 Bass JC, Korobkin MT, Cooper KD, Kane NM, Platt JF. Cutaneous T-cell lymphoma: CT in evaluation and staging. *Radiology* 186: 273-278, 1993
- 19 Reubi JC, Waser B, Horisberger U, Krenning E, Lamberts SWJ, Gebbers JO, Gersbach P, Laissue JA. In vitro autoradiographic and in vivo scintigraphic localization of somatostatin receptors in human lymphatic tissue. *Blood* 82: 2143-2151, 1993
- 20 Reubi JC, Horisberger U, Waser B, Gebbers JO, Laissue J. Preferential location of somatostatin receptors in germinal centers of human gut lymphoid tissue. *Gastroenterology* 103: 1207-1214, 1992
- 21 Reubi JC, Waser B, van Hagen PM, Lamberts SWJ, Krenning EP, Gebbers JO, Laissue JA. In vitro and in vivo detection of somatostatin receptors in human malignant lymphomas. *Int J Cancer* 50: 895-900, 1992
- 22 Van Hagen PM, Krenning EP, Reubi JC, Mulder AH, Bakker WH, Oei HY, Löwenberg B, Lamberts SWJ. Somatostatin analogue scintigraphy of malignant lymphomas. *Br J Haematol* 83: 75-79, 1993
- 23 Krenning EP, Kwekkeboom DJ, Bakker WH, Breeman WAP, Kooij PPM, Oei HY, van Hagen M, Postema PTE, de Jong M, Reubi JC, Visser T, Reijs AEM, Hofland LJ, Koper JW, Lamberts SWJ. Somatostatin receptor scintigraphy with [¹¹¹In-DTPA-D-Phe¹] and [¹²³I-Tyr³]-octreotide: the Rotterdam experience with more than 1000 patients. *Eur J Nucl Med* 20: 716-731, 1993
- 24 Lipp RW, Silly H, Ranner G, Dobnig H, Passath A, Leb G, Krejs GJ. Radiolabeled octreotide for the demonstration of somatostatin receptors in malignant lymphoma and lymphadenopathy. *J Nucl Med* 36: 13-18, 1995

- 25 Krenning EP, Bakker WH, Kooij PPM, Breeman WAP, Oei HY, de Jong M, Reubi JC, Visser TJ, Bruns C, Kwekkeboom DJ, Reijs AEM, van Hagen PM, Koper JW, Lamberts SWJ. Somatostatin receptor scintigraphy with [¹¹¹In-DTPA-D-Phe¹]-octreotide in man: metabolism, dosimetry, and comparison with [¹²³I-Tyr³]-octreotide. *J Nucl Med* 33: 652-658, 1992
- 26 Bakker WH, Albert R, Bruns C, Breeman WAP, Hofland LJ, Marbach P, Pless J, Koper JW, Lamberts SWJ, Visser TJ, Krenning EP. [¹¹¹In-DTPA-D-Phe¹]-octreotide, a potential radiopharmaceutical for imaging of somatostatin receptor positive tumors: radiolabeling and in vitro validation. *Life Sci* 49: 1583-1591, 1991
- 27 Rappaport H, Thomas LB. Mycosis fungoides: the pathology of extracutaneous involvement. *Cancer* 34: 1198-1229, 1974
- 28 Long JC, Mihm M. Mycosis fungoides with extracutaneous dissemination: a clinical pathologic entity. *Cancer* 34: 1745-1755, 1974
- 29 Weiss LM, Hu E, Wood GS, Moulds C, Cleary ML, Warnke R, Sklar J. Clonal rearrangements of T-cell receptor genes in mycosis fungoides and dermatopathic adenopathy. *N Engl J Med* 313: 539-544, 1985
- 30 Whittaker SJ, Smith NP, Jones RR, Luzzatto L. Analysis of beta, gamma, and delta T-cell receptor genes in mycosis fungoides and Sézary syndrome. *Cancer* 68: 1572-1582, 1991
- 31 Scheffer G, Meijer CJLM, van Vloten WA. Dermatopathic lymphadenopathy and lymph node involvement in mycosis fungoides. *Cancer* 45: 137-148, 1980
- 32 Schonbrunn A. Glucocorticoids down-regulate somatostatin receptors on pituitary cells in culture. *Endocrinology* 110: 1147-1154, 1982
- 33 Viguerie N, Estève JP, Susini C. Dexamethasone effects on somatostatin receptors in pancreatic acinar AR4-2J cells. *Biochem Biophys Res Commun* 147: 942-948, 1987
- 34 Witzig TE, Letendre L, Gerstner J, Schroeder G, Mailliard JA, Colon-Otero G, Marschke RF, Windschitl HE. Evaluation of a somatostatin analog in the treatment of lymphoproliferative disorders: results of a phase II North Central Cancer Treatment Group Trial. *J Clin Oncol* 13: 2012-2015, 1995

CHAPTER 4

Somatostatin receptor scintigraphy useful in stage I-II Hodgkin's disease: more extended disease identified

P.J. Lugtenburg^{1,6}, E.P. Krenning^{2,3}, R. Valkema², H.Y. Oei², S.W.J. Lamberts³,
M.J.C. Eijkemans⁴, W.L.J. van Putten⁵, B. Löwenberg^{1,6}

¹Dept. of Hematology, University Hospital and Erasmus University Rotterdam

²Dept. of Nuclear Medicine, University Hospital and Erasmus University Rotterdam

³Dept. of Internal Medicine, University Hospital and Erasmus University Rotterdam

⁴Dept. of Public Health, Erasmus University Rotterdam

⁵Dept. of Statistics, University Hospital and Erasmus University Rotterdam

⁶Dept. of Hematology, Daniel den Hoed Cancer Center, Rotterdam

The Netherlands

Br J Haematol 112: 936-944, 2001

Abstract

Somatostatin receptor (SS-R) scintigraphy successfully shows primary cancers and metastases in patients with a variety of SS-R positive tumors. *In vitro* studies have shown that SS-Rs are present in lymph nodes from patients with Hodgkin's disease (HD). We performed a prospective study in 126 newly diagnosed patients with HD and compared the results of SS-R scintigraphy with conventional staging procedures, i.e. physical examination, computerized tomography (CT) scanning and other imaging techniques. We report positive scintigraphy in all patients. The lesion-related sensitivity was 94% and varied from 98% for supradiaphragmatic lesions to 67% for infradiaphragmatic lesions. In comparison with CT scanning and ultrasonography, SS-R scintigraphy provided superior results for the detection of Hodgkin's localizations above the diaphragm. In the intra-abdominal region, the CT scan was more sensitive than the SS-R scan. A false-positive scan was rarely seen. In stages I and II supradiaphragmatic HD patients, SS-R scintigraphy detected more advanced disease in 18% (15 out of 83) of patients, resulting in an upstaging to stage III or IV, thus directly influencing patient management. Our data would support the validity of SS-R scanning as a powerful imaging technique for the staging of patients with HD.

Introduction

Limited stage and disseminated Hodgkin's disease (HD) have different outcomes and require different treatment. Patients with limited disease (stages I and II) may be cured using regional radiotherapy. However, in approximately 30% of cases, relapses occur (1). These patients usually relapse in previously non-irradiated sites (2,3). Therefore, in patients with limited disease, prognostic factors are now used to identify patients at high risk of relapse if treated with local (radio)therapy alone (3,4). Advanced disease (stages III and IV) is treated with systemic chemotherapy (5). HD is nowadays curable in most patients (5,6).

Diagnostic radiology is one of the cornerstones for assessing the extent of the disease. Imaging studies that are commonly used include conventional frontal and lateral chest radiographs, computerized tomography (CT) scanning, ultrasonography and magnetic resonance imaging (MRI). CT or MRI have definite shortcomings. For instance, they do not distinguish inactive disease or scar tissue from viable tumor tissue. Diagnosis of possible nodal tumor involvement is typically based on detection of lymph nodes > 1.0 cm in short-axis measurements. However, smaller nodes of less than 1.0 cm may also harbor malignant lymphoma, while larger lymph nodes may be benign. In HD, about 10% of involved nodes are normal in size and will therefore not be detected by CT (7). There

is an apparent need for further improvement of current methods as well as for the development of new imaging techniques. Nuclear medicine studies may offer valuable complementary information.

Somatostatin (SS) is a peptide hormone existing in two different forms, containing 14 or 28 amino acids (8,9). SS binds to specific SS receptors (SS-Rs). Five distinct subtypes of human SS-Rs have been cloned (hSSTR 1-5), all with high affinity binding characteristics for SS-14 and SS-28 (10). A wide variety of human malignancies express SS-Rs (11). We previously demonstrated the presence of SS-Rs in lymph nodes with HD using *in vitro* SS-R autoradiography (12,13). The presence of SS-Rs on malignant cells of lymphoid origin allows *in vivo* visualization of sites of HD. The ¹¹¹Indium-labeled SS analog DTPA-D-Phe¹- octreotide (pentetreotide, OctreoScan) has been conveniently used to visualize SS-R bearing tumors (11). We have previously reported on the clinical value of SS-R scintigraphy in an initial study in 56 patients with HD (13). Several other groups have investigated the clinical significance of SS-R scintigraphy in the staging of HD (14-20), but these studies were based upon relatively small (less than 15) numbers of patients. Here we report the results of a prospectively designed study using SS-R scintigraphy for the staging of HD in 126 newly diagnosed patients, in which the value of SS-R scintigraphy was compared with the conventional work-up.

Patients and methods

Patients

One hundred and twenty-six consecutive, newly diagnosed and previously untreated patients with histologically proven HD were enrolled in a prospective study. The stage of the disease according to the Ann Arbor classification (21) was established using conventional methods which always included a physical examination, chest radiography and CT scanning of chest, abdomen and pelvis, and sometimes also ultrasonography of the neck and/or abdomen or a lymphangiography. The diagnosis of bone marrow involvement was always verified following cytological and histopathological examination of a marrow aspirate and biopsy. CT scanning was performed with contiguous 10 mm axial sections after oral and intravenous administration of contrast material. All patients had given informed consent to the study, which had been approved by the ethics committee of the University Hospital Rotterdam.

On the basis of clinical prognostic factors, two subgroups of patients with supradiaphragmatic HD were identified consisting of patients with a favorable and an unfavorable prognosis [according to criteria of the European Organization for Research and Treatment of Cancer (EORTC) lymphoma collaborative group (3)]. Patients were

classified as unfavorable if they were either aged ≥ 50 years or had an erythrocyte sedimentation rate (ESR) ≥ 30 mm (with B symptoms: weight loss, fever, night sweats), an ESR ≥ 50 mm (with absence of B symptoms), four or more different nodal areas involved or a mediastinum/thorax ratio ≥ 0.35 . All other patients were considered favorable.

SS-R scintigraphy

The maximum interval between conventional staging procedures and SS-R scintigraphy was 3 weeks. All examinations were completed before initiation of therapy.

Patients were injected intravenously with 220 MBq ^{111}In -labeled pentetreotide (OctreoScan, Mallinckrodt Medical BV, Petten, The Netherlands). Planar total body scintigraphy was performed 24 h after injection with a large-field-of-view gamma camera (Counterbalance 3700 and ROTA II; Siemens Gammasonics, Erlangen, Germany) equipped with a medium-energy collimator. Repeated scintigrams were performed 48 h after injection when accumulation of radioactivity in the abdomen was observed on the 24-h scintigrams. Laxatives were given to reduce the presence of intestinal radioactivity, caused by some hepatobiliary clearance of ^{111}In -pentetreotide. Head and neck images were obtained anteriorly and laterally from both sides. The remainder of the body was imaged with separate anterior and posterior images of the thorax, upper abdomen (including liver/spleen and kidneys), lower abdomen and extremities. The thorax was imaged with arms elevated. Preset counts were 300.000 for the head and neck and 500.000 for the chest and abdomen or a maximum of 15 min. In all patients, Single Photon Emission Computed Tomography (SPECT) images of the upper abdomen were made 24 h after injection using a triple-head camera (3000XP, Picker, Cleveland, OH, USA). Reconstruction of the SPECT data was carried out by filtered back projection. A detailed description of the scanning protocol that is used at the University Hospital Rotterdam is given in several reviews (11,22-24). In normal individuals, a physiological accumulation of radioactivity is seen at 24h after injection of ^{111}In -pentetreotide in the pituitary and thyroid gland, the liver, spleen, kidneys, the intestines, the urinary bladder and the gallbladder. Accumulation of radioactivity at other sites is considered to be abnormal and indicates the presence of pathological SS-R positive tissue. In organs with physiological uptake of ^{111}In -pentetreotide (e.g. liver and spleen), inhomogeneous or focal uptake patterns were considered to be indicative of lymphoma. Two experienced nuclear medicine physicians evaluated the scans at the same time; they did not know the identity of the patients or the results of the conventional staging procedures. If initial

interpretations were different (this occurred in less than 5% of cases), a blind discussion was held until consensus was reached.

Assessment of the true state of a lesion or a region

CT scans and other radiological test were evaluated by experienced radiologists without knowledge of SS-R scintigraphy data. Lymph nodes of more than 15 mm in diameter were considered unequivocally abnormal on CT scanning or ultrasonography and were interpreted to represent HD (25). Lymph nodes of less than 10 mm were considered benign. Lymph nodes with a diameter between 10 mm and 15 mm were considered equivocal. CT and ultrasound criteria for involvement in normal-sized spleen or liver included unexplained infiltrates or focal abnormalities of decreased attenuation. The spleen was considered enlarged on the CT scan, ultrasonography or SS-R scan if the longitudinal diameter was greater than 130 mm (26,27).

Findings of SS-R scintigraphy were compared with the sum of conventional staging procedures. The following lymph node regions were evaluated: occipital left/right, upper cervical left/right, medial cervical left/right, supraclavicular left/right, submandibular left/right, preauricular left/right, axillary left/right, infraclavicular left/right, brachial left/right, mediastinal, lung-hilar left/right, para-aortic (including celiac nodes and nodes from the hepatic and splenic hili), iliac left/right, inguinal left/right, femoral left/right, popliteal left/right, mesenteric and the Waldeyer's ring. In addition, all possible extranodal sites of involvement were also evaluated. This resulted in a total of 70 possibly involved lymph node regions and extranodal sites. In case of discrepant findings between SS-R scintigraphy and conventional staging procedures, we attempted to determine the status of the lesion. Discrepant findings were verified if possible by biopsy or by using non-invasive methods, including ultrasonography, MRI, CT or bone scintigraphy. All patients were followed during and after therapy. For any documented lesion, a final assessment was made of its true state as benign, malignant, or indeterminate. This assessment was based on the result of pathological examination (histology and/or cytology if done), supplemented by the clinical course. A lesion was considered benign because of pathological evidence or if the size was less than 10 mm in long-axis measurements and the lesion did not increase in size. A lesion was considered malignant because of pathological evidence or if the size was more than 15 mm in largest diameter or, in retrospect, on the basis of the clinical course (disappearance or change in size of a lesion following therapy). The status of the lesion was considered indeterminate if the nature of the lesion could not be assessed from the data. Regions without lesions on any test were considered to have a true state of absence of disease. Spleen and liver

involvement was diagnosed according to the Cotswolds criteria (25). The spleen was considered positive for HD if there was unequivocal palpable splenomegaly alone or equivocal palpable splenomegaly with radiological confirmation of either enlargement or multiple focal defects that were not cystic or vascular. Liver involvement was diagnosed if there were multiple focal defects, which were not cystic or vascular, noted with at least two imaging techniques.

Assessment of sensitivity and specificity of a test

The sensitivity and specificities of the different tests were calculated separately for each of the regions for which the test was performed. For the calculation of the sensitivity, the lesions with the true state 'malignant' were used, while for the calculation of the specificity the regions without any lesions or only lesions with final assessment 'benign' were used. The sensitivity of a test for a lymph node region or extranodal site was defined as the number of lesions with a positive test result for that region divided by the total number of lesions with final assessment 'malignant' in that region. The specificity of a test for a lymph node region or extranodal site was defined as the number of patients with a negative test result divided by the total number of patients tested with true state 'benign/absent' in that region.

Results

Patients

The clinical characteristics of the 126 patients enrolled in the study are shown in Table 1. Nodular sclerosis and mixed cellularity subtypes were most frequent. A majority (70%) of the patients had limited HD (stage I or stage II). Table 2 presents the anatomical distribution of involved sites of HD. Almost all patients (97%) presented with supradiaphragmatic lesions. These were predominantly located in the neck and/or mediastinum. Lesions below the diaphragm were apparent in 29% of patients and extranodal lesions were rare.

Sensitivity and specificity of SS-R scintigraphy

All 126 patients were positive on SS-R scintigraphy. In these patients, 483 malignant lesions, i.e. lesions with involvement of HD, were documented using physical examination in combination with SS-R scintigraphy, other imaging techniques, histopathology and subsequent follow-up. Of these, 423 lesions were above the diaphragm, 54 lesions were below the diaphragm and an additional six lesions were recorded. The majority of the lesions were nodal ($n = 457$). Only 26 were extranodal.

Table 1. Clinical characteristics of 126 patients with Hodgkin's disease

Age (years)	
Median	29
Range	15-75
Sex	
Male	75 (59%)
Female	51 (41%)
Histologic subtype	
Lymphocyte predominance	9 (7%)
Nodular sclerosis	95 (76%)
Mixed cellularity	18 (14%)
Lymphocyte depleted	1 (1%)
Not classifiable	3 (2%)
Ann Arbor clinical stage*	
Stage I	29 (23%)
Stage II	59 (47%)
Stage III	25 (20%)
Stage IV	13 (10%)

*based on the results of the standard staging procedures.

Table 2. Anatomical distribution of the 483 malignant lesions in 126 patients with Hodgkin's disease, diagnosed on the basis of standard staging procedures and SS-R scintigraphy

Localization malignant lesion	% Patients
Supraclavicular lymph nodes	75
Mediastinal lymph nodes	71
Cervical lymph nodes*	42
Lung hilar lymph nodes	25
Axillary lymph nodes	24
Infraclavicular lymph nodes	21
Para-aortic lymph nodes	19
Spleen	11
Inguinal lymph nodes	8
Iliac lymph nodes	6
Lungs	5
Bones	2
Mesenteric lymph nodes	1
Waldeyer's ring	1

*occipital, submandibular and cervical lymph nodes.

Table 3 gives the sensitivity of SS-R scintigraphy for the detection of HD in each of the lymph node regions and extranodal sites. SS-R scintigraphy showed a very high

Table 3. Sensitivity of various diagnostic approaches for the detection of Hodgkin's disease in the different lymph node regions and extranodal sites

Localization of malignant lesion	Number of lesions	Physical examination (%)	X-thorax (%)	CT scan (%)	LAG (%)	Ultrasonography (%)	SS-R scan (%)
Supraclavicular lymph nodes	116	86 (115)		80 (15)		96 (45)	100
Cervical lymph nodes*	91	86		92 (12)		97 (31)	97
Mediastinal lymph nodes	90		61 (82)	96			100
Lung hilar lymph nodes	45		54 (39)	91			96
Axillary lymph nodes	38	58		77 (35)			95
Infraclavicular lymph nodes	36			78			100
Lungs	6		50	83			83
Para-aortic lymph nodes	24			88	75 (4)	100 (7)	50
Spleen	14	50		93		100 (9)	93
Iliac lymph nodes	8			88	100 (1)		38
Inguinal lymph nodes	7	71		71			100
Total	483						94

*occipital, submandibular and cervical lymph nodes; LAG, bipedal lymphangiography. Numbers in parentheses indicate frequency at which the test was performed, only given if different from the number of malignant lesions.

sensitivity (95%-100%) for the detection of HD in the neck, mediastinum, lung hila and axillae (Figure 1).

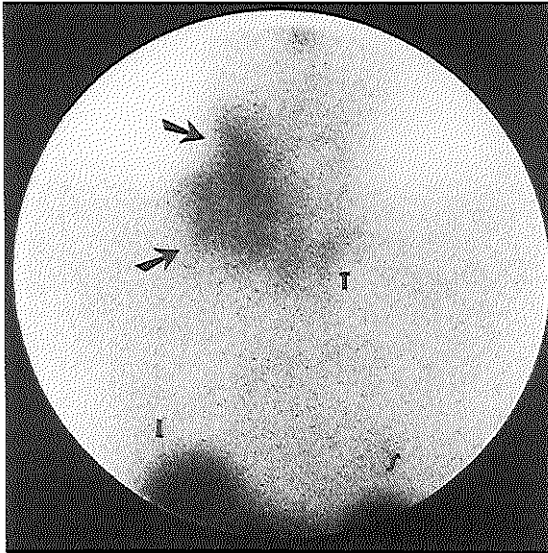


Figure 1

SS-R scintigraphy in a 63-year-old woman with a 2-month history of cervical lymph node enlargement that biopsy revealed to be Hodgkin's disease. Planar anterior image of the neck and upper thorax at 24 h after injection of ^{111}In -pentetreotide. There is marked uptake of ^{111}In -pentetreotide in lymph nodes in the right cervical and supraclavicular region (arrows).

Physiological accumulation of radioactivity is seen in the thyroid (T), liver (L) and spleen (S).

Of the six malignant intrapulmonary lesions, five were visualized using SS-R scintigraphy. The smallest lesion above the diaphragm detected using SS-R scintigraphy had a diameter of 5 mm and was located in the supraclavicular region. Below the diaphragm the sensitivity of SS-R scintigraphy ranged from 38%-100% (Figure 2). The scintigraphic sensitivity for para-aortic lesions was low, i.e. 50%. In four patients the para-aortic lesions were visualized only on SPECT but were not shown on the planar images. There was no apparent relationship between the size of the pathologic lymph node and the probability of a positive para-aortic SS-R scan. The smallest malignant lesion under the diaphragm that was detected by SS-R scintigraphy was an inguinal lymph node with a diameter of 15 mm. In six patients there was pathologic evidence of bone marrow infiltration with HD. In only one of these patients did the SS-R scan revealed marrow positivity.

The sensitivity of SS-R scintigraphy for the detection of supradiaphragmatic lesions was 98% and for lesions below the diaphragm 67%. For nodal lesions the sensitivity was 94% and for extranodal lesions 88%. The sensitivity for all lesions combined was 94%.

In four lesions, SS-R scintigraphy gave a false-positive result. In two patients, non-specific accumulation of radioactivity was seen in the pleural region, probably as a result of old aspecific lesions. In the third patient, a large hematoma in the anterior iliac spine

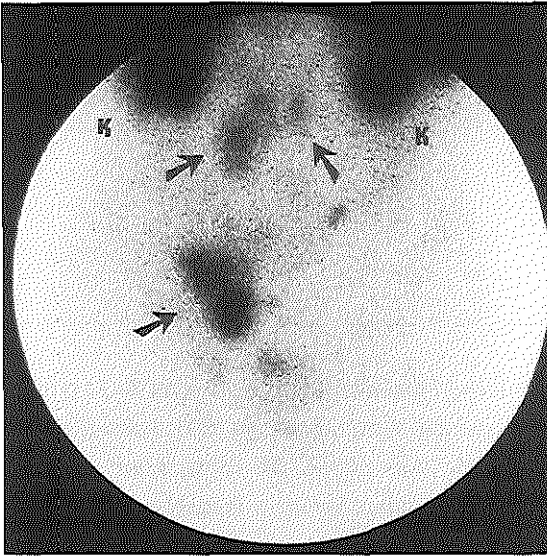


Figure 2

Visualization of abdominal Hodgkin's disease in a 39-year-old man using SS-R scintigraphy. Planar anterior image of the lower abdominal region scanned at 24 h. The SS-R scan reveals positive para-aortic (upper arrows) and right inguinal lymph nodes (lower arrow). There is physiological accumulation of radioactivity in the kidneys (K).

after a bone marrow biopsy caused aspecific accumulation of radioactivity at that site. The fourth patient with a false-positive SS-R scan showed uptake in the shoulder, owing to a bursitis. Thus, the specificity of SS-R scintigraphy is high.

Sensitivity of different imaging techniques

Table 3 gives the estimated sensitivities of each of the imaging techniques used in this study, expressed per distinct lymph node region and extranodal site. In comparison with conventional imaging modalities, SS-R scintigraphy has a high sensitivity for the detection of lymph nodes in the neck, axilla and groin. SS-R scintigraphy is also superior for the visualization of mediastinal localizations of HD. However, in the intra-abdominal region, the SS-R scintigraphy is inferior to the CT scan and ultrasonography.

Comparison of SS-R scintigraphy with conventional staging procedures

In Table 4 an overview is given of a comparison between the results of SS-R scintigraphy and the conventional staging procedures in the 126 patients. In 43% (n = 54) of the patients, SS-R scintigraphy disclosed activity suggestive of HD that had not been revealed following conventional staging procedures. In 24 of these 54 patients, the enhanced diagnostic yield of SS-R scintigraphy could be confirmed by additional investigations, i.e. by repeated palpation (n = 3), subsequent additional radiodiagnosis (n = 14), cytopathology (n = 2) and/or the clinical course (n = 5). We were unable to verify 30 discrepant SS-R scintigraphy and conventional staging findings because of ethical

Table 4. Comparison of the results of SS-R scintigraphy with the conventional staging procedures in 126 patients with Hodgkin's disease

Result	Patients	
	Number	%
SS-R scan detects new lesions	54	43
SS-R scan misses lesions	14	11
SS-R scan detects new lesions, but also misses lesions in the same patient	8	6
Agreement between SS-R scan and conventional staging procedures	50	40

considerations, lack of patient consent or lack of therapeutic consequences. In 14 patients (11%), lesions apparent by conventional staging were missed on SS-R scintigraphy. In eight patients, the result of SS-R scintigraphy was mixed, i.e. in the same individual additional lesions were disclosed by SS-R scintigraphy, but other lesions were missed. In 40% of patients, the results of SS-R scintigraphy and conventional staging procedures were concordant.

Table 5 shows the estimated clinical stages based on the sum of the conventional staging procedures compared with the clinical stages based on the results of SS-R scintigraphy only.

Table 5. Comparison of the clinical stage based on the results of the SS-R scan with the clinical stage based on conventional work-up

Stage based on SS-R scan only	Stage based on conventional staging procedures				
	I	II	III	IV	Total
I	17	0	1*	2*	20
II	8	45	4*	1*	58
III	3*	11*	18	1	33
IV	1*	3*	2	9	15
Total	29	59	25	13	126

*indicate a change in clinical stage with potential consequences for the treatment choice.

The additional lesions revealed using SS-R scintigraphy upgraded the clinical stage in 28 patients. As a result, the treatment plan would have changed in 18 patients (14%). However, in those nine patients (7%) in whom SS-R scintigraphy had failed to recognize

certain apparent localizations of HD, the clinical stage, if based on SS-R scintigraphy only, would have been underestimated.

Analysis of SS-R scintigraphy in favorable and unfavorable subjects of stage I and II patients

Stages I and II patients with HD are commonly stratified by risk (according to selected clinical favorable or unfavorable prognostic factors) to adjust and select more or less intensive therapy. We considered in more detail the consequences of the results of the SS-R scan in these prognostically distinct subsets among all 88 patients with stage I and stage II HD. Three different subgroups were identified: favorable supradiaphragmatic HD (37 patients), unfavorable supradiaphragmatic HD (46 patients) and infradiaphragmatic HD (five patients). Table 6 shows the localization of the additional new lesions found using SS-R scintigraphy for each of the three prognostic subgroups of stages I and II patients.

Table 6. Additional lesions demonstrated with SS-R scintigraphy in 88 stages I and II Hodgkin's disease patients subdivided according to risk

Patient prognosis category	Number of patients (%) with additional lesions			
	Nodal			Extranodal*
	Above diaphragm	Below diaphragm	Above and below diaphragm	
Favorable patients (n = 37)	13 (35)	4 (11)	1 (3)	2 (5)
Unfavorable patients (n = 46)	10 (22)	3 (7)	3 (7)	2 (4)
Abdominal HD (n = 5)	3 (60)	0	0	0

*if the SS-R scan detected additional nodal lesions as well as extranodal sites in the same patient, the patient was scored as extranodal.

In 19% (7 out of 37) of the favorable patients and in 17% (8 out of 46) of the unfavorable patients SS-R scintigraphy disclosed previously unknown lesions below the diaphragm or at extranodal sites, resulting in an upstaging to stage III or stage IV. In three of the five patients with infradiaphragmatic HD, the disease was upstaged to stage III as a consequence of SS-R scintigraphy demonstrating previously undetected lesions above the diaphragm.

Discussion

Studies concerning the value of staging laparotomy have demonstrated that about 30% of patients with stage I and stage II HD have occult splenic or upper abdominal nodal involvement not detected by CT, MRI or lymphangiography (28,29). An indirect

estimation of the probability of occult abdominal disease will direct treatment choice in patients with limited stage HD. In patients with supradiaphragmatic HD, clinical prognostic factors are used as surrogate markers for more or less extended disease to select a more or less intensive treatment approach (3,30). Patients with favorable prognostic factors are usually candidates for radiation therapy with or without dose-reduced chemotherapy. Patients with unfavorable prognostic factors receive more dose-intensive chemotherapy with or without radiation therapy as the initial treatment. However, more sensitive imaging techniques, which would directly demonstrate abdominal involvement of HD more precisely, would allow for better tailoring of treatment.

The expression of SS-Rs on cells in lymph nodes from patients with HD, as demonstrated several years ago (12,13), has opened possibilities for *in vivo* visualization of SS-R positive Hodgkin's localizations. Several groups have shown the feasibility of SS-R scintigraphy for imaging of HD (13-20). However, the numbers of patients in these studies have remained minimal, varying from two to 11 patients, so that the clinical value of SS-R scintigraphy for staging of HD has never been properly established. Our prior experience in 56 HD patients yielded a high patient-related sensitivity (13). This prospective study was designed to investigate the role of SS-R scintigraphy in the initial staging of 126 patients with untreated HD. The results of the study confirm unambiguously that SS-R scintigraphy has a notably high positivity in patients with HD. In our study, each patient had one or more Hodgkin's localizations that were positive on the SS-R scan, demonstrating that Hodgkin's lymphomas, without exception, express SS-Rs.

The results of our study would support the validity of SS-R scanning as a powerful diagnostic method for staging patients with HD. The lesion-related sensitivity was 94% and varied from 98% for supradiaphragmatic lesions to 67% for infradiaphragmatic lesions. In contrast to most other studies, in which new patients and previously treated patients were evaluated together, our study specifically addressed the question of the value of SS-R scintigraphy in newly diagnosed cases (14,16,20).

Compared with CT scanning and ultrasonography, SS-R scintigraphy provided superior results for the detection of Hodgkin's localizations above the diaphragm. Malignant lymph nodes as small as 5 mm diameter were visualized. In the intra-abdominal region, the CT scan appeared considerably more sensitive than SS-R scintigraphy. The limited sensitivity for intra-abdominal Hodgkin's lesions is a disadvantage of SS-R scintigraphy. Optimal visualization of the para-aortic and iliac regions is hampered by the physiological accumulation of the labeled pentetreotide in the liver and spleen and its

elimination by bile, bowel and kidneys. Apparently, the use of SPECT can overcome this problem at least in part. We have used standard filtered back projection for the reconstruction of the SPECT data (31). A drawback of this method is the presence of considerable reconstruction artifacts in the region between the liver, spleen and kidneys. It is conceivable that the use of iterative reconstruction methods will avoid such artifacts. Additionally, the extension of SPECT imaging to the lower abdominal region may further improve the sensitivity. The sensitivity of SS-R scintigraphy in the intra-abdominal region is currently insufficient to recommend its use in all patients. However, in stage I and stage II patients, SS-R scintigraphy has added value in detecting more advanced disease in a significant proportion of the patients, thus directly impacting on treatment decision. Not only patients with unfavorable prognostic factors but also patients with favorable prognostic factors appear to carry more disseminated disease according to *in vivo* SS-R evaluation. We recognize that lack of histological proof of our imaging interpretations is a significant deficiency of our study. However, invasive diagnostic procedures represent increased risk for the patient and staging laparotomies are now infrequently performed. Because there were only a small fraction of false-positive SS-R scintigraphy findings (four lesions), we think that most of the unresolved SS-R scintigraphy findings are probably true positive.

The usefulness of SS-R scintigraphy is heavily dependent on optimal equipment and technique. We administered a high dose of ^{111}In dium (always > 200 MBq), which probably enhances the sensitivity of detection. Furthermore, the counting time of images should be sufficiently long in order to avoid lesions with a relatively low uptake of radioactivity being missed. In our experience, SPECT imaging of the upper abdomen is essential. In a considerable number of patients (four out of 24) with abdominal HD, the para-aortic lesions were not detected on the planar images but were visualized by SPECT. This makes the procedure time-consuming (SPECT, counting time) and expensive (dose, time). However, in our study, the addition of an SS-R scan to the work-up in patients with stages I and II HD proved to be cost-effective. The results of the cost-effective study will be reported in a separate paper.

SS-R scintigraphy by its nature can never compete with conventional imaging in anatomical delineation of the disease sites, but the technique offers complementary information owing to its physiological features. In patients with HD, the presence and abundance of SS-R expression can easily be detected *in vivo*. At present, peptide receptor-targeted radionuclide therapy (PRRT) is being developed as a new therapeutic option for cancer patients. A promising effect of therapy with multiple high radiotherapeutical doses of ^{111}In -pentetreotide was demonstrated in patients with end-

stage neuroendocrine tumors (32). In this study, there was a tendency towards better results in patients whose tumors had a higher accumulation of the radioligand. Most neuroendocrine tumors have a high SSTR-2 expression, while lymphomas generally have a medium to low rate of SSTR-2 expression. However, in contrast to the relatively radioresistant neuroendocrine tumors, lymphomas are generally radiosensitive. Thus, despite the low receptor expression, it is possible to expect therapeutic effects of targeted treatment with ^{111}In -pentetreotide, or one of its variants, e.g. ^{90}Y -DOTATOC (33), in patients with HD. Critical organs for PRRT are the kidneys and probably the bone marrow. This imposes a limit to the maximal activity that can be employed safely. Whether PRRT is a promising option for malignant lymphoma remains to be investigated.

Gallium scintigraphy is not routinely used for the initial staging of HD, owing to the lower sensitivity compared with the CT scan, especially in the abdomen (34-36). Traditionally, gallium scintigraphy plays a role in the evaluation of the post-treatment residual mass. Gallium imaging may be helpful to confirm the presence of residual active disease and resistance to treatment (37-40). However, it tends to underestimate small deposits of disease (39,41). A number of reports have recently demonstrated a potential role for whole-body positron emission tomography with 2-[^{18}F]-fluoro-2-deoxy-D-glucose (FDG-PET) in lymphoma imaging (42). Published results indicate that FDG-PET may be equal or superior to CT for the detection of nodal as well as extranodal involvement in HD (43,44). For post-treatment evaluation, data indicate that FDG-PET has a higher diagnostic and prognostic value than CT (45,46). We are currently investigating in a prospective study on the role of SS-R scintigraphy in the management of residual masses. Furthermore, it will be of interest to investigate the comparative values of gallium scanning, SS-R scintigraphy and FDG-PET in the diagnostic work-up of patients with Hodgkin's disease.

Acknowledgments

The authors thank Mrs. J.J. Sluys-Dallinga and Mrs. P. Blom, research nurses, for their excellent data management. This study was supported by a grant from the Dutch National Health Care Council.

References

- 1 Gospodarowicz MK, Sutcliffe SB, Clark RM, Dembo AJ, Fitzpatrick PJ, Munro AJ, Bergsagel DE, Patterson BJ, Tsang R, Chua T, Bush RS. Analysis of supradiaphragmatic

- clinical stage I and II Hodgkin's disease treated with radiation alone. *Int J Radiat Oncol Biol Phys* 22: 859-865, 1992
- 2 Tubiana M, Henry-Amar M, Hayat M, Burgers M, Qasim M, Somers R, Sizoo W, Van der Schueren E. The EORTC treatment of early stages of Hodgkin's disease: the role of radiotherapy. *Int J Radiat Oncol Biol Phys* 10: 197-210, 1984
 - 3 Tubiana M, Henry-Amar M, Carde P, Burgers JM, Hayat M, Van der Schueren E, Noordijk EM, Tanguy A, Meerwaldt JH, Thomas J, de Pauw B, Monconduit M, Cosset JM, Somers R. Toward comprehensive management tailored to prognostic factors of patients with clinical stages I and II in Hodgkin's disease. The EORTC Lymphoma Group controlled clinical trials: 1964-1987. *Blood* 73: 47-56, 1989
 - 4 Mauch PM. Controversies in the management of early stage Hodgkin's disease. *Blood* 83: 318-329, 1994
 - 5 Engert A, Wolf J, Diehl V. Treatment of advanced Hodgkin's lymphoma: standard and experimental approaches. *Semin Hematol* 36: 282-289, 1999
 - 6 Advani RH, Horning SJ. Treatment of early-stage Hodgkin's disease. *Semin Hematol* 36: 270-281, 1999
 - 7 Reznec RH, Richards MA. The radiology of lymphoma. *Clinical haematology: the lymphomas*. McElwain TJ, Lister TA, eds. Ballière Tindall, London. 77-107, 1987
 - 8 Reichlin S. Somatostatin. *N Engl J Med* 309: 1495-1501, 1983
 - 9 Reichlin S. Somatostatin. *N Engl J Med* 309: 1556-1561, 1983
 - 10 Patel YC, Greenwood MT, Warszynska A, Panetta R, Srikant CB. All five cloned human somatostatin receptors (hSSTR1-5) are functionally coupled to adenylyl cyclase. *Biochem Biophys Res Commun* 198: 605-612, 1994
 - 11 Krenning EP, Kwekkeboom DJ, Bakker WH, Breeman WAP, Kooij PPM, Yoe Oei H, van Hagen M, Postema PTE, de Jong M, Reubi JC, Visser TJ, Reijs AEM, Hofland LJ, Koper JW, Lamberts SWJ. Somatostatin receptor scintigraphy with [¹¹¹In-DTPA-D-Phe¹] and [¹²³I-Tyr³]-octreotide: the Rotterdam experience with more than 1000 patients. *Eur J Nucl Med* 20: 716-731, 1993
 - 12 Reubi JC, Waser B, van Hagen M, Lamberts SWJ, Krenning EP, Gebbers JO, Laissue JA. In vitro and in vivo detection of somatostatin receptors in human malignant lymphomas. *Int J Cancer* 50: 895-900, 1992
 - 13 Van den Anker-Lugtenburg PJ, Krenning EP, Oei HY, van Hagen MP, Gerrits CJH, Reubi JC, Lamberts SWJ, Löwenberg B. Somatostatin receptor scintigraphy in the initial staging of Hodgkin's disease. *Br J Haematol* 93: 96-103, 1996

- 14 Bares R, Galonska P, Dempke W, Handt S, Büll U, Osieka R. Somatostatin receptor scintigraphy in malignant lymphoma: first results and comparison with glucose metabolism measured by positron-emission tomography. *Horm Metab Res Suppl* 27: 56-58, 1993
- 15 Van Hagen PM, Krenning EP, Reubi JC, Mulder AH, Bakker WH, Yoe Oei H, Löwenberg B, Lamberts SWJ. Somatostatin analogue scintigraphy of malignant lymphomas. *Br J Haematol* 83: 75-79, 1993
- 16 Bong SB, VanderLaan JG, Louwes H, Schuurman JJ. Clinical experience with somatostatin receptor imaging in lymphoma. *Semin Oncol Suppl* 21: 46-50, 1994
- 17 Sarda L, Duet M, Zini JM, Berolatti B, Benelhadj S, Tobelem G, Mundler O. Indium-111 pentetreotide scintigraphy in malignant lymphomas. *Eur J Nucl Med* 22: 1105-1109, 1995
- 18 Lipp RW, Silly H, Ranner G, Dobnig H, Passath A, Leb G, Krejs GJ. Radiolabeled octreotide for the demonstration of somatostatin receptors in malignant lymphoma and lymphadenopathy. *J Nucl Med* 36: 13-18, 1995
- 19 Goldsmith SJ, Macapinlac HA, O'Brien JP. Somatostatin-receptor imaging in lymphoma. *Semin Nucl Med* 25: 262-271, 1995
- 20 Ivancevic V, Wörmann B, Nauck C, Sandrock D, Munz DL, Hiddeman W, Emrich D. Somatostatin receptor scintigraphy in the staging of lymphomas. *Leuk Lymphoma* 26: 107-114, 1997
- 21 Carbone PP, Kaplan HS, Musshoff K, Smithers DW, Tubiana M. Report of the committee on Hodgkin's disease staging classification. *Cancer Res* 31: 1860-1861, 1971
- 22 Krenning EP, Bakker WH, Kooij PPM, Breeman WAP, Yoe Oei H, de Jong M, Reubi JC, Visser TJ, Bruns C, Kwekkeboom DJ, Reijs AEM, van Hagen PM, Koper JW, Lamberts SWJ. Somatostatin receptor scintigraphy with [¹¹¹In-DTPA-Phe¹]-octreotide in man: metabolism, dosimetry and comparison with [¹²³I-Tyr³]-octreotide. *J Nucl Med* 33: 652-658, 1992
- 23 Krenning EP, Kwekkeboom DJ, de Jong M, Visser TJ, Reubi JC, Bakker WH, Kooij PPM, Lamberts SWJ. Essentials of peptide receptor scintigraphy with emphasis on the somatostatin analog octreotide. *Semin Oncol Suppl* 21: 6-14, 1994
- 24 Krenning EP, Kwekkeboom DJ, Pauwels S, Kvols K, Reubi JC. Somatostatin receptor scintigraphy. In: Freeman LM, ed. *Nuclear Medicine Annual*. New York: Raven Press 1-50, 1995
- 25 Lister TA, Crowther D, Sutcliffe SB, Glatstein E, Canellos GP, Young RC, Rosenberg SA, Coltman CA, Tubiana M. Report of a committee convened to discuss the evaluation and staging of patients with Hodgkin's disease: Cotswolds meeting. *J Clin Oncol* 7: 1630-1636, 1989

- 26 Hess CF, Kurtz B, Hoffmann W, Bamberg M. Ultrasound diagnosis of splenic lymphoma: ROC analysis of multidimensional splenic indices. *Br J Radiol* 66: 859-864, 1993
- 27 Munker R, Stengel A, Stabler A, Hiller E, Brehm G. Diagnostic accuracy of ultrasound and computed tomography in the staging of Hodgkin's disease. *Cancer* 76: 1460-1466, 1995
- 28 Leibenhaut MH, Hoppe RT, Efron B, Halpern J, Nelsen T, Rosenberg SA. Prognostic indicators of laparotomy findings in clinical stage I-II supradiaphragmatic Hodgkin's disease. *J Clin Oncol* 7: 81-91, 1989
- 29 Mauch P, Larson D, Osteen R, Silver B, Yeap B, Canellos G, Weinstein H, Rosenthal D, Pinkus G, Jochelson M, Coleman CN, Hellman S. Prognostic factors for positive surgical staging in patients with Hodgkin's disease. *J Clin Oncol* 8: 257-265, 1990
- 30 Pavlovsky S, Maschio M, Santarelli MT, Muriel FS, Corrado C, Garcia I, Schwartz L, Montero C, Sanahuja FL, Magnasco O, Rana R, Cavagnaro F. Randomized trial of chemotherapy versus chemotherapy plus radiotherapy for stage I-II Hodgkin's disease. *J Natl Cancer Inst* 80: 1466-1473, 1988
- 31 Rusinek H. SPECT reconstruction techniques. *Clinical SPECT imaging*. Kramer EL, Sanger JJ, eds. Raven Press, New York, 43-67, 1995
- 32 Krenning EP, de Jong M, Kooij PPM, Breeman WAP, Bakker WH, de Herder WW, van Eijck CHJ, Kwekkeboom DJ, Jamar F, Pauwels S, Valkema R. Radiolabelled somatostatin analogue(s) for peptide receptor scintigraphy and radionuclide therapy. *Ann Oncol Suppl* 10: 23-29, 1999
- 33 Otte A, Herrmann R, Heppeler A, Behe M, Jermann E, Powell P, Maecke HR, Muller J. Yttrium-90 DOTATOC: first clinical results. *Eur J Nucl Med* 26: 1439-1447, 1999
- 34 Front D, Israel O, Epelbaum R, Ben Haim S, Sapir EE, Jerushaimi J, Kolodny GM, Robinson E. Ga-67 SPECT before and after treatment of lymphoma. *Radiology* 175: 515-519, 1990
- 35 Hagemeister FB, Fesus SM, Lamki LM, Hayne TP. Role of the gallium scan in Hodgkin's disease. *Cancer* 65: 1090-1096, 1990
- 36 Larcos G, Farlow DC, Antico VF, Gruenewald SM, Boyages J. The role of high dose 67-gallium scintigraphy in staging untreated patients with lymphoma. *Aust NZ J Med* 24: 5-8, 1994
- 37 Wylie BR, Southee AE, Joshua DE, McLaughlin AF, Gibson J, Hutton BF, Morris JG, Kronenberg H. Gallium scanning in the management of mediastinal Hodgkin's disease. *Eur J Haematol* 42: 344-347, 1989
- 38 Front D, Ben-Haim S, Israel O, Epelbaum R, Haim N, Even-Sapir E, Kolodny GM, Robinson E. Lymphoma: predictive value of Ga-67 scintigraphy after treatment. *Radiology* 182: 359-363, 1992

- 39 Cooper DL, Caride VJ, Zloty M, Germino J, Farber LR, Hoffer PB. Gallium scans in patients with mediastinal Hodgkin's disease treated with chemotherapy. *J Clin Oncol* 11: 1092-1098, 1993
- 40 Zinzani PL, Magagnoli M, Franchi R, Zompatori M, Frezza G, Galassi R, Gherlinzoni F, Bendandi M, Albertini P, Monetti N, Tura S. Diagnostic role of gallium scanning in the management of lymphoma with mediastinal involvement. *Haematologica* 84: 604-607, 1999
- 41 Salloum E, Brandt DS, Caride VJ, Cornelius E, Zelterman D, Schubert W, Mannino T, Cooper DL. Gallium scans in the management of patients with Hodgkin's disease: a study of 101 patients. *J Clin Oncol* 15: 518-527, 1997
- 42 Bar-Shalom R, Valdivia AY, Blaufox MD. PET imaging in oncology. *Semin Nucl Med* 30: 150-185, 2000
- 43 Bangerter M, Moog F, Buchmann I, Kotzerke J, Griesshammer M, Hafner M, Elsner K, Frickhofen N, Reske SN, Bergmann L. Whole-body 2-[18F]-fluoro-2-deoxy-D-glucose positron emission tomography (FDG-PET) for accurate staging of Hodgkin's disease. *Ann Oncol* 9: 1117-1122, 1998
- 44 Stumpe KDM, Urbinelli M, Steinert HC, Glanzmann Ch, Buck A, von Schulthess GK. Whole-body positron emission tomography using fluorodeoxyglucose for staging of lymphoma: effectiveness and comparison with computed tomography. *Eur J Nucl Med* 25: 721-728, 1998
- 45 Jerusalem G, Beguin Y, Fassote MF, Najjar F, Paulus P, Rigo P, Fillet G. Whole-body positron emission tomography using ¹⁸F-fluorodeoxyglucose for posttreatment evaluation in Hodgkin's disease and non-Hodgkin's lymphoma had higher diagnostic and prognostic value than classical computed tomography scan imaging. *Blood* 94: 429-433, 1999
- 46 Zinzani PL, Magagnoli M, Chierichetti F, Zompatori M, Garraffa G, Bendandi M, Gherlinzoni F, Cellini C, Stefoni V, Ferlin G, Tura S. The role of positron emission tomography (PET) in the management of lymphoma patients. *Ann Oncol* 10: 1181-1184, 1999

CHAPTER 5

Somatostatin receptor scintigraphy in the initial staging of low-grade non-Hodgkin's lymphomas

Pieterella J. Lugtenburg^{1,6}, Bob Löwenberg^{1,6}, Roelf Valkema²,
Hong-Yoe Oei², Steven W. Lamberts³, Marinus J. Eijkemans⁴,
Wim L. van Putten⁵ and Eric P. Krenning^{2,3}

¹Dept. of Hematology, University Hospital and Erasmus University Rotterdam

²Dept. of Nuclear Medicine, University Hospital and Erasmus University Rotterdam

³Dept. of Internal Medicine, University Hospital and Erasmus University Rotterdam

⁴Dept. of Public Health, Erasmus University Rotterdam

⁵Dept. of Statistics, University Hospital and Erasmus University Rotterdam

⁶Dept. of Hematology, Daniel den Hoed Cancer Center, Rotterdam

The Netherlands

J Nucl Med 42: 222-229, 2001

Abstract

In this prospective study somatostatin receptor (SS-R) scintigraphy was compared with conventional staging procedures for the initial staging of patients with low-grade non-Hodgkin's lymphoma (NHL). Fifty consecutive untreated patients with low-grade NHL underwent SS-R scintigraphy as part of their initial staging. Planar images were obtained 24 and 48 h after intravenous injection of 220 MBq ^{111}In -pentetretotide. SPECT images of the upper abdomen were obtained from all patients. SS-R scans were evaluated blindly without knowledge of the results of the conventional staging methods. SS-R scintigraphy findings were compared with the results of physical and radiologic examinations. SS-R scintigraphy findings were positive in 42 of 50 patients (84%). In 10 patients (20%), the SS-R scan revealed new lesions that had not been revealed by conventional staging procedures. These 10 patients were all upgraded to a higher stage. Consequently, the treatment plan would have been altered in 5 patients (10%). However, in 19 patients (38%), lesions apparent after conventional staging methods were missed by SS-R scintigraphy. The sensitivity of SS-R scintigraphy varied from 62% for supra-diaphragmatic lesions to 44% for infradiaphragmatic lesions. The specificity of SS-R scintigraphy was high (98%-100%). In comparison with CT scanning and sonography, SS-R scintigraphy is inferior for the visualization of NHL lesions in the thorax and abdomen. Although SS-R scintigraphy findings are positive in a large proportion of patients with low-grade NHL, in most patients only part of the lesions can be visualized. Because of the limited sensitivity, we recommend SS-R scintigraphy for initial staging of patients with low-grade NHL only in selected conditions and not for the general work-up.

Introduction

Low-grade non-Hodgkin's lymphomas (NHLs) often present as disseminated disease. Bone marrow involvement is frequently seen. The survival curves reveal a progressive decline with no indication of plateau, providing no evidence of a cure. The median survival is about 8 years (1). Local irradiation can result in prolonged freedom from progression and possibly a cure in approximately half of patients with stage I and small-volume stage II low-grade NHL (2,3). Therefore, for low-grade NHLs, staging is important to identify patients with truly localized disease who may be cured by radiotherapy.

Somatostatin receptors (SS-Rs) are present in a wide variety of human tumors (4). The radiolabeled SS analog [^{111}In indium-diethylenetriaminepentaacetic acid-D-phenylalanine]-octreotide has been used successfully for the in vivo visualization of SS-R positive tumors (4). With in vitro autoradiography, SS-R presence was shown in lymph nodes

with NHLs. Of 11 low-grade B-cell NHLs, 10 were SS-R positive, and a high receptor density was restricted to the neoplastic follicles (5).

Studies evaluating the clinical impact of SS-R scintigraphy for the staging of NHLs are rare, and they are all based on relatively small numbers of patients and heterogeneous patient groups (6-13).

We report the results of a prospective study of 50 patients newly diagnosed with low-grade NHL in which the value of SS-R scintigraphy was assessed.

Patients and methods

Patients

Fifty consecutive, newly diagnosed and previously untreated patients with low-grade NHL were enrolled in a prospective study. The diagnosis of low-grade NHL was substantiated by histologic and immunohistologic methods and was classified according to the Working Formulation (14). The stage of the disease according to the Ann Arbor classification (15) was established by conventional methods that always included a physical examination; inspection of the Waldeyer's ring by an ear, nose, and throat specialist; chest radiography; computerized tomography (CT) scanning of the chest, abdomen, and pelvis; and sometimes sonography of the neck or abdomen. The diagnosis of bone marrow involvement was always verified after cytologic, immunologic, and histopathologic examination of marrow aspiration and biopsy. CT scanning was performed with contiguous 10 mm axial sections after oral and intravenous administration of contrast material. All patients gave informed consent to the study, which was approved by the ethics committee of the University Hospital Rotterdam.

SS-R scintigraphy

The maximum interval between conventional staging procedures and SS-R scintigraphy was 3 wk. All examinations were completed before initiation of therapy. Patients were injected intravenously with 220 MBq ^{111}In -pentetreotide (OctreoScan; Mallinckrodt, Inc. BV, Petten, The Netherlands). Planar total body scintigraphy was performed 24 h after injection with a large-field-of-view gamma camera (Counterbalance 3700 and ROTA II; Siemens Gammasonics, Erlangen, Germany) equipped with a medium-energy collimator. Repeated scintigrams were obtained 48 h after injection, when accumulation of radioactivity in the abdomen was observed on 24-h scintigrams. Laxatives were given to reduce intestinal radioactivity caused by some hepatobiliary clearance of ^{111}In -pentetreotide. Head and neck images were obtained anteriorly and laterally from both sides. The remainder of the body was imaged with separate anterior and posterior images

of the thorax, upper abdomen (including liver/spleen and kidneys), lower abdomen, and extremities. The thorax was imaged with arms elevated. Preset counts were 300,000 for the head and neck and 500,000 for the thorax and abdomen, or a maximum of 15 min. In all patients, SPECT images of the upper abdomen were made 24 h after injection using a triple-head camera (3000XP; Picker, Cleveland, OH). SPECT data were reconstructed by filtered backprojection. A detailed description of the scanning protocol is given in several reviews (16-18). In healthy individuals, a physiologic accumulation of radioactivity may be seen 24 h after injection of ^{111}In -pentetreotide in the pituitary gland, thyroid gland, liver, spleen, kidneys, intestines, urinary bladder, and, frequently, the gallbladder. Accumulation of radioactivity at other sites is considered to be abnormal and indicates the presence of pathologic SS-R positive tissue. In organs with physiologic uptake of ^{111}In -pentetreotide (e.g., liver and spleen) inhomogeneous or focal uptake patterns were considered to be indicative of lymphoma. Independent, blinded evaluation of SS-R scans was performed by two experienced nuclear medicine physicians at the same time. If the initial interpretations were different (occurring in less than 5% of patients), a blind discussion was held until consensus was reached. The intensity of pathologic uptake of ^{111}In -pentetreotide in the lesions observed on the planar images was graded semiquantitatively as follows: grade 0 = negative, no abnormal activity; grade 1 = equivocally positive, small amount of accumulation of radioactivity; grade 2 = clear accumulation of radioactivity, intensity less than that of the liver; and grade 3 = clear accumulation of radioactivity, intensity equal to or greater than that of the liver. The SS-R scan was considered positive in any given patient if at least one of the identified lymphoma lesions was positive on the scan (grade 1, 2, or 3).

Assessment of the true state of lesion or region

CT scans and other radiologic tests were evaluated by experienced radiologists without knowledge of the SS-R scintigraphy data. Lymph nodes >15 mm in diameter were considered unequivocally abnormal on CT scanning or sonography and were interpreted to represent NHL. Lymph nodes <10 mm were considered benign. Lymph nodes with a diameter of 10-15 mm were considered equivocal. CT and sonography criteria for involvement in a normal-sized spleen or liver included unexplained infiltrates or focal abnormalities of decreased attenuation. The spleen was considered enlarged on CT, sonogram, or SS-R scan if the longitudinal diameter was >130 mm (19,20).

Findings of SS-R scintigraphy were compared with the sum of the results of conventional staging procedures. The following lymph node regions were evaluated: occipital left/right, upper cervical left/right, medial cervical left/right, preauricular left/right,

submandibular left/right, supraclavicular left/right, infraclavicular left/right, axillary left/right, brachial left/right, mediastinal, lung-hilar left/right, para-aortic (including celiac nodes and nodes from the hepatic and splenic hili), iliac left/right, inguinal left/right, femoral left/right, popliteal left/right, mesenteric, and the Waldeyer's ring. In addition, all extranodal sites of potential involvement were also evaluated. This process resulted in a total of 70 possibly involved lymph node regions and extranodal sites. In cases of disagreement between findings in SS-R scintigraphy and conventional staging procedures, we attempted to determine the status of the lesion. Status was verified if possible by biopsy or using noninvasive methods, including sonography, magnetic resonance imaging, CT or bone scintigraphy. All patients were followed during and after therapy. For any documented lesion, a final assessment was made of its true state as benign, malignant, or indeterminate. This assessment was based on the result of the pathologic examination (histology or cytology if done) supplemented by the clinical course. A lesion was considered benign because of pathologic evidence, or if the long-axis measurement was <10 mm and the lesion did not increase in size. A lesion was considered malignant because of pathologic evidence, or if the largest diameter was >15 mm, or in retrospect on the basis of the clinical course (disappearance or change in size of a lesion of >10 mm after therapy). The status of the lesion was considered indeterminate if the nature of the lesion could not be assessed from the data. Regions without lesions on any test were considered to have a true state of absence of disease. The spleen was considered positive for NHL if there was unequivocal palpable splenomegaly alone or equivocal palpable splenomegaly with radiologic confirmation of either enlargement or multiple focal defects that were neither cystic nor vascular. Liver involvement was diagnosed if there were multiple focal defects that were neither cystic nor vascular, noted with at least two imaging techniques.

Assessment of sensitivity and specificity of a test

The sensitivity and specificity of the different tests were calculated separately for each of the regions for which each test was performed. For the calculation of sensitivity, the lesions with a true state of malignancy were used, whereas for the calculation of specificity, the regions with no lesions or only lesions with a final assessment of benign were used. The sensitivity of a test for a lymph node region or extranodal site was defined as the number of lesions with a positive test result for that region divided by the total number of lesions with a final assessment of malignant in that region. The specificity of a test for a lymph node region or extranodal site was defined as the number of patients with

a negative test result divided by the total number of patients tested with true state of benign/absent in that region.

Results

Patients

The clinical characteristics of the 50 patients with low-grade NHL enrolled in the study are listed in Table 1.

Table 1. Clinical characteristics of 50 patients with low-grade NHL

Characteristic	No. of patients (%) [‡]
Sex	
Male	30 (60)
Female	20 (40)
Ann Arbor clinical stage*	
Stage I	25 (50)
Stage II	5 (10)
Stage III	7 (14)
Stage IV	13 (26)
Histologic subtype (Working Formulation)	
A: Small lymphocytic	7 (14)
B: Follicular, predominantly small cleaved cell	2 (4)
C: Follicular, mixed small cleaved and large cell	30 (60)
MALT	9 (18)
Unclassifiable low-grade	2 (4)

*based on results of standard staging procedures; [‡]Age range, 28-76 y; mean age, 51 y.

Follicular lymphoma constituted for 64% of the histologies. There were 9 patients (18%) with a lymphoma of mucosal-associated lymphoid tissue (MALT). Immunophenotypically, all NHLs were of B-cell origin. Localized disease (i.e., stages I or II) was more common (60%) than advanced disease (40%). Details of the anatomic distribution of the malignant lesions are given in Table 2. Lymph nodes in the neck were involved in 56% of the patients. Approximately half of the patients (52%) presented with infradiaphragmatic disease. Below the diaphragm, the para-aortic region and the mesenteric and inguinal lymph nodes were most frequently involved. The most common sites of extranodal involvement were the stomach and orbita/eye. Bone marrow infiltration with NHL was apparent in 22% of patients.

Patient-related sensitivity of SS-R scintigraphy

The SS-R scan was positive in 42 of 50 patients (84%). An entirely negative scan was

Table 2. Anatomic distribution of 162 malignant lesions in 50 patients with low-grade NHL*

Localization malignant lesion	% of patients
Neck lymph nodes	56
Para-aortic lymph nodes	34
Mesenteric lymph nodes	22
Inguinal lymph nodes	20
Mediastinal lymph nodes	18
Axillary lymph nodes	18
Iliac lymph nodes	12
Spleen	10
Stomach	10
Orbit/eye	10
Lung hilar lymph nodes	4
Waldeyer's ring	4
Intestine	4
Skin	4
Central nervous system	2
Urinary bladder	2
Pleura	2
Parotid gland	2
Mouth	2

*diagnosed on basis of conventional staging procedures and SS-R scintigraphy.

seen in 8 of 50 patients (16%). In 4 of 9 patients (44%) with a MALT lymphoma, the SS-R scan was negative; 2 had gastric lymphoma and 2 had ocular lymphoma. The SS-R scans in the other 5 patients with MALT lymphoma were positive; 2 had lymphoma of the stomach, 1 had lymphoma of the parotid gland, 1 had lymphoma of the orbit, and 1 had lymphoma of the orbit, stomach, intestine, spleen and abdominal lymph nodes.

Comparison of SS-R scintigraphy with conventional staging procedures

Table 3 compares the results of SS-R scintigraphy with those of conventional staging (exclusive bone marrow examination) in the 50 patients. In 10 patients (20%), the SS-R scan revealed new lesions suggestive of NHL that were not revealed by conventional staging procedures. We were unable to verify the discrepant findings in these 10 patients because of ethical considerations, lack of patient consent, or lack of therapeutic consequences. In 19 patients (38%), lesions apparent after conventional staging were missed on SS-R scintigraphy. Furthermore, in 3 patients (6%), the results of the comparison were mixed; that is, in the same patient, new lesions were disclosed by SS-R

Table 3. Comparison of results of SS-R scintigraphy with those of conventional staging in 50 patients with low-grade NHL

Result	Patients	
	Number	%
SS-R scan detects new lesions	10	20
SS-R scan misses lesions	19	38
SS-R scan detects new lesions and misses lesions in same patient	3	6
Agreement between SS-R scan and conventional staging procedures	18	36

scintigraphy and other lesions were missed. Finally, the results of SS-R scintigraphy and conventional staging procedures were concordant in 36% of the patients.

Table 4 shows the clinical stage based on conventional staging procedures (excluding the bone marrow evaluation) in comparison with the clinical stage based on conventional staging procedures complemented with SS-R scintigraphy.

Table 4. Clinical stage based on conventional staging procedures complemented with SS-R scintigraphy compared with clinical stage based on conventional staging only

Stage based on conventional staging complemented with SS-R scintigraphy	Stage based on conventional staging only*				
	I	II	III	IV	Total
I	15	1	0	0	16
II	5	4	0	0	9
III	4 [*]	0	7	0	11
IV	1 [†]	0	0	13	14
Total	25	5	7	13	50

* conventional staging procedures excluding bone marrow pathology; [†]Change in clinical stage with potential consequences for treatment choice.

Because of the different SS-R scintigraphy findings, the clinical stage was upgraded in 10 patients (20%). As a result, the treatment plan would have been altered in 5 patients (10%). On the other hand, in 12 patients (24%), in whom SS-R scintigraphy missed certain apparent localizations of NHL, the clinical stage would have been underestimated when based only on the results of SS-R scintigraphy.

Lesion-related sensitivity and specificity of SS-R scintigraphy

In the 50 patients, a total of 162 malignant lesions were distinguished from the physical examination in combination with SS-R scintigraphy, other imaging techniques, histopathology, and the outcome of subsequent follow-up. Of these, 95 lesions were localized above the diaphragm, 64 lesions were below the diaphragm, and 3 were elsewhere. A minority of the lesions were extranodal ($n = 20$). Table 5 gives the sensitivity of SS-R scintigraphy for detecting lymphoma in each of the lymph node regions and extranodal sites. For supradiaphragmatic nodal lesions, the sensitivity varied from 59% to 78% (Figure 1).

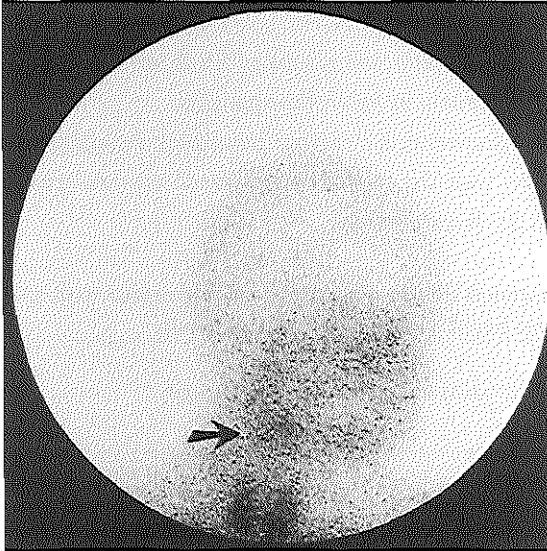


Figure 1

Visualization of submandibular lymph node in 42-y-old woman with stage IA NHL of low-grade malignancy by SS-R scintigraphy. Right lateral image of head and neck shows grade 2 pathologic uptake (arrow) within submandibular lesion. Normal uptake of radioactivity is seen in thyroid. On physical examination, a lymph node of 3 cm in diameter was palpated.

The sensitivity was best for lesions in the mediastinum (78%). The smallest NHL lesion above the diaphragm that was correctly visualized by SS-R scintigraphy was located in the upper cervical region and had a diameter of 1.2 cm. The largest supradiaphragmatic lesion that was missed by SS-R scintigraphy had a diameter of 4.0 cm and was located in the axilla. The scintigraphic sensitivity for lymph nodes in the abdominal and inguinal regions varied from 30% to 54% (Figures 2 and 3). Only 38% of the gastrointestinal lymphomas were visualized by SS-R scintigraphy. In the para-aortic and iliac regions, small lymph nodes of 1.5 cm in diameter were detected by SS-R scintigraphy. However, 1 mesenteric lymph node mass of 7.0 cm in diameter was entirely missed by SS-R scintigraphy. In 1 patient, lymphoma localization in the stomach was detected by SPECT only, whereas it had not been visualized on the planar images. In the other patients,

Table 5. Sensitivity of various diagnostic approaches for detection of low-grade NHL lesions in different lymph node regions and extranodal sites

Localization of malignant lesion	Number of malignant lesions	Physical examination (%)	Chest radiograph (%)	CT scan (%)	LAG (%)	Sonography (%)	SS-R scan (%)
Cervical lymph nodes*	38	96				70 (10)	66
Supraclavicular lymph nodes	17	90				63 (8)	59
Axillary lymph nodes	16	94		86 (14)			63
Mediastinal lymph nodes	9		25 (8)	100 (8)			78
Orbit/eye	6	67		40 (5)			33
Lung-hilar lymph nodes	3		0	100			67
Para-aortic lymph nodes	17			82	100 (2)	43 (7)	35
Mesenteric lymph nodes	11			100		67 (6)	36
Inguinal lymph nodes	13	69		85 (13)			54
Iliac lymph nodes	10			90			30
Stomach/intestine	8			13			38
Spleen	5	100		100		100 (2)	100

* occipital, submandibular and cervical lymph nodes; LAG, bipedal lymphangiography. Numbers in parentheses indicate frequency at which the test was performed and are given only if different from number of malignant lesions.

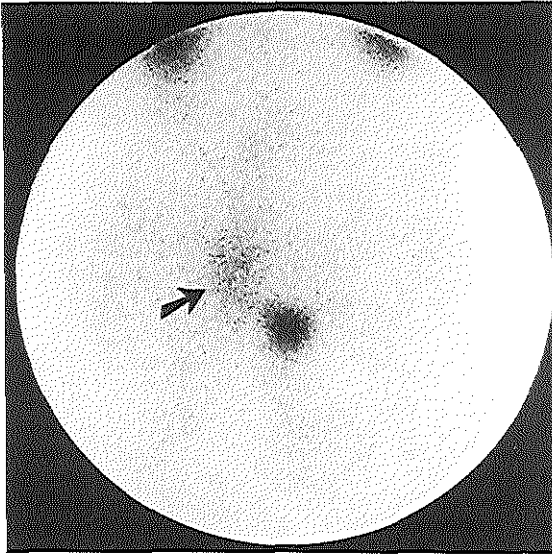


Figure 2

SS-R scintigraphy in 36-y-old man with low-grade NHL shows multiple enlarged lymph nodes of 2-3 cm in diameter in right inguinal and iliac regions. Pathologic lymph nodes are clearly seen (grade 2 uptake, arrow). Normal accumulation of radioactivity is seen in bladder and kidneys.

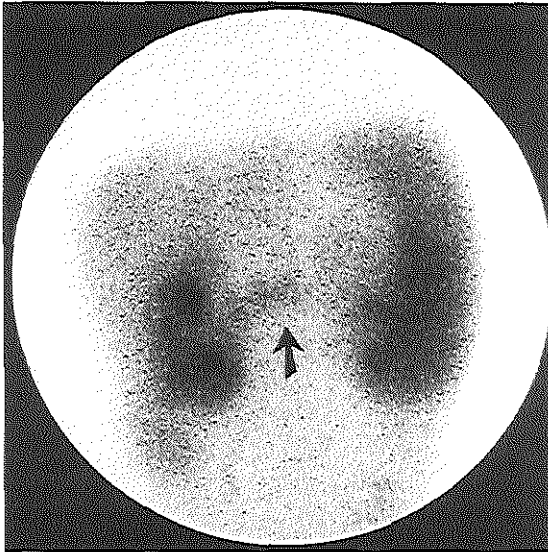


Figure 3

SS-R scintigraphy in 52-y-old woman with low-grade NHL shows pathologic uptake in abdominal region between kidneys (arrow). Normal uptake of radioactivity is seen in enlarged spleen. Normal uptake is also seen in liver and kidneys. CT scan of abdomen showed enlarged mesenteric lymph nodes.

SPECT provided no added value. In only 1 of the patients (9%) with bone marrow infiltration, the SS-R scan revealed marrow positivity. The sensitivity of SS-R scintigraphy for all lesions combined was 55%, varying from 62% for supradiaphragmatic lesions to 44% for lesions below the diaphragm. For nodal lesions, the sensitivity was 56%, and for extranodal sites, it was 45%. The estimated overall

sensitivity of SS-R scintigraphy in the 42 patients with a positive scan was 60%. The specificity of SS-R scintigraphy was high (98%-100%). The intensity of uptake of ^{111}In -pentetreotide in the malignant lesions was negative in 45%, grade 1 in 31%, grade 2 in 23%, and grade 3 in 1%. The maximum uptake of ^{111}In -pentetreotide in the malignant lesions per patient was negative in 16%, grade 1 in 28%, grade 2 in 54%, and grade 3 in 2%. The mean uptake per patient was grade 1.07.

In six lesions, a false-positive result was obtained. In three patients, nonspecific accumulation of radioactivity was caused by recent surgery. Extreme dental caries caused aspecific uptake in the jaws of the fourth patient. The fifth patient suffered from autoimmune hemolytic anemia and showed a high uptake of radioactivity in an enlarged spleen. After a splenectomy, the histopathologic examination did not provide indications of splenic infiltration of NHL. In the last patient, a multinodular goiter caused a high aspecific accumulation of radioactivity in the thyroid. Cytologic and immunologic analyses of a thyroid puncture were negative for NHL.

Sensitivity of several imaging techniques

Table 5 gives the estimated sensitivities of each imaging technique applied, expressed per distinct lymph node region and extranodal site. For the detection of peripheral lymph nodes, the sensitivity of SS-R scintigraphy appears inferior to physical examination and CT scanning. CT scanning is also superior for the visualization of nodal lesions in the thorax and abdominal region. CT scanning and SS-R scintigraphy each have a low sensitivity for gastrointestinal and orbit/eye localizations.

Discussion

SS-R scintigraphy has been shown to be a useful imaging tool in a wide variety of SS-R bearing tumors, including neuroendocrine cancers, brain tumors, breast cancer, and Hodgkin's disease (4,21,22). Although previous *in vitro* studies indicated the presence of SS-Rs in lymph nodes with NHLs (5), only a few studies have used SS-R scintigraphy. These studies were all based on a small number of patients, varying from 4 to 28 patients with NHL (6-13). Therefore, the clinical value of SS-R scintigraphy in the staging of NHLs has not been properly established.

We report on the results of a prospective study that investigated the role of SS-R scintigraphy in the initial work-up of 50 patients with untreated low-grade NHL. Findings in SS-R scans were positive in 84% of the patients. There were 9 patients with a MALT lymphoma in whom SS-R sensitivity was comparatively low. A high proportion (44%) of SS-R scan findings were negative in patients with a MALT NHL. In our study, 3 of 5

patients with primary gastric MALT lymphomas had positive findings. Raderer et al. (23) reported negative SS-R findings in all 15 investigated patients with primary gastric MALT lymphomas. These investigators suggested that the expression of mRNA for SS-R subtypes 3 and 4, but not for SS-R subtype 2, in the gastric samples of their patients might explain the negative scanning results. The low sensitivity of SS-R scintigraphy in MALT lymphomas is similar to that of other imaging modalities, such as CT and FDG PET (24-27).

In 20% of the patients, the new lesions revealed by SS-R scintigraphy resulted in an upgrading of the clinical stage. As a result, these findings would have affected the treatment plan in 10% of the patients. These patients were restaged from stage I to stage III or stage IV and therefore were no longer eligible for curative radiotherapy. This discordance between SS-R scintigraphy and other techniques was not confirmed by biopsy. Although histologic confirmation would have been desirable, this process was not feasible in practice. On the other hand, in a substantial proportion (38%) of patients, lesions disclosed by conventional staging procedures were missed by SS-R scintigraphy. We estimated the lesion-related sensitivity at 55%. The sensitivity varied from 62% for supradiaphragmatic lesions to 44% for lesions below the diaphragm. SPECT of the upper part of the abdomen was of little value. In one patient, only SPECT disclosed an NHL lesion that was not apparent on the planar images. CT was superior to SS-R scintigraphy for the detection of nodal lesions and also for most extranodal sites. However, SS-R scintigraphy was superior to CT for gastrointestinal lesions, although both imaging modalities have a low sensitivity.

The patient- and lesion-related sensitivity of SS-R scintigraphy in this study is higher than that reported by other groups (8,10,12,13), who found lesion-related sensitivities varying from 29% to 35% in patients with low-grade NHL. The number and selection of patients may explain part of this difference in sensitivity. In other published studies, the number of patients investigated with low-grade NHL ranges from 3 to 12 (6-13). In the study reported here, 50 newly diagnosed patients were enrolled, and a relative high proportion of these patients had stage I or stage II disease. Furthermore, differences in imaging protocol and dosage of ^{111}In or pentetretotide may also play a role. The majority of the lesions showed a relative small accumulation of radioactivity (i.e., grade 1 in 31% of lesions). Therefore, it is our opinion that the counting time should be long enough (at least 15 min) and the applied doses of the radionuclide should be sufficiently high (at least 200 MBq) to enhance the visibility of these lesions with relatively low uptake. Interestingly, Lipp et al. (13) were able to improve their previous reported results by doubling the doses of octreotide and ^{111}In and using extended SPECT.

The reported low sensitivity for low-grade NHLs is quite different from that for Hodgkin's disease. We, as well as other groups, have found a distinctly higher sensitivity (94%) in patients with Hodgkin's disease (8,12,21,22,28). This result may be partly explained by the fact that approximately 80% of the lesions in Hodgkin's disease show a high uptake of radioactivity (grade 2 or grade 3) (29). We also found a higher sensitivity (71%) in patients with intermediate- and high-grade NHL (Lugtenburg, data not shown). In patients with low-grade NHL, the intensity of the uptake of radioactivity in the lesions is probably too low for the radiotherapeutic use of high doses of ^{111}In -pentetreotide.

Six false-positive SS-R scintigraphy findings were obtained, and three of these are notable. In the first patient, inflammatory reactions caused by extreme dental caries resulted in aspecific uptake in the jaw. Clinically, this patient suffered from gingivitis and paradontitis. The second patient had autoimmune hemolytic anemia and splenomegaly for several years. A high uptake of radioactivity occurred in the spleen, which histologically was not infiltrated with NHL. The third patient had an enlarged thyroid caused by a multinodular goiter. Cytopathologic examination of the thyroid did not reveal NHL. False-positive uptake in thyroid diseases has been described previously (30). In the last three patients, radioactivity accumulated at sites of recent operation, a known pitfall (4). We agree with Gibril et al. (30), who state that by thoroughly understanding the circumstances that can result in false-positive localization and comparing the SS-R scintigraphy result with the clinical context, a correct diagnosis can be made in almost every case. We found a high specificity for SS-R scintigraphy (98%-100%).

The role of gallium scintigraphy in the staging of patients with NHL is still a subject of controversy. Available data in the literature indicate a low sensitivity of gallium scintigraphy in low-grade NHL. Even in studies using high-dose gallium and modern equipment, low sensitivities are reported ranging from 56% to 79% per patient and 32% to 69% per lesion (31-33). Therefore, gallium scintigraphy currently has no standard place in disease staging of malignant lymphoma. Whole-body FDG PET has been shown to detect both nodal and extranodal sites of disease in patients with Hodgkin's disease and NHL (34,35). Several studies have shown that FDG PET is at least comparable with other imaging modalities such as CT (36,37). Sensitivities of 86%-89% have been reported (38). However, limited data have been published concerning the value of PET in the initial staging of low-grade NHL (38,39).

A shortcoming of our study is that no gold standard was obtained. This is a major problem in tumor staging for tumors that are widespread and cannot be subject to complete histologic evaluation. Sensitivities and specificities are difficult to assess in these types of studies. We defined criteria for assessment of lesions as benign, malignant,

or indeterminate as a second-best alternative. The assessment was based on the results of pathologic examination supplemented by the clinical course. Despite these shortcomings, we believe that the data are sufficiently solid to assess the value of SS-R scintigraphy in the initial staging of low-grade NHL.

Optimal staging of low-grade NHL is important for identifying those patients who present with truly localized disease and may be cured by radiotherapy. Although SS-R scintigraphy findings are positive in 84% of patients with low-grade NHL, our data indicate that SS-R scintigraphy is insufficiently sensitive. In most patients, not all of the lesions can be detected. This lack of sensitivity makes SS-R scintigraphy not generally useful in the initial staging of patients with low-grade NHL. However, its use may be considered in selected patients with stage I or II disease to identify more extended disease. This use, of course, must be weighed against the high costs and patient burden.

Acknowledgments

The authors thank Janneke J. Sluys-Dallinga and Petra Blom, research nurses, for their excellent data management. This study was supported by a grant from the Dutch National Health Care Council.

References

- 1 Portlock CS. Management of the low-grade non-Hodgkin's lymphomas. *Semin Oncol* 17: 51-59, 1990
- 2 Besa PC, McLaughlin PW, Cox JD, LM Fuller. Long term assessment of patterns of treatment failure and survival in patients with stage I or II follicular lymphoma. *Cancer* 75: 2361-2367, 1995
- 3 Mac Manus MP and Hoppe RT. Is radiotherapy curative for stage I and II low-grade follicular lymphoma? Results of a long-term follow-up study of patients treated at Stanford University. *J Clin Oncol* 14: 1282-1290, 1996
- 4 Krenning EP, Kwekkeboom DJ, Bakker WH, Breeman WAP, Kooij PPM, Oei HY, van Hagen M, Postema PTE, de Jong M, Reubi JC, Visser TJ, Reijs AEM, Hofland LJ, Koper JW, Lamberts SWJ. Somatostatin receptor scintigraphy with [¹¹¹In-DTPA-D-Phe¹] and [¹²³I-Tyr³]-octreotide: the Rotterdam experience with more than 1000 patients. *Eur J Nucl Med* 20: 716-731, 1993
- 5 Reubi JC, Waser B, van Hagen M, Lamberts SWJ, Krenning EP, Gebbers JO, Laissue JA. In vitro and in vivo detection of somatostatin receptors in human malignant lymphomas. *Int J Cancer* 50: 895-900, 1992

- 6 Bares R, Galonska P, Dempke W, Handt S, Büll U, Osieka R. Somatostatin receptor scintigraphy in malignant lymphoma: first results and comparison with glucose metabolism measured by positron-emission tomography. *Horm Metab Res Suppl* 27: 56-58, 1993
- 7 Sarda L, Duet M, Zini JM, Berolatti B, Benelhadj S, Tobelem G, Mundler O. Indium-111 pentetreotide scintigraphy in malignant lymphomas. *Eur J Nucl Med* 22:1105-1109, 1995
- 8 Lipp RW, Silly H, Ranner G, Dobnig H, Passath A, Leb G, Krejs GJ. Radiolabeled octreotide for the demonstration of somatostatin receptors in malignant lymphoma and lymphadenopathy. *J Nucl Med* 36: 13-18, 1995
- 9 Goldsmith SJ, Macapinlac HA, O'Brien JP. Somatostatin-receptor imaging in lymphoma. *Semin Nucl Med* 25: 262-271, 1995
- 10 Ivancevic V, Wörmann B, Nauck C, Sandrock D, Munz DL, Hiddemann W, Emrich D. Somatostatin receptor scintigraphy in the staging of lymphomas. *Leuk Lymphoma* 26: 107-114, 1997
- 11 Van Hagen PM, Krenning EP, Reubi JC, Mulder AH, Bakker WH, Oei HY, Löwenberg B, Lamberts SWJ. Somatostatin analogue scintigraphy of malignant lymphomas. *Br J Haematol* 83: 75-79, 1993
- 12 Bong SB, VanderLaan JG, Louwes H, Schuurman JJ. Clinical experience with somatostatin receptor imaging in lymphoma. *Semin Oncol Suppl* 21: 46-50, 1994
- 13 Lipp RW, Schnedl WJ, Aglas F, Ranner G, Beham-Schmid C, Leb G, Sill H. Visualization of non-Hodgkin's lymphoma by high dosed somatostatin receptor specific scintigraphy and extended single photon emission tomography. *Acta Med Austriaca* 26: 105-108, 1999
- 14 The non-Hodgkin's lymphomas pathological classification project. National Cancer Institute sponsored study of classification of non-Hodgkin's lymphoma: Summary and description of a working formulation for clinical usage. *Cancer* 49: 2112-2135, 1982
- 15 Carbone PP, Kaplan HS, Musshoff K, Smithers DW, Tubiana M. Report of the committee on Hodgkin's disease staging classification. *Cancer Res* 31: 1860-1861, 1971
- 16 Krenning EP, Bakker WH, Kooij PPM, Breeman WAP, Oei HY, de Jong M, Reubi JC, Visser TJ, Bruns C, Kwekkeboom DJ, Reijs AEM, van Hagen PM, Koper JW, Lamberts SWJ. Somatostatin receptor scintigraphy with [¹¹¹Indium-DTPA-D-Phe¹]-octreotide in man: metabolism, dosimetry and comparison with [¹²³I-Tyr³]-octreotide. *J Nucl Med* 33: 652-658, 1992
- 17 Krenning EP, Kwekkeboom DJ, de Jong M, Visser TJ, Reubi JC, Bakker WH, Kooij PPM, Lamberts SWJ. Essentials of peptide receptor scintigraphy with emphasis on the somatostatin analog octreotide. *Semin Oncol Suppl* 21: 6-14, 1994

- 18 Krenning EP, Kwekkeboom DJ, Pauwels S, Kvols K, Reubi JC. Somatostatin receptor scintigraphy. In: Freeman LM, ed. *Nuclear Medicine Annual*. New York, Raven Press 1-50, 1995
- 19 Hess CF, Kurtz B, Hoffmann W, Bamberg M. Ultrasound diagnosis of splenic lymphoma: ROC analysis of multidimensional splenic indices. *Br J Radiol* 66: 859-864, 1993
- 20 Munker R, Stengel A, Stähler A, Hiller E, Brehm G. Diagnostic accuracy of ultrasound and computed tomography in the staging of Hodgkin's disease. *Cancer* 76: 1460-1466, 1995
- 21 Van den Anker-Lugtenburg PJ, Krenning EP, Oei HY, van Hagen MP, Gerrits CJH, Reubi JC, Lamberts SWJ, Löwenberg B. Somatostatin receptor scintigraphy in the initial staging of Hodgkin's disease. *Br J Haematol* 93: 96-103, 1996
- 22 Van den Anker-Lugtenburg PJ, Löwenberg B, Lamberts SWJ, Krenning EP. The relevance of somatostatin receptor expression in malignant lymphomas. *Metabolism Suppl* 45: 96-97, 1996
- 23 Raderer M, Valencak J, Pfeffel F, Drach J, Pangerl T, Kurtaran A, Hejna M, Vorbeck F, Chott A, Virgolini I. Somatostatin receptor expression in primary gastric versus nongastric extranodal B-cell lymphoma of mucosa-associated lymphoid tissue type. *J Nat Cancer Inst* 91: 716-718, 1999
- 24 Grau E, Gomez A, Cunat A, Oltra C. Computed tomography in staging of primary gastric lymphoma. *Lancet* 347: 1261, 1996
- 25 Ferreri AJ, Ponzoni M, Cordio S, Vanzulli A, Garuti E, Viale E, Villa E. Low sensitivity of computed tomography in the staging of gastric lymphomas of mucosa-associated tissue: impact on prospective trials and ordinary clinical practice. *Am J Clin Oncol* 21: 614-616, 1998
- 26 Rodriguez M, Ahlström H, Sundin A, Rehn S, Sundström C, Hagberg H, Glimelius B. [¹⁸F] FDG PET in gastric non-Hodgkin's lymphoma. *Acta Oncol* 36: 577-584, 1997
- 27 Hoffmann M, Kletter K, Diemling M, Becherer A, Pfeffel F, Petkov V, Chott A, Raderer M. Positron emission tomography with fluorine-18-2-fluoro-2-deoxy-D-glucose (F18-FDG) does not visualize extranodal B-cell lymphoma of the mucosa-associated lymphoid tissue (MALT)-type. *Ann Oncol* 10: 1185-1189, 1999
- 28 Lugtenburg PJ, Löwenberg B, Eijkemans MJC, Habbema JDF, Lamberts SWJ, Valkema R, Krenning EP. Somatostatin receptor scintigraphy in limited Hodgkin's disease: clinical impact and cost-effectiveness analysis. *J Nucl Med (abstract)* 39: 39p, 1998
- 29 Van den Anker-Lugtenburg PJ, Löwenberg B, Lamberts SWJ, Oei HY, Valkema R, Krenning EP. Somatostatin receptor scintigraphy with 111-Indium pentetretotide for staging of Hodgkin's lymphomas. *J Nucl Med (abstract)* 38: 102p, 1997

- 30 Gibril F, Reynolds JC, Chen CC, Yu F, Goebel SU, Serrano J, Doppman JL. Specificity of somatostatin receptor scintigraphy: a prospective study and effects of false-positive localizations on management in patients with gastrinomas. *J Nucl Med* 40: 539-553, 1999
- 31 Waxman AD, Eller D, Ashook G, Ramanna L, Brachman M, Heifetz L, McAndrews P, Bierman H, Taub R, Avedon M, Wall F. Comparison of gallium-67-citrate and thallium-201 scintigraphy in peripheral and intrathoracic lymphoma. *J Nucl Med* 37: 46-50, 1996
- 32 Ben-Haim S, Bar-Shalom R, Israel O, Haim N, Epelbaum R, Ben-Shachar M, Gaitini D, Kolodny GM, Front D. Utility of gallium-67 scintigraphy in low-grade non-Hodgkin's lymphoma. *J Clin Oncol* 14: 1936-1942, 1996
- 33 Gallamini A, Biggi A, Fruttero A, Pugno F, Cavallero G, Pregno P, Grasso M, Farinelli C, Leone A, Gallo E. Revisiting the prognostic role of gallium scintigraphy in low-grade non-Hodgkin's lymphoma. *Eur J Nucl Med* 24: 1499-1506, 1997
- 34 Moog F, Bangerter M, Diederichs CG, Guhlmann A, Kotzerke J, Merkle E, Kolokythas O, Herrmann F, Reske SN. Lymphoma: role of whole-body 2-deoxy-2-[F-18]fluoro-D-glucose (FDG) PET in nodal staging. *Radiology* 203: 795-800, 1997
- 35 Moog F, Bangerter M, Diederichs CG, Guhlmann A, Merkle E, Frickhofen N, Reske SN. Extranodal malignant lymphoma: detection with FDG PET versus CT. *Radiology* 206: 475-481, 1998
- 36 Newman JS, Francis IR, Kaminski MS, Wahl RL. Imaging of lymphoma with PET with [¹⁸F]-FDG: correlation with CT. *Radiology* 190: 111-116, 1994
- 37 Hoh CK, Glaspy J, Rosen P, Dahlbom M, Lee SJ, Kunkel L, Hawkin RA, Maddahi J, Phelps M. Whole-body FDG-PET imaging for staging of Hodgkin's disease and lymphoma. *J Nucl Med* 38: 343-348, 1997
- 38 Stumpe KD, Urbinelli M, Steinert HC, Glanzmann C, Buck A, von Schulthess GK. Whole-body positron emission tomography using fluorodeoxyglucose for staging of lymphoma: effectiveness and comparison with computed tomography. *Eur J Nucl Med* 25: 721-728, 1998
- 39 Jerusalem G, Warland V, Najjar F, Paulus P, Fassotte MF, Fillet G, Rigo P. Whole-body ¹⁸F-FDG PET for the evaluation of patients with Hodgkin's disease and non-Hodgkin's lymphoma. *Nucl Med Commun* 20: 13-20, 1999

CHAPTER 6

Somatostatin receptor scintigraphy in the initial staging of intermediate- and high-grade non-Hodgkin's lymphomas

P.J. Lugtenburg^{1,6}, E.P. Krenning^{2,3}, R. Valkema², H.Y. Oei², S.W.J. Lamberts³,
M.J.C. Eijkemans⁴, W.L.J. van Putten⁵, B. Löwenberg^{1,6}

¹Dept. of Hematology, University Hospital and Erasmus University Rotterdam

²Dept. of Nuclear Medicine, University Hospital and Erasmus University Rotterdam

³Dept. of Internal Medicine, University Hospital and Erasmus University Rotterdam

⁴Dept. of Public Health, Erasmus University Rotterdam

⁵Dept. of Statistics, University Hospital and Erasmus University Rotterdam

⁶Dept. of Hematology, Daniel den Hoed Cancer Center, Rotterdam

The Netherlands

Haematol J in press

Abstract

In patients with intermediate- and high-grade non-Hodgkin's lymphoma (NHL) the stage of disease is a major prognostic factor, which has important implications on therapeutic strategy. Somatostatin receptor scintigraphy has been demonstrated to be successful in the visualization of SS-R bearing tumors. In this prospective study SS-R scintigraphy was compared with conventional staging techniques for the initial staging of patients with intermediate- and high-grade NHL. Ninety-four, newly diagnosed and previously untreated patients with intermediate- and high-grade NHL underwent SS-R scintigraphy in addition to the standard diagnostic work-up. Planar images were obtained 24 and 48 h after intravenous injection of 220 MBq ^{111}In -pentetreotide. SPECT images were performed in all patients. The SS-R scan was positive in 85 of 94 (90%) patients. In 19 patients (20%) the SS-R scan revealed new lesions suggestive of NHL, which had not been demonstrated following conventional staging procedures. In these 19 patients, as a consequence of the different SS-R scintigraphy findings, the clinical stage was upgraded. Consequently, the treatment plan would have been altered in 17 patients (18%). In 17 patients (18%) lesions apparent following conventional staging methods were not visualized by SS-R scintigraphy. The sensitivity of SS-R scintigraphy varied from 77% for supradiaphragmatic lesions to 57% for infradiaphragmatic lesions. The specificity of SS-R scintigraphy was high (98%-100%). Our data indicate that SS-R may be useful in patients with clinical stage I intermediate- and high-grade NHL, where it may distinguish a subset of patients with extended NHL.

Introduction

In patients with intermediate- and high-grade non-Hodgkin's lymphomas (NHLs) it is important to distinguish between stage I and stage II-IV disease, because the choice of treatment is influenced by the stage of disease. The majority of patients (80%-90%) with truly localized stage I disease enjoy durable relapse free survival following short-course combination chemotherapy with or without radiotherapy (1-3). The treatment of choice for patients with more advanced disease is combination chemotherapy with long term disease free survival of approximately 30% (4). It is therefore essential that the patient is accurately staged at the time of diagnosis.

A wide variety of imaging studies have been utilized in the staging of NHL. These include chest X-ray, computed tomography (CT) scan, lymphangiogram, ultrasound scan and magnetic resonance imaging (MRI). Of the radionuclide imaging techniques, gallium scintigraphy can be useful, especially in re-evaluating patients after therapy. This holds particularly for those with residual masses (5,6). In the last decades considerable

technologic advances in diagnostic radiology have been made. Spiral computed tomography is standard today. Despite these technical improvements however, assessment of intra-abdominal nodal or organ involvement still represents a clinical problem.

Somatostatin receptors (SS-Rs) are expressed on the surface of neoplastic cells in a wide variety of human tumors (7). SS-R scintigraphy with the radioactive somatostatin analog ^{111}In -pentetretotide has been demonstrated to be useful in imaging of SS-R bearing tumors, such as neuroendocrine cancers, brain tumors and breast cancer (7). By use of in vitro autoradiography the presence of SS-Rs were demonstrated in lymph nodes infiltrated with NHL (8). Particularly lymphomas of high-grade malignancy expressed SS-Rs at a high density. Studies assessing the clinical value of SS-R scintigraphy in the staging of NHLs are scarce. They are based on relatively small numbers of patients and heterogeneous patient groups (9-17). Hence, the diagnostic value of SS-R scintigraphy in patients with aggressive NHL has not been settled.

Here, we report the results of a prospective study in 94 newly diagnosed patients with intermediate- and high-grade NHL, in which the findings of SS-R scintigraphy were evaluated in relation with those of the conventional work-up.

Patients and methods

Patients

Ninety-four consecutive, newly diagnosed and previously untreated patients with intermediate- and high-grade NHL were enrolled in a prospective study. The diagnosis of NHL had been substantiated by histologic and immunohistologic methods. Pathological diagnosis was classified according to the Working Formulation (18). The stage of the disease according to the Ann Arbor classification (19) was established following physical examination, inspection of the Waldeyer's ring by an ear, nose, and throat specialist, chest radiography and CT scanning of chest, abdomen and pelvis and sometimes ultrasonography of the neck or abdomen. The diagnosis of bone marrow involvement was always verified after cytologic, immunologic, and histopathologic examination of marrow aspiration and biopsy. CT scanning was performed with contiguous 10 mm axial sections after oral and intravenous administration of contrast material. All patients had given informed consent to the study, which had been approved by the ethics committee of the University Hospital Rotterdam.

SS-R scintigraphy

In addition to the standard diagnostic work-up (see above), SS-R scintigraphy was planned. All examinations were completed before initiation of therapy. Patients were injected intravenously with 220 MBq ^{111}In -labeled pentetretotide (OctreoScan, Mallinckrodt Medical BV, Petten, The Netherlands). Planar total body scintigraphy was performed 24 h after injection with a large-field-of-view gamma camera (Counterbalance 3700 and ROTA II; Siemens Gammasonics, Erlangen, Germany) equipped with a medium-energy collimator. Repeated scintigrams were obtained 48 h after injection, when accumulation of radioactivity in the abdomen was observed on the 24-h scintigrams. Laxatives were given to reduce the presence of intestinal radioactivity, caused by some hepatobiliary clearance of ^{111}In -pentetretotide. Head and neck images were obtained anteriorly and laterally from both sides. The remainder of the body was imaged with separate anterior and posterior images of the thorax, upper abdomen (including liver/spleen and kidneys), lower abdomen and extremities. The thorax was imaged with arms elevated. Preset counts were 300.000 for the head and neck and 500.000 for the thorax and abdomen or a maximum of 15 minutes. In all patients SPECT images of the upper abdomen were made 24 h after injection using a triple-head camera (3000XP, Picker, Cleveland, OH). SPECT data were reconstructed by filtered backprojection. A detailed description of the scanning protocol is given in several reviews (20-22). In healthy individuals a physiologic accumulation of radioactivity may be seen at 24 h after injection of ^{111}In -pentetretotide in the pituitary gland, thyroid gland, liver, spleen, kidneys, intestines, urinary bladder, and, frequently the gallbladder. Accumulation of radioactivity at other sites is considered to be abnormal and indicates the presence of pathologic SS-R positive tissue. In organs with physiologic uptake of ^{111}In -pentetretotide (e.g. liver and spleen), inhomogeneous or focal uptake patterns were considered to be indicative of lymphoma. Independent, blinded evaluation of SS-R scans was performed by two experienced nuclear medicine physicians at the same time. If initial interpretations were different (occurring in less than 5% of cases), a blind discussion was held until consensus was reached. The intensity of pathologic uptake of ^{111}In -pentetretotide in the lesions observed on the planar images was graded semiquantitatively as follows: grade 0 = negative, no abnormal activity; grade 1 = equivocally positive, small amount of accumulation of radioactivity; grade 2 = clear accumulation of radioactivity, intensity less than that of the liver; grade 3 = clear accumulation of radioactivity, intensity equal to or greater than that of the liver. The SS-R scan was considered positive in any given patient if at least one of the identified lymphoma lesions was positive on the scan (grade 1, 2 or 3).

Assessment of the true state of a lesion or a region

CT scans and other radiologic tests were evaluated by experienced radiologists without knowledge of SS-R scintigraphy data. Lymph nodes of more than 15 mm in diameter were considered unequivocally abnormal on CT scanning or ultrasonography and were interpreted to represent NHL. Lymph nodes of less than 10 mm were considered benign. Lymph nodes with a diameter between 10 mm and 15 mm were considered equivocal. CT and ultrasound criteria for involvement in normal-sized spleen or liver included unexplained infiltrates or focal abnormalities of decreased attenuation. The spleen was considered enlarged on the CT scan, ultrasonography or SS-R scan if the longitudinal diameter was greater than 130 mm (23,24).

Findings of SS-R scintigraphy were compared with the sum of conventional staging procedures. The following lymph node regions were evaluated: occipital left/right, upper cervical left/right, medial cervical left/right, supraclavicular left/right, submandibular left/right, preauricular left/right, infraclavicular left/right, axillary left/right, brachial left/right, mediastinal, lung-hilar left/right, para-aortic (including celiac nodes and nodes from the hepatic and splenic hili), iliac left/right, inguinal left/right, femoral left/right, popliteal left/right, mesenteric and the Waldeyer's ring. In addition, all possible extranodal sites of involvement were also evaluated. This resulted in a total of 70 possibly involved lymph node regions and extranodal sites. In case of discrepant findings between SS-R scintigraphy and conventional staging procedures, we attempted to determine the status of the lesion. Discrepant findings were verified if possible by biopsy or by using non-invasive methods, including ultrasonography, MRI, CT or bone scintigraphy. All patients were followed during and after therapy. For any documented lesion a final assessment was made of its true state as benign, malignant, or indeterminate. This assessment was based on the results of pathologic examination (histology or cytology if done), supplemented by the subsequent clinical course. A lesion was considered benign because of pathologic evidence or if the size was less than 10 mm in long-axis measurements and the lesion did not grow in size. A lesion was considered malignant because of pathologic evidence or if the largest diameter was more than 15 mm, or in retrospect on the basis of the clinical course (disappearance or change in size of a lesion of more than 10 mm after therapy). The status of the lesion was considered indeterminate if the nature of the lesion could not be assessed from the data. Regions without lesions on any test were considered to have a true state of absence of disease. The spleen was considered positive for NHL if there was unequivocal palpable splenomegaly alone or equivocal palpable splenomegaly with radiologic confirmation of either enlargement or multiple focal defects that were neither cystic nor vascular. Liver

involvement was diagnosed if there were multiple focal defects, which were not cystic or vascular, noted with at least two imaging techniques.

Assessment of sensitivity and specificity of a test

The sensitivity and specificity of the different tests were calculated separately for each of the regions for which each test was performed. For the calculation of sensitivity, the lesions with a true state of malignancy were used, whereas for the calculation of specificity, the regions with no lesions or only lesions with a final assessment of benign were used. The sensitivity of a test for a lymph node region or extranodal site was defined as the number of lesions with a positive test result for that region divided by the total number of lesions with a final assessment of malignant in that region. The specificity of a test for a lymph node region or extranodal site was defined as the number of patients with a negative test result divided by the total number of patients tested with a true state of benign/absent in that region.

Results

Patients

The clinical characteristics of the 94 patients with intermediate- and high-grade NHL enrolled on study are listed in Table 1. Forty-five percent of patients presented with diffuse large cell lymphoma. Forty percent of the patients had localized stage I disease and 31% stage IV. The majority (89%) of NHLs were immunophenotypically classified as B-cell lineage. T-cell lymphomas were a minority (8%). Details of the anatomic distribution of the malignant lesions are given in Table 2. Lymph nodes in the neck were seen in 53% of patients. Forty-five patients (48%) presented with infradiaphragmatic disease. In the latter instances the para-aortic lymph nodes were most frequently involved (33% of patients). The most frequent sites of extranodal involvement were the bones, stomach, testis and lung. Bone marrow infiltration with NHL was apparent in 10 patients (11%).

Comparison of SS-R scintigraphy with conventional staging procedures

The SS-R scan was positive in 85 of 94 (90%) patients. An entirely negative scan was seen in 9 of 94 (10%) patients. All patients with a T-cell lymphoma were positive on SS-R scintigraphy. There was no apparent relationship between the pathologic classification and the probability of a negative SS-R scan.

In Table 3, an overview is given of a comparison between the results of SS-R scintigraphy and the conventional staging procedures (exclusive bone marrow

Table 1. Clinical characteristics of 94 patients with intermediate- and high-grade NHL

Age (years)	
Median	58
Range	18-81
Sex	
Male	62 (66%)
Female	32 (34%)
Ann Arbor clinical stage*	
Stage I	38 (40%)
Stage II	18 (19%)
Stage III	9 (10%)
Stage IV	29 (31%)
Histologic subtype (Working Formulation)	
D: follicular, predominantly large cell	1 (1%)
E: diffuse, small cleaved cell	2 (2%)
F: diffuse, mixed small cleaved and large cell	18 (19%)
G: diffuse, large cell	42 (45%)
H: large cell, immunoblastic	8 (9%)
I: lymphoblastic	1 (1%)
MALT	6 (6%)
Unclassifiable intermediate/high grade	16 (17%)
Immunophenotype	
B-cell	84 (89%)
T-cell	7 (8%)
Other	3 (3%)

*based on the results of the standard staging procedures.

examination) in the 94 patients. In 19 patients (20%) the SS-R scan revealed new lesions indicative of NHL that had not been demonstrated following conventional staging procedures. In 6 of the latter 19 patients additional biopsy (n = 1) or the subsequent clinical course (n = 5) provided additional support for active NHL at the positive sites of SS-R scintigraphy. In 17 patients (18%) lesions demonstrated following conventional staging were not apparent on SS-R scintigraphy. Furthermore, in 17 patients (18%) the results of the comparison were mixed, i.e. in the same patient new lesions were disclosed by SS-R scintigraphy, but other lesions were missed. The results of SS-R scintigraphy and conventional staging procedures were entirely concordant in 44% of the patients.

Table 2. Distribution of 270 malignant lesions in 94 patients with intermediate- and high-grade NHL*

Localization malignant lesion	% of patients
Neck lymph nodes	53
Para-aortic lymph nodes	33
Mediastinal lymph nodes	25
Waldeyer's ring	20
Axillary lymph nodes	15
Mesenteric lymph nodes	9
Bones	9
Inguinal lymph nodes	7
Iliac lymph nodes	7
Spleen	7
Stomach	7
Testis	6
Lung	5
Intestine	4
Lung hilar lymph nodes	3
Skin	3
CNS	3
Thyroid	3
Kidney	2
Sinus/nose	2
Mamma	2
Liver	1
Adrenal gland	1

*diagnosed on basis of conventional staging procedures and SS-R scintigraphy.

Table 3. Comparison of results of SS-R scintigraphy with those of conventional staging in 94 patients with intermediate- and high-grade NHL

Result	Patients	
	Number	%
SS-R scan detects new lesions	19	20
SS-R scan misses lesions	17	18
SS-R scan detects new lesions and misses lesions in same patient	17	18
Agreement between SS-R scan and conventional staging procedures	41	44

Table 4 shows the overall clinical stage based on the outcome of the conventional staging procedures (excluding the bone marrow evaluation) in comparison with the clinical stage established by SS-R scintigraphy findings only.

Table 4. Clinical stage based on the SS-R scintigraphy findings compared with the clinical stage based on the results of the conventional work-up

Stage based on SS-R scan only	Stage based on conventional staging procedures*				
	I	II	III	IV	Total
I	21	3 [†]	1 [†]	6 [*]	31
II	5 [†]	13	1	4	23
III	5 [†]	2	7	5	19
IV	7 [†]	0	0	14	21
Total	38	18	9	29	94

[†]indicate a change in clinical stage with potential consequences for the treatment choice

*conventional staging methods exclusive bone marrow pathology.

As a result of the additional SS-R scintigraphy findings the clinical stage would have been upgraded in 19 patients (20%). Consequently, the treatment plan would have been altered in 17 patients (18%). There were 20 patients (21%), in whom SS-R scintigraphy did not show otherwise apparent localizations of NHL, so that the clinical stage would have been underestimated, when based on the results of SS-R scintigraphy only.

Lesion- related sensitivity and specificity of SS-R scintigraphy

In the 94 patients, a total of 270 malignant lesions were distinguished considering the results of physical examination in combination with SS-R scintigraphy, X-ray, CT scanning, ultrasound, histopathology and considering the outcome of subsequent follow up. Of these, 175 lesions were localized above the diaphragm, 83 lesions were below the diaphragm and 12 were elsewhere. A minority of the lesions was extranodal (n = 54). In Table 5 the sensitivities of SS-R scintigraphy are given for detecting NHL in each of the lymph node regions and extranodal sites. For supradiaphragmatic nodal lesions the sensitivity varied from 61%-100%. A consistently high sensitivity was obtained for lesions in the supraclavicular region and mediastinum, respectively 91% and 87% (Figure 1). The smallest NHL lesion above the diaphragm that was correctly visualized by SS-R scintigraphy was located in the supraclavicular region and had a diameter of 0.5 cm. The largest supradiaphragmatic lesion that was missed on SS-R scintigraphy had a diameter of 4.0 cm and was located in the Waldeyer's ring. The scintigraphic sensitivity for the detection of NHL involvement in the abdominal and inguinal region ranged from 33% to 86% (Figure 2). Only 33% of gastrointestinal lymphomas were seen on SS-R scintigraphy. In the para-aortic region small lymph nodes of 1.0 cm diameter were

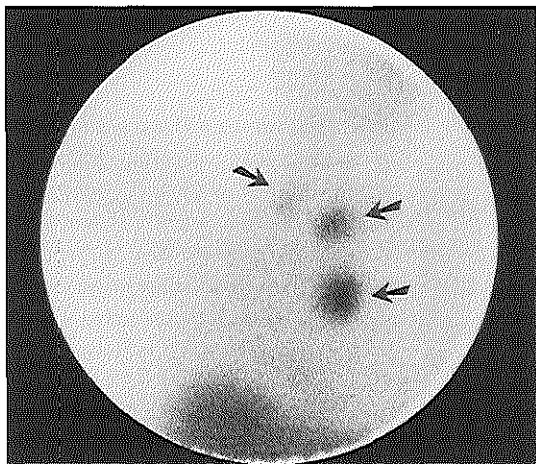


Figure 1

In this 53 year old man who presented with bilateral enlarged lymph nodes in the neck a high-grade malignancy NHL was diagnosed. Anterior image of the thorax at 24 h. SS-R scintigraphy showed clear uptake in supraclavicular lymph nodes on both sides and in the mediastinum (arrows).

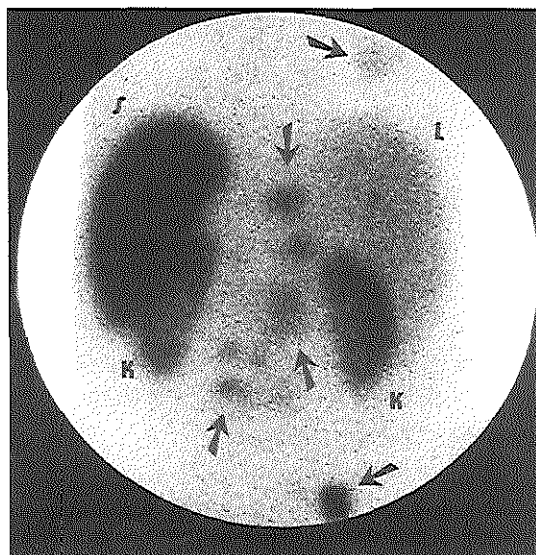


Figure 2

SS-R scintigraphy in a 79 year old man with a high-grade malignancy NHL and abdominal lymphoma localizations. Posterior view of the upper abdomen at 24 h. Pathological uptake is seen in the right lung (arrow), para-aortic, iliac and mesenteric lymph nodes (arrows). Note the high uptake in the enlarged spleen (S). Physiologic uptake is seen in the liver (L) and kidneys (K).

detected by SS-R scintigraphy. However, one mesenteric lymph node mass of 15.0 cm diameter was missed by SS-R scintigraphy. In three patients localizations of NHL in the stomach and para-aortic region were demonstrated by SPECT only, while it had not been visualized on the planar images. In the other patients SPECT had no added value. The SS-R scan revealed all breast (2/2), skin (3/3) and bone (7/7) lesions (Figure 3). However, lesions in the kidneys ($n = 3$) and adrenal glands ($n = 2$) were missed. In only one of ten patients (10%) with bone marrow infiltration, the SS-R scan revealed marrow positivity.

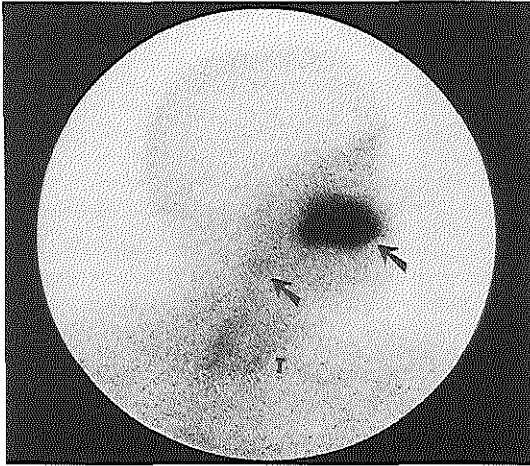


Figure 3

SS-R scintigraphy in a 64 year old man with an intermediate-grade malignancy NHL of the right maxilla and midcervical lymph nodes at the right side of the neck. Right lateral anterior view of the head and neck at 24 h after injection. Clear visualization of the tumor in the maxilla (grade 3 uptake, arrow) and small amount of accumulation of radioactivity in the lymph nodes in the neck (grade 1 uptake, arrow). Physiologic uptake is seen in the thyroid (T).

The sensitivity of SS-R scintigraphy for all lesions combined was 71%, varying from 77% for supradiaphragmatic lesions to 57% for lesions below the diaphragm. For nodal lesions the sensitivity was 72% and for extranodal sites 65%. The specificity of SS-R scintigraphy was high (98%-100%). The intensity of uptake of ^{111}In -pentetretotide in the malignant lesions was: negative in 30%, grade 1 in 15%, grade 2 in 39% and grade 3 in 16%. The maximum uptake of ^{111}In -pentetretotide in the malignant lesions per patient was: negative in 12%, grade 1 in 16%, grade 2 in 46% and grade 3 in 26%.

The SS-R scan detected 70 lesions in 38 patients for which the true state could not be reliably derived from histology, cytology or follow up. None of these lesions were detected by the other tests, except for one lesion in the lung-hilus that was positive on both the SS-R scan and X-thorax, but was not picked up by the CT scan. These lesions were excluded from the calculations of sensitivity and specificity.

In 8 lesions, a false-positive result was obtained. In three patients nonspecific accumulation of radioactivity was caused by recent surgery (two hematomas and one surgical scar). A cerebral infarction caused aspecific uptake in the brain in the fourth patient. The fifth and sixth patient suffered from pneumonia and showed high uptake of radioactivity in the lungs. The seventh patient had grade 2 uptake in the submandibular region. Following palpation a mass of 1.5 cm was shown. Histopathologic examination showed a salivary gland infiltrated with adenoid cystic carcinoma. In the last patient a histologically proven neurinoma (2.0 cm) caused grade 3 uptake of radioactivity in the supraclavicular region.

Sensitivity of several imaging techniques

Table 5 gives the estimated sensitivities of each of the imaging techniques applied, expressed per distinct lymph node region and individual extranodal site. In comparison with CT scanning, SS-R scintigraphy is inferior for the detection of NHL lesions in the thorax and abdomen. CT scanning and SS-R scintigraphy share a low sensitivity for the visualization of NHL in the stomach and intestine. In the supraclavicular region SS-R scintigraphy offers the highest sensitivity.

Discussion

Several years ago the successful in vivo visualization of lymphoma lesions by SS-R scintigraphy after intravenous injection of ^{111}In -pentetretotide was reported (7-9,14). Shortly thereafter in vitro studies indicated the presence of SS-Rs in lymph nodes with NHL (8). Surprisingly, at present only a few studies have assessed the clinical value of SS-R scintigraphy in NHL.

Here we report a prospective study in 94 patients with newly diagnosed untreated intermediate- and high-grade NHL, in whom the SS-R scan was positive in 90% of cases. Both intermediate-grade and high-grade NHL were positive on SS-R scintigraphy. There was no apparent relationship between the histologic subtype according to the Working Formulation and the likelihood of a positive SS-R scan. This high rate of positive scans is in agreement with the high incidence of SS-R expression in NHL biopsies (8,14). To our knowledge this is the first study in which the effectiveness of other imaging and staging modalities as X-ray, CT scanning, ultrasonography and physical examination was prospectively assessed and compared with that of SS-R scintigraphy. CT scanning was superior to SS-R scintigraphy for the detection of nodal lesions in the thorax and abdomen. Only in the supraclavicular region SS-R scintigraphy obtained the highest diagnostic yield.

Previously unsuspected localizations, not recognized with other staging techniques, were found in 20% of patients by SS-R scintigraphy. In these patients the clinical value of SS-R scintigraphy was demonstrated by an upgrading of the clinical stage. As a consequence of the additional lesions that were detected by SS-R scintigraphy 17 of 94 (18%) patients were upstaged from stage I to stage II, III or IV disease. This change in stage is of therapeutic and prognostic importance. Stage I disease is generally treated with a limited series of 3 to 4 courses of chemotherapy with or without involved field radiotherapy. In contrast to more advanced disease, for which more extended chemotherapy is given. The additional findings of NHL on SS-R scintigraphy could be confirmed by biopsy in one patient. Furthermore, in 25% of the additional lesions identified by SS-R scanning the

Table 5. Sensitivity of various diagnostic approaches for the detection of intermediate-and high-grade NHL lesions in different lymph node regions and extranodal sites

Localization of malignant lesion	Number of malignant lesions	Physical examination (%)	Chest radiograph (%)	CT scan (%)	Sonography (%)	SS-R scan (%)
Cervical lymph nodes*	56	84			83 (36)	68
Supraclavicular lymph nodes	32	66			70 (20)	91
Axillary lymph nodes	18	72		89		72
Mediastinal lymph nodes	23		64 (22)	91		87
Lung-hilar lymph nodes	3		100	100		100
Waldeyer's ring	18	89		100 (7)		61
Lung	9		67	89		67
Para-aortic lymph nodes	31			84	67 (12)	61
Mesenteric lymph nodes	8			100	80 (5)	50
Inguinal lymph nodes	11	82		100		64
Iliac lymph nodes	10			70		70
Stomach/intestine	9			33		33
Spleen	7	43		100	100 (5)	86

* occipital, submandibular and cervical lymph nodes; LAG, bipedal lymphangiography. Numbers in parentheses indicate frequency at which the test was performed and are given only if different from number of malignant lesions.

clinical data were consistent with NHL involvement at those sites. If the clinical stage had been based on the SS-R scintigraphy findings only, the stage would have been underestimated in 21% of cases. Thus, because certain lesions were not visualized on SS-R scanning, the best results are apparently obtained if SS-R scintigraphy is performed in addition to CT scanning.

We estimated the overall lesion-related sensitivity of SS-R scintigraphy at 71%. The sensitivity varied from a satisfactory value of 77% for supradiaphragmatic lesions to an unsatisfactory estimate of 57% for lesions below the diaphragm. SPECT imaging can increase the diagnostic effectiveness compared with planar SS-R scanning. However, SPECT of the upper part of the abdomen was of limited value. In three patients SPECT disclosed NHL lesions that were not visualized on the planar images.

The low sensitivity in the abdominal region is also seen in low-grade NHL and Hodgkin's disease (Table 6) (25-27). Various factors are considered to interfere with the visualization of SS-R positive tumors with ^{111}In -pentetreotide. Lymphoma lesions that are situated in or close to organs that accumulate the radioligand by receptor binding or clearance are difficult to detect selectively. Notoriously difficult areas for NHL staging by SS-R scintigraphy are the para-aortic and mesenteric lymph node regions and

Table 6. Patient- and lesion- related sensitivity of SS-R scintigraphy in malignant lymphoma

Diagnosis (ref)	Number of patients	Uptake score 2 or 3 (% of lesions)	Patient sensitivity %	Lesion sensitivity %		
				Total	Above diaphragm	Below diaphragm
LG-NHL (27)	50	24	84	55	62	44
IH-NHL	94	55	90	71	77	57
HD (25,26)	126	79	100	94	98	67

LG-NHL, low-grade NHL; IH-NHL, intermediate- and high-grade NHL; HD, Hodgkin's disease.

lymphoma infiltration in liver, spleen and kidneys. SS-R scintigraphy shares this lack of sensitivity in the abdominal region with other imaging modalities like ultrasonography, CT scanning and gallium scintigraphy.

The sensitivity of SS-R scintigraphy in intermediate- and high-grade NHL in our study is better than that reported by certain other groups. In three studies a lesion-related sensitivity of approximately 44% was found (9,11,13). However, the conclusions of these studies are based on only 6-10 patients with high-grade NHL. Our results are similar to those obtained by Bong et al, who reported a sensitivity of 72% in 26 patients with

intermediate- and high-grade NHL (15). Not only patient number and selection, but most likely also differences in imaging protocol and dosage of ^{111}In -pentetreotide may explain part of the reported differences in sensitivity.

SS-R scintigraphy is positive in Hodgkin's disease as well as in NHL of low- and intermediate- and high-grade malignancy (Table 6) (9-17,25-27). The best results are obtained in Hodgkin's disease, where positive scans are found in all patients and the majority of lesions are visualized (25,26). Although the SS-R scan is positive in most patients with low-grade NHL, only approximately half of the lesions indeed are revealed *in vivo* by SS-R scintigraphy (27). We determined the intensity of uptake of radioactivity in the malignant lesions of all our patients with malignant lymphoma (Table 6). Interestingly, the highest uptake is seen in patients with Hodgkin's disease and the lowest in patients with low-grade NHL (26,27). The sensitivity of SS-R scintigraphy appears to correlate with the intensity of uptake of the radioligand in the lesions. Sarda et al also found a lower sensitivity and a low tracer uptake in low-grade NHLs, although in a much smaller patient group (10).

SS-R scintigraphy is a sensitive technique to show *in vivo* the presence and abundance of SS-Rs. Recently, a new therapy was developed taking advantage of this information. Several patients with end-stage neuroendocrine tumors were treated with multiple high doses of ^{111}In -pentetreotide. The results were promising and there was a tendency towards better results in patients whose tumors showed a higher accumulation of the radioligand (28).

The limitation of the specificity of SS-R scintigraphy for NHL is caused by the fact that SS-Rs are expressed in various other malignant tissues, e.g., neuroendocrine tumors, breast tumors, brain tumors and Hodgkin's disease (7). Granulomatous and autoimmune diseases may also express SS-Rs (29,30). We obtained false-positive results in 8 patients. In five of these cases recent surgery and infections had caused the aspecific uptake of radioactivity. These obviously pitfalls must be born in mind for a correct interpretation of SS-R scintigrams (7,31). In two other cases a carcinoma of the salivary gland and a neurinoma gave a false-positive scan.

Gallium scintigraphy using high-dose, modern equipment and SPECT may play an important role in the evaluation of the treatment response in patients with NHL (5,6,32,33). However, in the initial staging of patients with newly diagnosed NHL the role of gallium scintigraphy is still subject of controversy. Prospective studies using high-dose gallium and modern equipment in untreated patients with intermediate- and high-grade NHL are scarce. Sensitivities have ranged from 59%-89% (34-38). Whole body FDG-PET has been shown to detect both nodal and extranodal sites of disease in patients

with HD and NHL (39–42). Although preliminary results are encouraging, its role in the staging of NHL has yet to be defined.

Optimal staging of intermediate- and high-grade NHL is important for identifying those patients who present with truly localized stage I disease. As SS-R scintigraphy is positive in the majority of patients (90%) with intermediate- and high-grade NHL, SS-R scintigraphy may be applied together with CT scanning for more accurate staging in selected patients with NHL. SS-R scintigraphy may be particularly useful in individuals with clinical stage I NHL, where it may distinguish a subset of patients with extended lymphoma.

Acknowledgments

The authors thank Janneke J. Sluys-Dallinga and Petra Blom, research nurses, for their excellent data management. This study was supported by a grant from the Dutch National Health Care Council.

References

- 1 Longo DL, Glatstein E, Duffey PL, Ihde DC, Hubbard SM, Fischer RI, Jaffe ES, Gilliom M, Young RC, DeVita Jr VT. Treatment of localized aggressive lymphomas with combination chemotherapy followed by involved-field radiation therapy. *J Clin Oncol* 7: 1295-1302, 1989
- 2 Tondini C, Zanini M, Lombardi F, Bengala C, Rocca A, Giardini R, Buzzoni R, Valagussa P, Bonnadonna G. Combined modality treatment with primary CHOP chemotherapy followed by locoregional irradiation in stage I or II histologically aggressive non-Hodgkin's lymphomas. *J Clin Oncol* 11: 720-725, 1993
- 3 Miller TP, Dahlberg S, Cassady JR, Adelstein DJ, Spier CM, Grogan TM, LeBlanc M, Carlin S, Chase E, Fisher RI. Chemotherapy alone compared with chemotherapy plus radiotherapy for localized intermediate- and high-grade non-Hodgkin's lymphoma. *N Engl J Med* 339: 21-26, 1998
- 4 Fischer RI, Gaynor ER, Dahlberg S, Oken MM, Grogan TM, Glick JH, Coltman CA Jr, Miller TP. Comparison of standard regimen (CHOP) with three intensive chemotherapy regimens for advanced non-Hodgkin's lymphoma. *N Engl J Med* 328: 1002-1006, 1993
- 5 Kaplan WD, Jochelson MS, Herman TS, Nadler LM, Stomper PC, Takvorian T, Andersen JW, Canellos GP. Gallium-67 imaging: A predictor of residual tumor viability and clinical outcome of patients with diffuse large-cell lymphoma. *J Clin Oncol* 8: 1966-1970, 1990

- 6 Janicek M, Kaplan W, Neuberg D, Canellos GP, Shulman LN, Shipp MA. Early restaging gallium scans predict outcome in poor-prognosis patients with aggressive non-Hodgkin's lymphoma treated with high-dose CHOP chemotherapy. *J Clin Oncol* 15: 1631-1637, 1997
- 7 Krenning EP, Kwekkeboom DJ, Bakker WH, Breeman WAP, Kooij PPM, Oei HY, van Hagen M, Postema PTE, de Jong M, Reubi JC, Visser TJ, Reijs AEM, Hofland LJ, Koper JW, Lamberts SWJ. Somatostatin receptor scintigraphy with [¹¹¹In-DTPA-D-Phe¹] and [¹²³I-Tyr³]-octreotide: the Rotterdam experience with more than 1000 patients. *Eur J Nucl Med* 20: 716-731, 1993
- 8 Reubi JC, Waser B, van Hagen M, Lamberts SWJ, Krenning EP, Gebbers JO, Laissue JA. In vitro and in vivo detection of somatostatin receptors in human malignant lymphomas. *Int J Cancer* 50: 895-900, 1992
- 9 Bares R, Galonska P, Dempke W, Handt S, Büll U, Osieka R. Somatostatin receptor scintigraphy in malignant lymphoma: first results and comparison with glucose metabolism measured by positron-emission tomography. *Horm Metab Res Suppl* 27: 56-58, 1993
- 10 Sarda L, Duet M, Zini JM, Berolatti B, Benelhadj S, Tobelem G, Mundler O. Indium-111 pentetreotide scintigraphy in malignant lymphomas. *Eur J Nucl Med* 22: 1105-1109, 1995
- 11 Lipp RW, Silly H, Ranner G, Dobnig H, Passath A, Leb G, Kresj GJ. Radiolabeled octreotide for the demonstration of somatostatin receptors in malignant lymphoma and lymphadenopathy. *J Nucl Med* 36: 13-18, 1995
- 12 Goldsmith SJ, Macapinlac HA, O'Brien JP. Somatostatin-receptor imaging in lymphoma. *Sem Nucl Med* 25: 262-271, 1995
- 13 Ivancevic V, Wörmann B, Nauck C, Sandrock D, Munz DL, Hiddemann W, Emrich D. Somatostatin receptor scintigraphy in the staging of lymphomas. *Leuk Lymphoma* 26: 107-114, 1997
- 14 Van Hagen PM, Krenning EP, Reubi JC, Mulder AH, Bakker WH, Oei HY, Löwenberg B, Lamberts SWJ. Somatostatin analogue scintigraphy of malignant lymphomas. *Br J Haematol* 83: 75-79, 1993
- 15 Bong SB, Van der Laan JG, Louwes H, Schuurman JJ. Clinical experience with somatostatin receptor imaging in lymphoma. *Semin Oncol Suppl* 21: 46-50, 1994
- 16 Lipp RW, Schnedl WJ, Aglas F, Ranner G, Beham-Schmid C, Leb G, Sill H. Visualization of non-Hodgkin's lymphoma by high dosed somatostatin receptor specific scintigraphy and extended single photon emission tomography. *Acta Med Austriaca* 26: 105-108, 1999
- 17 Van den Anker-Lugtenburg PJ, Löwenberg B, Lamberts SWJ, Krenning EP. The relevance of somatostatin receptor expression in malignant lymphomas. *Metabolism Suppl* 45: 96-97, 1996

- 18 The non-Hodgkin's lymphomas pathological classification project. National Cancer Institute sponsored study of classification of non-Hodgkin's lymphoma: Summary and description of a working formulation for clinical usage. *Cancer* 49: 2112-2135, 1982
- 19 Carbone PP, Kaplan HS, Musshoff K, Smithers DW, Tubiana M. Report of the committee on Hodgkin's disease staging classification. *Cancer Res* 31: 1860-1861, 1971
- 20 Krenning EP, Bakker WH, Kooij PPM, Breeman WAP, Yoe Oei H, de Jong M, Reubi JC, Visser TJ, Bruns C, Kwekkeboom DJ, Reijts AEM, van Hagen PM, Koper JW, Lamberts SWJ. Somatostatin receptor scintigraphy with [¹¹¹In-DTPA-Phe¹]-octreotide in man: metabolism, dosimetry and comparison with [¹²³I-Tyr³]-octreotide. *J Nucl Med* 33: 652-658, 1992
- 21 Krenning EP, Kwekkeboom DJ, de Jong M, Visser TJ, Reubi JC, Bakker WH, Kooij PPM, Lamberts SWJ. Essentials of peptide receptor scintigraphy with emphasis on the somatostatin analog octreotide. *Semin Oncol Suppl* 21: 6-14, 1994
- 22 Krenning EP, Kwekkeboom DJ, Pauwels S, Kvols K, Reubi JC. Somatostatin receptor scintigraphy. In: Freeman LM, ed. *Nuclear Medicine Annual*. New York, Raven Press. 1-50, 1995
- 23 Hess CF, Kurtz B, Hoffmann W, Bamberg M. Ultrasound diagnosis of splenic lymphoma: ROC analysis of multidimensional splenic indices. *Br J Radiol* 66: 859-864, 1993
- 24 Munker R, Stengel A, Stähler A, Hiller E, Brehm G. Diagnostic accuracy of ultrasound and computed tomography in the staging of Hodgkin's disease. *Cancer* 76: 1460-1466, 1995
- 25 Van den Anker-Lugtenburg PJ, Krenning EP, Oei HY, van Hagen MP, Gerrits CJH, Reubi JC, Lamberts SWJ, Löwenberg B. Somatostatin receptor scintigraphy in the initial staging of Hodgkin's disease. *Br J Haematol* 93: 96-103, 1996
- 26 Lugtenburg PJ, Krenning EP, Valkema R, Oei HY, Lamberts SWJ, Eijkemans MJC, van Putten WLJ, Löwenberg B. Somatostatin receptor scintigraphy useful in stage I-II Hodgkin's disease: more extended disease identified. *Br J Haematol* 112: 936-944, 2001
- 27 Lugtenburg PJ, Löwenberg B, Valkema R, Oei HY, Lamberts SWJ, Eijkemans MJC, van Putten WLJ, Krenning EP. Somatostatin receptor scintigraphy in the initial staging of low-grade non-Hodgkin's lymphomas. *J Nucl Med* 42: 222-229, 2001
- 28 Krenning EP, de Jong M, Kooij PPM, Breeman WAP, Bakker WH, de Herder WW, van Eijck CHJ, Kwekkeboom DJ, Jamar F, Pauwels S, Valkema R. Radiolabeled somatostatin analogue(s) for peptide receptor scintigraphy and radionuclide therapy. *Ann Oncol Suppl* 10: 23-29, 1999
- 29 Vanhagen PM, Krenning EP, Reubi JC, Kwekkeboom DJ, Bakker WH, Mulder AH, Laissue I, Hoogstede HC, Lamberts SWJ. Somatostatin analogue scintigraphy in granulomatous diseases. *Eur J Nucl Med* 21: 497-502, 1994

- 30 Vanhagen PM, Markusse HM, Lamberts SWJ, Kwekkeboom DJ, Reubi JC, Krenning EP. Somatostatin receptor imaging: the presence of somatostatin receptor receptors in rheumatoid arthritis. *Arthritis Rheum* 37: 1521-1527, 1994
- 31 Gibril F, Reynolds JC, Chen CC, Yu F, Goebel SU, Serrano J, Doppman JL, Jensen RT. Specificity of somatostatin receptor scintigraphy: a prospective study and effects of false-positive localizations on management in patients with gastrinomas. *J Nucl Med* 40: 539-553, 1999
- 32 Gasparini M, Bombardieri E, Castellani M, Tondini C, Maffioli L, Devizzi L, Gerundini P. Gallium-67 scintigraphy evaluation of therapy in non-Hodgkin's lymphoma. *J Nucl Med* 39: 1586-1590, 1998
- 33 Zinzani PL, Martelli M, Magagnoli M, Pescarmona E, Scaramucci L, Palombi F, Bendandi M, Martelli MP, Ascani S, Orcioni GF, Pileri SA, Mandelli F, Tura S. Treatment and clinical management of primary mediastinal large B-cell lymphoma with sclerosis: MACOP-B regimen and mediastinal radiotherapy monitored by (67)Gallium scan in 50 patients. *Blood* 94: 3289-3293, 1999
- 34 Waxman AD, Eller D, Ashook G, Ramanna L, Brachman M, Heifetz L, McAndrews P, Bierman H, Taub R, Avedon M, Wall F. Comparison of gallium-67-citrate and thallium-201 scintigraphy in peripheral and intrathoracic lymphoma. *J Nucl Med* 37: 46-50, 1996
- 35 Front D, Israel O, Epelbaum R, Ben Haim S, Sapir EE, Jerushalmi J, Kolodny GM, Robinson E. Ga-67 SPECT before and after treatment of lymphoma. *Radiology* 175: 515-519, 1990
- 36 Sandrock D, Lastoria S, Margrath I, Neumann RD. The role of gallium-67 tumour scintigraphy in patients with small, non-cleaved cell lymphoma. *Eur J Nucl Med* 20: 119-122, 1993
- 37 Larcos G, Farlow DC, Antico VF, Gruenewald SM, Boyages J. The role of high dose 67-gallium scintigraphy in staging untreated patients with lymphoma. *Aust N Z J Med* 24: 5-8, 1994
- 38 Hussain R, Christie DR, Gebiski V, Barton MB, Gruenewald SM. The role of the gallium scan in primary extranodal lymphoma. *J Nucl Med* 39: 95-98, 1998
- 39 Moog F, Bangerter M, Diederichs CG, Guhlmann A, Kotzerke J, Merkle E, Kolokythas O, Herrmann F, Reske SN. Lymphoma: role of whole-body-2-deoxy-2-[F-18]fluoro-D-glucose (FDG) PET in nodal staging. *Radiology* 203: 795-800, 1997
- 40 Moog F, Bangerter M, Diederichs CG, Guhlmann A, Merkle E, Frickhofen N, Reske SN. Extranodal malignant lymphoma: detection with FDG PET versus CT. *Radiology* 206: 475-481, 1998

- 41 Jerusalem G, Warland V, Najjar F, Paulus P, Fassotte MF, Fillet G, Rigo P. Whole-body ^{18}F -FDG PET for the evaluation of patients with Hodgkin's disease and non-Hodgkin's lymphoma. Nucl Med Commun 20: 13-20, 1999
- 42 Stumpe KD, Urbinelli M, Steinert HC, Glanzmann Ch, Buck A, von Schulthess GK. Whole-body positron emission tomography using fluorodeoxyglucose for staging of lymphoma: effectiveness and comparison with computed tomography. Eur J Nucl Med 25: 721-728, 1998

CHAPTER 7

Summary and general discussion

At the time of initial presentation of malignant lymphoma the range of therapeutic options is broadest and the chance of cure greatest. The objectives of initial staging are not only to define the local extent of clinically overt disease as exactly as possible, but also to disclose occult disease elsewhere. In designing an imaging strategy to search for occult sites of disease, one should be aware of preferential sites of tumor involvement, the sensitivity and specificity of the tests for particular sites and the likely impact on treatment. Computed tomography (CT) of thorax, abdomen and pelvis currently represents the standard imaging technique in patients with malignant lymphoma, even though it has shortcomings. Following therapy CT as well as magnetic resonance imaging (MRI) perform suboptimally in distinguishing fibrotic scar tissue from residual viable tumor. CT is also inadequate for demonstrating lymphoma involvement in spleen or liver. Therefore, an accurate non-invasive evaluation of the extent of disease currently remains a continuing challenge in the clinical management of patients with lymphoma.

Fourteen years have elapsed since somatostatin receptor (SS-R) scintigraphy was introduced (1). Subsequent clinical studies have demonstrated the successful visualization of SS-R positive neuroendocrine tumors after intravenous administration of a radiolabeled analog of SS and subsequent radionuclide scanning. In a small pilot study it became evident that it was possible to visualize non-Hodgkin's lymphoma (NHL) and Hodgkin's disease (HD) in vivo using SS-R scintigraphy with ¹¹¹Indium-pentetreotide (2). At the same time the tissue expression of SS-Rs in biopsies of malignant lymph nodes of these patients was demonstrated with in vitro autoradiography (2).

In the studies presented in this thesis we have evaluated SS-R scintigraphy in the staging of untreated patients with HD and NHL.

7.1 Place of SS-R scintigraphy in the staging of Hodgkin's disease

Favorable results with SS-R scintigraphy were obtained in patients with HD (chapters 2 and 4). All 126 patients with newly diagnosed HD were positive on SS-R scintigraphy, indicating the high frequency of SS-R expression in Hodgkin's lymphomas. Hence, SS-R scintigraphy can conveniently be used in patients with HD to investigate the spread of the disease. In the majority of patients with HD the neoplastic lesions show a high uptake of radioactivity and can readily be detected. In addition, 'new' lymphoma lesions frequently became apparent following additional SS-R scanning. SS-R scintigraphy showed excellent sensitivities for the detection of Hodgkin's localizations in the neck, axilla and mediastinum (95%-100%). Indeed, in comparison with CT scanning and ultrasonography, SS-R scintigraphy proved to be the most sensitive imaging technique for supradiaphragmatic Hodgkin's disease. In contrast, CT scanning offers the highest

sensitivity in the intra-abdominal region, where SS-R scintigraphy showed inferior sensitivities of 38%-100%. In a substantial proportion of stage I and stage II HD patients more extensive disease was demonstrated following work-up with SS-R scintigraphy. As a result of this patients were upstaged from stages I/II to stages III or IV. This may have apparent implications for planning treatment strategies in these patients.

Would the results of SS-R scintigraphy have influenced patient outcome? It is not easy to provide a direct answer. It will be difficult to directly demonstrate in quantitative terms how changes in patient management based upon information from SS-R scintigraphy might contribute to eventual improvement in patient outcome. In the studies described in this thesis, it was agreed that new lesions that were found using SS-R scintigraphy would not influence patient management, unless the presence of active HD was proven. Therefore, possible benefits for the patient in terms of an improvement in prognosis can only be estimated in scenario estimates. A prospective randomised study could determine if a group in which treatment is changed because of the additional lesions found following SS-R scintigraphy will have a better outcome compared with a conventionally treated group in which the initial protocol is continued, independent of the SS-R scintigraphy results. Such a study would require large numbers of patients. Based on our own estimations, in a cost-effective analysis, the addition of a SS-R scan to the conventional staging procedures proved to be cost-effective in patients with stages I and II HD. In this analysis, it was demonstrated that the costs of the SS-R scan would be counterbalanced by a gain in life expectation (data not shown).

7.2 Place of SS-R scintigraphy in the staging of non-Hodgkin's lymphoma

Histologic subtype and clinical parameters, rather than extent of disease provide the major prognostic factors in NHL. We conducted studies on SS-R scintigraphy in patients with indolent NHL (chapter 5) and more aggressive NHL (chapter 6), respectively.

Although a majority (84%) of patients with indolent NHL have a positive scan, the overall sensitivity of SS-R scintigraphy was only 55%. A selective analysis of the results of SS-R scintigraphy in the subset of patients with a positive scan only, confirmed the low sensitivity of 60%. In fact, in many patients lesions are missed by SS-R scintigraphy. In a direct comparison with CT scanning, SS-R scintigraphy is inferior for the detection of nodal as well as most extranodal lesions. Thus, the clinical value of SS-R scintigraphy in staging of patients with indolent NHL is limited (chapter 5).

The SS-R scan was positive in 90% of patients with an aggressive NHL (chapter 6). Both, B-cell and T-cell lymphomas were positive on SS-R scintigraphy. The overall sensitivity of SS-R scintigraphy was 71%. The best sensitivity was reached in the supradiaphrag-

matic region (77%), the sensitivity was worst in the abdominal region (57%). SS-R scintigraphy was inferior to CT scanning for the detection of nodal lesions in the thorax and abdomen. However, in 20% of patients more advanced disease was demonstrated following SS-R scintigraphy. In 18% of patients the clinical stage was upstaged from stage I to stages II, III or IV. Thus, the results of SS-R scintigraphy could directly impact on therapeutic management in these individuals. In particular in patients with stage I disease, the addition of SS-R scintigraphy to the conventional staging approach may lead to the discovery of extensive disease. In this selected patient group the use of SS-R scintigraphy may therefore be considered.

Primary cutaneous NHL is an infrequent distinct entity of NHL, which arises in the skin. Although at presentation only the skin is involved, the disease subsequently may progress to involve lymph nodes and organs. The experience with SS-R scintigraphy in 14 patients with primary cutaneous NHL are reported in chapter 3. In contrast to CT scanning, SS-R scintigraphy appeared useful to differentiate between benign dermatopathic lymphadenopathy and malignant lymph node infiltration. Although the number of evaluated patients was small, this result warrants further study in a larger group of patients.

7.3 Future issues in imaging Hodgkin's disease and non-Hodgkin's lymphoma

Several imaging techniques have been introduced for the visualization of malignant lymphoma e.g., CT, MRI, gallium scanning and FDG-PET scanning. What is the value of each of these diagnostic methods and how could their use contribute to optimise the diagnostic work-up in these patients?

MRI has no standard place in the staging of malignant lymphoma. In general MRI provides little incremental information compared to CT scanning at the time of initial staging (3). MRI depends on the same lymph node size criteria as CT for an interpretation of lymphadenopathy. Moreover, CT is more practical as a 'whole body' staging procedure than MRI. However, MRI appears to be useful in specific situations. MRI may be more sensitive than blind biopsy in detecting bone marrow infiltration (4). In contrast to CT, involvement of the chest wall can be identified by MRI independent of anatomic distortion (5). MRI is the imaging method of choice for the detection of central nervous system involvement in malignant lymphoma (6,7). There is no conclusive evidence that MRI can reliably predict relapse within a residual mass after treatment for lymphoma. The sensitivity is probably too low (about 45%) (8). MRI does not involve exposure to radiation, which is an advantage of this technique. A limitation of MRI is that it is contraindicated in patients with pacemakers.

The role of gallium imaging continues to be controversial in the staging evaluation of patients with malignant lymphoma. The reason why gallium scintigraphy has not been broadly established relates to the variable sensitivity of the procedure, depending on the anatomic location of the tumor, as well as the histology of the lymphoma. The overall sensitivity is highly dependent on lesion size. The minimal detectable lesion with ^{67}Ga scan is usually above 1 cm in diameter. Most studies document a low sensitivity of about 60% in the evaluation of abdominal disease (9,10). Detection of hepatic and splenic involvement is difficult because of the physiological uptake of ^{67}Ga by these organs. Several investigators have noted that gallium avidity varies with tumor histology, the aggressive NHL and HD are more often gallium positive than the indolent NHL (9,11,12). Because of the relatively low sensitivity, gallium scintigraphy uncommonly detects occult disease not documented by other non-invasive studies, and actual upstaging of disease as a result of findings on gallium scanning is rare. In addition to the initial work-up, patients with treated HD and NHL might also benefit from functional methods to differentiate a residual mass. Accurate monitoring of response to therapy is vital for subsequent treatment decision. To diagnose relapse or resistant disease in patients with HD and aggressive NHL as early as possible, many consider gallium scanning as the standard in judging the residual mass (13,14). The positive predictive value of a post-treatment gallium scan is high. However, the negative predictive value is much lower (14). Gallium imaging has inherent shortcomings. Besides the already mentioned lack of sensitivity in the abdomen and for lesions smaller than 2 cm, post-therapy non-specific hilar uptake and uptake in the regenerating thymus constitute difficulties, especially in patients with mediastinal and hilar involvement (15,16).

FDG-PET has been reported to be highly accurate in the staging of HD and NHL prior to therapy. In most studies the diagnostic efficiency of FDG-PET for nodal involvement was equivalent or superior to that of CT (17-19). Three studies have reported the superiority of FDG-PET over CT in the detection of extranodal lesions (20-22). FDG-PET demonstrated greater tumor extension in the stomach than was found following endoscopy or on CT scans (21). Another study showed that FDG-PET is capable of demonstrating discrete, clinically occult skeletal involvement (20). Accurate identification of lymphoma infiltration in liver and spleen is an unresolved issue in staging. The sensitivity of CT, ultrasonography and gallium scanning has ranged between 15% and 63% (17). Although the experience on this issue is limited, FDG-PET is able to detect liver and spleen lesions with high glycolytic activity (17,20,23). In one study FDG-PET localized 66% more spleen lesions than CT (20). Evaluation of bone marrow with

FDG-PET may lead to many false-negative and false-positive results (17). Therefore, FDG-PET cannot replace bone marrow biopsy.

Some investigators believe that FDG-PET would be most informative as a non-invasive modality in differentiating recurrence or residual disease from fibrosis. The reported data in literature are still limited and not unambiguous. Positive and negative predictive values between 57% and 100% have been reported (17). In some studies the high false-positive results have created doubts on the practical utility of FDG-PET (8,17). Several organs in the body can show physiologically normal but relatively intense FDG activity that can pose problems in detection of tumors. The most notable regions for physiological FDG uptake are brain, heart, liver, bladder and bowel. False-positive results can be seen at the site of thymic hyperplasia (24). On the other hand, FDG-PET offers certain potential advantages over gallium scanning and SS-R scintigraphy. The interpretation of FDG-PET in the abdominal region is less impeded by bowel excretion of radionuclides. Moreover, imaging is possible within one hour of FDG injection, unlike gallium and ¹¹¹Indium-pentetreotide, which require long intervals between injection and imaging.

There are no published data of studies investigating the role of SS-R scintigraphy for the evaluation of the treatment response in patients with malignant lymphoma. However, it is our experience that SS-R scintigraphy is capable of demonstrating relapse of malignant lymphoma in previously treated patients (data not shown). In Table 1 an overview is presented of the value of various imaging techniques that can be used for the imaging of malignant lymphoma.

Further studies comparing FDG-PET to gallium scintigraphy and SS-R scintigraphy are warranted. These studies may also address the question of the best cost-benefit approach of patients with residual masses at the end of treatment.

7.4 New developments in SS-R imaging

SS-R expressing tumors can be visualized by injecting a radiolabeled SS analog and imaging tissue uptake of the radionuclide via scintigraphy. Selective radioactive uptake will depend on the density and affinity of the receptor population. Scintigraphy with radiolabeled ligands of octreotide will only allow the detection of tumors expressing SS-R subtypes 2 and 5 and possibly those neoplasms expressing SS-R subtype 3. Recent reports suggest the existence of different SS-R subtypes on some human cancers, which bind the synthetic SS analogs differentially (25). Besides octreotide, several other SS analogs have been synthesized. These are currently used therapeutically in patients with acromegaly and neuroendocrine tumors (e.g., lanreotide and vapreotide).

Table 1. Place of different imaging techniques in the management of malignant lymphoma

	Initial staging		Posttreatment evaluation	Targeted therapy	Cost (relative)
	Nodal sensitivity	Extranodal sensitivity			
CT scanning	High	Low	PPV low NPV high	-	Low
MRI	High	Low	PPV low NPV low-intermediate	-	Intermediate
Gallium scintigraphy	Intermediate	Low	PPV high NPV intermediate	-	High
SS-R scintigraphy	Intermediate-high	Low-intermediate	No data	+	High
FDG-PET scanning	High	High?	PPV intermediate-high NPV intermediate-high	-	High

PPV, positive predictive value; NPV, negative predictive value.

The biological actions of these peptides are not always identical. These differences appear to be related to the different affinities of the natural hormone and synthetic derivatives for the different SS-R subtypes. New 'receptor-selective' and 'universal' radiolabeled SS analogs are being developed and might be of interest for future use in cancer patients as radiopharmaceuticals for imaging those SS-R positive tumors that express hSSTR-4, but not hSSTR-2 and hSSTR-5 and therefore do not bind octreotide. An example of such a 'universal' SS analog is DOTA-lanreotide. Compared with the parent peptide (i.e. lanreotide), DOTA-lanreotide seems to display a distinct binding pattern, since it binds all transfected hSSTR subtypes as well as a variety of primary tumors. As a consequence, DOTA-lanreotide is claimed to be a 'universal' SS-R ligand (26). Chelated octreotides have also been labeled with positron-emitting ^{67}Ga , ^{64}Cu or ^{18}F . Of special interest is [^{64}Cu -TETA-D-Phe¹]-octreotide, which binds to SS-R at five-fold affinity as compared to ^{111}In -pentetreotide, and it has favorable clearance properties (renal clearance with rapid excretion) and is a potential agent applicable in PET imaging of SS-Rs (27).

7.5 SS-R imaging as a guide in targeted treatment

A new application of radiolabeled peptides refers to their use in so-called peptide receptor radionuclide therapy. The underlying principle is to preferentially deliver radionuclides to the tumor using ligands that are capable of targeting the tumor. ^{111}In -pentetretotide has been used for radionuclide therapy in patients with advanced SS-R positive neuroendocrine tumors (28). In a clinical phase-I trial the capacity of ^{111}In -pentetretotide was demonstrated to deliver radiation doses (20-75 GBq) to tumors that resulted in significant tumor shrinkage. The trial suggested greater responses in patients whose tumors had a higher accumulation of the radioligand. ^{111}In -pentetretotide is not the ideal radiopharmaceutical for radionuclide therapy, because of the small particle range of the Auger electrons and, therefore, short tissue penetration.

Recently, new alternative SS radioligands have been synthesized, with the aim of using these for radionuclide therapy of tumors. One example is [DOTA-D-Phe¹-Tyr³]-octreotide (DOTATOC or Octreother®). DOTA is a universal chelator, to which the high-energy pure beta-particle emitter ^{90}Y (Yttrium) and ^{177}Lu (Lutetium), a low energy beta-particle and gamma emitter can be linked in a stable manner. It can be expected that the radiotherapeutic use of radionuclides, such as ^{90}Y , emitting the higher energies of beta-particles, will permit for the delivery of higher radiation doses to greater parts of the tumor, also because of their more appropriate particle ranges or tissue penetration. Recent studies showed encouraging results after [^{90}Y -DOTA-D-Phe¹-Tyr³]-octreotide treatment in patients with advanced cancer (29). Another example of such a new SS analog is octreotate. Reubi et al demonstrated a marked improvement of affinity for SS-R subtype 2 for [Y-DOTA-Tyr³]-octreotate and [In-DTPA-Tyr³]-octreotate compared with [In-DTPA-Phe³]-octreotide (30). Since most SS-R positive tumors, including malignant lymphomas, express the SS-R subtype 2, an improvement in affinity for the SS-R subtype 2 may represent a considerable advantage as regards better tumor visualization and more effective therapy. Data from studies in tumor-bearing rats confirm the greater potential of radiolabeled octreotate over radiolabeled octreotide. The highest uptake in SS-R positive tumors and organs was seen following injection of the radiolabeled octreotate preparation. The latter radioligand also performed best for the visualization of these tumors (31,32). In a small comparative study in patients with SS-R positive tumors the uptake in the tumors was much higher after ^{177}Lu -octreotate than that after ^{111}In -octreotide (33). Therefore, radiolabeled octreotate has been selected for future (PET) imaging and targeted radiotherapy studies. The exquisite sensitivity of lymphoma to radiation together with the high frequency of SS-R expression in lymphomas may provide a rationale for the use of SS-R targeted radiotherapy in malignant lymphoma. As patients

with HD and aggressive NHL frequently show high uptake of the radioligand, they would appear candidates for SS-R targeted radiotherapy. SS-R positive scintigrams could then be used to correlate images with treatment effects or predict whether SS-R targeted therapy would make sense. Also the effect of treatment can be evaluated conveniently by means of follow-up SS-R imaging. A variant approach of targeted treatment of SS-R expressing tumors is SS conjugated chemotherapy. By synthesizing conjugates of SS analogs (radioactive or non-radioactive) and cytostatic drugs selective accumulation of cytotoxic radicals in SS-R positive tumor cells may be exploited for therapeutic purposes. Future investigations should also be aimed at further exploring the use of long-acting SS analogs as antineoplastic agents, either alone or in combination with other drugs. Witzig et al reported that octreotide as single agent shows activity in patients with low-grade NHL (34). Recently, a high response rate was reported of a combination of cyclophosphamide together with SS, bromocriptin, retinoids, melatonin and ACTH in patients with low-grade NHL at advanced stage (35). The administration of SS is not associated with bone marrow toxicity. This may open the possibilities for the use of SS in combination with myelosuppressive chemotherapy regimens without enhancing myelosuppression. The combination of SS analogs with other classes of antineoplastic agents thus offers an interesting area for future studies.

7.6 References

- 1 Krenning EP, Bakker WH, Breeman WAP, Koper PP, Kooij PPM, Aulsema L, Lameris LS, Reubi JC, Lamberts SWJ. Localization of endocrine-related tumours with radioiodinated analogue of somatostatin. *Lancet* 1: 242-244, 1989
- 2 Van Hagen PM, Krenning EP, Reubi JC, Mulder AH, Bakker WH, Oei HY, Löwenberg B, Lamberts SWJ. Somatostatin analogue scintigraphy of malignant lymphomas. *Br J Haematol* 83: 75-79, 1993
- 3 Castellino RA, Podoloff DA. Diagnostic radiology and nuclear medicine imaging in Hodgkin's disease. In: Mauch PM, Armitage JO, Diehl V, Hoppe RT, Weiss LM, eds. *Hodgkin's disease*. Philadelphia, Lippincott, Williams and Wilkins 241-262, 1999
- 4 Tardivon AA, Vanel D, Munck JN, Bosq J. Magnetic resonance imaging of the bone marrow in lymphomas and leukemias. *Leuk Lymphoma* 25: 55-68, 1997
- 5 Bergin CJ, Healy MV, Zincone GE, Castellino RA. MRI evaluation of chest wall involvement in malignant lymphoma. *J Comput Assist Tomogr* 14: 926-932, 1990
- 6 Schumacher M, Orszagh M. Imaging techniques in neoplastic meningiosis. *J Neurooncol* 38: 111-120, 1998

- 7 Thurnher MM, Rieger A, Kleibl-Popov C, Settinck U, Henk C, Haberler C, Schindler E. Primary central nervous system lymphoma in AIDS: a wider spectrum of CT and MRI findings. *Neuroradiology* 43: 29-35, 2001
- 8 Maisey NR, Hill ME, Webb A, Cunningham D, Flux GD, Padhani A, Ott RJ, Norman A, Bishop L. Are ¹⁸fluorodeoxyglucose positron emission tomography and magnetic resonance imaging useful in the prediction of relapse in lymphoma residual masses? *Eur J Cancer* 36: 200-206, 2000
- 9 Hagemester FB, Fesus SM, Lamki LM, Haynie TP. Role of gallium scan in Hodgkin's disease. *Cancer* 65:1090-1096, 1990
- 10 Front D, Israel O, Epelbaum R, Ben Haim S, Even Sapir E, Jerushalmi J, Kolodny GM, Robinson E. Ga-67 SPECT before and after treatment of lymphoma. *Radiology* 175: 515-519, 1990
- 11 Gallamini A, Biggi A, Fruttero A, Pugno F, Cavallero G, Pregno P, Grasso M, Farinelli C, Leone A, Gallo E. Revisiting the prognostic role of gallium scintigraphy in low-grade non-Hodgkin's lymphoma. *Eur J Nucl Med* 24: 1499-1506, 1997
- 12 Delcambre C, Reman O, Henry-Amar M, Peny AM, Macro M, Cheze S, Genot JY, Tanguy A, Switsers O, Van HL, Couette JE, Leporrier M, Bardet S. Clinical relevance of gallium-67 scintigraphy in lymphoma before and after therapy. *Eur J Nucl Med* 27: 176-184, 2000
- 13 Vose JM, Bierman PJ, Anderson JR, Harrison KA, Dalrymple GV, Byar K, Kessinger A, Armitage JO. Single-photon emission computed tomography gallium imaging versus computed tomography: predictive value in patients undergoing high-dose chemotherapy and autologous stem-cell transplantation for non-Hodgkin's lymphoma. *J Clin Oncol* 14: 2473-2479, 1996
- 14 Salloum E, Brandt DS, Caride VJ, Cornelius E, Zelterman D, Schubert W, Manninó T, Cooper DL. Gallium scans in the management of patients with Hodgkin's disease: a study of 101 patients. *J Clin Oncol* 15: 518-527, 1997
- 15 Tumei SS, Rosenthal DS, Kaplan WD, English RJ, Holman BL. Lymphoma: evaluation with Ga-67 SPECT. *Radiology* 164: 111-114, 1987
- 16 Peylan-Ramu N, Haddy TB, Jones E, Horvath K, Adde MA, Margrath IT. High frequency of benign mediastinal uptake of gallium-67 after completion of chemotherapy in children with high-grade non-Hodgkin's lymphoma. *J Clin Oncol* 7: 1800-1806, 1989
- 17 Kostakoglu L, Goldsmith SJ. Fluorine-18 fluorodeoxyglucose positron emission tomography in the staging and follow-up of lymphoma: is it time to shift gears? *Eur J Nucl Med* 27: 1564-1578, 2000
- 18 Mainolfi C, Maurea S, Varella P, Alaia C, Imperato C, Alfano B, Aate G, Bazzicalupo L. Positron emission tomography with fluorine-18-deoxyglucose in the staging and control of

- patients with lymphoma. Comparison with clinico-radiologic assessment. *Radiol Med* 95: 98-104, 1998
- 19 Moog F, Bangerter M, Diederichs CG, Guhlman A, Kotzerke J, Merkle E, Kolokythas O, Herrmann F, Reske SN. Lymphoma: role of whole-body 2-deoxy-2-[F-18]fluoro-D-glucose (FDG) PET in nodal staging. *Radiology* 203: 795-800, 1997
- 20 Moog F, Bangerter M, Diederichs CG, Guhlman A, Merkle E, Frickhofen N, Reske SN. Extranodal malignant lymphoma: detection with FDG PET versus CT. *Radiology* 206: 475-481, 1998
- 21 Rodriguez M, Ahlstrom H, Sundin A, Rehn S, Sundstrom C, Hagberg H, Glimelius B. ¹⁸F FDG PET in gastric non-Hodgkin's lymphoma. *Acta Oncol* 36: 577-584, 1997
- 22 Wiedman E, Baican B, Hertel A, Baum RP, Chow KU, Knupp B, Adams S, Hör G, Hoelzer D, Mitrou PS. Positron emission tomography (PET) for staging and evaluation of response to treatment in patients with Hodgkin's disease. *Leuk Lymphoma* 34: 545-551, 1999
- 23 Bangerter M, Moog F, Griesshammer M, Merkle E, Hafner M, Ellenrieder V, Reske SN, Heimpel H. Usefulness of FDG-PET in diagnosing primary lymphoma of the liver. *Int J Hematol* 66: 517-520, 1997
- 24 Bangerter M, Kotzerke J, Griesshammer M, Elsner K, Reske SN, Bergmann L. Positron emission tomography with 18-fluorodeoxyglucose in the staging and follow-up of lymphoma in the chest. *Acta Oncol* 38: 799-804, 1999
- 25 Reubi JC, Schaer JC, Waser B, Mengod G. Expression and localization of somatostatin receptor SSTR1, SSTR2, and SSTR3 messenger RNAs in primary human tumors using in situ hybridisation. *Cancer Res* 54: 3455-3459, 1994
- 26 Virgolini I, Szilvasi I, Kurtaran A, Angelberger P, Raderer M, Havlik E, Vorbeck F, Bischof C, Leimer M, Dorner G, Kletter K, Niederle B, Scheithauer W, Smith-Jones P. Indium-111-DOTA-lanreotide: biodistribution, safety and radiation absorbed dose in tumor patients. *J Nucl Med* 39: 1928-1936, 1998
- 27 Eriksson B, Örlfors A, Sundin A, Skodseid B, Langström B, Bregström M, Öberg K. Positron emission tomography in neuroendocrine tumors. *Ital J Gastroenterol Hepatol* 31: (suppl) S167-S171, 1999
- 28 Kwekkeboom D, Krenning EP, de Jong M. Peptide receptor imaging and therapy. *J Nucl Med* 41: 1704-1713, 2000
- 29 Otte A, Herrmann R, Heppeler A, Behe M, Jermann E, Powell P, Maecke HR, Müller J. Yttrium-90 DOTATOC: first clinical results. *Eur J Nucl Med* 26: 1439-1447, 1999
- 30 Reubi JC, Schar JC, Waser B, Wenger S, Heppeler A, Schmitt JS, Macke HR. Affinity profiles for human somatostatin receptor subtypes SST1-SST5 of somatostatin radiotracers selected for scintigraphic and radiotherapeutic use. *Eur J Nucl Med* 27: 273-282, 2000

- 31 De Jong M, Breeman WAP, Bakker WH, Kooij PPM, Bernard BF, Hofland LJ, Visser TJ, Srinivasan A, Schmidt MA, Erion JL, Bugaj JE, Macke HR, Krenning EP. Comparison of (111)In-labeled somatostatin analogues for tumor scintigraphy and radionuclide therapy. *Cancer Res* 58: 437-441, 1998
- 32 Lewis JS, Lewis MR, Srinivasan A, Schmidt MA, Wang J, Anderson CJ. Comparison of four ⁶⁴Cu-labeled somatostatin analogues in vitro and in a tumor-bearing rat model: evaluation of new derivatives for positron emission tomography imaging and targeted radiotherapy. *J Med Chem* 42: 1341-1347, 1999
- 33 Kwekkeboom DJ, Bakker WH, Kooij PPM, Konijnenberg MW, Srinivasan A, Erion JL, Schmidt MA, Bugaj JL, de Jong M, Krenning EP. [¹⁷⁷Lu-DOTA⁰,Tyr³]octreotate: comparison with [¹¹¹In-DTPA⁰]octreotide in patients. *Eur J Nucl Med* 28: 1319-1325, 2001
- 34 Witzig TE, Letendre L, Gerstner J, Schroeder G, Mailliard JA, Colon-Otero G, Marschke RF, Windschill HE. Evaluation of a somatostatin analog in the treatment of lymphoproliferative disorders: results of a phase II North Central Cancer Treatment Group trial. *J Clin Oncol* 13: 2012-2015, 1995
- 35 Todisco M, Casaccia P, Rossi N. Cyclophosphamide plus somatostatin, bromocriptin, retinoids, melatonin and ACTH in the treatment of low-grade non-Hodgkin's lymphomas at advanced stage: results of a phase II trial. *Cancer Biother Radiopharm* 16: 171-177, 2001

Samenvatting

Elk jaar wordt in Nederland bij 2500 personen een maligne lymfoom gediagnostiseerd. In 80% van de gevallen betreft dit een non-Hodgkin lymfoom (NHL). De overige patiënten hebben de ziekte van Hodgkin (Hodgkin lymfoom, HL). De prognose van patiënten met een maligne lymfoom is de laatste 30 jaar verbeterd. Dit is niet alleen te danken aan betere behandelingsmogelijkheden, maar ook aan gevoeliger diagnostische methoden om de verspreiding van de ziekte in het lichaam op te sporen.

Bij patiënten met een maligne lymfoom is het voor de prognose en voor het vaststellen van de behandeling van essentieel belang om de uitbreiding van de ziekte in het lichaam te detecteren. Bij iedere nieuw gediagnostiseerde patiënt met een maligne lymfoom wordt daarom een stageringsonderzoek verricht. Dit stageringsonderzoek bestaat meestal naast de anamnese en het lichamelijk onderzoek uit beenmergonderzoek en een aantal röntgenologische onderzoeken. Het standaard röntgenologisch onderzoek omvat over het algemeen een X-thorax, CT scan van thorax, abdomen en bekken, soms aangevuld met een echografisch onderzoek van de hals of bovenbuik. De huidige methoden ter detectie van maligne lymfoomlokalisaties zijn niet optimaal. De sensitiviteit van de CT scan, MRI en echografie voor het aantonen van lymfoominfiltratie in lever en milt is laag. Ook aangedane lymfeklieren in de bovenbuik, lever- en milthilus en het mesenterium worden frequent gemist. Bij de CT scan en de MRI wordt de grootte van de lymfeklier als criterium gehanteerd voor de beoordeling van lymfadenopathie. Er is echter gebleken dat een vergrote lymfeklier niet altijd maligne is en omgekeerd kan een niet vergrote lymfeklier maligne weefsel bevatten. Daarnaast kunnen de CT scan en de MRI in een restmassa, welke is achtergebleven na behandeling van de ziekte, geen goed onderscheid maken tussen fibrotisch litteken weefsel en nog actieve ziekte.

Somatostatine receptor (SS-R) positieve neuroendocriene tumoren kunnen succesvol scintigrafisch worden gevisualiseerd na toediening van het radioactief gekoppelde somatostatine (SS) analogon ¹¹¹In-pentetreotide. In een kleine pilotstudie bleek het mogelijk door middel van SS-R scintigrafie lymfoomlokalisaties zichtbaar te maken in patiënten met een NHL en HL. Tevens werd door middel van in vitro autoradiografie met radioactief gemerkt SS aangetoond dat de lymfeklieren van deze patiënten SS-Rn tot expressie brengen. In dit proefschrift worden een aantal prospectieve studies gepresenteerd, waarin de waarde wordt onderzocht van SS-R scintigrafie bij de primaire staging van patiënten met een NHL en HL.

In de hoofdstukken 2 en 4 worden de resultaten beschreven van het onderzoek bij patiënten met een HL. Alle 126 HL patiënten hebben een positieve SS-R scan. Hieruit kunnen we concluderen dat SS-R scintigrafie zonder uitzondering kan worden toegepast

bij iedere nieuw gediagnostiseerde patiënt met een HL. In vergelijking met de CT scan en echografie blijkt SS-R scintigrafie de hoogste sensitiviteit te hebben voor het opsporen van Hodgkin lokalisaties boven het diafragma. Voor Hodgkin lokalisaties onder het diafragma is de CT scan echter de meest gevoelige techniek. De prognose en de behandeling van een HL worden voor een belangrijk deel bepaald door de uitbreiding van de ziekte. SS-R scintigrafie blijkt een duidelijke meerwaarde te hebben bij HL patiënten met een stadium I of II. Bij een belangrijk deel (20%) van deze patiënten vindt SS-R scintigrafie nieuwe lesies, welke niet ontdekt zijn met het conventionele onderzoek. Hierdoor stijgt het stadium van de ziekte naar een stadium III of IV. Dit heeft belangrijke consequenties voor de prognose en de behandeling. Het is dan ook bij de groep patiënten met een stadium I of II, dat de toepassing van SS-R scintigrafie wordt geadviseerd.

De prognose en de behandeling van een NHL hangt meer samen met het histologische subtype en bepaalde klinische parameters, dan met de uitbreiding van de ziekte. Studies met SS-R scintigrafie in patiënten met een indolent NHL en in patiënten met een meer agressief NHL worden in respectievelijk hoofdstuk 5 en hoofdstuk 6 beschreven.

Hoewel een groot deel (84%) van de patiënten met een indolent NHL een positieve scan heeft, bedraagt de sensitiviteit van SS-R scintigrafie slechts 55%. Bij veel patiënten worden door SS-R scintigrafie lokalisaties van de ziekte gemist. Dit betreft lokalisaties zowel boven als onder het diafragma. De klinische waarde van SS-R scintigrafie bij de staging van patiënten met een indolent NHL is dan ook beperkt (hoofdstuk 5).

De SS-R scan is positief bij 90% van de patiënten met een meer agressief NHL (hoofdstuk 6). De hoogste sensitiviteit (77%) wordt bereikt voor lokalisaties boven het diafragma. De sensitiviteit is het laagst in het abdominale gebied (57%). Voor het opsporen van nodale lokalisaties in de thorax en buikholte is de CT scan beter dan SS-R scintigrafie. Echter bij 20% van de patiënten wordt door SS-R scintigrafie een meer uitgebreide ziekte gevonden. Bij 18% van de patiënten leidt dit tot een ophoging van het klinische stadium van een stadium I naar een stadium II, III of IV, hetgeen gevolgen heeft voor de prognose en de behandeling van deze patiënten. Bij patiënten met een stadium I agressief NHL kan de toevoeging van SS-R scintigrafie aan het conventionele onderzoek leiden tot de ontdekking van een meer gedissemineerde ziekte. In deze specifieke patiëntengroep kan daarom de toepassing van SS-R scintigrafie worden overwogen.

Primair cutane NHLn vormen een zeldzame entiteit binnen de NHLn. Aanvankelijk bevindt de ziekte zich in de huid, later kan verspreiding optreden naar de lymfeklieren en organen. In hoofdstuk 3 worden ervaringen beschreven met SS-R scintigrafie in 14 patiënten met een primair cutaan NHL. In tegenstelling tot met de CT scan, blijkt het met

SS-R scintigrafie mogelijk om te differentiëren tussen benigne dermatopatische lymfadenopathie en maligne lymfoominfiltratie van de lymfeklier.

In hoofdstuk 7 volgt een discussie van de resultaten van de onderzoeken, die beschreven zijn in dit proefschrift. Er wordt besproken welke plaats SS-R scintigrafie zou kunnen innemen in de staging van maligne lymfomen. Van verscheidene andere beeldvormende technieken die gebruikt worden voor de visualisatie van maligne lymfomen, zoals de CT scan, MRI, gallium scintigrafie en de FDG-PET scan, worden de sterke en zwakke punten belicht. Vervolgens worden een aantal nieuwe ontwikkelingen genoemd waarmee de scintigrafische visualisatie van SS-R-positieve tumoren zou kunnen verbeteren. Tenslotte wordt een nieuwe klinische toepassing besproken van SS, namelijk het therapeutisch gebruik van radioactieve verbindingen van SS analoga.

List of publications

- 1 De Leeuw PW, Lugtenburg PJ, van Houten H, Looman JHM, Birkenhäger WH. Preliminary experiences with Hoe 498 a novel long-acting converting enzyme inhibitor in hypertensive patients. *J Cardiovasc Pharmacol* 7: 1161-1165, 1985
- 2 Van den Anker-Lugtenburg PJ, Sizoo W. Myelodysplastic syndrome and secondary acute leukemia after treatment of essential thrombocythemia with hydroxyurea. *Am J Hematol* 33: 152, 1990
- 3 Van den Anker-Lugtenburg PJ, van 't Veer MB. Alpha-interferon in a case of hypereosinophilic syndrome. *Br J Haematol* 77: 258, 1991
- 4 Van Hagen PM, Krenning EP, Kwekkeboom DJ, Reubi JC, van den Anker-Lugtenburg PJ, Löwenberg B, Lamberts SWJ. Somatostatin and the immune and hematopoietic system: a review. *Eur J Clin Invest* 24: 91-99, 1994
- 5 Van Hagen PM, van den Anker-Lugtenburg PJ, Reubi JC, Lamberts SWJ, Krenning EP. The role of octreotide scintigraphy in malignant lymphomas, granulomatous diseases and rheumatoid arthritis. *Handbook of targeted delivery of imaging agents*. Torchilin VP, ed. CRC Press, Inc. 631-644, 1995
- 6 Van Hagen PM, Breeman WAP, Reubi JC, Postema PTE, van den Anker-Lugtenburg PJ, Kwekkeboom DJ, Laissue J, Waser B, Lamberts SWJ, Visser TJ, Krenning EP. Visualization of the thymus by substance-P scintigraphy in man. *Eur J Nucl Med* 23: 1508-1513, 1996
- 7 Van den Anker-Lugtenburg PJ, Krenning EP, Oei HY, van Hagen MP, Gerrits CJH, Reubi JC, Lamberts SWJ, Löwenberg B. Somatostatin receptor scintigraphy in the initial staging of Hodgkin's disease. *Br J Haematol* 93: 96-103, 1996
- 8 Van den Anker-Lugtenburg PJ, Löwenberg B, Lamberts SWJ, Krenning EP. The relevance of somatostatin receptor expression in malignant lymphomas. *Metabolism Suppl* 45: 96-97, 1996
- 9 Van den Anker-Lugtenburg PJ, Heule F, van Hagen PM, van Joost Th, Oei HY, Löwenberg B, Krenning EP. Somatostatin receptor scintigraphy in cutaneous malignant lymphomas. *J Am Acad Dermatol* 34: 985-993, 1996
- 10 Arentsen JC, van den Anker-Lugtenburg PJ, Jonkers GH, Schipper MEI, Michiels JJ, van Buuren HR. Short-segment jejunal stenosis complicating subacute portomesenteric venous thrombosis in a patient with protein S deficiency type II. *Am J Gastroenterol* 91: 1653-1654, 1996
- 11 Heide R, Vuzevski VD, Heule F, Engelens HJH, Lugtenburg PJ. Bulleuze amyloidose bij multipel myeloom. *N T Derm Vener* 8: 11-12, 1998

- 12 Heule F, Lugtenburg PJ, van Hagen PM, Krenning EP. De betekenis van somatostatine receptor scintigrafie voor de staging van primair cutane lymfomen. *N T Derm Vener* 8: 33-34, 1998
- 13 Lugtenburg PJ, Löwenberg B, Valkema R, Oei HY, Lamberts SW, Eijkemans MJ, van Putten WL, Krenning EP. Somatostatin receptor scintigraphy in the initial staging of low-grade non-Hodgkin's lymphomas. *J Nucl Med* 42: 222-229, 2001
- 14 Lugtenburg PJ, Krenning EP, Valkema R, Oei HY, Lamberts SWJ, Eijkemans MJC, van Putten WLJ, Löwenberg B. Somatostatin receptor scintigraphy useful in stage I-II Hodgkin's disease: more extended disease identified. *Br J Haematol* 112: 936-944, 2001
- 15 Van Belkum A, Goessens W, van der Schee C, Lemmens-den Toom N, Vos MC, Cornelissen J, Lugtenburg PJ, de Marie S, Verbrugh H, Löwenberg B, Endtz H. Rapid emergence of ciprofloxacin-resistant enterobacteriaceae containing multiple gentamicin resistance-associated integrons in a Dutch hospital. *Emerg Infect Dis* 7: 862-871, 2001
- 16 Lugtenburg PJ, Krenning EP, Valkema R, Oei HY, Lamberts SWJ, Eijkemans MJC, van Putten WLJ, Löwenberg B. Somatostatin receptor scintigraphy in the initial staging of intermediate- and high-grade non-Hodgkin's lymphomas. *Haematol J* in press

Dankwoord

Een proefschrift is nooit het werk van slechts één persoon en kan alleen maar tot een goed einde worden gebracht dankzij de steun en bijdrage van vele anderen. Iedereen die op één of andere manier heeft bijgedragen aan dit proefschrift zeg ik hierbij hartelijk dank.

In het bijzonder gaat mijn dank uit naar mijn promotoren Prof.dr. B. Löwenberg en Prof.dr. E.P. Krenning. Prof. Löwenberg, beste Bob, dank voor al je goede zorgen de afgelopen 13 jaren, niet alleen op het werk, maar ook daarbuiten. Ik heb je warme belangstelling altijd zeer op prijs gesteld. Zonder jouw stimulerende invloed was het boekje er nooit gekomen. Prof. Krenning, beste Eric, bedankt voor je enthousiasme en het vertrouwen dat je hebt gehouden in de goede afloop. Ik weet zeker dat we de komende jaren de samenwerking op het gebied van de beeldvorming en behandeling van lymfomen met evenveel plezier zullen voortzetten.

Prof.dr. S.W.J. Lamberts, beste Steven, ik wil je danken voor je steun en belangstelling in de afgelopen jaren. Prof.dr. A. Hagenbeek, beste Ton, jij bent één van mijn leermeesters op het gebied van de hematologie en de voordrachtskunst. Ik dank je voor het blijven volgen van mijn vorderingen, zowel op het wetenschappelijke als het persoonlijke pad. Prof.dr. P.C. Huijgens dank ik voor het kritisch doorlezen van het manuscript.

Prof. L. Kvols, dear Larry, it is an honor to have an expert in the neuroendocrine oncology-field like you in my thesis committee. I appreciate your stimulating words and the fruitful discussions we had several times during research meetings and afterwards during dinner. I also thank you for your friendly attempts to improve my English pronunciation.

De scans werden nauwgezet en met veel enthousiasme beoordeeld door Yoe Oei, Roelf Valkema en soms ook door Dik Kwekkeboom. Ook de andere medewerkers van de nucleaire geneeskunde dank ik voor hun steun en belangstelling gedurende de jaren van het onderzoek. Willem, Peter, Wouter, Ambroos en natuurlijk mijn slaapje Marion, dank voor alles. Een woord van dank gaat ook uit naar de laboranten en de altijd hulpvaardige en vriendelijke baliemedewerkers van de nucleaire. Ik voel mij helemaal thuis op jullie afdeling. Wat was het altijd gezellig in Indonesia!

Wim van Putten, dank je voor de statistiek en niet te vergeten voor het leasen van je broer voor het maken van de D-base. De groep van het centrum voor klinische besliskunde onder leiding van Prof.dr. J.D.F. Habbema, dank ik voor de prettige samenwerking. Aan de vele sessies met René Eijkemans en het uitzicht vanuit zijn kamer bewaar ik goede herinneringen. Ze waren allemaal van hoog niveau.

Mijn beide research verpleegkundigen Janneke Sluys-Dallinga en Petra Blom dank ik voor hun geweldige inzet voor dit onderzoek. De duizenden gegevens van patiënten die

door jullie werden achterhaald en nauwkeurig ingevoerd in de D-base vormen de bouwstenen van dit proefschrift. Dit boekje was er zonder jullie hulp nooit gekomen.

Mijn collega hematologen aan beide zijden van de tunnel dank ik voor de prettige samenwerking en het getoonde begrip als er weer eens aan het proefschrift gewerkt moest worden. Paula Schuijff en recent ook Anke Vink, dank ik voor de zeer plezierige manier van samenwerken op 5Zuid en A2/B2 en de warme belangstelling voor mijn persoontje. Het is een genot om samen met jullie een tandem te mogen vormen.

Een leven zonder mijn vriendinnen is voor mij niet goed denkbaar. Lieve Noline, Christine, Gerrie en Jeanette, het voelt zo goed te weten dat jullie er zijn. Helaas mogen er maar twee paranimfen zijn.

In de eerste plaats gaat mijn dank uit naar het thuisfront. Door jullie bestaan besef ik telkens weer hoe relatief alles blijkt te zijn. Lieve Deborah, het is fantastisch om jou van dichtbij te zien opgroeien. Je hebt je op een geweldige manier door een moeilijke periode heengeslagen.

Lieve Ineke, het meest dank ik jou. Het boekje ziet er dankzij jouw verzorging van de lay-out fraai uit. Niet alleen op het badmintonveld vormen we een goed koppel, gelukkig raken we ook daarbuiten steeds beter op elkaar ingespeeld.

Curriculum Vitae

Pieterella Johanna (Elly) Lugtenburg

- 22 april 1958 : Geboren in Rotterdam
1976 : Diploma Atheneum B, Johan Van Oldenbarnevelt
scholengemeenschap Rotterdam
1976 - 1983 : Studie Geneeskunde, Erasmus Universiteit Rotterdam
Februari 1983 : Artsexamen (cum laude)
1983-1988 : Opleiding Inwendige Geneeskunde, Zuiderziekenhuis
Rotterdam (opleider Prof.dr. W.H. Birkenhäger)
Maart 1988 : Registratie als internist
1988 - 1992 : Opleiding aandachtsgebied Hematologie, Daniel den Hoed
kliniek Rotterdam (opleider Prof.dr. B. Löwenberg)
November 1992 : Registratie als internist-hematoloog
1992 - 1996 : Chef de clinique afdeling Hematologie, Daniel den Hoed
kliniek Rotterdam (hoofd Prof.dr. B. Löwenberg)
1996 - : Stafid afdeling Hematologie, Academisch Ziekenhuis
Rotterdam (hoofd Prof.dr. B. Löwenberg)