

# Portal Vein Thrombosis in non cirrhotic patients

---

Manon Spaander

ISBN: 978-90-8559-141-2

Layout and print: Optima Grafische Communicatie, Rotterdam, The Netherlands

# Portal Vein Thrombosis in non cirrhotic patients

Patiënten met vena porta trombose zonder levercirrose

## Proefschrift

ter verkrijging van de graad van doctor aan de  
Erasmus Universiteit Rotterdam  
op gezag van de  
rector magnificus  
Prof.dr. H.G. Schmidt  
en volgens besluit van het College voor Promoties.

De openbare verdediging zal plaatsvinden op  
Vrijdag 17 december 2010 om 09.30 uur

door

Vooke Magdalena Constance Wilhelmina Spaander  
Manon

geboren te Amsterdam



## **PROMOTIECOMMISSIE**

### **Promotor:**

Prof.dr. H.L.A. Janssen

### **Overige leden:**

Prof.dr. E.J. Kuipers

Prof.dr. F.W.G. Leebeek

Prof.dr. H.W. Tilanus

*"Retirer pour mieux sauter"*

Witha Spaander-Rogge (mijn moeder)



# Contents

Chapter 1	Introduction and outline of the thesis	9
Chapter 2	Non-cirrhotic non-malignant portal vein thrombosis: a review	15
Chapter 3	Endoscopic treatment of gastroesophageal variceal bleeding in patients with EPVT	27
Chapter 4	Ascites is a significant predictor of survival in patients with non-cirrhotic non-malignant EPVT	41
Chapter 5	Anticoagulation in patients with non-cirrhotic extrahepatic portal vein thrombosis	53
Chapter 6	Risks and benefits of transcatheter thrombolytic therapy in patients with splanchnic venous thrombosis	67
Chapter 7	Incidence and clinical outcome of symptomatic portal biliopathy in patients with non-cirrhotic non-malignant extrahepatic portal vein thrombosis	79
Chapter 8	Summary and discussion	91
	Samenvatting en discussie	97
Chapter 9	List of publications	103
	Dankwoord	105
	Curriculum vitae	107






# Chapter 1

---

## Introduction and outline of the thesis

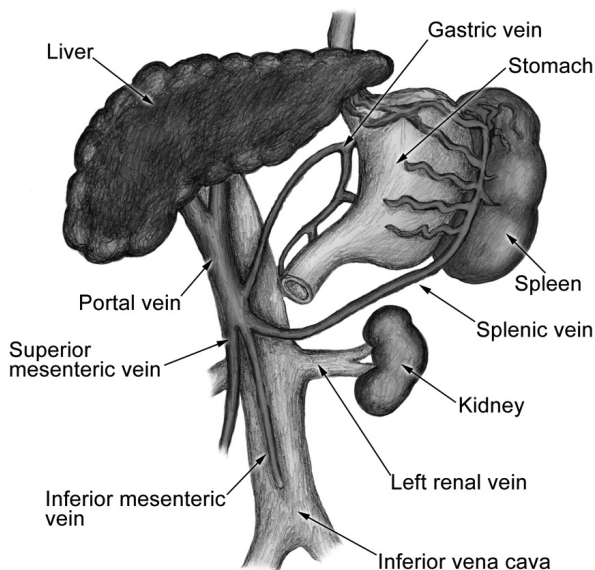




## INTRODUCTION

Extrahepatic portal vein thrombosis (EPVT) is the most common cause of portal hypertension in non-cirrhotic patients. EPVT has been defined as an obstruction of the extrahepatic portal vein with or without involvement of the intrahepatic portal veins[1]. Although the portal vein accounts for two third of the total hepatic blood flow, interruption of the portal vein has few clinical consequences. This could be explained by two findings. First a compensatory mechanism so called arterial 'buffer' response, which consists of immediate vasodilatation of the hepatic arterial bed in response to a decreased portal vein blood flow. This mechanism has been well demonstrated experimentally, but also in patients following portal vein clamping at hepatic surgery[2]. The second compensatory mechanism is a rapid development of collateral veins bypassing the thrombosed portion of the portal vein. As a result of the arterial buffer response and development of collaterals, total hepatic blood flow is minimally reduced[3]. Portal pressure, however is increased. This increase in portal pressure can be viewed as a compensatory mechanism allowing portal vein perfusion to be maintained through the collateral veins. So, portal perfusion is maintained at the expense of portal hypertension.

The etiology of EPVT is diverse and can be divided into local risk factors such as cirrhosis, hepatobiliary malignancies and pancreatitis, and systemic risk factors such as inherited and acquired prothrombotic disorders. In at least one third of the patients a combination of thrombotic risk factors is demonstrated[4]. If EPVT is suspected, diagnosis can be rapidly established by use of noninvasive imaging, which generally reveals



**Figure 1.** Anatomy of the portal vein

the presence of solid material within the venous lumen. Ultrasonography is the imaging modality most frequently used.

From a clinical point of view, EPVT consists of two different entities, recent and chronic EPVT. They share similar causes, but differ in clinical presentation and management. A recent thrombosis is characterized by the sudden formation of a thrombus in the portal vein and usually presents with abdominal pain. When extensive thrombosis involves the mesenteric venous arches, intestinal ischemia and later infarction can occur[5]. Chronic EPVT, usually becomes manifest as a complication of the existing portal hypertension. The goal of treatment depends on the onset of the thrombosis. In patients with recent EPVT treatment is aimed to restore flow patency and prevent recurrence or extension of the thrombosis. In chronic EPVT patients treatment is mainly aimed to manage portal hypertension related complications. Variceal bleeding is the most common complication of portal hypertension. Endoscopic therapy have been found to be effective in the control and prevention of variceal bleeding. If endoscopic therapy fails a transjugular intrahepatic portosystemic shunt (TIPS), if technical applicable, can be considered. Another alternative that can be considered is a surgical shunt. Main problems with this treatment are peroperative bleeding and thrombosis of the shunt.

In the last decade new advantages and insights have been made, especially in identifying prothrombotic disorders as underlying cause of EPVT [4, 6-8]. These findings have led to a more prominent role of anticoagulation therapy in EPVT patients [9]. However data on the risk and benefit of anticoagulation therapy are scarce, due to lack of large cohort studies. This lack of data is also seen with regard to portal hypertension related complications. In contrast to cirrhotic patients less is known in non cirrhotic patients with portal hypertension related complications.

## **AIMS**

In this thesis we aim to study the prevalence, clinical outcome and management of patients with non- cirrhotic non- malignant EPVT. In particular we studied the risk- benefit ratio of anticoagulation and endoscopic therapy as treatment option for complications related to portal hypertension in EPVT.

## OUTLINE OF THE THESIS

**Chapter 1.** Introduction and aims

**Chapter 2.** This chapter gives a general overview of patients with non- cirrhotic non-malignant EPVT. Etiology, clinical features depending on the onset of the thrombosis and the corresponding treatment modalities are discussed. In patients with chronic EPVT clinical features are portal hypertension related.

**Chapter 3.** The most common complication of portal hypertension in EPVT patients is variceal bleeding. Gastrointestinal bleeding caused by portal hypertension in patients with EPVT has been reported to cause death in 1.0 to 20% of the patients [9-11]. Endoscopic treatment is the first line intervention in patients with bleeding esophagogastric varices. In this chapter we describe the long-term clinical outcome and efficacy of endoscopic treatment in patients with esophagogastric variceal bleeding secondary to non cirrhotic EPVT.

**Chapter 4.** Another phenomenon of portal hypertension is ascites. In contrast to patients with cirrhosis, where ascites is a poor prognostic feature, little is known of ascites in non- cirrhotic non- malignant patients with EPVT. In this chapter we assessed all patients with ascites at the time EPVT was diagnosed and observed the frequency, natural history and prognostic implication of ascites in these patients.

**Chapter 5.** The role of anticoagulation therapy in patients with EPVT is ambiguous. The evidence is rather low due to lack of large trials. In this chapter we studied a cohort of patients with and without anticoagulation therapy and assessed the effect of anticoagulation therapy on risk of gastrointestinal bleeding and recurrent thrombotic events in patient with EVPT.

**Chapter 6.** Another treatment modality of recent EPVT is thrombolysis. In the last decade we have done transcatheter local thrombolytic therapy in patients with recent EPVT. In this chapter we describe our experience with this treatment modality.

**Chapter 7.** In almost all patients with chronic EPVT biliary abnormalities can be found. In only a few patients this will lead to symptomatic manifestations [12, 13]. In this chapter we describe incidence and clinical outcome of non- cirrhotic patients with symptomatic portal biliopathy seen at our hospital.

**Chapter 8.** Summary and discussion

**REFERENCES**

- [1] De Franchis R. Revising consensus in portal hypertension. Report of the Baveno V consensus Workshop on methodology of diagnosis and therapy in Portal Hypertension. *J Hepatol*. Milano: University of Milano 2010.
- [2] Henderson JM, Gilmore GT, Mackay GJ, Galloway JR, Dodson TF, Kutner MH. Hemodynamics during liver transplantation: the interactions between cardiac output and portal venous and hepatic arterial flows. *Hepatology*. 1992 Sep;16(3):715-8.
- [3] Lebrech D, Bataille C, Bercoff E, Valla D. Hemodynamic changes in patients with portal venous obstruction. *Hepatology*. 1983 Jul-Aug;3(4):550-3.
- [4] Janssen HL, Meinardi JR, Vleggaar FP, van Uum SH, Haagsma EB, van Der Meer FJ, et al. Factor V Leiden mutation, prothrombin gene mutation, and deficiencies in coagulation inhibitors associated with Budd-Chiari syndrome and portal vein thrombosis: results of a case-control study. *Blood*. 2000 Oct 1;96(7):2364-8.
- [5] Kumar S, Sarr MG, Kamath PS. Mesenteric venous thrombosis. *N Engl J Med*. 2001 Dec 6;345(23):1683-8.
- [6] Primignani M, Martinelli I, Bucciarelli P, Battaglioli T, Reati R, Fabris F, et al. Risk factors for thrombophilia in extrahepatic portal vein obstruction. *Hepatology*. 2005 Mar;41(3):603-8.
- [7] Egesel T, Buyukasik Y, Dundar SV, Gurgey A, Kirazli S, Bayraktar Y. The role of natural anticoagulant deficiencies and factor V Leiden in the development of idiopathic portal vein thrombosis. *J Clin Gastroenterol*. 2000 Jan;30(1):66-71.
- [8] Colaizzo D, Amitrano L, Tiscia GL, Scenna G, Grandone E, Guardascione MA, et al. The JAK2 V617F mutation frequently occurs in patients with portal and mesenteric venous thrombosis. *J Thromb Haemost*. 2007 Jan;5(1):55-61.
- [9] Condat B, Pessione F, Hillaire S, Denninger MH, Guillin MC, Poliquin M, et al. Current outcome of portal vein thrombosis in adults: risk and benefit of anticoagulant therapy. *Gastroenterology*. 2001 Feb;120(2):490-7.
- [10] Webb LJ, Sherlock S. The aetiology, presentation and natural history of extra-hepatic portal venous obstruction. *Q J Med*. 1979 Oct;48(192):627-39.
- [11] Cohen J, Edelman RR, Chopra S. Portal vein thrombosis: a review. *Am J Med*. 1992 Feb;92(2):173-82.
- [12] Khuroo MS, Yattoo GN, Zargar SA, Javid G, Dar MY, Khan BA, et al. Biliary abnormalities associated with extrahepatic portal venous obstruction. *Hepatology*. 1993 May;17(5):807-13.
- [13] Khare R, Sikora SS, Srikanth G, Choudhuri G, Saraswat VA, Kumar A, et al. Extrahepatic portal venous obstruction and obstructive jaundice: approach to management. *J Gastroenterol Hepatol*. 2005 Jan;20(1):56-61.

## Chapter 2

---


### **Non-cirrhotic non-malignant portal vein thrombosis: a review on the management of non-cirrhotic non- malignant portal vein thrombosis and the concurrent portal hypertension complications in adults**

MCW Spaander, HR van Buuren, HLA Janssen

*Department of Gastroenterology and Hepatology, Erasmus MC University Medical Center  
Rotterdam, The Netherlands*



*Aliment Pharmacol Ther. 2007 Dec;26 Suppl 2:203-9.*



## ABSTRACT

**Background:** Extrahepatic portal vein thrombosis (EPVT) is an important cause of non-cirrhotic portal hypertension throughout the globe.

**Aim:** To provide an update on recent advances in the aetiology and management of acute and chronic non-cirrhotic non-malignant EPVT.

**Method:** A Pubmed search was performed to identify relevant literature using search terms including 'portal vein thrombosis', 'variceal bleeding' and 'portal biliopathy'.

**Results:** Myeloproliferative disease is the most common risk factor in patients with non-cirrhotic non-malignant EPVT. Anticoagulation therapy for at least three months is indicated in patients with acute EPVT. However, in patients with EPVT due to a prothrombotic disorder, permanent anticoagulation therapy has been recommended. The most important complication of EPVT is esophagogastric variceal bleeding. Endoscopic treatment is the first-line treatment for variceal bleeding. In several of the patients with EPVT biliopathy changes on ERCP have been reported. Dependent on the persistence of the biliary obstruction treatment can vary from ERCP to hepaticojunostomy.

**Conclusion:** Prothrombotic disorders are the major cause of non-cirrhotic, non-malignant EPVT. Anticoagulation therapy is warranted in these patients. The prognosis of patients with non-cirrhotic non-malignant EPVT is good, and is not determined by portal hypertension complications but mainly by underlying causes of thrombosis.



## INTRODUCTION

Extrahepatic portal vein thrombosis (EPVT) is an important cause of non-cirrhotic portal hypertension throughout the globe. The aetiology of EPVT is heterogeneous and both local and systemic risk factors can be involved. Primary local risk factors for EPVT are cirrhosis, hepatobiliary malignancies and pancreatitis.[1, 2] Myeloproliferative disorders and prothrombotic genetic defects are the major systemic risk factors for EPVT. [3] The most important complication of EPVT is esophagogastric variceal bleeding with a reported mortality rate of 1.0 to 20%.[1, 2, 4-7]

## ACUTE PORTAL VEIN THROMBOSIS

Acute EPVT is characterised by a sudden formation of a thrombus within the portal vein, which leads to a complete or partial obstruction of the portal vein.

Patients with acute EPVT may experience a sudden onset of right upper abdominal or lumbar pain, but symptoms can also be non-specific or absent. Partial obstruction seems to be associated with fewer symptoms, than acute complete obstruction where features of intestinal congestion as permanent abdominal pain and diffuse thickening of the intestinal wall or an ileus can be present. Fever and ascites, usually in small quantities and of transient character, may be present. All these manifestations of acute EPVT are completely reversible, provided that the thrombus is limited to the portal vein. When the thrombosis extends into the mesenteric venous arches, intestinal ischaemia and later, infarction can occur.[8] Liver enzymes and bilirubin are usually normal or only mildly disturbed in patients free of liver diseases.[9] For most patients, in whom EPVT is suspected, diagnosis can be established by non-invasive imaging techniques, including Color Doppler- ultrasonography, CT-scan and MRI. Color Doppler-ultrasonography is the least expensive method, but the sensitivity and specificity are affected by inter-patient variability and expertise of a given radiologist.[10] CT-scan and MRI can provide more additional information on adjacent organs, vascular status, and extension of the thrombus. Once acute EPVT has been diagnosed, the cause of EPVT should be elucidated. In about 30% of the patients with acute EPVT a local risk factor can be identified and in 70% a systemic risk factor can be found. [11-16] Local risk factors are mainly infectious and inflammatory diseases, such as diverticulitis, appendicitis, pancreatitis, cholecystitis, cholangitis and inflammatory bowel diseases. But also abdominal trauma and surgery, especially splenectomy, can cause EPVT. The latter is mainly seen in patients with myeloproliferative diseases and rarely in patient with lymphoma or splenic trauma. [17] An acquired or inherited prothrombotic disorder can be identified in the majority of patients . (Table 1) Concurrence of either acquired or inherited prothrombotic dis-

**Table 1.** Thrombotic risk factors in patients with extrahepatic portal vein thrombosis

<i>Thrombotic risk factor</i>	<i>prevalence of risk factor in patients with EPVT %</i>
<b>Systemic</b>	
Myeloproliferative disease	14 – 35
Antiphospholipid syndrome	6 – 11
Factor V Leiden mutation	3 – 8
Factor II gene mutation	3– 22
Protein C deficiency*	0 – 7
Protein S deficiency*	2 – 30
Antithrombin deficiency*	1 – 5
Recent oral contraceptive use	21 – 48
<b>Local</b>	
Inflammatory diseases/ Infectious diseases*	5 - 17
Surgery*	5 - 30
Trauma	0 - 3
Cirrhosis	17- 22
Malignancies	24

\* different definitions are used  
[7, 11-13]

orders is common.[7, 12]Therefore extensive investigation of prothrombotic disorders is recommended. Frequently, EPVT is the first manifestation of a myeloproliferative disease, which is the major cause of EPVT and can be identified in at least 25- 30% of the patients[11, 12, 18]. It is often problematic to diagnose an underlying myeloproliferative disorder in patients with EPVT; clinical and haematological parameters usually yield insufficient information. The JAK2 V617F has recently been reported to represent, a reliable and non-invasive molecular tool and can be used as an additional diagnostic tool for identifying myeloproliferative disorders.[19, 20]

Treatment of acute EPVT aims to recanalize the obstructed veins and prevent extension of the thrombus. Once the diagnosis has been established anticoagulant treatment is indicated. The current recommendation is to continue oral anticoagulation for a period of at least three months. [21] In patients with a prothrombotic disorder life-long anticoagulant therapy should be considered. Although there are several case reports and reports of small series indicating that procedures as thrombectomy and local or systemic thrombolysis may be successful, the place of these invasive procedures is as yet uncertain. Also considering the risk of major procedure related complications, in one report in up to 60% of the cases, most centers tend to choose a more conservative therapeutic strategy. [22]

## CHRONIC PORTAL VEIN THROMBOSIS

Chronic portal vein thrombosis usually leads to the formation of portal cavernoma. Cavernous transformation refers to the development of a network of porto-portal collateral veins bypassing the site of obstruction. Non-invasive imaging as ultrasound, CT-scan or MRI, can easily make a diagnosis of portal cavernoma.

Systemic causes are similar in prevalence as in acute EPVT.[23] However local risk factors can be missed in patients with chronic EPVT. The clinical presentation of chronic EPVT is mainly characterised by manifestations of portal hypertension such as esophago-gastric varices and hypersplenism. Encephalopathy and ascites are uncommon features in patients with chronic EPVT without underlying cirrhosis. In contrast to variceal bleeding in patients with cirrhosis the risk of developing liver failure and death is rare and mortality is primarily related to medical conditions, which are often the cause of EPVT, rather than to variceal bleeding. [7] Serum liver tests are typically normal or near normal. However, when cholestatic features are present abnormalities of the extra- and intra-hepatic bile ducts should be considered.

The treatment of chronic EPVT aims to reverse manifestations of portal hypertension such as gastrointestinal bleeding (see variceal bleeding). There is no consensus on the indication for anticoagulant therapy. However in patients with a persistent prothrombotic state, anticoagulant therapy can be considered.

## VARICEAL BLEEDING

More than 85 to 90% of patients with chronic EPVT have esophageal varices and 30 to 40% percent have concomitant gastric varices.[1] Also, rectal, duodenal and other types of ectopic varices may occur. The size of esophageal varices and to a lesser degree, initial presentation with gastroesophageal bleeding are independent predictors for rebleeding both in patients with EPVT as in patients with cirrhosis[4, 24]. Although variceal bleeding is the most important complication, EPVT-related mortality appears primarily determined by other causes than variceal bleeding[7, 25].

Prophylaxis: there are no controlled studies of  $\beta$ -adrenergic blockade or endoscopic therapy as primary prophylaxis for esophageal variceal bleeding in patients with EPVT. It has only been speculated that in patients with large esophageal varices  $\beta$ -adrenergic blockade or endoscopic therapy can be carried out and reduce the incidence of first bleeding as they are for patients with cirrhosis[26]. Two retrospective studies have suggested that  $\beta$ -adrenergic blockade may play a role in secondary prophylaxis as they reduce the risk of rebleeding and improve survival after EPVT-induced variceal haemorrhage[4, 27]. However, there is as yet insufficient evidence to recommend wide spread

use of  $\beta$ -adrenergic blockade for secondary prophylaxis [21]. Endoscopic therapy is safe and have been found to be effective in prevention of rebleeding[25].

Treatment of active variceal bleeding: endoscopic injection sclerotherapy (EIS) and endoscopic variceal ligation (EVL) of esophagogastric varices have been found to be effective in the control and prevention of variceal haemorrhage[25, 28-34]. Since 1986 EVL has mainly been used as endoscopic method for treating esophageal varices. EIS is often reserved for the treatment of active gastric variceal bleeding. Although there are limited data on the use of vasoactive agents for the control of active bleeding in patients with EPVT, these drugs are usually recommended [21]. There is evidence that TIPS is successful, when technical applicable.[35-37] Unsuccessful TIPS placement are mainly due to fact that the lumen of the thrombosed portal vein is no longer catheterizable or the fragile cavernomatous vein could not be dilated without risk of rupture. If endoscopic treatment fail a surgical shunt can be considered [21]. (Table 2). Both total and selective shunts have been used[38-40].However, nowadays selective shunts, as the (distal) splenorenal shunt, are the preferred type of shunt surgery, due to a low risk of encephalopathy and durable decompression. [41, 42] The main problems that occur with these procedures is per operative bleeding due to existence of collaterals, extension of the thrombosis into the splenic and mesenterial veins and thrombosis of the shunt. It

**Table 2.** Treatment recommendations of EPVT

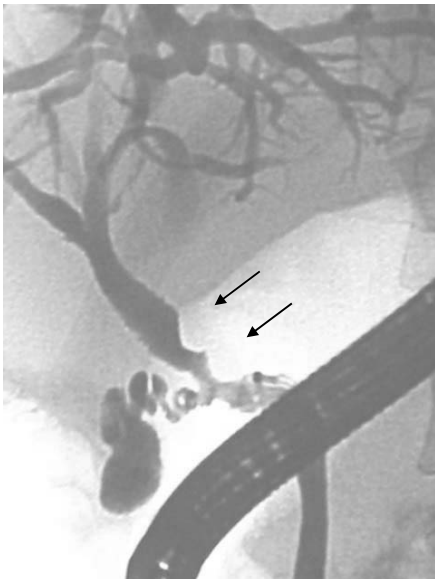<i>Treatment</i>	<i>indication</i>
<b>Thrombotic obstruction</b>	
Anticoagulants	acute EPVT chronic EPVT if a prothrombotic disorder is present
Thrombolysis and thrombectomy	not recommended (high complication rate)
<b>Variceal bleeding</b>	
Endoscopic treatment	active variceal bleeding secondary prophylaxis for rebleeding
Vasoactive agents	can be considered in patients with active variceal bleeding
$\beta$ -adrenergic blockade	not yet recommended (insufficient evidence)
TIPS	if endoscopic treatment fails and if technical applicable (little evidence)
Surgical shunt	if endoscopic treatment fails
<b>Portal biliopathy</b>	
Sphincterotomy, balloon dilatation, endoprosthesis	jaundice/ cholangitis/ biliary stenosis/ bile duct stones
Portosystemic shunt	persistent biliary obstruction despite endoscopic treatment
Hepaticojejunostomy	persistent biliary obstruction despite a portosystemic shunt

is suggested that shunt thrombosis depends mainly on sufficient caliber and thrombus free veins, which are suitable to create a tension free and wide anastomosis.[43] Splenectomy alone is an inappropriate operation for the treatment of hypersplenism and portal hypertension.[38, 44] It does not prevent variceal bleeding and destroys the opportunity to use the splenic vein for a shunt. Especially in patients with non-cirrhotic portal hypertension and in patients with myeloproliferative disorders, where the spleen may become a place for extramedullary marrow formation, one should preserve the spleen, whenever possible.[43]

## PORTAL BILIOPATHY

Portal biliopathy is defined as abnormalities of the extrahepatic and intrahepatic bile ducts due to impressions of porta-portal collaterals in patients with portal hypertension secondary to EPVT. [45-48] (Figure 1). In 80-100% of the patients with EPVT biliary abnormalities, such as indentations, marked angles, stenosis and biliary stones have been reported. The biliary abnormalities involve the large bile ducts, especially the common bile duct and the main left hepatic duct. The small bile ducts remain normal as liver biopsy does not demonstrate evidence of ductopenia or ductular proliferation.

The left hepatic duct is involved more often; this may due to formation of prominent collateral veins where the umbilical vein joins the left branch of the portal vein. The bili-



**Figure 1.** Portal biliopathy in a patient with chronic portal vein thrombosis. ERCP showing a sharp angled CBD with impressions (arrows)

ary abnormalities are common in EPVT because paracholecystic and paracholedochal form the porto-portal collaterals to bypass the obstructed segment of the portal vein. The cause of the biliary abnormalities can not only be explained by compression of the bile ducts due to the collaterals but also by ischemic injury of the bile ducts due to thrombosis of veins draining the bile duct.[45] Portal biliopathy is despite its common occurrence, rarely symptomatic. [47] However biochemical changes can be seen. Symptomatic patients are usually adults, which may indicate that portal biliopathy is a slowly progressive disease. Portal biliopathy can be diagnosed with ERCP or MRCP and can mimic the bead-like appearance of primary sclerosing cholangitis.[49] In patients with cholangitis and choledocholithiasis biliary stenting, balloon dilatation, sphincterotomy and stone extraction can give symptomatic relief. For dominant biliary strictures and endoscopic failures, portosystemic shunting can be considered, which can lead to amelioration of the biliary obstruction. In patients with persistent obstruction, hepaticojejunostomy may be needed to treat the biliary obstruction. (Table 2). Prior to the hepaticojejunostomy a portosystemic shunt can be made, to have better access to the region.[50]

## CONCLUSION

Thrombotic risk factors, especially myeloproliferative disorders are the main cause of non-cirrhotic EPVT. Extensive investigation for these risk factors is recommended, also because concurrence of acquired and inherited prothrombotic disorders is common. [7, 12] In patients with acute EPVT oral anticoagulation for at least three months is warranted. In patients with chronic EPVT, due to a prothrombotic disorder, permanent oral anticoagulation therapy can be considered. The most important complication of EPVT is variceal bleeding. Endoscopic treatment is the first-line treatment both for active variceal bleeding and for secondary prophylaxis. If endoscopic treatment fails, a TIPS or a selective surgical shunt should be considered. The use of  $\beta$ -adrenergic blockade as primary or secondary prophylaxis is not yet recommendable, due to insufficient evidence.

Portal biliopathy can play a role in the long-term outcome, because of its slowly progressive character. If endoscopic treatment fails a portosystemic shunt with if necessary a hepaticojejunostomy can be considered.

The prognosis of patients with EPVT is good. Mortality is mainly determined by concomitant diseases which led to EPVT and not by complications of portal hypertension.

## REFERENCES

- [1] Webb LJ, Sherlock S. The aetiology, presentation and natural history of extra-hepatic portal venous obstruction. *Q J Med.* 1979 Oct;48(192):627-39.
- [2] Cohen J, Edelman RR, Chopra S. Portal vein thrombosis: a review. *Am J Med.* 1992 Feb;92(2):173-82.
- [3] Valla D, Casadevall N, Huisse MG, Tulliez M, Grange JD, Muller O, et al. Etiology of portal vein thrombosis in adults. A prospective evaluation of primary myeloproliferative disorders. *Gastroenterology.* 1988 Apr;94(4):1063-9.
- [4] Condat B, Pessione F, Hillaire S, Denninger MH, Guillin MC, Poliquin M, et al. Current outcome of portal vein thrombosis in adults: risk and benefit of anticoagulant therapy. *Gastroenterology.* 2001 Feb;120(2):490-7.
- [5] Grauer SE, Schwartz SI. Extrahepatic portal hypertension: a retrospective analysis. *Ann Surg.* 1979 May;189(5):566-74.
- [6] Voorhees AB, Jr., Price JB, Jr. Extrahepatic portal hypertension. A retrospective analysis of 127 cases and associated clinical implications. *Arch Surg.* 1974 Mar;108(3):338-41.
- [7] Janssen HL, Wijnhoud A, Haagsma EB, van Uum SH, van Nieuwkerk CM, Adang RP, et al. Extrahepatic portal vein thrombosis: aetiology and determinants of survival. *Gut.* 2001 Nov;49(5):720-4.
- [8] Kumar S, Sarr MG, Kamath PS. Mesenteric venous thrombosis. *N Engl J Med.* 2001 Dec 6;345(23):1683-8.
- [9] Sarin SK, Agarwal SR. Extrahepatic portal vein obstruction. *Semin Liver Dis.* 2002 Feb;22(1):43-58.
- [10] Wang JT, Zhao HY, Liu YL. Portal vein thrombosis. *Hepatobiliary Pancreat Dis Int.* 2005 Nov;4(4):515-8.
- [11] Primignani M, Martinelli I, Bucciarelli P, Battaglioli T, Reati R, Fabris F, et al. Risk factors for thrombophilia in extrahepatic portal vein obstruction. *Hepatology.* 2005 Mar;41(3):603-8.
- [12] Denninger MH, Chait Y, Casadevall N, Hillaire S, Guillin MC, Bezeaud A, et al. Cause of portal or hepatic venous thrombosis in adults: the role of multiple concurrent factors. *Hepatology.* 2000 Mar;31(3):587-91.
- [13] Janssen HL, Meinardi JR, Vleggaar FP, van Uum SH, Haagsma EB, van Der Meer FJ, et al. Factor V Leiden mutation, prothrombin gene mutation, and deficiencies in coagulation inhibitors associated with Budd-Chiari syndrome and portal vein thrombosis: results of a case-control study. *Blood.* 2000 Oct 1;96(7):2364-8.
- [14] Chamouard P, Pencreach E, Maloisel F, Grunebaum L, Ardizzone JF, Meyer A, et al. Frequent factor II G20210A mutation in idiopathic portal vein thrombosis. *Gastroenterology.* 1999 Jan;116(1):144-8.
- [15] Mahmoud AE, Elias E, Beauchamp N, Wilde JT. Prevalence of the factor V Leiden mutation in hepatic and portal vein thrombosis. *Gut.* 1997 Jun;40(6):798-800.
- [16] Bhattacharyya M, Makharia G, Kannan M, Ahmed RP, Gupta PK, Saxena R. Inherited prothrombotic defects in Budd-Chiari syndrome and portal vein thrombosis: a study from North India. *Am J Clin Pathol.* 2004 Jun;121(6):844-7.
- [17] Hassn AM, Al-Fallouji MA, Ouf TI, Saad R. Portal vein thrombosis following splenectomy. *Br J Surg.* 2000 Mar;87(3):362-73.
- [18] Briere JB. Budd-Chiari syndrome and portal vein thrombosis associated with myeloproliferative disorders: diagnosis and management. *Semin Thromb Hemost.* 2006 Apr;32(3):208-18.

- [19] Primignani M, Barosi G, Bergamaschi G, Gianelli U, Fabris F, Reati R, et al. Role of the JAK2 mutation in the diagnosis of chronic myeloproliferative disorders in splanchnic vein thrombosis. *Hepatology*. 2006 Dec;44(6):1528-34.
- [20] Janssen HL, Leebeek FW. JAK2 mutation: The best diagnostic tool for myeloproliferative disease in splanchnic vein thrombosis? *Hepatology*. 2006 Dec;44(6):1391-3.
- [21] de Franchis R. Evolving consensus in portal hypertension. Report of the Baveno IV consensus workshop on methodology of diagnosis and therapy in portal hypertension. *J Hepatol*. 2005 Jul; 43(1):167-76.
- [22] Hollingshead M, Burke CT, Mauro MA, Weeks SM, Dixon RG, Jaques PF. Transcatheter thrombolytic therapy for acute mesenteric and portal vein thrombosis. *J Vasc Interv Radiol*. 2005 May;16(5): 651-61.
- [23] Condat B, Pessione F, Helene Denninger M, Hillaire S, Valla D. Recent portal or mesenteric venous thrombosis: increased recognition and frequent recanalization on anticoagulant therapy. *Hepatology*. 2000 Sep;32(3):466-70.
- [24] Pagliaro L, D'Amico G, Luca A, Pasta L, Politi F, Aragona E, et al. Portal hypertension: diagnosis and treatment. *J Hepatol*. 1995;23 Suppl 1:36-44.
- [25] Vleggaar FP, van Buuren HR, Schalm SW. Endoscopic sclerotherapy for bleeding oesophagogastric varices secondary to extrahepatic portal vein obstruction in an adult Caucasian population. *Eur J Gastroenterol Hepatol*. 1998 Jan;10(1):81-5.
- [26] Condat B, Valla D. Nonmalignant portal vein thrombosis in adults. *Nat Clin Pract Gastroenterol Hepatol*. 2006 Sep;3(9):505-15.
- [27] Orr D. Chronic portomesenteric and portosplenomesenteric venous thrombosis: evaluation of long term follow up and determinants of survival. *Hepatology*. 2005;42 Suppl 1:212A.
- [28] Kahn D, Terblanche J, Kitano S, Bornman P. Injection sclerotherapy in adult patients with extrahepatic portal venous obstruction. *Br J Surg*. 1987 Jul;74(7):600-2.
- [29] Sarin SK, Nanda R, Kumar N, Vij JC, Anand BS. Repeated endoscopic sclerotherapy for active variceal bleeding. *Ann Surg*. 1985 Dec;202(6):708-11.
- [30] Van Stiegmann G, Cambre T, Sun JH. A new endoscopic elastic band ligating device. *Gastrointest Endosc*. 1986 Jun;32(3):230-3.
- [31] Laine L, Cook D. Endoscopic ligation compared with sclerotherapy for treatment of esophageal variceal bleeding. A meta-analysis. *Ann Intern Med*. 1995 Aug 15;123(4):280-7.
- [32] Lo GH, Lai KH, Cheng JS, Lin CK, Huang JS, Hsu PI, et al. Emergency banding ligation versus sclerotherapy for the control of active bleeding from esophageal varices. *Hepatology*. 1997 May;25(5): 1101-4.
- [33] Stiegmann GV, Goff JS, Sun JH, Davis D, Bozdech J. Endoscopic variceal ligation: an alternative to sclerotherapy. *Gastrointest Endosc*. 1989 Sep-Oct;35(5):431-4.
- [34] Celinska-Cedro D, Teisseyre M, Woynarowski M, Socha P, Socha J, Ryzko J. Endoscopic ligation of esophageal varices for prophylaxis of first bleeding in children and adolescents with portal hypertension: preliminary results of a prospective study. *J Pediatr Surg*. 2003 Jul;38(7):1008-11.
- [35] Senzolo M, Tibbals J, Cholongitas E, Triantos CK, Burroughs AK, Patch D. Transjugular intrahepatic portosystemic shunt for portal vein thrombosis with and without cavernous transformation. *Aliment Pharmacol Ther*. 2006 Mar 15;23(6):767-75.
- [36] Bilbao JI, Elorz M, Vivas I, Martinez-Cuesta A, Bastarrika G, Benito A. Transjugular intrahepatic portosystemic shunt (TIPS) in the treatment of venous symptomatic chronic portal thrombosis in non-cirrhotic patients. *Cardiovasc Intervent Radiol*. 2004 Sep-Oct;27(5):474-80.



- [37] Stambo GW, Grauer L. Transhepatic portal venous power-pulse spray rheolytic thrombectomy for acute portal vein thrombosis after CT-guided pancreas biopsy. *AJR Am J Roentgenol.* 2005 Mar; 184(3 Suppl):S118-9.
- [38] Orloff MJ, Orloff MS, Girard B, Orloff SL. Bleeding esophagogastric varices from extrahepatic portal hypertension: 40 years' experience with portal-systemic shunt. *J Am Coll Surg.* 2002 Jun; 194(6):717-28; discussion 28-30.
- [39] Warren WD, Henderson JM, Millikan WJ, Galambos JT, Bryan FC. Management of variceal bleeding in patients with noncirrhotic portal vein thrombosis. *Ann Surg.* 1988 May;207(5):623-34.
- [40] Henderson JM, Millikan WJ, Galambos JT, Warren WD. Selective variceal decompression in portal vein thrombosis. *Br J Surg.* 1984 Oct;71(10):745-9.
- [41] Gawish Y, El-Hammadi HA, Kotb M, Awad AT, Anwar M. Devascularization procedure and DSRS: a controlled randomized trial on selected haemodynamic portal flow pattern in schistosomal portal hypertension with variceal bleeding. *Int Surg.* 2000 Oct-Dec;85(4):325-30.
- [42] Mitra SK, Rao KL, Narasimhan KL, Dilawari JB, Batra YK, Chawla Y, et al. Side-to-side lienorenal shunt without splenectomy in noncirrhotic portal hypertension in children. *J Pediatr Surg.* 1993 Mar;28(3):398-401; discussion -2.
- [43] Wolff M, Hirner A. Current state of portosystemic shunt surgery. *Langenbecks Arch Surg.* 2003 Jul; 388(3):141-9.
- [44] el-Khishen MA, Henderson JM, Millikan WJ, Jr., Kutner MH, Warren WD. Splenectomy is contraindicated for thrombocytopenia secondary to portal hypertension. *Surg Gynecol Obstet.* 1985 Mar; 160(3):233-8.
- [45] Dhiman RK, Puri P, Chawla Y, Minz M, Bapuraj JR, Gupta S, et al. Biliary changes in extrahepatic portal venous obstruction: compression by collaterals or ischemic? *Gastrointest Endosc.* 1999 Nov;50(5):646-52.
- [46] Khuroo MS, Yattoo GN, Zargar SA, Javid G, Dar MY, Khan BA, et al. Biliary abnormalities associated with extrahepatic portal venous obstruction. *Hepatology.* 1993 May;17(5):807-13.
- [47] Khare R, Sikora SS, Srikanth G, Choudhuri G, Saraswat VA, Kumar A, et al. Extrahepatic portal venous obstruction and obstructive jaundice: approach to management. *J Gastroenterol Hepatol.* 2005 Jan;20(1):56-61.
- [48] Sarin SK. Portal biliopathy in extrahepatic portal vein thrombosis. *Ind J of Gastroenterology.* 1992; 11(A82).
- [49] Condat B, Vilgrain V, Asselah T, O'Toole D, Rufat P, Zappa M, et al. Portal cavernoma-associated cholangiopathy: a clinical and MR cholangiography coupled with MR portography imaging study. *Hepatology.* 2003 Jun;37(6):1302-8.
- [50] Chaudhary A, Dhar P, Sarin SK, Sachdev A, Agarwal AK, Vij JC, et al. Bile duct obstruction due to portal biliopathy in extrahepatic portal hypertension: surgical management. *Br J Surg.* 1998 Mar; 85(3):326-9.



## Chapter 3


---

### **Endoscopic treatment of esophagogastric variceal bleeding in patients with non- cirrhotic extrahepatic portal vein thrombosis: A long term follow-up study**

MCW Spaander<sup>1</sup>, S Darwish Murad<sup>1</sup>, HR van Buuren<sup>1</sup>, BE Hansen<sup>2</sup>, EJ Kuipers<sup>1</sup>,  
HLA Janssen<sup>1</sup>

*1. Department of Gastroenterology and Hepatology, 2. Department of Epidemiology and Biostatistics, Erasmus MC University Medical Center Rotterdam, Rotterdam, The Netherlands*

*Gastrointest Endosc. 2008 Jan 16 vol 67;6 821-827*



## ABSTRACT

**Background:** Esophagogastric variceal bleeding is the most important complication of extrahepatic portal vein thrombosis (EPVT), and is usually treated endoscopically. Little is known on the prognosis of these patients.

**Objectives:** To investigate the long-term clinical outcome and efficacy of endoscopic treatment in patients with esophagogastric variceal bleeding secondary to EPVT.

**Design:** Retrospective observational study.

**Settings:** Single university center.

**Patients:** Twenty-seven consecutive patients with esophagogastric variceal bleeding secondary to non-cirrhotic, non-malignant EPVT, who underwent endoscopic treatment between 1982 and 2005.

**Interventions:** endoscopic band ligation and/ or endoscopic sclerotherapy.

**Main outcome measurements:** overall rebleeding risk, overall survival, complications of the endoscopic procedures and predictive values of rebleeding. Analyses were performed by Kaplan Meier method and univariate Cox regression.

**Results:** All patients were followed after their first endoscopic treated variceal bleeding. A total of 241 endoscopic procedures were performed. In all patients, initial control of bleeding was obtained. Overall re-bleeding risk was 23% (95% CI 0-24) at 1- year and 37% (95% CI 43-83) at 5-years. Extension of thrombosis into the splenic vein and the presence of fundal varices were significant predictors of re-bleeding, with a nearly 5-fold increased risk for EPVT patients with fundal varices at the time of the first variceal hemorrhage (HR= 5.07; p= 0.01). A porto-systemic shunt procedure was performed in five patients, in four for variceal bleeding and in one for refractory ascites. Seven patients died, not one due to variceal bleeding. Overall 5- and 10-year survival was 100% and 62% (95% CI 38%-96%), respectively.

**Limitations:** retrospective design.

**Conclusion:** In patients with variceal bleeding secondary to EPVT endoscopic treatment, in particular band ligation, appears safe and effective. EPVT-related mortality is primarily determined by other causes than variceal bleeding.

## INTRODUCTION

Extra-hepatic portal vein thrombosis (EPVT) is throughout the globe an important cause of non-cirrhotic portal hypertension. The aetiology of EPVT is heterogeneous. Primary risk factors for EPVT are cirrhosis, hepatobiliary malignancies and pancreatitis. In addition, systemic risk factors for thrombosis, such as myeloproliferative disorders and prothrombotic genetic defects, have been identified as major risk factors for EPVT. Esophagogastric variceal bleeding is the most important complication of EPVT<sup>1</sup>. In one study the incidence rate of esophagogastric variceal bleeding in patients with EPVT was 35%. Fifty-eight percent of these patients had a recurrent bleeding<sup>1-6</sup>. Gastrointestinal bleeding caused by portal hypertension in patients with EPVT has been reported to cause death in 1.5 to 20% of the patients<sup>1-5</sup>. Endoscopic treatment is the first line intervention in patients with bleeding esophagogastric varices. Since 1986 endoscopic variceal ligation (EVL) has increasingly being used as an alternative endoscopic method for treating esophageal varices<sup>6</sup>. EVL is as effective as endoscopic injection sclerotherapy (EIS) but has less complications<sup>6-9</sup>. In contrast to endoscopic treatment of variceal bleeding in patients with cirrhosis, little is known about the outcome of this treatment in adult patients with EPVT.

In the current cohort study we investigated the efficacy of endoscopic treatment and clinical outcome as well as predictors of rebleeding in adult patients with esophagogastric variceal bleeding due to non-cirrhotic, non-malignant EPVT.

## PATIENTS AND METHODS

### Design of the study

Patients were identified by means of a search in the computerised patient registration system of our clinic, which serves a tertiary referral function. All adult patients identified between January 1982 and October 2005 were enrolled if (1) extra-hepatic portal vein thrombosis was documented (2) cancer and/ or cirrhosis were absent, (3) variceal bleeding was present and (4) endoscopic treatment was performed. For all patients a standardised clinical record form for specific clinical data, obtained from the medical charts, was completed.

From a total of 195 patients with EPVT, 27 patients were included in this study. Patients were excluded for the following reasons: 63 patients had cirrhosis, 49 patients had malignancies, 7 patients had developed EPVT after liver transplantation and in 49 patients variceal bleeding did not occur.

Among the 27 patients in the cohort, follow-up lasted from the time of endoscopic treatment of variceal bleeding to either November 2005 or death, whichever came first.

### **Diagnostic assessment**

Diagnostic criteria for EPVT were partial or complete obstruction of the extrahepatic portal vein, as documented by appropriate radiological imaging, such as Doppler ultrasonography, computed tomography, magnetic resonance imaging, venography and angiography. Cirrhosis was excluded by a combination of absence of biochemical evidence of liver failure, absence of cirrhosis at imaging and in 18 cases absence of cirrhosis on liver biopsy.

Gastroesophageal varices were graded according to the following classification<sup>10</sup>: grade 1, varices flattened by insufflation; grade 2, varices not flattened by insufflation; grade 3, confluence of varices not flattened by insufflation; grade 4, grade 3 with red marks. The aim of endoscopic treatment was either to stop the bleeding or to reach variceal eradication. Endoscopic sclerotherapy was performed with flexible endoscopes and a 25-gauge disposable injection needle. Ethanolamine or 2% ethoxysclerol were used as sclerosing agents. Persistent variceal bleedings not responsive to injections of sclerosing agents were treated with additional local injections of thrombin. Injections were intentionally intravascular with a volume not exceeding 1 ml. Endoscopic ligation was performed using an endoscope with a multi-band ligator.

Variceal eradication was defined as nonvisualization of varices or grade I varices. Variceal (re)bleeding was defined according to internationally accepted criteria of the Baveno consensus meetings<sup>11-13</sup>. Variceal bleeding was defined as: active variceal bleeding seen endoscopically, signs of recent variceal bleeding, varices without other bleeding sources with a history of haematemesis and/ or melaena or blood present in the stomach. Rebleeding was defined according to Baveno consensus II as<sup>13</sup>: evidence of any bleeding after at least 48 hours.

Data on diagnosis, endoscopic procedures and outcome were collected by systematic review of the charts and endoscopy reports.

### **STATISTICS**

Statistical analysis was performed using the Kaplan Meier method for overall and re-bleeding free survival. Due to the small amount of events univariate Cox regression models, stratified for number of re-bleedings, were used to determine significant predictors of re-bleeding.

## RESULTS

Twenty-seven patients were enrolled in this study. The main baseline characteristics are presented in table 1. EPVT was initially demonstrated by means of ultrasound (n=14), computed tomography (n=7), venography (n=4), magnetic resonance imaging (n=1) and angiography (n=1). The median duration of follow up after the first bleeding episode was 8.6 years (range 0.7- 22.1 years). No patient was lost to follow up.

### Variceal bleeding

In the 27 consecutive patients a total of 241 endoscopic procedures were performed. Of these 241 endoscopic procedures 42 (17%) endoscopic procedures were performed for variceal bleeding (Figure 1). Of these 42 procedures, 27 (64%) were done for initial treatment of variceal bleeding. In 18 patients (67%) the first variceal bleeding was due to esophageal varices, in 9 (33%) patients due to gastric varices. In one patient variceal bleeding occurred due to duodenal variceal bleeding which was treated with sclerotherapy. In 2 (7%) patients with an active variceal bleeding endoscopic therapy was not successful. In these patients hemostasis was achieved by construction of a mesocaval shunt and placement of a balloon tamponade.

### Variceal eradication

Variceal band ligation (n=11) was performed in 33 sessions, sclerotherapy (n=20) was performed in 93 sessions and in one session both endoscopic modalities were performed. Overall, five patients were treated with both endoscopic modalities for achieving and maintaining variceal eradication. A mean of five endoscopic procedures (range 1-11) per patient were needed for variceal eradication. In five patient variceal eradication was not

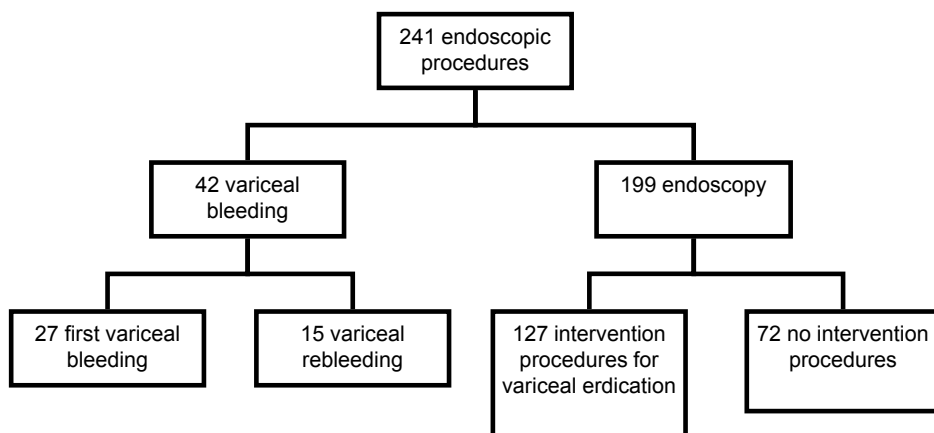


Figure 1. Study algorithm

**Table 1.** Baseline Characteristics of the Patients

Variable at baseline	N= 27	%
Sex		
Male	7	25
Female	20	75
Median age (yrs)	48	-
Extension of thrombosis		
- Portal vein	13	50
- Portal and splenic veins	3	11
- Portal and mesenteric veins	2	7
- Portal, splenic and mesenteric veins	9	32
Underlying cause		
- Myeloproliferative disease	10	36
- Polycythemia vera	2	7
- Essential thrombocytosis	3	11
- Myelofibrosis	3	11
- Unclassified	2	7
- Infection	3	11
- Surgery		
- Splenectomy	3	11
- Cholecystectomy	2	7
- Gynaecologic procedure	2	7
- Appendectomy	1	7
- Other	1	4
- Other		
- Oral contraception	7	25
- Smoking	5	18
- History of thrombosis	4	14
- Family history of thrombosis	4	14
Varices grade		
- Grade I	1	4
- Grade II	1	4
- Grade III	8	29
- Grade IV	14	50
Varices location		
- Esophagus	12	43
- Esophagus and cardia	6	21
- Esophagus and fundus	4	14
- Esophagus, fundus and corpus	1	4
- Esophagus, cardia and fundus	3	11
Previous treatment		
- Shunt placement	1	4
Signs and symptoms		
- Splenomegaly	12	43
- Ascites	6	21
- Abdominal pain	13	46



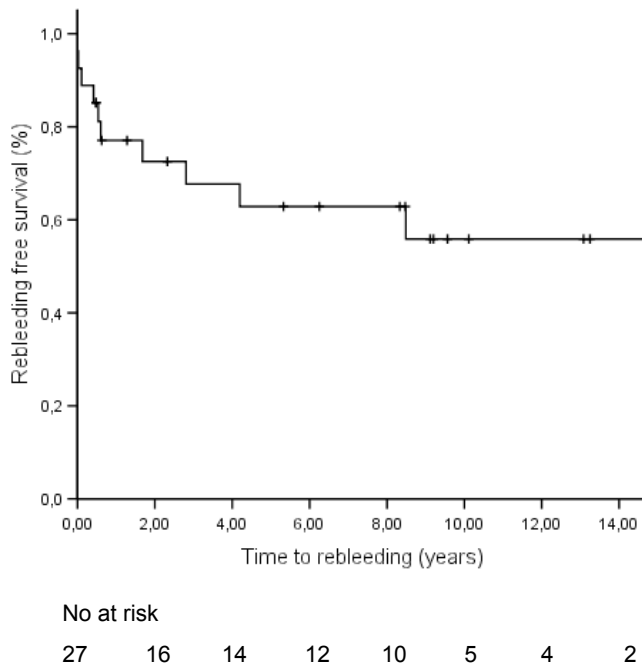
accomplished. All of these patients had grade II varices at last follow up. None of these patients developed a recurrence of variceal bleeding.

### Variceal rebleeding

Variceal rebleeding was observed in 37% (n= 10) of the patients. In seven of these ten patients, variceal rebleeding occurred due to gastric varices and in three due to esophageal varices. In six patients variceal rebleeding occurred after sclerotherapy, and in four patients after ligation. Overall re-bleeding risk was 23% (95% CI 0- 24) at 1-year, 37% (95% CI 43- 83) at 5-years and 44% (95% CI 34-78) at 10-years (Figure 2). Using univariate analysis we studied different variables to identify significant independent predictors of re-bleeding (see Table 2). Extension of thrombosis into the splenic vein and the presence of fundal varices appeared to be predictors of re-bleeding, with an approximately 5-fold risk for EPVT patients with concomitant splenic vein thrombosis and fundal varices (HR= 4.21 p=0.03 and HR= 5.07 p=0.01 respectively).

### Shunts

A porto-systemic shunt procedure was performed in five patients for the following reasons: ongoing active variceal bleeding despite endoscopic sclerotherapy (n=1), variceal



**Figure 2.** Kaplan- Meier curve showing the percentage patients free of esophagogastric variceal rebleeding

**Table 2.** Predictive values for rebleeding

Variable at baseline	N= 27	rebleeding n= 10	HR	95% CI Lower – upper	P p-value
Age	27	10	1.01	0.97 – 1.06	0.55
Male	7	3	1		
Female	20	7	0.65	0.17 – 2.52	0.53
Site of thrombosis:					
Portal vein	13	3	1		0.36
Portal and splenic veins	3	2	3.59	0.59 – 21.66	0.16
Portal and mesenterial veins	2	0			0.99
Portal, splenic and mesenterial veins	9	5	3.41	0.81 – 14.35	0.10
Splenic vein thrombosis					
Absent	15	3	1		
Present	12	7	4.21	1.08 – 16.4	0.03
Mesenterial vein thrombosis					
Absent	16	5	1		
Present	11	5	1.67	0.48 – 5.79	0.4
Ascites					
Absent	16	6	1		
Present	8	4	1.79	0.50 - 6.41	0.37
Site of varices					
- Limited to esophagus	12	4	1		
- Esophagus and stomach <sup>*)</sup>	14	6	1.25	0.35 – 4.42	0.73
Fundus	8	6	5.07	1.40 – 18.4	0.01
Cardia	6	0	0.31	0.06 – 1.50	0.11
Corpus	1	1			
Cavernoma					
Absent	14	6	1		
Present	12	4	0.95	0.27 – 3.40	0.94
Splenomegaly					
Absent <sup>**)</sup>	6	2	1		
Present	18	7	1.95	0.41 – 1.95	0.40
After initial bleeding					
ICU admission					
Absent	20	6	1		
Present	5	3	0.41	0.10 – 1.72	0.20
Packed cells given					
No	10	4	1		
Yes	15	3	1.97	0.49 – 7.98	0.33
Thrombopenia					
Absent	21	6	1		
Present	5	3	0.44	0.12 – 1.58	0.20

\*) Combined presence occurred in 4 patients

\*\*) Also includes patients who underwent splenectomy

rebleeding (n=2) and refractory ascites (n=1); in one patient the therapeutic algorithm of endoscopic therapy as preferred standard treatment was not followed for unknown reasons and a distal splenorenal shunt was constructed. Shunt occlusion was seen in three of the five patients. In two of them this resulted in variceal rebleeding.

### **Medication**

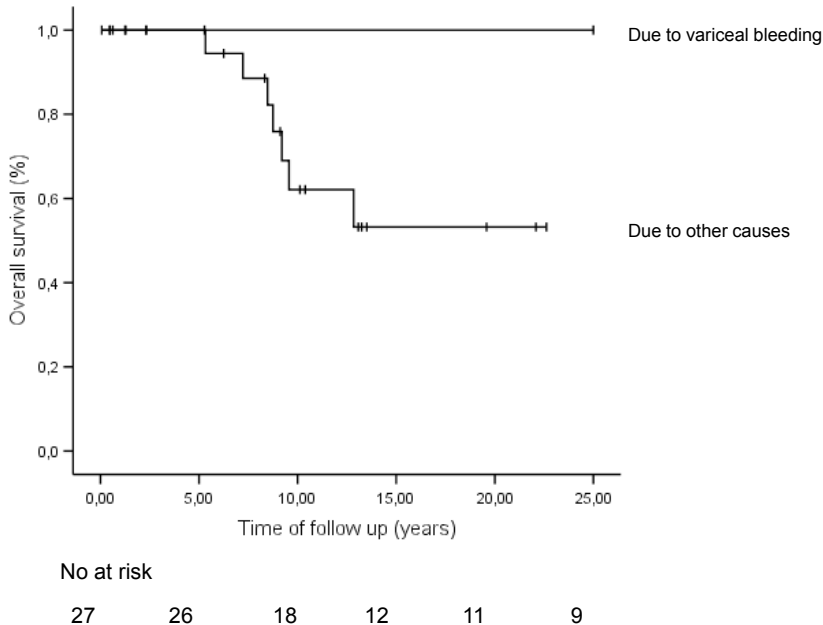
Four patients were treated with a vasoactive agent for the first variceal bleeding and one patient was treated with a vasoactive agent for rebleeding. A total of five patients were treated with oral anticoagulation therapy, three of them were already on this treatment at the time of the first variceal bleeding. In only one patient oral anticoagulation therapy was discontinued after the index variceal bleeding occurred. In none of the five patients a variceal rebleeding occurred. A total of ten patients were treated with  $\beta$ -adrenergic blocking agents. Six of them were already on treatment with  $\beta$ -adrenergic blocking agents, for prevention of variceal bleeding, at the time of baseline hemorrhage. In three of the ten patients a variceal rebleeding occurred. In all of these patients fundal varices were present and  $\beta$ -blocking therapy was started before the index bleeding. In patients started with  $\beta$ -blocking therapy after endoscopic treatment no rebleeding occurred. From the twelve patients that had developed ascites, ten patients were treated with diuretics.

### **Survival**

Seven patients died. Of these seven deaths that occurred none was caused by variceal bleeding. Causes of death were: myelofibrosis (n=2), infection (n=2), gastro-intestinal bleeding due to a pill induced esophageal ulcer (n=1), cerebellar hematoma accompanied by disseminated intravascular coagulation (n=1), and decompensated cirrhosis (n=1). The latter patient developed cirrhosis 13 years after the diagnosis EPVT was established. Early biopsies of the liver did not show any signs of cirrhosis. Overall survival was 100% at five years and 62% (95% CI 38- 96) at 10-years (Figure 3).

### **Complications**

In one patient a symptomatic esophageal stenosis occurred, after endoscopic treatment with sclerotherapy, which needed endoscopic dilatation. One patient died of a gastro-intestinal bleeding due to a pill induced esophageal ulcer eight years after endoscopic treatment with sclerotherapy.



**Figure 3.** Kaplan-Meier curve showing the percentage of patients dying from variceal bleeding an other causes

## DISCUSSION

In this study we investigated the clinical outcome and predictors of rebleeding in patients with esophagogastric variceal bleeding due to non-cirrhotic EPVT. We found that the rebleeding rate was 23% after the first year and decreased over time with maintained endoscopic follow-up. The presence of fundal varices and extension of thrombosis into the splenic vein were predictors of rebleeding. Mortality was determined by other causes than variceal (re)bleeding or endoscopic treatment complications. As of yet, studies on efficacy of endoscopic treatment of variceal bleeding and predictors of rebleeding in adult patients with non cirrhotic portal hypertension are scarce. In general, endoscopic treatment of variceal bleeding appears successful<sup>14-16</sup>. One study reported high recurrence of variceal bleeding after endoscopic treatment. However, this study started in the late fifties, was designed to investigate porto-systemic shunting rather than endoscopic therapy and details on the endoscopic interventions are lacking<sup>17</sup>. The observed rate of variceal rebleeding at 1 year was 23% in our study, which is also substantially lower than the 36-50% rebleeding risk at 1 year reported for historic controls with cirrhosis<sup>18,19</sup>. Over time, the rate of variceal rebleeding decreased, indicating that in these patients variceal eradication appears feasible and is associated with an almost complete protection against rebleeding. Previously, the size of esophageal varices and to a lesser degree, initial presentation with gastroesophageal bleeding were found to be

independent predictors for rebleeding both in patients with EPVT and cirrhosis<sup>1,20</sup>. In our study we found that the extension of thrombosis into the splenic vein as the presence of fundal varices were significant predictors of rebleeding. We also found that in 67% of our patients rebleeding was caused by gastric varices. These findings could be explained by gastric hemodynamic changes after endoscopic therapy, because prophylactic variceal eradication with EVL and EIS may increase both the incidence and the severity of fundal varices formation<sup>21</sup>. Since gastric varices are difficult to eradicate by endoscopy and thus often the source of rebleeding, theoretically one could reconsider the use of  $\beta$ -blocking agents as secondary prophylaxis, in particular for those with extensive fundal varices at the time of the index bleeding. Two studies indeed suggested that  $\beta$ -blockers may reduce the risk of rebleeding after EPVT-induced variceal hemorrhage<sup>1,22</sup>. This concurs with our findings that in patients started with  $\beta$ -blockers after endoscopic treatment no rebleeding occurred. However, there is as yet limited evidence to recommend wide spread use of  $\beta$ -blockers for secondary prophylaxis<sup>13</sup>. The absence of variceal (re)bleeding related mortality in our patients with EPVT contrasts the hospital related mortality of 20% in cirrhotic patients with variceal bleeding<sup>23</sup>. This difference is largely caused by the fact that variceal bleeding in cirrhotic patients may be difficult to control due to an impaired coagulation and that these patients are at increased risk of life-threatening infections<sup>24</sup>. Regarding the causes of death our study confirms earlier findings that survival in patients with EPVT is primarily determined by other - sometimes underlying - diseases of thrombosis rather than variceal (re)bleeding itself<sup>25</sup>.

Several biases might have been introduced in the current retrospective study. Firstly, our hospital is a tertiary referral center and selection bias may have led to under- or over-representation of certain patient categories. Secondly, during the long study period (23 years) a shift in the treatment modalities, in particular the transition from sclerotherapy to band ligation, may have influenced our results. Due to the design of this study, the limited number of patients treated with band ligation and the fact that some patients were treated with both endoscopic procedures over time, comparison between the two modalities and differences in outcomes such as rebleeding rates was not possible. In children and adolescents with EPVT, endoscopic variceal ligation was superior to sclerotherapy, particularly in lowering the complication rate, rebleeding and mortality<sup>26</sup>. The limited number of patients treated with band ligation in our study could therefore have led to overestimation of rebleeding. In current practice almost exclusively band ligation is used. In summary, our data indicate that endoscopic treatment, is a safe and effective primary treatment modality for variceal bleeding in patients with EPVT. Rebleeding rate was low and mainly caused by gastric varices. Most important risk factors for rebleeding were the extension of thrombosis into the splenic vein and the presence of fundal varices. In contrast to patients with cirrhosis, EPVT-related mortality appears primarily determined by other causes than variceal bleeding.

**REFERENCES**

1. Condat B, Pessione F, Hillaire S, et al. Current outcome of portal vein thrombosis in adults: risk and benefit of anticoagulant therapy. *Gastroenterology* 2001;120(2):490-7.
2. Cohen J, Edelman RR, Chopra S. Portal vein thrombosis: a review. *Am J Med* 1992;92(2):173-82.
3. Webb LJ, Sherlock S. The aetiology, presentation and natural history of extra-hepatic portal venous obstruction. *Q J Med* 1979;48(192):627-39.
4. Grauer SE, Schwartz SI. Extrahepatic portal hypertension: a retrospective analysis. *Ann Surg* 1979;189(5):566-74.
5. Voorhees AB, Jr., Price JB, Jr. Extrahepatic portal hypertension. A retrospective analysis of 127 cases and associated clinical implications. *Arch Surg* 1974;108(3):338-41.
6. Van Stiegmann G, Cambre T, Sun JH. A new endoscopic elastic band ligating device. *Gastrointest Endosc* 1986;32(3):230-3.
7. Laine L, Cook D. Endoscopic ligation compared with sclerotherapy for treatment of esophageal variceal bleeding. A meta-analysis. *Ann Intern Med* 1995;123(4):280-7.
8. Lo GH, Lai KH, Cheng JS, et al. Emergency banding ligation versus sclerotherapy for the control of active bleeding from esophageal varices. *Hepatology* 1997;25(5):1101-4.
9. Stiegmann GV, Goff JS, Sun JH, Davis D, Bozdech J. Endoscopic variceal ligation: an alternative to sclerotherapy. *Gastrointest Endosc* 1989;35(5):431-4.
10. Paquet KJ, Oberhammer E. Sclerotherapy of bleeding oesophageal varices by means of endoscopy. *Endoscopy* 1978;10(1):7-12.
11. de Franchis R. Developing consensus in portal hypertension. *J Hepatol* 1996;25(3):390-4.
12. de Franchis R, Pascal JP, Ancona E, et al. Definitions, methodology and therapeutic strategies in portal hypertension. A Consensus Development Workshop, Baveno, Lake Maggiore, Italy, April 5 and 6, 1990. *J Hepatol* 1992;15(1-2):256-61.
13. de Franchis R. Evolving consensus in portal hypertension. Report of the Baveno IV consensus workshop on methodology of diagnosis and therapy in portal hypertension. *J Hepatol* 2005;43(1):167-76.
14. Vleggaar FP, van Buuren HR, Schalm SW. Endoscopic sclerotherapy for bleeding oesophagogastric varices secondary to extrahepatic portal vein obstruction in an adult Caucasian population. *Eur J Gastroenterol Hepatol* 1998;10(1):81-5.
15. Valla DC, Condat B. Portal vein thrombosis in adults: pathophysiology, pathogenesis and management. *J Hepatol* 2000;32(5):865-71.
16. Wang JT, Zhao HY, Liu YL. Portal vein thrombosis. *Hepatobiliary Pancreat Dis Int* 2005;4(4):515-8.
17. Orloff MJ, Orloff MS, Girard B, Orloff SL. Bleeding esophagogastric varices from extrahepatic portal hypertension: 40 years' experience with portal-systemic shunt. *J Am Coll Surg* 2002;194(6):717-28; discussion 728-30.
18. Terblanche J, Burroughs AK, Hobbs KE. Controversies in the management of bleeding esophageal varices (2). *N Engl J Med* 1989;320(22):1469-75.
19. Stiegmann GV, Goff JS, Michaletz-Onody PA, et al. Endoscopic sclerotherapy as compared with endoscopic ligation for bleeding esophageal varices. *N Engl J Med* 1992;326(23):1527-32.
20. Pagliaro L, D'Amico G, Luca A, et al. Portal hypertension: diagnosis and treatment. *J Hepatol* 1995;23 Suppl 1:36-44.
21. Yuksel O, Koklu S, Arhan M, et al. Effects of esophageal varice eradication on portal hypertensive gastropathy and fundal varices: a retrospective and comparative study. *Dig Dis Sci* 2006;51(1):27-30.

22. Orr D. Chronic portomesenteric and portosplenomesenteric venous thrombosis: evaluation of long term follow up and determinants of survival. *Hepatology* 2005;42 Suppl 1:212A.
23. El-Serag HB, Everhart JE. Improved survival after variceal hemorrhage over an 11-year period in the Department of Veterans Affairs. *Am J Gastroenterol* 2000;95(12):3566-73.
24. Merkel C, Bolognesi M, Bellon S, et al. Long-term follow-up study of adult patients with non-cirrhotic obstruction of the portal system: comparison with cirrhotic patients. *J Hepatol* 1992; 15(3):299-303.
25. Janssen HL, Wijnhoud A, Haagsma EB, et al. Extrahepatic portal vein thrombosis: aetiology and determinants of survival. *Gut* 2001;49(5):720-4.
26. Celinska-Cedro D, Teisseyre M, Woynarowski M, Socha P, Socha J, Ryzko J. Endoscopic ligation of esophageal varices for prophylaxis of first bleeding in children and adolescents with portal hypertension: preliminary results of a prospective study. *J Pediatr Surg* 2003;38(7):1008-11.





# Chapter 4


---

## **Ascites in patients with non-cirrhotic non-malignant extrahepatic portal vein thrombosis**

MCW Spaander<sup>1</sup>, HR van Buuren<sup>1</sup>, BE Hansen<sup>1,2</sup>, HLA Janssen<sup>1</sup>

*1. Department of Gastroenterology and Hepatology, 2. Department of Biostatistics, Erasmus MC  
University Medical Center Rotterdam, Rotterdam, The Netherlands*

*Aliment Pharmacol Ther. 2010 Aug 32(4):529- 534*



## ABSTRACT

**Background and Aims:** The clinical significance of ascites in patients with extrahepatic portal vein thrombosis (EPVT) has been poorly defined. The aim of this study was to assess the frequency, natural history and prognostic implication of ascites in patients with EPVT, and to identify risk factors for this complication.

**Methods:** Single-center retrospective study of all consecutive patients diagnosed with non-cirrhotic non-malignant EPVT between 1985 and 2005. The main outcome was survival for patients with and without ascites at presentation.

**Results:** One hundred and three patients (35% males; median age 43 (range 16–83) years) were included and followed for a median time of 5.2 (range 0.9 – 32.5) years. Twenty-nine (28%) had ascites at the time of diagnosis. Ascites was associated with increased mortality ( $p = < 0.01$ ). There was no correlation between the presence of ascites and the extension of the thrombus into the large splanchnic veins, the duration of thrombosis or the presence of gastrointestinal bleeding.

**Conclusion:** Ascites is present in a substantial proportion of adults presenting with non-cirrhotic non-malignant EPVT. Ascites is a significant and independent prognostic factor and associated with a decreased long-term survival.

## INTRODUCTION

Extrahepatic portal vein thrombosis (EPVT) is the second cause of portal hypertension worldwide. Main causes of non- cirrhotic non- malignant portal vein thrombosis are myeloproliferative diseases and inherited or acquired thrombophilic disorders [1-4]. Portal hypertension often develops as a result of EPVT. Ascites is a common complication of portal hypertension in cirrhotic patients [5-7]. Twenty percent of the cirrhotic patients have ascites at the time of diagnosis, while 30% and 50% will develop ascites by 5 and 10 years, respectively [5, 8]. In children with EPVT ascites has been described in association with gastrointestinal hemorrhage and / or surgery and appeared to be transient [9]. In young adult patients with EPVT and a history of gastrointestinal hemorrhage ascites can also develop spontaneously with an annual incidence rate of 20% [10]. In contrast to ascites in cirrhotic patients which is associated with an increased risk for mortality and associated with an expected survival below 50% after 5 years, little is known about the morbidity and mortality of adult patients with non- cirrhotic non- malignant EPVT and ascites [11, 12]. In the current cohort study we investigated the incidence and clinical outcome of ascites in adult patients with non- cirrhotic non- malignant EPVT.

## PATIENTS AND METHODS

### Design of the study

From 1985 until 2009 all consecutive patients from our hospital with a non- cirrhotic non- malignant EPVT were enrolled in this study. Date of diagnosis was defined as the first date EPVT was found on radiological imaging either elsewhere or in our tertiary referral center. Patients who were referred to our clinic underwent radiological imaging in our hospital to confirm the diagnosis. In these cases data with regard to the presence of ascites at diagnosis were retrieved from the referring hospital. Follow up started after the diagnosis EPVT was established and lasted until either December 2009 or death, whichever came first. For all patients a standardized clinical record form with data on diagnosis, ascites, treatment and outcome was collected by a systematic review of the medical charts.

### Diagnostic assessment

Patients with EPVT and previous or concurrent malignant disease, Budd-Chiari syndrome, veno-occlusive disease, liver transplantation or with concurrent heart failure at the time of diagnosis were excluded. Cirrhosis was excluded by liver biopsy and/or a combination of radiological imaging and biochemical tests. EPVT was classified according to international consensus guidelines, namely obstruction of the extra-hepatic portal vein, with or without involvement of the intrahepatic portal veins [9]. The diagnosis

of EPVT was based on radiological imaging using Doppler ultrasonography, computed tomography, magnetic resonance imaging or venography. EPVT was defined as chronic, when multiple hepatopetal collaterals, so called portal cavernoma or gastrointestinal varices were present. When these features were absent the presentation of EPVT was considered acute. Ascites was diagnosed by radiological imaging. Examination of the ascitic fluid was performed in case of clinical suspicion of bacterial peritonitis or if other causes of ascites than EPVT were suspected.

## STATISTICS

Kaplan Meier method was used to calculate overall survival and the log-rank test was used for comparing groups. Determinants of survival and the effect of ascites were estimated as a hazard ration (HR) and corresponding 95% confidence interval (CI) using Cox regression analysis adjusted for sex and age. Occurrence of ascites during follow-up was analysed as a time-dependent factor. Proportionality assumption was checked for each determinant and no significant division from proportionality was found. A p-value of < 0.05 was considered statistically significant. All statistical analysis were performed with the Statistical Package for Social Sciences for Windows, version 16.0 (SPSS, Chicago, IL).

## RESULTS

From a total of 113 patients presenting with non- cirrhotic non- malignant EPVT 103 patients were included in this study. Ten patients were excluded due to lack of reliable data with regard to ascites at the time of diagnosis. The median age of those enrolled in the study was 43 years (range 16 – 83 years). The median duration of follow up was 5.2 years (range 0.9 – 32.5 years). Baseline patient characteristics according to the presence of ascites at baseline are summarized in table I. Cirrhosis was excluded by liver biopsy in 39 patients.

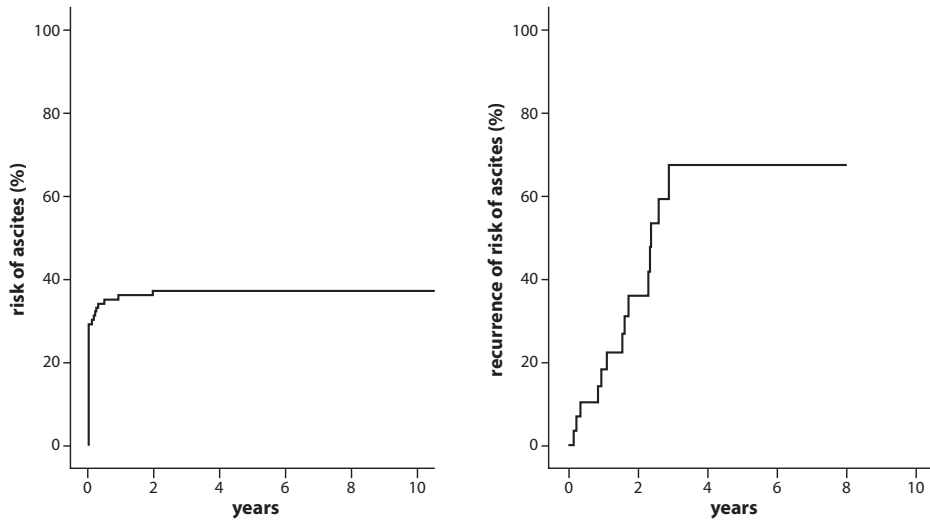
At baseline and during follow up ascites was diagnosed in a total of 39 patients. Twenty-nine patients had ascites at the time of diagnosis and ten patients developed de novo ascites during follow up. The overall risk of developing ascites was 36% (95% CI 27-45) at 1-year and 37% (95% CI 28-46) at 10- years (figure 1A). Diagnostic paracentesis was performed in fourteen patients. Examination of the ascitic fluid showed a serum-ascites albumin gradient  $\geq 11$  gr/l in all cases. Bacterial peritonitis was diagnosed in three cases during follow up. In all the other patients the ascitic fluid showed no elevated absolute polymorphonuclear leukocyte count (< 250 cells/mm<sup>3</sup>) and bacterial cultures were negative.

**Table 1.** Baseline Characteristics of the 103 Patients

Variable at baseline	Patients with ascites n=29 (%)	Patients without ascites n = 74 (%)
Sex (m/f)	16/ 13	23 / 51
Age (yrs) <sup>1*</sup>	41 ± 16 (27 - 77)	43 ± 17 (16 - 83)
Duration of thrombosis		
- Acute	6 /28(21%)	28/68 (41%)
- Chronic	22/28(79%)	40/68 (59%)
Site of thrombosis		
- Portal vein	15/29 (52%)	43/74 (58%)
- Portal and splenic veins	1/29 (3%)	7/74 (9%)
- Portal and mesenterial veins	3/29 (10%)	10/74 (14%)
- Portal, splenic and mesenterial veins	10/29 (34%)	14/74 (19%)
Underlying causes		
- Inherited thrombophilia	5/23 (22%)	18/61 (30%)
- Acquired disorders	22/29 (76%)	55/74 (74%)
Acquired disorders		
- Myeloproliferative disease	13/29 (45%)	20/73 (27%)
- Infection	5/29 (17%)	16/74 (22%)
- Surgery	3/29 (10%)	24/74 (32%)
Signs and symptoms		
- Abdominal pain	19/29 (66%)	50/72 (69%)
- Splenomegaly	19/25 (76%)	36/67 (54%)
- Ascites	28/28 (100%)	0/74 (0%)
- Hepatomegaly	2/27 (7%)	9/74 (12%)
Varices	17/27 (63%)	33/53 (62%)
- Variceal bleeding (yes / no)	9/27 (33%)	14/59 (22%)
Blood hemoglobin (mmol/ L) <sup>2*</sup>	6.7 ± 1.5 (4.9 – 10.0)	7.7 ± 1.7 (4.3 – 13.8)
Platelet count (x 10E9/ L) <sup>3*</sup>	247 ± 239 (49 – 1083)	267 ± 175 (31 – 888)
Bilirubin (µmol/L) <sup>4*</sup>	15 ± 19 (3 – 100)	13 ± 35 (4 – 242)
Aspartate transaminase (U/ L) <sup>5*</sup>	33 ± 15 (7 – 57)	27 ± 41 (3 – 284)
Alanine transaminase (U/ L) <sup>6*</sup>	28 ± 22 (9 – 111)	29 ± 43 (9 – 198)
Serum albumin (g/ L) <sup>7*</sup>	37 ± 8.0 (22- 48)	38 ± 7 (24 – 51)
Serum creatinin (µmol/ L) <sup>8*</sup>	69 ± 26 (44 – 170)	67 ± 56 (35 – 385)
APTT (sec)*	36 ± 17 (25 – 83)	32 ± 13 (3 – 88)
PT (sec)*	15 ± 2.2 (11 – 20)	16 ± 8.8 (10 – 57)
PTINR *	1.3 ± 0.5 (1.0 – 2.8)	1.3 ± 0.9 (1.0 – 4.3)

In the twenty-nine patients who had ascites at the time EPVT was diagnosed, thrombosis was seen in the portal vein only (n= 15), in the portal and splenic vein (n= 1), in the portal and superior mesenteric vein (n= 3) and in the portal, splenic and superior mesenteric vein(n= 10). EPVT was acute in six of 28 patients and chronic in 22 of 28 patients. In one patient no description of acute or chronic EPVT was given.

Among the total group of 103 EPVT patients 33 (32%) had a myeloproliferative disorder (MPD). There was no significant correlation between the presence of ascites and other important baseline variables such as MPD, duration of thrombosis (acute versus



**Figure 1.** A. Occurrence of ascites in patients with EPVT. B. Recurrence of ascites in patients with EPVT

chronic), the extension of thrombosis into any of the splanchnic veins or with concomitant variceal bleeding.

The presence of ascites during follow up was diagnosed by radiological imaging in 95 patients and by a laparoscopic procedure in one patient. In the patients a median of three (range 1-11) radiological imaging procedures were performed during follow-up. In 23 patients ascites (re)occurred during follow up. Refractory ascites was seen in six patients. The risk of recurrence of ascites was at the first year 18% (95% CI 4-33) and at five years 77% (95% CI 54-100) (figure1B). Ascites which developed during follow up could be related to various causes in thirteen patients, namely (gastrointestinal) blood loss (n=6) surgical intervention (n=1), septic shock with diverticulitis and liver abscesses (n=1) extramedullary haematopoiesis (n=1), protein losing enteropathy (n=1), peripheral stem cell transplantation (n=1), kidney failure (n=1) and shunt occlusion (n=1). In ten patients there was no identifiable cause.

### Treatment

Twenty-five patients were on diuretic treatment. Reasons to start diuretics were presence of ascites (n=20), developing heart failure (n=4) and hypertension (n=1). Only the last patients was already on diuretic treatment before the diagnose EPVT was established. Two patients underwent porto-systemic shunt surgery for variceal bleeding refractory to endoscopic treatment. Three patients received a trans-jugular intra-hepatic porto-systemic shunt (TIPS) to enable local thrombolysis in the portal vein. Oral anticoagulation was used in 14 (50%) patients with ascites. We found that patients with ascites, who were not on anticoagulation therapy, had a higher mortality rate (p= 0.07).

## Survival

Among the total group of 103 patients 20 patients died during follow-up. Causes of death were: MPD (n= 5), variceal bleeding (n= 2), infectious diseases (n= 3), cardiovascular diseases (n= 2) and various other causes (n= 5). In three patients the cause of death was unknown.

Survival in the total group of 103 patients was 91% (95% CI 85-97) at five years and 80% (95% CI 69-91) at ten years (Figure 2). When we compared patients without ascites at diagnosis and with ascites, we found a five years survival of 95% (95% CI 89-100) versus 83% (95% CI 68-99) and a ten years survival of 87% (95% CI 76-97) versus 42% (95% CI 0-83) (Figure 3). In the univariate analysis we found that age (HR = 1.1 p = <0.001), MPD (HR = 3.7 p = 0.004), chronic portal vein thrombosis (HR 2.89 p = 0.03), variceal bleeding (HR 3.64 p 0.01) and ascites at time of diagnosis (HR = 6.6 p = 0.001) were significant predictors of survival (table 2). In the multivariate analysis, after adjustment for age (p<0.01) and sex (p= 0.06), we found that the presence of ascites at diagnosis (HR 5.1 p=0.03) was the only independent significant factor which predicted survival.

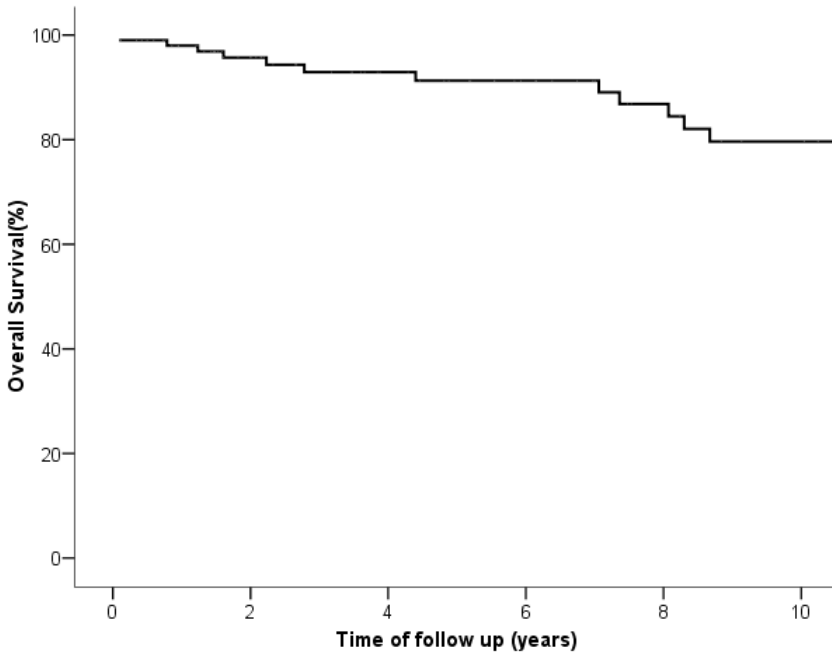
**Table 2.** Univariate analysis of variables associated with a poor survival

Variable	HR (CI 95%)	P value
Age (years)	1.08 (1.04- 1.11)	<0.001**
Male gender	1.38 (0.53- 3.59)	0.52
Chronic portal vein thrombosis	3.14 (0.91-10.77)	0.04**
Site of thrombosis		
- Portal vein	1	0.60
- Portal and splenic veins	1.53 (0.33- 7.09)	0.59
- Portal and mesenterial veins	0.34 (0.04- 2.61)	0.30
- Portal, splenic and mesenterial veins	0.94 (0.30- 2.93)	0.92
Ascites at baseline	6.61 (2.21- 19.73)	0.001**
Ascites at baseline and during follow-up*	4.94 (1.73- 14.14)	0.004**
Ascites during follow-up*	1.78 (0.22- 4.66)	0.59
Presence of MPD	3.68 (1.51- 9.00)	0.005**
Presence of varices <sup>1)</sup>	1.28 (0.40- 4.11)	0.68
Presence of variceal bleeding <sup>1)</sup>	3.54 (1.31- 9.56)	0.02**
Splenomegaly <sup>1)</sup>	1.33 (0.46- 3.83)	0.59
Bilirubin <sup>1)</sup>	0.03 (1.00- 1.02)	0.03**
Asat <sup>1)</sup>	0.03 (1.00-1.02)	0.02**

<sup>1)</sup> variable at baseline

\* analysed as a time-dependent factor

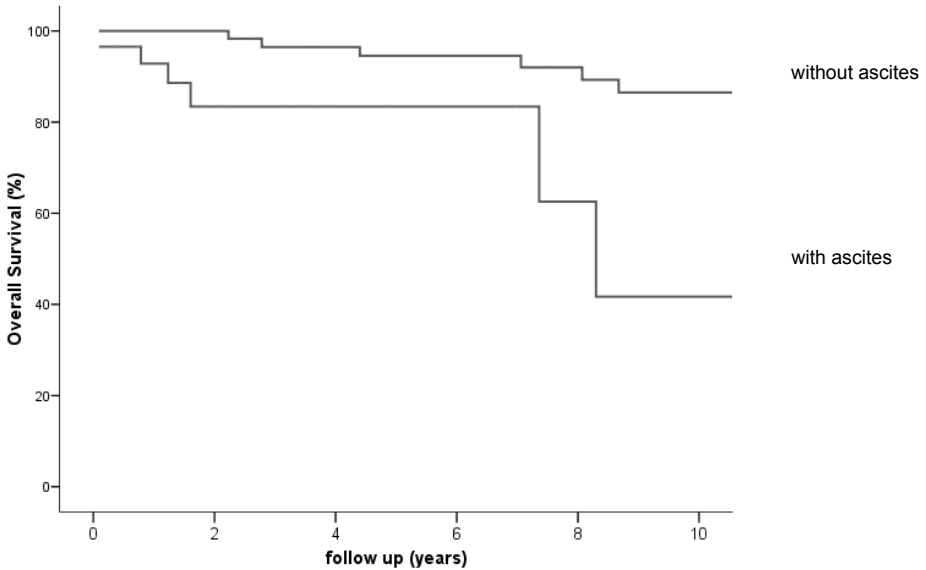
\*\* statistical significant



Number of patients

103      77      58      47      37      31

**Figure 2.** Kaplan- Meier curve showing the overall survival of patients with EPVT



**Figure 3.** Kaplan- Meier curve showing the survival of patients with and without ascites and EPVT



## DISCUSSION

In this study we investigated the morbidity and mortality in adult patients with a non-cirrhotic non-malignant EPVT and ascites. We found that in approximately a quarter of the patients ascites was present at the time of diagnosis and that 75% of these patients were at risk for a second episode of ascites. This group of patients had a significant reduced survival compared to patients without ascites.

According to the literature, ascites in patients with an acute EPVT is correlated with mesenterial thrombosis, intestinal ischemia or intestinal infarction [13, 14]. In patients with a chronic EPVT ascites is correlated with gastrointestinal hemorrhage, renal insufficiency, sepsis and/or surgery [9]. Most of the patients with ascites in our study were patients with a chronic EPVT. However in our patients renal function was normal, there was no significant relation between age, gastrointestinal hemorrhage, surgery or infection and the presence of ascites. Other causes that could clarify the presence of ascites, such as liver failure or low osmotic pressure, appeared also unlikely, because all patients lacked histological, biochemical and radiologic evidence of cirrhosis. It is known that the onset of ascites in patients with a history of thrombotic disease should heighten the clinical suspicion of mesenterial venous thrombosis [13]. However, we found no correlation between the extension of the thrombus towards the superior mesenteric vein and the presence of ascites.

Mortality in patients with EPVT is often determined by underlying causes [15]. We found however a remarkably high mortality rate in the group of patients with ascites at the time of diagnosis, which was not correlated with the underlying MPD or other etiological factors. Patients with EPVT and an underlying prothrombotic state, who did not use oral anticoagulation, had a significantly higher incidence rate of splanchnic venous obstruction compared to patients who did use oral anticoagulation [16]. We found that in patients with ascites, who were not using oral anticoagulation survival was decreased compared to those who did use oral anticoagulation. This underlines the need of anticoagulation in EPVT even if esophageal varices are present [16-19].

Our study suffers from the following limitations. Firstly, not all the patients did have a liver biopsy, therefore we looked in all other possible ways to exclude cirrhosis. Secondly, decisions about performing a radiological imaging and starting a specific treatment were made by the treating physician. This led to the fact that not all patients did have a systemic radiological imaging during follow up and that the time between the radiological imaging differed among the patients. Ascites could have occurred in some patients and remained unidentified. There were however clearly no significant signs or symptoms suggesting the presence of ascites, according to the medical charts.

In conclusion, in our series of patients with non-cirrhotic non-malignant EPVT, ascites is present in about one quarter of the patients. Ascites at the time of EPVT diagnosis is independently related to a high mortality rate.

**REFERENCES**

- [1] Janssen HL, Meinardi JR, Vleggaar FP, van Uum SH, Haagsma EB, van Der Meer FJ, et al. Factor V Leiden mutation, prothrombin gene mutation, and deficiencies in coagulation inhibitors associated with Budd-Chiari syndrome and portal vein thrombosis: results of a case-control study. *Blood*. 2000 Oct 1;96(7):2364-8.
- [2] Denninger MH, Chait Y, Casadevall N, Hillaire S, Guillin MC, Bezeaud A, et al. Cause of portal or hepatic venous thrombosis in adults: the role of multiple concurrent factors. *Hepatology*. 2000 Mar;31(3):587-91.
- [3] Primignani M, Martinelli I, Bucciarelli P, Battaglioli T, Reati R, Fabris F, et al. Risk factors for thrombophilia in extrahepatic portal vein obstruction. *Hepatology*. 2005 Mar;41(3):603-8.
- [4] Rosendaal FR. Venous thrombosis: a multicausal disease. *Lancet*. 1999 Apr 3;353(9159):1167-73.
- [5] Gines P, Quintero E, Arroyo V, Teres J, Bruguera M, Rimola A, et al. Compensated cirrhosis: natural history and prognostic factors. *Hepatology*. 1987 Jan-Feb;7(1):122-8.
- [6] Runyon BA. Management of adult patients with ascites due to cirrhosis. *Hepatology*. 2004 Mar;39(3):841-56.
- [7] Garcia-Tsao G. Current management of the complications of cirrhosis and portal hypertension: variceal hemorrhage, ascites, and spontaneous bacterial peritonitis. *Gastroenterology*. 2001 Feb;120(3):726-48.
- [8] Leiva JG, Salgado JM, Estradas J, Torre A, Uribe M. Pathophysiology of ascites and dilutional hyponatremia: contemporary use of aquaretic agents. *Ann Hepatol*. 2007 Oct-Dec;6(4):214-21.
- [9] de Franchis R. Evolving consensus in portal hypertension. Report of the Baveno IV consensus workshop on methodology of diagnosis and therapy in portal hypertension. *J Hepatol*. 2005 Jul;43(1):167-76.
- [10] Rangari M, Gupta R, Jain M, Malhotra V, Sarin SK. Hepatic dysfunction in patients with extrahepatic portal venous obstruction. *Liver Int*. 2003 Dec;23(6):434-9.
- [11] Kuiper JJ, de Man RA, van Buuren HR. Review article: Management of ascites and associated complications in patients with cirrhosis. *Aliment Pharmacol Ther*. 2007 Dec;26 Suppl 2:183-93.
- [12] Salerno F, Borroni G, Moser P, Badalamenti S, Cassara L, Maggi A, et al. Survival and prognostic factors of cirrhotic patients with ascites: a study of 134 outpatients. *Am J Gastroenterol*. 1993 Apr;88(4):514-9.
- [13] Kumar S, Sarr MG, Kamath PS. Mesenteric venous thrombosis. *N Engl J Med*. 2001 Dec 6;345(23):1683-8.
- [14] DeLeve LD, Valla DC, Garcia-Tsao G. Vascular disorders of the liver. *Hepatology*. 2009 May;49(5):1729-64.
- [15] Janssen HL, Wijnhoud A, Haagsma EB, van Uum SH, van Nieuwkerk CM, Adang RP, et al. Extrahepatic portal vein thrombosis: aetiology and determinants of survival. *Gut*. 2001 Nov;49(5):720-4.
- [16] Condat B, Pessione F, Hillaire S, Denninger MH, Guillin MC, Poliquin M, et al. Current outcome of portal vein thrombosis in adults: risk and benefit of anticoagulant therapy. *Gastroenterology*. 2001 Feb;120(2):490-7.
- [17] Spaander MC, Murad SD, van Buuren HR, Hansen BE, Kuipers EJ, Janssen HL. Endoscopic treatment of esophagogastric variceal bleeding in patients with noncirrhotic extrahepatic portal vein thrombosis: a long-term follow-up study. *Gastrointest Endosc*. 2008 May;67(6):821-7.
- [18] Vleggaar FP, van Buuren HR, Schalm SW. Endoscopic sclerotherapy for bleeding oesophagogastric varices secondary to extrahepatic portal vein obstruction in an adult Caucasian population. *Eur J Gastroenterol Hepatol*. 1998 Jan;10(1):81-5.

- [19] Spaander VM, van Buuren HR, Janssen HL. Review article: The management of non-cirrhotic non-malignant portal vein thrombosis and concurrent portal hypertension in adults. *Aliment Pharmacol Ther.* 2007 Dec;26 Suppl 2:203-9



# Chapter 5


---

## **Anticoagulation in patients with non cirrhotic extrahepatic portal vein thrombosis**

MCW Spaander<sup>1</sup>, J.Hoekstra<sup>1</sup>, BE Hansen<sup>1,2</sup>, HR van Buuren<sup>1</sup>, HLA Janssen<sup>1</sup>

*1. Department of Gastroenterology and Hepatology, 2. Department of Biostatistics, Erasmus MC  
University Medical Center Rotterdam, Rotterdam, The Netherlands*

*Submitted*



## ABSTRACT

**Background:** In patients with non-cirrhotic extrahepatic portal vein thrombosis (EPVT) anticoagulation therapy should be considered when thrombosis is of recent onset or when a prothrombotic state is present. However, data on this topic are scarce. The aim of this study was to assess the effect of anticoagulation therapy on gastrointestinal bleeding and recurrent thrombotic events in patient with non-cirrhotic EPVT.

**Methods:** All consecutive patients with non-cirrhotic EPVT, seen at our hospital from 1985 to 2009 were enrolled in this study. Data were collected by systemic chart review.

**Results:** Hundred-twenty patients (36% male; median age 44 years (range 16-87)) were followed after the diagnosis EPVT was made (median follow up 5.5 years, range 0.1-32.5). Forty patients had recent EPVT, 71 patients had chronic EPVT and in nine cases the onset was unknown. Sixty-six patients were treated with anticoagulation therapy. In thirty-seven patients 83 bleeding events occurred (variceal bleeding  $n=52$  and gastrointestinal non variceal bleeding  $n=31$ ). Re-bleeding risk was 19% at one year, 46% at five years and 49% at ten years. Gastrointestinal bleeding at presentation (HR 2.1  $p<0.01$ ), ascites (HR 2.0  $p=0.01$ ) and use of anticoagulation therapy (HR 2.0  $p<0.01$ ) were significant predictors of (re)bleeding. Anticoagulation therapy had no effect on the severity of gastro-intestinal bleeding. Two out of four patients with fatal gastrointestinal bleeding were using anticoagulants.

Twenty-two new thrombotic events occurred in nineteen patients (venous  $n=15$  arterial  $n=7$ ). Overall thrombotic risk was 4% at one year, 8% at five year and 27% at ten years. Seventy-four percent of all new thrombotic events occurred in patients with a prothrombotic disorder. Anticoagulation therapy tended to lower the risk of a new thrombosis (HR 0.2  $p=0.1$ ), yet the only significant predictor of a new thrombotic event was presence of a prothrombotic disorder (HR 3.1  $p=0.03$ ). New thrombotic events were significantly associated with poor survival (HR 3.1  $p=0.02$ ). Bleeding (HR 1.6  $p=0.2$ ) and anticoagulant treatment (HR 0.5  $p=0.2$ ) had no significant effect on survival.

**Conclusion:** In EPVT patients new thrombotic events were mainly observed in patients with prothrombotic disorders. Anticoagulation therapy tended to prevent new thrombosis but also significantly increased the risk of gastrointestinal (re)bleeding. This finding suggest that anticoagulation therapy should be used selectively and with caution in EPVT patients.

## INTRODUCTION

Extrahepatic portal vein thrombosis (EPVT) is an important cause of non-cirrhotic portal hypertension. Variceal bleeding is one of the major complications of EPVT. [1-5]. Several local risk factors for developing EPVT, including cirrhosis, hepatobiliary malignancies and pancreatitis, and systemic risk factors, including myeloproliferative neoplasm and prothrombotic genetic defects, have been identified. [6-15] In patients with recent thrombosis or with an underlying prothrombotic disorder, anticoagulation therapy is usually considered. [15-21] However, data on the risk and benefit of anticoagulation therapy are limited. Benefit of treatment was reported by two cohort studies. One of these studies addressed anticoagulation therapy in patients with recent EPVT only. [16, 22].

The aim of this retrospective study was to assess the effect of anticoagulation therapy on gastro-intestinal (re-) bleeding and thrombotic events during a long-term follow up in patients with EPVT.

## PATIENTS AND METHODS

### Design of the study

Patients were identified by means of a search in the computerized patient registration system of our clinic. All adult patients identified between January 1985 and November 2008 were enrolled if EPVT was documented and cancer, cirrhosis, liver transplantation or combined Budd-Chiari syndrome were absent. For all patients a standardized clinical record form for detailed clinical data was completed with data obtained from the medical charts.

From a total of 241 patients with EPVT 120 patients were included in this study. Patients were excluded for the following reasons: 63 patients had cirrhosis, 49 had malignancies, seven had developed EPVT after liver transplantation and two had Budd-Chiari syndrome.

Follow-up started at the time of diagnosis, defined as the date of the first radiological imaging documenting EPVT, and was continued to either December 2009 or death, whichever came first. Patients lost to follow-up were censored at the last visit.

### Diagnostic assessment

Diagnostic criteria for EPVT were partial or complete obstruction of the extrahepatic portal vein, as documented by radiological imaging, such as Doppler ultrasonography, computed tomography, magnetic resonance imaging, and venography. Risk factors for the development of EPVT were divided in inherited and acquired risk factors. Inherited risk factors were: factor V Leiden mutation, prothrombin gene mutation, protein C defi-

ciency, protein S deficiency, and antithrombin deficiency. Inherited deficiencies of the latter three proteins were diagnosed if patients were known with this deficiency prior to EPVT or low concentration of these proteins was confirmed at least six weeks after the onset of EPVT or in case anticoagulation therapy was given at least six weeks after discontinuation, all in the absence of hepatic dysfunction. Acquired risk factors were: myeloproliferative neoplasm (MPN), paroxysmal nocturnal hemoglobinuria, antiphospholipid antibody syndrome, abdominal surgery, infection, inflammatory bowel disease (IBD), use of oral contraceptives or trauma. Abdominal surgery, trauma or abdominal infections were regarded as underlying cause if these events had occurred within three months prior to the development of EPVT. EPVT was defined recent in the absence of a portal cavernoma and gastrointestinal varices. All other cases were classified as chronic EPVT. Gastroesophageal varices were graded as [23]: grade I, varices flattened by insufflation; grade 2, varices not flattened by insufflation; grade 3, confluence of varices not flattened by insufflation; grade 4, grade 3 with red marks. Anticoagulation therapy included treatment with vitamin K antagonists, therapeutic use of low molecule weight heparin or heparin. To compare the severity of bleeding between patients with and without anticoagulation therapy, we assessed the number of bleeding events per patient, the amount of units transfused red blood cells, the number of Intensive Care Unit admissions and hemoglobin level at admission for each bleeding episode in both groups.

## STATISTICS

Kaplan Meier method was used to calculate (re-) bleeding free, thrombotic free and overall survival and the log-rank test was used for comparing groups. Predictors of (re-) bleeding and new thrombosis were estimated as a hazard ratio (HR) and corresponding 95% confidence interval (CI) using Cox regression analysis adjusted for sex and age. The effect of bleeding, thrombotic events and anticoagulants use on survival were estimated as time dependent covariates using Cox regression analysis. Due to the small amount of thrombotic events univariate Cox regression models, stratified for number of thrombosis, were used to determine significant predictors of thrombosis. Since patients could stop and restart anticoagulation therapy during the course, we correlated new thrombotic and bleeding events to the therapy used at that time. In case of oral anticoagulation use a period of three days was added to the stop date and considered as using anticoagulation therapy. Use of anticoagulation therapy was analysed as a time-dependent factor. Sensitivity analysis was performed for subgroups. A p-value of  $< 0.05$  was considered statistically significant. Data were expressed as median with the accompanying range and Interquartile range (IQR), where appropriate. All statistical analysis were performed with the Statistical Package for Social Sciences for Windows, version 16.0 (SPSS, Chicago, IL).



## RESULTS

A total of 120 patients, 43 men and 77 females with a median age of 44 years (range 16-87 years) were enrolled. Baseline characteristics are summarized in Table 1. In approximately 50% of the patients thrombosis was confined to the portal vein. In the rest of the cases thrombosis was more extensive, involving the splenic and- or mesenteric veins. Two patients presented with concomitant thrombosis outside the portal venous system: deep vein thrombosis of the lower limb and sinus sagittalis thrombosis, respectively. EPVT was diagnosed by ultrasound (n= 69), computed tomography (n= 45), venography (n= 2), magnetic resonance imaging (n= 3) and per-operative (n=1). Median duration of follow up was 5.5 years (range 0.1- 32.5 years; IQR was 2.0- 10.4 years). A prothrombotic state was found in 69(58%) patients. Thirty-nine patients had MPN as determined by either bone marrow biopsy and/or JAK2 mutation. Gastro-intestinal blood loss at baseline was caused by variceal bleeding, in all except of two patients where angiomatosis of the stomach and arteriovenous malformation of the rectum were present.

Sixty-six patients - 29/40 cases with recent EPVT, 33/71 cases with chronic EPVT and 4/9 cases where onset of thrombosis could not be determined - were treated with anticoagulation therapy. In 59 patients therapy was instituted immediately after the diagnosis EPVT was established. In the seven other cases anticoagulation therapy was started during follow up after a median period of 3.4 years (range 1.2- 15.4). Anticoagulation therapy was used during a median period of 1.9 years (range 0 - 15.8 years; IQR was 0.7-5.1 years). Forty-two patients still used anticoagulants at the end of follow up. Anticoagulants were stopped in 24/66 patients for the following reasons: completed intended time of treatment (n=16), iron deficiency anemia caused by menorrhagia (n=2), epistaxis (n=1), presence of varices grade  $\geq 2$  or variceal bleeding (n=2) or unknown (n=3).

From the 120 patients, 16 were treated with both anticoagulation therapy and an antiplatelet drug, 13 were on antiplatelet treatment only and 41 were not on anticoagulation nor on antiplatelet treatment. The number of patients on antiplatelet therapy was too small to assess effects on bleeding, recurrent thrombosis or survival.

### Bleeding

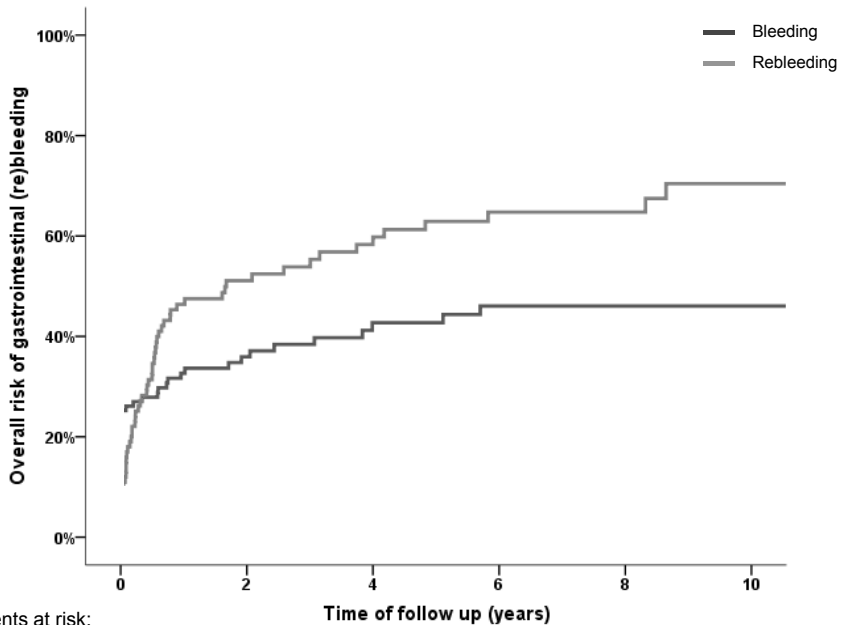
A total of 83 bleeding episodes (variceal bleeding n= 52 and other gastro-intestinal bleeding n=31) occurred in 37 patients during follow up. Sixteen patients had a single episode of bleeding, 11 patients had two episodes and 10 patients had more than three episodes of bleeding (range 3-9 events). The median time that the first bleeding occurred was seven months after EPVT diagnosis was established (range 0.1-11.5 years; IQR was 0.2- 3.0 years). Overall risk of gastro-intestinal bleeding was 33% (95% CI 24 - 41) at one year, 43% (95% CI 33-53) at five years and 46% (95% CI 36-56) at ten years

**Table 1.** Baseline Characteristics

Variable at baseline	Patients N=120	(%)
Sex (m/f)	43/ 77	
Age (yrs) <sup>9*</sup>	44 ± 16 (16 - 87)	
History of thrombosis	14/ 118	12%
Acute/ chronic thrombosis	40/71	
Site of thrombosis		
- Portal vein	64/120	53%
- Portal and splenic veins	9/120	8%
- Portal and mesenteric veins	17/120	14%
- Portal, splenic and mesenteric veins	30/120	25%
Underlying cause		
Inherited thrombophilia	24/95	25%
- Protein C deficiency	4/82	5%
- Protein S deficiency	11/83	13%
- Antithrombin deficiency	4/101	4%
- Factor V Leiden	6/86	7%
- Prothrombin gene mutation	1/71	1%
Acquired disorders	96/120	80%
- Myeloproliferative neoplasm	39/120	33%
- Infection	22/120	18%
- IBD		6%
- Antiphospholipid syndrome	7/120	7%
- Surgery	6/88	29%
- Splenectomy	35/120	6%
- Oral contraceptive use (females)	7/120	25%
- Smoking	28/113	30%
	28/94	
At diagnosis		
Varices	61/94	65%
- Varices grade I/II/III/IV	10/12/16/16	
- Gastro-intestinal bleeding	27/98	28%
- Ascites	32/118	27%
Blood hemoglobin (mmol/ L) <sup>10*</sup>	7.3 ± 1.7 (3.9 – 13.8)	
Platelet count (x 10E9/ L) <sup>11*</sup>	257 ± 194 (31 –1083)	
Bilirubin (µmol/L) <sup>12*</sup>	14 ± 33 (3 – 242)	
Aspartate transaminase (U/ L) <sup>13*</sup>	27 ± 73 (3 – 709)	
Alanine transaminase (U/ L) <sup>14*</sup>	28 ± 59 (9 – 508)	
Serum albumin (g/ L) <sup>15*</sup>	38 ± 7.0 (22- 51)	
Serum creatinin (µmol/ L) <sup>16*</sup>	68 ± 55 (35 – 385)	
APTT (sec)*	34 ± 21 (3 – 144)	
PT (sec)*	15 ± 10 (10 – 66)	
PTINR *	1.3 ± 0.8 (1.0 – 4.3)	

\* median ± sd (range)

(figure 1). The median time that a rebleeding occurred was four months (range 0.01- 8.6 years; IQR 0.9- 8 months) after the initial bleeding. Overall risk of re-bleeding was 46% (95% CI 36- 56) at one year, 63% at five years (95% CI 52-74) and 69% at ten years (95%



**Figure 1.** Overall risk of (re)bleeding

CI 59- 82) (figure 1). Predictors of (re)bleeding in the univariate analysis are shown in table 2. In the multivariate analysis we found that gastrointestinal bleeding (HR 2.1  $p < 0.01$ ), ascites at baseline (HR 2.0  $p = 0.01$ ) and use of anticoagulation therapy at the time of bleeding (HR 2.0  $p < 0.01$ ) were significant predictors of gastrointestinal (re) bleeding. There was no significant relation between the severity of the gastro-intestinal bleeding and the use of anticoagulants. Patients with anticoagulation therapy ( $n = 66$ ) had 58 bleeding episode versus 25 in patients without anticoagulation therapy ( $n = 54$ ). Median hemoglobin level at admission was 5.5 mmol/L (range 1.8- 8.7) in patients with anticoagulation therapy versus 5.8 (3.0- 8.5) mmol/L in patients without anticoagulation therapy. Median transfused packed red blood cells per bleeding episode was four (range 2- 20) in both groups. In total there were seven admissions to the ICU in the group of patients on anticoagulation therapy versus five in the other group.

### New thrombotic events

A total of 22 new thrombotic events occurred in 19 patients (venous events  $n = 15$ , arterial events  $n = 7$ ). Sites of thrombosis were: pulmonary embolism ( $n = 3$ ), superior mesenteric vein ( $n = 2$ ), lower limb ( $n = 4$ ), upper limb ( $n = 4$ ), sinus sagittalis ( $n = 1$ ), mesocaval shunt ( $n = 2$ ), intestinal ischemia ( $n = 2$ ) and ischemic stroke ( $n = 4$ ). The median time between diagnosis of EPVT and occurrence of a new thrombotic event was 5.7 years (range 0.1

**Table 2.** Univariate analysis of variables associated with bleeding and recurrent thrombosis

Variable	Bleeding		Thrombosis		Survival	
	HR (CI 95%)	P value	HR (CI 95%)	P value	HR (CI 95%)	P value
Age (years)***	1.1 (0.9-1.2)	0.5	1.2 (0.9-1.6)	0.20	1.9 (1.5-2.4)	< 0.01**
Female gender	0.7 (0.5-1.1)	0.2	0.9 (0.4-2.4)	0.9	0.9 (0.4-2.0)	0.8
Recent portal vein thrombosis						
Chronic portal vein thrombosis	1.1 (0.7-1.8)	0.7	1.2 (0.5-3.0)	0.8	1.7(0.7-4.0)	0.2
Site of thrombosis						
- Portal vein only	1	0.2	1	0.2	1	0.8
- Portal, splenic and mesenteric veins	1.7 (1.0-2.9)	0.04**	1.4 (0.5-3.9)	0.5	1.0 (0.4-2.6)	0.9
Varices	1.0 (0.6-1.7)	0.9	0.7 (0.3-2.0)	0.5	0.9 (0.4-2.3)	0.8
Varices grade $\geq 2$ ****	4.2 (1.0-18.0)	0.02**	1.1 (0.2-5.7)	0.9	1.3 (0.3-6.1)	0.8
Gastro-intestinal bleeding at baseline	1.7 (1.0-2.7)	0.04**	1.3 (0.5-3.6)	0.6		
Gastro-intestinal(re) bleeding during the follow up*					1.6 (0.7-3.5)	0.2
Ascites	2.2 (1.3-3.6)	< 0.01**	1.7(0.5-5.5)	0.4	6.1 (2.2-16.4)	<0.01**
New thrombotic event*					3.1 (1.2-8.0)	0.02**
Anticoagulation therapy *	1.7 (1.1-2.7)	0.03**	0.2 (0.0-1.9)	0.1	0.5 ( 0.2-1.3)	0.2
Underlying causes						
- Inherited	1.0 (0.5-1.7)	0.9	1.0 (0.3-3.6)	0.9	0.3 (0.0- 2.5)	0.2
- Acquired	0.7 (0.4-1.1)	0.1	0.9 (0.3-2.8)	0.9	1.4 (0.5-4.0)	0.6
▪ MPD	1.2 (0.8-2.0)	0.4	1.9 (0.8-4.5)	0.2	2.6 (1.3-5.5)	0.01**
▪ Infection	0.6 (0.3-1.3)	0.1	0.3 (0.8-1.5)	0.1	0.3 (0.1-1.1)	0.04**
▪ IBD	- <sup>†)</sup>		1.0 (0.2-4.4)	0.9	0.8 (0.2-3.5)	0.8
- Prothrombotic disorder	1.1 (0.7-1.7)	0.7	3.1(1.0-9.5)	0.03**	3.0(1.2-7.4)	0.01**

\* Analysed as a time-dependent factor

\*\* Statistical significant

\*\*\* Ten-year increment

\*\*\*\*According the Paquet Classification[23]

<sup>†)</sup>There were not enough bleeding events observed to assess the effect of IBD

– 19.0 years; IQR was 1.8-8.6 years). Overall risk of a new thrombotic event was 3% (95% CI 0-7) at one year, 8% (95% CI 3- 14) at five years and 24% (95% CI 13- 36) at ten years (figure 2). Seventy-four percent of the new thrombotic events occurred in patients with a prothrombotic disorder. Recurrence or extension of thrombosis into the splanchnic veins was only seen in patients with a prothrombotic disorder. Sixteen new thrombotic events were found in 69 (23%) patients with a prothrombotic disorder versus six events in 51(11%) patients without a prothrombotic disorder. Use of anticoagulants tended to reduce the occurrence of a new venous thrombotic event (HR 0.2 p= 0.1). Predictors of a new thrombotic event are shown in table 2.

## Survival

Twenty-nine patients died. Median age of death was 64.2 years (range 30.4- 95.3 years). Overall survival was 90% (95%CI 84-96) and 70% (95%CI 58-82) at 5 and 10 years, respec-

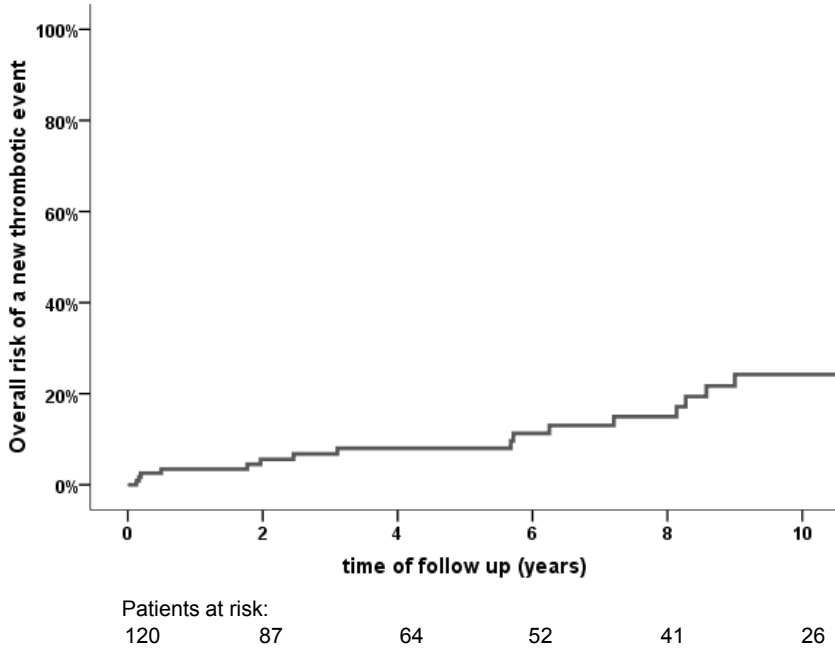


Figure 2. Overall risk of new thrombotic event

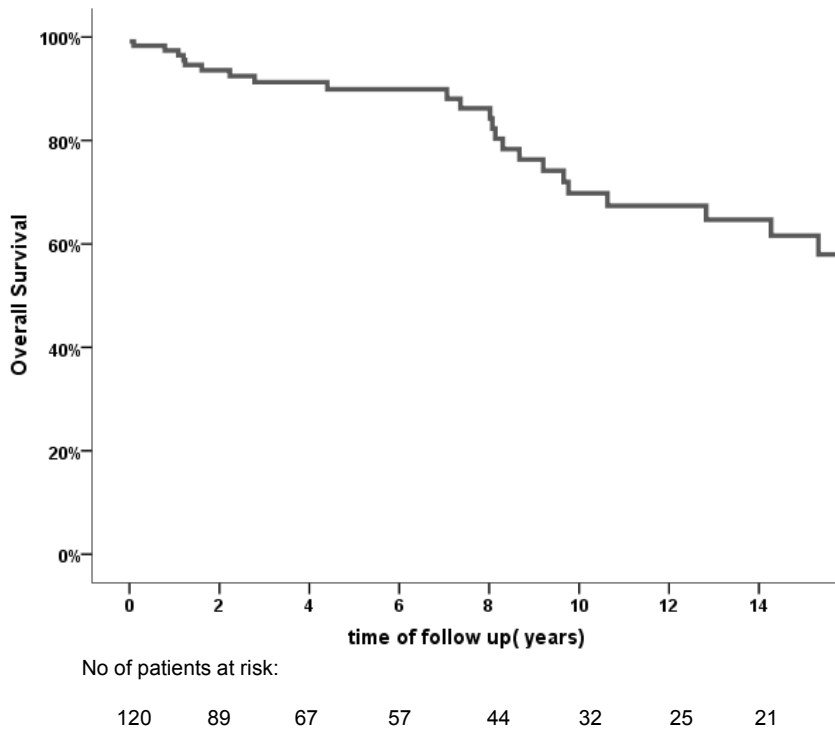


Figure 3. Overall survival

tively (figure 3). Predictors of survival in the univariate analysis are presented in table 2. In the multivariate analysis increased age (HR 1.1  $p < 0.01$ ) and ascites at diagnosis (HR 4.0  $p = < 0.01$ ) were the only significant factors associated with increased mortality. In the time- dependent covariate analysis we found that a new thrombotic event was significantly associated with a poor survival (HR 3.1  $p = 0.02$ ). Gastrointestinal bleeding (HR 1.6  $p = 0.2$ ) and anticoagulants use had both their effect (HR 0.5  $p = 0.2$ ) on survival, but not statistically significant. Five patients died due to a bleeding: cerebellar hematoma ( $n = 1$ ), variceal bleeding ( $n = 2$ ) and other upper gastro-intestinal bleeding ( $n = 2$ ). The latter two patients were both on anticoagulation therapy. Three patients died due to a new thrombotic event (necrotic colon due to massive arterial ischemia, ischemic cerebral vascular accident and sinus sagittalis thrombosis. The last two patients were both on anticoagulation therapy when the thrombotic events occurred. Other causes of death were progressive MPN ( $n = 6$ ), infection ( $n = 3$ ), other causes ( $n = 7$ ) and unknown ( $n = 5$ )

## DISCUSSION

In this study we investigated anticoagulation therapy and other factors associated with gastrointestinal bleeding, new thrombotic events and survival in patients with non-cirrhotic non malignant EPVT. In about twenty percent of the patients with a prothrombotic disorder a new thrombotic event occurred, which was significantly associated with decreased survival. Anticoagulation therapy showed a tendency to prevent new thrombosis, however it significantly increased the risk of gastro-intestinal bleeding.

As is known from previous studies (re)bleeding is mainly determined by size of varices and initial presentation of a gastrointestinal bleeding [5, 16, 24]. In addition to these factors, we found that both extension of thrombosis into the splanchnic veins as ascites at baseline were significant factors predicting (re)bleeding. These new findings may help to identify patients with a high risk of gastrointestinal bleeding and also may influence whether to start anticoagulation therapy. Condat et al. concluded that the benefit-risk ratio favours anticoagulation therapy for most patients with EPVT [16]. They made this conclusion on two major findings. Firstly, the risk of new thrombotic events was profoundly reduced by anticoagulation therapy. This reduction involved mainly thrombotic recurrence or extension within the portal venous system. Secondly, they did not find a significant correlation between the risk and severity of gastro-intestinal bleedings and the use of anticoagulation therapy. We found that patients with EPVT and a prothrombotic disorder had a three-fold increased risk to develop new thrombotic events both in and outside the splanchnic veins. Extension of thrombosis into the splanchnic veins occurred only in patients with a prothrombotic disorder. These findings suggest that anticoagulation therapy is warranted in patients with a prothrombotic disorder. In our

study anticoagulation therapy tended to have an overall beneficial effect on decreasing new thrombotic events and even somewhat on improving survival. On the other hand the use of anticoagulation therapy significantly increased the risk of gastrointestinal bleeding. A total of four patients (3%) died due to gastrointestinal bleeding, two were on anticoagulation therapy. Three patients (3%) died due to a thrombotic event, of which two were on adequate anticoagulation therapy.

With this study we support the current guidelines which state that anticoagulation therapy can be considered in patients with EPVT and an underlying prothrombotic disorder [19, 25]. However, we also found that anticoagulation therapy is not without risk.

Our study has several limitations. Decisions about anticoagulation treatment and performing radiological imaging were made by the treating physician. This led to the fact that not all patients did have a systemic radiological imaging during follow up and that the time between radiological imaging differed among the patients. Recurrence of portal vein thrombosis or extension of thrombosis into the splanchnic veins could have occurred in some patients and remained unidentified. Especially in those cases where no clinical significant signs or symptoms were present. Patients with an extensive thrombosis are more likely to get anticoagulation therapy than patients presenting with a gastro-intestinal bleeding. Both factors were carefully taken into account in the uni- and multivariate analysis. Furthermore during the long study period new insights and diagnostic tests have been developed. This may have led to an underrepresentation and - treatment of patients with prothrombotic disorders enrolled in the early part of the study. In parallel, these patients were initially not on anticoagulation therapy. Also patients could stop and restart anticoagulation therapy during their course. We therefore analyzed each bleeding or thrombotic event according to the therapy used at that time.

In conclusion, in patients with non- cirrhotic EPVT new thrombotic events occur primarily in patients with a prothrombotic disorder and are significantly associated with decreased survival. Anticoagulation therapy can lead to prevention of new thrombosis, but also significantly increases the risk of gastrointestinal bleeding. These findings imply that anticoagulation therapy on one hand is warranted in patients with EPVT and an underlying prothrombotic disorder, while on the other hand it should be given with caution to those with high risk of bleeding.

## REFERENCES

- [1] Grauer SE, Schwartz SI. Extrahepatic portal hypertension: a retrospective analysis. *Ann Surg.* 1979 May;189(5):566-74.
- [2] Webb LJ, Sherlock S. The aetiology, presentation and natural history of extra-hepatic portal venous obstruction. *Q J Med.* 1979 Oct;48(192):627-39.
- [3] Cohen J, Edelman RR, Chopra S. Portal vein thrombosis: a review. *Am J Med.* 1992 Feb;92(2):173-82.
- [4] Voorhees AB, Jr., Price JB, Jr. Extrahepatic portal hypertension. A retrospective analysis of 127 cases and associated clinical implications. *Arch Surg.* 1974 Mar;108(3):338-41.
- [5] Spaander MC, Darwish Murad S, van Buuren HR, Hansen BE, Kuipers EJ, Janssen HL. Endoscopic treatment of esophagogastric variceal bleeding in patients with noncirrhotic extrahepatic portal vein thrombosis: a long-term follow-up study. *Gastrointest Endosc.* 2008 May;67(6):821-7.
- [6] Janssen HL, Meinardi JR, Vleggaar FP, van Uum SH, Haagsma EB, van Der Meer FJ, et al. Factor V Leiden mutation, prothrombin gene mutation, and deficiencies in coagulation inhibitors associated with Budd-Chiari syndrome and portal vein thrombosis: results of a case-control study. *Blood.* 2000 Oct 1;96(7):2364-8.
- [7] Primignani M, Martinelli I, Bucciarelli P, Battaglioli T, Reati R, Fabris F, et al. Risk factors for thrombophilia in extrahepatic portal vein obstruction. *Hepatology.* 2005 Mar;41(3):603-8.
- [8] Chamouard P, Pencreach E, Maloisel F, Grunebaum L, Ardizzone JF, Meyer A, et al. Frequent factor II G20210A mutation in idiopathic portal vein thrombosis. *Gastroenterology.* 1999 Jan;116(1):144-8.
- [9] Egesel T, Buyukasik Y, Dundar SV, Gurgey A, Kirazli S, Bayraktar Y. The role of natural anticoagulant deficiencies and factor V Leiden in the development of idiopathic portal vein thrombosis. *J Clin Gastroenterol.* 2000 Jan;30(1):66-71.
- [10] Mahmoud AE, Elias E, Beauchamp N, Wilde JT. Prevalence of the factor V Leiden mutation in hepatic and portal vein thrombosis. *Gut.* 1997 Jun;40(6):798-800.
- [11] Ahuja V, Marwaha N, Chawla Y, Dilawari JB. Coagulation abnormalities in idiopathic portal venous thrombosis. *J Gastroenterol Hepatol.* 1999 Dec;14(12):1210-1.
- [12] Chait Y, Condat B, Cazals-Hatem D, Rufat P, Atmani S, Chaoui D, et al. Relevance of the criteria commonly used to diagnose myeloproliferative disorder in patients with splanchnic vein thrombosis. *British journal of haematology.* 2005 May;129(4):553-60.
- [13] Valla D, Casadevall N, Huisse MG, Tulliez M, Grange JD, Muller O, et al. Etiology of portal vein thrombosis in adults. A prospective evaluation of primary myeloproliferative disorders. *Gastroenterology.* 1988 Apr;94(4):1063-9.
- [14] Colaizzo D, Amitrano L, Tiscia GL, Scenna G, Grandone E, Guardascione MA, et al. The JAK2 V617F mutation frequently occurs in patients with portal and mesenteric venous thrombosis. *J Thromb Haemost.* 2007 Jan;5(1):55-61.
- [15] Valla DC, Condat B. Portal vein thrombosis in adults: pathophysiology, pathogenesis and management. *J Hepatol.* 2000 May;32(5):865-71.
- [16] Condat B, Pessione F, Hillaire S, Denninger MH, Guillin MC, Poliquin M, et al. Current outcome of portal vein thrombosis in adults: risk and benefit of anticoagulant therapy. *Gastroenterology.* 2001 Feb;120(2):490-7.
- [17] Joh JH, Kim DI. Mesenteric and portal vein thrombosis: treated with early initiation of anticoagulation. *Eur J Vasc Endovasc Surg.* 2005 Feb;29(2):204-8.



- [18] Denninger MH, Chait Y, Casadevall N, Hillaire S, Guillin MC, Bezeaud A, et al. Cause of portal or hepatic venous thrombosis in adults: the role of multiple concurrent factors. *Hepatology*. 2000 Mar;31(3):587-91.
- [19] DeLeve LD, Valla DC, Garcia-Tsao G. Vascular disorders of the liver. *Hepatology*. 2009 May;49(5):1729-64.
- [20] Bauer KA. Role of thrombophilia in deciding on the duration of anticoagulation. *Semin Thromb Hemost*. 2004 Dec;30(6):633-7.
- [21] Condat B, Pessione F, Helene Denninger M, Hillaire S, Valla D. Recent portal or mesenteric venous thrombosis: increased recognition and frequent recanalization on anticoagulant therapy. *Hepatology*. 2000 Sep;32(3):466-70.
- [22] Plessier A, Darwish-Murad S, Hernandez-Guerra M, Consigny Y, Fabris F, Trebicka J, et al. Acute portal vein thrombosis unrelated to cirrhosis: a prospective multicenter follow-up study. *Hepatology*. Jan;51(1):210-8.
- [23] Paquet KJ, Oberhammer E. Sclerotherapy of bleeding oesophageal varices by means of endoscopy. *Endoscopy*. 1978 Feb;10(1):7-12.
- [24] Pagliaro L, D'Amico G, Luca A, Pasta L, Politi F, Aragona E, et al. Portal hypertension: diagnosis and treatment. *J Hepatol*. 1995;23 Suppl 1:36-44.
- [25] De Franchis R. Revising consensus in portal hypertension. Report of the Baveno V Consensus Workshop on methodology of diagnosis and therapy in portal hypertension. *J Hepatol*. 2010.



## Chapter 6


---

### **Risks and benefits of transcatheter thrombolytic therapy in patients with splanchnic venous thrombosis**

Jasper H. Smalberg<sup>1</sup>, Manon C.W. Spaander<sup>2</sup>, Kon-Siong G. Jie<sup>1</sup>, Peter M.T. Pattynama<sup>3</sup>, Henk R. van Buuren<sup>2</sup>, Bart van den Berg<sup>4</sup>, Harry L.A. Janssen<sup>2</sup> and Frank W.G. Leebeek<sup>1</sup>.

*1.Department of Hematology, 2.Department of Gastroenterology & Hepatology, 3.Department of Radiology and 4. Department of Intensive Care Medicine, Erasmus MC University Medical Center, Rotterdam, The Netherlands*

*Thrombosis and Haemostasis 2008 Dec;100(6):1084-8.*



## ABSTRACT

**Introduction:** Transcatheter local thrombolytic therapy in patients with acute, extended splanchnic venous thrombosis is controversial. Here we present our single-center experience with transcatheter thrombolytic therapy in these patients.

**Methods:** All consecutive patients (n=12) with acute, extended splanchnic venous thrombosis who underwent transcatheter thrombolytic therapy in our hospital, were included in this study.

**Results:** Thrombolytic therapy was successful for three thrombotic events and partially successful for four thrombotic events. Two patients developed minor procedure related bleeding (17%). Six patients (50%) developed major procedure related bleeding, with a fatal outcome in two.

**Conclusions:** Transcatheter thrombolytic therapy in patients with acute, extended splanchnic vein thrombosis is found to be associated with a high rate of procedure related bleeding. Therefore, thrombolysis should be reserved for patients in whom the venous flow cannot be restored by using conventional anticoagulant therapy or stent placement across the thrombosed vessel segment.

## INTRODUCTION

Splanchnic venous thrombosis (SVT) comprises thrombosis of the hepatic veins and the portal venous system. It includes the Budd-Chiari syndrome (BCS), characterized by hepatic outflow obstruction (1) and portal vein thrombosis (PVT) (2). SVT is often related to prothrombotic disorders (3, 4) or caused by underlying haematological diseases that predispose to hypercoagulability, such as myeloproliferative diseases and paroxysmal nocturnal haemoglobinuria (5, 6). One of the treatment options in SVT patients is locally delivered transcatheter thrombolytic therapy, which is mainly used in patients with acute, combined thrombosis of both portal and hepatic veins. Several case studies or small case series describe successful thrombolytic therapy in SVT patients with a low incidence of bleeding complications (7-14). However, these reports should be interpreted with caution in view of a potential publication bias of successful cases. Only two larger studies have been performed in which success and complication rates vary widely (15, 16). Therefore, it is difficult to properly assess the risk/benefit ratio and thrombolytic therapy remains controversial. Here we present our single-center experience with thrombolytic therapy in a series of consecutive patients with SVT.

## MATERIAL AND METHODS

All SVT patients who underwent transcatheter thrombolytic therapy in our hospital, between January 1996 and December 2007, were included in this study. Clinical records of all patients were reviewed and demographics, etiology, clinical presentation, duration of symptoms, details of thrombolytic therapy, outcome, complications and follow-up were reported in a standardized way. The diagnosis of SVT was established by computed tomography, transcatheter portography, magnetic resonance imaging or Doppler Ultrasound. The obstruction was graded partially when there was a significant remaining patent vein lumen or complete. The Child-Pugh score was used as an indication of liver function prior to thrombolytic therapy in patients with cirrhosis and BCS. Patients were followed from initiation of thrombolysis until death, study closure (December 31, 2007), or, in case of loss to follow up, the last date of visit. Survival rates were calculated by means of the Kaplan-Meier method.

Patients were considered for thrombolysis if they met the following criteria. First, only patients with an acute thrombosis (duration of symptoms  $\leq$  14 days) were considered for thrombolytic therapy. Second, thrombolytic therapy was only used in patients with thrombosis in two or more vessel systems in the splanchnic area, e.g. thrombosis of the hepatic veins combined with PVT. Third, in most patients thrombolysis was considered after standard anticoagulant therapy had proven insufficient, i.e. in patients exhibiting

a progressive thrombosis or a clinical deterioration despite anticoagulation. Informed consent was obtained from each patient after informing them on the possible risks and benefits of the treatment.

To facilitate creation of the transhepatic tract from the liver vein (inferior caval vein in BCS) to the portal vein during transjugular intrahepatic portosystemic shunt (TIPS) placement, a marker catheter was introduced in the portal vein by the direct percutaneous transhepatic route and by using ultrasound guidance. The decision to deliver thrombolytic therapy through a percutaneously inserted transhepatic catheter, or through a catheter placed through a pre-existing or specially created TIPS, was not a constant but rather evolved over time – influenced also by literature suggesting the benefit of additional TIPS for thrombolysis (17-19). Thrombolysis was considered successful when vessel patency and blood flow were restored, as observed during venography, and considered partially successful when flow was restored in some, but not all, thrombosed veins. Thrombolysis was considered unsuccessful when no lysis was obtained in any of the occluded vessels. Thrombolytic therapy was discontinued in case of resolution of the thrombus or in case of severe bleeding.

All patients were initially treated by APTT-controlled (APTT ratio 2.2-2.9, reflecting an anti Xa activity of 0.3-0.7 U/ml) infusion of unfractionated heparin (UFH) or a therapeutic dose of low molecular weight heparin (LMWH, dalteparin, 200 U/kg BW s.c.). Recombinant tissue type plasminogen activator (Actilyse®, Boehringer-Ingelheim, Germany), rtPA, was used as thrombolytic agent and was delivered by means of a locally placed catheter. Patients were treated by continuous infusion of 2-4 mg/hr rtPA, in some cases preceded by a 4-10 mg bolus injection. In one patient urokinase was administered. During thrombolysis all patients were admitted to an intensive care unit for hemodynamic monitoring. Low dose UFH was continued during thrombolytic treatment (10,000 IU/24 hours). After thrombolytic treatment was stopped, UFH was again administered in a therapeutic dosage and was discontinued once the patient was adequately anticoagulated with vitamin K antagonists. After discharge from hospital, patients were followed at the outpatient department of our hospital.

## RESULTS

### Patient characteristics

Twelve patients (58% male) with a mean age of 32 years (range 26-53) underwent thrombolytic therapy and were included in this study. Six patients had BCS with additional thrombosis in the portal system. The majority of patients had an underlying pro-thrombotic haematological disorder. Patient characteristics, including etiology and indication for thrombolytic therapy, are presented in table 1.

**Table 1.** Characteristics of 12 patients with splanchnic vein thrombosis (SVT) treated with thrombolysis

Pt.	Sex	Age	Etiology	Indication	Duration of symptoms	Child-Pugh class
<b>Budd-Chiari syndrome</b>						
1.	M	26	Factor V Leiden (heterozygous)	Progression of thrombosis despite heparin	9 days	A
2.	F	30	Factor V Leiden (homozygous), OCC	Progression of thrombosis despite heparin	14 days	A
3.	M	33	Myeloproliferative disease	Clinical deterioration despite anticoagulation	7 days	C
4.	M	30	Paroxysmal nocturnal hemoglobinuria	Progression of thrombosis despite anticoagulation	7 days	B/C
5.	F	26	Antiphospholipid antibodies, OCC	Progression of thrombosis despite heparin	7 days	B
6.	M	38	Myeloproliferative disease	Thrombotic complication during TIPS creation		C
<b>Portal vein thrombosis</b>						
7.	F	34	Lymphoma, splenectomy	Extensive post-splenectomy thrombosis	7 days	-
8.	F	25	Lymphangiomas, OCC	Extensive PV and MV thrombosis	14 days	-
9.	F	27	OCC, hyperhomocysteinemia	Progression of thrombosis despite heparin	12 days	-
10.	M	27	Hemolytic anemia, splenectomy	Progression of thrombosis despite heparin	9 days	-
<b>Cirrhotic patients</b>						
11.	M	53	Alcoholic liver cirrhosis	Extensive thrombosis and thrombotic complication during TIPS creation	8 days	C
12.	M	37	Auto-immune liver cirrhosis, ulcerative colitis	TIPS dysfunction and extensive thrombosis with a thrombotic complication during TIPS revision and renewed thrombosis despite anticoagulation	6 days	B

OCC: oral contraceptives; PV: portal vein ; MV : mesenteric vein ; TIPS : transjugular intrahepatic portosystemic shunt.

Child-Pugh score was obtained for patients with BCS and liver cirrhosis.

### Details of thrombolytic therapy and outcome

Twelve patients were treated with thrombolytic therapy for thirteen thrombotic events. One patient (pt. 12) was treated twice, because of renewed thrombosis five days after initial successful thrombolysis despite heparin therapy. Route of delivery of the thrombolytic agent was percutaneous transhepatic (n=4), transjugular transhepatic (n=6) or other (n=3). The total percutaneous transhepatic catheters amounted to eight, in which they were either used as a marker catheter to facilitate TIPS placement, or as an indwelling catheter through which the thrombolytic agent was administered. TIPS insertion/revision was performed in six patients. Thrombolysis was successful for three thrombotic

events in two patients (pt. 7 and 12). Therapy was partially successful in four patients (pt. 2, 5, 6 and 8). Details of thrombolytic therapy are presented in table 2. Five out of six procedures which were combined with a TIPS insertion/revision were (partially) successful.

### **Complications**

Two patients developed minor bleeding, not requiring transfusion, after cessation of thrombolytic therapy (pt 2 and 7). Six patients developed major bleeding necessitating discontinuation of thrombolytic treatment. In two of these patients, thrombolysis had been partially successful at that time (pt. 5 and 8).

One patient died directly related to bleeding (pt. 3). This BCS patient had additional PVT and MVT and developed a fatal massive sub-capsular liver haemorrhage resulting in hypovolemic shock. Patient 11 died two weeks after thrombolytic therapy, which was complicated by bacterial peritonitis and renal failure after massive abdominal bleeding. The patient eventually died from multiple organ failure. The death of this patient was considered to be partly caused by procedure related bleeding.

Four patients developed major, but nonfatal, bleeding, including retroperitoneal bleeding (pt 4), intraperitoneal bleeding (pt 5), massive intra-abdominal bleeding (pt 8) and a subcapsular liver haematoma (pt 9) (table 2).

### **Clinical parameters related to outcome**

Laboratory evaluation showed a marked decrease of fibrinogen in patient 2, 3, and 11 (pre-treatment values of 3.6 g/l, 2.2 g/l, and 2.5 g/l, respectively [normal 1.5-3.6 g/l]) to a nadir of 0.6 g/l, 0.3 g/l and 0.7 g/l, respectively, during thrombolytic treatment. Patient 5 already had a pre-treatment fibrinogen of 0.7 g/l and remained < 1.0 g/l during thrombolysis. These four patients all developed bleeding complications (of which three major bleeding). The two patients with a fatal outcome showed the lowest fibrinogen levels of all patients (0.3 g/l and 0.4 g/l) during thrombolytic therapy. None of the four patients without bleeding complications had fibrinogen levels <1.0 g/l (table 3).

The Child-Pugh score was obtained for six patients with BCS and two patients with liver cirrhosis. Six patients had a Child-Pugh score > 7 and were considered to have liver dysfunction. Four of these patients developed major bleeding complications, of which two were fatal. The two patients with a fatal outcome exhibited the highest Child-Pugh scores. Bleeding complications were also observed in four of six patients with a normal liver function, of which two were major (table 3).

### **Follow-up**

The mean time of follow-up was 3.7 years (range 3 days – 10.6 years). Survival according to Kaplan-Meier analysis at 1, 3 and 5 years was 67% (95% CI, 40%-93%). One patient was lost to follow-up. Patient 1 and 4 died 5.6 and 2.9 months after thrombolysis, respec-



**Table 2.** Details on thrombolysis and thrombolytic therapy in 12 SVT patients treated with thrombolysis

Patient <sup>a</sup> , approach <sup>b</sup>	Dosage and duration <sup>c</sup>	Occluded vessel(s) <sup>d</sup>	Additional interventions	Outcome	Complications	Follow-up
<b>Budd-Chiari syndrome</b>						
1. TH	b 0 mg c 2 mg/hr for 24 hr c 3 mg hr for 24 hr c 4 mg/hr for 5 days	HV, ICV (complete) PV, SV, MV (partial)	None	Unsuccessful	None	Died 5.6 months later
2. TJ	b 10 mg c 4 mg/hr for 20 hr c 2 mg hr for 4 hr	HV, PV, MV (partial)	TIPS	Partially successful: PV/ MV open	Minor bleeding	10.6 years
3. TH	b 10 mg c 2 mg/hr for 3 hr c 4 mg hr for 29 hr	HV, PV, MV (complete)	None	Unsuccessful	Major bleeding, death	
4. Other <sup>c</sup>	b 10 mg c 4 mg/hr for 31 hr	HV, PV (complete)	None	Unsuccessful	Major bleeding	Died 2.9 months later
5. Other <sup>c</sup>	b 4mg c 4 mg/hr for 6 hr c 2 mg hr for 2 hr	HV, PV, MV, SV (complete)	TIPS	Partially successful: MV open	Major bleeding	7.3 years
6. TJ <sup>d</sup>	500000 units urokinase in 20 min	HV, TIPS (complete)	TIPS revision	Partially successful: TIPS open	None	1.9 years
<b>Portal vein thrombosis</b>						
7. TH	b 0 mg c 3 mg/hr for 6 days	PV, SV (partial)	None	Successful	Minor bleeding	Died 7.5 years later
8. TJ <sup>d</sup>	b 10 mg c 2 mg/hr for 10 hr	PV (partial) MV (complete)	TIPS	Partially successful: PV open	Major bleeding	7 years
9. TJ	b 10 mg c 2 mg/hr for 6 hr c 4 mg/hr for 5.5 hr	PV, MV, SV (complete)	None	Unsuccessful	Major bleeding	6.3 years

Patient <sup>a</sup> , approach <sup>b</sup>	Dosage and duration <sup>c</sup>	Occluded vessel(s) <sup>f</sup>	Additional interventions	Outcome	Complications	Follow-up
10. TH	b 10 mg c 2 mg/hr for 96 hr	PV, VL, MV (complete)	None	Unsuccessful	None	8.5 months
<b>Cirrhotic patients</b>						
11. TJ <sup>d</sup>	b 10 mg c 4 mg/hr for 12 hr	PV, TIPS (complete)	TIPS revision	Unsuccessful	Major bleeding, death	
12.1 TJ	b 10 mg c 2 mg/hr for 6 hr	PV, TIPS (complete)	TIPS revision	Successful	None	
12.2 Other <sup>e</sup>	b 10 mg c 2 mg/hr for 6 hr	MV (complete)	None	Successful	None	1.7 years

<sup>a</sup> Patient 12 exhibited two thrombotic events, which were subdivided in 12.1 and 12.2.

<sup>b</sup> TH: transhepatic; TJ: transjugular

<sup>c</sup> Patient 4: catheter was positioned utilizing a previously created portocaval shunt; patient 5: multiple catheters were used for thrombolytic treatment; percutaneous transhepatic, transjugular-transhepatic and a catheter placed in the superior mesenteric artery; patient 12: the catheter for thrombolysis was positioned in the superior mesenteric artery because of extensive thrombosis of the superior mesenteric vein extending far into the peripheral vein branches.

<sup>d</sup> A marker catheter was introduced via the percutaneous transhepatic approach.

<sup>e</sup> b: bolus; c: continuous.

<sup>f</sup> PV: portal vein; HV: hepatic veins; MV: mesenteric veins; SV: splenic vein; ICV: inferior caval vein; TIPS: transjugular intrahepatic portosystemic shunt.

**Table 3.** Fibrinogen levels and liver function during thrombolytic therapy in relation to bleeding complications

	Number of patients	Major bleeding n (%)	Minor bleeding n (%)	No complications n (%)
Fibrinogen < 1.0 g/l	4	3 <sup>a</sup> (75%)	1 (25%)	0 (0%)
Fibrinogen > 1.0 g/l	8	3 (38%)	1 (13%)	4 (50%)
Liver dysfunction	6	4 <sup>a</sup> (67%)	0 (0%)	2 (33%)
No liver dysfunction	6	2 (33%)	2 (33%)	2 (33%)

<sup>a</sup>Outcome was fatal in two patients.

tively, due to multiple complications of combined BCS and PVT, which were not related to thrombolysis. Patient 7 died 7.5 years after thrombolysis from lymphoma.

## DISCUSSION

Both systemic and local administration of thrombolytics have been described in the treatment of SVT, but the latter is preferred (15, 16, 20). Despite several successful single-case reports and two larger case-series, thrombolytic treatment remains controversial (7-16). In our study, one of the largest series on thrombolysis in SVT patients, we report slightly lower success rates accompanied by a previously unreported high rate of procedure related bleeding.

When thrombolytic therapy is indicated, TIPS placement, creating a patent portal venous outflow tract to the systemic venous circulation, followed by local administration of thrombolytic agents in the portal vein appears an effective approach. This is supported by previous reports (17-19). In three out of six TIPS procedures, major bleeding occurred and one patient eventually died, however, it is difficult to determine whether this is related to the TIPS procedure itself. The invasive procedure necessary for using local thrombolysis has a great overlap with the TIPS procedure. Therefore, it seems prudent to simultaneously create a TIPS when performing thrombolysis, as a patent TIPS has been shown to be beneficial in terms of clinical improvement and survival in SVT patients (21-23).

The relation between fibrinogen levels and bleeding risk suggests that, for safety reasons, it is prudent to monitor fibrinogen levels during thrombolysis and fibrinogen should be supplemented if levels fall <1.0 g/l. Our results indicate that liver dysfunction might be a risk factor for procedure related bleeding, implying that thrombolysis should be cautiously used in these patients. The association between the percutaneous transhepatic approach and bleeding concurs with previous reports, where also the transjugular approach was preferred (16, 24, 25).

A limitation of our study is that it is a single-center, retrospective study with a limited number of patients. Patients are heterogeneous in terms of etiology, clinical presentation, extent of thrombosis, baseline health status and details of thrombolytic therapy. Our study population is highly selected from a large number of cases referred to our specialized tertiary care center and most of the patients had a deteriorating clinical course before thrombolytic therapy was initiated. The strength of our study is that it includes all patients that have been treated avoiding publication bias of successful cases.

In conclusion, in a series of consecutive patients receiving locally delivered thrombolysis for acute, extended SVT we found a previously unreported high rate of bleeding complications. These patients generally have a poor prognosis (26) and it is up to the treating physician to determine whether the potential benefits of thrombolysis outweigh the apparent risks associated with the procedure. Based on our findings, and previous reports in the literature, we have come to the following preferred approach in patients with acute, extended SVT. Start with conventional anticoagulant therapy and in case of insufficient results proceed to TIPS placement. If venous flow cannot be restored by either of these treatment modalities, local thrombolytic therapy, administered via transjugular approach, can be considered.

## REFERENCES

1. Janssen HL, Garcia-Pagan JC, Elias E, Mentha G, Hadengue A, Valla DC. Budd-Chiari syndrome: a review by an expert panel. *J Hepatol.* 2003 Mar;38(3):364-71.
2. Valla DC, Condat B. Portal vein thrombosis in adults: pathophysiology, pathogenesis and management. *J Hepatol.* 2000 May;32(5):865-71.
3. de Bruijne EL, Murad SD, de Maat MP, Tanck MW, Haagsma EB, van Hoek B, et al. Genetic variation in thrombin-activatable fibrinolysis inhibitor (TAFI) is associated with the risk of splanchnic vein thrombosis. *Thromb Haemost.* 2007 Feb;97(2):181-5.
4. Dentali F, Galli M, Gianni M, Ageno W. Inherited thrombophilic abnormalities and risk of portal vein thrombosis. A meta-analysis. *Thromb Haemost.* 2008 Apr;99(4):675-82.
5. Poulou LS, Xila V, Rokas GI, Karianakis G, Bartzoudis D, Ziakas PD. Temporal trends in mortality rates from visceral vein thrombosis in paroxysmal nocturnal haemoglobinuria: An optimistic view. *Thromb Haemost.* 2008 Mar;99(3):642-5.
6. Smalberg JH, Murad SD, Braakman E, Valk PJ, Janssen HL, Leebeek FW. Myeloproliferative disease in the pathogenesis and survival of Budd-Chiari syndrome. *Haematologica.* 2006 Dec;91(12):1712-3.
7. Guglielmi A, Fior F, Halmos O, Veraldi GF, Rossaro L, Ruzzenente A, et al. Transhepatic fibrinolysis of mesenteric and portal vein thrombosis in a patient with ulcerative colitis: a case report. *World J Gastroenterol.* 2005 Apr 7;11(13):2035-8.
8. Henao EA, Bohannon WT, Silva MB, Jr. Treatment of portal venous thrombosis with selective superior mesenteric artery infusion of recombinant tissue plasminogen activator. *J Vasc Surg.* 2003 Dec;38(6):1411-5.
9. Kercher KW, Sing RF, Watson KW, Matthews BD, LeQuire MH, Heniford BT. Transhepatic thrombolysis in acute portal vein thrombosis after laparoscopic splenectomy. *Surg Laparosc Endosc Percutan Tech.* 2002 Apr;12(2):131-6.
10. Kuo GP, Brodsky RA, Kim HS. Catheter-directed thrombolysis and thrombectomy for the Budd-Chiari syndrome in paroxysmal nocturnal hemoglobinuria in three patients. *J Vasc Interv Radiol.* 2006 Feb;17(2 Pt 1):383-7.
11. Leebeek FW, Lameris JS, van Buuren HR, Gomez E, Madretsma S, Sonneveld P. Budd-Chiari syndrome, portal vein and mesenteric vein thrombosis in a patient homozygous for factor V Leiden mutation treated by TIPS and thrombolysis. *Br J Haematol.* 1998 Sep;102(4):929-31.
12. Nakai M, Sato M, Sahara S, Kawai N, Kimura M, Maeda Y, et al. Transhepatic catheter-directed thrombolysis for portal vein thrombosis after partial splenic embolization in combination with balloon-occluded retrograde transvenous obliteration of splenorenal shunt. *World J Gastroenterol.* 2006 Aug 21;12(31):5071-4.
13. Ozkan U, Oguzkurt L, Tercan F, Tokmak N. Percutaneous transhepatic thrombolysis in the treatment of acute portal venous thrombosis. *Diagn Interv Radiol.* 2006 Jun;12(2):105-7.
14. Sherigar R, Amir KA, Bobba RK, Arsura EL, Srinivas N. Abdominal pain secondary to pylephlebitis: an uncommon disease of the portal venous system, treated with local thrombolytic therapy. *Dig Dis Sci.* 2005 May;50(5):983-7.
15. Hollingshead M, Burke CT, Mauro MA, Weeks SM, Dixon RG, Jaques PF. Transcatheter thrombolytic therapy for acute mesenteric and portal vein thrombosis. *J Vasc Interv Radiol.* 2005 May;16(5):651-61.

16. Sharma S, Texeira A, Texeira P, Elias E, Wilde J, Olliff SP. Pharmacological thrombolysis in Budd Chiari syndrome: a single centre experience and review of the literature. *J Hepatol.* 2004 Jan; 40(1):172-80.
17. Blum U, Haag K, Rossle M, Ochs A, Gabelmann A, Boos S, et al. Noncavernomatous portal vein thrombosis in hepatic cirrhosis: treatment with transjugular intrahepatic portosystemic shunt and local thrombolysis. *Radiology.* 1995 Apr;195(1):153-7.
18. Nolte W, Figulla R, Ringe B, Wiltfang J, Munke H, Hartmann H, et al. [TIPSS in the Budd-Chiari syndrome with portal vein thrombosis]. *Dtsch Med Wochenschr.* 1997 Jan 31;122(5):116-21.
19. Uflacker R. Applications of percutaneous mechanical thrombectomy in transjugular intrahepatic portosystemic shunt and portal vein thrombosis. *Tech Vasc Interv Radiol.* 2003 Mar;6(1):59-69.
20. Bogin V, Marcos A, Shaw-Stiffel T. Budd-Chiari syndrome: in evolution. *Eur J Gastroenterol Hepatol.* 2005 Jan;17(1):33-5.
21. Murad SD, Luong TK, Pattynama PM, Hansen BE, van Buuren HR, Janssen HL. Long-term outcome of a covered vs. uncovered transjugular intrahepatic portosystemic shunt in Budd-Chiari syndrome. *Liver Int.* 2008 Feb;28(2):249-56.
22. Murad SD, Valla DC, de Groen PC, Zeitoun G, Haagsma EB, Kuipers EJ, et al. Pathogenesis and treatment of Budd-Chiari syndrome combined with portal vein thrombosis. *Am J Gastroenterol.* 2006 Jan;101(1):83-90.
23. Senzolo M, Tibbals J, Cholongitas E, Triantos CK, Burroughs AK, Patch D. Transjugular intrahepatic portosystemic shunt for portal vein thrombosis with and without cavernous transformation. *Aliment Pharmacol Ther.* 2006 Mar 15;23(6):767-75.
24. Aytekin C, Boyvat F, Kurt A, Yologlu Z, Coskun M. Catheter-directed thrombolysis with transjugular access in portal vein thrombosis secondary to pancreatitis. *Eur J Radiol.* 2001 Aug;39(2):80-2.
25. Eapen CE, Velissaris D, Heydtmann M, Gunson B, Olliff S, Elias E. Favourable medium term outcome following hepatic vein recanalisation and/or transjugular intrahepatic portosystemic shunt for Budd Chiari syndrome. *Gut.* 2006 Jun;55(6):878-84.
26. Mahmoud AE, Helmy AS, Billingham L, Elias E. Poor prognosis and limited therapeutic options in patients with Budd-Chiari syndrome and portal venous system thrombosis. *Eur J Gastroenterol Hepatol.* 1997 May;9(5):485-9

# Chapter 7


---

## **Incidence and clinical outcome of symptomatic portal biliopathy in patients with non-cirrhotic non-malignant extrahepatic portal vein thrombosis**

MCW Spaander, J.Hoekstra, HR van Buuren, HLA Janssen

*Department of Gastroenterology and Hepatology, Erasmus MC University Medical Center  
Rotterdam, The Netherlands*

*Submitted*



## ABSTRACT

**Background:** Extrahepatic portal vein thrombosis (EPVT) has been associated with the appearance of biliary changes. Although biliary abnormalities, or portal biliopathy, can be detected in almost all patients with chronic EPVT, only a few patients become symptomatic. The aim of this study was to assess the incidence of symptomatic portal biliopathy in a large cohort of patients with a non- cirrhotic non- malignant EPVT and describe its clinical features and outcome.

**Methods:** From our cohort of consecutive patients with non-cirrhotic non- malignant EPVT, seen at our hospital from 1985 to 2010, we assessed all patients with overt clinical signs of cholestasis. These patients were reviewed to study the presentation, management and outcome of symptomatic portal biliopathy.

**Results:** From a total of 122 patients (37% males) with a median follow up of 5.5 years (range 0-59 years), 18 patients (15%) had signs of cholestasis. From these 18 patients, 10 patients were excluded because biliary abnormalities were absent. Eight (7%) patients met our criteria for symptomatic portal biliopathy. Median time between diagnosis of EPVT and the occurrence of symptomatic portal biliopathy was 3.5 years (range 0-38 years). ERCP revealed intra- and extrahepatic strictures with dominant stenoses in the extrahepatic bile duct. A total of 30 ERCP-procedures were performed in seven patients. ERCP was effective in four out of the other six patients. One (3%) ERCP-related complication (cholangitis) was reported.

**Conclusion:** In patients with non- cirrhotic EPVT symptomatic portal biliopathy is an infrequent problem. Both intra- and extrahepatic bile duct strictures are present. ERCP as first line treatment appears to be effective and safe in patients with symptomatic portal biliopathy.



## INTRODUCTION

In the absence of liver cirrhosis, thrombotic occlusion of the extrahepatic portal vein is the most common cause of portal hypertension (1). Especially in developing countries, extrahepatic portal vein thrombosis (EPVT) is frequently diagnosed in patients presenting with upper gastrointestinal bleeding or splenomegaly (2-3). In Europe, non-cirrhotic EPVT is less common but due to the widespread use of imaging techniques it is increasingly being recognized, specifically in asymptomatic patients (4). Although a cause for thrombosis is not always found, well-known risk factors for EPVT are local inflammation, such as pancreatitis, and systemic prothrombotic conditions such as myeloproliferative neoplasms and prothrombin disorders (5-6). Complete occlusion of the main portal vein inevitably leads to increased portal pressure causing portal hypertension (7). Development of gastroesophageal varices as a result of portal hypertension is considered the most important complication of EPVT. However, the severity of portal hypertension and its complications differs greatly between individual patients. In part, this is due to the compensatory effects of collateral vessels that develop in response to the portal vein obstruction (8). Generally, a network of these collaterals develops, often referred to as a portal cavernoma.

A less recognized complication associated with EPVT is portal biliopathy. This term denotes morphologic abnormalities of the biliary tree, most commonly the extrahepatic bile ducts, that are related to the presence of periportal and pericholedochal collaterals (9). Possible abnormalities are irregular, albeit smooth, strictures or segmental dilations. The cause of these changes has not been fully clarified but it has been postulated that direct compression of the bile ducts by the cavernoma plays an important role. (10) Although structural changes have been described in large percentage of patients with EPVT (11-12), the number of patients with symptomatic portal biliopathy is unknown. Few studies have described the prevalence and features of this group of patients. In this long-term follow-up study, we have evaluated the incidence and clinical outcome of patients with non-cirrhotic EPVT and symptomatic portal biliopathy.

## PATIENTS AND METHODS

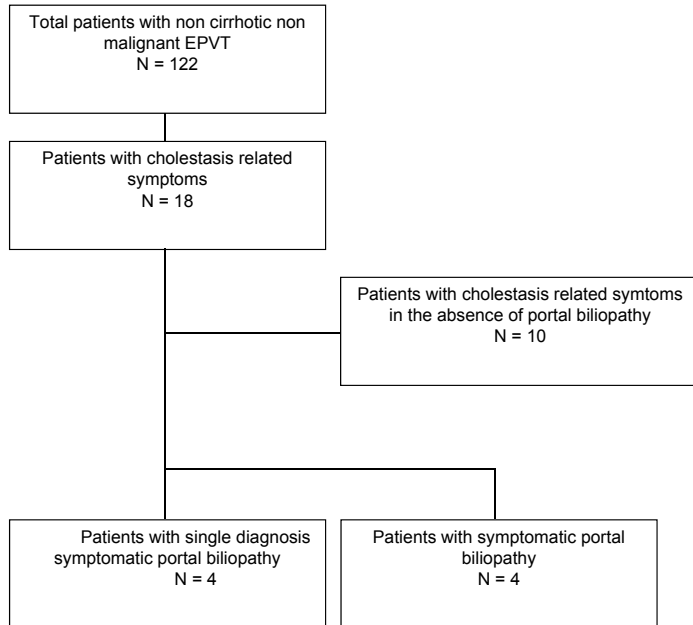
The study cohort consisted of patients with non-cirrhotic non-malignant EPVT that were seen at our tertiary referral center from January 1985 until April 2010. Patients with Budd-Chiari syndrome, patients with overt carcinoma or patients who had undergone a liver transplantation were excluded from the study. The diagnosis of EPVT was established by radiological imaging, such as Doppler ultrasonography, computed tomography, magnetic resonance imaging, and venography. Cirrhosis was excluded by

liver biopsy and/or a combination of radiological imaging and biochemical tests. EPVT was defined as chronic when hepatopetal collaterals or gastrointestinal varices were present. When these features were absent, the onset of EPVT was considered recent.

From this cohort, we assessed all patients with overt signs of cholestasis, defined as cholangitis (fever  $>38^{\circ}\text{C}$  with dilated bile ducts), jaundice (bilirubin  $>35$   $\mu\text{mol/l}$ ) and/or choledocholithiasis, either at the time EPVT was diagnosed or during follow-up. Portal biliopathy was diagnosed when cholangiographic abnormalities were documented with magnetic resonance cholangiography (MRCP) or endoscopic retrograde cholangiopancreatography (ERCP). These cholangiographic abnormalities included strictures, caliber irregularities, segmental dilatations, collaterals causing extra-luminal bile duct impression, and choledocholithiasis located above a stenosis and not associated with gallbladder stones (13-14). A patient was considered as having symptomatic portal biliopathy when one or more of these cholangiographic abnormalities was present together with signs of cholestasis (i.e. cholangitis, jaundice or choledocholithiasis). As a differential diagnosis between cholestasis caused by vascular bile duct injury and cholestasis resulting from other causes can be difficult, patients were divided into two groups based on whether or not additional causes of cholestasis were present. For each patient clinical data, treatment and outcome were extensively reviewed using standardized data forms.

## RESULTS

A total of 122 patients with EPVT were enrolled in the study cohort. Median age at diagnosis was 44 years (range 16- 87 years) and 45 cases (37%) were males. A recent thrombosis was diagnosed in 39 patients (32%), signs of chronic EPVT were present in 74 patients (61%) and in 9 patients (7%) the onset of the EPVT was not known. Median follow-up of the total cohort after diagnosis was 5.5 years (range 0.1-59 years). Eighteen patients (15%) had signs of cholestasis, either at diagnosis of EPVT or at some time during follow-up. Ten of these patients were subsequently excluded from the study as cholangiography did not show any abnormalities ( $n=9$ ) or because the biliary tree was not visualized ( $n=1$ ). (Figure 1) Underlying causes of cholestasis in these ten excluded patients were chronic pancreatitis ( $n=3$ ), cholecystectomy-related complications ( $n=2$ ), liver abscess ( $n=2$ ), drug-induced liver disease ( $n=2$ ), and choledocholithiasis ( $n=1$ ). Eight patients (7%) met our criteria for symptomatic portal biliopathy. Portal biliopathy was diagnosed on MRCP in one case whereas the other seven cases underwent ERCP. Baseline characteristics of the patients with symptomatic portal biliopathy are shown in Table 1. Four patients were diagnosed with symptomatic portal biliopathy without any additional cause of cholestasis. Median time between diagnosis of EPVT and the occurrence of symptomatic portal biliopathy was 3.5 years (range 0-38 years). Presenting



**Figure 1.** Diagram of patient selection

symptoms were increased cholestatic pattern of liver function tests (n=8), jaundice (n=5), right upper abdominal pain (n=3) and fever (n=1). A total of thirty ERCP-procedures were performed in seven patients with symptomatic portal biliopathy with a median of five ERCP-procedures per patient (range 1-8). In one patient ERCP was not performed as the symptoms of cholestasis were also related to a liver abscess, which was treated with radiological drainage (case 7). ERCP revealed a dominant stenosis in the proximal or middle part of the common bile duct (CBD) in all four patients that did not have an additional cholestasis-related factors.(figure 2) In the four patients with symptomatic portal biliopathy in whom an additional cholestasis-related factor was present the dominant stenosis was mostly located in the distal part of the CBD. (Table 1) Histology or cytology of the stenosis was performed in two patients and did not show any dysplastic cells. Seven patients with symptomatic portal biliopathy underwent a therapeutic ERCP, whereby cannulation of the CBD failed in one patient. The following therapeutic ERCP interventions were performed: sphincterotomy (n=3), balloon dilatation (n=9), placement of an endoprosthesis (plastic n=11 or metal n=1), placement of a nasobiliary drain (n=2) and a balloon trawl to extract debris and stones (n=2). Ursodeoxycholic acid was prescribed in three out of eight patients. In these three patients bile duct stones were present and they were treated with endoscopic extraction of the stones and ursodeoxycholic acid, which was effective in all cases. No bleedings from the biliary tree occurred during stone extraction.

**Table 1.** Baseline characteristics of patients with symptomatic portal biliopathy

nr	Age (years)	Sex	Location	Variceal thrombosis	Bleeding	Previous cholecystectomy	Bilirubin (mmol/L)	Alkaline phosphatase (U/L)	Findings of biliary imaging: site portal biliopathy	Findings of biliary imaging: site of dominant stenosis	Additional cholestasis-related factor
1	41	Female	pv and mv	no	no	yes	38	220	Extrahepatic	Proximal CBD	-
2	53	Male	pv	yes	yes	yes	-	324	Extrahepatic	Proximal CBD	-
3	40	Male	pv and mv	yes	yes	no	37	278	Intra- and extrahepatic	Proximal CBD	-
4	41	male	pv	yes	yes	no	132	1372	Intra- and extrahepatic	Mid CBD	-
5	45	male	pv and sv	no	no	yes	78	952	Extrahepatic	Mid and distal CBD	Chronic pancreatitis
6	49	male	pv	-	-	yes	-	223	Extrahepatic	Distal CBD	Post-cholecystectomy stenosis
7	47	female	Pv	no	no	yes	6	183	Intra- and extrahepatic	-	Intrahepatic choledocholithiasis
8	64	female	pv	no	no	no	82	259	Intra- and extrahepatic	Distal CBD	PSC and intrahepatic stones

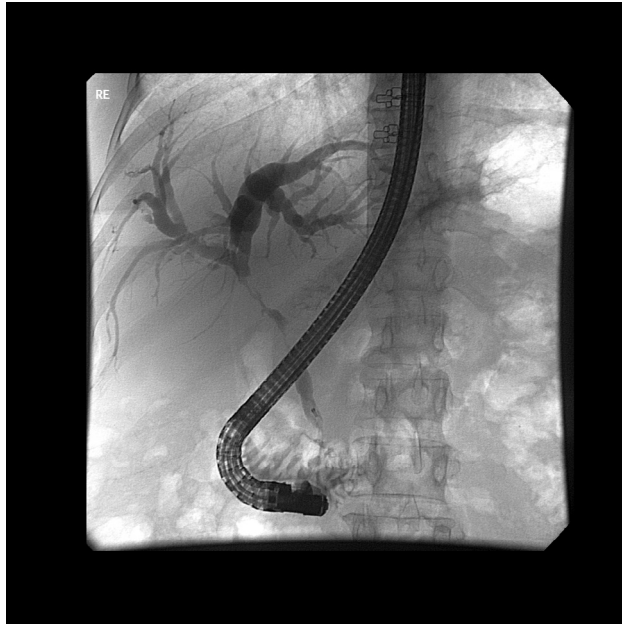**Abbreviations:**

pv: portal vein mv: mesenteric vein sv: splenic vein

CBD: common bile duct

PSC: primary sclerosing cholangitis

\* median  $\pm$  sd (range)



**Figure 2.** ERCP of case 1 showing a proximal CBD stenosis with dilatation of the biliary tree

Of the six patients in whom cannulation of the CBD was achieved, ERCP was successful in four cases. In these patients no episodes of cholangitis did occur and bilirubin remained normal. The two other patients continued to experience recurrent episodes of cholangitis despite repeated ERCP-procedures. One of these patients (case 5) subsequently underwent a biliary-digestive anastomosis. However, during the operation a hepaticojejunostomy could not be performed and the patient died two days later due to liver necrosis caused by an obstruction of the hepatic artery. The other patient (case 3) with a history of kidney transplantation could not be operated and eventually died resulting from ongoing cholangitis. The median symptom-free survival of the six patients successfully treated by ERCP was 7.5 years (0.4-14 years). Of the total of 30 ERCP-procedures, one (3%) ERCP-related complication (cholangitis) occurred.

## DISCUSSION

In this study we have evaluated the incidence and outcome of symptomatic portal biliopathy in a large cohort of consecutive patients with non-cirrhotic non-malignant EPVT. We found that symptomatic portal biliopathy was present in 7% of the cases. Therapeutic ERCP was the treatment modality of choice in almost all these patients. Although repeated ERCP procedures were often needed, it appeared to be safe and effective for most of our patients.

In patients with portal hypertension due to EPVT, collateral vessels will develop within the hepatoduodenal ligament and in the vascular plexus of the bile ducts. Dilatation of veins in the paracholedochal plexus and the epicholedochal venous plexus can subsequently cause bile duct compression. The resulting bile duct irregularities, described as portal biliopathy, are shown to be present in nearly all patients with chronic EPVT. (10-11,13) However, symptoms related to portal biliopathy are rarely seen and data on this topic are scarce. The incidence of symptomatic portal biliopathy differs in literature from 5-33%, due to marked differences between small selected study populations. (10, 13-17) It has been suggested that the incidence of symptomatic portal biliopathy is higher in developing countries compared to Western countries.(18) However, our incidence of 7% concurs with a large Indian cohort study which reported an incidence of symptomatic portal biliopathy in 4% of the patients with EPVT.(19) Symptomatic portal biliopathy thus remains a rare complication in patients with EPVT and screening for this disorder does not seem useful. Still, due to a better control of gastrointestinal bleeding and recurrent thrombotic events, the outcome of chronic EPVT has improved over the last ten years.(11) As portal biliopathy is mostly seen in patients with presumably long-standing EPVT, an improved prognosis can potentially lead to an increase in late EPVT-related complications, such as portal biliopathy. (10, 13)

Choledocholithiasis associated with portal biliopathy has previously been characterized by three specific features: 1) bile duct stones are located proximal of the stenosis, 2) they are not associated with gallbladder stones and 3) they are of the pigment type. (10, 20) Three patients in our cohort had choledocholithiasis, in the absence of gallbladder stones, and the bile duct stones were located in the dilated portion of the bile duct, proximal of the stenosis. All three patients were successfully treated with ERCP. As ursodeoxycholic acid is effective in controlling cholestasis-related symptoms and intrahepatic stones (21), this was prescribed in these patients with no recurrence of biliary symptoms. In concordance with Bhatia *et al*, who performed ERCP-procedures with sfincterotomy for portal biliopathy-induced choledocholithiasis, we also found a low ERCP-related complication rate and no bleedings.(20) Our results support the treatment algorithm proposed by Chandra *et al.*, where endoscopic treatment should be considered as the first line treatment for stone extraction or dilatation with or without stent insertion. (22) In those cases where biliary drainage by endoscopic and radiological approach is not successful portal biliopathy remains a challenging problem (20, 23). For the second-line treatment of symptomatic portal biliopathy, a portosystemic shunt, if feasible, should be considered. It is, however, questionable if this treatment is successful for patients with a dominant biliary stenosis unrelated to the present portal biliopathy. Another option is a biliary-intestinal bypass, however this type of surgery is accompanied with a high risk of morbidity in the setting of portal hypertension (24-25), as shown in our patient.

Therefore, this surgical intervention should only be considered in those cases where other treatment modalities have failed. (10, 22)

In conclusion, in patients with non-cirrhotic non-malignant EPVT, symptomatic portal biliopathy is an uncommon complication of portal hypertension, occurring in less than 10% of the cases. When present, ERCP appeared to be an effective and safe first-line treatment modality. Larger series of patients will be required to determine the true complication rate of ERCP-procedures for portal biliopathy.

## REFERENCES

1. Belli L, Romani F, Riolo F, Rondinara G, Aseni P, Di Stefano M, et al. Thrombosis of portal vein in absence of hepatic disease. *Surgery, gynecology & obstetrics*. 1989 Jul;169(1):46-9.
2. Sarin SK, Sollano JD, Chawla YK, Amarapurkar D, Hamid S, Hashizume M, et al. Consensus on extra-hepatic portal vein obstruction. *Liver Int*. 2006 Jun;26(5):512-9.
3. Anand CS, Tandon BN, Nundy S. The causes, management and outcome of upper gastrointestinal haemorrhage in an Indian hospital. *Br J Surg*. 1983 Apr;70(4):209-11.
4. Condat B, Pessione F, Helene Denninger M, Hillaire S, Valla D. Recent portal or mesenteric venous thrombosis: increased recognition and frequent recanalization on anticoagulant therapy. *Hepatology* (Baltimore, Md. 2000 Sep;32(3):466-70.
5. Valla D, Casadevall N, Huisse MG, Tulliez M, Grange JD, Muller O, et al. Etiology of portal vein thrombosis in adults. A prospective evaluation of primary myeloproliferative disorders. *Gastroenterology*. 1988 Apr;94(4):1063-9.
6. Janssen HL, Meinardi JR, Vlegaar FP, van Uum SH, Haagsma EB, van Der Meer FJ, et al. Factor V Leiden mutation, prothrombin gene mutation, and deficiencies in coagulation inhibitors associated with Budd-Chiari syndrome and portal vein thrombosis: results of a case-control study. *Blood*. 2000 Oct 1;96(7):2364-8.
7. Bernades P, Baetz A, Levy P, Belghiti J, Menu Y, Fekete F. Splenic and portal venous obstruction in chronic pancreatitis. A prospective longitudinal study of a medical-surgical series of 266 patients. *Digestive diseases and sciences*. 1992 Mar;37(3):340-6.
8. Lebrech D, Bataille C, Bercoff E, Valla D. Hemodynamic changes in patients with portal venous obstruction. *Hepatology* (Baltimore, Md. 1983 Jul-Aug;3(4):550-3.
9. Ohnishi K, Okuda K, Ohtsuki T, Nakayama T, Hiyama Y, Iwama S, et al. Formation of hilar collaterals or cavernous transformation after portal vein obstruction by hepatocellular carcinoma. Observations in ten patients. *Gastroenterology*. 1984 Nov;87(5):1150-3.
10. Condat B, Vilgrain V, Asselah T, O'Toole D, Rufat P, Zappa M, et al. Portal cavernoma-associated cholangiopathy: a clinical and MR cholangiography coupled with MR portography imaging study. *Hepatology*. 2003 Jun;37(6):1302-8.
11. Khuroo MS, Yattoo GN, Zargar SA, Javid G, Dar MY, Khan BA, et al. Biliary abnormalities associated with extrahepatic portal venous obstruction. *Hepatology* (Baltimore, Md. 1993 May;17(5):807-13.
12. Dhiman RK, Puri P, Chawla Y, Minz M, Bapuraj JR, Gupta S, et al. Biliary changes in extrahepatic portal venous obstruction: compression by collaterals or ischemic? *Gastrointestinal endoscopy*. 1999 Nov;50(5):646-52.
13. Nagi B, Kochhar R, Bhasin D, Singh K. Cholangiopathy in extrahepatic portal venous obstruction. Radiological appearances. *Acta Radiol*. 2000 Nov;41(6):612-5.
14. Malkan GH, Bhatia SJ, Bashir K, Khemani R, Abraham P, Gandhi MS, et al. Cholangiopathy associated with portal hypertension: diagnostic evaluation and clinical implications. *Gastrointestinal endoscopy*. 1999 Mar;49(3 Pt 1):344-8.
15. Dilawari JB, Chawla YK. Pseudosclerosing cholangitis in extrahepatic portal venous obstruction. *Gut*. 1992 Feb;33(2):272-6.
16. Palazzo L, Hochain P, Helmer C, Cuillerier E, Landi B, Roseau G, et al. Biliary varices on endoscopic ultrasonography: clinical presentation and outcome. *Endoscopy*. 2000 Jul;32(7):520-4.
17. Vibert E, Azoulay D, Aloia T, Pascal G, Veilhan LA, Adam R, et al. Therapeutic strategies in symptomatic portal biliopathy. *Ann Surg*. 2007 Jul;246(1):97-104.



18. Oo YH, Olliff S, Haydon G, Thorburn D. Symptomatic portal biliopathy: a single centre experience from the UK. *Eur J Gastroenterol Hepatol*. 2009 Feb;21(2):206-13.
19. Chaudhary A, Dhar P, Sarin SK, Sachdev A, Agarwal AK, Vij JC, et al. Bile duct obstruction due to portal biliopathy in extrahepatic portal hypertension: surgical management. *Br J Surg*. 1998 Mar; 85(3):326-9.
20. Bhatia V, Jain AK, Sarin SK. Choledocholithiasis associated with portal biliopathy in patients with extrahepatic portal vein obstruction: management with endoscopic sphincterotomy. *Gastrointest Endosc*. 1995 Aug;42(2):178-81.
21. Rosmorduc O, Hermelin B, Poupon R. MDR3 gene defect in adults with symptomatic intrahepatic and gallbladder cholesterol cholelithiasis. *Gastroenterology*. 2001 May;120(6):1459-67.
22. Chandra R, Kapoor D, Tharakan A, Chaudhary A, Sarin SK. Portal biliopathy. *J Gastroenterol Hepatol*. 2001 Oct;16(10):1086-92.
23. De Franchis R. Revising consensus in portal hypertension. Report of the Baveno V Consensus Workshop on methodology of diagnosis and therapy in portal hypertension. *J Hepatol*. 2010.
24. Khare R, Sikora SS, Srikanth G, Choudhuri G, Saraswat VA, Kumar A, et al. Extrahepatic portal venous obstruction and obstructive jaundice: approach to management. *Journal of gastroenterology and hepatology*. 2005 Jan;20(1):56-61.
25. Mork H, Weber P, Schmidt H, Goerig RM, Scheurlen M. Cavernous transformation of the portal vein associated with common bile duct strictures: report of two cases. *Gastrointestinal endoscopy*. 1998 Jan;47(1):79-83.




# Chapter 8

---

**Summary and discussion**

**Samenvatting en discussie**





## SUMMARY AND DISCUSSION

This thesis focused on patients with non-cirrhotic non-malignant extrahepatic portal vein thrombosis (EPVT). EPVT is defined as obstruction of the extrahepatic portal vein with or without involvement of the intrahepatic portal veins and does not include isolated thrombosis of splenic or superior mesenteric vein. Clinical presentation depends on the onset of the thrombosis. The typical presentation of a recent thrombosis is with abdominal pain. Fever and ascites, usually in small quantities and of transient character, may also be present. Chronic EPVT most frequently presents with problems related to portal hypertension, including gastrointestinal bleeding, splenomegaly and ascites. For most patients, in whom EPVT is suspected, diagnosis can be established by non-invasive imaging techniques, including ultrasonography, CT-scan and MRI. Once EPVT has been diagnosed, the cause of EPVT should be elucidated. Local risk factors are mainly infectious and inflammatory diseases, but also abdominal trauma and surgery can cause EPVT. Systemic risk factors are acquired or inherited prothrombotic disorders. Over the last decade significant advances have been made in identifying prothrombotic predispositions in patients with thrombosis. By JAK2 mutation screening more evidence can be obtained for the presence of a latent or overt MPD as underlying cause of EPVT. The treatment goal of EPVT can be divided into two broad aims: (i) to reverse or to prevent recurrence or extension of thrombosis within the portal venous system and (ii) to treat the portal hypertension complications of chronic EPVT.

In **chapter 2** we give a general overview of management of non-cirrhotic non-malignant EPVT patients and the concurrent portal hypertension complications. Esophagogastric variceal bleeding is the most important complication of chronic EPVT. In one fourth of the EPVT patients variceal bleeding is the presenting symptom. Endoscopic treatment is the first line intervention in patients with bleeding esophagogastric varices. In contrast to endoscopic treatment of variceal bleeding in patients with cirrhosis, little is known about the outcome of this treatment in adult patients with non-cirrhotic EPVT. In **chapter 3** we describe that patients with variceal bleeding had a rebleeding rate of 23% after the first year and this rate decreased over time with maintained endoscopic follow-up. The presence of fundal varices and extension of thrombosis into the splenic vein were predictors of variceal rebleeding. In contrast to patients with cirrhosis mortality was not determined by variceal (re)bleeding or endoscopic treatment complications.

A second phenomenon of portal hypertension is ascites. In contrast to patients with cirrhosis, where ascites is a poor prognostic feature, little is known of ascites in non-cirrhotic non-malignant patients with EPVT. In **chapter 4** we described that in approximately a quarter of the patients ascites was present at the time EPVT was diagnosed. Most of these patients were patients with chronic EPVT. Seventy-five percent of these

patients were at risk for a second episode of ascites. In contrast to the literature, we did not find a correlation between the presence of ascites and gastrointestinal hemorrhage, renal insufficiency, sepsis or surgery. Also other causes that could clarify the presence of ascites, such as liver failure or low osmotic pressure, appeared unlikely, because all patients lacked any evidence of cirrhosis. It is known that the onset of ascites in patients with a history of thrombotic disease should heighten the clinical suspicion of mesenteric venous thrombosis. However, we found no correlation between the extension of the thrombus towards the superior mesenteric vein and the presence of ascites. We also found a remarkably high mortality rate in patients with ascites compared to patients without ascites at diagnosis.

The role of anticoagulation therapy in patients with EPVT is ambiguous. It is nowadays recommended to start anticoagulation therapy for patients with a recent EPVT to recanalize the portal vein and prevent extension of the thrombosis into the splanchnic veins. Considerably more controversy has surrounded the role of anticoagulants in patients with chronic EPVT. The reason to start anticoagulation therapy in these patients is to prevent new thrombotic events or extension of the thrombosis into the splanchnic veins in patients with a prothrombotic disorder. In **chapter 5** we found that patients with a prothrombotic disorder were prone to develop extension of thrombosis into the splanchnic veins and in 20% of these patients a new thrombotic event occurred, which was significantly associated with decreased survival. Although anticoagulation decreased new thrombotic events, it significantly increased the risk of gastrointestinal bleeding. The severity of the bleeding was not affected by the use of anticoagulants. Gastrointestinal bleeding and anticoagulants use had both their effect on survival, but not statistically significant. By identifying predictive factors on the occurrence of a gastrointestinal bleeding as varices size, previous gastrointestinal bleeding, extended thrombosis and ascites together with the indication of anticoagulation therapy, a patient-based treatment strategy can be made.

Another treatment modality to recanalize the portal vein in patients with EPVT is thrombolysis. In the last decade we have performed transcatheter local thrombolytic therapy in patients with recent EPVT. In **chapter 6** we assessed all patients, who underwent this procedure in our center. A total of 12 patients were included of whom six patients had additional thrombosis of the hepatic veins (Budd- Chiari Syndrome) and two patients had cirrhosis. In three patients transcatheter local thrombolytic therapy was successful, in four patients the flow was restored in some vessels, but not all and in five patients no lysis was obtained in any of the occluded vessels. Fifty percent of the patients developed major procedure related bleeding with fatal outcome in two. This high complication rate makes this therapy unattractive and it should only be performed in patients with progressive thrombosis or clinical deterioration, where other treatment modalities as anticoagulants and TIPS placement have failed.

In almost all patients with chronic EPVT biliary abnormalities can be found on radiological imaging. In only a few patients this will lead to symptomatic manifestations. Data on this topic are scarce. In **chapter 7** we assessed all patients with symptomatic biliary symptoms, either at the time of EPVT diagnosis or during follow up. During a median follow up of 5.5 years we found that 18 (15%) patients had signs of cholestasis related symptoms and 8 (7%) patients had symptomatic portal biliopathy. ERCP showed a stenosis in the proximal or mid CBD stenosis in all patients with a single diagnosed symptomatic portal biliopathy. Although repeated ERCP procedures per patient are necessary, ERCP as first line treatment seemed to be safe and successful in most patients with symptomatic portal biliopathy.





## SAMENVATTING EN DISCUSSIE

Dit proefschrift richt zich op patiënten met een extrahepatische vena porta trombose (EPVT), waarbij er geen sprake is van levercirrose of maligniteit. Extrahepatische vena porta trombose wordt gedefinieerd als een obstructie van de extrahepatische vena porta met of zonder uitbreiding naar de intrahepatisch gelegen portale venen en omvat niet een geïsoleerde trombose van de vena lienalis of vena mesenterica superior. De symptomen zijn afhankelijk van de duur van de trombose. De klassieke presentatie van een acute EPVT gaat gepaard met buikpijn. Daarbij kunnen ook koorts en ascites aanwezig zijn. De ascites is meestal gering en van voorbijgaande aard. De symptomen van een chronische EPVT zijn gerelateerd aan de door portale hypertensie ontstane complicaties, zoals gastro-intestinale bloedingen, miltvergroting en ascites. Bij de meeste patiënten bij wie EPVT vermoed wordt kan de diagnose gesteld worden door middel van niet-invasieve beeldvorming, zoals echo, CT-scan en MRI. Zodra de diagnose EPVT vastgesteld is, is het zaak de oorzaak van de EPVT op te sporen. Locale factoren, die tot EPVT kunnen leiden, zijn vooral lokale infecties en inflammatoire darmziekten, maar ook een buiktrauma of een operatieve ingreep kunnen de oorzaak zijn van EPVT. Systemische ziekten, die tot EPVT leiden, zijn verworven of erfelijke protrombotische ziekten. In de laatste tien jaar zijn er aanzienlijke vorderingen gemaakt ten aanzien van het opsporen van genetische varianten, die leiden tot een verhoogd trombose risico bij patiënten met een doorgemaakte trombose. Door screening op een JAK2 mutatie kan een latente of reeds aanwezige myeloproliferatieve ziekte als onderliggende oorzaak van EPVT aangetoond worden.

De behandeling van een acute EPVT is erop gericht om de trombose in het portale systeem op te lossen en een recidief te voorkomen. Bij chronische EPVT is de behandeling erop gericht de complicaties van de portale hypertensie te bestrijden.

In **Hoofdstuk 2** wordt een overzicht gegeven van de behandeling van patiënten met een EPVT en de hiermee samenhangende complicaties van portale hypertensie. Gastro-intestinale bloedingen zijn de belangrijkste complicatie bij patiënten met een chronische EPVT.

In een kwart van de patiënten is een varix bloeding de eerste uiting van chronische EPVT. Endoscopische behandeling is dan de behandeling van keuze. In tegenstelling tot patiënten met levercirrose is er weinig bekend over het effect van endoscopische behandeling van varices bloedingen bij volwassen patiënten met EPVT zonder levercirrose. In **Hoofdstuk 3** beschrijven we dat 23% van de patiënten met een varix bloeding na één jaar een tweede bloeding heeft gehad, waarbij de kans op een nieuwe bloeding met de tijd afnam. Factoren, die gepaard gingen met een verhoogd risico op recidiefbloedingen waren de aanwezigheid van varices in de maag en uitbreiding van de trombose in de vena lienalis. In tegenstelling tot patiënten met levercirrose, bij wie een

varix bloeding gepaard gaat met een hoge mortaliteit, vonden we bij patiënten zonder levercirrose geen relatie tussen (recidief) bloeding, complicaties van de endoscopische behandeling en het overlijden van de patiënt.

Een tweede kenmerk van portale hypertensie is ascites. In tegenstelling tot patiënten met levercirrose, waarbij ascites een slechte prognostische factor is, is er weinig bekend over ascites bij patiënten met EPVT. In **Hoofdstuk 4** beschrijven we dat in ongeveer een kwart van de patiënten ascites aanwezig was op het moment dat de diagnose EPVT gesteld werd. Het merendeel van deze patiënten had een chronische EPVT. Vijfenzeventig procent van deze patiënten ontwikkelde opnieuw ascites. In tegenstelling tot de literatuur vonden we geen correlatie tussen de aanwezigheid van ascites en gastro-intestinale bloedingen, nierinsufficiëntie, sepsis of status na een operatie. Ook andere oorzaken die de ascites zouden kunnen verklaren, zoals leverfalen of lage osmotische druk, leken onwaarschijnlijk omdat er bij geen van de patiënten aanwijzingen waren voor levercirrose. Het is bekend dat bij patiënten met een verhoogde tromboseneiging en ascites er een aanzienlijke kans is dat er sprake is van een mesenteriaal trombose. Daarentegen vonden wij geen correlatie tussen de uitbreiding van de trombose naar de vena mesenterica superior en de aanwezigheid van ascites. Tevens vonden wij een opmerkelijk hoge sterfte bij patiënten met ascites vergeleken met patiënten zonder ascites ten tijde van het stellen van de diagnose.

De rol van antistolling bij patiënten met EPVT is niet eensluidend. In de huidige richtlijnen wordt aanbevolen antistolling te starten bij patiënten met een acute EPVT met als doel de vena porta te rekanaliseren en uitbreiding van de trombose naar de darmvenen te voorkomen. De rol van het gebruik van antistolling bij patiënten met een chronische EPVT is aanzienlijk meer omstrepen en lijkt met name weggelegd voor patiënten met een protrombotische ziekte om te voorkomen dat een nieuwe trombose ontstaat of dat er uitbreiding van de trombose naar de darmvenen plaatsvindt. In **Hoofdstuk 5** laten we zien dat patiënten met een protrombotische ziekte een verhoogde kans hadden op uitbreiding van de trombose naar de darmvenen en dat 20% van deze patiënten een nieuwe trombose ontwikkelde, hetgeen significant geassocieerd was met een verkorte levensduur. Hoewel antistolling de kans op een nieuwe trombose verminderde was er een significant verhoogde kans op het krijgen van een gastro-intestinale bloeding. Het gebruik van antistolling had geen invloed op de ernst van de bloeding. Gastro-intestinale bloedingen en het gebruik van antistolling hadden beiden invloed op de overleving maar waren niet statistisch significant. Door factoren, die gepaard gaan met een verhoogd risico op gastro-intestinale bloedingen, op te sporen, zoals de grootte van de varices, eerdere gastro-intestinale bloedingen, uitgebreide trombose en ascites, en deze af te zetten tegen de indicatie voor antistolling kan een geïndividualiseerde behandelstrategie opgesteld worden.

Een andere behandelmethode bij patiënten met acute EPVT, om de vena porta te rekanaliseren is trombolysie. In de laatste tien jaar werd lokale trombolysie verricht bij patiënten met recente EPVT. In **Hoofdstuk 6** hebben we alle patiënten geanalyseerd die deze procedure in ons centrum hebben ondergaan. Twaalf patiënten werden in de analyse opgenomen waarvan zes patiënten een trombose van de venae hepaticae hadden (Budd- Chiari Syndroom) en twee patiënten levercirrose. Bij drie patiënten was deze lokale behandeling met trombolysie succesvol, in vier patiënten werd de bloedstroom in enkele vaten hersteld maar niet in alle en in vijf patiënten werd geen effect gezien. Vijftig procent van de patiënten kreeg een aan de procedure gerelateerde grote bloeding met bij twee patiënten een fatale afloop. Dit hoge complicatie risico maakt dat deze therapie slechts in uiterste omstandigheden te overwegen is als alle andere therapie modaliteiten geen effect gehad hebben en er sprake is van uitbreiding van de trombose of klinische verslechtering.

Bij bijna alle patiënten met chronische EPVT kunnen bij radiologisch onderzoek afwijkingen aan de galwegen gevonden worden. Bij slechts weinig patiënten geeft dit aanleiding tot symptomen. Data hierover zijn schaars. In **Hoofdstuk 7** hebben we alle patiënten geanalyseerd met symptomatische galweg klachten, hetzij ten tijde van de diagnose EPVT , hetzij tijdens de follow-up. We vonden dat gedurende een mediane follow-up van 5,5 jaar 18 (15%) patiënten cholestase gerelateerde symptomen hadden en 8 (7%) patiënten hadden symptomatische portale biliopathie. Bij patiënten met een symptomatische portale biliopathie zonder andere cholestase gerelateerde factoren, werd bij ERCP een stenose gevonden in het proximale of middelste deel van de ductus choledochus communis. Hoewel er meerdere ERCP's per patiënt nodig zijn, lijkt deze eerste keus behandeling effectief en veilig.




# Chapter 9

---

**Publications**

**Dankwoord**

**Curriculum vitae**





## PUBLICATIONS

A Huitema, MCW Spaander, S Rodenhuis, JH Beijnen. Relationship between exposure and toxicity in high dose chemotherapy with cyclophosphamide, thiotepa and carboplatin. *Ann Oncol*. 2002 Mar;13(3):374-84.

MCW Spaander, HR van Buuren, HLA Janssen. Non-cirrhotic non-malignant portal vein thrombosis: a review on the management of non-cirrhotic non-malignant portal vein thrombosis and the concurrent portal hypertension complications in adults. *Aliment Pharmacol Ther*. 2007 Dec;26 Suppl 2:203-9.

MCW Spaander, S Darwish Murad, HR van Buuren, BE Hansen, EJ Kuipers, HLA Janssen. Endoscopic treatment of esophagogastric variceal bleeding in patients with non-cirrhotic extra hepatic portal vein thrombosis: A long term follow-up study. *Gastrointest Endosc*. 2008 Jan 16 vol 67;6 821-27.

JH Smalberg MCW Spaander, KSG Jie, PMT Pattynama, HR van Buuren, B van den Berg, HLA Janssen, FWG Leebeek. Risks and Benefits of Transcatheter Thrombolytic Therapy in Patients with Splanchnic Venous Thrombosis. *Thrombosis and Haemostasis* 2008 Dec;100(6):1084-8.

RC van den Bergh, T Wolters, MC Spaander, FH Schröder, GJ van Leenders. Non-prostatic pathology on prostate needle-biopsy - colorectal carcinoid: a case report. *Cases J*. 2009 Jan 21;2(1):75.

MJ Uitdehaag, PD Siersema, MCW Spaander, FP Vleggaar, EML Verschuur, EW Steyerberg, EJ Kuipers. A fully covered stent with anti-migration properties for the palliation of malignant dysphagia: a prospective cohort study. *Gastrointest Endosc*. 2010 Mar;71(3):600-5.

NCM van Heel, J Haringsma, MCW. Spaander, EJ Kuipers. Short term esophageal stenting in the management of benign perforations. *Am J Gastroenterol*. 2010 Jul;105(7):1515-20.

BA Grotenhuis, P van Hagen, BP Wijnhoven, MC Spaander, HW Tilanus, J van Lanschot. Delay in Diagnostic Workup and Treatment of Esophageal Cancer. *J Gastrointest Surg*. 2010 Mar;14(3):476-83.

NC van Heel, J Haringsma, MC Spaander, MJ Bruno, EJ Kuipers. Esophageal stents for the relief of malignant dysphagia due to extrinsic compression. *Endoscopy*. 2010 Juli 42(7): 536- 540.

NC van Heel, J Haringsma, MC Spaander, P Didden, MJ Bruno, EJ Kuipers. Esophageal stents for the palliation of malignant dysphagia and fistula recurrence after esophagectomy. *Gastrointest Endosc*. 2010 Aug 72(2): 249- 254.

MC Spaander, HR van Buuren, BE Hansen, HL Janssen. Ascites in patients with non-cirrhotic non-malignant extrahepatic portal vein thrombosis. *Aliment Pharmacol Ther*. 2010 Aug 32(4): 529-534.



## DANKWOORD

Deze pagina biedt mij de gelegenheid om een woord van dank uit te spreken, voor allen die ieder op zijn of haar manier bereid is geweest om een bijdrage te leveren aan de totstandkoming van dit boek. Een aantal personen in het bijzonder.

Allereerst wil ik mijn promotor prof. dr. H.L.A. Janssen bedanken. Beste Harry, in de loop van mijn promotietraject heeft onze relatie een aantal veranderingen ondergaan. Van co-promotor werd jij mijn promotor, van arts-assistent werd ik jouw collega. Deze veranderingen hebben echter nooit ons doel in de weg gestaan. Door jouw wetenschappelijke interesse, inzet en perfectionisme leerde je mij wetenschap bedrijven. Ondanks je drukke programma had je tijd en vertrouwen om dit boek tot een goed eind te brengen. Dank hiervoor. Marion Hoogendoorn bedankt voor al het regelwerk in de aanloop tot deze promotie.

Dr. B.E. Hansen: beste Bettina, dank voor je hulp met betrekking tot de statistiek van mijn artikelen. Ik heb erg genoten van onze afspraken. Je had altijd tijd en nam de moeite om je te verdiepen in mijn onderwerpen. Daarnaast was het erg gezellig en vond ik steun door samen de laatste fase van ons promotietraject te doorlopen.

Dr. H.R. van Buuren: beste Henk, dank voor je betrokkenheid. Je frisse kijk op mijn artikelen zowel vanuit klinisch, wetenschappelijk als tekstueel oogpunt was een enorme toevoeging.

Prof.dr. E.J. Kuipers: beste Ernst, als aanstichter van dit promotietraject wil ik je bedanken voor de mogelijkheid hiertoe. Ondanks dat we het over het onderwerp van mijn promotie nog wel eens kunnen hebben, wil ik je bedanken voor de ruimte die je me hebt geboden om mijn promotie tot een goed einde te brengen.

Prof.dr. F.W.G. Leebeek en prof.dr. H.W. Tilanus dank voor het goedkeuren van mijn manuscript en jullie deelname in de promotiecommissie.

Prof.dr. C.J.J. Mulder en prof.dr. P.D. Siersema, dank voor jullie deelname in de promotiecommissie.

Mijn collega's: beste collega's graag wil ik jullie bedanken voor de tijd en ondersteuning waar nodig. Janneke dank voor al je wijze adviezen.

Nathalie: lieve Nath, als ervaringsdeskundige en als vriendin vind ik het heerlijk dat je mijn paranimf bent. Jouw interesse in de ander, jouw kijk op het leven en je gevatte opmerkingen en humor zijn elke keer weer een genot om naar te luisteren.

Jarcine: lieve Jar, ondanks al de drukte op je werk, wilde jij mijn paranimf zijn, dankjewel. Naast jouw organisatorisch en ondernemend talent, heb je een ruime interesse, luisterend oor en heel veel geduld. Heerlijk om jou als mijn paranimf te hebben, maar bovenal dat je mijn zusje bent.

Ouders: lieve papa en mama, dank voor jullie steun, liefde en vertrouwen. Pap, dank voor de middagen sparren, je opmerkingen en correcties. Mam dank voor je luisterend oor en wijze adviezen. En dank voor het opvangen van Valentijn en bijdrage in al onze logistieke beslommering. Dit geldt ook voor Paul en Miranda. Lieve Paul en Miranda, dank voor jullie begrip, inzet en hulp.

Fianne: lieve Fitje, jouw enthousiasme, passie voor eten en koken en het gezellig bijkletsen, zorgden voor een heerlijke afleiding in drukke tijden. Blij dat jij mijn zusje bent.

Alle vrienden en familie en in het bijzonder: Nathalie Kuipers, Iris, Marlies, Leonieke, Sarwa, Jilling, Krista, Bram, Monique, Arthur (dank voor je hulp bij de stellingen), Mechtild, Marc, Rachel, Swiebo, Ellen, Alex, Ilse en Valentijn. Dank dat jullie er waren en zijn. Jullie vervullen een groot en belangrijk deel van mijn/ ons leven en hoop nog lang van jullie te mogen genieten.

Ronald: lieverd, elke dag geniet ik dat jij in mijn leven bent gestapt, elke dag geniet ik van jouw aanwezigheid, je kijk op dingen, je eigengereidheid, je vertrouwen en je steun. Dank voor je hulp ten aanzien van de lay-out en het behouden van overzicht, maar vooral dank dat je er onvoorwaardelijk voor me bent.

## CURRICULUM VITAE

De auteur van dit proefschrift werd geboren op 24 december 1972 te Amsterdam. Na het behalen van haar eindexamen aan het Stedelijk Gymnasium te Haarlem, startte ze in september 1991 met de studie geneeskunde aan de Universiteit van Amsterdam. Na een wetenschappelijke stage van vier maanden aan de Universidad de Navarra in Pamplona, Spanje, behaalde ze in mei 1996 haar doctoraal examen. Na het behalen van haar arts- examen in oktober 1998, was ze werkzaam als arts- assistent op de afdeling interne geneeskunde van het toenmalige Andreas ziekenhuis in Amsterdam. Gezien haar interesse in de oncologie, verruilde zij deze baan voor een plek in het Antonie van Leeuwenhoek ziekenhuis te Amsterdam. Vanaf augustus 1999 tot november 2000 was ze werkzaam als arts-assistent op de afdeling medische oncologie en verrichtte ze naast het klinisch werk, wetenschappelijk onderzoek naar de farmacodynamiek van hoge dosis chemotherapie en de gastro-intestinale toxiciteit van intra- arteriële chemotherapie. In januari 2001 startte ze met de (voor)opleiding tot internist in het toenmalige Rode Kruis ziekenhuis in Den Haag (opleider dr. R.M. Valentijn). Tijdens deze vooropleiding werd haar interesse gewekt voor de maag- darm- leverziekte. In januari 2005 resulteerde dit in het starten van de opleiding tot maag- darm- leverarts in het Erasmus Medisch Centrum te Rotterdam (opleiders prof. dr. E.J. Kuipers en dr. R.A. de Man). En daarmee de start van dit proefschrift (onder begeleiding van prof. dr. H.L.A. Janssen). Zij is sinds januari 2008 werkzaam als stafid op de maag- darm- leverafdeling in het Erasmus Medisch Centrum te Rotterdam met als aandachtsgebied de gastro-intestinale oncologie. Zij woont samen met Ronald van den Mosselaar in Rotterdam en zij hebben een heerlijke zoon van bijna 2 jaar, Valentijn.

“Want zij die bijvoorbeeld een proefschrift schrijven, dat immers alleen bestemd is om aan het oordeel van enige professoren te worden onderworpen, en die dus de strengste en meest deskundige critici niet vrezen, zijn, dunkt me, meer te beklagen dan te benijden, daar ze zich eindeloos aftobben. Ze voegen toe, veranderen, schrappen, herstellen weer, herzien, werken het geheel en al om, laten het graag anderen zien, houden het negen jaar in portefeuille en zijn nooit tevreden met het resultaat. De beloning, die ze er tenslotte voor krijgen – immers de lof van een enkeling – is wel heel duur betaald met al dat zwoegen, zweten en gebrek aan het zoetste, wat er bestaat: de slaap. Voeg hierbij nog dat dit alles ten koste gaat van hun gezondheid, dat ze daardoor humeurig, lelijk, bijziende of zelfs blind worden, tot armoede vervallen, bij een ieder uit de gunst zijn, dat ze alle genoegens moeten verzaken, dat ze voor hun tijd oud zijn, ontijdig sterven en wat dies meer zij”

Desiderius Erasmus, uit: Lof der Zotheid, 1515