

# PEDIATRICS®

OFFICIAL JOURNAL OF THE AMERICAN ACADEMY OF PEDIATRICS

## **Congenital Diaphragmatic Hernia and Situs Inversus Totalis**

Coranne D. Tesselaar, Roelf R. Postema, Marieke F. van Dooren, Karel Allegaert and  
Dick Tibboel

*Pediatrics* 2004;113;256-258

DOI: 10.1542/peds.113.3.e256

**This information is current as of November 7, 2006**

The online version of this article, along with updated information and services, is  
located on the World Wide Web at:

<http://www.pediatrics.org/cgi/content/full/113/3/e256>

PEDIATRICS is the official journal of the American Academy of Pediatrics. A monthly publication, it has been published continuously since 1948. PEDIATRICS is owned, published, and trademarked by the American Academy of Pediatrics, 141 Northwest Point Boulevard, Elk Grove Village, Illinois, 60007. Copyright © 2004 by the American Academy of Pediatrics. All rights reserved. Print ISSN: 0031-4005. Online ISSN: 1098-4275.

American Academy of Pediatrics

DEDICATED TO THE HEALTH OF ALL CHILDREN™



# Congenital Diaphragmatic Hernia and Situs Inversus Totalis

Coranne D. Tesselaar, MD\*; Roelf R. Postema, MD\*; Marieke F. van Dooren, MD\*; Karel Allegaert, MD‡; and Dick Tibboel, MD, PhD\*

ABBREVIATIONS. ECMO, extracorporeal membrane oxygenation; VA-ECMO, venoarterial ECMO.

**C**ongenital diaphragmatic hernia is a relatively rare disorder (1:3000 newborns) that frequently presents with respiratory distress in the immediate neonatal period due to severe pulmonary hypertension and lung hypoplasia. Extracorporeal membrane oxygenation (ECMO) can be used as a last resort when artificial ventilation and/or modulation of the pulmonary vascular tone fail to improve the clinical condition.

Situs inversus totalis is a rare condition in which orientation of all asymmetrical organs in the body is a mirror image of the normal morphology.<sup>1</sup> Diaphragmatic hernia may be caused by predisposing genes that are involved in left-right axis determination.

A few cases of an eventration of the diaphragm combined with situs inversus totalis have been described in the literature. We report for the first time a patient with a right-sided posterolateral diaphragmatic hernia, type Bochdalek, and a situs inversus totalis for which contralateral cannulation for the institution of venoarterial ECMO (VA-ECMO) was warranted.

## CASE REPORT

A girl with a birth weight of 3810 g, born at the postmenstrual age of 39 + 6 weeks, developed acute respiratory distress, cyanosis, and lethargy within 30 minutes after birth. Physical examination revealed a scaphoid abdomen and decreased breathing sounds at the right side of the thorax. A chest radiograph revealed that the heart and mediastinum were displaced to the left and that the right pleural cavity was filled with intestines (Fig 1). Ultrasound confirmed that the right hemithorax was almost completely filled with loops of intestine, mesenteric fat, and the spleen due to a large defect in the right hemidiaphragm. An abdominal situs inversus was documented; ie, a normally formed liver positioned left and the spleen on the right side. Echocardiography confirmed a left descending aorta and a mirror image dextrocardia; ie, a structurally normal heart mirrored and unusually positioned in the right chest. At first, there were no signs of clinical, relevant pulmonary hypertension on ultrasonography.

Karyotyping revealed a normal female (46XX). Family history

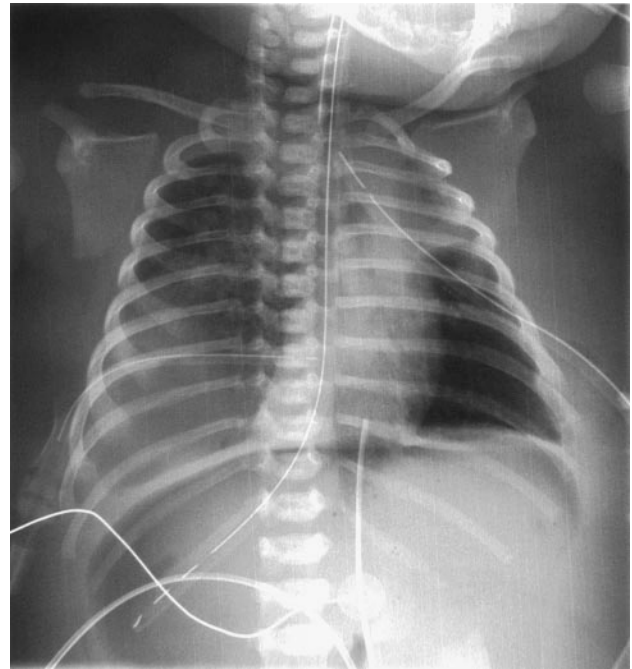


Fig 1. Chest radiograph demonstrating a displaced heart and mediastinum due to a diaphragmatic hernia.

showed no parental consanguinity and no congenital anomalies or minor laterality defects.

Initial management consisted of emergency endotracheal intubation. Next, different ventilatory settings were used to optimize oxygenation, ranging from conventional mechanical ventilation to high-frequency oscillation with these following maximum settings: frequency, 10 Hz; mean airway pressure, 17;  $\delta$  P, 50; fractional inspired oxygen concentration, 100%. Supportive therapy consisted of exogenous surfactant (Alvofact, 50 mg/kg, Boehringer Inc, Ingelheim, Germany), cardiovascular support with inotropic agents (maximum dosages: dopamine, 20  $\mu$ g/kg per min; dobutamine, 20  $\mu$ g/kg per min; noradrenaline, 0.3 mg/kg per min), and pulmonary vasodilators such as inhaled nitric oxide (maximum dosage: 20 ppm).

Because the girl showed progressive respiratory failure complicated by a left-sided pneumothorax, a pneumoperitoneum, and therapy-resistant pulmonary hypertension, she was referred to our ECMO center on day 9 of life (Fig 2). On day 10, VA-ECMO was initiated. The abnormal position of the heart and heart chambers necessitated a left-access approach. The venous cannula for drainage then was inserted in the left internal jugular vein, and the left common carotid artery was cannulated for arterial access (Fig 3). Maximal ECMO flow was 130 mL/kg per min. There were no technical complications during ECMO. Flow was weaned progressively, and the girl was decannulated after 9 days.

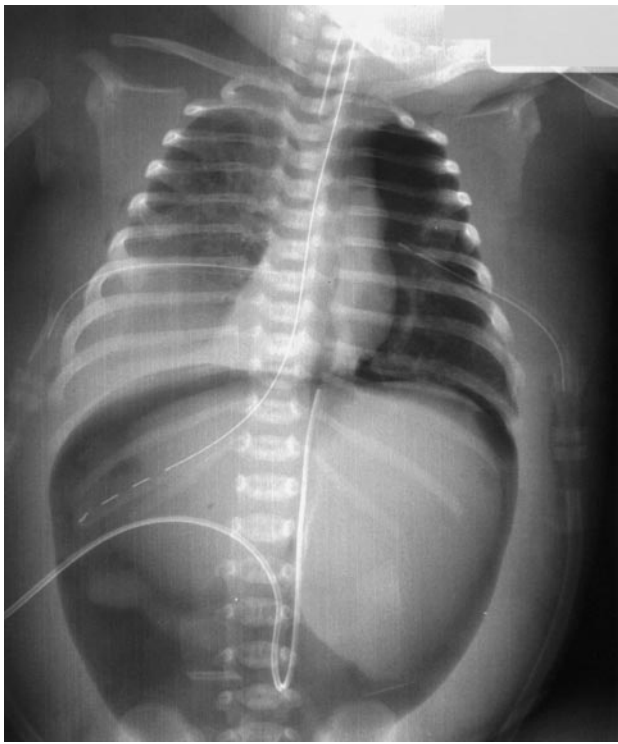
Sixteen days after decannulation (day 35), she underwent elective surgical correction. By right-subcostal incision, the diaphragmatic defect was exposed and repaired with interposition of a Gore-Tex patch. At surgery the malrotation of the small bowel and colon was corrected by adhesiolysis and derotation and accompanied by appendectomy. She was extubated 12 days after the

From the \*Department of Pediatric Surgery, Sophia Children's Hospital, Rotterdam, The Netherlands; and ‡Department of Neonatology, University Hospital, Leuven, Belgium.

Received for publication Aug 26, 2002; accepted Oct 31, 2003.

Address correspondence to Dick Tibboel, MD, PhD, Head Pediatric Surgical Intensive Care Unite, Erasmus MC-Sophia, Dr Molewaterplein 60, 3015 GJ Rotterdam, The Netherlands. E-mail: illsley@chis.azr.nl

PEDIATRICS (ISSN 0031 4005). Copyright © 2004 by the American Academy of Pediatrics.



**Fig 2.** Chest radiograph demonstrating pneumothorax and pneumoperitoneum, revealing the situs inversus of the abdominal viscera.

operation (day 47). At the age of 3 months (day 91), she was discharged. Until the age of 4 months she needed a nasogastric tube because of ongoing feeding problems.

At the age of 6 months, there were no signs of hernia-associated pathologic gastroesophageal reflux. Growth and neurologic and motor development corresponded to her age. She appeared to be doing well, with no apparent complications of the hernia, the ECMO procedure itself, or the operation.

### DISCUSSION

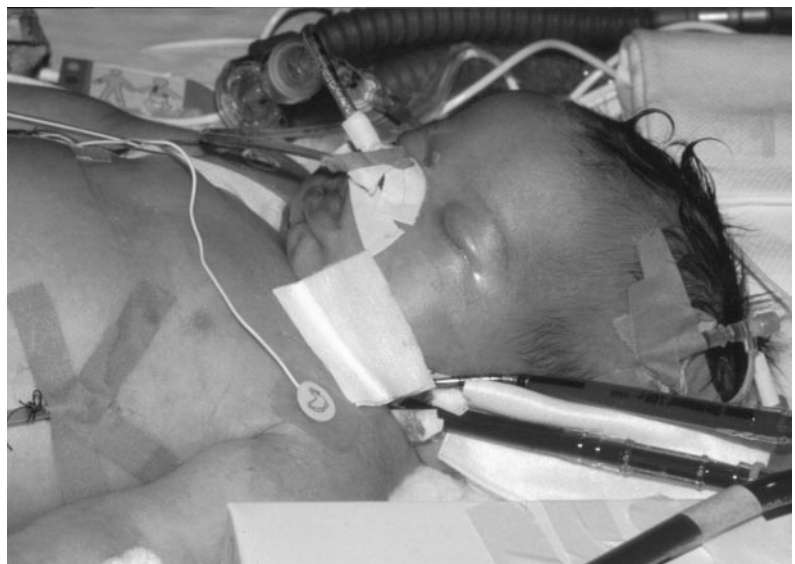Congenital diaphragmatic hernia presents in ~1 in 3000 newborns. In most cases (83%–94%), it is a left-sided posterolateral (Bochdalek) defect.<sup>2</sup> Approximately 1% of the congenital diaphragmatic hernias are bilateral.

Notwithstanding advances in surgical and ventilatory support techniques, diaphragmatic hernia is still a life-threatening malformation with a mortality rate of 25% to 60%.<sup>3,4</sup> Although competition for space by the abdominal viscera during fetal life affects the bronchial growth and the vascular elements in the lung, postnatal pulmonary hypertension and the degree of lung hypoplasia greatly determine survival.<sup>5</sup> Before, during, and after surgery, ECMO may be required to provide respiratory and circulatory support.

A defect in the normal development of the human left-right asymmetry during embryogenesis results in laterality defects with cardiovascular, abdominal, and pulmonary malformations.<sup>6</sup> Mirror-image dextrocardia is a common form of cardiac malposition and has been estimated to occur in 1 of 8000 live births. Mirror-image dextrocardia is almost always associated with situs inversus of the abdominal organs.<sup>7</sup> The prevalence of situs inversus totalis seems to range between 1 in 8000 and 1 in 25 000.<sup>8</sup> It is a condition in which the morphologic right atrium is on the left and the morphologic left atrium is on the right. The normal pulmonary anatomy is reversed such that the left lung has 3 lobes and the right lung has 2. In addition, the liver and gallbladder are located on the left, and the spleen and stomach are on the right. The remaining internal structures also mirror the normal situation. One fourth to one fifth of patients with situs inversus totalis have the Kartagener syndrome, which is characterized by ciliary dyskinesia, bronchiectasia, sinusitis, and infertility.

Etiologic factors in situs inversus are unknown; familial occurrence suggests multiple inheritance patterns. Genes involved in human situs anomalies include ZIC3 (zinc finger transcription factor), LEFTB (transforming growth factor B-related factor), ACVR2B (human activin receptor type IIB), and Cryptic.<sup>9</sup> Mutations in these genes have been found in patients with laterality defects.<sup>10</sup> Strikingly, the *inversin* knockout mouse showed, in addition to a situs defect, an eventration of the diaphragm in 1 of the offspring, suggestive of a common developmen-

**Fig 3.** The individualized VA-ECMO approach, with cannulation of the left jugular vein and the left carotid artery.



tal pathway.<sup>11</sup> Several individual chromosome anomalies have been reported in co-occurrence with situs inversus.<sup>12</sup> The karyotype of our patient was normal, and the family history mentioned no other cases of laterality defects. Retinoic acid must be assumed as a potential environmental risk factor for the 2 defects, because it is involved both in development of the diaphragm and in ACVR2B metabolism.<sup>13</sup>

Only 2 case reports described laterality abnormalities in combination with a right-sided diaphragmatic defect. However, these reports concerned eventrations in combination with other midline defects such as a total laryngotracheoesophageal cleft or a heart defect such as an atrial septum defect.<sup>14,15</sup> The patient we present is, to our knowledge, the first reported neonate with a Bochdalek diaphragmatic hernia and situs inversus totalis. In this case, an abdominal situs inversus was associated with a right-sided diaphragmatic hernia that had significant consequences for the placement of the ECMO cannulas. The individualized approach for ECMO cannulation resulted in an uneventful clinical course.

#### REFERENCES

- Morelli SH, Young L, Reid B, Ruttenberg H, Bamshad MJ. Clinical analysis of families with heart, midline, and laterality defects. *Am J Med Genet.* 2001;101:388–392
- Torfs CP, Curry CJ, Bateson TF, Honore LH. A population-based study of congenital diaphragmatic hernia. *Teratology.* 1992;46:555–565
- Beresford MW, Shaw NJ. Outcome of congenital diaphragmatic hernia. *Pediatr Pulmonol.* 2000;30:249–256
- Boloker J, Bateman DA, Wung JT, Stolar CJ. Congenital diaphragmatic hernia in 120 infants treated consecutively with permissive hypercapnea/spontaneous respiration/elective repair. *J Pediatr Surg.* 2002;37:357–366
- Keijzer R, Liu J, Deimling J, Tibboel D, Post M. Dual-hit hypothesis explains pulmonary hypoplasia in the nitrofen model of congenital diaphragmatic hernia. *Am J Pathol.* 2000;156:1299–1306
- Casey B. Genetics of human situs abnormalities. *Am J Med Genet.* 2001;101:356–358
- Gutgesell HP. Cardiac malposition and heterotaxy. In: Garson A, Bricker JT, Fisher DJ, Neish SR, eds. *The Science and Practice of Pediatric Cardiology.* 1997:1539–1561
- Splitt MP, Burn J, Goodship J. Defects in determination of left-right asymmetry. *J Med Genet.* 1996;33:498–503
- Bamford RN, Roessler E, Burdine RD, et al. Loss-of-function mutations in the EGF-CFC gene CFC1 are associated with human left-right laterality defects. *Nat Genet.* 2000;26:365–369
- Kosaki R, Gebbia M, Kosaki K, et al. Left-right axis malformations associated with mutations in ACVR2B, the gene for human activin receptor type IIB. *Am J Med Genet.* 1999;82:70–76
- McQuinn TC, Miga DE, Mjaatvedt CH, Phelps AL, Wessels A. Cardio-pulmonary malformations in the inv/inv mouse. *Anat Rec.* 2001;263:62–71
- Aylsworth AS. Clinical aspects of defects in the determination of laterality. *Am J Med Genet.* 2001;101:345–355
- Mendelsohn C, Lohnes D, Décimo D, et al. Function of the retinoic acid receptors (RARs) during development (II). Multiple abnormalities at various stages of organogenesis in RAR double mutants. *Development.* 1994;120:2749–2771
- Heitmann F, Erdem S, Langwieder C, Roggenkamp K, Stock GJ. Total laryngo-tracheo-esophageal cleft with situs inversus totalis, aplasia of the right diaphragm and hypoplasia of the lung on the right side [in German]. *Z Geburtshilfe Perinatol.* 1988;192:181–183
- Itoh M, Wada Y, Hashimoto U, Sasaki Y, Ohga K, Oka T. A case of intralobular pulmonary sequestration associated with ASD, dextrocardia, hypoplasia of the right lung and eventration of the diaphragm [in Japanese]. *Kyobu Geka.* 1987;40:1099–1103

## Congenital Diaphragmatic Hernia and Situs Inversus Totalis

Coranne D. Tesselaar, Roelf R. Postema, Marieke F. van Dooren, Karel Allegaert and  
Dick Tibboel

*Pediatrics* 2004;113;256-258

DOI: 10.1542/peds.113.3.e256

**This information is current as of November 7, 2006**

<b>Updated Information &amp; Services</b>	including high-resolution figures, can be found at: <a href="http://www.pediatrics.org/cgi/content/full/113/3/e256">http://www.pediatrics.org/cgi/content/full/113/3/e256</a>
<b>References</b>	This article cites 14 articles, 2 of which you can access for free at: <a href="http://www.pediatrics.org/cgi/content/full/113/3/e256#BIBL">http://www.pediatrics.org/cgi/content/full/113/3/e256#BIBL</a>
<b>Subspecialty Collections</b>	This article, along with others on similar topics, appears in the following collection(s): <b>Surgery</b> <a href="http://www.pediatrics.org/cgi/collection/surgery">http://www.pediatrics.org/cgi/collection/surgery</a>
<b>Permissions &amp; Licensing</b>	Information about reproducing this article in parts (figures, tables) or in its entirety can be found online at: <a href="http://www.pediatrics.org/misc/Permissions.shtml">http://www.pediatrics.org/misc/Permissions.shtml</a>
<b>Reprints</b>	Information about ordering reprints can be found online: <a href="http://www.pediatrics.org/misc/reprints.shtml">http://www.pediatrics.org/misc/reprints.shtml</a>

American Academy of Pediatrics

DEDICATED TO THE HEALTH OF ALL CHILDREN™

