

LEADING ARTICLE

CML – Gastroenterology 2011;30(3):xx–xx.

Treatment Options for Perforated Colonic Diverticular Disease

Irene M Mulder, MD, and Jeffrey Vermeulen, MD, PhD

Department of Surgery, Erasmus University Medical Centre, Rotterdam, the Netherlands

All correspondence to:

J Vermeulen, MD, PhD

Erasmus University Medical Centre

Department of surgery

Dr Molewaterplein 40

3015 GD, Rotterdam

The Netherlands

j.vermeulen.1@erasmusmc.nl

Key words:

Treatment strategy, perforated diverticulitis, laparoscopy, Hartmann procedure

Introduction

Diverticular disease is one of the most common diseases of the gastrointestinal (GI) tract requiring in-hospital treatment in Western countries. Despite its high incidence, controversies remain about the optimal treatment of the different stages of this disease.

Most people with diverticular disease remain asymptomatic; however, approximately 15% develop symptoms, and of these, 15% will develop significant complications such as perforation [1]. Although the absolute prevalence of perforated diverticulitis (PD) complicated by generalized peritonitis is low, its importance lies in the significant postoperative mortality rate, ranging from 4–26% [2–4]. Owing to the low prevalence of generalized peritonitis due to PD (GPPD), strategies for the treatment of this stage of diverticulitis are even less thoroughly investigated. There are two major reasons for this.

Firstly, in the pathogenesis of diverticular disease, diverticulitis and perforation seem to have multifactorial origins, including lifelong dietary habits, medicine use, coexistence of other bowel or collagen-related diseases, and genetic influences. This complex interaction of factors makes it very difficult to investigate. Nevertheless, fundamental epidemiological research is warranted to assess the etiology of this disease and subsequently to develop prevention strategies.

Secondly, although uncomplicated diverticulitis is a common GI disease, the incidence of PD is relatively low (fewer than four cases per 100 000) [3]. Owing to this low incidence, it is difficult to design and successfully complete randomized controlled trials to assess optimal treatment strategies. Operations for PD are classified as emergency and may be performed outside office hours, rendering it even more difficult to start such trials.

Nevertheless, the consequences of this disease for general healthcare and for the patients in particular are enormous, as it is accompanied by high morbidity and mortality rates and poor quality of life after having survived the event. Healthcare costs are significant owing to long periods of intensive care and overall hospital stay, the high rate of additional interventions or operations to treat complications, and outpatient stoma care.

Etiology

The prevalence of diverticulosis is estimated at 5% by the age of 40 years and up to 50–70% at 80 years of age [1,5]. Its exact prevalence is difficult to assess because most people remain asymptomatic [1]. Only about 15% of patients with diverticulosis will manifest any related

clinical symptoms [1,6]. Approximately 80% of patients presenting with PD do not have a previous history of diverticular disease [7].

The pathogenesis of this disease process is probably multifactorial involving dietary habits (low fiber), changes in colonic pressure, motility, and wall structure associated with ageing, along with other factors [8]. The reason why a subgroup of individuals with diverticulosis progresses from asymptomatic to symptomatic or even to complicated PD remains poorly understood.

Dietary shifts during the past century have likely not only influenced colonic motility and intraluminal pressure, but also altered colonic flora [9]. The change in the colonic microbial environment may be an important element in the transformation of asymptomatic diverticular disease into diverticulitis, but its exact role has not been adequately defined [10].

Like the pathophysiology of diverticula, the etiology of diverticular inflammation is also speculative. The development of diverticulitis has been described as similar to that of appendicitis. Perforation of variable extent may result, accounting for a range of symptoms [11,12].

In general, patients with diverticular disease show raised intracolonic pressures, especially in the sigmoid colon [13]. As almost all diverticular perforations occur in the sigmoid colon, these pressure changes must be an important etiological factor. Furthermore, the properties of the colonic wall are likely important because diverticula consist predominantly of mucosa lacking a smooth muscle layer. The mucosal barrier is vulnerable and may be impaired by various exogenous factors, such as the use of nonsteroidal anti-inflammatory drugs (NSAIDs), corticosteroids or opiate analgesics, smoking, and alcohol consumption [14].

The etiology of perforation remains unknown, but it is thought to be a result of an excessive increase in intradiverticular pressure and focal necrosis [15]. This local perforation may form pericolic phlegmones and pus collections (Hinchey I) [16]. If this process progresses further, localized abscesses may form between loops of the small bowel or in the pelvic peritoneum (Hinchey II). If the pus cannot be contained, the abdominal peritoneum becomes contaminated, producing generalized purulent peritonitis (Hinchey III). The same is found when a large intraperitoneal diverticular abscess ruptures into the abdominal cavity [17]. If the initial perforation is large, fecal contamination of the abdominal cavity can occur (Hinchey IV) [16].

Since the incidence of diverticulosis increases with age, the majority of patients presenting with symptoms are elderly. Complicated diverticulitis is also observed predominantly in older patients. This problem is caused by an obscure presentation of diverticular complications in

the elderly patient, with a consequent delay in diagnosis. Polypharmacy (e.g. with NSAIDs or corticosteroids) may further exacerbate this problem and may even increase the risk of developing complications [18].

Prevention

The possible role of diet and lifestyle offers strategies for prevention. Large, prospective studies have identified a preventive effect of both vegetable and high fiber intake and physical exercise in the development of diverticular disease, as well as diverticulitis [19–21]. Fiber as a dietary supplement may be beneficial in prevention. Nevertheless, it is remarkable that the incidence of diverticular disease has not been reduced, given the fact that several studies have shown an increased intake of fiber in Western populations over the last three decades [22]. The exact role of fiber in the pathophysiology of diverticulosis and its prevention remains unclear. Furthermore, when symptoms have developed, evidence of a benefit of fiber intake is even less convincing [22].

One of the latest therapies for the prevention of recurrent diverticulitis is the use of mesalazine, rifaximin, or a combination of the two [23,24]. The rationale for mesalazine use is that it inhibits some key factors of the inflammatory cascade [25]. Another very recent therapeutic strategy is the use of probiotics [26]. Probiotics diminish changes in the spectrum of intestinal microflora and the adherence and translocation of pathogens. They also regulate the production of antimicrobials and interact as competitive metabolites with pro-inflammatory organisms. Importantly, the combination of the *Lactobacillus* spp. with rifaximin seems effective in reducing severe forms of diverticulitis and preventing recurrences, hence reducing surgical treatment significantly [27,28].

The role of surgery in the prevention of complicated diverticular disease is unclear. Advances in diagnostic modalities, medical therapy, and surgical techniques over the past two decades have changed both the management and outcomes of diverticulitis [29]. Patients treated nonoperatively would be expected to do well without elective colectomy since most patients will not have further episodes of diverticulitis [30,31]. Recurrent episodes of diverticulitis do not lead to more complications or failure of conservative treatment [3,32]. At present, it is thought that elective resection for uncomplicated diverticulitis does not alter outcome, nor does it decrease mortality or prevent severe complications of the disease (e.g. perforation) [31,32]. Moreover, the prevalence of persistent symptoms after surgery for diverticular disease (up to 25%) may be an additional reason to discuss the indication for prophylactic surgery.

PD with localized peritonitis: treatment strategies [H1]

The optimal treatment strategy for PD depends on the degree of peritonitis. The introduction of computed tomography (CT) has improved preoperative assessment of diverticular disease. The CT-based classification by Hansen–Stock is the primary classification system and accounts for asymptomatic diverticulosis as well as complicated diverticulitis in different stages, including perforation [34]. Nevertheless, the degree of peritonitis – and hence the severity of disease – in PD can be represented best by Hinchey’s classification (**Figure 1**). Hinchey I and II represent localized peritonitis with phlegmone or abscess near the affected sigmoid and abscess elsewhere, respectively. Even localized PD can present as acute abdominal pain, frequently resulting in emergency surgery when preoperative CT scan for diagnosis is not performed.

The high specificity of CT has allowed this modality to become a surrogate for the perioperative assessment made by the Hinchey classification [35]. Furthermore, CT has become an important therapeutic aid. It is now recognized that patients with small, contained perforations, who are not systemically ill, can be treated initially with antibiotics alone or by CT-guided percutaneous drainage [35,36]. Although mechanical control of the source of infection remains important, several studies have found that abscesses up to 4 cm seem to respond better to antibiotics alone [36,37].

Therefore, in general, Hinchey I and II PD can be treated conservatively with fluids, analgesics, and antibiotics, with or without percutaneous drainage of abscesses. It must also be noted that in Hinchey I and II, small amounts of free air are shown on CT scan, but this does not imply surgical treatment *per se*. If conservative treatment fails, surgical intervention is indicated, in which resection with primary anastomosis (PA) is preferred above sigmoid colectomy with subsequent colostomy, also referred to as Hartmann’s procedure (HP). The performance of a diverting loop-ileostomy to “protect” the anastomosis should be considered, especially in patients with more comorbidity factors [38].

PD with generalized peritonitis: treatment strategies

Hinchey III and IV (GPPD) are characterized by generalized purulent and fecal peritonitis, respectively. Both represent indications for emergency surgery. Since the beginning of the previous century, a three-stage operation strategy was common practice for the treatment of complicated diverticular disease. A preliminary transverse colostomy was advised with a period of delay before resection of 3–6 months [39,40]. The rationale for this strategy was

that primary resection is too difficult in the acute stage of the disease. After several months, the second stage – resection of the involved bowel – could be performed to treat and prevent relapse of the disease.

Since the 1960s, combinations of antibiotics were used for the treatment of Gram-negative bacteria and anaerobic bacteria, and these resulted in improved survival in septic patients [41]. Unfortunately, mortality rates in patients with GPPD remained high. It was thought that the basic cause of this high mortality was the remaining source of infection in the peritoneal cavity. Based on this “expert opinion evidence”, the conviction arose that the colonic perforation had to be removed immediately [42,43].

A two-stage operation (e.g. HP) subsequently became the preferred surgical strategy in these patients [44]. The second stage was represented by the colostomy closure. This change in strategy was mainly based on the results of two reviews published in 1980 and 1984 by Greif et al. [45] and Krukowski and Matheson [46], respectively. Unfortunately, these reviews were not systematic, containing a wide range of different surgical techniques and covering more than 25 years during which substantial improvements in antibiotic and other perioperative supportive therapies had taken place. Furthermore, it is not known whether the patients were comparable for a number of essential variables, such as age, American Society of Anesthesiologists (ASA) classification, and Hinchey scores.

Between 1993 and 2000, two randomized controlled trials assessing primary versus secondary resection were published [47,48]. These randomized controlled trials drew opposing conclusions. Kronborg [47] concluded that three-stage nonresectional surgery (suture and transverse colostomy) in PD was still superior to primary resection because of a lower postoperative mortality rate; however, mortality was not different in Hinchey IV patients who underwent primary resection or patients who were treated according the three-staged surgical strategy. Unfortunately, the study was stopped early because of low recruitment (an average of four patients each year) and hence underpowered. A total of 62 patients were included and operated by 27 different surgeons over a period of 14 years. Zeitoun et al. concluded that primary resection was superior to nonresectional surgery because of less postoperative peritonitis and fewer reoperations [48]. However, postoperative mortality after primary resection was higher compared with nonresectional surgery (24% vs. 19%). Nonetheless, HP became the advocated surgical strategy.

Improvements in surgical and radiological intervention techniques and progress in the management of peritoneal sepsis has resulted in increasing interest in colonic resection with PA since the 1990s. Several systematic reviews have concluded PA to have a better clinical

outcome than HP for patients with GPPD [21]. However, fear of anastomotic leakage often deters many surgeons from performing a one-stage procedure (e.g. PA) in GPPD, although it is becoming more widely accepted that anastomotic leakage does not seem to be related to the grade of contamination of the abdomen.

Restoration of bowel continuity after HP is a technically challenging operation and is associated with significant morbidity and mortality [49]. These rates can be as high as 25% and 14%, respectively, after colostomy reversal in patients who have undergone HP for PD [2,4]. The performance of a diverting loop-ileostomy has been reported to decrease the rate of symptomatic anastomotic leakage in patients operated on for diverticular peritonitis. The risk of a permanent ileostomy is recognizably less than that of HP, with fewer complications [50,51].

In 1996, a new nonresectional laparoscopic approach was described [52]. In patients with peritonitis without gross fecal contamination, laparoscopic peritoneal lavage, inspection of the colon, and the placement of abdominal drains appeared to diminish morbidity and improve outcome [52–54]. In a series of 100 patients with GPPD, Myers et al. showed excellent results after laparoscopic lavage and drainage of the peritoneal cavity, with morbidity and mortality rates <5% [54].

In a second elective stage, definitive surgery can take place (e.g. laparoscopic resection and PA) [53,54], although subsequent elective resection is probably unnecessary [55,56]. Nevertheless, the number of studies are rather limited and mostly based on small groups of patients. Furthermore, the rates of additional radiological interventions and conversion to an open procedure are high [57]. Finally, for many hospitals, it will not be possible to have a surgical team with expertise in colorectal laparoscopic surgery present at all times.

Some authors have expressed their concerns regarding laparoscopic nonresectional treatment of GPPD. They state that the decision to perform nonresectional surgery is influenced by the surgical access to the abdomen (i.e. laparoscopy), rather than based on evidence in literature [58]. Unfortunately, the evidence to which these investigators refer (primary resection favoring three-stage procedures) is equivocal or contradictory, as stated above [46–48].

The major criticism of the nonresectional laparoscopic lavage technique is the continued presence of the perforated colon as a septic focus and the column of feces in the colon as potential ongoing sources of contamination. This was also the main criticism towards the three-stage procedure that was used to treat GPPD until the 1970s. However, GPPD is accompanied by ileus, hence it is not likely that the fecal column is propelled towards the perforation. Moreover, a patent communication between the colonic lumen and the peritoneal

cavity usually cannot be found during laparoscopy because the site of the original perforation has become sealed by the inflammatory process and omentum, and seems efficient to control the source of contamination. In patients who are found to have fecal peritonitis or who fail to improve after lavage, acute resection should still be performed [57,59].

The suggestion that nonresectional surgery in combination with more advanced antibiotics has never been proven to be an inferior strategy, could explain the excellent results after laparoscopic lavage in combination with modern management of peritoneal sepsis with improved antibiotics and intensive care medicine.

In the case of Hinchey III peritonitis, laparoscopic treatment by lavage and drainage without resection has shown such excellent results that this new approach cannot be ignored [53-55,57]. The problem is that Hinchey's classification represents the severity of disease during surgery. Preoperative CT scanning is essential to differentiate between Hinchey I, II, and generalized peritonitis (Hinchey III and IV), but exact differentiation between purulent of fecal peritonitis is not possible with today's radiological modalities. It is therefore advised that all patients with GPPD on CT scan undergo diagnostic laparoscopy. In cases of purulent peritonitis, laparoscopic lavage and drainage can then be performed. Alternatively, resectional surgery can be considered, for which PA is preferred. In cases of fecal peritonitis, conversion to laparotomy is advised to perform sigmoid resection with PA (or HP), as laparoscopic lavage and drainage have shown not to be successful in Hinchey IV PD.

The abovementioned statements still need to be confirmed in randomized controlled trials. Currently, a nationwide randomized trial (Ladies [Laparoscopic Peritoneal Lavage or Resection for Generalized Peritonitis for PD] trial) is running in The Netherlands under the auspices of the Dutch Diverticular Disease (3D) Collaborative Study Group [60]. While awaiting the results of randomized trials assessing laparoscopic lavage, the open approach (PA or HP) presently remains the standard procedure in patients with generalized (purulent of fecal) peritonitis from a free macroperforation in diverticulitis.

Future strategies

Currently, the only patients who require surgery (laparoscopically or open) are those who fail conservative treatment and those with generalized peritonitis who require emergency surgery [37,61]. It seems that a more minimally invasive surgical treatment could be a safe and feasible option in GPPD. To ensure good results, it is essential that these procedures are performed by dedicated colorectal surgeons who have laparoscopic lavage in their

armamentarium of procedures. Minimally invasive nonresectional treatment of GPPD has the highest probability of success. [53]

If nonresectional laparoscopic lavage and drainage to treat GPPD is found to be a safe and better alternative for resectional surgery in the future, why should this be different from nonresectional nonsurgical (e.g. CT-guided) percutaneous lavage and drainage? As yet, the literature does not report this treatment strategy. Is it possible that this will be the next step in the ever more conservative management of different stages in diverticular disease?

Fluid resuscitation and modern antibiotic strategies will not be different from laparoscopically lavage procedures. In order to gain control of the septic focus using percutaneous techniques, it is important that large size catheters are used for adequate drainage of thick and viscous purulent contents [62]. The main problem is the inability for inspection of the abdominal cavity to localize the site and size of the perforation. Such a careful inspection of the abdominal cavity, to look for or exclude other causes of generalized purulent peritonitis, is not possible using today's radiographic modalities. Furthermore, in cases of a large perforation causing fecal peritonitis, source control by percutaneous lavage and drainage is impossible; hence, surgical treatment will be necessary to achieve source control and restore premonitory anatomy and function. It is, therefore, not likely that percutaneous (nonsurgical) nonresectional lavage and drainage will play a prominent role in the treatment of GPPD in the near future, because it cannot yet meet to the principles of abdominal infection treatment.

Proposal for a treatment strategy for PD

Further basic and clinical investigations need to be performed in order to fill the several gaps in our knowledge of the pathophysiology of diverticulitis, as well as its treatment and prevention. For the same reason, there is a need for further good quality epidemiological research to identify risk factors in diverticular perforation. Whether new insights into the etiology will lead to new surgical strategies for prevention and treatment of PD remains to be seen.

Abdominal CT scanning is essential in patients suspected of having PD, because only patients with generalized peritonitis (free fluid and large amount of peritoneal free air) need to undergo emergency surgery. Unfortunately, CT scans cannot presently differentiate between Hinchey III or IV PD. The differentiation between the two is essential because the treatment strategy is different. It is therefore advised that patients who have GPPD on CT scan will undergo diagnostic laparoscopy, followed by definitive surgery. Hinchey III patients should

undergo laparoscopic lavage and drainage, while Hinchey IV patients need to undergo conversion towards laparotomy for resection of the affected colon segment. Future randomized controlled trials must assess whether laparoscopic lavage for Hinchey III, and PA with ileostomy for Hinchey IV, are indeed the preferred surgical strategies. In cases of Hinchey I and II, a conservative treatment is advocated.

Disclosures: The authors declare that they have no potential conflicts that are relevant to the manuscript.

References

1. Parks TG. Natural history of diverticular disease of the colon. *Clin Gastroenterol* 1975;4:53–69.
2. Vermeulen J GM, Hop WCJ et al. Hospital mortality after emergency surgery for perforated diverticulitis. *Ned Tijdschr Geneesk* 2009;153:1209–14.
3. Morris CR, Harvey IM, Stebbings WS et al. Incidence of perforated diverticulitis and risk factors for death in a UK population. *Br J Surg* 2008;95:876–81.
4. Salem L, Flum DR. Primary anastomosis or Hartmann's procedure for patients with diverticular peritonitis? A systematic review. *Dis Colon Rectum* 2004;47:1953–64.
5. Painter NS, Burkitt DP. Diverticular disease of the colon: a deficiency disease of Western civilization. *Br Med J* 1971;2:450–4.
6. Almy TP, Howell DA. Medical progress. Diverticular disease of the colon. *N Engl J Med* 1980;302:324–31.
7. Hart AR, Kennedy HJ, Stebbings WS et al. How frequently do large bowel diverticula perforate? An incidence and cross-sectional study. *Eur J Gastroenterol Hepatol* 2000;12:661–5.
8. Heise CP. Epidemiology and pathogenesis of diverticular disease. *J Gastrointest Surg* 2008;12:1309–11.
9. Tomkins AM, Bradley AK, Oswald S et al. Diet and the faecal microflora of infants, children and adults in rural Nigeria and urban U.K. *J Hyg (Lond)* 1981;86:285–93.
10. Korzenik JR, NDSG. Diverticulitis: new frontiers for an old country: risk factors and pathogenesis. *J Clin Gastroenterol* 2008;42:1128–9.
11. Stollman N, Raskin JB. Diverticular disease of the colon. *Lancet* 2004;363:631–9.

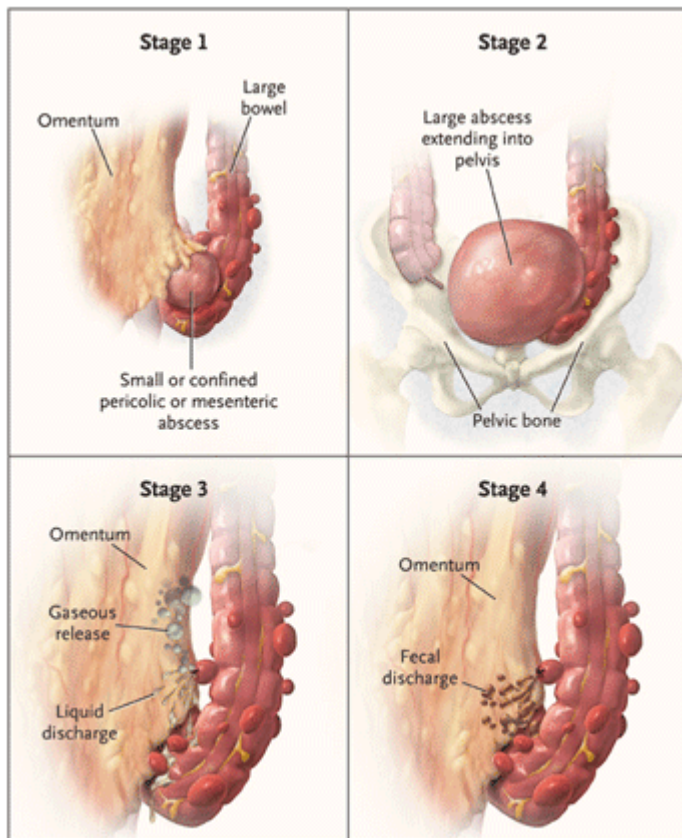
12. Floch CL. Diagnosis and management of acute diverticulitis. *J Clin Gastroenterol* 2006;40(Suppl. 3):S136–44.
13. Arfwidsson S, Knock NG, Lehmann L et al. Pathogenesis of multiple diverticula of the sigmoid colon in diverticular disease. *Acta Chir Scand Suppl* 1964;63(Suppl. 342):1–68.
14. Watters DA, Smith AN. Strength of the colon wall in diverticular disease. *Br J Surg* 1990;77:257–9.
15. Ferzoco LB, Raptopoulos V, Silen W. Acute diverticulitis. *N Engl J Med* 1998;338:1521–6.
16. Hinchey EJ, Schaal PG, Richards GK. Treatment of perforated diverticular disease of the colon. *Adv Surg* 1978;12:85–109.
17. Morris CR, Harvey IM, Stebbings WS et al. Epidemiology of perforated colonic diverticular disease. *Postgrad Med J* 2002;78:654–8.
18. Camilleri M, Lee JS, Viramontes B et al. Insights into the pathophysiology and mechanisms of constipation, irritable bowel syndrome, and diverticulosis in older people. *J Am Geriatr Soc* 2000;48:1142–50.
19. Ornstein MH, Littlewood ER, Baird IM et al. Are fibre supplements really necessary in diverticular disease of the colon? A controlled clinical trial. *Br Med J (Clin Res Ed)* 1981;282:1353–6.
20. Brodribb AJ. Treatment of symptomatic diverticular disease with a high-fibre diet. *Lancet* 1977;1:664–6.
21. Aldoori WH, Giovannucci EL, Rimm EB et al. Prospective study of physical activity and the risk of symptomatic diverticular disease in men. *Gut* 1995;36:276–82.
22. Tan KY, Seow-Choen F. Fiber and colorectal diseases: separating fact from fiction. *World J Gastroenterol* 2007;13:4161–7.
23. Tursi A, Brandimarte G, Daffinà R. Long-term treatment with mesalazine and rifaximin versus rifaximin alone for patients with recurrent attacks of acute diverticulitis of colon. *Dig Liver Dis* 2002;34:510–5.
24. Colecchia A, Vestito A, Pasqui F et al. Efficacy of long term cyclic administration of the poorly absorbed antibiotic Rifaximin in symptomatic, uncomplicated colonic diverticular disease. *World J Gastroenterol* 2007;13:264–9.
25. Grisham MB. Oxidants and free radicals in inflammatory bowel disease. *Lancet* 1994;344:859–61.

26. Fric P, Zavoral M. The effect of non-pathogenic *Escherichia coli* in symptomatic uncomplicated diverticular disease of the colon. *Eur J Gastroenterol Hepatol* 2003;15:313–5.
27. Giaccari S, Tronci S, Falconieri M et al. Long-term treatment with rifaximin and lactobacilli in post-diverticulitic stenoses of the colon. *Riv Eur Sci Med Farmacol* 1993;15:29–34.
28. Lamiki P, Tsuchiya J, Pathak S et al. Probiotics in diverticular disease of the colon: an open label study. *J Gastrointestin Liver Dis* 2010;19:31–6.
29. Chapman J, Davies M, Wolff B et al. Complicated diverticulitis: is it time to rethink the rules? *Ann Surg* 2005;242:576–81; discussion 581–3.
30. Collins D, Winter DC. Elective resection for diverticular disease: an evidence-based review. *World J Surg* 2008;32:2429–33.
31. Salem TA, Molloy RG, O'Dwyer PJ. Prospective, five-year follow-up study of patients with symptomatic uncomplicated diverticular disease. *Dis Colon Rectum* 2007;50:1460–4.
32. Chapman JR, Dozois EJ, Wolff BG et al. Diverticulitis: a progressive disease? Do multiple recurrences predict less favorable outcomes? *Ann Surg* 2006;243:876–30; discussion 880–3.
33. Egger B, Peter MK, Candinas D. Persistent symptoms after elective sigmoid resection for diverticulitis. *Dis Colon Rectum* 2008;51:1044–8.
34. Hansen O, Graupe F, Stock W. Prognostic factors in perforated diverticulitis of the large intestine. *Chirurg* 1998;69:443–9.
35. Lohrmann C, Ghanem N, Pache G et al. CT in acute perforated sigmoid diverticulitis. *Eur J Radiol* 2005;56:78–83.
36. Cheadle WG, Spain DA. The continuing challenge of intra-abdominal infection. *Am J Surg* 2003;186:15S–22S.
37. Blot S, De Waele JJ. Critical issues in the clinical management of complicated intra-abdominal infections. *Drugs* 2005;65:1611–20.
38. Mueller MH, Karpitschka M, Renz B et al. Co-morbidity and postsurgical outcome in patients with perforated sigmoid diverticulitis. *Int J Colorectal Dis* 2011;26:227–34.
39. Lockhart-Mummery J. Late results of diverticulitis. *Lancet* 1938;2:1401–4.
40. Smithwick RH. Experiences with the surgical management of diverticulitis of the sigmoid. *Ann Surg* 1942;115:969–85.

41. Jacobson MA, Young LS. New developments in the treatment of gram-negative bacteremia. *West J Med* 1986;144:185–94.
42. Large JM. Treatment of perforated diverticulitis. *Lancet* 1964;1:413–4.
43. Eng K, Ranson JH, Localio SA. Resection of the perforated segment. A significant advance in treatment of diverticulitis with free perforation or abscess. *Am J Surg* 1977;133:67–72.
44. Auguste L, Borrero E, Wise L. Surgical management of perforated colonic diverticulitis. *Arch Surg* 1985;120:450–2.
45. Greif JM, Fried G, McSherry CK. Surgical treatment of perforated diverticulitis of the sigmoid colon. *Dis Colon Rectum* 1980;23:483–7.
46. Krukowski ZH, Matheson NA. Emergency surgery for diverticular disease complicated by generalized and faecal peritonitis: a review. *Br J Surg* 1984;71:921–7.
47. Kronborg O. Treatment of perforated sigmoid diverticulitis: a prospective randomized trial. *Br J Surg*. 1993;80:505–7.
48. Zeitoun G, Laurent A, Rouffet F et al. Multicentre, randomized clinical trial of primary versus secondary sigmoid resection in generalized peritonitis complicating sigmoid diverticulitis. *Br J Surg* 2000;87:1366–74.
49. Banerjee S, Leather AJ, Rennie JA et al. Feasibility and morbidity of reversal of Hartmann's. *Colorectal Dis* 2005;7:454–9.
50. Vermeulen J, Coene PP, Van Hout NM et al. Restoration of bowel continuity after surgery for acute perforated diverticulitis: should Hartmann's procedure be considered a one-stage procedure? *Colorectal Dis* 2009;11:619–24.
51. Bell C, Asolati M, Hamilton E et al. A comparison of complications associated with colostomy reversal versus ileostomy reversal. *Am J Surg* 2005;190:717–20.
52. Faranda C, Barrat C, Catheline JM et al. Two-stage laparoscopic management of generalized peritonitis due to perforated sigmoid diverticula: eighteen cases. *Surg Laparosc Endosc Percutan Tech* 2000;10:135–8.
53. Franklin ME Jr., Portillo G, Treviño JM et al. Long-term experience with the laparoscopic approach to perforated diverticulitis plus generalized peritonitis. *World J Surg* 2008;32:1507–11.
54. Bretagnol F, Pautrat K, Mor C et al. Emergency laparoscopic management of perforated sigmoid diverticulitis: a promising alternative to more radical procedures. *J Am Coll Surg* 2008;206:654–7.

55. Myers E, Hurley M, O'Sullivan GC et al. Laparoscopic peritoneal lavage for generalized peritonitis due to perforated diverticulitis. *Br J Surg* 2008;95:97–101.
56. Favuzza J, Friel JC, Kelly JJ et al. Benefits of laparoscopic peritoneal lavage for complicated sigmoid diverticulitis. *Int J Colorectal Dis* 2009;24:797–801.
57. Taylor CJ, Layani L, Ghusn MA et al. Perforated diverticulitis managed by laparoscopic lavage. *ANZ J Surg* 2006;76:962–5.
58. Santaniello M, Bergamaschi R. Perforated diverticulitis: should the method of surgical access to the abdomen determine treatment? *Colorectal Dis* 2007;9:494–5.
59. O'Sullivan GC, Murphy D, O'Brien MG et al. Laparoscopic management of generalized peritonitis due to perforated colonic diverticula *Am J Surg* 1996;171:432–4.
60. Swank HA, Vermeulen J, Lange JF et al. The ladies trial: laparoscopic peritoneal lavage or resection for purulent peritonitis and Hartmann's procedure or resection with primary anastomosis for purulent or faecal peritonitis in perforated diverticulitis (NTR2037). *BMC Surg* 2010;10:29.
61. Soumian S, Thomas S, Mohan PP et al. Management of Hinchey II diverticulitis. *World J Gastroenterol* 2008;14:7163–9.
62. Men S, Akhan O, Koroğlu M. Percutaneous drainage of abdominal abscess. *Eur J Radiol* 2002;43:204–18.

Figure 1. The Hinchey Classification of perforated diverticulitis.



Redrawn with permission from Jacobs DO. Clinical practice. Diverticulitis. N Engl J Med 2007; 357: 2057-2066. Copyright © 2007 Massachusetts Medical Society. All rights reserved.