

# The Journal of Laryngology & Otology

<http://journals.cambridge.org/JLO>


Additional services for *The Journal of Laryngology & Otology*:

Email alerts: [Click here](#)

Subscriptions: [Click here](#)

Commercial reprints: [Click here](#)

Terms of use : [Click here](#)



---

## A warning to users of disposable tonsillectomy instruments

The Journal of Laryngology & Otology / Volume 115 / Issue 08 / August 2001, pp 686 - 687  
DOI: 10.1258/0022215011908667, Published online: 08 March 2006

Link to this article: [http://journals.cambridge.org/abstract\\_S0022215101002006](http://journals.cambridge.org/abstract_S0022215101002006)

### How to cite this article:

(2001). A warning to users of disposable tonsillectomy instruments. The Journal of Laryngology & Otology, 115, pp 686-687 doi:10.1258/0022215011908667

Request Permissions : [Click here](#)

## Letters to the Editor

### A warning to users of disposable tonsillectomy instruments

Dear Sirs,

We wish to draw readers' attention to a potential hazard of using disposable tonsillectomy instruments.

Growing concern regarding the transmission of new variant Creutzfeldt-Jakob disease during tonsillectomy has resulted in the widespread adoption of disposable tonsillectomy sets. One of the instruments used routinely is a Boyle-Davis mouth gag, which has a tongue blade that is split in the middle to accommodate the endotracheal tube. The distal ends of the split tongue blade are held together by a welded metal loop, which prevents herniation of the endotracheal tube (Figure 1).

We experienced a case where this metal loop became detached intra-operatively, and came to lie within the postnasal space. Fortunately, the problem was discovered intra-operatively, the loop was removed atraumatically and the patient suffered no harm.

We, however feel that this highlights a possible weakness in the manufacture of these instruments, which creates the potential for aspiration of a loose foreign body after extubation. Furthermore, a missing instrument component could easily be missed, unless specifically looked for.

We wish to strongly advise readers to thoroughly inspect disposable tonsillectomy instruments both pre and post-operatively, to avoid this potentially disastrous complication.

D. W. Chicken, M.B.Ch., N. Sivaji, D.L.O.,  
R. G Kanegaonkar, M.R.C.S., D.L.O.  
Department of Otolaryngology,  
Farnborough Hospital,  
Kent BR6 8ND, UK.

### Clinical effect of canal plugging for paroxysmal positional vertigo.

*J Laryngol Otol* 2000;**114**:959-62

Dear Sirs,

We read with interest the article by Suzuki *et al.*<sup>1</sup> as well as their previous experimental work on the subject.<sup>2</sup> The report immaculately documented the nystagmus and its changes with position and time and correlated these with a pathophysiological explanation accounting for a diagnosis of right LSC cupulolithiasis. The patient was treated by plugging of the implicated LSC and this was claimed to have

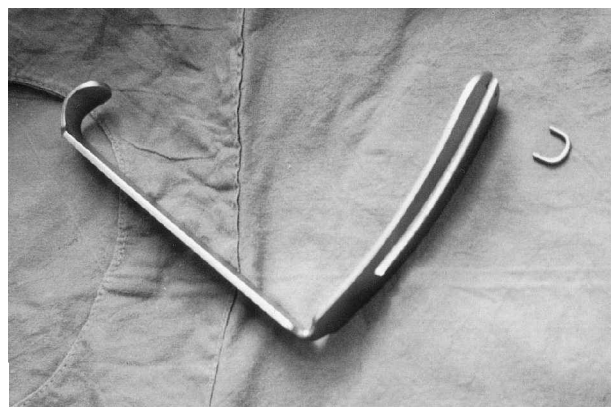

FIG. 1

Disposable Doyle-Davis mouth gag with detached loop.

prevented further stimulation of the cupulolithiatic LSC. However, the authors explanation that 'plugging creates a closed space in the canal between the plugged site and the cupula, thus effectively inhibiting deflection of the cupula' is not a plausible explanation for positional vertigo secondary to cupulolithiasis. It is not clear as to how such a creation of a 'closed space' would in any way inhibit the gravitational pull on a cupulolithiatic cupula which is loaded with otoconia and has a resultant increased specific gravity.

Going by the clinical records presented it is in fact quite possible that the patient's clinical improvement resulted from the said labyrinth suffering significant surgical damage leading to a loss of function of the right vestibular labyrinth/LSC.

We are ourselves currently treating a similar patient with ageotropic horizontal positional transient nystagmus presumably secondary to a left LSC cupulolithiasis. The patient has remained refractory to conservative measures and repositioning manoeuvres. We have nevertheless not proceeded to canal plugging due to the lack of a definite logical explanation for its efficacy in cupulolithiasis. We eagerly await the authors explanation regarding the same.

A. Thakar, F.R.C.S.Ed.,  
Assistant Professor Otolaryngology & Head-Neck Surgery,  
All India Institute of Medical Sciences,  
New Delhi 110029, India.  
Fax: (91) 11 6862663  
E-mail: meenaal@ndb.vsnl.net.in

### References

- 1 Suzuki M, Ichimura A, Veda K, Suzuki N. Clinical effect of canal plugging for paroxysmal positional vertigo. *J Laryngol Otol* 2000;**114**:959-62
- 2 Suzuki M, Kadir A, Takamoto M, Hayashi N. Experimental model of vertigo induced by detached otoconia. *Acta Otolaryngol* 1996;**116**:269-72

### Author's reply

The main point of the question is whether or not the resolution of vertigo is due to dysfunction of the lateral semicircular canal (LSC). In fact the author had the same question, since left beating nystagmus was constantly seen for some period after surgery. This indicates that the operated canal suffered from hypofunction and I was prepared for this before surgery. I understand that canal plugging to the human semicircular canal may well induce hypofunction more or less, since the human membranous labyrinth is very thin and hence may easily be affected by even gentle manipulation. Therefore, I presume that mild hypofunction occurred after surgery in this particular case, too.

However, I do not think that the effect of suppressing the vertigo and nystagmus is solely due to this hypofunctional effect. As I indicated in the paper, the positional nystagmus and vertigo were extremely intense. If any hypofunction of LSC should suppress these, it must be total or near-total loss of LSC function. However, considering that post-operative paralytic nystagmus and dizziness subsided and disappeared in rather a short period of time (five to six days), total loss would not be plausible. Furthermore, the experiment on the monkey showed that the plugging does not disturb the sensory epithelia (previous publication). In my past report, I demonstrated that the cupulolithiasis model easily changed the ampullary

nerve firing depending on the direction of the impinging gravity on the cupula, but the plugging procedure completely abolished this change. From the above findings I think plugging effect is the main mechanism of suppression of vertigo, however, contribution of slight or mild hypofunction of LSC is also possible.

It is my impression that positional vertigo with short and brisk nystagmus of vertical and torsional direction-changing component is potentially due to canalolithiasis and is well controlled by physical manoeuvre. Another type of vertigo that shows long lasting and persistent nystagmus is possibly due to cupulolithiasis of the responsible canal. This type is, regardless if it is of posterior canal or lateral canal origin, sometimes intractable and bothers patients. The present case is one of this type involving LSC.

Mamoru Suzuki, M.D.,  
Department of Otolaryngology,  
Tokyo Medical College Hospital,  
Tokyo 160, Japan.

### Pleomorphic adenoma of retropharyngeal space: a rare location.

*J Laryngol Otol* 2000;**114**:639–40

Dear Sirs,

We read with interest the recent case report by Tariq *et al.*<sup>1</sup> concerning pleomorphic adenoma of the retropharyngeal space causing dysphagia. In this report the imaging modality used in the investigation of the patient was computerized tomography (CT). A 65-year-old patient similarly presented in our ENT department with dysphagia and on examination there was fullness in her right lateral oro- and nasopharyngeal wall. Magnetic resonance imaging (MRI) of the pharynx demonstrated a large mass with imaging characteristics of pleomorphic adenoma in the right parapharyngeal region. This was separate to, but compressing the deep lobe of the parotid gland (Figure 1). Per-oral fine needle aspiration confirmed this lesion to represent a pleomorphic adenoma. At operation the tumour was found to arise from ectopic salivary gland tissue in the parapharyngeal space separate from the parotid gland.

MR is the imaging modality of choice in the investigation of pathology of the parotid gland because of its multiplanar capacity and superior spatial resolution. It also demonstrates vessels and lymph nodes related to the gland and is able to visualize the facial nerve. Pleomorphic adenoma on a T2-weighted sequence typically appears thin walled, well circumscribed and of homogenous high signal due to high myxoid content. These tumours are of low signal on T1-weighting and usually show homogenous enhancement following intravenous gadolinium-DPTA administration. As pleomorphic adenomas enlarge they may develop cystic areas and internal calcification and become inhomogeneous and diagnosis may then become more difficult.<sup>2,3</sup>

K. W. Kesse, F.R.C.S. (Ed.),  
G. Manjaly, F.R.C.S.,  
D.C. Howlett, M.R.C.P., F.R.C.R.\*  
Departments of Otolaryngology and Radiology\*,  
Eastbourne District General Hospital,  
Eastbourne, UK.

### References

- 1 Tariq M, Surenththrian SS, Kobbe AER. Pleomorphic adenoma of retropharyngeal space: a rare location. *J Laryngol Otol* 2000;**114**:639–40

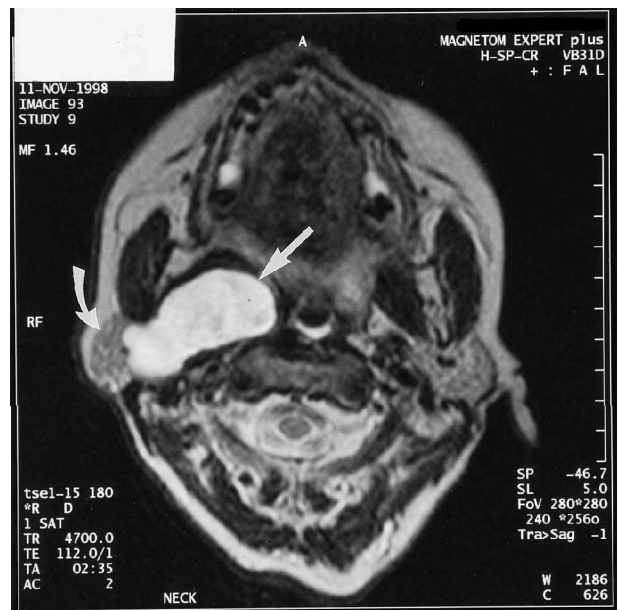

FIG. 1

An axial T2-weighted (TR/TE 4700/112 msec) image through the oropharynx demonstrates a large, well circumscribed mass of relatively homogenous high signal (straight arrow) arising in the parapharyngeal space, which abuts and displaces the right parotid gland (curved arrow). Biopsy confirmed this to represent pleomorphic adenoma. This mass can also be seen to compress and displace the right lateral wall of the oropharynx.

- 2 Tsushima Y, Matsumoto M, Endo K, Aihura T, Nakajima T. Characteristic bright signal of parotid pleomorphic adenoma on T-2 MR weighted images with pathological correlations. *Radiology* 1994;**49**:485–9
- 3 Joe VQ, Westersson PL. Tumours of the parotid gland: MR imaging characteristics of various histological types. *Am J Roent* 1994;**163**:433–8

Dear Sirs,

I read with great interest the paper by Diamantopoulos, Jones and Lowe<sup>1</sup> and the letter by Professor Imre Friedmann<sup>2</sup> and I would like to express my support for sending all nasal polyps removed for histological examination.

Just in the last 12 months I encountered the following:

1. Six cases of inverted papilloma – some of these cases were suspected pre-operatively, but others not.
2. 'Normal' polyps removed for a fifth time and the histological report on that occasion was sarcoidosis.
3. Polyps showing worrying features which have not been fully sorted out as yet!

The idea that all inverted papillomas can be spotted pre-operatively i.e. gross appearance, is in fact not supported by experience.

I congratulate Professor Nick Jones and his group on the excellent paper.

Ahmes L. Pahor, M.A., F.R.C.S., D.L.O., F.I.C.S.,  
D.H.M.S.A., D.M.Sc.(Path.)  
Consultant ENT Surgeon  
City Hospital,  
Birmingham B18 7QH, UK.

### References

- 1 Diamantopoulos II, Jones NS, Lowe J. All nasal polyps need histological examination: an audit-based appraisal of clinical practice. *J Laryngol Otol* 2000;**114**:755–9
- 2 Friedmann I. Letters to the Editor. *J Laryngol Otol* 2001;**115**:352–3