

## ORIGINAL ARTICLE

# A Novel Prion Disease Associated with Diarrhea and Autonomic Neuropathy

Simon Mead, M.D., Sonia Gandhi, M.D., Jon Beck, B.Sc., Diana Caine, Ph.D., Dillip Gallujipali, M.D., Christopher Carswell, M.D., Harpreet Hyare, M.D., Susan Joiner, M.Sc., Hilary Ayling, B.Sc., Tammayn Lashley, Ph.D., Jacqueline M. Linehan, B.Sc., Huda Al-Doujaily, M.Sc., Bernadette Sharps, B.Sc., Tamas Revesz, M.D., Malin K. Sandberg, Ph.D., Mary M. Reilly, M.D., Martin Koltzenburg, M.D., Alastair Forbes, M.D., Peter Rudge, M.D., Sebastian Brandner, M.D., Jason D. Warren, M.D., Jonathan D.F. Wadsworth, Ph.D., Nicholas W. Wood, M.D., Janice L. Holton, M.D., and John Collinge, M.D.

## ABSTRACT

**BACKGROUND**

From the Medical Research Council (MRC) Prion Unit (S.M., J.B., C.C., S.J., J.M.L., H.A.-D., B.S., M.K.S., S.B., J.D.F.W., J.C.), Department of Molecular Neuroscience (S.G., N.W.W.), and Dementia Research Centre, Department of Neurodegenerative Disease (J.D.W.), and MRC Centre for Neuromuscular Diseases (M.M.R.), University College London (UCL) Institute of Neurology; the National Prion Clinic (S.M., D.C., D.G., H.H., P.R., J.C.), National Hospital for Neurology and Neurosurgery (M.K.), UCL Hospitals National Health Service Trust (A.F.); and the Queen Square Brain Bank (H.A., T.L., T.R., J.L.H.) — all in London. Address reprint requests to Dr. Collinge at the MRC Prion Unit, UCL Institute of Neurology, Queen Sq., London WC1N 3BG, United Kingdom, or at [j.collinge@prion.ucl.ac.uk](mailto:j.collinge@prion.ucl.ac.uk).

Drs. Mead and Gandhi and Drs. Holton and Collinge contributed equally to this article.

N Engl J Med 2013;369:1904-14.

DOI: 10.1056/NEJMoa1214747

Copyright © 2013 Massachusetts Medical Society.

Human prion diseases, although variable in clinicopathological phenotype, generally present as neurologic or neuropsychiatric conditions associated with rapid multifocal central nervous system degeneration that is usually dominated by dementia and cerebellar ataxia. Approximately 15% of cases of recognized prion disease are inherited and associated with coding mutations in the gene encoding prion protein (*PRNP*). The availability of genetic diagnosis has led to a progressive broadening of the recognized spectrum of disease.

**METHODS**

We used longitudinal clinical assessments over a period of 20 years at one hospital combined with genealogical, neuropsychological, neurophysiological, neuroimaging, pathological, molecular genetic, and biochemical studies, as well as studies of animal transmission, to characterize a novel prion disease in a large British kindred. We studied 6 of 11 affected family members in detail, along with autopsy or biopsy samples obtained from 5 family members.

**RESULTS**

We identified a *PRNP* Y163X truncation mutation and describe a distinct and consistent phenotype of chronic diarrhea with autonomic failure and a length-dependent axonal, predominantly sensory, peripheral polyneuropathy with an onset in early adulthood. Cognitive decline and seizures occurred when the patients were in their 40s or 50s. The deposition of prion protein amyloid was seen throughout peripheral organs, including the bowel and peripheral nerves. Neuropathological examination during end-stage disease showed the deposition of prion protein in the form of frequent cortical amyloid plaques, cerebral amyloid angiopathy, and tauopathy. A unique pattern of abnormal prion protein fragments was seen in brain tissue. Transmission studies in laboratory mice were negative.

**CONCLUSIONS**

Abnormal forms of prion protein that were found in multiple peripheral tissues were associated with diarrhea, autonomic failure, and neuropathy. (Funded by the U.K. Medical Research Council and others.)

**T**HE PRION DISEASES ARE TRANSMISSIBLE, fatal, neurodegenerative disorders that may be inherited or acquired or that may occur spontaneously as sporadic Creutzfeldt–Jakob disease.<sup>1</sup> The transmissible agent, or prion, is thought to comprise misfolded and aggregated forms of the normal cell-surface prion protein. Prion propagation is thought to occur by means of seeded protein polymerization, a process involving the binding and templated misfolding of normal cellular prion protein. Similar processes are increasingly recognized as relevant to other, more common neurodegenerative diseases. In prion and other neurodegenerative disorders, the aggregates of misfolded protein in the central nervous system are highly heterogeneous, occurring as amyloid plaques, more diffuse deposits, and soluble species. The inherited prion diseases are autosomal dominant disorders caused by mutations in the gene encoding prion protein (*PRNP*).<sup>2</sup> These disorders have been classified into three overlapping neurologic syndromes: the Gerstmann–Sträussler–Scheinker (GSS) syndrome, fatal familial insomnia, and familial Creutzfeldt–Jakob disease.<sup>1</sup>

In contrast to the proteins forming abnormal deposits in other neurodegenerative diseases, prion protein is tethered to the cell membrane by a glycosylphosphatidylinositol (GPI) anchor. The development of transgenic mice that express prion protein lacking the GPI-anchor addition site (known as “anchorless” prion protein) has been of considerable interest, since these mice may propagate infectious prions and abnormal prion protein deposits around blood vessels in the brain and peripheral tissues, but they show highly delayed and variable clinical signs of prion disease.<sup>3,4</sup> In humans, a premature stop-codon mutation also results in abnormal prion protein without a GPI anchor, but clinical reports are very limited. The *PRNP* Y145X mutation has been described in a single patient with an Alzheimer-type dementia and prion protein amyloid deposition in the cerebral vessels,<sup>5</sup> the Q160X mutation has been described in a small family with dementia,<sup>6</sup> and two C-terminal truncation mutations have been associated with the GSS syndrome in case reports.<sup>7</sup> Here we describe the clinical, pathological, and molecular characteristics of a large kindred with a consistent and novel prion disease phenotype that is associated with chronic diarrhea and hereditary sensory and

autonomic neuropathy caused by a novel *PRNP* mutation.

---

## METHODS

---

### PATIENTS

The proband (Patient IV-1) donated his brain to the Queen Square Brain Bank for Neurological Disorders, London, for research into the cause of his family’s neuropathy. Analysis of human tissue samples and transmission studies in mice with the use of human brain tissue were performed with consent from relatives and approval from the local research ethics committee. Patients IV-1, IV-4, IV-6, V-2, and V-7 provided written informed consent.

### IMMUNOHISTOCHEMICAL ANALYSIS

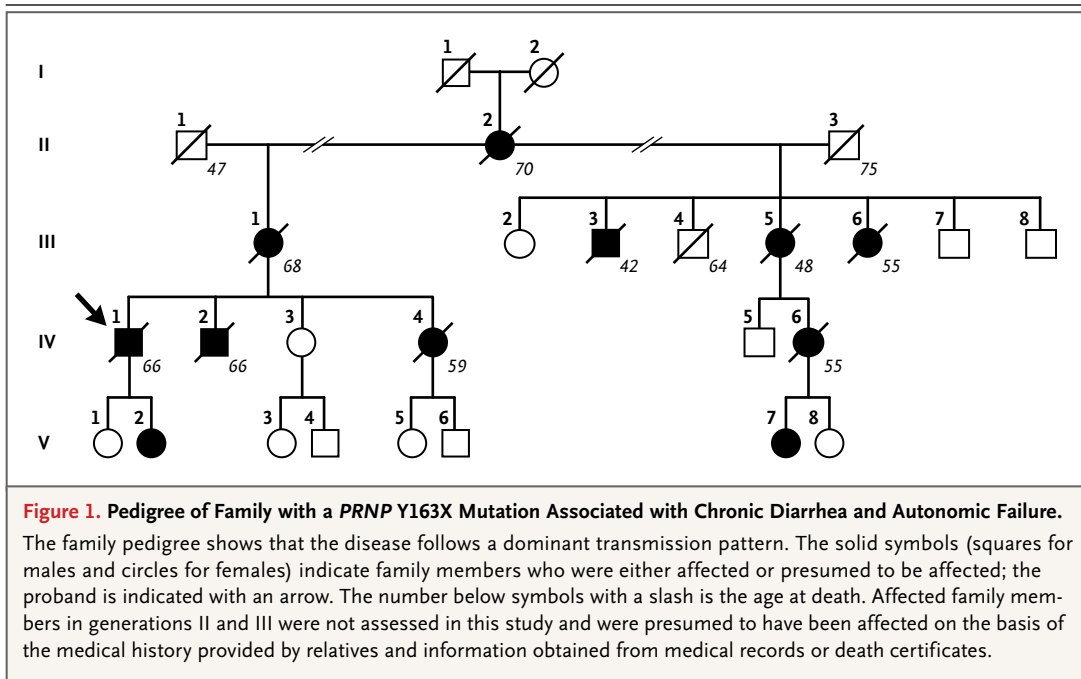
After fixation of the tissue, we processed the tissue blocks into paraffin wax with the use of standard protocols and pretreatment with formic acid. Tissue sections with a thickness of 7  $\mu$ m were stained by means of routine methods, including hematoxylin and eosin, Luxol fast blue, periodic acid–Schiff, Congo red, and thioflavin S. Immunohistochemical analysis was performed on the basis of a standard avidin–biotin protocol with the use of antibodies against prion protein (KG9, 3F4, ICSM 35, and Pri-91<sup>78</sup>), amyloid P component, glial fibrillary acidic protein, tau (AT8), tau-3R, tau-4R, amyloid- $\beta$ , neurofilament cocktail, TDP-43, CD68, CR3/43, and  $\alpha$ -synuclein. (For the results of transmission electron microscopy and other details, see the Methods section in the Supplementary Appendix, available with the full text of this article at NEJM.org.)

### MOLECULAR GENETIC AND PROTEIN STUDIES

We sequenced the entire open reading frame of *PRNP* from genomic DNA using standard techniques. Aliquots of brain homogenate were analyzed with or without proteinase K digestion and with or without phosphotungstic acid precipitation by means of sodium dodecyl sulfate–polyacrylamide gel electrophoresis (SDS-PAGE) and immunoblotting (see the Methods section in the Supplementary Appendix).

### MURINE MODELS

Transgenic mice homozygous for a human prion protein 129V transgene array and murine prion protein–null alleles (*Prnp*<sup>0/0</sup>), designated



Tg(HuPrP129V<sup>+/+</sup>Prnp<sup>0/0</sup>)-152 mice (129VV Tg152 mice), or homozygous for a human prion protein 129M transgene array and murine prion protein-null alleles, designated Tg(HuPrP129 M<sup>+/+</sup>Prnp<sup>0/0</sup>)-35 mice (129MM Tg35 mice), and inbred FVB/NHsd mice were inoculated intracerebrally with brain (frontal cortex) obtained from Patient IV-1 (see the Methods section in the Supplementary Appendix).

## RESULTS

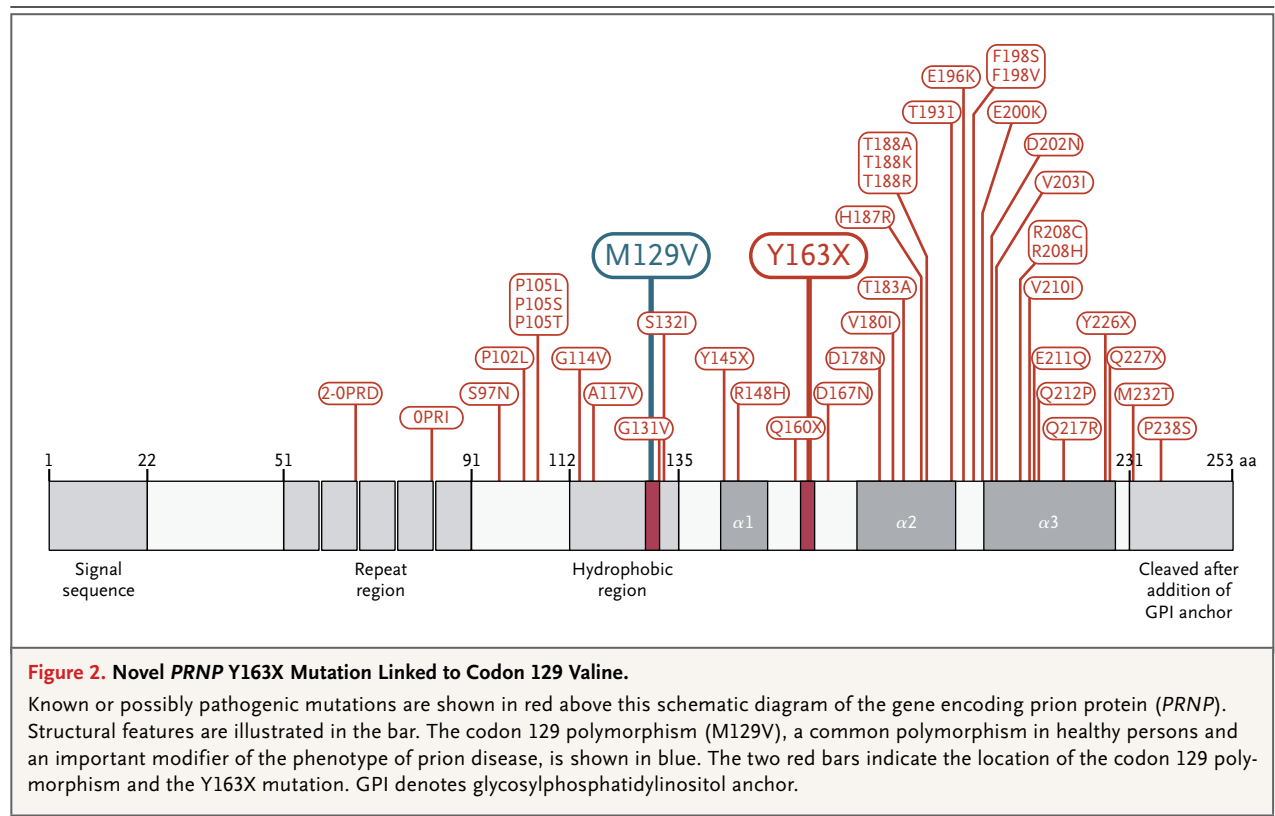
### CLINICAL SYNDROME

The clinical syndrome was similar in all the patients and was transmitted as a dominant trait (Fig. 1). All the patients for whom clinical details were available presented with chronic diarrhea, with onset when they were in their 30s, followed by symptoms and signs of a mixed, predominantly sensory and autonomic neuropathy (Table S1 in the Supplementary Appendix). Watery diarrhea was reported to occur several times daily and nocturnally and was associated with bloating and fluctuating weight, leading to diagnoses of the irritable bowel syndrome and Crohn's disease. Urinary retention caused by denervation of the bladder, which necessitated intermittent self-catheterization, and impotence were early symptoms in two patients. Another early symptomatic feature was postural hypotension, which responded

to therapy with mineralocorticoids and non-pharmacologic supportive measures. In patients with moderately advanced disease, weight loss, vomiting, and diarrhea were severe, warranting the use of parenteral feeding in two patients. This treatment stabilized weight and helped relieve nausea and reduce diarrhea, benefits that persisted when normal oral nutrition was reintroduced several months later. The onset of cognitive problems and seizures occurred when the patients were in their 40s or 50s. The average age at the time of death was 57 years (range, 40 to 70).

Electrophysiological studies on 11 occasions in five patients consistently showed a progressive, length-dependent, predominantly sensory, axonal polyneuropathy (Table S2 in the Supplementary Appendix). Thermal thresholds were markedly abnormal in the feet but not in the hands. Motor involvement was less severe, with evidence of denervation, especially in distal leg muscles, at advanced stages. The clinical and electrophysiological studies prompted the diagnosis of hereditary sensory and autonomic neuropathy, and the findings are reminiscent of familial amyloid polyneuropathy.

Formal neuropsychological studies were performed on eight occasions in three patients. The most prominent finding was impairment of memory and executive function when the pa-



tients were in their 50s. Two of the markedly affected patients (Patients IV-4 and IV-6) showed phonologic language impairment. Magnetic resonance imaging (MRI) of the brain showed generalized volume loss in the supratentorial compartment in one patient with advanced disease but was normal in the other patients. Examination of the cerebrospinal fluid showed an elevation of total tau (>1200 pg per milliliter; normal range, 0 to 320) and S100b protein (2.17 ng per milliliter; normal value, <0.61), and elevated amounts of 14-3-3 protein in one patient.

Cardiac assessments were carried out because cardiomyopathy occurs in transgenic mice expressing anchorless prion protein.<sup>9</sup> However, there were no indications of cardiac involvement in the patients' medical history or on examination; electrocardiography in six patients and echocardiography in three patients showed no abnormalities.

#### MOLECULAR GENETICS

Sequencing of PRNP in DNA samples obtained from patients who provided consent showed a novel PRNP Y163X mutation. This mutation was found

in association with valine at polymorphic prion protein residue 129 (c.489C→G, p.Y163X) (Fig. 2). The polymorphism at codon 129 of PRNP is common in the healthy population and is known to be a strong susceptibility factor for prion disease, as well as a disease-modifying factor. Three other patients with evidence of the clinical syndrome (Patients II-2, III-1, and III-5) were deemed to be obligate carriers. No mutations were found in 18 unrelated patients in whom hereditary sensory and autonomic neuropathy had been diagnosed at the National Hospital for Neurology and Neurosurgery, which suggests that prion disease is not a common cause of this clinical syndrome. We have not seen this mutation in evaluations of more than 4000 patients and controls.<sup>10</sup>

#### BRAIN AND PERIPHERAL-ORGAN DISEASE

We hypothesized that this unusual clinical syndrome might be associated with an atypical pathological appearance and distribution of abnormal prion protein. We therefore investigated the tissues obtained both on autopsy (in Patients IV-1, IV-4, and IV-6) and on biopsy (in Patients V-2

and V-7). (Histologic and immunohistochemical analyses of samples obtained from Patients IV-1 and IV-6 are shown in Fig. 3.) Duodenal-biopsy samples obtained from Patient IV-6 showed extensive focal accumulation of prion protein in the muscularis mucosae as plaques and more diffuse deposits in the lamina propria and submucosa (Fig. 3D); similar findings were present in several biopsy samples obtained from Patient V-2. Histopathological analysis of multiple internal organs obtained on autopsy from Patients IV-4 and IV-6 showed consistent, widespread, and extensive deposition of prion protein amyloid (Table S3 in the Supplementary Appendix).

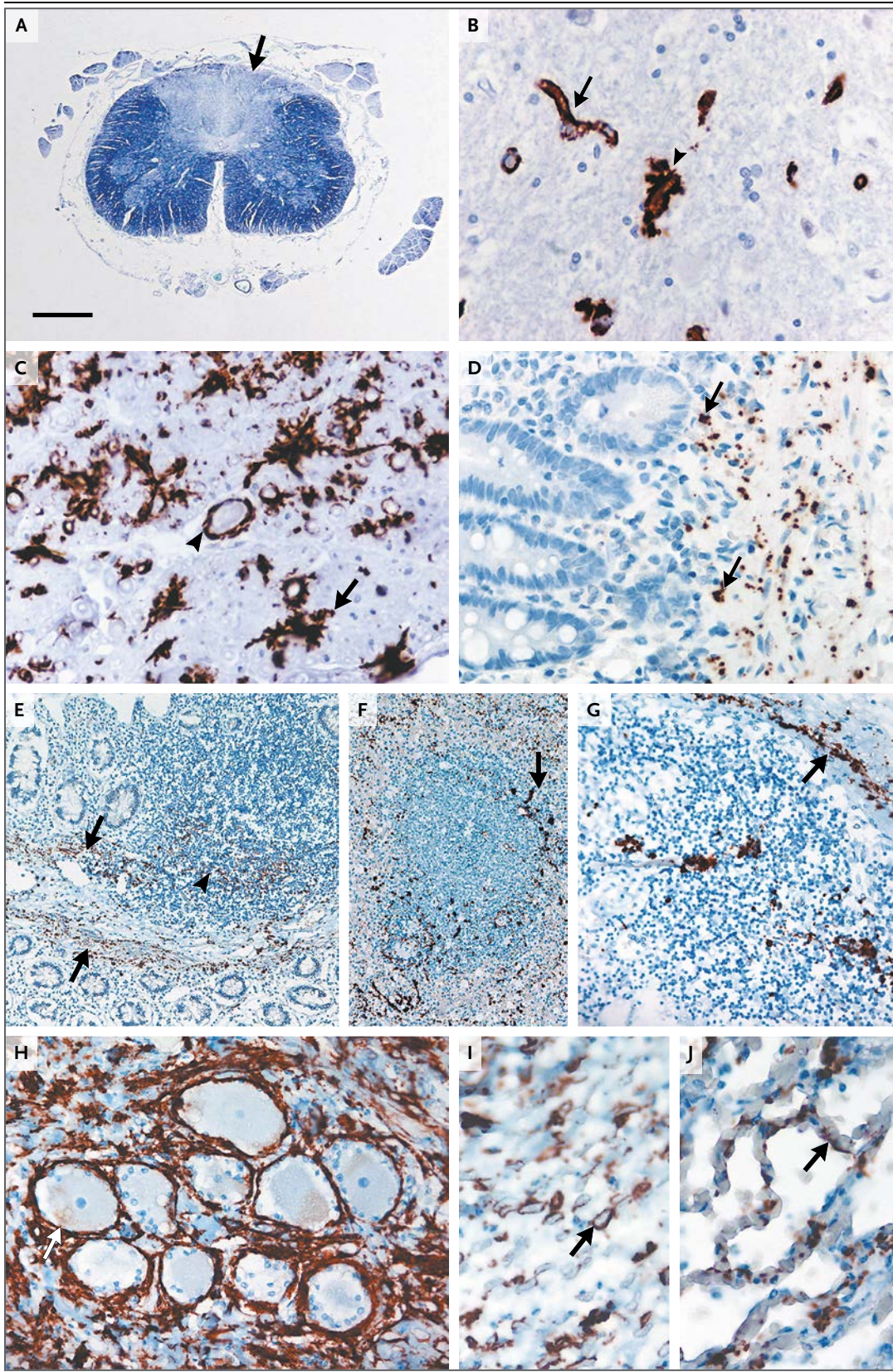
In brief, granular staining was seen around ganglion cells in the dorsal-root ganglia and around nerve fibers in multiple peripheral nerves. Prion protein immunoreactivity was also conspicuous between axons of cranial-nerve roots and those of dorsal and ventral roots in the spinal cord (Fig. 3C). The peripheral lymphoreticular system was involved but showed a pattern of disease distinct from that seen in patients with variant Creutzfeldt-Jakob disease, with abnormal prion protein staining of lymphoid capsules and stroma. In the cardiovascular system, extensive deposition was seen around cardiac myocytes and in the walls of arteries and veins. The deposition of prion protein was also seen in the portal tract of the liver, around kidney tubules, and in lung alveoli. Although abnormal prion protein has been detected in peripheral tissues of some patients with sporadic Creutzfeldt-Jakob disease with the use of high-sensitivity Western blot techniques, abnormal prion protein has not been identified on immunohistochemical analysis in such patients.<sup>11-13</sup>

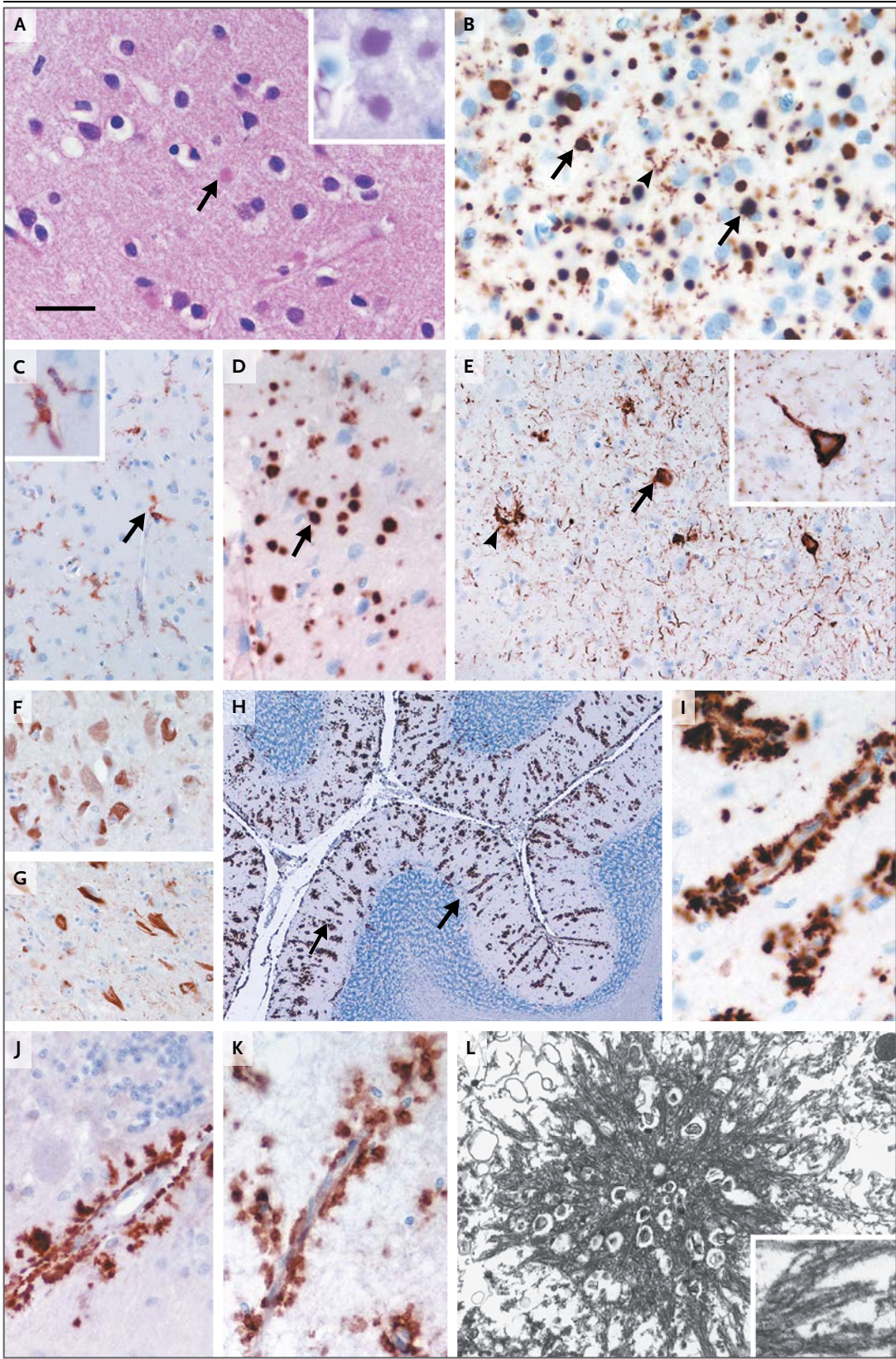
Histologic examination of neocortical regions of brain samples obtained from Patient IV-1 showed mild spongiosis that was restricted mainly to cortical layers 1 and 2; findings in Patients IV-4 and IV-6 were similar. Vacuolation of deeper cortical laminae, which has been associated with some forms of sporadic prion disease, was not a prominent feature. We observed widespread prion protein plaques and a substantial amount of tau-related disease in the form of neurofibrillary tangles and neuropil threads (Fig. 4, and Table S4 in the Supplementary Appendix) — findings that are also seen in some forms of the GSS syndrome. Microglia also showed immunoreactivity for prion protein (Fig. 4C) whereas neurons and

**Figure 3 (facing page). Histologic and Immunohistochemical Analyses of Spinal Cord and Peripheral Tissue Obtained from Patients IV-1 and IV-6.**

Histologic examination of the spinal cord and peripheral tissues obtained from family members was performed to clarify the distribution of deposits of prion protein and to determine whether this finding might shed light on the clinical findings. The findings were very similar for Patient IV-1 (Panels A, B, and C) and Patient IV-6 (Panels D through J). In the spinal cord, myelinated axonal loss in the dorsal columns was shown by a marked reduction in staining of myelin (Panel A, arrow). Immunohistochemical analysis showed deposition of prion protein in the gray matter of the spinal cord, which was largely confined to vessel walls (Panel B, arrow) and the immediately adjacent neuropil (arrowhead). In the dorsal roots, there was abundant deposition of prion protein between nerve fibers (Panel C, arrow) and in the walls of blood vessels (arrowhead). Widespread deposition of prion protein was found in the peripheral nervous system and in systemic organs in Patient IV-6. Punctate deposits were found in the lamina propria and muscularis mucosae of the duodenum in a biopsy specimen (Panel D, arrows). In post-mortem samples, the colon showed similar punctate staining of the lamina propria and muscularis mucosae (Panel E, arrows) in addition to staining at the periphery of lymphoid aggregates (arrowhead). In the spleen (Panel F) and a mesenteric lymph node (Panel G), similar staining was seen at the margins of follicles (arrows), but follicular dendritic cells were unstained, a finding that contrasts with findings in samples obtained from patients with variant Creutzfeldt-Jakob disease. There was pronounced deposition of prion protein around ganglion cells in a dorsal-root ganglion (Panel H, arrow) and around nerve fibers in peripheral nerves (Panel I, median nerve, arrow). In the lung, punctate deposition of prion protein was observed in the alveolar walls (Panel J, arrow). The scale bar (shown only in Panel A) represents 1.9 mm in Panel A, 25  $\mu$ m in Panels B, C, D, H, and J, 100  $\mu$ m in Panels E and F, and 50  $\mu$ m in Panel G. Staining was performed with the use of Luxol fast blue in Panel A, anti-prion protein monoclonal antibody 3F4 in Panels B and C, and anti-prion protein monoclonal antibody ICSM 35 in Panels D through J.

astrocytes were unstained. Focal prion protein immunoreactivity in the walls of capillaries, often extending into surrounding neuropil, was most prominent in subcortical regions. The presence of protein deposits with amyloid conformation was confirmed with the use of the periodic acid-Schiff technique (Fig. 4A, inset), which showed immunoreactivity for serum amyloid P component (Fig. 4D). Ultrastructural examination of neocortex confirmed the presence of amyloid with the detection of small unicentric plaques composed of fibrils radiating





**Figure 4 (facing page). Neuropathological Analyses of Brain Tissue Obtained from Patient IV-1.**

Detailed neuropathological examination of the brain was performed to establish the key histologic features and distribution of deposits of prion protein. Shown here are samples obtained from Patient IV-1, in whom features were very similar to those in Patients IV-4 and Patient IV-6. In the neocortex, small, round eosinophilic structures were seen in the neuropil (Panel A, arrow); these structures are stained with Schiff's reagent (inset). Immunohistochemical staining for prion protein revealed numerous dense deposits scattered in the cortical neuropil (Panel B, arrows), although neurons and astrocytes were unstained. Prion protein immunoreactive structures with the morphologic appearance of activated microglia (Panel B, arrowhead) were also present in the cortex, and the presence of activated microglia was confirmed by means of immunohistochemical staining for CR3/43 (Panel C, arrow, with magnification in inset). Cortical deposits were also strongly immunoreactive for amyloid P component (Panel D, arrow). Tau immunohistochemical analysis revealed abundant cortical tau disease in the form of neurofibrillary tangles (Panel E, arrow, with magnification in inset), neuropil threads, and small numbers of abnormal neurites (arrowhead). Neurofibrillary tangles were composed of a mixture of three-repeat tau isoforms (Panel F) and four-repeat tau isoforms (Panel G), indicating tau disease with a biochemical composition similar to that found in Alzheimer's disease. In the cerebellum, there was abundant deposition of prion protein in the molecular layer (Panel H, arrows), where it was predominantly localized in the walls of small blood vessels extending into the adjacent neuropil (Panel I) and was strongly immunoreactive for amyloid P component (Panel J). The presence of nonmutant prion protein in deposits was shown with the use of a C-terminal-specific antibody, Pri-917 (Panel K). Ultrastructural analysis confirmed the presence of cortical amyloid plaques (Panel L, with magnification shown in inset). Frontal cortex is shown in Panels A, B, C, and E; temporal cortex in Panels D and L; subiculum in Panels F and G; and cerebellum in Panels H through K. The scale bar (shown only in Panel A) represents 25  $\mu\text{m}$  in Panels A, B, D, I, J, and K and the insets in Panels C and E and 10  $\mu\text{m}$  in the inset in Panel A; 50  $\mu\text{m}$  in Panels C, E, F, and G; 260  $\mu\text{m}$  in Panel H; and 0.7  $\mu\text{m}$  in Panel L and 290 nm in the inset. Staining was performed with the use of hematoxylin and eosin in Panel A, with periodic acid-Schiff in the inset; ICSM 35 in Panels B, H, and I; CR3/43 in Panel C, including the inset; amyloid P component in Panels D and J; tau immunohistochemical analysis in Panel E; three-repeat tau immunohistochemical analysis in Panel F; four-repeat tau immunohistochemical analysis in Panel G; and antibody Pri-917 in Panel K. The image in Panel L and its inset are electron micrographs, so no antibody was used.

at the periphery (Fig. 4L). To determine whether nonmutant prion protein was recruited into deposits, immunohistochemical staining with the

use of an antibody against the C-terminal of prion protein (Pri-917, epitope 216–221) was performed.<sup>8</sup> This showed a pattern of staining that was similar to that seen with the three other prion protein antibodies used in the study (Fig. 4K), although molecular and transmission studies did not suggest that nonmutant prion protein is a participant in the disease process.

**IMMUNOBLOTTING**

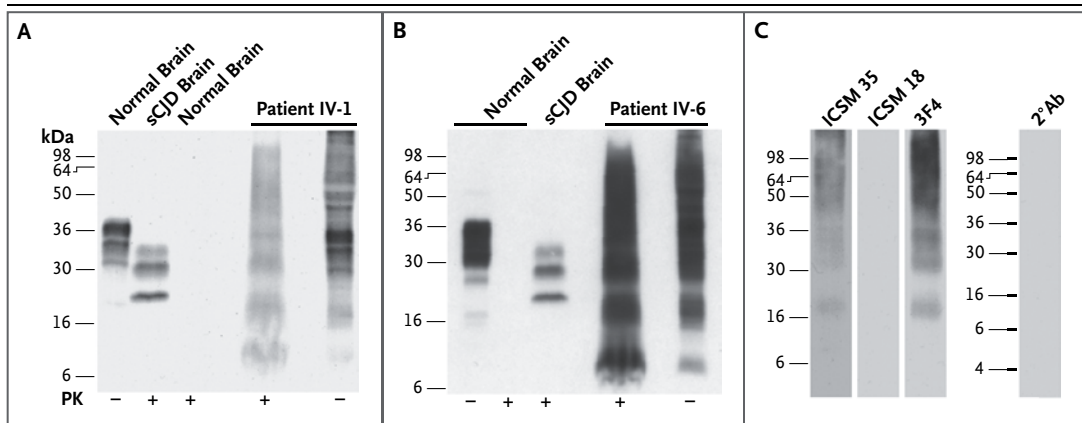
Abnormal prion protein in prion disease may be studied by means of Western blot analysis after partial digestion of the protein with proteases, revealing a diversity of fragment sizes and glycosylation patterns that may correlate with clinical features.<sup>14</sup> We performed these molecular studies to compare abnormal prion protein in this condition with abnormal prion protein seen in other prion diseases.

We analyzed 10% brain homogenate (weight per volume) prepared from frontal-cortex samples obtained from Patients IV-1 and IV-6 before or after digestion with proteinase K.<sup>15</sup> After digestion, Y163X brain homogenate showed a ladder of protease-resistant fragments reactive to anti-prion protein monoclonal antibody 3F4, with apparent molecular masses ranging from approximately 10 kDa to more than 100 kDa (Fig. 5A and 5B).<sup>15</sup> This pattern of disease-related prion protein fragments is highly unusual and contrasts markedly with the much more discrete patterns of truncated proteinase K-resistant prion protein fragments that are seen in other prion diseases.<sup>16–20</sup> Prion protein amino acids 23 to 162 have a molecular mass of approximately 14.6 kDa and lack the sites for known post-translational modification of prion protein by either N-glycosylation or the addition of a GPI anchor. The presence of proteinase K-resistant species of prion protein with apparent molecular masses much greater than expected for full-length, diglycosylated, nonmutant prion protein suggests that prion protein encoded by *PRNP* Y163X may be forming stable sodium dodecyl sulfate-resistant oligomers.<sup>5</sup>

**ABSENCE OF TRANSMISSION TO MICE**

We performed studies using patients' brain tissue to determine whether prion infection could be transmitted to mice. None of the 24 mice from three lines showed any clinical signs of prion disease up to 600 days after inoculation,





**Figure 5. High-Sensitivity Immunoblot Analyses of Frontal Cortex Obtained from Patients IV-1 and IV-6.**

High-sensitivity immunoblot analyses of prion protein were performed in frontal cortex obtained from Patients IV-1 and IV-6, both of whom had the *PRNP* Y163X mutation, to characterize protease-resistant prion protein as compared with known variation in prion disease. Panels A and B show 10 mm<sup>3</sup> of 10% frontal cortex homogenates (weight to volume) prepared from normal human brain, sporadic Creutzfeldt–Jakob disease brain (sCJD) (*PRNP* codon 129MM with type 2 abnormal prion protein; London classification<sup>16</sup>), and brain tissue from Patient IV-1 (Panel A) and Patient IV-6 (Panel B), analyzed before (–) or after (+) digestion with proteinase K (PK) with the use of anti–prion protein monoclonal antibody 3F4. In the sCJD sample, three PK-resistant immunoreactive bands are seen, representing the different glycosylation states of prion protein with an N-terminal truncation. Because the smallest fragment of prion protein that was detected in PK-digested brain homogenate obtained from Patients IV-1 and IV-6 has an apparent molecular mass of approximately 10 kDa, it would appear that prion protein 23–162 is truncated by the protease. To investigate this further, phosphotungstic acid was used to precipitate disease-related prion protein from detergent-solubilized brain homogenate.<sup>15</sup> The pattern of PK-resistant fragments was then reanalyzed with the use of different anti–prion protein monoclonal antibodies. Panel C shows PK-digested phosphotungstic acid pellets derived from 33 mm<sup>3</sup> of 10% frontal cortex homogenate from Patient IV-1 with the use of anti–prion protein monoclonal antibodies ICSM 35, ICSM 18, and 3F4 or secondary antibody alone (2°Ab). PK-digested precipitant from the sample obtained from Patient IV-1 showed a pattern of PK-resistant fragments of prion protein equivalent to that seen after direct PK digestion of brain homogenate, except that the smallest species of prion protein (with an apparent molecular mass of approximately 10 kDa) was absent, in contrast to what is seen in Panels A and B. These findings suggest that the abnormal prion protein conformer that generates the 10-kDa fragment either is soluble in detergent and thus is not recovered by precipitation or becomes sensitive to proteolysis in the presence of detergent. All the remaining PK-resistant species of prion protein showed similar immunoreactivity and were reactive with anti–prion protein monoclonal antibodies ICSM 35 (epitope 93–105 of human prion protein) and 3F4 (epitope 104–113 of human prion protein) and nonreactive with anti–prion protein monoclonal antibody ICSM 18 (epitope 142–153 of human prion protein) or secondary antibody alone. The lack of reactivity of all prion protein species with ICSM 18 indicates that oligomers are composed of fragments of prion protein that are truncated at the C-terminal by PK. It also indicates that these data exclude the involvement of C-terminal protease-resistant conformers of nonmutant prion protein that characterize sporadic and acquired CJD and certain forms of inherited prion diseases.

when the experiment was terminated. We also analyzed brain samples for subclinical infection but observed no proteinase K-resistant prion protein on Western blot analysis or abnormal deposition of prion protein on immunohistochemical analysis.

## DISCUSSION

We describe a novel clinical and pathological phenotype associated with a Y163X mutation in *PRNP*, a disorder that is of particular interest for several reasons. The phenotype is distinct from other prion diseases in that it is associated with

a non-neurologic presentation, the widespread deposition of prion protein amyloid in systemic organs, and slow disease progression. These findings highlight the possibility that there are peripheral abnormalities in other brain diseases associated with protein misfolding. Since the predominant symptoms are peripheral, patients often are referred initially to a gastroenterologist and undergo gastrointestinal endoscopy and biopsy, before a neurologic opinion is sought; thus, the condition is a challenging one to diagnose. The unusually long and distinct clinical syndrome raises interesting mechanistic issues with respect to the role of the GPI anchor in prion

pathobiology and the toxicity of prion protein amyloid.

Prion strains, which are associated with distinct types of misfolded prion protein, are known to be critically important determinants of toxicity and pathological targeting.<sup>21</sup> The truncation mutation may result in misfolded prion protein with radically different strain properties. The relative contributions to observed strain properties of nonmutant prion protein, the lack of a GPI anchor, a truncation of the protein, and the association between the Y163X mutation and the presence of valine at polymorphic residue 129 are unclear. These issues might be further addressed by the generation of transgenic mice that express human prion protein with the Y163X mutation.

Two transgenic mouse models have been reported that have homozygous expression of full-length prion protein lacking the GPI anchor (“anchorless prion protein”). In both models, there are vascular and perivascular deposits of prion protein that are similar in appearance to those in the brains of humans who have inherited prion diseases with *PRNP* stop-codon mutations.<sup>3,4</sup> This finding suggests that the cerebrovascular phenotype associated with the deposition of prion protein may relate to the loss of the GPI anchor alone, rather than C-terminal truncation of prion protein. One model in transgenic mice showed cardiac defects on testing but no overt clinical signs,<sup>3</sup> whereas a spontaneous and transmissible neurodegenerative disease developed in a second model.<sup>4</sup> After one of these models was infected with prions, extraneural deposition of abnormal prion protein and of infectious prions was seen in peripheral tissues.<sup>9,22</sup> These observations in transgenic mice have parallels with the patients we describe, and it is possible that poor ascertainment of diarrhea and autonomic dysfunction in mice explains the apparent discrepancy in clinical presentation. A further distinction is that the transgenic models have minimal brain parenchymal deposits of prion protein, whereas parenchymal prion protein amyloid plaques are prominent in patients with the Y163X mutation (Fig. 4A, 4B, and 4D).

Autonomic failure and peripheral neuropathy are not major clinical features in the recognized inherited prion diseases. Dysautonomia has been reported in the rapidly progressive fatal familial insomnia,<sup>23</sup> which is classically caused by a mutation at codon 178<sup>24</sup> in association with methionine at polymorphic residue 129. However, pe-

ripheral neuropathy is not a feature of fatal familial insomnia.<sup>25,26</sup> Inherited prion disease associated with the Y163X mutation is consistently associated with autonomic failure, characterized by severe parasympathetic and sympathetic dysfunction. It is likely that the cause of autonomic failure is predominantly peripheral, as suggested by the clinical and electrophysiological evidence and by evidence of pathologic features in the peripheral nervous system. Diarrhea in these patients has multiple potential causes and may be caused by autonomic denervation of the bowel; alternatively, abnormal prion protein may have direct toxic effects on the mucosa causing malabsorption, bacterial overgrowth, or gastroparesis, as described in familial amyloid polyneuropathy.<sup>27</sup>

Presentation with diarrhea led to invasive investigations or surgery in several patients, with concomitant potential for iatrogenic transmission of prions from the gut through contamination of medical or surgical instruments.<sup>28</sup> It is reassuring, however, that murine studies did not show experimental transmissibility, although this finding does not completely rule out the presence of potentially infectious human prions. Although nonmutant prion protein was detected in the protein deposits in multiple tissues, Western blotting showed that the protein was not protease-resistant. *PRNP* analysis should be considered in the investigation of unexplained chronic diarrhea associated with a neuropathy or an unexplained syndrome similar to familial amyloid polyneuropathy. The prevalence of systemic amyloidosis associated with prion protein is probably low but might be better characterized with more widespread testing of *PRNP* and histologic examination for prion protein in biopsy samples.

Supported by grants from the U.K. Medical Research Council (MRC) (in part to Dr. Reilly), the Reta Lila Weston Institute of Neurological Studies (to Dr. Holton and Ms. Ayling), Alzheimer's Research UK (to Drs. Holton, Revesz, and Lashley), the Multiple System Atrophy Trust (to Drs. Holton and Revesz), the National Institute for Health Research (NIHR) Biomedical Research Centre at the University College London Hospitals NHS Foundation Trust and University College London, the NIHR Dementia Biomedical Research Unit, the National Institutes of Neurological Diseases and Stroke and Office of Rare Diseases Research (U54NS065712, to Dr. Reilly), a Wellcome Trust Senior Clinical Fellowship (to Dr. Warren), and a Wellcome Trust/MRC Neurodegeneration award (WT089698).

Disclosure forms provided by the authors are available with the full text of this article at NEJM.org.

We thank the patients and their families, caregivers, and physicians for providing medical histories and assessments for use in the patient reports; Ray Young for assistance with the original figures; Kerrie Venner for assistance with electron microscopy; and Prof. Bernardino Ghetti for helpful discussions.

## REFERENCES

1. Collinge J. Prion diseases of humans and animals: their causes and molecular basis. *Annu Rev Neurosci* 2001;24:519-50.
2. Mead S. Prion disease genetics. *Eur J Hum Genet* 2006;14:273-81.
3. Chesebro B, Trifilo M, Race R, et al. Anchorless prion protein results in infectious amyloid disease without clinical scrapie. *Science* 2005;308:1435-9.
4. Stöhr J, Watts JC, Legname G, et al. Spontaneous generation of anchorless prions in transgenic mice. *Proc Natl Acad Sci U S A* 2011;108:21223-8.
5. Ghetti B, Piccardo P, Spillantini MG, et al. Vascular variant of prion protein cerebral amyloidosis with tau-positive neurofibrillary tangles: the phenotype of the stop codon 145 mutation in *PRNP*. *Proc Natl Acad Sci U S A* 1996;93:744-8.
6. Jayadev S, Nochlin D, Poorkaj P, et al. Familial prion disease with Alzheimer disease-like tau pathology and clinical phenotype. *Ann Neurol* 2011;69:712-20.
7. Jansen C, Parchi P, Capellari S, et al. Prion protein amyloidosis with divergent phenotype associated with two novel nonsense mutations in *PRNP*. *Acta Neuropathol* 2010;119:189-97.
8. Demart S, Fournier JG, Creminon C, et al. New insight into abnormal prion protein using monoclonal antibodies. *Biochem Biophys Res Commun* 1999;265:652-7.
9. Trifilo MJ, Yajima T, Gu Y, et al. Prion-induced amyloid heart disease with high blood infectivity in transgenic mice. *Science* 2006;313:94-7.
10. Beck JA, Poulter M, Campbell TA, et al. *PRNP* allelic series from 19 years of prion protein gene sequencing at the MRC Prion Unit. *Hum Mutat* 2010;31(7):E1551-E1563.
11. Glatzel M, Abela E, Maissen M, Aguzzi A. Extraneural pathologic prion protein in sporadic Creutzfeldt-Jakob disease. *N Engl J Med* 2003;349:1812-20.
12. Joiner S, Linehan J, Brandner S, Wadsworth JD, Collinge J. Irregular presence of abnormal prion protein in appendix in variant Creutzfeldt-Jakob disease. *J Neurol Neurosurg Psychiatry* 2002;73:597-8.
13. Hill AF, Butterworth RJ, Joiner S, et al. Investigation of variant Creutzfeldt-Jakob disease and other human prion diseases with tonsil biopsy samples. *Lancet* 1999;353:183-9.
14. Collinge J, Sidle KC, Meads J, Ironside J, Hill AF. Molecular analysis of prion strain variation and the aetiology of 'new variant' CJD. *Nature* 1996;383:685-90.
15. Wadsworth JD, Joiner S, Hill AF, et al. Tissue distribution of protease resistant prion protein in variant CJD using a highly sensitive immunoblotting assay. *Lancet* 2001;358:171-80.
16. Hill AF, Joiner S, Wadsworth JD, et al. Molecular classification of sporadic Creutzfeldt-Jakob disease. *Brain* 2003;126:1333-46.
17. Wadsworth JD, Joiner S, Linehan JM, et al. Kuru prions and sporadic Creutzfeldt-Jakob disease prions have equivalent transmission properties in transgenic and wild-type mice. *Proc Natl Acad Sci U S A* 2008;105:3885-90.
18. Kovács GG, Trabattoni G, Hainfellner JA, Ironside JW, Knight RS, Budka H. Mutations of the prion protein gene phenotypic spectrum. *J Neurol* 2002;249:1567-82.
19. Gambetti P, Kong Q, Zou W, Parchi P, Chen SG. Sporadic and familial CJD: classification and characterisation. *Br Med Bull* 2003;66:213-39.
20. Hill AF, Joiner S, Beck J, et al. Distinct glycoform ratios of protease resistant prion protein associated with *PRNP* point mutations. *Brain* 2006;129:676-85.
21. Collinge J, Clarke A. A general model of prion strains and their pathogenicity. *Science* 2007;318:930-6.
22. Lee AM, Paulsson JF, Cruite J, Andaya AA, Trifilo MJ, Oldstone MBA. Extraneural manifestations of prion infection in GPI-anchorless transgenic mice. *Virology* 2011;411:1-8.
23. Montagna P, Gambetti P, Cortelli P, Lugaresi E. Familial and sporadic fatal insomnia. *Lancet Neurol* 2003;2:167-76.
24. Medori R, Tritschler HJ, LeBlanc A, et al. Fatal familial insomnia, a prion disease with a mutation at codon 178 of the prion protein gene. *N Engl J Med* 1992;326:444-9.
25. Cortelli P, Parchi P, Contin M, et al. Cardiovascular dysautonomia in fatal familial insomnia. *Clin Auton Res* 1991;1:15-21.
26. Portaluppi F, Cortelli P, Avoni P, et al. Diurnal blood pressure variation and hormonal correlates in fatal familial insomnia. *Hypertension* 1994;23:569-76.
27. Planté-Bordeneuve V, Said G. Familial amyloid polyneuropathy. *Lancet Neurol* 2011;10:1086-97.
28. Edgeworth JA, Sicilia A, Linehan J, Brandner S, Jackson GS, Collinge J. A standardized comparison of commercially available prion decontamination reagents using the Standard Steel-Binding Assay. *J Gen Virol* 2011;92:718-26.

Copyright © 2013 Massachusetts Medical Society.

**JOURNAL ARCHIVE AT NEJM.ORG**

Every article published by the *Journal* is now available at NEJM.org, beginning with the first article published in January 1812. The entire archive is fully searchable, and browsing of titles and tables of contents is easy and available to all. Individual subscribers are entitled to free 24-hour access to 50 archive articles per year. Access to content in the archive is available on a per-article basis and is also being provided through many institutional subscriptions.