

Acta Med. Okayama, 2013
Vol. 67, No. 5, pp. 319-324

Copyright©2013 by Okayama University Medical School.

Acta Medica
Okayama

<http://escholarship.lib.okayama-u.ac.jp/amo/>

Case Report

Preparation of Enteric-coated Capsules of Beclomethasone Dipropionate for Patients with Intestinal Graft-versus-Host Disease and a Case Study

Kiminaka Murakawa^a, Tomoaki Sato^a, Yoshinobu Maeda^b, Yoshihisa Kitamura^{a*},
Mitsune Tanimoto^b, and Toshiaki Sendo^a

^aDepartment of Pharmacy, Okayama University Hospital, and ^bDepartment of Hematology, Oncology, Allergy and Respiratory Medicine, Okayama University Graduate School of Medicine, Dentistry and Pharmaceutical Sciences, Okayama 700-8558, Japan

Graft-versus-host disease (GVHD) is a major concern in transplantation patients. Gut GVHD is accompanied by diarrhea, abdominal pain, and/or melena. Although oral treatment with corticosteroids (CSs) is effective in treating gut GVHD, it can cause adverse reactions that affect the entire body. Topical administration of CSs can be effective in treating diseases in which lesions are limited locally, because adverse reactions can then be alleviated. In this study, we examine and discuss an enteric-coated beclomethasone dipropionate (BDP) capsule (BDP-EC) formulated at Okayama University Hospital. The BDP-EC did not dissolve in solution 1 (pH1.2), and began disintegrating in solution 2 (pH6.8) after 5 min, with a mean dissolution rate at 15 min of 85%. We then used the capsule to treat a patient who developed gut GVHD after allogeneic hematopoietic stem cell transplantation. Clinically, the frequency of diarrhea decreased after BDP-EC administration. In addition, we were able to decrease the prednisolone equivalent dose. Symptoms associated with adverse reactions to BDP were not observed during the hospitalization period. These findings suggest that the administration of BDP-EC in the early stages of gut GVHD may allow a reduction in the initial doses of systemic CSs.

Key words: beclomethasone, intestinal graft-versus-host disease, enteric-coated capsule, in-hospital formulation

Hematopoietic stem cell transplantation aims to recover hematopoiesis and immunity in patients with diseases in which hematopoietic function is damaged, such as leukemia, lymphoma, and myeloma [1]. In allogeneic transplants, hematopoietic stem cells from a human leukocyte antigen (HLA)-compatible donor are used. The graft-versus-leukemia (GVL) effect, in which the hematopoietic cells of the donor attack the remaining tumor cells in the recipient, has

been well established. As a result, the trend is toward performing mini-transplantations that alleviate the heavy burden of pretreatment. However, graft-versus-host disease (GVHD), an adverse immunological reaction in which T cells derived from the donor damage the recipient cells, is a common complication of allogeneic hematopoietic stem cell transplantation, and a major concern.

A previous study showed that at the onset of acute GVHD, 81% of patients had skin involvement, 54% gastrointestinal involvement, and 50% liver involvement after the first allogeneic marrow transplant [1], which greatly affected the success rate of transplanta-

Received February 19, 2013; accepted May 23, 2013.

*Corresponding author. Phone: +81-86-235-7641; Fax: +81-86-235-7974

E-mail: kitamu-y@cc.okayama-u.ac.jp (Y. Kitamura)

tions [2]. Gut GVHD, which develops in the digestive tract, is accompanied by diarrhea, abdominal pain, and/or melena. Corticosteroids (CSs) are used as the first-line treatment for this disease. However, while effective anti-inflammatory agents, CSs cause adverse reactions that affect the whole body and are therefore considered unsafe [3]. Recently, an enteric-coated formulation of the antedrug beclomethasone dipropionate (BDP) was tested as an anti-inflammatory treatment for gut GVHD [4, 5]. BDP is absorbed through the mucous membranes and is rapidly metabolized and inactivated; it is considered to be an active glucocorticoid with strong anti-inflammatory activity and few adverse systemic effects [6].

We prepared an enteric-coated BDP capsule (BDP-EC) at Okayama University Hospital (hereafter referred to as our institution) as an in-hospital formulation, and studied its pharmacologic properties. We then used it to treat a patient who developed gut GVHD after an allogeneic hematopoietic stem cell transplant and examined the clinical usefulness of our BDP-EC formulation.

Methods

Preparation of BDP-EC. The BDP-EC capsule was prepared using a method described in an article entitled "BDP-EC Capsules" in *Byoin Yakkyoku Seizai* (Japanese Society of Hospital Pharmacists ed.) (Yakuji Nippo Ltd., Tokyo, Japan) [7]. Japanese Pharmacopoeia gelatin No. 2 capsules (Matsuya Corp., Osaka, Japan) were filled with a mixture of 2 mg of BDP and 0.198 g of lactose. Carboxymethyl ethyl cellulose (Freund Industrial Co., Ltd., Tokyo, Japan) was used as the enteric-coating substrate. Twenty layers of the enteric-coating liquid were airbrushed (Tamiya Inc., Shizuoka, Japan; nozzle caliber, 0.3 mm) onto each capsule body and cap.

Dissolution test. Sample enteric-coated capsules were filled with Evans blue (Wako Pure Chemical Industries, Ltd., Osaka, Japan) as a marker, and used in a dissolution test. The test was performed according to the 2nd (paddle) method of the Japanese Pharmacopoeia, using 900 mL ($37.0 \pm 0.5^\circ\text{C}$) of 2 test solutions: 1 (pH 1.2) and 2 (pH 6.8). Paddle rotation was set at 50 rpm. Aliquots of the test solutions were collected over time and passed through a membrane filter (Nihon Millipore K. K., Tokyo, Japan; pore

size, $0.45\mu\text{m}$). The absorbance of each filtrate was measured at 600 nm by ultraviolet absorptiometry to calculate the dissolution rates.

Clinical administration. The patient was a 73-year-old man diagnosed with adult T-cell leukemia and admitted to the Division of Hepatology and Oncology at our institution for a cord blood transplant. After the transplant, cyclosporine and mycophenolate mofetil were administered to prevent GVHD. However, frequent watery diarrhea was observed from day 27 following transplantation, and the patient was switched to the immunosuppressant tacrolimus hydrate. In addition, an intravenous drip infusion of prednisolone sodium succinate (PSL) was started on day 32 after the transplant. Fourteen days after initiation of the PSL drip infusion, daily oral administration of 8 mg of BDP-EC (2 mg per dose, 4 times per day) was initiated and continued for 22 days [8]. We examined medical records before and after BDP-EC administration and determined the following: frequency of diarrhea, melena, and abdominal pain as indices of clinical efficacy; levels of C-reactive protein (CRP), serum potassium (K), and hemoglobin (Hb) as laboratory values; and occurrence of adverse reactions due to CSs (infectability, peptic ulcers, blood pressure, adrenocortical insufficiency, and psychoneurotic disorders) throughout CS administration.

Ethical considerations. This study was reviewed and approved by the Institutional Review Board of our institution, and informed consent was obtained from the patient.

Results

Dissolution behavior of the enteric-coated capsule. The results of the dissolution test are shown in Fig. 1. The enteric-coated capsule did not dissolve in solution 1 (pH 1.2) even after 120 min, and the dissolution rate for Evans blue was 0%. In solution 2 (pH 6.8) the capsule did not disintegrate and the Evans blue did not dissolve for 5 min; however, the capsule began disintegrating after 5 min, and the mean dissolution rate at 15 min was 85%.

Therapeutic course and clinical administration. The drugs administered after the transplant and the frequency of diarrhea are shown in Fig. 2. Mild diarrhea was observed from day 23 following transplantation and increased after day 27 (frequency

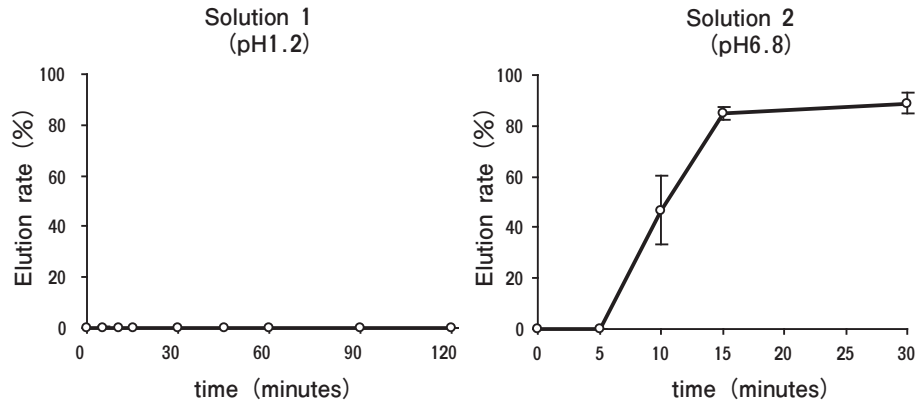


Fig. 1 Dissolution rate of Evans blue in enteric-coated capsules determined by paddle rotation tests *in vitro*. An enteric-coated Evans blue capsule was added to solution 1 (pH 1.2) or solution 2 (pH 6.8) for 30 min. Aliquots of the test solutions were collected over time and filtered through a membrane filter. The absorbance of each filtrate was measured at 600 nm by ultraviolet absorptiometry to calculate the dissolution rate. Data represent the mean \pm S. D. for 6 experiments.

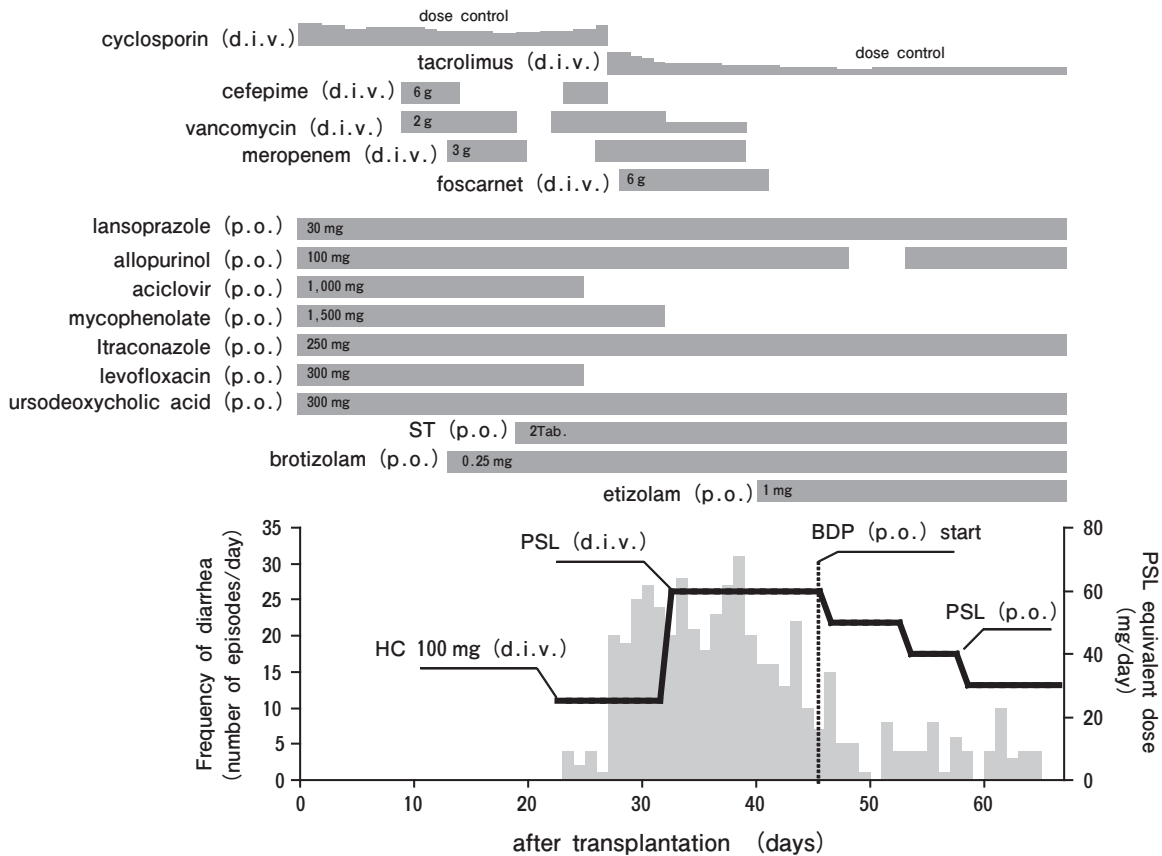


Fig. 2 Schedule of medication for adult T-cell leukemia after cord blood transplantation and the frequency of diarrheal episodes. Prednisolone (PSL) equivalent dose: Hydrocortisone (HC): PSL = 1 : 4; ST, Sulfamethoxazole/trimethoprim (400 mg: 80 mg/tablet); BDP, beclomethasone dipropionate.

of diarrhea: 20/day). Abdominal pain and melena developed on day 29 and 31, respectively. A colonoscopy revealed that the patient had gut GVHD with diffuse erosion mainly in the colon. With this diagnosis (on day 32 after transplant), a 14-day intravenous drip infusion of PSL (60mg/day) was begun. Although the symptoms of abdominal pain and melena improved with PSL administration, diarrhea persisted (day 44: frequency of diarrhea: 10/day). As a result, BDP-EC was started on day 45 following transplantation.

Fig. 2 shows the change in frequency of diarrhea when PSL and BDP-EC were administered. The PSL dose was gradually decreased from 60 to 30mg/day (a 50% decrease) during the 22 days that BDP-EC was administered. At the end of the 22 days, the patient was transferred to another hospital. Despite the decrease in PSL, there was no recurrence of abdominal pain or melena, and no marked abnormalities in any of the measured laboratory values, including CRP, K, and Hb levels (Fig. 3). As may be seen in Fig. 3, the patient had additional complications from the transplant and treatment: cytomegalovirus (CMV) infection was detected on day 24 after trans-

plantation, a sleep disorder was observed early after transplant and lasted until the patient transferred hospitals, and delirium was observed from day 62 after transplantation. No symptoms associated with the occurrence of peptic ulcers, changes in blood pressure, or adrenocortical insufficiency were observed during the hospitalization period.

Discussion

GVHD is one of the causes of early death after allogeneic hematopoietic stem cell transplantation, and the use of methotrexate, cyclosporine, or CSs is recommended for hematopoietic stem cell transplantation [9]. PSL and other CSs possess strong anti-inflammatory activities. However, since these drugs have systemic effects, they must be administered with care. It is possible to separate the therapeutic activities from the adverse effects of CSs by administering them topically. Topical administration of CSs is an effective way to treat diseases in which the lesions are limited locally because adverse reactions can be alleviated. In this study, we prepared enteric-coated cap-

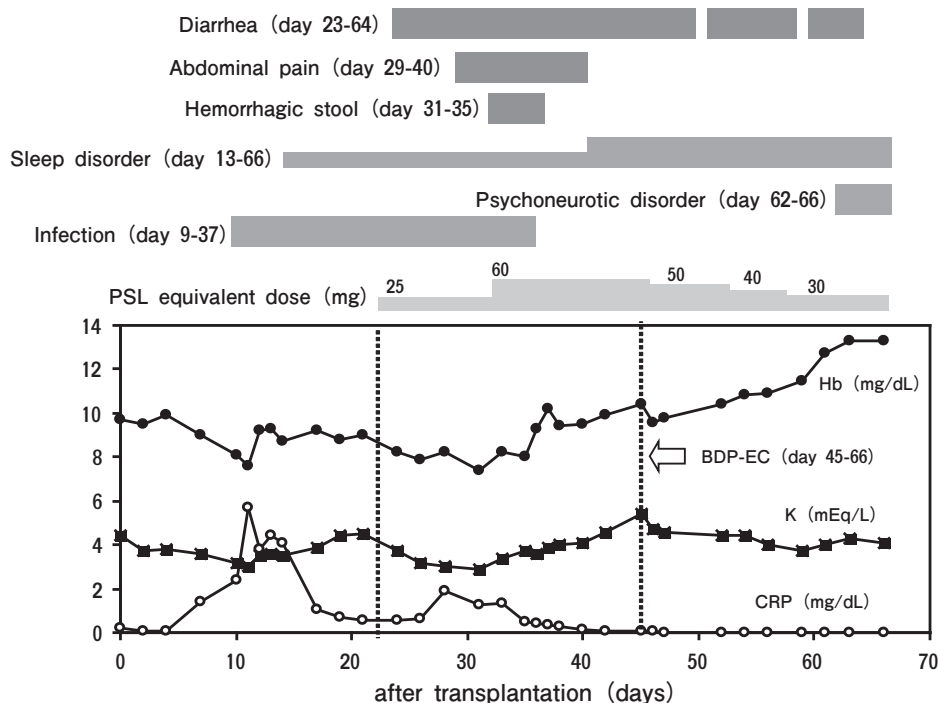


Fig. 3 Various symptoms and laboratory data after cord blood transplantation. PSL, prednisolone sodium succinate; Hb, hemoglobin; K, potassium; CRP, C-reactive protein.

sules of BDP, which has about 600 times more anti-inflammatory activity than PSL and is believed to cause few systemic effects due to its rapid metabolism by serum esterases. We also clinically examined the usefulness of the administration of BDP-EC in a patient with gut GVHD.

BDP-EC was prepared using the method described in *Byoin Yakkyoku Seizai* (Yakuji Nippo Ltd., Tokyo, Japan) [7]. Our previous studies indicated that the disintegration of capsules begins at the joint of the cap and the body of the capsule. We thus recognized that these vulnerable parts of the capsule required very careful coating. The use of general or trigger-type spray bottles resulted in a wide diffusion of the liquid, making it very difficult to spray a specific area. In addition, the amount of liquid sprayed varied, and thus it was not possible to achieve a homogeneous coating of the capsules. We chose instead an airbrush that allowed adjustments to the spray diffusion angle and the amount of enteric-coating liquid. Despite these precautions, it was difficult to coat the capsules while adjusting the various conditions, and different operators may have introduced slight variations in the coating.

As it was critical for this formulation that the contents of the capsule be released only after reaching the small intestine, we increased the number of coats from the generally accepted 5 to 20, and focused particularly on spraying the joint of the capsules. This was important because the procedure also increased the strength of the outer surface of the enteric-coated capsules. In the dissolution tests, the dissolution rate in solution 1 (pH1.2, 120min) was 0%, while that in solution 2 (pH6.8, 15min) was 85%. These results show that this is an effective method for preparing enteric-coated capsules that release their contents in the small intestine (pH of about 6.8) rather than in the stomach (acidic conditions).

We then examined the clinical usefulness of oral administration of BDP-EC in a patient with gut GVHD. The BDP-EC was started 23 days after the onset of diarrhea, *i.e.*, during the remission phase of gut GVHD. The BDP-EC produced a marked reduction in the mean daily frequency of diarrhea, while causing neither a relapse in abdominal pain or melena nor an increase in the frequency of diarrhea. In addition, initiation of BDP-EC allowed us to begin to gradually decrease the dose of PSL (*i.e.*, the dose was

reduced by 10mg per dose during the first 7 days and by another 10mg per dose during the next 5 days). This schedule was very similar to the gradual decrease in CSs described in the published guidelines [9]. By the time the patient was transferred to another hospital, the daily dose of PSL had been decreased by half.

In hematopoietic stem cell transplantation, bone marrow function is completely lost due to the pretreatment; it is therefore very important to prevent infections until neutrophil engraftment. As PSL and other CSs have immunosuppressive activity, infectability should be considered. There is, moreover, a high expectation that the GVL effect will occur in mini-transplantation therapy. Because the immunosuppressive effects of CSs can lead to a decrease in the GVL effect, it is preferable that CS use after transplant be of short duration. In the current study, we were able to gradually decrease the dose of PSL with the administration of BDP-EC, and also to avoid the long-term use of CSs. We therefore argue that BDP-EC is useful in clinical applications.

Avoiding the long-term use of CSs prevented CS-induced adverse reactions in this study. We investigated clinical records to determine the onset of CS-induced adverse reactions during the systemic administration of CSs. Our patient showed a positive CMV reaction on day 24 after transplantation. CMV infection was confirmed when the cumulative dose of CSs was 75mg (as converted to the weight of PSL). In addition, since CS-induced CMV infection has been linked to the long-term administration of CSs, we inferred that our patient's CMV infection was not induced by a decrease in the lymphocyte count, but rather by lowered immunity due to transplantation and GVHD. The risk of adrenocortical dysfunction has been known to increase with the long-term administration (about 6 months) of moderate or high doses of CSs. In the present case, considering the duration of CS administration (44 days), it is unlikely that CSs played a role in adrenocortical dysfunction.

Our patient was observed to have a persistent sleep disorder from the time of the transplant, as well as a psychoneurotic disorder in the form of delirium, observed from day 62 after transplantation. Sleep disorder is a common adverse reaction associated with CSs. Disease conditions and future treatment schedules may also have affected the patient psychologi-

cally, leading to the observed psychoneurotic disorders. However, considering that 30mg or more of PSL was administered during the hospitalization period, it is also possible that the CSs affected the psychoneurological system. The symptoms were well controlled by sleep-inducing and anti-anxiety drugs, and no extreme psychoneurotic disorders were observed. There were no marked changes in peptic ulcers or blood pressure even after the administration of CSs. The use of a proton-pump inhibitor was effective in treating peptic ulcers.

We conclude from these results that the administration of BDP-EC for gut GVHD makes it possible to gradually decrease the dose of concomitant systemic CSs early, and that BDP-EC can help circumvent the long-term administration of CSs and prevent CS-induced serious adverse reactions. Our findings thus suggest that BDP-EC is clinically useful. Inflamed sites of gut GVHD often occur in the area spanning from the ileum to the cecum and in the ascending colon [5]. In the present case, the main lesion was in the ileum; it is therefore possible that the contents of the prepared enteric-coated capsules reached the lesion. However, various factors, such as pH and duration of intestinal movement, should be considered in future studies. It will also be necessary to investigate coating substrates, additives, and coating methods to improve site specificity.

BDP-EC is currently administered concomitantly with systemic CSs in our institution. This medication is highly valued by our physicians since it allows them to reduce doses of systemic CSs. As the administration of BDP-EC in the early stage of gut GVHD may make it possible to reduce the initial dose of systemic

CSs, we plan to evaluate the early administration of BDP-EC for gut GVHD in future studies.

References

1. Martin PJ, Schoch G, Fisher L, Byers V, Appelbaum FR, McDonald GB, Storb R and Hansen JA: A retrospective analysis of therapy for acute graft-versus-host disease: secondary treatment. *Blood* (1991) 77: 1821-1828.
2. Ferrara JL, Levine JE, Reddy P and Holler E: Graft-versus-host disease. *Lancet* (2009) 373: 1550-1561.
3. Weissinger EM, Schiffer E, Hertenstein B, Ferrara JL, Holler E, Stadler M, Kolb HJ, Zander A, Zübig P, Kellmann M and Ganser A: Proteomic patterns predict acute graft-versus-host disease after allogeneic hematopoietic stem cell transplantation. *Blood* (2007) 109: 5511-5519.
4. Hockenbery DM, Cruickshank S, Rodell TC, Gooley T, Schuening F, Rowley S, David D, Brunvand M, Berryman B, Abhyankar S, Bouvier M and McDonald GB: A randomized, placebo-controlled trial of oral beclomethasone dipropionate as a prednisone-sparing therapy for gastrointestinal graft-versus-host disease. *Blood* (2007) 109: 4557-4563.
5. Castilla C, Pérez-Simón JA, Sanchez-Guijo FM, Diez-Campelo M, Ocio E, Pérez-Persona E, López-Villar O, Vazquez L, Caballero D and San Miguel JF: Oral beclomethasone dipropionate for the treatment of gastrointestinal acute graft-versus-host disease (GVHD). *Biol Blood Marrow Transplant* (2006) 12: 936-941.
6. Hübner M, Hochhaus G and Derendorf H: Comparative pharmacology, bioavailability, pharmacokinetics, and pharmacodynamics of inhaled glucocorticosteroids. *Immunol Allergy Clin North Am* (2005)25: 469-488.
7. BDP-EC capsule. *Byoin Yakkyoku Seizai* 6th Ed, Japanese Society of Hospital Pharmacists eds, Yakuji Nippo Ltd., Tokyo (2008) pp. 23 (in Japanese).
8. McDonald GB, Bouvier M, Hockenbery DM, Stern JM, Gooley T, Farrand A, Murakami C and Levine DS: Oral beclomethasone dipropionate for treatment of intestinal graft-versus-host disease: A randomized, controlled trial. *Gastroenterology* (1998) 115: 28-35.
9. The Japanese Society for Hematopoietic Cell Transplantation. "The guideline for hematopoietic cell transplantation -GVHD-", JSHCT monograph. ISSN: 1344-5898, Jul. 2008 (in Japanese).