

LIVER ABSCESS AS A THERAPEUTIC AND DIAGNOSTIC CHALLENGE

Marijan Kolovrat¹, Željko Bušić¹, Dražen Servis¹, Andrej Šitum¹ and Vlatka Čavka²

¹Department of Endoscopic Surgery, Dubrava University Hospital, ²Clinical Department of Dermatovenereology, Sestre milosrdnice University Hospital Center, Zagreb, Croatia

SUMMARY – Liver abscess still represents a significant clinical entity with mortality rates of up to 10%. Traditional treatment of liver abscesses is open surgical treatment. Recently, percutaneous and laparoscopic drainage has been increasingly used. Still, in spite of these relatively novel techniques and improved imaging, liver abscess can sometimes be difficult to diagnose or treat. Here we present two cases of chronic liver abscess treated at our department. First patient was twice hospitalized in other hospitals without reaching definitive diagnosis. He was admitted at our department because of clinical presentation of sepsis, and definitive diagnosis of liver abscess was established only during open surgery. Second patient was admitted after laparoscopic drainage and repeated percutaneous drainage had failed to resolve his symptoms. In both cases, liver segment resection led to complete healing. These cases indicate that chronic liver abscess can still present a diagnostic and therapeutic challenge.

Key words: *Liver abscess; Surgical treatment*

Introduction

Liver abscess is the result of infection of the liver parenchyma, with subsequent infiltration by inflammatory cells and formation of pus collection. In the pathogenesis of hepatic abscess, various bacteria and amebas are mentioned as the possible causes of disease¹. The potential expansion routes of the mentioned pathogenic organisms are biliary tree, portal vein, hepatic artery, direct extension of a nearby focus of intra-abdominal infection or trauma.

Despite novel scientific and clinical evidence, liver abscess, as one of the intra-abdominal infection forms, still represents a major diagnostic and therapeutic problem.

With early detection and better understanding of the clinical course, based on new imaging techniques (ultrasonography (US), computed tomography

(CT) and magnetic resonance imaging (MRI)), new approaches in the treatment have been made possible. Although minimally invasive therapy is rapidly developing², helped by early empirical use of broad spectrum antibiotics (or specific antibiotic therapy), surgical treatment is still one of the main therapeutic approaches³. However, differential diagnosis, especially when other infective cystic liver diseases (echinococcus cysts) are present, poses considerable problem.

Here we present two cases of chronic hepatic abscess that are indicative of how persistent this condition can be.

Case Report 1

A 37-year-old patient with a previously verified structure in hepatic segment VII resembling echinococcosis was hospitalized with clinical findings of septic state. In 12 months prior to this hospitalization, he was hospitalized twice in other hospitals due to a similar state, when echinococcus liver abscess

Correspondence to: Željko Bušić, MD, PhD, Dubrava University Hospital, Av. Gojka Šuška 6, HR-10000 Zagreb, Croatia
E-mail: zbusic@kbd.hr

Received July 19, 2011, accepted April 3, 2013

was suspected and he was administered albendazole for ten days, with no improvement in his clinical presentation. The patient's previous history revealed the diagnoses of reflux esophagitis type B and chronic gastritis (HP negative).

Now, the patient presented with axillary temperature of 38.5 °C. Peripheral blood leukocyte count was $19 \times 10^9/L$. Serum C-reactive protein (CRP) concentration was 206 mg/L, whilst other liver markers were within the normal range.

Considering no improvement in the patient's state despite previous conservative treatment, multi-slice CT (MSCT) liver finding and other laboratory findings, surgical treatment was indicated. The operation was started by laparoscopic technique. Abdominal cavity exploration revealed enlarged bile bladder with adhesions. Adhesiolysis was performed and the liver was partially mobilized, but the abscess site was not exposed. The operation was therefore converted to open approach by "hockey-stick" incision in the right hypochondriac area. Exploration revealed a tumefaction in the hepatic segment VII, 8-10 cm in diameter. Incision was made to evacuate a few cubical centimeters of pus, which was sent for microbiological analysis. Using Pringle maneuver for 15 minutes, segmentectomy of the hepatic segment VII was carried out (Fig. 1). After meticulous hemostasis and drain placement, the operation was finished.

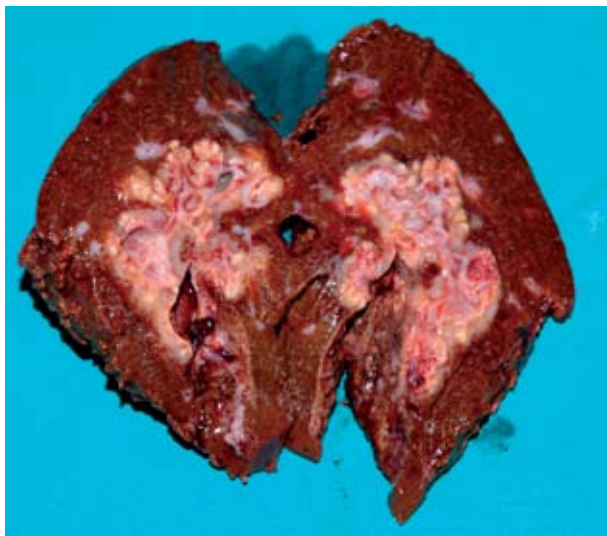


Fig. 1. Resected hepatic segment VII with visible abscess cavity.

The operation lasted for 150 minutes, without complications. During the operation, there was no extensive bleeding, thus there was no need for the administration of blood transfusion and blood derivatives. The postoperative course, with oral administration of antibiotic therapy (cefazolin 3x1 g and metronidazole 3x500 mg throughout six days), anticoagulant therapy (clexane 20 mg s.c.) and analgesic therapy, was without complications.

Microbiological finding of the liver abscess aspirate was sterile. Abdominal drain was removed on postoperative day 3. On postoperative day 10, follow up US of the abdomen showed satisfactory findings.

On day 3 of discharge from the hospital, the patient was re-admitted *via* emergency surgery unit due to febrile state. MSCT and abdominal US findings showed a small collection (3x3 cm) of free liquid in the right subphrenic space and right phrenicocostal sinus. Conservative therapy with antibiotics was applied (cefazolin 3x1 g and metronidazole 3x500 mg), upon which his clinical presentation showed improvement. On day 14 of his hospital stay, follow up abdominal US revealed resorption of the previously described collection. Laboratory blood tests were performed on several occasions showing gradual improvement, except for the still elevated blood CRP, which was 119 mg/L at discharge from the hospital. The patient was released on day 16 of hospital stay. On subsequent periodical follow ups over one year after the operation, the patient was without difficulties and with normal test results.

Case Report 2

A 41-year-old patient with previously verified and several times conservatively treated liver abscess was hospitalized due to planned operation of liver abscess. During first hospitalization eight months before, when he was hospitalized *via* emergency surgery unit, presenting with fever and abdominal pain, a right liver lobe abscess of 12 cm in diameter was verified (MSCT and US). Laparoscopic drainage and evacuation were performed. Follow up US taken prior to his discharge from the hospital verified still present liquid content in the abscess cavity. The patient was then discharged on his own demand despite suggested operative treatment.

One month after the surgery, he was re-hospitalized *via* emergency surgery unit due to similar symptomatology (fever and abdominal pain). US-guided puncture of liver abscess was made repeatedly, each time with complete aspiration of abscess content, with microbiologically verified *Streptococcus constelatus*. Specific antibiotic therapy was administered orally (clindamycin and amoxicillin with clavulanic acid). After one month of hospital treatment, the patient was discharged with satisfactory US findings.

On this hospitalization, the patient presented with axillary temperature of 37.5 °C. Peripheral blood leukocyte count was $10.2 \times 10^9/L$. Serum CRP concentration was 140 mg/L, gamma-glutamyltransferase 133 IU/L, amylase 152 IU/L, whilst other liver markers were within the normal range. During preoperative period, US-guided liver abscess puncture was performed, which revealed *Streptococcus* spp. Operative treatment was indicated. Operative approach was performed by “hockey-stick” incision in the right hypochondriac area. Exploration found extensive perihepatic adhesions, which were removed. An abscess, 7 cm in diameter, was visualized in hepatic segment VIII. Using Pringle maneuver for 27 minutes, segmentectomy of the hepatic segment VIII was carried out. After meticulous hemostasis and drain placement, the operation was finished.

The operation lasted for 120 minutes, without complications. During the operation, there was no extensive bleeding, thus there was no need for administration of blood transfusion and blood derivatives.

The postoperative course, with administration of antibiotic therapy (cefazolin 3x1 g and metronidazole 3x500 mg), was without complications. Abdominal drain was removed on postoperative day 3. The patient was discharged on postoperative day 7, with satisfactory laboratory findings. He regularly underwent follow up examinations, presenting with no symptoms. The last clinical examination was made one year after the surgery.

Discussion

Liver abscess, although not so frequent, still represents a serious hepatic disease with a high mortality rate (6%-14%)^{1,4}. Liver abscess is most frequently caused by bacteria (*Escherichia coli*, *Staphylococcus au-*

reus, *Streptococcus* and *Klebsiella pneumoniae*)¹. Biliary obstruction, cholangitis and diverticular disease are sometimes complicated by liver abscess⁵⁻⁷. Patients with verified liver abscess typically present with severe general condition, high body temperature (septic state), right subcostal pain, leukocytosis, elevated CRP and liver transaminases, thrombocytopenia and anemia.

Historically, the first treatment option was surgical (open surgical drainage)⁸. With further advancements in medicine, liver abscesses have been treated with percutaneous drainage and antibiotic therapy⁹. In the era of high resolution diagnostic methods (CT, US), percutaneous puncture/drainage and antibiotic therapy have become the gold standard in liver abscess treatment. Despite all this, open surgical approach (liver resection and drainage) still represents the only possible option in liver abscess treatment in some patients with complications, such as inadequate biliary drainage, chronic liver abscesses, intrahepatic stone disease, multiloculated cavities, central areas of necrosis, liver atrophy and location of the abscess in segments II and III¹⁰.

In the two cases presented, we encountered difficulties in liver abscess diagnosis and treatment. The patients initially presented with febrile state, leukocytosis and elevated CRP values. Liver transaminases were within the reference range, thus not indicating liver parenchyma lesion corresponding to liver abscess. Another major diagnostic difficulty was the inability to differentiate liver abscess and other focal liver parenchymal diseases (such as echinococcosis). This suggested that only early and justified percutaneous drainage, with imaging methods (US, CT, MRI) and microbiologic diagnosis can diagnose and differentiate with certainty liver abscess and other focal liver diseases.

In the cases presented, percutaneous drainage and laparoscopic approach were not successful, leaving open surgical approach (liver resection and drainage) as the only treatment option. This points to the fact that in some cases, only open surgical approach can verify and treat liver abscess. Naturally, perioperative antibiotic therapy remains an important aspect in liver abscess treatment.

In addition, the length of hospital stay and overall treatment costs, arising from difficulty in diagnosis

and treatment modality for liver abscess, also pose a major problem.

Although clinical studies give advantage to percutaneous puncture/drainage and antibiotic therapy as the gold standard in liver abscess treatment, open surgical treatment (liver resection and drainage) should be considered as sometimes the only option in diagnostic and therapeutic approach to liver abscess treatment.

References

1. CERWENKA H. Pyogenic liver abscess: differences in etiology and treatment in Southeast Asia and Central Europe. *World J Gastroenterol* 2010;16(20):2458-62.
2. VUČIČEVIĆ Z, SPAJIĆ B, BABIĆ N, DEGORICIJA V. Primary bilateral iliopsoas abscess in an elderly man. *Acta Clin Croat* 2012;51:83-7.
3. NG SSM, LEE JFY, LAI PBS. Role and outcome of conventional surgery in the treatment of pyogenic liver abscess in the modern era of minimally invasive therapy. *World J Gastroenterol* 2008;14(5):747-51.
4. YU SC, HO SS, LAU WY, YEUNG DT, YUEN EH, LEE PS, METREWELI C. Treatment of pyogenic liver abscess: prospective randomized comparison of catheter drainage and needle aspiration. *Hepatology* 2004;39: 932-8.
5. RINTOUL R, O'RIORDIAN MG, LAURENSEN IF, CROSBIE JL, ALLAN PL, GARDEN OJ. Changing management of pyogenic liver abscess. *Br J Surg* 1996;83:1215-8.
6. HUANG CJ, PITT H, LIPSETT P, *et al.* Pyogenic hepatic abscess: changing trends over 42 years. *Ann Surg* 1996;223:600-9.
7. CHOU F, SHEEN-CHEN SM, CHEN YS, CHEN MC. Single and multiple pyogenic liver abscesses: clinical course, etiology and results of treatment. *World J Surg* 1997;21:384-9.
8. OCHSNER A, DeBAKEY M, MURRAY S. Pyogenic abscess of the liver. II: An analysis of forty-seven cases with review of the literature. *Am J Surg* 1938;40:292-319.
9. CHEN SC, HUANG CC, TSAI SJ, YEN CH, LIN DB, WANG PH, CHEN CC, LEE MC. Severity of disease as main predictor for mortality in patients with pyogenic liver abscess. *Am J Surg* 2009;198:164-72.
10. CLARKE DL, CURRIE EJ, MADHAVAN KK, PARKS RW, GARDEN OJ. Hepatic resection for benign non-cystic liver lesions. *HPB* 2004;6:2:115-9.

Sažetak

JETRENI APSCES KAO TERAPIJSKI I DIJAGNOSTIČKI PROBLEM

M. Kolovrat, Ž. Bušić, D. Servis, A. Šitum i V. Čavka

Jetreni apscesi i dalje predstavljaju ozbiljan klinički entitet sa stopom smrtnosti i do 10%. Tradicionalno liječenje apscesa jetre je putem otvorenog kirurškog zahvata, iako se u posljednje vrijeme sve češće rabi perkutana ili laparoscopska drenaža. Usprkos tim načinima liječenja i sve boljim dijagnostičkim metodama apsces jetre ponekad nije jednostavno niti dokazati ni liječiti. Ovdje prikazujemo dva slučaja kroničnog apscesa jetre liječena na našem odjelu. U prvom slučaju bolesnik je bio u dva navrata hospitaliziran u drugim ustanovama pod dijagnozom jetrene ehinokoke. Kod nas je bio primljen zbog kliničke slike sepse. Cistična tvorba u jetri je dijagnosticirana kao apsces tek tijekom operacije. Učinjena je resekcija VII. segmenta jetre gdje se apsces nalazio. Drugi bolesnik je primljen nakon pokušaja laparoscopske drenaže i više pokušaja perkutane drenaže apscesa. U oba slučaja je učinjena segmentektomija jetre, što je dovelo do izlječenja bolesnika. Ova dva slučaja pokazuju kako kronični jetreni apscesi još uvijek ponekad predstavljaju dijagnostički i terapijski izazov.

Ključne riječi: *Apsces jetre; Kirurško liječenje*