

# EXPRESSION OF GROWTH HORMONE AND GROWTH HORMONE RECEPTOR IN FIBROADENOMAS OF THE BREAST

Tanja Leniček<sup>1</sup>, Dino Kasumović<sup>2</sup>, Emil Štajduhar<sup>3</sup>, Tihana Džombeta<sup>2</sup>, Zoran Jukić<sup>4</sup> and Božo Krušlin<sup>1,2</sup>

<sup>1</sup>Ljudevit Jurak Department of Pathology, Sestre milosrdnice University Hospital Center; <sup>2</sup>Department of Pathology, School of Medicine, University of Zagreb; <sup>3</sup>Department of Radiology, Sestre milosrdnice University Hospital Center, Zagreb; <sup>4</sup>Department of Surgery, Nova Gradiška General Hospital, Nova Gradiška, Croatia

**SUMMARY** – Fibroadenoma is the most prevalent benign breast tumor. It consists of epithelial and stromal components. In general, breast tumors are highly hormonally dependent and growth hormone by its physiology may have a possible oncogenic potential. Therefore, the aim of this study was to determine the expression of growth hormone and growth hormone receptor in epithelial and stromal components of fibroadenomas. Study group included 30 randomly chosen fibroadenomas from female patients aged between 18 and 69 years. The expression of growth hormone and growth hormone receptor was defined in both histologic components of fibroadenomas. Growth hormone was expressed in 96.7% of both epithelial and stromal components of fibroadenomas, with stronger expression in the stromal component. The same percentage of positive reaction (96.7%) was obtained in the epithelial component of fibroadenomas for growth hormone receptor expression. Only 6.7% of stromal components tested for growth hormone receptor were positive. The high expression of growth hormone and growth hormone receptor in fibroadenoma tissue indicates their possible role in the pathogenesis of this tumor. Follow up of patients with high expression of growth hormone and growth hormone receptor may be suggested.

**Key words:** *Fibroadenoma; Growth hormone; Growth hormone receptor*

## Introduction

Fibroadenoma is one of the most common causes of a benign lump in the breast<sup>1</sup>. It may occur at any age after puberty but is most frequent in the third decade<sup>1</sup>. Fibroadenoma presents as a painless, solitary, firm, slowly growing, mobile, well-defined nodule and less frequently it may appear in the form of multiple nodules. The admixture of stromal and epithelial proliferation gives rise to two distinct growth patterns of no clinical significance<sup>2</sup>. Both epithelial and stromal

components can show a wide spectrum of changes typically occurring at certain age, such as apocrine and squamous metaplasia in the epithelial component or focal and diffuse hypercellularity, extensive myxoid change and hyalinization with dystrophic calcification, or ossification in the stromal component<sup>2</sup>. Ductules vary in configuration; two classic patterns are described, intracanalicular when ductules are compressed by the stroma into clefts, and pericanalicular when the stroma appears to surround ductules in a circumferential fashion<sup>1</sup>.

Pituitary growth hormone (GH) acts on growth mainly through the regulation of the insulin-like growth factor (IGF) system<sup>3</sup>. It binds with the growth hormone receptor (GHR), thus inducing the production of IGFs (IGF-I and IGF-II) in the majority of

Correspondence to: *Božo Krušlin, MD, PhD*, Department of Pathology, School of Medicine, University of Zagreb, Šalata 10, HR-10000 Zagreb, Croatia  
E-mail: [krušlin@mef.hr](mailto:krušlin@mef.hr)

Received September 20, 2012, accepted May 5, 2013

organs and body tissues. These have autocrine, paracrine and endocrine actions on metabolism and cell proliferation, growth and differentiation<sup>3</sup>.

The evidence that GH, IGF-I and insulin can promote and contribute to cancer progression comes from various sources, including transgenic and knockout mouse models and animal and human cell lines derived from cancers<sup>4</sup>. Cullen *et al.*<sup>5</sup> report that IGFs are mitogens for many cancer cell types. In breast cancer cells, IGF-I and IGF-II have both been shown to stimulate cell proliferation<sup>5</sup>. Increased GHR level was found in colorectal carcinoma and other tumors including breast, squamous cell and basal cell carcinoma of the skin and melanoma but also preneoplastic lesions<sup>6-8</sup>.

There are also epidemiologic data supporting a link between GH/IGF status and cancer risk. Epidemiologic studies of patients with acromegaly showed an increased risk of colorectal cancer, although the risk of other cancers is unproven. Also, a long-term follow-up study of children deficient in GH treated with pituitary-derived GH has shown an increased risk of colorectal cancer<sup>9</sup>. The risk of prostate cancer is increased in men with elevated plasma IGF-I, and this association is particularly strong in younger men, suggesting that early pathogenesis of prostate cancer may be connected with circulating IGF-I plasma levels<sup>10</sup>.

The aim of this study was to determine the expression of GH and GHR in the epithelial and stromal components of fibroadenomas and to compare the results both between these two compartments and between fibroadenomas as a whole.

## Materials and Methods

The study was performed on archival material taken from the Ljudevit Jurak Department of Pathology, Sestre milosrdnice University Hospital Center. Study group included 30 randomly chosen fibroadenomas from female patients aged between 18 and 69 years. Specimens were fixed in 10% buffered formalin, embedded in paraffin, cut at 5- $\mu$ m thickness, and routinely stained with hematoxylin and eosin. The diagnosis of fibroadenoma was histologically confirmed in all cases.

Immunohistochemical staining for GH (DAKO, Denmark, dilution 1:400) and GHR (Novocastra, United Kingdom, dilution 1:100) was performed following LSAB visualization method on DakoTechMate™ automated machine for immunohistochemical

staining with streptavidin immunoperoxidase (MSIP protocol). The expression of GH and GHR was evaluated in both epithelial and stromal components of fibroadenomas. The area with the highest number of GH/GHR positive cells ('hot-spot') was selected under low magnification field (X40), and then the reaction was evaluated under high magnification (X400) in 1000 tumor cells.

The results of immunohistochemical staining were expressed semiquantitatively using the immunohistochemical staining index (ISI), obtained by multiplying the intensity of the staining reaction (IR) and the percentage of immunoreactive cells (PRC).

The intensity of the staining reaction was presented as follows: 0 for negative reaction; 1 for weakly positive reaction; 2 for moderately positive reaction; and 3 for very strong reaction. The percentage of immunoreactive cells was presented as follows: 0 for negative reaction; 1 for up to 20% of positive cells; 2 for more than 20% but less than 50% of positive cells; and 3 for over 50% of positive cells. According to the above mentioned conditions, four groups were established: ISI 0 – negative reaction; ISI 1 – weakly positive reaction (ISI product 1-3); ISI 2 – moderately positive reaction (ISI product 4-6); and ISI 3 – very strong reaction (ISI product 7-9).

## Results

Study results are presented in Table 1. In the epithelial component of fibroadenoma, GH was expressed in 29 of 30 samples (96.7%), with 7 samples showing

*Table 1. Immunohistochemical staining index (ISI) of growth hormone (GH) and growth hormone receptor (GHR) in epithelial and stromal components of fibroadenoma*

	GH, epithelium	GH, stroma	GHR, epithelium	GHR, stroma
ISI 0	1	1	1	28
ISI 1	9	0	7	2
ISI 2	13	9	14	0
ISI 3	7	20	8	0
Total	30	30	30	30

ISI 0 = negative reaction; ISI 1 = weakly positive reaction; ISI 2 = moderately positive reaction; ISI 3 = very strong reaction

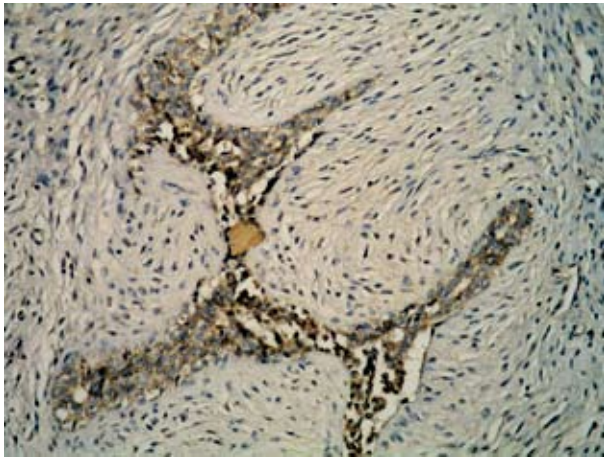


Fig. 1. Immunohistochemical staining, showing positive reaction for growth hormone in the cytoplasm of both epithelial and stromal components of fibroadenoma. (X200)

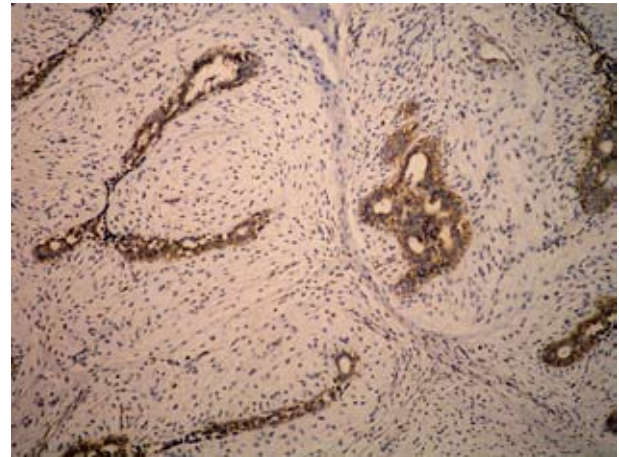


Fig. 2. Immunohistochemical staining showing positive reaction for growth hormone receptor in the cytoplasm of epithelial component of fibroadenoma. (X100)

very strong reaction, 13 samples moderately positive and 9 samples weakly positive reaction. In the stromal component of fibroadenoma, GH was expressed in 29 of 30 samples (96.7%), with 20 samples showing very strong reaction and 9 samples moderately positive reaction (Fig. 1). In the epithelial component of fibroadenoma, GHR was expressed in 29 (96.7%) of 30 samples, with 8 samples showing very strong reaction, 14 samples showing moderately positive reaction and 7 samples showing weakly positive reaction (Fig. 2). In the stromal component of fibroadenoma, GHR was practically not detected, with only 2 (6.7%) samples showing a weakly positive reaction. All positive reactions were observed in the cytoplasm of epithelial and stromal cells.

## Discussion

Like normal breast tissue, benign proliferations developing in breast are under a complex system of controls by both systemic hormonal and local factors<sup>11</sup>. Although there are several studies that investigated the expression of GH and GHR in fibroadenomas, none of them included both of these markers. It is likely that GH plays an important role in the development of fibroadenomas since a number of studies have demonstrated an association between the somatotrophic axis and the risk of developing tumors of the mammary gland<sup>5,6</sup>.

Some investigators focused on the local production of GH. In the study by Raccurt *et al.*<sup>12</sup>, in situ RT-PCR was used to detect GH mRNA in the tumoral and non-tumoral epithelial components and also in the cells of reactive stroma. The intensity of cellular labeling was always stronger compared with that in the adjacent normal tissue irrespective of the component observed<sup>12</sup>. GH protein was also present in a significantly higher concentration in proliferative disorders of the mammary gland compared with normal mammary gland<sup>12</sup>. Our study confirmed the high presence of GH in fibroadenomas.

Gil-Puig *et al.*<sup>13</sup> found the expression of Pit-1 mRNA and protein in both normal and tumorous human breast. The transcription factor pituitary-1 (Pit-1) is usually mainly expressed in the pituitary gland, where it has a critical role in cell differentiation and is a transcriptional factor for GH and prolactin (PRL). The Pit-1 mRNA levels were found to be significantly increased in breast carcinoma compared with normal breast<sup>13</sup>. The increase in the number of cancer cells in breast as a consequence of autocrine production of GH is a result of both increased mitogenesis and decreased apoptosis<sup>14</sup>. Mol *et al.*<sup>15</sup> have come to a conclusion that the gene encoding GH is expressed in the mammary gland of a variety of species, including human, and that this appears to represent a contribution to the molecular explanation of the role of progestins on proliferation of mammary epithelium. Briefly, there

is evidence that locally produced GH is involved in neoplastic changes in the breast. The study by Kaulsay *et al.*<sup>16</sup> showed that the effects of autocrine GH on human mammary carcinoma cell behavior are mediated *via* the GHR.

Mertani *et al.*<sup>17</sup> found the expression of GHR and prolactin receptor (PRLR) genes and their translation in epithelial cells of normal, proliferative and neoplastic lesions of the breast including fibroadenoma, where GHR was detected using immunohistochemistry both in the epithelial and stromal components. Stromal cells were found sometimes positive, but the labeling intensity was always weaker than for neoplastic epithelial cells, including fibroadenomas<sup>17</sup>. This correlates with our results where only 2 stromal samples of fibroadenoma tissue were positive for GHR compared to 29 positive epithelial samples. Gebre-Medhin *et al.*<sup>6</sup> demonstrated greater GHR expression in breast carcinoma than in normal breast tissue. Detecting the GHR by PCR, 75% of the samples (36 of 48) were evidently positive<sup>6</sup>.

Some studies were focused on circulating GH and/or IGF in order to unfold the pathogenesis of breast tumors. Hankinson *et al.*<sup>18</sup> and Toniolo *et al.*<sup>19</sup> found a positive correlation between circulating IGF-I concentration and the risk of breast cancer among premenopausal but not postmenopausal women. On the contrary, literature data show no statistically significant differences in the expression of estrogen and progesterone receptors in invasive ductal breast carcinoma between premenopausal and postmenopausal women<sup>20</sup>. The results obtained by Sawyer *et al.*<sup>21</sup> revealed IGF-I and IGF-II overexpression in fibroadenomas and the most similar phylloides tumors, which seems to be important in their pathogenesis.

In conclusion, it is obvious that there is stronger expression of GH and GHR in fibroadenomas and other tumorous breast tissues than in normal breast tissue, which was confirmed in this study. Our results show that there is a higher GH expression in the stromal than in the epithelial component of fibroadenoma. Likewise, GHR is mostly expressed in the epithelial component, while there is almost no expression in the stromal component, rendering epithelial component the probable main pathway for GH influence.

Based on our and previous studies, it can be concluded that the pathogenesis of breast tumors, such as

fibroadenoma, is highly hormone dependent. Follow up of patients with high expression of GH and GHR may be suggested. Further research in this area may hopefully lead us to more efficient hormonally dependent therapy.

#### Acknowledgment

This work was supported in part by the Ministry of Science, Education and Sports, Republic of Croatia, project number 108-1081870-1884.

#### References

1. ELLIS IO, PINDER SE, LEE AHS. Tumors of the breast. In: FLETCHER CDM, editor. Diagnostic histopathology of tumors, 3<sup>rd</sup> edn. Philadelphia: Churchill Livingstone, 2007;906-7.
2. TAN PH, TSE G, LEE A, SIMPSON JF, HANBY AM. Fibroepithelial tumors. In: LAKHANI SR, ELLIS IO, SCHNITT SJ, TAN PH, van de VIJVER MJ, editors. WHO classification of tumours of the breast, 4<sup>th</sup> edn. Lyon: International Agency for Research on Cancer, 2012;142-7.
3. MARTINELLI CE Jr, CUSTODIO RJ, AGUIAR-OLIVEIRA MH. Physiology of the GH-IGF axis. *Arq Bras Endocrinol Metab* 2008;52:717-25.
4. CLAYTON PE, BANERJEE I, MURRAY PG, RENEGHAN AG. Growth hormone, the insulin-like growth factor axis, insulin and cancer risk. *Nat Rev Endocrinol* 2011;7:11-24.
5. CULLEN KJ, ALLISON A, MARTIRE I, ELLIS M, SINGER C. Insulin-like growth factor expression in breast cancer epithelium and stroma. *Breast Cancer Res Treat* 1992;22:21-9.
6. GEBRE-MEDHIN M, KINDBLOM LG, WENNBO H, TORNEL J, MEIS-KINDBLOM JM. Growth hormone receptor is expressed in human breast cancer. *Am J Pathol* 2001;158:1217-22.
7. JUKIĆ Z, TOMAS D, MIJIĆ A, KRUSLIN B. Expression of growth hormone receptor and growth hormone in colorectal carcinoma. *Hepatogastroenterology* 2009;56:85-8.
8. GINARTE M, GARCIA-CABALLERO T, FERNANDEZ-REDONDO V, BEIRAS A, TORIBIO J. Expression of growth hormone receptor in benign and malignant cutaneous proliferative entities. *J Cutan Pathol* 2000;27:276-82.
9. JENKINS PJ, BESSER M. Clinical perspective: acromegaly and cancer: a problem. *J Clin Endocrinol Metab* 2001;86:2935-41.
10. STATTIN P, BYLUND A, RINALDI S, BIESSY C, DECHAUD H, STENMAN UH, EGEVAD L, RIBOLIE E, HALLMANS G, KAAKS R. Plasma insulin-like

- growth factor-I, insulin-like growth factor-binding proteins, and prostate cancer risk: a prospective study. *J Natl Cancer Inst* 2000;92:1910-7.
11. COURTILOT C, PLU-BUREAU G, BINART N, BALLEYGUIER C, SIGAL-ZAFRANI B, GOFFIN V, KUTTENN F, KELLY PA, TOURAINE P. Benign breast diseases. *J Mammary Gland Biol Neoplasia* 2005;10:325-35.
  12. RACCURT M, LOBIE PE, MOUDILOU E, GARCIA-CABALLERO T, FRAPPART L, MOREL G, MERTANI HC. High stromal and epithelial human GH gene expression is associated with proliferative disorders of the mammary gland. *J Endocrinol* 2001;175:307-18.
  13. GIL-PUIG C, SEOANE S, BLANCO M, MACIA M, GARCIA-CABALLERO T, SEGURA C, PEREZ-FERNANDEZ R. Pit-1 is expressed in normal and tumorous human breast and regulates GH secretion and cell proliferation. *Eur J Endocrinol* 2005;153:335-44.
  14. KAULSAY KK, MERTANI HC, TORNELL J, MOREL G, LEE KO, LOBIE PE. Autocrine stimulation of human mammary carcinoma cell proliferation by human growth hormone. *Exp Cell Res* 1999;250:35-50.
  15. MOL JA, van GARDEREN E, RUTTEMAN GR, RIJNBEEK A. New insights in the molecular mechanism of progestin-induced proliferation of mammary epithelium: induction of the local biosynthesis of growth hormone (GH) in the mammary glands of dogs, cats and humans. *J Steroid Biochem Mol Biol* 1996;57:67-71.
  16. KAULSAY KK, ZHU T, BENNETT W, LEE KO, LOBIE PE. The effects of autocrine human growth hormone (hGH) on human mammary carcinoma cell behavior are mediated *via* the hGH receptor. *Endocrinology* 2001;142:767-77.
  17. MERTANI HC, GARCIA-CABALLERO T, LAMBERT A, GERARD F, PALAYER C, BOUTIN JM, VONDERHAAR BK, WATERS MJ, LOBIE PE, MOERL G. Cellular expression of growth hormone and prolactin receptors in human breast disorders. *Int J Cancer* 1998;79:202-11.
  18. HANKINSON SE, WILLET WC, COLDITZ GA, HUNTER DJ, MICHAUD DS, DEROO B, ROSNER B, SPEIZER FE, POLLAK M. Circulating concentrations of insulin-like growth factor-I and risk of breast cancer. *Lancet* 1998;351:1393-406.
  19. TONIOLO P, BRUNING PF, AKHMEDKHANOV A, BONFRER JM, KOENIG KL, LUKANOVA A, SHORE RE, ZELENIUCH-JACQUOTTE A. Serum insulin-like growth factor-I and breast cancer. *Int J Cancer* 2000;88:828-32.
  20. PETRIČEVIĆ J, PETKOVIĆ M, JONJIĆ N. Expression of estrogen and progesterone receptors in human ductal invasive breast carcinoma not otherwise specified: is there any difference between premenopausal and postmenopausal women? *Acta Clin Croat* 2011;50:169-75.
  21. SAWYER EJ, HANBY AM, POULSOM R, JEFFERY R, GILLET CE, ELLIS IO, ELLIS P, TOMLINSON IP. Beta-catenin abnormalities and associated insulin-like growth factor overexpression are important in phyllodes tumours and fibroadenomas of the breast. *J Pathol* 2003;200:627-32.

### Sažetak

#### EKSPRESIJA HORMONA RASTA I RECEPTORA HORMONA RASTA KOD FIBROADENOMA DOJKE

*T. Leniček, D. Kasumović, E. Štajduhar, T. Džombeta, Z. Jukić i B. Krušlin*

Fibroadenom je najčešća dobroćudna novotvorina dojke, a sastoji se od epitelne i stromalne komponente. Uzimajući u obzir hormonsku osjetljivost tumora dojke, te potencijalni onkogeni potencijal hormona rasta, cilj našega rada bio je utvrditi ekspresiju hormona rasta i receptora hormona rasta u epitelnoj i stromalnoj komponenti fibroadenoma. U studiju je bilo uključeno 30 nasumice odabranih fibroadenoma nastalih u žena u dobi od 18 do 69 godina. Ekspresija hormona rasta i receptora hormona rasta određivana je u obje histološke komponente fibroadenoma. Ekspresija hormona rasta nađena je u 96,7% epitelne i stromalne komponente, uz jaču izraženost ekspresije u stromalnoj komponenti. Ekspresija receptora hormona rasta u epitelnoj je komponenti također iznosila 96,7%, a u stromalnoj samo 6,7%. Visoka ekspresija hormona rasta i receptora hormona rasta u fibroadenomima označava potencijalnu ulogu ovoga hormona u patogenezi ispitivane bolesti, te bi se u bolesnica ove skupine mogle preporučiti češće kliničke kontrole.

*Ključne riječi: Fibroadenom; Hormon rasta; Receptor hormona rasta*

