

## Case Report

Neuro-  
degenerative  
Diseases

Neurodegenerative Dis 2005;2:56–60  
DOI: [10.1159/000089284](https://doi.org/10.1159/000089284)

Received: June 13, 2005  
Accepted after revision: July 26, 2005

# Evidence of a Genetic Basis of Morgagni-Stewart-Morel Syndrome

## A Case Report of Identical Twins

Michael F. Koller<sup>a,b</sup> Andreas Papassotiropoulos<sup>a</sup> Katharina Henke<sup>a</sup>  
Britta Behrends<sup>a</sup> Shigeru Noda<sup>a</sup> Adelgunde Kratzer<sup>b</sup> Christoph Hock<sup>a</sup>  
Marc Hofmann<sup>a</sup>

<sup>a</sup>Division of Psychiatry Research and <sup>b</sup>Institute of Legal Medicine, University of Zürich, Zürich, Switzerland

### Key Words

Hyperostosis frontalis interna · Obesity · Seizure ·  
Dementia · Cognitive impairment · Twins ·  
Monozygotic · Neuropsychology · Morgagni-Stewart-  
Morel

### Abstract

We report two 71-year-old female monozygotic twins presenting with advanced hyperostosis frontalis interna, obesity, shortness and cognitive impairment. They both have suffered from generalized seizures since their early adulthood. Moreover, the patients showed some additional conditions only occurring in one individual or the other such as migraine, marked recurrent depressive disorder or polyarthrosis. The symptoms common to both twins appear to correspond to the Morgagni-Stewart-Morel syndrome and indicate a genetic basis of this disorder as these features occur in genetically identical patients.

Copyright © 2005 S. Karger AG, Basel

### Introduction

Hyperostosis frontalis interna (HFI) is a thickening of the inner table of the frontal bone. It is mainly diagnosed in elderly women and is an age-dependent process. In a population of European American females, studied by Hershkovitz et al. [1], 8–19% of over 70-year-old women showed advanced HFI. The pathogenesis remains unclear; some authors believe HFI to be caused by increased leptin levels or prolonged estrogen stimulation [1–3].

HFI may occur as an independent entity. However, it is often associated with other conditions and may be part of several syndromes such as the Morgagni-Stewart-Morel (MSM) syndrome, the most current features of which are HFI, obesity, hirsutism and neuropsychiatric or metabolic disorders like diabetes mellitus.

In this case report, we present two monozygotic twins suffering from marked HFI, generalized seizures, cognitive impairment, obesity and shortness, suggesting a genetic background of this symptom complex. In addition to these common disturbances, the patients show some interindividually differing features demonstrating phenotypic variability in these genetically identical twins.

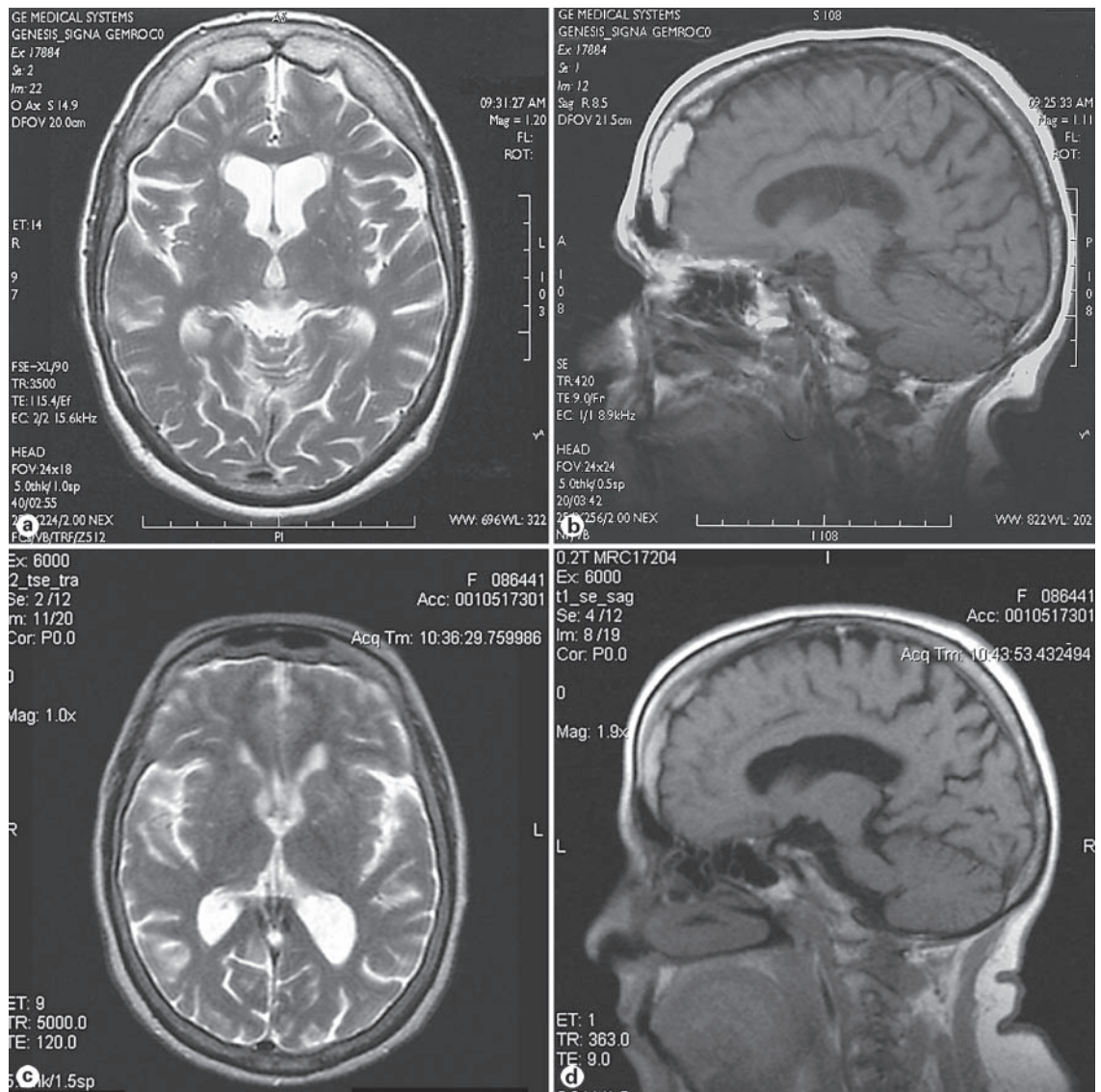
### KARGER

Fax +41 61 306 12 34  
E-Mail [karger@karger.ch](mailto:karger@karger.ch)  
[www.karger.com](http://www.karger.com)

© 2005 S. Karger AG, Basel  
1660-2854/05/0022-0056\$22.00/0

Accessible online at:  
[www.karger.com/ndd](http://www.karger.com/ndd)

Dr. Michael F. Koller  
Institute of Legal Medicine, University of Zürich  
Winterthurerstrasse 190  
CH-8057 Zürich (Switzerland)  
Tel. +41 44 635 56 11, Fax +41 44 635 68 51, E-Mail [miko1@gmx.ch](mailto:miko1@gmx.ch)



**Fig. 1.** Cranial MRI scans from twin 1 (**a, b**) and cranial open MRI scans from twin 2 (**c, d**). **a, c** Axial T<sub>2</sub>-weighted MRI scans with gadolinium. **b, d** Sagittal T<sub>1</sub>-weighted MRI scans. **a, b** Bilateral thickening of the inner layer of the frontal bone with oppression of the forebrain. White matter lesions, predominantly in the frontal lobe. Moderate cortical atrophy. **c, d** Bilateral thickening of the inner layer of the frontal bone, no clear cortical atrophy.

## Case Reports

The index subject (twin 1), a 71-year-old widowed mother of one daughter, was admitted to the Inpatient Unit of the Division of Psychiatry Research, Psychiatric University Hospital Zurich, with dementia accompanied by behavioral symptoms such as aggression and confusion. Symptoms of dementia had evolved over the preceding 9 years. The patient had suffered from epilepsy with generalized tonic-clonic seizures since the age of 15 years. Anticonvulsive treatment with phenobarbital was initiated at the age of 27 and continued until the present. At the age of 51, valproic acid was

added. Upon admission, the patient received phenobarbital (100 mg/day), valproic acid (800 mg/day) and olanzapine (15 mg/day), the latter because of behavioral abnormalities. She had been seizure free over the past 5 years. Physical examination showed obesity (74.5 kg, 144 cm, body mass index, BMI, 35.9) and dysmorphic features. The findings of the examination of the cardiovascular system were unremarkable. There were no focal neurological signs and symptoms. The patient suffered from polyarthrosis, psoriasis, prurigo and urine incontinence. Hematological examination and urine analysis were normal. Blood chemistry and hormone testing showed hyperprolactinemia, hyperlipidemia and slight hyperglyce-

mia. Anti-*Borrelia* antibodies and *Treponema pallidum* testing were negative. Normal blood concentrations were obtained for vitamin B<sub>12</sub>, folate, free T<sub>3</sub>, free T<sub>4</sub>, cortisol, testosterone, free testosterone, dihydrotestosterone, androstenedione and dehydroepiandrosterone sulfate. Cerebrospinal fluid examination showed slightly increased liquor pressure (18 cm H<sub>2</sub>O) but was otherwise normal. EEG was abnormal with increased delta wave activity and seizure-associated sporadic bifrontal spike activity. Cranial magnetic resonance imaging (MRI; fig. 1a, b) revealed symmetric thickening of the inner table of the frontal bone, generalized cerebral atrophy and moderate vascular white-matter lesions. The patient was in an affectively labile state but not depressed (Montgomery Asberg Depression Scale, MADRS, 9/60) [4]. She showed markedly impaired cognitive performance (Mini Mental State Examination, MMSE, 16/30) [5]. Neuropsychological assessment using the CERAD test battery [6] yielded a severe impairment of verbal and nonverbal learning and retrieval, extremely weak lexical and associative semantic memory and massively reduced executive functions (verbal and nonverbal fluency, conceptual thinking and cognitive flexibility). The patient was not properly oriented with respect to time, place, situation and to herself. Moreover, she exhibited dyscalculia, dyslexia and mild difficulties in language comprehension. There were also signs of a visual apperceptive agnosia. These impairments clearly exceeded those commonly observed in relation to epilepsy or phenobarbital intake [7, 8] and were rather indicative of moderate dementia according to the DSM-IV criteria (Diagnostic and Statistical Manual of Mental Disorders, 4th edition). After admission, phenobarbital and olanzapine were discontinued, valproic acid was increased to 1,000 mg/day. This change in pharmacotherapy management led to a marked amelioration of the confusional state and of the aggressive behavior. Dementia, however, persisted unchanged, and the patient had to be discharged into a nursing-home.

The index patient's twin sister (twin 2), a married mother of three healthy children, was recruited at the same time for ambulant clinical examination. She reported a similar medical history as her sister with generalized epileptic seizures since the age of 18. She had been treated with anticonvulsants since the age of 27. At the time of this examination, she was receiving phenobarbital at 100 mg/day and valproic acid at 800 mg/day and had been free of seizures for the past 4 years. A standard EEG recorded 2 years before this examination failed to reveal epileptic activity. In her thirties, the patient developed recurrent depressive disorder leading to psychiatric hospitalization, and in her forties she developed frontal migraine-like headaches. The current physical examination showed obesity (60 kg, 141.5 cm, BMI 30.0) but was otherwise normal. She showed some moderate behavioral symptoms such as disinhibition and logorrhea typically observed along with prefrontal dysfunctions, but no signs of depression (MADRS 8/60) [4]. Her cognitive abilities were impaired with an MMSE score of 21/30 [5]. She was fully oriented. The neuropsychological assessment (CERAD battery) [6] revealed discrete difficulties with nonverbal episodic memory. Yet, verbal episodic memory was normal. Regarding executive functions, she exhibited mildly reduced conceptual thinking abilities and a more clearly reduced verbal and nonverbal fluency. Her visuoconstructive abilities were also mildly diminished. This pattern of dysfunction and the progression of these symptoms were suggestive of beginning dementia. Cranial MRI (fig. 1c, d) showed bilateral HFI but no clear brain atrophy. Hematology, blood chemistry and urine analysis were normal; hormone levels were not determined.

The twins' parents, two sisters (83 years, 82 years) and one brother (60 years) were reported free of epilepsy. The index patient's daughter (35 years) has suffered from generalized seizures since early adulthood. The twin sister's children (a son 50 years of age, two daughters 49 and 46 years of age) were reported healthy. In the distant maternal lineage, two members are known to have suffered from seizures. In the father's family, no epileptic disorders are known.

To assess whether the twin sisters are genetically identical, a DNA profile for determination of monozygosity was done. Examination of 17 highly polymorphic DNA markers (D3S1358, TH01, D21S11, D18S51, Penta E, D5S818, D13S317, D7S820, D16S539, CSF1P0, Penta D, VWA, D8S1179, TPOX, FGA, D2S1338, D19S433) showed that the sisters were monozygotic twins [9, 10].

## Discussion

We report advanced HFI accompanied by generalized seizures, obesity, shortness and cognitive impairment in 71-year-old female monozygotic twins. The index patient (twin 1) was admitted to the Psychiatric University Hospital Zurich for an inpatient investigation and treatment of dementia, aggressivity and confusion. Twin 2 was invited for an ambulant examination at the same time as her sister was hospitalized which allowed us to make a comparison between these two genetically identical sisters.

The sisters have suffered from generalized seizures and have received anticonvulsive medication since their early adulthood. They have been free of seizures for several years. Epilepsy has been reported to occur in several female members of the maternal line of the family suggestive of a genetic basis of the seizures. Yet, we are not able to describe the mode of transmission.

HFI and obesity were more pronounced in twin 1 than in twin 2 (table 1). The index patient was moderately demented with cerebral atrophy and showed frontal dysfunctions as shown in the neuropsychological assessment. Moreover, she displayed dysmorphic features, polyarthrosis, psoriasis, hyperprolactinemia, hyperlipidemia and slight hyperglycemia. Upon changing medication, behavioral abnormalities such as aggressivity and confusion decreased while dementia persisted. Therefore, she had to be discharged from hospital to a nursing-home. Neuropsychological assessment of her sister revealed only mild dementia with diminished executive functions, episodic memory and visuoconstructive skills. The sister exhibited no cerebral atrophy. She has suffered from migraine and marked recurrent depressive disorder for decades. Altogether, the inpatient was physically and mentally more impaired than her sister, despite their ge-

**Table 1.** Pathological features

	Twin 1	Twin 2
HFI	+++	++
Obesity	+++	++
Generalized epilepsy	+++	+++
Cognitive impairment	++	+
Frontal dysfunctions	+++	++
Cortical atrophy	++	–
Shortness	++	++
Recurrent depressive disorder	–	++
Migraine	–	++
Dysmorphic features	++	–
Polyarthrosis	++	–
Metabolic disorders	+	–

Semiquantitative estimates: – = absent; + = mild; ++ = marked; +++ = severe.

netical identity. The reason for the phenotypic variability may lie either in different environmental factors such as lifestyle or nutrition, in mosaicism occurring in monozygotic twins or in a more complex polygenetic etiology. Unfortunately, we do not know about HFI and the other features mentioned above in the family members as we did not have the opportunity to examine them. The neuropsychological assessments of the twins indicative of prefrontal dysfunctions are in line with the literature of prefrontal dysfunctions. These might be a consequence of the compression of the prefrontal cortex by the thickening frontal bone in HFI [11, 12]. If HFI is also the reason for dementia remains unclear since – to our knowledge – such a relationship has never been observed. Neither are epilepsy or the antiepileptic treatment [7, 8] reasonable causes of dementia. Instead, we believe that dementia and the other symptoms in our twins are part of an MSM syndrome – a syndrome with a controversial history.

HFI was first described by Morgagni in the 18th century in an elderly obese and virilized woman [13]. This first report was followed by numerous further publications on this condition where HFI was both described as an independent entity and as part of a syndrome including obesity, hirsutism and metabolic or neuropsychiatric disorders like seizures. The terminology of the syndrome is variable: it has been referred to as MSM syndrome, metabolic craniopathy, Morel-Moore syndrome etc. The definition of the syndrome remains nonuniform both due to the diversity of the reported associated symptoms and

to the variable penetrance of the condition; not all symptoms have to be present for the diagnosis of the syndrome; e.g. signs of hirsutism have often been reported to be very mild or even absent [14, 15] – as in our patients. Some authors [1, 2] doubt the existence of the syndrome *sui generis* because certain symptoms of the MSM syndrome may occur as independent entities in elderly women and because the syndrome is ill defined. These authors claim that the combination of the symptoms is accidental. This notion is not consistent with the first signs of the syndrome being present at the age of puberty. Also, it conflicts with the findings of numerous authors who observed the symptom complex in several members of a single family. Klein et al. [15] and Rosatti [16] examined an affected family over four generations and postulated an autosomal-dominant or X-linked mode of inheritance with variable and incomplete penetrance. The existence of a hereditary syndrome is supported by its occurrence in monozygotic twins, such as reported here. The coincidence of the conspicuous conditions in our twins is unlikely to be accidental because some of the observed features are infrequent, e.g. familial seizures, advanced HFI which only occurs in 8–19% of women over 70 years old [1], a BMI of over 30 which is found in only 10% of Swiss females between 35 and 74 years [17] and a body height of less than 145 cm which is far below the mean of the Swiss female height standard of 165 cm (SD 6 cm) [18]. It is hard to say whether the seizures appeared as part of the MSM syndrome or as a nonassociated second hereditary illness. Anyhow, seizures have been described as part of the MSM syndrome [16]. The same goes for hyperprolactinemia, as observed in twin 1, which may both be a symptom of the MSM syndrome and a side effect of olanzapine, an antipsychotic twin 1 was treated with.

To summarize, this case report adds evidence for the validity of the MSM syndrome and for its inheritance with an incomplete penetrance.

### Acknowledgements

We thank Christin Wilde and Esmeralda Garcia for their support as study nurses, Drs. Rolf Nagel, Wolf Schweitzer, Johannes Streffer and Pascal Py for their technical help and Prof. Philipp Christen for critical reading of the manuscript.

## References

- 1 Hershkovitz I, Greenwald C, Rothschild BM, Latimer B, Dutour O, Jellema LM, Wish-Baratz S: Hyperostosis frontalis interna: an anthropological perspective. *Am J Phys Anthropol* 1999;109:303–325.
- 2 She R, Szakacs J: Hyperostosis frontalis interna: case report and review of literature. *Ann Clin Lab Sci* 2004;34:206–208.
- 3 Ruhli FJ, Henneberg M: Are hyperostosis frontalis interna and leptin linked? A hypothetical approach about hormonal influence on human microevolution. *Med Hypotheses* 2002;58:378–381.
- 4 Montgomery SA, Asberg M: A new depression scale designed to be sensitive to change. *Br J Psychiatry* 1979;134:382–389.
- 5 Folstein MF, Folstein SE, McHugh PR: 'Minimal state': a practical method for grading the cognitive state of patients for the clinician. *J Psychiatr Res* 1975;12:189–198.
- 6 Morris JC, Heyman A, Mohs RC, Hughes JP, van Belle G, Fillenbaum G, Mellits ED, Clark C: The Consortium to Establish a Registry for Alzheimer's Disease (CERAD). I. Clinical and neuropsychological assessment of Alzheimer's disease. *Neurology* 1989;39:1159–1165.
- 7 Bermejo F, Benito J, Pena P: Epilepsy and dementia: an atavistic association. *Rev Neurol* 1996;24:392–396.
- 8 Jokeit H, Ebner A: Long-term effects of refractory temporal lobe epilepsy on cognitive abilities: a cross sectional study. *J Neurol Neurosurg Psychiatry* 1999;67:44–50.
- 9 Cotton EA, Allsop RF, Guest JL, Frazier RRE, Koumi P, Callow IP, Seager A, Sparkes RL: Validation of the AMPF/STR<sup>®</sup> SGM<sup>™</sup> Plus system for use in forensic casework. *Forensic Sci Int* 2000;112:151–161.
- 10 Krenke BE, Tereba A, Anderson SJ, Buel E, Culhane S, Finis CJ, Tomsey CS, Zachetti JM, Masibay A, Rabbach DR, Amriott EA, Sprecher CJ: Validation of a 16-locus fluorescent multiplex system. *J Forensic Sci* 2002;47:773–785.
- 11 de Zubicaray GI, Chalk JB, Rose SE, Semple J, Smith GA: Deficits on self ordered tasks associated with hyperostosis frontalis interna. *J Neurol Neurosurg Psychiatry* 1997;63:309–314.
- 12 Paulus KS, Magnano I, Aiello I, Sechi GP, Rosati G, Casu AR, Piras MR, Cherchi R, Sotgiu S: P300 and executive function alterations: possible links in a case of Morgagni-Stewart-Morel syndrome. *Neurol Sci* 2002;22:459–462.
- 13 Morgagni GB: De sedibus et causis morborum per anatomen indagatis. Liber secundus de morbis thoracis. *Epistola anatomico-medica XXVII*. Padua, 1761.
- 14 Knies PT, Le Fever HE: Metabolic craniopathy: hyperostosis frontalis interna. *Ann Intern Med* 1941;14:1858–1892.
- 15 Klein D, Rosatti P, Mach RS, Ferrier PE, Rauch S: Morgagni-Morel syndrome: an independent clinical and genetic entity, demonstrated in a family study covering 4 generations. *Schweiz Arch Neurol Neurochir Psychiatr* 1973;112:239–250.
- 16 Rosatti P: Family affected by hyperostosis frontalis interna (Morgagni-Morel syndrome) through 4 successive generations. *J Genet Hum* 1972;20:207–252.
- 17 Luong B-L, Beer-Borst S, Morabia A: Übergewicht, Adipositas und zu geringes Körpergewicht in Genf: Ergebnisse der Studie Bus Santé, 1993–2001. *Bull Bundesamt für Gesundheitswesen* 2003;38:659.
- 18 Prader A, Largo RH, Molinari L, Issler C: Physical growth of Swiss children from birth to 20 years of age. First Zurich longitudinal study of growth and development. *Helv Paediatr Acta Suppl* 1989;52:1–125.