

Article IX. — ADAPTIVE SIGNIFICANCE OF THE
SHORTENING OF THE ELEPHANT'S SKULL.

BY W. K. GREGORY.

PLATE XXIII AND 4 TEXT FIGURES.

The following observations were made in connection with Professor Osborn's forthcoming memoir on American fossil Proboscidea, for which were also prepared the figures here used by his kind permission.

Weithofer¹ regards the changes in the elephant's skull observable during individual growth as well as in phylogeny, such as the compression and vertical heightening and deepening of the skull, the wide separation of the inner and outer tabulæ of the bones, and the cancellous condition of the diploë, the forward shifting of the orbits from a point above the anterior grinders, etc., as primarily correlated with the prodigious development of the tusks — weapons and crow-bars whose effectiveness increased with and reciprocally hastened the phyletic advance in body dimensions. Now the earliest known proboscideans (*Meritherium*) possessed upper as well as lower incisor tusks, and there are other grounds also for inferring that the ancestors of *Dinotherium* probably possessed upper incisor tusks of small size, even smaller than in the primitive *Mastodon* (*Trilophodon euhypodon*); the presence of these may have initiated the shortening of the head, but the final compression of the skull in *Dinotherium* progressed notwithstanding the reduction and entire disappearance of upper tusks, and this, together with the underlying similarity of its skull to that of *Mastodon* and of *Elephas*, shows that some other factor must also be represented in the extraordinary end results of the process of fore-and-aft compression.

This factor seems to be the development of the proboscis. This unique organ probably owes its existence partly to the shortening reach of the head and neck which took place

¹ Die Fossilen Proboscidier des Arnothales in Toskana. 4to, Wien, 1890.

simultaneously with increasing stature and longer limbs, partly to the necessity of reaching outside the lengthening tusks, partly to the intrinsic advantages of a prehensile organ of such manifold possibilities. On the one hand, we may suppose, the enlargement of the trunk intensified the changes due to the shifting and enlargement of the tusks, and on the other hand inaugurated many of the peculiar conditions described below.

The backward shifting of the weighty tusks and trunk, compensating their adverse leverage, lessened the antero-posterior space available for the grinding series, while the work put upon the individual grinders increased with larger bodies and longer lives. This may explain in part why the simple grinders of *Dinotherium*, with their two, or at most three, low, widely separated ridges, were constrained to evolve into the wonderfully specialized and effective grinders of the Mammoth; with ridges in great number, exceedingly high, and closely appressed, and in which there is a so-called horizontal succession in use, the unworn teeth being pushed into place from behind. The weighty, rapidly heightening molars, together with their immense, backward and upwardly growing alveolar pouch, might thus be regarded as a third factor in the evolution and individual growth history of the skull. It is plain, however, that this factor was a minor one and that the characteristic features of the skull were attained, in great part, before the teeth had become so highly specialized; for the typical *Mastodon americanus*, with its great size, and great tusk-and-trunk development, shows nearly the same degree of backward and downward extension of the posterior nares and hard palate as in *Elephas*, yet retains comparatively primitive low-crowned grinders, and the considerable space between the posterior border of the last molar and the posterior lateral limits of the hard palate in this genus was not nearly so much utilized for storing incoming grinders as it is in *Elephas*.

Principally then, to the enlargement and backward shifting of the trunk and tusks and the consequent fore-and-aft compression of the whole skull, combined with the progressively

widening separation of the inner and outer surfaces of the bones for the sake of lightness and large area for the head muscles, we may ascribe the following morphological conditions, which attain the extreme of specialization in the skull of the Mammoth. In the inferior view of the skull the hard palate, contrary to what obtains in most Ungulates, is tilted somewhat upward; the palatines become reduced antero-posteriorly and shoved backward so as to diverge widely posteriorly; the posterior nares, probably *pari passu* with the anterior nares, have been pushed very far back¹; the enormous vertical pterygoid wing of the alisphenoid wraps itself around and functionally replaces the hinder end of the encroaching molar-tooth pouch; the foramen ovale of the alisphenoid, which in the most primitive Ungulates is anterior to the foramen lacerum medius, has been shifted obliquely backward and outward, and becomes confluent with it externally (Fig. 1)²; the presphenoid, basisphenoid, basioccipital thicken in the median plane and at diminishing rates, the lower tabulæ of these bones growing downward to a less and less extent as we pass backward, so that in the adult the inferior surface of the basis cranii points sharply downward, and forms, with the plane of the back of the occiput, an angle greater than 90°; the tympanic bullæ, relatively large and inflated in the young, flatten down and become closely appressed to the skull, pointing obliquely downward, forward, and inward, with the wider end toward the transversely expanded occipital region (Fig. 1, *Ty.*). In brief, the progressive brachycephaly of the skull has apparently involved not so much a fore-and-aft shortening of the individual elements as a readjustment and modification of them, and secondly an expansion in the transverse vertical planes.

The shortening and deepening of the temporal fossæ, and perhaps to some extent the above-mentioned expansion of

¹ Among the Glyptodonts a similar backward and downward growth of the palate and posterior nares seems to be correlated chiefly with the shortening of the skull, as the anterior nares remain terminal.

² This change must have taken place at a very early date in the history of the Proboscidea, as it is already established in the primitive *Mastodon* (*Trilophodon*) *productus* and also, if Kaup's figures are here rightly interpreted, in *Dinotherium*.

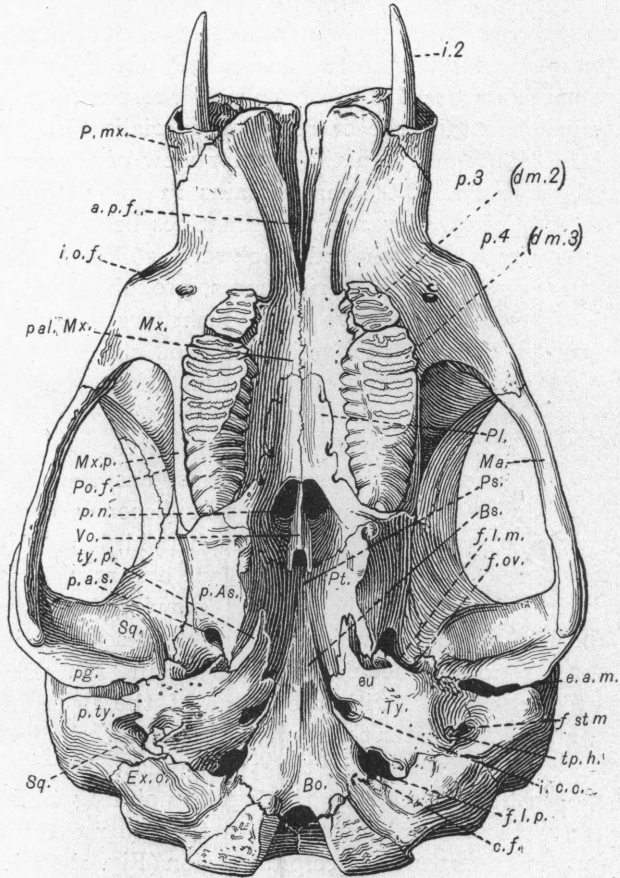


Fig. 1. Inferior view of the skull of a young Asiatic elephant. About $\frac{1}{2}$ nat. size. From a forthcoming memoir by Professor Osborn.

P. mx.—Premaxillary.
Mx.—Maxillary.
Mx. p.—Maxillary pouch for molars.
Ma.—Malar.
Po. f.—Postorbital ridge of frontal.
pal. Mx.—Palatine ledge of maxillary.
Pl.—Palatine.
Vo.—Vomer.
Ps.—Presphenoid.
Bs.—Basisphenoid.

ty. p.—Anterior process of tympanic.
tp. h.—Tympanohyal.
eu.—Eustachian opening of tympanic.
a. p. f.—Anterior palatine foramina (canals).
i. o. f.—Infraorbital foramen.
p. n.—Posterior nares.
p. a. s.—Alisphenoid canal.

i. 2.—Tusk.

p.³ (dm2).—Third premolar (or second deciduous molar of authors).
p.⁴ (dm3).—Fourth premolar (or third deciduous molar of authors).

BONES.

Bo.—Basioccipital.
p. As.—Pterygoid wing of alisphenoid.
Pt.—Pterygoid.
Sq.—Squamosal.
Ex. o.—Exoccipital.
Ps.—Postglenoid ledge of squamosal.
p. ty.—Posttympanic ledge of squamosal, which with *fg.* forms a secondary external auditory meatus.
Ty.—Tympanic bulla.

FORAMINA, ETC.

f. l. m.—Foramen lacerum medius.
f. ov.—Foramen ovale (confluent with *f. l. m.*)
i. c. c.—Canal for internal carotid artery.
f. st. m.—Stylomastoid foramen.
f. l. p.—Foramen lacerum posterius.
c. f.—Notch, a vestige of condylar foramen (?) (confluent with *f. l. p.*).

TEETH.

the grinders and their alveolar pouch, have had a marked effect on the relations of the bones and foramina of the sphenoidal region: the obliquely placed external portion of the orbito sphenoid (Fig. 2); has been squeezed into a long,

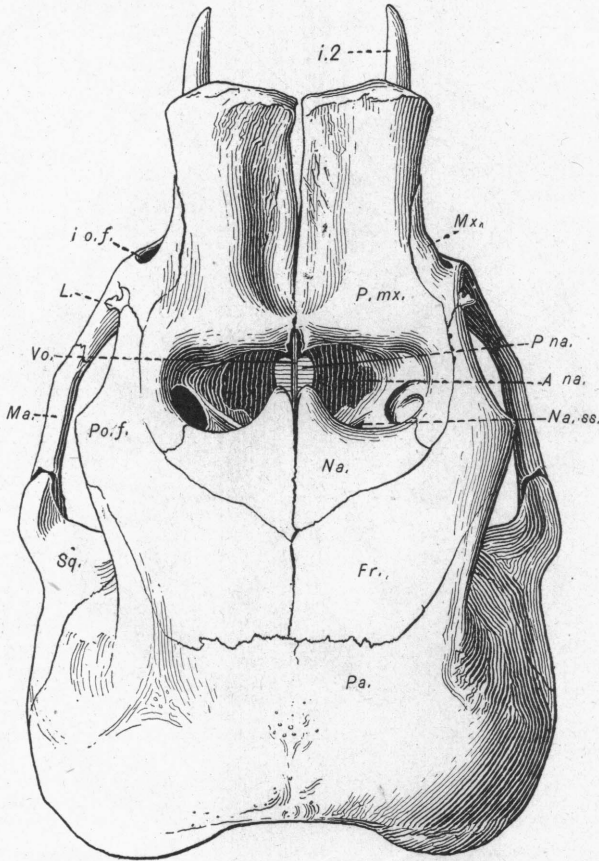


Fig. 2. Superior view of the same skull. From Osborn. Abbreviations as above; also *La.*—Lachrymal. *A. na.*—Anterior nares. *Na. s.*—Narial sinus.

thin process; internally (Pl. xxiii) the anterior edges of the basisphenoid are directed outward and backward; both internally and externally the optic foramen, foramen lacerum anterius, and foramen rotundum, in the order named, are

obliquely arranged on descending levels from within outward and from in front backward, the whole region having been thickened by the separation of the inner and outer tabulæ of

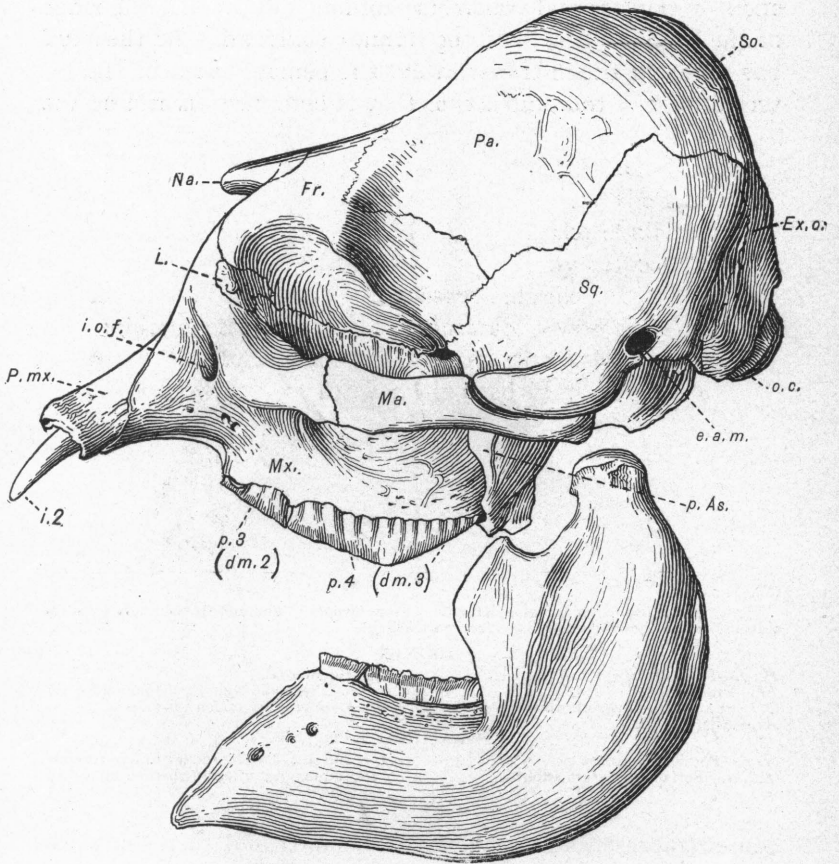


Fig. 3. Side view. From Osborn.

all the bones, and also sharing in the upward-and-backward tilting of the nasal region and in the general fore-and-aft squeezing of the skull, the end result being that the foramina have been pulled out into long tunnels running obliquely for-

ward, outward, and downward; especially internally the fore-and-aft extent of the alisphenoid proper is brief.

Internally the skull has shortened up, one might almost say in bellows fashion, with the optic foramen on each side at the apex of the internal transverse folding (Pl. xxiii), the ridge of the "lesser wing" of the human sphenoid. As the skull has also expanded transversely, the general effect of the internal view of the skull is thus that of compression around the

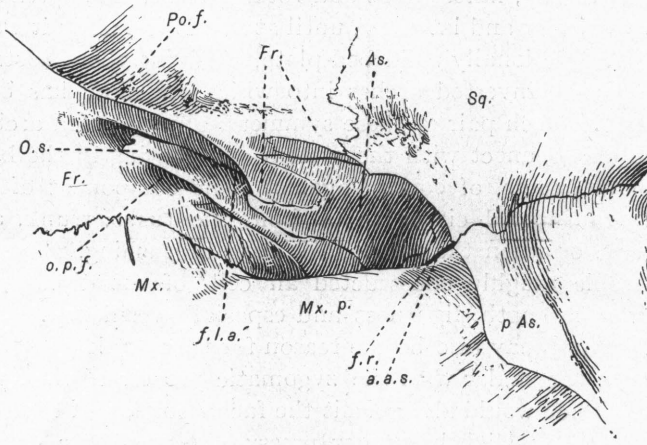


Fig. 4. Orbito-sphenoidal region, left side. From Osborn. The view is obliquely from the side and from below the malar bone (compare Fig. 3).

BONES.

- Po. f.*—Post-orbital ridge of frontal.
- Fr.*—Frontal.
- O. s.*—External process of orbitosphenoid.
- As.*—Alisphenoid.
- Sq.*—Squamosal.
- p. As.*—Pterygoid wing of alisphenoid.
- Mx. p.*—Maxillary pouch for molars.

FORAMINA, ETC.

- o. p. f.*—Foramen opticum.
- f. l. a.*—Foramen lacerum anterius.
- f. r.* and *a. a. s.*—Arcade leading to foramen rotundum and anterior opening of the alisphenoid canal.

center (represented by the basisphenoid) and increasing expansion toward the periphery — somewhat recalling the conditions of the domelike human skull. Between the frontal and temporo-sphenoidal fossæ, which form a large trefoil as seen from above, there is on each side, running obliquely outward, forward, and upward, a prominent triangular buttress, the transverse ridge mentioned above, to the formation of which the orbitosphenoid, frontal, and parietal contribute. On each

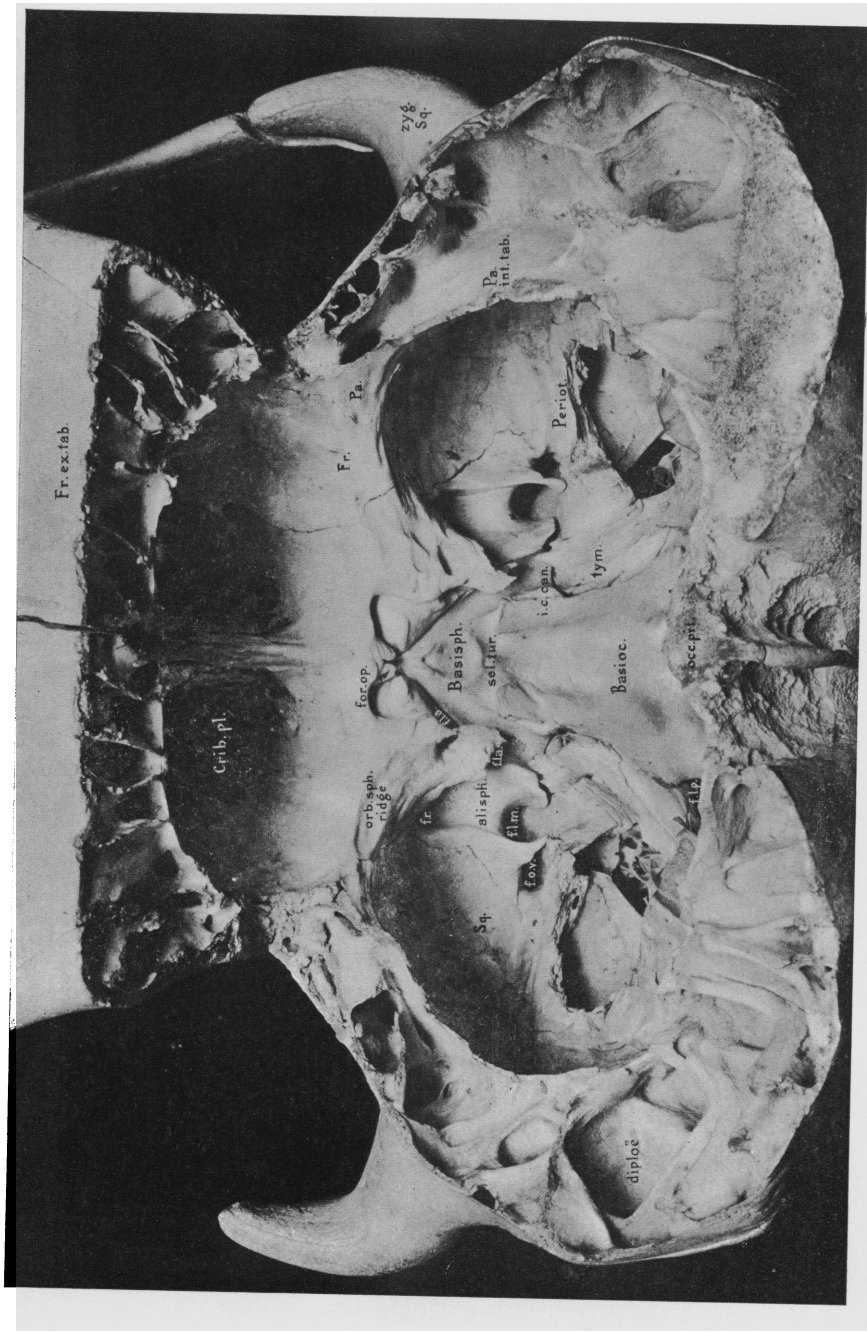
side, at a point opposite the malars, where the skull is most constricted laterally, these buttresses branch off externally into symmetrically opposed arches in different planes, which pass forward, backward, downward, or upward. The wedge-shaped basisphenoid, situated between the inner ends of the buttresses, is the veritable keystone of this converging system.

The skull as a whole is thus highly adapted to resist the severe strains put upon it. The occiput, both in ontogeny and phylogeny, flattens out and rotates backward, spreading both vertically and laterally, until at last it forms, as it were, a great, functionally solid bed-plate, receiving the thrusts of the opposite inverted arches into which the skull has been resolved. Each pair of these symmetrically disposed arches, which also connect with the system culminating in the basisphenoid, reacts, of course, against some component of the force transmitted either to or from the tusks, trunk, and grinders, or when the forehead is used in pushing. The innumerable toughly constructed air cells of the diploë give immense strength, lightness and especially resiliency. This desideratum may also be the reason for the very loose articulation of the malar with the zygomatic process of the squamosal, which would also permit the facial portion of the skull to bend back slightly, under pressure, toward the cranial portion.

EXPLANATION OF PLATE XXIII.

Interior view of the skull of a young Asiatic elephant. From a forthcoming memoir by Professor Osborn.

Crib. pl.	= cribriform plate.
Fr. ex. tab.	= external tabula of frontal.
Fr.	= frontal.
Pa.	= parietal.
Pa. int. tab.	= internal tabula of parietal.
Zyg. Sq.	= zygomatic process of squamosal.
Periot.	= broken edge of periotic.
tym.	= tympanic.
Basisph.	= basisphenoid.
Sel. tur.	= sella turcica.
Basioc.	= basioccipital.
occ. pit.	= occipital pit for ligamentum nuchæ.
Alisph.	= alisphenoid.
orb. sph. ridge	= orbitosphenoidal ridge.
for. op.	= foramen opticum.
f. l. a.	= foramen lacerum anterius.
f. r.	= foramen rotundum.
f. l. m.	= foramen lacerum medius.
f. ov.	= foramen ovale.
i. c. can.	= opening of internal carotid canal.
f. l. p.	= foramen lacerum posterius.



INTERIOR VIEW OF SKULL OF YOUNG ASIATIC ELEPHANT.

