

Severe hypercalcemia after a single high dose of vitamin D in a patient with sarcoidosis

Angela Hassler · Olivier Lamy · Alain Rossier ·
Claudio Sartori · David Gachoud

Received: 9 March 2012 / Accepted: 23 August 2012 / Published online: 6 September 2012
© Springer-Verlag 2012

Dear Editor,

Vitamin D supplementation in patients who suffer from sarcoidosis and are simultaneously at high risk of developing glucocorticoid-induced osteoporosis can represent a dilemma in clinical decision making. To illustrate this critical situation, we report the case of a 53-year-old woman with renal sarcoidosis, chronic hepatitis C, and an HIV infection effectively controlled with highly active anti-retroviral therapy. She was admitted to the emergency room due to progressive excessive fatigue, generalized weakness, lethargy, and headache. Physical examination revealed a reduced general condition, signs of hypovolemia, and generalized muscular weakness without focal signs. Regarding her medical history, sarcoidosis was diagnosed 2 years earlier. This disease predominantly affected the kidneys, manifesting itself as an interstitial granulomatous nephritis (Fig. 1). Liver and retinae were affected to a lesser extent, and lungs were free from the disease. Since the diagnosis, she had been treated with glucocorticoids and was taking 25 mg of prednisone per day at the time of admission. Although the patient was additionally taking 75 mg of

azathioprine per day, it was impossible to reduce the prednisone dose. Despite the continuous immunosuppressive therapy, sarcoidosis had already led to a significant renal impairment including a moderate proteinuria (1.5 g/day) and a reduced glomerular filtration rate (40 mL/min). During the previous 2 years, the patient occasionally received vitamin D supplementation based on 25(OH)D₃ serum levels. Two weeks before the admission to the hospital, 25(OH)D₃ serum concentration was measured at 18 ng/mL (47 nmol/L), for which the patient received a single oral dose of 300.000 IU cholecalciferol. At this time, serum calcium was 2.41 mmol/L (normal, 2.15–2.55 mmol/L). Laboratory analysis at the time of admission revealed serum calcium 3.42 mmol/L, serum phosphate 1.88 mmol/L (normal, 0.8–1.4 mmol/L), and serum creatinine 299 μmol/L. Serum levels of 25(OH)D₃ and 1,25-dihydroxyvitamin D [1,25(OH)₂D₃] were 52.4 ng/mL (=130 nmol/L) and 119 pmol/l (normal, 48–160 pmol/L), respectively. In view of these results, we diagnosed severe hypercalcemia, which we traced back to the single high dose of cholecalciferol. Other common causes of hypercalcemia were excluded. The patient was treated with stringent hydration (approx. 3000 mL sodium-chloride 0.9 %/day), which resulted in a slow decrease in serum calcium (2.47 mmol/L) and creatinine (212 μmol/L). The patient recovered from the clinical symptoms within six days and was discharged from hospital. One week later, serum calcium rebounded to 2.76 mmol/L. With a single dose of intravenous pamidronate (30 mg), serum calcium fell in the normal range. 25(OH)D₃ and 1,25(OH)₂D₃ serum levels remained at the normal range (32 ng/mL and 49 pmol/L, respectively) up to four months after the hospitalization.

The patient's clinical condition presented a dilemma in decision making. Indeed, the high risk of glucocorticoid-induced osteoporosis is normally an indication to maintain

A. Hassler
Johann Wolfgang Goethe University Hospital,
University of Frankfurt, 60590 Frankfurt am Main, Germany
e-mail: angela_hassler@web.de

O. Lamy · C. Sartori · D. Gachoud (✉)
Department of Internal Medicine, Centre Hospitalier
Universitaire Vaudois, University of Lausanne,
Rue du Bugnon 44, 1011 Lausanne, Switzerland
e-mail: david.gachoud@chuv.ch

A. Rossier
Nephrology Unit, Centre Hospitalier Universitaire Vaudois,
University of Lausanne, 1011 Lausanne, Switzerland

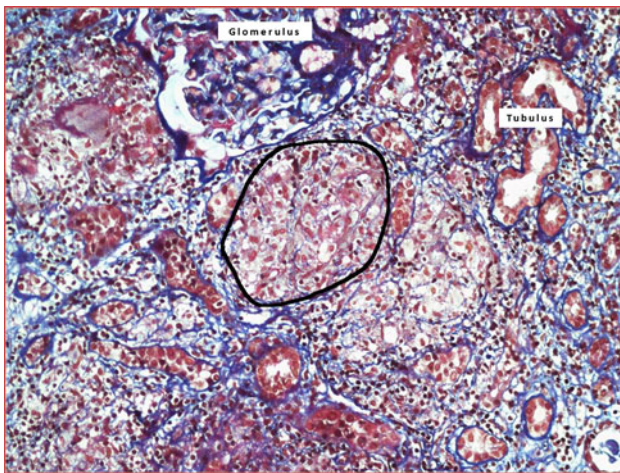


Fig. 1 Sarcoidosis interstitial granulomatous nephritis. FAOG-staining, $\times 200$. A granuloma is *encircled*

25(OH) D_3 serum levels ≥ 30 ng/mL, according to current international guidelines [1, 2]. However, levels of 25(OH) D_3 ≥ 30 ng/mL can already result in vitamin

D-related toxicity in sarcoidosis patients [3], as it was the case with our patient, although—theoretically—the administration of glucocorticoids should have sufficiently suppressed the expression of the inducible form of the 1α -hydroxylase [3]. In conclusion, our case suggests a cautious use of vitamin D supplementation, especially of single high doses, as well as a close monitoring of its effects in patients with granulomatous diseases, even in the presence of glucocorticoids.

Conflict of interest The authors have no conflicts of interest to disclose.

References

1. Weinstein RS (2011) Clinical practice. Glucocorticoid-induced bone disease. *N Engl J Med* 365:62–70
2. Rosen CJ (2011) Clinical practice. Vitamin D insufficiency. *N Engl J Med* 364:248–254
3. Berliner AR, Haas M, Choi MJ (2006) Sarcoidosis: the nephrologist's perspective. *Am J Kidney Dis* 48:856–870