

Serveur Académique Lausannois SERVAL serval.unil.ch

Author Manuscript

Faculty of Biology and Medicine Publication

This paper has been peer-reviewed but does not include the final publisher proof-corrections or journal pagination.

Published in final edited form as:

Title: Ruptured pseudo-aneurysm of a femoral artery in a drug abuser revealed by post-mortem CT angiography.

Authors: Michaud K, Grabherr S, Lesta Mdel M, Augsburger M, Doenz F, Mangin P

Journal: International journal of legal medicine

Year: 2013 Jul

Issue: 127

Volume: 4

Pages: 819-23

DOI: 10.1007/s00414-012-0803-6

In the absence of a copyright statement, users should assume that standard copyright protection applies, unless the article contains an explicit statement to the contrary. In case of doubt, contact the journal publisher to verify the copyright status of an article.

International Journal of Legal Medicine

Ruptured pseudo-aneurysm of a femoral artery in a drug abuser revealed by post-mortem CT-angiography --Manuscript Draft--

Manuscript Number:	IJLM-D-12-00339R1
Full Title:	Ruptured pseudo-aneurysm of a femoral artery in a drug abuser revealed by post-mortem CT-angiography
Article Type:	Case Report
Corresponding Author:	Katarzyna Michaud, MD University Center of legal medicine Lausanne, SWITZERLAND
Corresponding Author Secondary Information:	
Corresponding Author's Institution:	University Center of legal medicine
Corresponding Author's Secondary Institution:	
First Author:	Katarzyna Michaud, MD
First Author Secondary Information:	
Order of Authors:	Katarzyna Michaud, MD Silke Grabherr, MD Maria del Mar Lesta Marc Augsburger, PhD Francesco Doenz, MD Patrice Mangin, MD, PhD
Order of Authors Secondary Information:	
Abstract:	<p>A 35 year old drug addict was found dead in a public toilet with a ruptured groin, which was later diagnosed to be a leaking pseudo-aneurysm. Investigation at the scene revealed impressive external haemorrhage related to a groin wound. Post-mortem computed tomography angiography demonstrated an aneurysm of the right femoral artery with leak of contrast liquid. Signs of blood loss were evident at autopsy and histological examination revealed necrosis and rupture of the pseudo-aneurysm. Toxicological analyses were positive for methadone, cocaine, citalopram and benzodiazepines. This is the first case report in the literature of a ruptured femoral pseudo-aneurysm with a post-mortem radiological diagnosis.</p> <p>KEYWORDS: Parenteral drug abuse, femoral pseudo-aneurysm, haemorrhage, post-mortem angiography</p>

Abstract

A 35 year old drug addict was found dead in a public toilet with a ruptured groin, which was later diagnosed to be a leaking pseudo-aneurysm. Investigation at the scene revealed impressive external haemorrhage related to a groin wound. Post-mortem computed tomography angiography demonstrated an aneurysm of the right femoral artery with leak of contrast liquid. Signs of blood loss were evident at autopsy and histological examination revealed necrosis and rupture of the pseudo-aneurysm. Toxicological analyses were positive for methadone, cocaine, citalopram and benzodiazepines. This is the first case report in the literature of a ruptured femoral pseudo-aneurysm with a post-mortem radiological diagnosis.

Introduction

Parenteral drug injection can cause a wide range of vascular complications, from simple vascular irritation to severe infections, thrombosis and the formation of pseudo-aneurysms [1-3]. These latter complications can be limb or even life-threatening, with difficult and controversial clinical management [4]. The femoral localization of a pseudo-aneurysm has been reported in clinical practice [5-8], but a post-mortem diagnosis complete with post-mortem computed tomography angiography (PMCTA) has not been presented up until now.

In the University Center of Legal Medicine Lausanne - Geneva, the performance of pre-autopsy PMCTA has become part of the routine investigation for cases in which lesions of the vascular system are suspected. Such cases are investigated using a standardized technique called Multi-phase post-mortem CT-angiography (MPMCTA) [9].

We present a case of fatal haemorrhage in a drug addict, for whom the source of bleeding was identified and visualized by MPMCTA. To our knowledge, this is the first case report in the literature of a ruptured femoral pseudo-aneurysm with a post-mortem radiological diagnosis.

Case Report:

Clinical history: A 35 year old woman was found dead in a public toilet. She was known to have had a borderline personality and to have abused drugs with intravenous injections of cocaine and midazolam. She was HIV, HBV and HCV positive. Six years before her death, a Thiersch graft [10] was placed in the left inguinal area to treat an abscess. Two years later, she presented with a thrombosis of the right deep femoral vein and post thrombotic syndrome of the right leg. One month prior to her death, she was admitted to the hospital for Streptococcal bacteremia resulting from drug injections into the right inguinal region. During her stay, a chronic groin wound without purulent flow was observed and a pseudo-aneurysm of the right femoral artery was discovered by Doppler ultrasound. Multiple micro emboli of the right leg and foot attributed to probable intra-arterial injections of drugs were observed. The patient was treated with antibiotics over a 3 weeks period.

Scene investigation: The body was found undressed in a public toilet. Scene investigation revealed large quantities of blood on the floor and walls suggesting an arterial bleeding. A needle and small knife were found near the body.

External examination: performed by a board certified forensic pathologist showed signs of blood loss and a large groin wound on the right side (Fig.1). Multiple needle tracks were observed. A track on the left forearm had a recent appearance. There was a large scar in the left inguinal area. Multiple old linear transverse scars were present in the left forearm, compatible with auto mutilation.

Radiological investigation: Post-mortem computed tomography (PMCT) and MPMCTA were performed by a trained forensic radiographer [11] on a 8-row CT-unit (CT LightSpeed 8, GE Healthcare, Milwaukee, WI, USA). The scan parameters used are noted in Table 1. Prior to the performance of MPMCTA, peripheral blood, cerebrospinal and vitreous fluids, and hair samples were collected according to our standard autopsy protocol. The urinary bladder was empty. Samples of bile were obtained under CT-guidance as described by Schneider et al. [11]. MPMCTA was performed using a Virtangio® perfusion device with the oily contrast agent Angiofil® (Fumedica AG, Switzerland) mixed with paraffin oil (paraffinum liquidum, obtained in the local pharmacy). The left inguinal region was cannulated.

Radiological interpretation: Interpretation of all images was performed by two board certified radiologists (one specialized in vascular radiology, the other in neuro-radiology) and by one board certified forensic pathologist trained in forensic imaging. A post-mortem radiological report describing all findings observed in the PMCT and in each phase of MPMCTA was made. Radiological examination revealed subcutaneous infiltration in both inguinal regions (Fig.2a) and liquid in the small pelvis. During the arterial phase of angiography, an arterio-cutaneous fistula of the right inguinal region with extravasation of contrast agent into the muscular tissue was observed, originating from a pseudo-aneurysmal formation of the right femoral artery measuring approximately 2.5 cm in diameter (Fig. 2b-c).

Conventional autopsy and histological examination:

A conventional autopsy was performed 18 hours after MPMCTA. Three body cavities were opened and the organs were dissected according to internal and international recommendations [12]. A visceral pallor was noticed, which was attributed to external haemorrhage from the groin wound.

Dissection of the right femoral area showed an aneurysmal dilatation of the right femoral artery measuring 3 x 2.3 x 0.8 cm, with a gap passing between the fibrotic tissue (Fig.3a and b). Histological examination revealed a chronic fibro-inflammatory state (Fig.3c) and iron deposits (Fig.3d). The arterial wall was thickened, with ruptures of the elastic internal lamina and necrosis.

Toxicological analyses

Comprehensive drug screenings were performed on the blood by gas chromatography-mass spectrometry (GC-MS) [13], high-performance liquid chromatography coupled with diode-array detection (HPLC-DAD) and headspace-gas chromatography-flame ionization detection (HS-GC-DIF) for the detection of volatile substances. The confirmation and quantification of drugs was done by GC-MS, GC-MS/MS and HPLC-MS/MS.

The toxicological analyses performed on the peripheral blood revealed the presence of cocaine (160 µg/l) benzoylecgonine (700 µg/l), ecgonine methylester (200 µg/l), lorazepam (13 µg/l), nordiazepam (35 µg/l), oxazepam (5 µg/l), methadone (290 µg/l), EDDP (70 µg/l), desmethylocitalopram, acetaminophen, and caffeine. Alcohol was not detected. According to the literature these concentrations range below the lethal level ([14,15]

Toxicological analyses were also performed on hair samples and showed the presence of cocaine (100 ng/mg), benzoylecgonine (32 ng/mg), 6-monoacetylmorphine (0.4 ng/mg), morphine (0.3 ng/mg), codeine (0.1 ng/mg) and methadone (34 ng/mg), suggesting frequent consumption of cocaine and methadone during the months before the death, and occasional consumption of heroin during the same period.

Discussion

Pseudo-aneurysm formation at the site of injection is a well-known complication of parenteral drug use and had been previously reported in the literature [3,6,5]. This lesion may occur after arterial trauma resulting from accidental or intentional intra-arterial drug injection. This most commonly occurs when peripheral veins are inaccessible [1,8,16]. Repeated punctures of the femoral artery can lead to abscess formation and epithelisation of the arterial wall, resulting in the formation of a pseudo-aneurysm. Haemorrhage, sepsis, limb loss and death are possible sequelae. [4,2].

This is a rare case of a woman with a leaking pseudo-aneurysm presented as ruptured groin wound and external haemorrhage. Although well documented in clinical practice, pseudo-aneurysms of the femoral artery have been rarely reported in post-mortem studies [17]. This may be due to the fact that the majority of deaths in drug addicts are the result of intoxication, and hence the vascular system of the members is not routinely examined post-mortem. In this case, the scene investigation and external examination suggested an arterial bleeding. Post-mortem CT-angiography enabled the visualization and documentation of the lesion, and the autopsy examination provided more details. In our opinion, post-mortem radiological examination of the vascular system is recommended in cases of suspected arterial bleeding but it would be also interesting in cases with non-ruptured pseudo-aneurysms. Insights gained will be helpful for the understanding of the radiological evaluation of arterial pseudo-aneurysms in the clinical setting. The MPMCTA technique has great advantages over both conventional autopsy and ante-mortem clinical CT angiography for the detection of the source of bleeding in cases of acute haemorrhage. [18]. The detection and visualization of the origin of bleeding is sometimes crucial [19]. The combination of MPMCTA and conventional autopsy may represent a new standard of excellence.

In this case, MPMCTA enabled the visualization of both the source of the haemorrhage (arterio-cutaneous fistula) and the underlying pathological substrate (pseudo-aneurysm). To our knowledge, this is the first case report in which a pseudo-aneurysm was diagnosed by PMCTA.

Acknowledgements: The research project of post-mortem angiography was financially supported by the Promotion Agency for Innovation of the Swiss Confederation (KTI Nr. 10221.1 PFIW-IW) and by the Leenards Foundation, Switzerland.

Legends

Fig 1

Large groin wound found on external examination

Fig 2

Radiological images: Native CT (a) revealed the presence of subcutaneous infiltrations in both inguinal regions (arrows), essentially on the left side (dotted arrow). (b): A pseudo-aneurysm filled with contrast agent (dotted arrow) in the right inguinal region showing maximum intensity after an arterial phase of MPMCTA reconstruction was performed. Contrast agent extravasated via an arterio-cutaneous fistula outside the body and in the surrounding tissue (arrow). (c): volume rendered 3D-reconstruction of the distal aorta, iliac and femoral arteries of both sides. The aneurism is visualized and measured. The exact source of bleeding (fistula) can be easily recognized (arrow).

Fig 3

(a):Pseudo-aneurysm formation of the femoral artery and the wound of the right groin with the external rupture (arrow)

(b): Pseudo-aneurysm and its origin from the artery (arrow). Note the fibrous tissue around the arterial wall.

c):Histological examination of the groin wound showing a chronic fibro-inflammatory state with the areas of fresh haemorrhage and an intense neutrophils granulocytic infiltration (H&Ex40)

d): Detection of iron deposits by Prussian-blue reaction (x100) compatible with an old haemorrhage of the tissue surrounding the arterial wall

Table 1 Technical parametres for CT-data acquisition

References

1. Woodburn KR, Murie JA (1996) Vascular complications of injecting drug misuse. *British Journal of Surgery* 83 (10):1329-1334. doi:10.1002/bjs.1800831005
2. Fiddes R, Khattab M, Abu Dakka M, Al-Khaffaf H (2010) Patterns and management of vascular injuries in intravenous drug users: A literature review. *The Surgeon* 8 (6):353-361. doi:10.1016/j.surge.2010.07.006
3. McIlroy MA, Reddy D, Markowitz N, Saravolatz LD (1989) Infected False Aneurysms of the Femoral Artery in Intravenous Drug Addicts. *Review of Infectious Diseases* 11 (4):578-585. doi:10.1093/clinids/11.4.578
4. Salimi J, Shojaeefar A, Khashayar P (2008) Management of Infected Femoral Pseudoaneurysms in Intravenous Drug Abusers: A Review of 57 Cases. *Archives of Medical Research* 39 (1):120-124. doi:10.1016/j.arcmed.2007.07.004
5. Tsao JW, Marder SR, Goldstone J, Bloom AI (2002) Presentation, Diagnosis, and Management of Arterial Mycotic Pseudoaneurysms in Injection Drug Users. *Annals of Vascular Surgery* 16 (5):652-662. doi:10.1007/s10016-001-0124-6
6. Ting ACW, Cheng SWK (1997) Femoral Pseudoaneurysms in Drug Addicts. *World Journal of Surgery* 21 (8):783-787. doi:10.1007/s002689900306
7. Valentine RJ, Chung J (2012) Primary Vascular Infection. *Current Problems in Surgery* 49 (3):128-182. doi:10.1067/j.cpsurg.2011.11.004
8. Koželj M, Kobilica N, Flis V (2006) Infected femoral pseudoaneurysms from intravenous drug abuse in young adults. *Wiener Klinische Wochenschrift* 118 (0):71-75. doi:10.1007/s00508-006-0546-9
9. Grabherr S, Doenz F, Steger B, Dirnhofner R, Dominguez A, Sollberger B, Gyax E, Rizzo E, Chevallier C, Meuli R, Mangin P (2010) Multi-phase post-mortem CT angiography: development of a standardized protocol. *International Journal of Legal Medicine*:1-12. doi:10.1007/s00414-010-0526-5
10. Boudana D, Wolber A, Coeugnet E, Martinot-Duquennoy V, Pellerin P (2010) Une histoire de peau. *Annales de Chirurgie Plastique Esthétique* 55 (4):328-332. doi:10.1016/j.anplas.2009.08.003
11. Schneider B, Chevallier C, Dominguez A, Bruguier C, Elandoy C, Mangin P, Grabherr S (2012) The Forensic Radiographer: A New Member in the Medicolegal Team. *The American journal of forensic medicine and pathology* 33 (1):30-36 10.1097/PAF.1090b1013e31820c31826aa31823
12. Brinkmann B (1999) Harmonisation of Medico-Legal Autopsy Rules. *International Journal of Legal Medicine* 113 (1):1-14
13. Michaud K, Augsburger M, Romain N, Giroud C, Mangin P (1999) Fatal overdose of tramadol and alprazolam. *Forensic Science International* 105 (3):185-189. doi:10.1016/s0379-0738(99)00118-8
14. Druid H, Holmgren P (1997) A compilation of fatal and control concentrations of drugs in postmortem femoral blood. *Journal of Forensic Sciences* 42 (1):79-87
15. Winek CL, Wahba WW, Balzer TW (2001) Drug and chemical blood-level data 2001. *Forensic Science International* 122 (2-3):107-123. doi:10.1016/s0379-0738(01)00483-2
16. Coughlin PA, Mavor AID (2006) Arterial Consequences of Recreational Drug Use. *European Journal of Vascular and Endovascular Surgery* 32 (4):389-396. doi:10.1016/j.ejvs.2006.03.003
17. Lardi C, Fracasso T (9000) Spontaneous External Rupture of Femoral Pseudoaneurysm: Fatal Hemorrhage Related to Drug Abuse. *The American journal of forensic medicine and pathology Publish Ahead of Print*:10.1097/PAF.1090b1013e3182518e3182547
18. Palmiere C, Binaghi S, Doenz F, Bize P, Chevallier C, Mangin P, Grabherr S Detection of hemorrhage source: The diagnostic value of post-mortem CT-angiography. *Forensic Science International* (0). doi:10.1016/j.forsciint.2012.04.031

19. Zerlauth JB, Doenz F, Dominguez A, Palmiere C, Uské A, Meuli R, Grabherr S Surgical interventions with fatal outcome: Utility of multi-phase postmortem CT angiography. *Forensic Science International (0)*. doi:10.1016/j.forsciint.2012.05.013

Figure 1

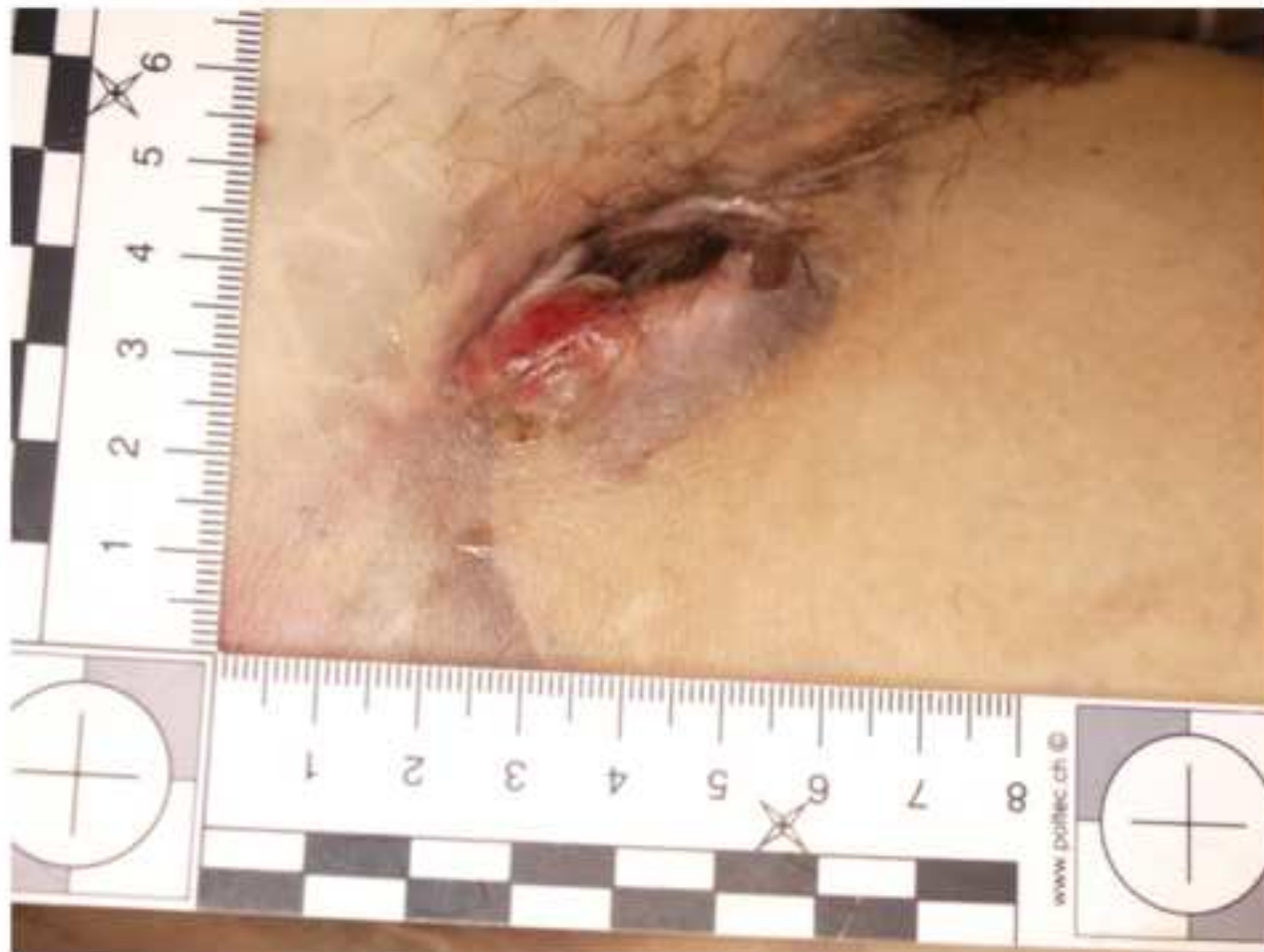

Fig. 1

Figure 2

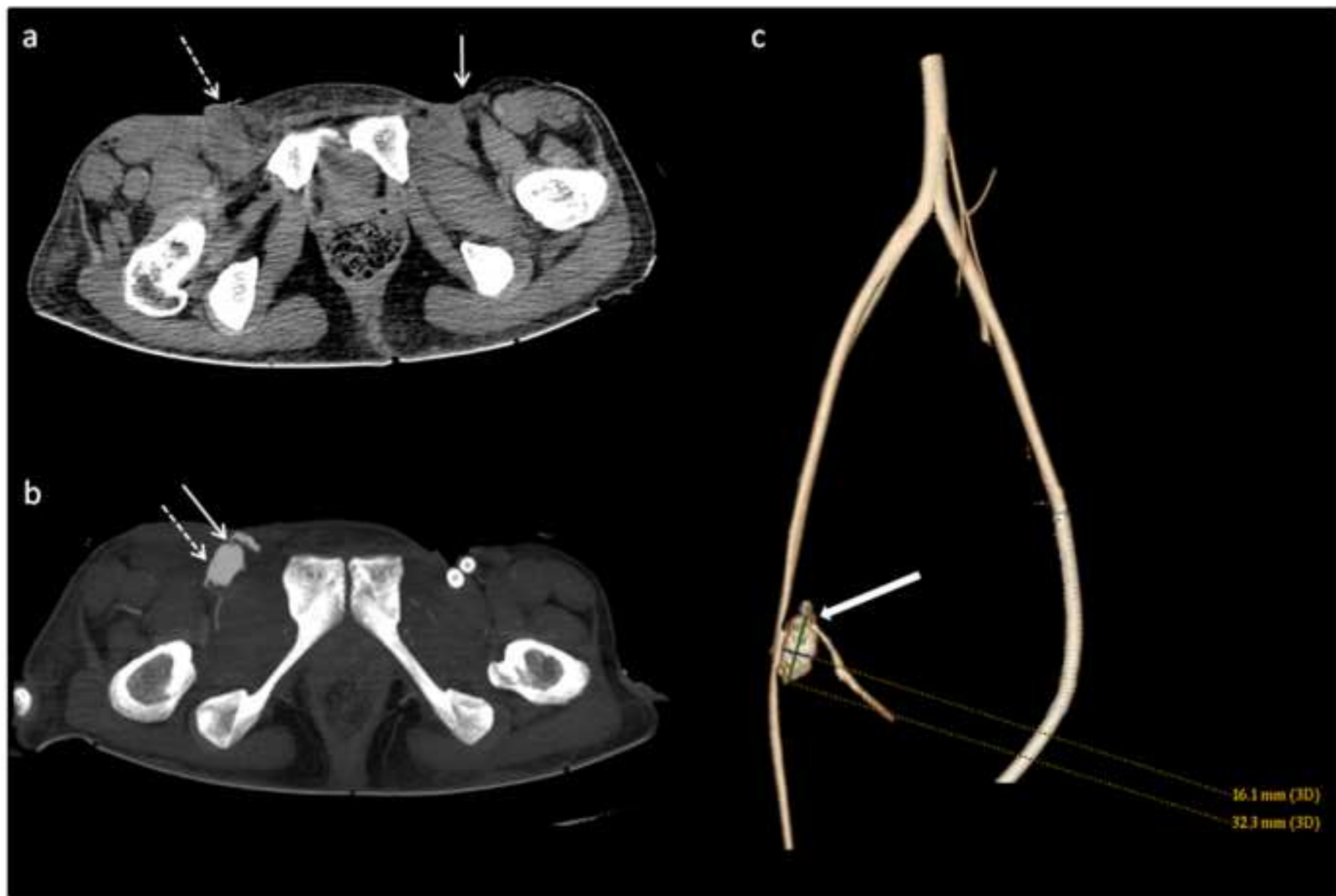

Fig. 2

Figure 3

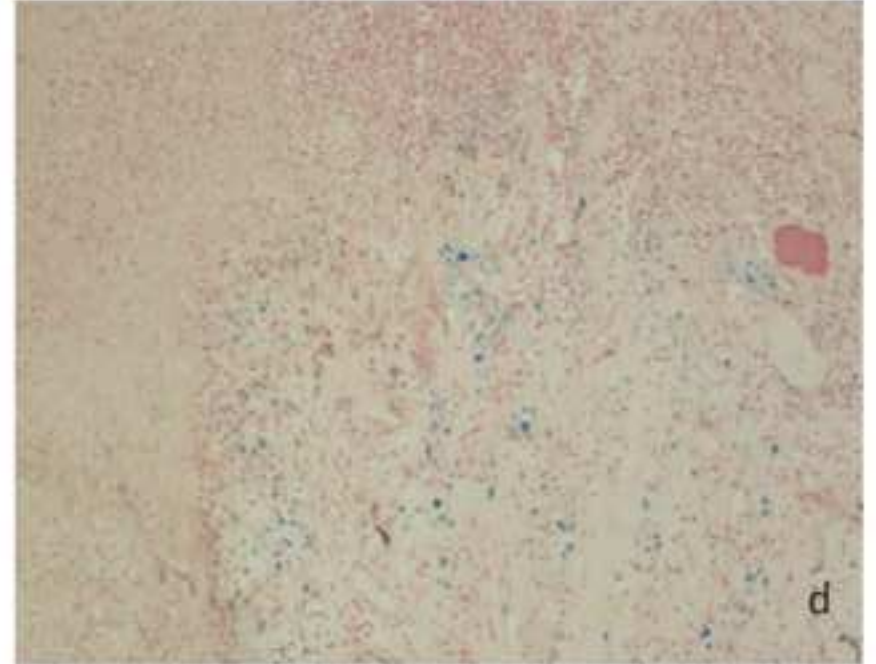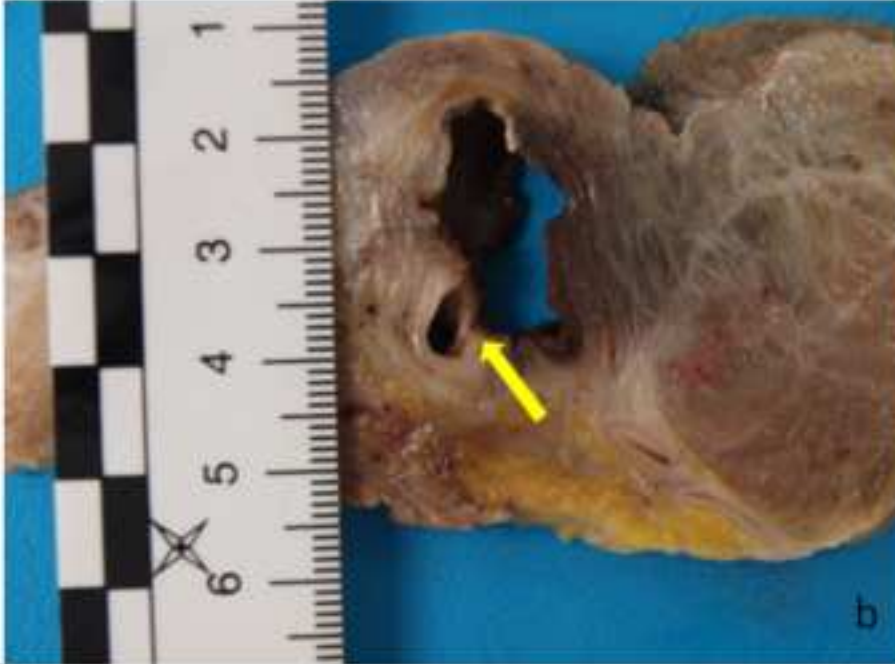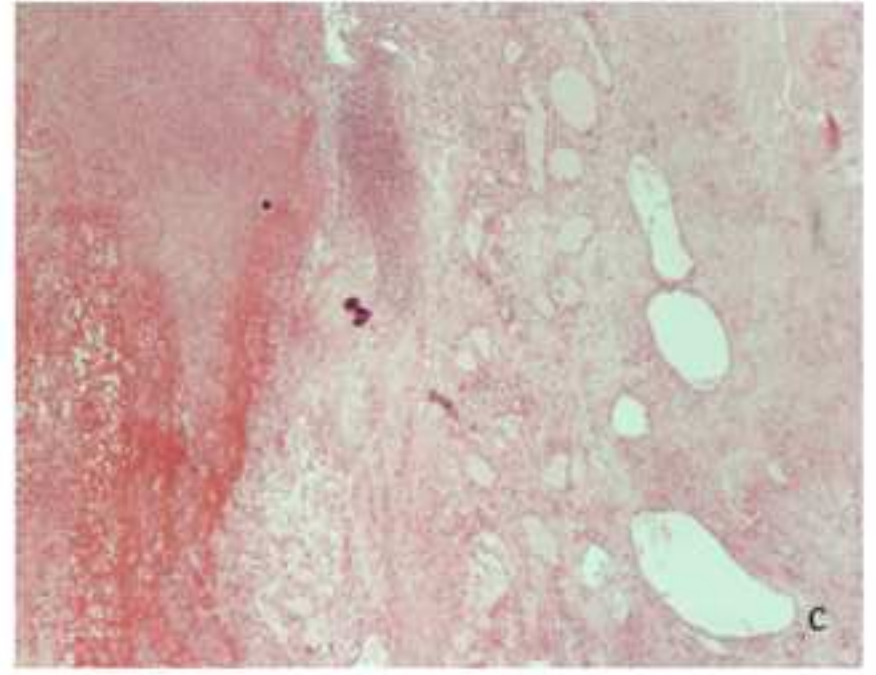
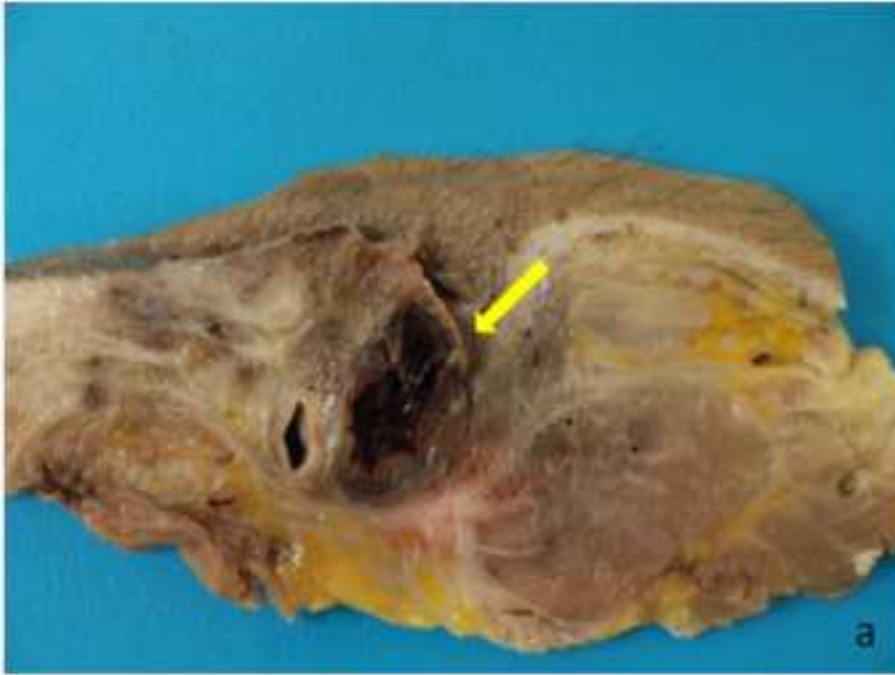


Fig. 3

	FOV	Slice thickness	Interval	kV	mA (modulated)	Tube rotation	Pitch
Native	50 cm	1.25 mm	1 mm	120	280	0.8 sec	0.875
Arterial	50 cm	1.25 mm	0.6 mm	120	280	0.8 sec	0.875
Venous	50 cm	2.5 mm	2 mm	120	280	0.8 sec	0.875
Dynamic	50 cm	2.5 mm	2 mm	120	280	0.8 sec	0.875

Table 1: Technical parameters for CT-data acquisition