

Serveur Académique Lausannois SERVAL serval.unil.ch

Author Manuscript

Faculty of Biology and Medicine Publication

This paper has been peer-reviewed but does not include the final publisher proof-corrections or journal pagination.

Published in final edited form as:

Title: Subtelomeric deletion of chromosome 10p15.3: clinical findings and molecular cytogenetic characterization.

Authors: DeScipio C, Conlin L, Rosenfeld J, Tepperberg J, Pasion R, Patel A, McDonald MT, Aradhya S, Ho D, Goldstein J, McGuire M, Mulchandani S, Medne L, Rupps R, Serrano AH, Thorland EC, Tsai AC, Hilhorst-Hofstee Y, Ruivenkamp CA, Van Esch H, Addor MC, Martinet D, Mason TB, Clark D, Spinner NB, Krantz ID

Journal: American journal of medical genetics. Part A

Year: 2012 Sep

Volume: 158A

Issue: 9

Pages: 2152-61

DOI: 10.1002/ajmg.a.35574

In the absence of a copyright statement, users should assume that standard copyright protection applies, unless the article contains an explicit statement to the contrary. In case of doubt, contact the journal publisher to verify the copyright status of an article.



Published in final edited form as:

Am J Med Genet A. 2012 September ; 158A(9): 2152–2161. doi:10.1002/ajmg.a.35574.

Subtelomeric Deletion of Chromosome 10p15.3: Clinical Findings and Molecular Cytogenetic Characterization

Cheryl DeScipio, Ph.D.¹ [Director], Laura Conlin², Jill Rosenfeld³, James Tepperberg⁴, Romela Pasion⁴, Ankita Patel⁵, Marie T McDonald⁶, Swaroop Aradhya⁷, Darlene Ho⁷, Jennifer Goldstein⁶, Marianne McGuire⁸, Surabhi Mulchandani², Livija Medne², Rosemarie Rupps⁹, Alvaro H. Serrano⁸, Erik C Thorland¹⁰, Anne C-H Tsai¹¹, Yvonne Hilhorst-Hofstee¹², Claudia AL Ruivenkamp¹², Hilde Van Esch¹³, Marie-Claude Addor¹⁴, Danielle Martinet¹⁴, Thornton B.A. Mason¹⁵, Dinah Clark², Nancy B Spinner^{2,16}, and Ian D Krantz²

¹Department of Pathology, The Johns Hopkins University School of Medicine, Baltimore, MD

²Division of Human Genetics, The Children's Hospital of Philadelphia, Philadelphia, PA

³Signature Genomics, Spokane, WA ⁴Center for Molecular Biology and Pathology, Laboratory Corporation of America, Research Triangle Park, Durham, North Carolina ⁵Department of Molecular and Human Genetics, Baylor College of Medicine, Houston, TX ⁶Department of Pediatrics, Duke University Medical Center, Durham, NC ⁷Clinical Microarray Services, GeneDx, Gaithersburg, MD ⁸Children's Hospital of Pittsburgh, Pittsburgh, PA ⁹Department of Medical Genetics, University of British Columbia, Vancouver, Canada ¹⁰Department of Laboratory Medicine and Pathology, Mayo Clinic, Rochester, MN ¹¹The Children's Hospital, Clinical Genetics, Denver, CO ¹²Center for Human and Clinical Genetics, Department of Clinical Genetics, Leiden University Medical Center, Leiden, Netherlands ¹³Centre for Human Genetics, University Hospitals Leuven, Leuven, Belgium ¹⁴Service of Medical Genetics, Centre Hospitalier Universitaire Vaudois, 1011 Lausanne, Switzerland ¹⁵Department of Neurology, The Children's Hospital of Philadelphia, Philadelphia, PA ¹⁶Division of Clinical Labs, The Children's Hospital of Philadelphia and The University of Pennsylvania School of Medicine, Philadelphia, PA

Abstract

We describe 19 unrelated individuals with submicroscopic deletions involving 10p15.3 characterized by chromosomal microarray (CMA). Interestingly, to our knowledge, only two individuals with isolated, submicroscopic 10p15.3 deletion have been reported to date; however, only limited clinical information is available for these probands and the deleted region has not been molecularly mapped. Comprehensive clinical history was obtained for 12 of the 19 individuals described in this study. Common features among these 12 individuals include: cognitive/behavioral/developmental differences (11/11), speech delay/language disorder (10/10), motor delay (10/10), craniofacial dysmorphism (9/12), hypotonia (7/11), brain anomalies (4/6) and seizures (3/7). Parental studies were performed for nine of the 19 individuals; the 10p15.3 deletion was *de novo* in seven of the probands, not maternally inherited in one proband and inherited from an apparently affected mother in one proband. Molecular mapping of the 19 individuals reported in this study has identified two genes, *ZMYND11* (OMIM# 608668) and *DIP2C* (OMIM# 611380) (UCSC Genome Browser), mapping within 10p15.3 which are most commonly deleted. Although no single gene has been identified which is deleted in all 19 individuals studied, the deleted region in all but one individual includes *ZMYND11* and the deleted region in all but one other individual includes *DIP2C*. There is not a clearly identifiable

CORRESPONDING AUTHOR Cheryl DeScipio, Ph.D. Director, Prenatal Cytogenetics Laboratory The Johns Hopkins Hospital Department of Pathology 600 North Wolfe Street Park Building SB202 Baltimore, MD 21287 Office Phone: (410) 614-6277 Fax: (410) 614-8766.

phenotypic difference between these two individuals and the size of the deleted region does not generally predict clinical features. Little is currently known about these genes complicating a direct genotype/phenotype correlation at this time. These data however, suggest that *ZMYND11* and/or *DIP2C* haploinsufficiency contributes to the clinical features associated with 10p15 deletions in probands described in this study.

Keywords

chromosomal microarray (CMA); 10p15.3; deletion; *ZMYND11*; *DIP2C*

INTRODUCTION

Two distinct clinical phenotypes have been described in association with deletion of chromosome 10p. Hypoparathyroidism, sensorineural deafness, and renal dysplasia syndrome (HDRS, also known as Barakat syndrome, OMIM#146255) is caused by haploinsufficiency of the *GATA3* gene (OMIM#131320) on chromosome 10p14 (~8 Mb from 10pter). Deletions proximal to this region have been associated with a clinical phenotype described as DiGeorge syndrome/velocardiofacial syndrome complex-2 (*DGS2*, OMIM#601362), with a proposed critical region mapping to 10p14-p13. Lindstrand et al. recently performed molecular characterization by array CGH of four probands with overlapping deletions including 10p15. This study identified two critical regions, defined by minimal regions of overlap. The first critical region spans 1.6 Mb within 10p15.1 (from 4.7 Mb to 6.3 Mb from 10pter, UCSC March 2006 build NCBI36/hg18) and is associated with intellectual disability and language impairment. The second critical region spans 4.3 Mb within 10p14 (from 6.3 Mb to 10.6 Mb from 10pter, UCSC March 2006 build NCBI36/hg18) and is associated with autism and dysmorphic features; this region does not include the *DGS2* locus.

The focus of this study is submicroscopic deletion of 10p15.3. Interestingly, to our knowledge, only two probands with isolated, submicroscopic 10p15.3 deletions have been reported. This study describes 19 unrelated individuals with submicroscopic deletions involving 10p15.3 characterized by chromosomal microarray (CMA), comprising the first such cohort reported to date. Comprehensive clinical history, available for 12 of the 19 individuals described in this study, in combination with detailed molecular mapping, allowed the first assessment of genotype/phenotype correlations among individuals with submicroscopic deletions within 10p15.3. Molecular mapping of the 19 individuals reported in this study has identified two genes, *ZMYND11* (OMIM# 608668) and *DIP2C* (OMIM# 611380), mapping within 10p15.3 which are most commonly deleted. Although no single gene has been identified which is deleted in all 19 individuals studied, the deleted region in all but one individual includes *ZMYND11* and the deleted region in all but one other individual includes *DIP2C* (Probands 10 and 17, respectively). There is not a clearly identifiable phenotypic difference between these two individuals (Probands 10 and 17) and the size of the deleted region does not generally predict clinical features in this cohort. Little is currently known about these genes complicating a direct genotype/phenotype correlation at this time. These data however, suggest that *ZMYND11* and/or *DIP2C* haploinsufficiency contributes to the clinical features associated with 10p deletions in our probands.

CLINICAL REPORTS

Proband 1

This male proband (previously reported as Patient 27, DeScipio et al., 2008) was born at full term to a 37-year-old G5P2 mother with an Apgar score of 9 at both 1 and 5 minutes. An

amniocentesis, performed for advanced maternal age, was normal. His birth weight was 2.76 kg (10th-25th centile). He remained in the neonatal intensive care unit for 5 days due to poor feeding and emesis. He had mild jaundice. A heart murmur was noted; an echocardiogram revealed bicuspid aortic valve. He had thickened superior helices, micrognathia, and fifth finger clinodactyly.

At 5 months of age, he was noted to have hypotonia, mild gross motor delay, and mitral valve regurgitation. At 8 months of age, developmental delay persisted and magnetic resonance imaging (MRI) of the brain demonstrated underperculization. At 11 months of age, he was reevaluated by a cardiologist who felt that he had an innocent heart murmur, possibly due to an abnormal pulmonary valve which can not be seen on echocardiogram. At one year of age, he had a normal audiology examination. At 3 years of age, he was walking, able to feed himself, and helped with dressing. He was not yet toilet trained. Developmental evaluation revealed persistence of hypotonia, some questionable cognitive delays, as well as speech and some motor delays. He had approximately fifteen words, as well as using some signs to communicate. He continues to have a strong gag reflex and increased emesis, often behaviorally initiated. He was receiving speech, occupational, and physical therapy. Craniofacial dysmorphism was noted (Fig 1A) with inverted epicanthal folds, long eyelashes and the appearance of hypertelorism. His nasal bridge was depressed, ears appeared normal with slightly thickened superior helices and there was a broad philtrum. The palate was slightly high with a normal tongue and a somewhat averted lower lip.

He developed partial complex seizures that have been well controlled on low dose tegretol. A repeat MRI of the brain demonstrated normal anatomy with resolution of the previously identified underperculization. Some concern was raised on this imaging over a possible craniovertebral junction anomaly and subsequent spinal radiographs and computed tomography (CT) with 3-D reconstruction demonstrated a hypoplastic arch of C1, asymmetrical occipital condyles (malformed on right) and shortening of the clivus.

Standard (G-banded) karyotype was interpreted as normal (46,XY); however, FISH analysis of all subtelomeres detected a deletion of the 10p15.3 subtelomere. SNP array confirmed this *de novo* 10p15.3 interstitial deletion refining the deleted region to 292,414 bp (chr10: 281,134- 573,548, hg18) (Table II).

Proband 2

This female proband (previously reported as Case 98, Ravnan et al., 2006 and Patient 28, DeScipio et al., 2008) was born at 41 1/7 weeks gestation after induced labor to a 24-year-old G3P2 Caucasian mother with an Apgar score of 9 at both 1 and 5 minutes, weight 3030g (25th centile), length 51.5 cm (75th centile) head circumference 35 cm (50th centile), and chest circumference 32.5 cm (50th centile). IUGR was noted during the pregnancy. At birth she was noted to have mild jaundice, redundant hymenal tissue and a ventral hernia superior to the umbilicus that was surgically corrected. She had hypotonia of the lower extremities and a sacral dimple. X-rays and ultrasound of the spine revealed no vertebral anomalies, a mildly enlarged thecal sac and a very narrow sinus tract extending from the thecal sac to the sacral dimple. A computed tomography (CT) scan of the brain showed a mild prominence of the extra-axial cerebrospinal fluid (CSF) spaces bilaterally, most likely representing benign external hydrocephalus.

At three months of age, she developed a urinary tract infection and was found to have bilateral grade I hydronephrosis and mild left ureterectasis. Follow-up renal ultrasound at 15 months showed interval resolution of the hydronephrosis. She had gastroesophageal reflux for the first few months of life. She also developed a feeding aversion and chronic constipation. She underwent surgery for bilateral blocked nasal lacrimal ducts bilaterally.

At 18 months, she was able to walk with minimal assistance. Physical therapy examination revealed a gross motor quotient of 70 on the Peabody test at 19 months. Her skills ranged from 10-14 months with standing and walking considered the greatest areas of delay. Her speech was delayed.

At 1-year, 11-months of age, her height and weight were at the 3rd centile with head circumference at the 75th. She had fine blonde hair, a triangular appearance to her face and a prominent forehead (Fig. 1B).

Standard (G-banded) karyotype was interpreted as normal (46,XX); however, FISH analysis of all subtelomeres detected a deletion of the 10p15.3 subtelomere. SNP array confirmed this apparently terminal de novo 10p15.3 deletion refining the deleted region to 487,155 bp (chr10: 103,934-591,089, hg18) (Table II).

Proband 3

This female proband had developmental delay. Additional clinical information is not available. Standard (G-banded) karyotype was interpreted as normal (46,XX); however, SNP array identified an apparently terminal 2,138,166 bp deletion within 10p15.3 (chr10: 62,747-2,200,913, hg18) (Table II). It is unknown whether this deletion is inherited or de novo.

Proband 4

On exam at age 7 years, this male proband's height was 119.5 cm (27th centile), weight was 24.4 kg (60th centile) and he was macrocephalic (OFC, 55.4 cm). He had global developmental delay, attention deficit hyperactivity disorder (ADHD), aggression and asthma. He had behavioral problems including acting out, aggression towards himself and others and lack of awareness of danger and stranger anxiety. He had sleep disturbance with nocturnal myoclonic jerks (not epileptic) and possible obstructive sleep apnea; he is being evaluated for seizures due to his mother's concern of periods (lasting ~15 seconds) in which he does not respond to voice but will jump if touched. He receives speech therapy. At 3 or 4 years of age he had tonsil and adenoidectomy. No craniofacial dysmorphism or abnormalities of the spine, chest, abdomen, lungs (clear to auscultation, bilaterally), heart (normal rate and rhythm and no murmurs) or dysmorphic features of the extremities were noted (Fig. 1C, D). On dermatologic exam, no birth marks were noted. On neurologic exam, he had decreased muscle tone, but good power. Pupils were equal, round and reactive to light bilaterally. His extraocular movements were intact. His reflexes were brisk but symmetric. He had normal gait. He had poor dentition and a normal palate. There were no records of an audiology evaluation. His father had a family history of lung cancer and reading problems. His mother had a family history of cancer and intellectual disability. Standard (G-banded) karyotype was interpreted as normal (46,XY); however, SNP array identified a 637,849 bp interstitial deletion within 10p15.3 (chr10: 101,955-739,804, hg18) (Table II). FISH analysis of this proband's mother also revealed a 10p15.3 deletion. This proband's mother (Fig. 1C) has not yet had a formal clinical evaluation; however, she has significant learning differences requiring special education services in school and requires assistance with an outside advocate to attend to her son's needs at school.

Proband 5

This male proband was born at term and weighed 2863g. On exam at age 10 years, his height was 127.7 cm (<3rd centile), weight was 25.5 kg (4th centile) and he was normocephalic. He had mild intellectual disability (not Autistic spectrum disorder), developmental articulation disorder and significant mixed receptive and expressive language disorder and hypospadias. He had normal muscle tone and strength. No craniofacial

dysmorphism or abnormalities of the hands, feet, spine or heart were noted. Oligonucleotide array identified an apparently terminal de novo 2,250,389 bp deletion within 10p15.3 (chr10:214,559- 2,464,948, hg18) (Table II).

Proband 6

On exam at age 5 years, this male proband's height was 108.31 cm (14th centile), weight was 16.9 kg (9th centile) and he was normocephalic. He had very mild epicanthal folds and pointed chin. He had hypotonia and hyporeflexia. He had global developmental delay, fine and gross motor delays, developmental coordination disorder, receptive and expressive language disorder and a very small arachnoid cyst in the medial temporal lobe. No abnormalities of the hands, feet or heart (normal rate and rhythm and no murmurs) were noted. Oligonucleotide array identified an apparently terminal 460,631 bp deletion within 10p15.3 (chr10: 170772- 631403, hg18) (Table II). It is unknown whether this deletion is inherited or de novo.

Proband 7

This male proband was born at 38 weeks gestation after induced vaginal delivery; his weight was 3402g. Pregnancy history includes a small amount of bleeding early in the pregnancy and diagnosis of a diaphragmatic hernia. His mother denies tobacco, alcohol or recreational or prescription drug use during the pregnancy. There was no maternal history of illness, fever, rash or radiation exposure during the pregnancy. He had surgical repair of this diaphragmatic hernia on day four of life; he was subsequently on a ventilator for approximately 3 weeks and discharged home at a month of age.

On exam at age 5 years, his height was 105.5 cm (25th), weight was 18.2kg (25-50th) and head circumference was 53cm (75th). He had partial complex seizures, diaphragmatic hernia and developmental, motor and language delays. He had craniofacial dysmorphism including plagiocephaly and a normally positioned nose with prominent columella and hypoplastic alae. He had bilateral fifth finger clinodactyly and pes planus with bilateral clinodactyly of toes 3, 4 and 5. Palm length was 6.5 cm (3rd to 25th centile); third finger length was 5 cm (25th centile). He had fetal fat pads on all digits. Finger and toenails were normal; palmar and plantar creases were normal. Pupils were equal, round and reactive to light with intact extraocular movements. Sclera was white. Interpupillary distance was 6 cm (>97th centile). Innercanthal distance was 3.25 cm (97th centile). Ears were normally shaped; ear length was 5.5 cm (50-75th centile). Oral mucosa was pink and moist without lesions. The palate was intact and mildly narrow. He had a single uvula. Dentition was normal except for caries. Neck was supple and without adenopathy. Chest was symmetric with no pectus carinarum or excavatum. Breasts were normal. Lungs were clear to auscultation with equal bilateral breath sounds. Normal heart rate and rhythm was present with I/VI systolic murmur. Spine was straight without palpable lesions. Abdomen was soft, nontender and nondistended with no masses or hepatosplenomegaly; a scar was consistent with surgery. Genitalia were immature male with shawl scrotum; testes descended bilaterally. Anus was normally placed. He had full range of motion of all joints. Skin had no lesions. He had deep tendon reflexes 2+ bilaterally in the upper and lower extremities. He had no sustained ankle clonus. Babinski signs were negative. He had a wide-based gait and clumsy running.

He was using single words between 2 and 3 years of age; he began using two word phrases between 3 and 4 years of age. At age 5 years, he was still using one or two word sentences. He also had marked gross motor delay; he is unable to run well or ride a bicycle. His fine motor skills were less delayed; he can grasp a pencil and use scissors. He is affectionate, social and hyperactive. He crawled between 17 and 18 months of age; he walked independently between two and two and a half years of age. Neurologic evaluation at 6

years and 6 months demonstrated significant problems with expressive and receptive language among other delays. He had a normal brain MRI.

He is the third child of his parents; he has two healthy sisters. His mother is of Italian ancestry and is in good health. His father is of Dutch, German and Swedish ancestry; he is in good health. There is no family history of consanguinity, multiple miscarriages or intellectual disability. FISH analysis detected a deletion of the 10p15.3 subtelomere; SNP array confirmed this apparently terminal *de novo* 1,168,170bp deletion within 10p15.3 (chr10: 62,797- 1,230,967, hg18) (Table II).

Proband 8

This 3-year-old male proband was referred for cytogenetic testing due to developmental delay (i.e., delayed motor skills) and hypotonia. Additional clinical information is not available. Oligonucleotide array identified an apparently terminal 2,964,573 bp deletion within 10p15.3 (chr10: 126,361-3,090,934, hg18) (Table II). It is unknown whether this deletion is inherited or *de novo*.

Proband 9

On exam at age 1 year, 9 months, this female proband's height was 78.9 cm (10th centile), weight was 8.25 kg (<3rd centile) and she was normocephalic. She had craniofacial dysmorphism including bilateral epicanthus inversus, epicanthal folds, wide nasal bridge, tall/bossed forehead, mild micrognathia, slightly high anterior palate, flat facial profile and mild tenting of the upper lip (Fig. 1E). She had developmental delay, hypotonia, gastroesophageal reflux disease (GERD), constipation, kyphosis, hypoplastic nipples and frequent respiratory and serous otitis media infections. Her heart was regular, without murmurs. No abnormalities of the ears, palmar creases, digits, nails, hands, or feet were noted. Oligonucleotide array identified a 446,016 bp *de novo* interstitial deletion within 10p15.3 (chr10:284,172-730,188, hg18) (Table II). Quantitative polymerase chain reaction (Q-PCR) of *DIP2C* confirmed the deletion in this proband and showed normal results in parental samples (data not shown).

Proband 10

On exam at age 7 years, this female proband's height was 103.3 cm, weight was 15.4 kg and head circumference was 51.5 cm. She had craniofacial dysmorphism including bifrontal narrowing of forehead, normally spaced, mildly downslanting eyes, deep set mildly upturned nose, high palate, downturned corners of the mouth, overfolded ears normal in position with no pits or tags. She had growth delay, mild hypotonia, hyperextensible hands, webbed toes, nasal speech and anxiety accompanied by some repetitive behaviors. There was a history of recurrent strep throat and enlarged tonsils. Audiologic evaluation was within normal limits. She had a history of a heart murmur that resolved. It is unclear whether this proband had developmental delay or language/speech delay due to her recent adoption and long history of neglect. She did not have seizures; no brain imaging had been performed. Oligonucleotide array identified a 278,240 bp interstitial deletion within 10p15.3 (chr10: 426,747-704,987, hg18) (Table II). It is unknown whether this deletion is inherited or *de novo*. Of note, this is the only proband within this cohort of 19 individuals whose 10p15 deleted region does not include the gene *ZMYND11* (Fig. 2).

Proband 11

This two year old female proband was referred for cytogenetic testing due to developmental delay. Additional clinical information is not available. Whole genome BAC array identified

an apparently terminal 3,995,011 bp deletion within 10p15.3 (chr10: 50,001-4,045,012, hg18) (Table II). It is unknown whether this deletion is inherited or *de novo*.

Proband 12

This 6-year-old male proband was referred for cytogenetic testing due to developmental delay and seizures. Additional clinical information is not available. Oligonucleotide array identified a 216,371 bp interstitial deletion within 10p15.3 (chr10: 144,508-360,879, hg18) (Table II). It is unknown whether this deletion is inherited or *de novo*.

Proband 13

On exam at age 12 years, this male proband's height was 154.1 cm (75th centile), weight was 68.2 kg (>97th centile) and head circumference was 56 cm (98th centile). His birth weight was 2.35 kg at 28 weeks gestation. He had craniofacial dysmorphism including frontal bossing, down-slanting palpebral fissures, bilateral epicanthal folds, stellate iris pattern, wide nasal bridge, prominent incisors and thin whitish eyebrows (Fig. 1F). He walked at 2 years of age and had speech at 6 years of age. At 10 years of age, his IQ was at 4 to 5-year-old level. He had tapered fingers with short, brittle nails, alopecia totalis, attention deficit hyperactivity disorder (ADHD), anger and aggression, large testes with deep rugae, and some tremors and incidental myoclonus. He did not have growth delay, hypotonia or seizures and had not had brain imaging. Oligonucleotide array identified an apparently terminal 336,199 bp deletion within 10p15.3 (chr10: 115,543-451,742, hg18) (Table II). It is unknown whether this deletion is inherited or *de novo*.

Proband 14

This 3-year-old female proband was referred for cytogenetic testing due to developmental delay. Additional clinical information is not available. Oligonucleotide array identified an 181,800 bp interstitial deletion within 10p15.3 (chr10: 215,071- 396,871, hg18) (Table II). It is unknown whether this deletion is inherited or *de novo*.

Proband 15

This 23-year-old female proband was referred for cytogenetic testing due to pervasive developmental delay (PDD). Additional clinical information is not available. Oligonucleotide array identified an apparently terminal 552,443 bp deletion within 10p15.3 (chr10: 128,680- 681,123, hg18) (Table II). It is unknown whether this deletion is inherited or *de novo*.

Proband 16

On exam at age 8 years, this male proband's height was <10th centile, weight was at the 90th centile and head circumference was at the 90th centile. His birth weight was 2320 g (<10th centile). He had craniofacial dysmorphism including synophrys, thick lower lip, thickened ears and relative macrocephaly (Fig. 1G). He did not have hypotonia or seizures and nuclear magnetic resonance (NMR) brain imaging was normal. He had developmental delay, autistic behavior, stereotypy and developmental and speech delay. He had prenatal onset short stature, patchy pigment of skin/café-au-lait spots and inverted nipple. Oligonucleotide array identified an apparently terminal *de novo* 1,633,037 bp deletion within 10p15.3 (chr10: 115,544-1,748,581, hg18) (Table II).

Proband 17

This female proband was born at 35 weeks gestation; her birth weight was 1500 g (-2.5SD, <3rd centile). Pregnancy was complicated by oligohydramnios and intrauterine growth retardation (IUGR). On exam at age 2 years and 5 months, her height was 83 cm (-2.5SD),

weight was 10.7kg (-1SD) and head circumference was 45 cm (-2.5SD). On exam at age 6 years and 1 month, her height was 105.9 cm (-2.7 SD), weight was 14.8 kg (-2 SD for height) and head circumference was 47 cm (-2.4 SD). She had craniofacial dysmorphism including short palpebral fissures, depressed nasal bridge, epicanthic folds, mild cleft uvula, thin/slow growing hair, smooth philtrum, broad mouth and thin upper lip vermilion (Fig. 1H,I). At birth, a persistent foramen ovale was detected. She had overriding toes (including clinodactyly) and one depigmented and one hyperpigmented nevus on the abdomen. She did not have epileptic insults. She had intellectual disability and motor delay; she walked at 18 months and at 6 years and 1 month of age was doing well running and swimming. She had speech delay with no speech at 2 years and 5 months of age and a few words at 6 years and 1 month of age. Standard karyotype was interpreted as normal (46, XX); however, multiplex ligation-dependent probe amplification (MLPA) detected a deletion of the 10p15.3 subtelomere. SNP array confirmed this apparently terminal *de novo* 154,558 bp deletion within 10p15.3 (chr10: 148,946-303,504, hg18) (Table II). Of note, this is the only proband within this cohort of 19 individuals whose 10p15 deleted region does not include the gene *DIP2C* (Fig. 2). Minimal deletion boundaries, based on array data, are from the most distal SNP probe on the array (rs11253562 at chr10:148,946, hg18) to the most proximal deleted probe (rs4880568 at chr10:303,504, hg18), resulting in a minimal deletion of 154,558 bp (chr10: 148,946-303,504, hg18). The maximal deletion boundaries, based on array data, are from 10pter (i.e., chr10: 1) to the proximal, non-deleted probe (rs10903844 at chr10:317,582-318,082, hg18) resulting in a maximal deletion of 317,582 bp (chr10:1-317,582, hg18). Based on array data, the proximal deletion breakpoint lies within a ~15,000 bp region between rs4880568 (distally) and rs10903844 (proximally). MLPA (MRC-Holland, Amsterdam, Netherlands) further substantiated the deletion boundaries: probe P070, mapping within *ZMYND11*, was deleted while proximal probe P036B, mapping within *DIP2C*, was present (data not shown). This proximal deletion boundary was further mapped with a FISH probe (GS-23B11, with in BAC RP11-486H9) containing *DIP2C*; this probe was not deleted. Furthermore, a SNP (rs10903844) mapping between *ZMYND11* and *DIP2C* was not deleted by SNP array. In summary, *ZMYND11* lies within the deleted region while *DIP2C* does not.

Proband 18

On exam at age 48 years, this male proband's height was 163 cm (5th-10th centile), weight was 92 kg (>97th centile) and head circumference was 58.5 cm (>97th centile). He was the second child to a nonconsanguineous couple. His birth weight was 2100 g (3rd centile) at 36 weeks gestation. He was a poor feeder. He had mild hemiparesis on the left since birth. He had craniofacial dysmorphism including high forehead, arched eyebrows, depressed nasal bridge, downturned corners of the mouth, thin upper lip vermilion, small eyes, and large low-set ears (Fig. 1J). He had growth delay and moderate intellectual disability. He had global psychomotor delay with independent walking at 3 years of age. He had severe language and speech delay. He speaks with single words, a lot of repetition and no sentences. His speech has remained stable, with no regression over the years. He had tonic epilepsy beginning at age 14 months and severe grand mal and absences for which he receives medication (Valproate, Carbamazepine and Primidone). He had cortical atrophy and pachygyria of the right hemisphere; MRI, at age 42 years, revealed cortico-subcortical atrophy of the cerebral cortex with pachygyria of the right surface. He had hypotonia initially. At age 38 years, he had a cerebral accident, of unknown etiology. He has since been confined to a wheelchair with spastic quadriplegia; however, his right arm and hand have remained functional. At age 31 years, when he was still mobile, his weight was 66 kg. He has a brother who is 16 months older, is well and has at least one son. His father is one of 6 children; his mother is one of 7 children. There is not a history of other affected family members. This proband's standard karyotype was interpreted as normal (46,XY); however,

oligonucleotide array identified an apparently terminal 3,706,088 bp deletion within 10p15.3 (chr10: 106,829- 3,812,917, hg18) (Table II). This deletion was not detected in the proband's mother or brother; his father is deceased.

Proband 19

This 15-month-old female proband was referred for cytogenetic testing due to hypotonia and delayed motor skills. Additional clinical information is not available. Oligonucleotide array identified an apparently terminal 387,042 bp deletion within 10p15.3 (chr10:106,418-493,460, hg18) (Table II). It is unknown whether this deletion is inherited or *de novo*.

METHODS

Cytogenetic and Molecular Cytogenetic Analysis

Chromosomal analysis was performed on metaphase spreads prepared from PHA stimulated cultured peripheral blood lymphocytes using standard methods (Probands 1, 2, 3, 4, 17, 18). Fluorescent *in situ* hybridization (FISH) was performed to analyze all subtelomeres using the Multiprobe Chromoprobe T System (CytoCell Technologies Ltd., Cambridge, U.K.) (Proband 1). Subtel FISH was also performed in Probands 2 and 7. FISH parental studies were performed in follow up to array studies in some cases. Quantitative polymerase chain reaction (Q-PCR) of *DIP2C* was performed in Proband 9 and her parents. Multiplex ligation-dependent probe amplification (MLPA) (MRC-Holland, Amsterdam, the Netherlands) and additional FISH studies were performed in Proband 17.

Microarray Analysis

The following array platforms (Table II) were used to analyze DNA samples from the probands described in this study: Illumina HumanHap550 V1 and V3 SNP arrays (Illumina, Inc., San Diego, CA) (Probands 2 and 1, respectively), Genome-wide Human SNP Array 6.0 (Affymetrix, Santa Clara, CA) (Probands 3, 4 and 7), Custom-designed Agilent CGH array (Probands 5 and 6), ISCA 44K CGH Array (Agilent Technologies, Palo Alto, CA) (Proband 8), whole-genome oligonucleotide array CGH GenomeDx microarray V3 105k oligo (Proband 9), whole genome bacterial artificial chromosome (BAC)-based microarray (SignatureChipWG, Signature Genomics, Spokane, WA) (Proband 11), 105K-feature whole-genome oligonucleotide microarray (SignatureChipOS v1.0, custom-designed by Signature Genomics, Spokane, WA, manufactured by Agilent Technologies, Santa Clara, CA) (Probands 12 and 13), 135K-feature whole-genome oligonucleotide microarray (SignatureChipOS v2.0, custom-designed by Signature Genomics, manufactured by Roche NimbleGen, Madison, WI) (Probands 10, 14 and 15), 244K CGH Array (Agilent Technologies, Palo Alto, CA) (Proband 16), GeneChip Human Mapping 250K Nsp Array (Affymetrix, Santa Clara, CA) (Proband 17), CytoSure ISCA 180k array (Oxford Gene Technologies, Oxford, UK) (Proband 18) and ISCA 180K CGH Array (Agilent Technologies, Palo Alto, CA) (Proband 19).

RESULTS

We report on 19 unrelated probands with molecularly characterized isolated submicroscopic overlapping deletions within 10p15.3; deletions vary in size from ~154 kb (Proband 17) to ~4 Mb (Proband 11). Parental studies were performed for 9 probands (including one family in which only the proband's mother and brother were available for study); parental studies were not conducted for the remaining 10 probands. The 10p15 deletion was *de novo* in seven of the probands (Probands 1, 2, 5, 7, 9, 16, 17), not maternally inherited in one proband (Proband 18), and maternally inherited in one proband (Proband 4). No other

clinically significant copy number changes were detected by CMA in any of these individuals.

This study describes 19 unrelated individuals with submicroscopic deletions involving 10p15.3 characterized by chromosomal microarray (CMA), comprising the first such cohort reported to date. Facial features are similar, especially among individuals with small 10p15.3 deletions (i.e., Probands 1, 2, 4, 9, 13, 16, 17) as compared to an individual with a large deletion (Proband 18) (Fig. 1). Comprehensive clinical history, available for 12 of the 19 individuals described in this study, in combination with detailed molecular mapping, permitted the first assessment of genotype/phenotype correlations among individuals with submicroscopic deletions within 10p15.3 (Table I). Common clinical findings (Table I) and genes mapping within this deleted region are described (Fig. 2).

Molecular mapping of the 10p15 deleted region in 19 individuals reported in this study has identified two genes, *ZMYND11* (OMIM# 608668) and *DIP2C* (OMIM# 611380) mapping within 10p15.3 which are most commonly deleted, according to UCSC Genome Browser hg18 build (Fig. 2). Although no single gene has been identified which is deleted in all 19 individuals studied, the deleted region in all but one individual (Proband 10) includes *ZMYND11* and the deleted region in all but one other individual (Proband 17) includes *DIP2C*. The 10p15 deleted region of seven probands (Probands, 3, 5, 7, 8, 11, 16 and 18) also includes *IDII* (OMIM: 604055) and *ADARB2* (OMIM: 602065). *PFKP* (OMIM: 171840) maps within the deleted region of three probands (Probands 8, 11, and 18). *KLF6* (OMIM: 602053) lies within the deleted region of two probands (Probands 11 and 18).

DISCUSSION

We report 19 unrelated probands, the first large cohort described to date, with molecularly characterized isolated submicroscopic overlapping deletions within 10p15.3 (Fig. 2). Comprehensive clinical history was available for 12 of the 19 individuals described in this study, allowing the first assessment of genotype/phenotype correlations among individuals with submicroscopic deletions within 10p15.3 (Table I). Common features among these 12 individuals include: cognitive/behavioral/developmental differences (11/11), speech delay/language disorder (10/10), motor delay (10/10), craniofacial dysmorphism (9/12), hypotonia (7/11), brain anomalies (4/6), and seizures (3/7) (Table I). Facial features are similar, especially among individuals with small 10p15.3 deletions (i.e., Probands 1, 2, 4, 9, 13, 16, 17) (Fig. 1).

Only two additional probands with isolated, submicroscopic 10p15.3 deletion have been reported [Ravnan et al., 2006]; only limited clinical information is available for these probands and the deleted region has not been molecularly mapped. The first proband is a 10-year-old female with multiple congenital anomalies [Ravnan et al., 2006, Case 99]. The other reported proband is a 7-year-old female with developmental delay, attention deficit hyperactivity disorder and seizure disorder [Ravnan et al., 2006, Case 100].

In the cohort described in this study, 10p15 deletions can be classified into one of two groups based on the size of the deletion identified by molecular mapping. “Group A” includes probands with a smaller deleted region of 10p15.3 (maximal size of deletion ~638kb, Proband 4); this group includes twelve probands (Probands 1, 2, 4, 6, 9, 10, 12, 13, 14, 15, 17, 19) (Fig. 2). Of note, six probands in “Group A” have interstitial 10p15.3 deletions (Probands 1, 4, 9, 10, 12, 14). “Group B” includes probands with a larger deleted region of 10p15 (deletion size range ~1.1 to 4 Mb); this group includes seven probands (Probands 11, 18, 8, 5, 3, 16, 7) (Fig. 2). Surprisingly, comparison of clinical finding of probands in Group A versus Group B does not reveal striking clinical differences (Table I).

Only two OMIM genes, *ZMYND11* (OMIM: 608668) and *DIP2C* (OMIM: 611380) map to the region deleted in probands in Group A. Four additional OMIM genes [*IDII* (OMIM: 604055), *ADARB2* (OMIM: 602065), *PFKP* (OMIM: 171840) and *KLF6* (OMIM: 602053)] map to the maximal region deleted in Group B. The 10p15 deleted region of seven probands (Probands, 3, 5, 7, 8, 11, 16 and 18) also includes *IDII* (OMIM: 604055) and *ADARB2* (OMIM: 602065). *PFKP* (OMIM: 171840) maps within the deleted region of three probands (Probands 8, 11, and 18). *KLF6* (OMIM: 602053) lies within the deleted region of two probands (Probands 11 and 18).

IDII, which catalyzes a critical activation step in the isoprenoid pathway, has been shown to localize to peroxisomes and have reduced activity in liver of patients with the peroxisomal deficiency diseases Zellweger syndrome (OMIM: 214100) and neonatal adrenoleukodystrophy (OMIM: 202370) [Krisans et al., 1994]. *PFK* encodes the platelet isoform of phosphofructokinase; little is known about its possible role in human disease. *KLF6* is a ubiquitously expressed zinc-finger tumor suppressor broadly involved in differentiation and development, growth related signal transduction, cell proliferation, apoptosis, and angiogenesis [Cho et al., 2005]. Somatic *KLF6* mutations have been identified in several human cancers, including gastric and prostate [Cho et al., 2005].

ADARB2, a member of the double-stranded RNA adenosine deaminase family of RNA-editing enzymes, is expressed only in selected areas of the brain (such as amygdala and thalamus) and postmitotic neurons [Chen et al., 2000]. *ADARB2*, an inactive enzyme, binds single-stranded RNA and possibly plays a role in the regulation of substrate-specific RNA editing in mammalian brains [Chen et al., 2000]. *ADARB2* haploinsufficiency may play a role in the cognitive and developmental deficits observed in individuals described in this study.

Although no single gene has been identified which is deleted in all 19 individuals studied, the deleted region in all but one individual (Proband 10) includes *ZMYND11* (OMIM: 608668) and the deleted region in all but one other individual (Proband 17) includes *DIP2C* (OMIM: 611380) (confirmed by array, FISH, and MLPA, data not shown). Comparison of clinical findings in Proband 10 versus Proband 17 does not reveal a sticking difference suggesting that there may be functional overlap between *ZMYND11* and *DIP2C*.

The *ZMYND11* (zinc finger MYND domain-containing protein 11) protein, first identified by its ability to bind the adenovirus E1A protein, localizes to the nucleus and functions as a transcriptional repressor with expression of E1A inhibiting this repression. *DIP2C* (disco-interacting protein 2 homolog C) expression has been detected in all adult and fetal tissues and specific adult brain regions examined except lung and pancreas, where expression was low. *ZMYND11* [Kurozumi et al., 1998] and *DIP2C* [Nagase et al., 1999] are expressed in various tissues including the brain; however, little is known about their function, making direct genotype/phenotype correlation currently unclear (Table III). We suggest that *ZMYND11* and/or *DIP2C* haploinsufficiency contributes to the clinical features associated with 10p15 deletions in probands described in this study and that one or both of these genes may be causative of isolated, or minimally syndromic, intellectual disability when mutated.

Acknowledgments

We are extremely grateful to the patients and their families for their participation and cooperation. This study makes use of data generated by the DECIPHER Consortium. A full list of centres who contributed to the generation of the data is available from <http://decipher.sanger.ac.uk> and via email from decipher@sanger.ac.uk. Funding for the project was provided by the Wellcome Trust.

Contract Grant Sponsor: National Institutes of Health (NIDDK) (IDK); Contract grant number: 5 KO8 DK02541-02.

REFERENCES

- Chen CX, Cho DS, Wang Q, Lai F, Carter KC, Nishikura K. A third member of the RNA-specific adenosine deaminase gene family, ADAR3, contains both single- and double-stranded RNA binding domains. *RNA*. 2000; 6:755–767. [PubMed: 10836796]
- Cho YG, Kim CJ, Park CH, Yang YM, Kim SY, Nam SW, Lee SH, Yoo NJ, Lee JY, Park WS. Genetic alterations of the KLF6 gene in gastric cancer. *Oncogene*. 2005; 24:4588–4590. [PubMed: 15824733]
- DeScipio C, Spinner NB, Kaur M, Yaeger D, Hu S, Shan S, Krantz ID, Riethman H. Fine-mapping subtelomeric deletions and duplication by comparative genomic hybridization in 42 individuals using a newly developed telomere array. *Am J Med Genet A*. 2008; 146A:730–739. [PubMed: 18257100]
- Krisans SK, Ericsson J, Edwards PA, Keller GA. Farnesyl-diphosphate synthase is localized in peroxisomes. *J Biol Chem*. 1994; 269:14165–14169. [PubMed: 8188698]
- Kurozumi K, Nishita M, Yamaguchi K, Fujita T, Ueno N, Shibuya H. BRAM1, a BMP receptor-associated molecule involved in BMP signaling. *Genes Cells*. 1998; 3:257–264. [PubMed: 9663660]
- Lindstrand A, Malmgren H, Verri A, Benetti E, Eriksson M, Nordgren A, Anderlid B-M, Golovleva I, Schoumans J, Blennow E. Molecular and clinical characterization of patients with overlapping 10p deletions. *Am J Med Genet A*. 2010; 152A:1233–1243. [PubMed: 20425828]
- Nagase T, Ishikawa K, Suyama M, Kikuno R, Hirotsawa M, Miyajima N, Tanaka A, Kotani H, Nomura N, Ohara O. The complete sequences of 100 new cDNA clones from brain which code for large proteins in vitro. *DNA Res*. 1999; 6:63–70. [PubMed: 10231032] Prediction of the coding sequences of unidentified human genes. XIII.
- Ravnan JB, Tepperberg JH, Papenhausen P, Lamb AN, Hedrick J, Eash D, Ledbetter DH, Martin CL. Subtelomere FISH analysis of 11,688 cases: An evaluation of the frequency and pattern of subtelomere rearrangements in individuals with developmental disabilities. *Med Genet*. 2006; 43:478–489.



Figure 1. Individuals with 10p15.3 Microdeletion

A: Proband 1, B: Proband 2, C: Proband 4 with his mother, D: Proband 4, E: Proband 9 at age 1 year, 11 months, F: Proband 13, G: Proband 16 at age 7 years, H: Proband 17 at age 2 years, 10 months, I: Proband 17 at age 6 years, 1 month and J: Proband 18. Age at time of photo is noted, when known.

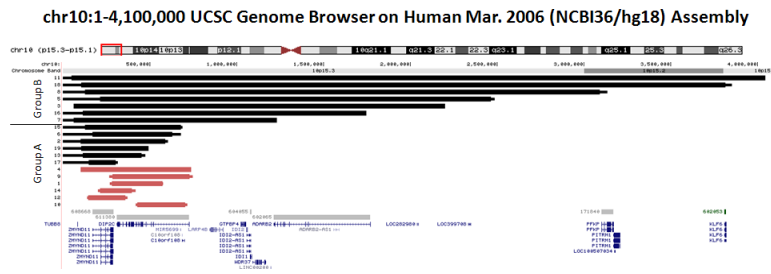


Figure. 2. Deletions in individuals with 10p15.3 microdeletion

Minimal deletion boundaries (thick bar); maximal deletion boundaries (thin bar); terminal deletions (black bars); interstitial deletions (pink bars: probands 1, 4, 9, 10, 12, 14); “Group A”: probands with a smaller deleted region; “Group B”: probands with a larger deleted region; OMIM and RefSeq Genes are represented below probands.

TABLE I

tion.

	Group A										Group B				
	Interstitial deletion (smallest to largest)					Terminal deletion (smallest to largest)					Terminal deletion (smallest to largest)				
	10	1	9	4	17	13	6	2	7	16	5	18			
278	292	446	638	154	336	461	487	1,168	1,633	2,250	3,706				
F	M	F	M	F	M	M	F	M	M	M	M				
7y	3y	1y9m	7y	6y1m	12y	5y	1y11m	5y	8y	10y	48y				
UK	10th-25th	UK	UK	-2.5SD	UK	UK	25th	UK	<10th	UK	3rd				
<5th	5th	10th	27th	-2.7SD	75th	14th	3rd	25th	<10th	<3rd	5-10th				
<5th	25th	<3rd	60th	-2SD	>97th	9th	3rd	25-50th	90th	4th	>97th				
UK	80th	NL	Macro	-2.4SD	98th	NL	75th	75th	90th	NL	>97th				
Anxiety, Repetitive behaviors	DD	DD	Global DD, ADHD, Aggression	ID	ID, ADHD, Anger, Aggression	Global DD	UK	Hyperactivity	ID, DD, Autism, Stereotypy	Mild ID	Moderate ID				
UK	Yes	UK	Yes	Yes	Yes	Yes	Yes	Yes	Yes	Yes	Yes				
UK	Yes	Yes	Yes	Yes	Yes	Yes	Yes	Yes	Yes	UK	Yes				
Yes	Yes	Yes	No	Yes	Yes	Mild	No	Yes	Yes	No	Yes				
UK	Cortical atrophy	UK	UK	UK	UK	Very small arachnoid cyst, medial temporal lobe	Hydrocephalus	No, NL MRI	No, NL, NMR	UK	Cortical atrophy and pachygyria, right hemisphere				
Mild	Yes	Yes	Yes	UK	No	Yes	Yes	No	No	No	Yes				
Hyperextensible hands, Webbed toes	5th finger clinodactyly (BL)	No	No	Over-riding toes and clinodactyly	Brittle finger nails, Tapered fingers	No	No	5th finger clinodactyly (BL), Pes planus, Clinodactyly toes 3,4,5 (BL), Fetal fat pads on all digits	No	No	UK				
No	Partial complex	UK	Evaluation pending	No	No	UK	UK	Partial complex	No	UK	Grand mal, absence, tonic				
Murmur, resolved	Bicuspid aortic valve	No	No	Foramen ovale	UK	No	No	Systolic murmur	UK	No	UK				

Group A				Group B							
Interstitial deletion (smallest to largest)		Terminal deletion (smallest to largest)		Terminal deletion (smallest to largest)		Terminal deletion (smallest to largest)					
High arched palate, Recurrent strep throat, Enlarged tonsils	Mild hirsutism, Cervical spine abnormality	GERD, Constipation, Hypoplastic nipples, Kyphosis, Frequent respiratory and serous otitis media infections	Asthma, Sleep disturbance	Oligohydramnios, IUGR, hyper/ hypopigmented nevus on abdomen, Mild cleft uvula, Thin/ slow growing hair	Alopecia totalis, Tremors and incidental myoclonus, Prominent incisors, Stellate iris pattern, Large testes with deep rugae	None	GERD, Constipation, Sacral dimple, Hydronephrosis, Ventral hernia, Redundant hymenal tissue	Diaphragmatic hernia, Mildly narrow palate, Wide-based gait, Shawl scrotum	Inverted nipple, Patchy pigment of skin/cafe au lait spots	Hypospadias	Mild left hemi-paresis since birth, current spastic quadri- plegia

Intellectual disability; ID = Intellectual disability; MRI = Magnetic resonance imaging; NMR = Nuclear magnetic resonance imaging; = intra-uterine growth retardation

5	6	7	8	9	10	11	12	13	14	15	16	17	18	19
<i>de novo</i>	UK	<i>de novo</i>	UK	<i>de novo</i>	UK	UK	UK	UK	UK	UK	<i>de novo</i>	<i>de novo</i>	not mat	UK
Yes	Yes	Yes	Yes	No	No	Yes	No	Yes	No	Yes	Yes	Yes	Yes	Yes
2,250	461	1,168	2,964	446	278	3,995	216	336	182	552	1,633	154	3,706	387
214,559	170,775	62,797	126,361	284,172	426,747	50,001	144,508	115,543	215,071	128,680	115,544	148,946	106,829	106,418
2,464,948	631,400	1,230,967	3,090,934	730,188	704,987	4,045,012	360,879	451,742	396,871	681,123	1,748,581	303,504	3,812,917	493,460
2,485	679	1,231	3,135	482	298	4,045	233	474	215	690	N/A	318	3,852	N/A
1	1	1	1	266,577	418,253	1	138,266	1	203,183	1	N/A	1	1	N/A
2,485,482	678,745	1,230,967	3,135,279	748,497	716,434	4,045,012	371,706	474,201	418,193	689,830	N/A	317,582	3,852,143	N/A
Custom-designed CGH array (Agilent)	Custom-designed CGH array (Agilent)	Genome-wide Human SNP Array 6.0 (Affymetrix)	ISCA 44K CGH Array (Agilent)	Whole-Genome Oligo Array CGH, GenomeDx microarray V3, 105K	135K-feature whole-genome oligo array SignatureChipOS v2.0 (Signature Genomics)	Whole-genome BAC array SignatureChipWG (Signature Genomics)	105K oligo (Signature ChipOS v1.0)	105K oligo (Signature Chip OS v1.0)	135K-feature whole-genome oligo array SignatureChipOS v2.0 (Signature Genomics)	135K-feature whole-genome oligo array SignatureChipOS v2.0 (Signature Genomics)	244K CGH Array (Agilent)	GeneChip Human Mapping 250K Nsp Array (Affymetrix)	CytoSure ISCA 180K Array (OGT)	ISCA 180K CGH Array (Agilent)

Am J Med Genet A. Author manuscript; available in PMC from 2013 September 01.

TABLE III

Genes Most Commonly Deleted in This Cohort of Nineteen Individuals

Gene	Full name	Function	Expression in tissues including*
<i>ZMYND11</i>	zinc finger MYND domain containing protein 11	regulator of NF-kappaB activation	brain, liver, kidney, lung, colon, testis
<i>DIP2C</i>	disco-interacting protein 2 homolog C (Drosophila)	Unknown	brain, liver, kidney, lung, fetal heart, spleen, ear, testis