

Prenatal diagnosis of urinary malformations: results in a series of 93 consecutive cases

Yves Brunisholz^a, Yvan Vial^b, Catherine Maillard-Brignon^a, Blaise Julien Meyrat^b, Peter Frey^b, Patrick Hohlfeld^a

^aDépartement de Gynécologie-Obstétrique, Maternité du CHUV, Lausanne, Switzerland

^bService de Chirurgie Pédiatrique du CHUV, Lausanne, Switzerland

Summary

Objective: to evaluate the pertinence of prenatal diagnosis in cases of congenital uropathy.

Study design: retrospective evaluation over a period of 6.5 years.

Method: 93 cases were involved in the comparison of prenatal ultrasonographic diagnosis with neonatal findings, autopsy results, and follow-up data.

Results: 33 fetuses had renal parenchymal lesions, 44 had excretory system lesions, and 6 had bladder and/or urethral lesions. Seventy-three pregnancies lead to live births. Eighteen terminations of pregnancy were performed on the parents' request for extremely severe malformations. Two intrauterine deaths were observed, and two infants died in the postnatal period. Prenatal diagnosis was obtained at an average of 27 weeks' gestation. Diagnostic concordance was excellent in 82% and partial in 12% of cases with renal parenchymal lesions; the false-positive rate was 6%. For excretory

system lesions, concordance was excellent in 87% and partial in 7.4% of cases, with a false-positive rate of 5.6%. Finally, concordance was excellent in 100% of cases of bladder and/or urethral lesions.

The overall rate of total concordance was 86%. Partial concordance cases consisted of malformations different from those previously diagnosed, but prenatal diagnosis nevertheless lead to further investigations in the neonatal period and to proper management. The false-positive diagnoses (5.4%) never lead to termination of pregnancy.

Conclusion: prenatal diagnosis of congenital uropathy is effective. A third-trimester ultrasonographic examination is necessary to ensure proper neonatal management, considering that the majority of cases are diagnosed at this gestational age.

Keywords: urinary malformations; congenital uropathy; ultrasonography

Introduction

Urinary tract and renal abnormalities represent 20% of all congenital malformations [1]. If undiagnosed before birth, they can lead to progressive hydronephrosis [2] and/or terminal renal failure (77% of cases) during infancy.

Systematic ultrasonographic screening allows the diagnosis of most urinary abnormalities. Thus, specific neonatal management and long-term follow-up can be planned for each case [3]. When end-stage renal disease is suspected, fetal renal

function can be evaluated through urinary electrolytes analysis [4–5] and/or fetal blood sampling [6]. Once the prognosis has been ascertained, prenatal invasive treatment can be considered in cases of bilateral progressive lesions [7–10].

The aim of this study was to describe the pertinence of prenatal diagnosis of congenital uropathies by comparing prenatal data with definitive clinical, surgical, or pathological diagnoses.

Patients and methods

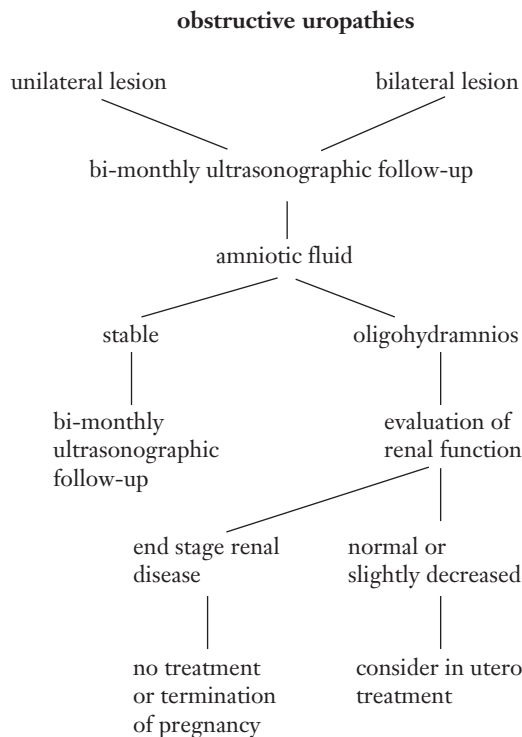
In this retrospective study, we analysed 105 cases of urinary tract and renal malformations, prenatally detected by ultrasonography in our Department between 1990 and 1996. Twelve cases were excluded from the study: eleven were lost to follow-up right after the neonatal period, and one did not undergo usual neonatal investigations. Hence,

93 cases were actually included in the study. The majority of patients (70 of 93) was referred for level III ultrasonography. Positive family history was present in 4 of the 93 cases.

During this period, three ultrasonographic examinations were systematically performed during pregnancy. All women had the same ultrasonographic screening with 3

scans during pregnancy. The first scan was done at 12 and 14 weeks in order to ascertain gestational age. The second and third scans were performed between 22 and 32 weeks. Pyelic dilatation was considered when the antero-posterior diameter exceeded 5 mm before 32 weeks or 8 mm later in pregnancy [11–14].

Figure 1
Management of obstructive uropathies.



When lethal lesions were detected, termination of pregnancy or palliative neonatal treatment was discussed with the parents. In all other cases, a multidisciplinary approach was organised, including paediatricians and paediatric surgeons whom the parents met systematically before birth. When parents elected to proceed with the pregnancy, a regular ultrasonographic follow-up was routinely initiated.

The management of obstructive lesions is summarized in Figure 1. In cases of bilateral lesions associated with oligohydramnios, an analysis of the fetal renal function was performed. It was achieved by urine sampling under ultrasonographic guidance and measurement of urinary electrolyte concentrations [4–5]. In some cases, fetal blood sampling was also carried-out in order to measure serum β 2-microglobulin and/or perform a karyotype analysis [6].

The pertinence of prenatal ultrasonographic screening was studied by comparing prenatal diagnoses with the results of pathology examinations, complete neonatal check-ups (including systematic ultrasonographic imaging and, in some cases, intravenous pyelogram, voiding cystourethrography or renal scintigraphy), and surgical diagnoses when available. Neonatal sonograms were performed 4 to 5 days after birth because earlier examinations are less reliable due to the physiological neonatal hypovolemia. Blood analysis and urine culture were also systematically performed. Detailed postnatal follow-up is described in Table 1 [15–16].

When there was perfect agreement between pre- and postnatal diagnoses, the concordance was considered excellent. It was considered partial when prenatal ultrasound incompletely described the patient's condition. In false-positive cases, the suspected diagnosis was not confirmed after birth.

Table 1

Timing of the first postnatal examinations according to the neonatal diagnosis.

Neonatal diagnosis	ultrasound	renal scintigraphy	cysto-urethrography
Pyelo-ureteral stenosis	3 months	3 months	–
Vesico-ureteral reflux I-II	1 year	2 years	–
Vesico-ureteral reflux III	6 months	1 year	1 year
Uretero-vesical stenosis	3 months	3 months	–
Ureterocele	3 months	3 months	3 months

Results

Five cases (5.4%) were diagnosed in the first, 35 cases (37.6%) in the second, and 53 cases (57%) in the third trimester of pregnancy. Mean gestational age at the time of diagnosis was 27.5 weeks, and in 63.5% of cases diagnosis was established after the 22nd week. Fetal urinary abnormalities were grouped according to their location: kidney (35.5%), higher urinary tract (58%) and lower urinary tract (6.5%) (Table 2).

Mean gestational age at the time of diagnosis varied in the different groups: 27.1 weeks [range: 15–40] in higher urinary tract lesions (n = 54); 27.4 weeks [range: 12–40] in renal lesions (n = 33) and 21.8 weeks [range: 12–34] in lower urinary tract lesions (n = 6). Fetal karyotype was studied in 22 cases (23.7%). Fetal serum β 2-microglobulin and urine electrolytes were measured in one case. Trisomy 18 was observed in one fetus presenting with early isolated megabladder.

According to the parents' wish, termination of

pregnancy was performed in 18 cases at a mean gestational age of 20.9 weeks [range: 12–31]: Prune-Belly syndrome (n = 4), Potter syndrome (n = 4), polycystic kidneys (n = 5), Trisomy 18 (n = 1), and multiple severe malformations (n = 3). All 18 cases were associated with early anamnios. Intrauterine death of unknown origin was observed in two fetuses, for which necropsy findings confirmed the prenatal diagnosis.

Obstetrical outcome for the remaining 73 patients was comparable to our general population. Instrumental delivery or Cesarean section (24.3%) was performed on pure obstetrical indications during labour. Mean gestational age at delivery was 39 weeks 2 days [range: 26–42]. Mean birth weight was 3323 g [range: 750–4470]. Mean APGAR score was 8.0 [range: 2–10] at 1 minute, 9.1 [range: 2–10] at 5 minutes and 9.4 [range: 2–10] at 10 minutes.

One newborn died after 10 minutes. He was diagnosed with left renal agenesis and right mul-

Table 2
Fetal urinary
abnormalities.

Ultrasonographic diagnosis	n	liveborn	TOP	IUD	MGAD
Pathology of the renal parenchyma					
Multicystic kidney and isolated cyst	6	3	2	1	28.7
Polycystic kidney	16	15	1	0	28.1
Horseshoe kidney	2	2	0	0	25.0
Hyperechogenic kidney	1	1	0	0	26
Renal agenesis	8	1	7	0	22.3
Pathology of higher urinary tract					
Hydronephrosis	37	34	2	1	29.5
Pyelic dilatation	15	15	0	0	25.2
Ureterocele	1	1	0	0	27
Ureteral dilatation	1	1	0	0	28
Pathology of the bladder and/or urethra					
Prune-Belly syndrome	4	0	4	0	19.4
Megabladder	1	0	1	0	16
Bladder agenesis	1	0	1	0	26

TOP: termination of pregnancy IUD: intrauterine demise MGAD: mean gestational age at the time of diagnosis

ticystic dysplasia as of the 20th week, and suffered from chronic oligohydramnios. The parents did not wish to consider termination of pregnancy.

All other infants (n = 72) received prophylactic antibiotherapy and underwent neonatal investigations as planned. The mean duration of follow-up was 21.9 months, [range: 3-60] in this population.

Conservative management was chosen in 42 cases. The outcome was good for 30 of the 42 infants. One infant having multiple malformations died at the age of 4 months. Two of the 42 infants showed a decreased renal function, and one underwent surgical treatment during the follow-up period. Nine infants out of the forty-two were lost to follow-up.

Surgical treatment was necessary in 30 cases. Eighteen Anderson-Hynes pyeloplasties were performed with and without preoperative percutaneous drainage for pyeloureteral junction stenosis associated with hydronephrosis. Unilateral nephrectomy was performed in 3 infants showing non functional unilateral multicystic kidney. Four infants underwent ureteral reimplantation, and three had endoscopic ureterocele incision and dilatation of uretero-vesical stenosis. Electrocoagulation of posterior urethral valves was performed in one case. One infant had to undergo surgery at age two after failure of the conservative management (right nephro-ureterectomy).

Nineteen infants were considered cured and 2 were considered stabilised. In four cases, the renal function deteriorated despite surgical treatment. A first infant developed progressive renal failure three years after being treated for junction steno-

sis (ureterocystoneostomy). A second one treated for bilateral hydronephrosis due to posterior urethral valves exhibited a significant unilateral decrease of the renal function (12%) 5 months after surgery. A third infant operated on for unilateral hydronephrosis due to pyeloureteral junction stenosis showed a slight decrease in renal function. The fourth one died at 4 months (multiple malformations). Four other infants were lost to follow-up after surgery.

Agreement between pre- and postnatal diagnoses

Concordance was excellent in 82% of renal parenchymal lesions, in 87% of higher urinary tract malformations, and in 100% of bladder or urethra abnormalities. Partial concordance was observed in 8 of the 93 cases (8.6%), but management was unchanged. Partial concordance occurred in 12% of renal parenchymal lesions and 7.4% of higher urinary tract malformations. Neonatal check-up showed simple pyelic dilatations in two cases of suspected polycystic kidney. Two prenatally diagnosed isolated renal cysts were in fact a renal neuroblastoma and a cystic lymphangioma. One renal duplication and one multicystic kidney were mistaken for hydronephrosis, and two suspected pyelic dilatations were in fact extra-renal pelvis.

False-positive prenatal diagnoses were observed in 6% of renal parenchymal lesions and 5.6% of higher urinary tract malformations. Two hyperechogenic kidneys and three pyelic dilatations were not confirmed after birth.

Discussion

Numerous studies have shown the efficacy of ultrasonographic screening of fetal malformations [1-17]. Published data show a significant geo-

graphic variation in the incidence of uropathies detected antenatally by routine ultrasound examinations [18]. Prenatal detection rate also varies ac-

ording to the frequency and timing of ultrasonographic examinations during pregnancy [1], and the chosen cut-offs for normal values [3].

In our study, bladder and urethra malformations were detected at an earlier age (21.8 weeks) compared to other urinary abnormalities. These lesions are often incompatible with survival and need to be detected as early as possible if termination of the pregnancy is to be discussed with the parents. Higher malformations are diagnosed at a later age (27 weeks). If the third-trimester ultrasonographic examination is not performed, these lesions will be missed at birth and the infants will not benefit from adequate prenatal and neonatal management, which is known to reduce the risk of renal failure. Diagnosis was established even later during pregnancy in patients requiring immediate surgery after birth (29 weeks). Thus, one third of infants (n = 29) presenting with urinary pathologies would not have been diagnosed without third-trimester ultrasound, leading to long-term renal function deterioration.

In our series, false-positive prenatal diagnosis never lead to termination of pregnancy, but caused unnecessary burden of anxiety to the parents. This retrospective study confirms the pertinence (86%) of prenatal ultrasonographic examinations. Vanderstichele et al. [19] described a 78% concordance in a series of 147 cases. In a large retrospective study, Droullé et al. [20] found that prenatal diagnosis was correct in 87% of cases. Sanghvi et al.

[17] reported 81.5% concordance for at least one ultrasonographic examination performed between 20 and 37 weeks gestation. As compared to cardiac or cerebral malformations which are considered difficult to detect, urinary abnormalities are more readily visible, because they are most often associated with hypoechogenic adjunctive lesions. Proper identification of the malformation can be performed in a referral centre, allowing adequate neonatal management in order to avoid recurrent urinary tract infections and renal failure. It is then obvious that systematic ultrasound examination during the third trimester of pregnancy should be recommended, since two thirds of the cases were diagnosed beyond the 24th week in our series as well as in others [17–21].

On the other hand, it is more difficult to demonstrate that early neonatal surgical therapy leads to a better outcome on a long term basis. Nevertheless, published data tend to show that infants presenting with uropathies detected later in life suffer more frequently from recurrent urinary tract infections [22–23]. These infections lead to a higher risk of severe and definitive renal function impairment.

Correspondence:

Dr méd. Yvan Vial

Service de gynécologie-obstétrique

Rue du Bugnon

CH-1011 Lausanne

References

- Kim EK, Song TB. A study on fetal urinary tract anomaly: antenatal ultrasonographic diagnosis and postnatal follow-up. *J Obstet Gynecol* 1996;22:569–73.
- Bugmann P, Negrini JF, Extermann P, Genin B, La Scala G, Girardin E, et al. Efficacité de la détection prénatale des uropathies par l'échographie. *Méd Hyg* 1998;56:311–4.
- Corteville JE, Gray DL, Crane JP. Congenital hydronephrosis: Correlation of fetal ultrasonographic findings with infant outcome. *Am J Obstet Gynecol* 1991;165:384–8.
- Guez S, Assael BM, Melzi ML, Tassis B, Nicolini U. Shortcomings in predicting postnatal renal function using prenatal urine biochemistry in fetuses with congenital hydronephrosis. *J Pediatr Surg* 1996;31:1401–4.
- Qureshi F, Jacques SM, Seifman B, Quintero R, Ewans MI, Smith C, et al. In utero fetal urine analysis and renal histology correlate with the outcome in fetal obstructive uropathies. *Fetal Diagn Ther* 1996;11:306–12.
- Berry SM, Lecolier B, Smith RS, Bercau G, Dombrowski MP, Puder KS, et al. Predictive value of fetal serum Beta-2 microglobulin for neonatal renal function. *Lancet* 1995;345:1277–8.
- Thorup F, Mortensen T, Diemer H, Johnsen A, Nielsen OH. The prognosis of surgically treated congenital hydronephrosis after diagnosis in utero. *J Urol* 1985;134:914–7.
- Lewis KM, Pinckert TL, Cain MP, Ghidini A. Complications of intrauterine placement of a vesicoamniotic shunt. *Obstet Gynecol* 1998;91:825–7.
- Coplen DE. Prenatal intervention for hydronephrosis. *J Urol* 1997;157:2270–7.
- Szafflik K, Kozarzewski M, Adamczewski D. Fetal bladder catheterisation in severe obstructive uropathy before the 24th week of pregnancy. *Fetal Diagn Ther* 1998;13:133–5.
- Blachar A, Blachar Y, Livne PM, Zurkowski L, Pelet D, Mogilner B. Clinical outcome and follow-up of prenatal hydronephrosis. *Pediatr Nephrol* 1994;8:30–5.
- Rickwood AMK, Harney JV, Jones MO, Oak S. Congenital hydronephrosis: limitations of diagnosis by fetal ultrasonography. *Br J Urol* 1995;75:529–30.
- Crombleholme TM, Harrison MR, Longaker MT, Langer JC. Prenatal diagnosis and management of bilateral hydronephrosis. *Pediatr Nephrol* 1988;2:334–42.
- Elder JS. Antenatal hydronephrosis: fetal and neonatal management. *Pediatr Clin North Am* 1997;44:1299–321.
- Chevalier RL, Klahr S. Therapeutic approaches in obstructive uropathy. *Sem Nephrol* 1998;18:652–8.
- Geary DF. Attitude of pediatric nephrologists to management of end-stage renal disease in infants. *J Pediatr* 1998;133:154–6.
- Sanghvi KP, Merchant R H, Gondhalekar A, Lulla CP, Mehta AA, Mehta KP, et al. Antenatal diagnosis of congenital renal malformations using ultrasound. *J Trop Ped* 1998;44:235–40.
- Thomas DF. Prenatally detected uropathy: epidemiological considerations. *Br J Urol* 1998;81:8–12.
- Vanderstichele S, Dufour P, Lefebvre C, Valat AS, Puech F, Codaccioni X, et al. Panorama des uropathies dépistées en période anténatale. *J Gynecol Obstet Biol Reprod* 1997;26:379–85.
- Droullé P, Didier F, Schmitt M. Registre Nancéen des malformations réno-urinaires. *Médecine fœtale et échographie en gynécologie* 1993;15:35–9.
- Shimada K, Hosokawa S, Tohda A, Matsumoto F, Suzuki M, Morimoto Y. Follow-up of children after fetal treatment for obstructive uropathy. *Int J Urol* 1998;5:312–6.
- Weiss RA. Update on childhood urinary tract infections and reflux. *Sem Nephrol* 1998;18:264–9.
- Ahmed SM, Swedlund SK. Evaluation and treatment of urinary tract infections in children. *Am Fam Phys* 1998;57:1573–80.

The many reasons why you should choose SMW to publish your research

What Swiss Medical Weekly has to offer:

- SMW's impact factor has been steadily rising, to the current 1.537
- Open access to the publication via the Internet, therefore wide audience and impact
- Rapid listing in Medline
- LinkOut-button from PubMed with link to the full text website <http://www.smw.ch> (direct link from each SMW record in PubMed)
- No-nonsense submission – you submit a single copy of your manuscript by e-mail attachment
- Peer review based on a broad spectrum of international academic referees
- Assistance of our professional statistician for every article with statistical analyses
- Fast peer review, by e-mail exchange with the referees
- Prompt decisions based on weekly conferences of the Editorial Board
- Prompt notification on the status of your manuscript by e-mail
- Professional English copy editing
- No page charges and attractive colour offprints at no extra cost

Editorial Board

Prof. Jean-Michel Dayer, Geneva
 Prof. Peter Gehr, Berne
 Prof. André P. Perruchoud, Basel
 Prof. Andreas Schaffner, Zurich
 (Editor in chief)
 Prof. Werner Straub, Berne
 Prof. Ludwig von Segesser, Lausanne

International Advisory Committee

Prof. K. E. Juhani Airaksinen, Turku, Finland
 Prof. Anthony Bayes de Luna, Barcelona, Spain
 Prof. Hubert E. Blum, Freiburg, Germany
 Prof. Walter E. Haefeli, Heidelberg, Germany
 Prof. Nino Kuenzli, Los Angeles, USA
 Prof. René Lutter, Amsterdam,
 The Netherlands
 Prof. Claude Martin, Marseille, France
 Prof. Josef Patsch, Innsbruck, Austria
 Prof. Luigi Tavazzi, Pavia, Italy

We evaluate manuscripts of broad clinical interest from all specialities, including experimental medicine and clinical investigation.

We look forward to receiving your paper!

Guidelines for authors:

http://www.smw.ch/set_authors.html

Impact factor Swiss Medical Weekly



All manuscripts should be sent in electronic form, to:

EMH Swiss Medical Publishers Ltd.
 SMW Editorial Secretariat
 Farnsburgerstrasse 8
 CH-4132 Muttenz

Manuscripts: submission@smw.ch
 Letters to the editor: letters@smw.ch
 Editorial Board: red@smw.ch
 Internet: <http://www.smw.ch>