

Endoscopic and surgical treatment of vesico-ureteral reflux in children

Comparative long-term follow-up

Christophe Oberson^a, Ariane Boubaker^b, Pascal Ramseyer^a, Blaise Julien Meyrat^a, Peter Frey^a

^a Paediatric Urology, Department of Paediatric Surgery, Centre Hospitalier Universitaire Vaudois

^b Department of Nuclear Medicine, Centre Hospitalier Universitaire Vaudois

Summary

Principles: This retrospective study analyzes the long-term results of endoscopic and surgical treatment of vesico-ureteral reflux in children.

Methods: A cohort of 130 patients, 67 girls and 63 boys with a mean age of 30 months were treated either by endoscopic subureteral collagen injection (SCIN) in 92 and by Cohen reimplantation surgery in 123 refluxing ureteral units. Mean follow-up was 4.2 years varying from 1 to 8.7 years. Reflux recurrence, urinary tract infection (UTI) and renal function were evaluated.

Results: After SCIN reflux was absent in 64% at 6 months. 20% of the initially 92 refluxing ureters were injected twice. After one or two injections reflux was absent in 71%. In 21% recurrent reflux was of grade I or II, not requiring further treatment. UTI was observed in 27%. After Cohen ureteral reimplantation reflux was absent

in 96% at 6 months. UTI was observed in 23%. Renal function at diagnosis and follow-up was compared in children with bilateral grade III reflux only. In patients treated with SCIN it was normal in 77% preoperatively and in 90% at follow-up. In patients treated by open surgery it was normal in 47% preoperatively and in 76% at follow-up.

Conclusion: For high-grade vesico-ureteral reflux re-implantation surgery remains the gold standard. SCIN is indicated for low and medium grade reflux. Recurrent bacteriuria was observed more often after SCIN and pyelonephritis more often after open surgery. The renal function seems to be preserved with both techniques.

Key words: vesico-ureteral reflux; endoscopy; collagen; reimplantation; radioisotope renography

Introduction

Vesico-ureteral reflux (VUR) is characterized by retrograde flow of urine from the bladder into the upper urinary tract. It affects approximately 1% of children and in the postnatal period is frequently associated with urinary tract infections (UTI), which lead to diagnostic procedures and final diagnosis [1–2]. Prenatal findings of hydronephrosis and mega-ureter should also initiate postnatal diagnostic procedures to exclude or confirm reflux. Untreated reflux may be responsible for recurrent upper UTI, renal scarring and in the long-term for renal insufficiency and hypertension [3–4]. The primary aim of reflux therapy is the prevention of parenchymatous damage due to ascending UTI. This therapy can be either medical or surgical. Medical therapy with long-term antibiotic prophylaxis is based on the principle that reflux often resolves with time. Antibiotic prophylaxis can be compromised by lack of com-

pliance, break-through infections due to antibiotic resistance and rarely by side effects of the therapy. Spontaneous resolution of VUR decreases with increasing grade of reflux [5]. Interventional therapy cures reflux immediately and therefore prevents ascending infection. It is done either by surgical ureteral reimplantation, applying the techniques of Cohen [6], Leadbetter-Politano [7], Lich-Gregoir [8] or Glenn-Anderson, or by endoscopic subureteral injection of a bulking agent. All techniques are based on the principle of elongation of the intravesical submucosal tunnel of the ureter. The endoscopic procedure has become more common, because patients prefer to undergo less painful outpatient surgery without scarring. Non-biological, but biocompatible bulking agents such as polytetrafluorethylene (Teflon) or silicone have been injected. Persistence in the body, local granuloma formation, distant migra-

tion [9–10] are disadvantages of these agents. Nowadays degradable biological materials such as bovine collagen [11] or hyaluronic acid (Deflux®) [12] are predominantly used, although they are less effective in curing reflux than non-degradable materials. In the use of collagen and Deflux® no particle migration has been observed, however collagen could theoretically provoke anaphylactic

reaction, which is unlikely in the use of Deflux® [13].

In this study we retrospectively analyzed our long-term experience of Cohen re-implantation versus endoscopic subureteral collagen injection (SCIN) [14] in regard to reflux recurrences, UTI and renal function.

Material and methods

Between 1992 and 1999, 130 children, 67 girls and 63 boys with a total of 215 refluxing ureteral units were treated by endoscopic subureteral collagen injection (SCIN) or by ureteral reimplantation according to Cohen.

Of the 215 refluxing ureteral units, 92 were treated by SCIN in 56 children and 123 by Cohen reimplantation in 74 cases. Reflux was diagnosed by standard voiding cystourethrography (VCUG) and graded according to the International Reflux Study (IRS) in children [15]. The repartition of initial reflux according to its grade and to the respective method of treatment is demonstrated in figure 1. Ureters showing grade I or II were only treated if the contralateral ureter had reflux of a higher grade as seen in 35 patients. In a further 8 cases low-grade reflux was treated because of break-through infections despite antibiotic prophylaxis or because deteriorating renal function was observed. Mean age at the first operation was 2.6 years, (2 months to 11.8 years) and the average follow-up was 50 months (12 to 104 months).

SCIN was performed under general anaesthesia with the patient placed in lithotomy position using a 9.5 or 11.5Ch cystoscope, according to the previously described method [16]. The average collagen injected per refluxing units was 2.7mls ranging from 0.4 to 4.5mls. Anti-reflux surgery consisted in trans-trigonal ureteroneocystostomy according to Cohen [6].

Postoperatively antibiotic treatment was given for 10 days followed by prophylaxis until VCUG proved the absence of reflux at the 6-month control. In addition patients treated with SCIN underwent a second VCUG at 12 months to exclude late recurrence. Ultrasonography was performed at each control.

I-123-hippuran renography was performed at diagnosis and 2 to 8 years after injection or surgery. Absolute individual renal function was measured by an accumulation index (AI) defined as the percentage of injected dose (% ID) extracted by each kidney 30 to 90 seconds after heart-peak activity injection. Normal AI (mean±SD) is 9±2 %ID in children aged >1 year, 8±2 %ID in neonates and infants [17–18].

Proven upper UTI led to further ultrasonography and VCUG. Apart from radiological work-up, medical history taking and clinical examination was performed at up to 5 years after treatment. Bacteriuria, seen in lower UTI, was characterized by $\geq 10^5$ bacteria/ml, with temperature lower than 38.5 °C. Pyelonephritis, seen in upper UTI, was characterized by $\geq 10^5$ bacteria/ml with temperature higher than 38.5 °C and bacterial monoculture. In patients with a history of urinary tract symptoms with urgency, pain at micturition without positive bacterial culture we considered a dysuria syndrome likely to be present.

Results

The initial 215 refluxing ureters treated either by endoscopic subureteral collagen injection (SCIN) (92 ureters) or by Cohen's reimplantation surgery (123 ureters), according to their grade, are shown in figure 1.

Voiding cystourethrography performed immediately after SCIN showed the absence of

reflux in all cases. These patients were followed up with a further voiding cystourethrography at 6 months. Reflux was absent in 61 of the 92 ureters (64%) treated by SCIN after one injection. Early recurrence of reflux after one injection is shown in figure 2 and its repartition in table 1. Of the 31 ureters with recurrent reflux at 6 months, 18 ureters in 14 patients (20% of the total of 92 ureters) required a second collagen injection. The remaining refluxing ureters showed reflux of grade I or II not requiring any further interventional treatment. In another 6 ureters in 3 patients, we found a late recurrence after one year that required a second collagen injection. Of all 24 re-injected ureters only 2 ureters in one patient were ultimately reimplanted for persistence of grade III reflux bilaterally. In the remaining ureters absence of reflux was noticed in 15 and recurrent reflux of grade I and II, not needing any further interventional treatment, in 7 ureters. In

Figure 1
Repartition of initially refluxing ureters according to grade of reflux and to type of treatment: SCIN endoscopic subureteral collagen injection (n = 92) or Cohen's reimplantation surgery (n = 123).

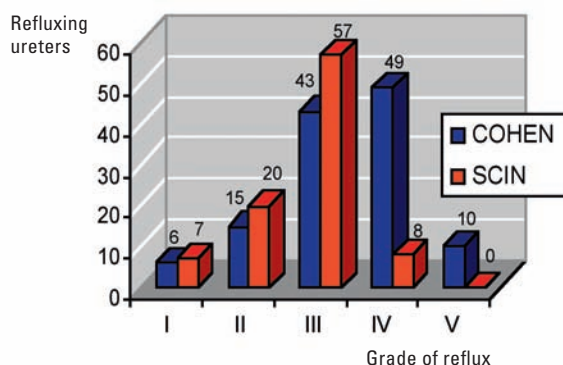
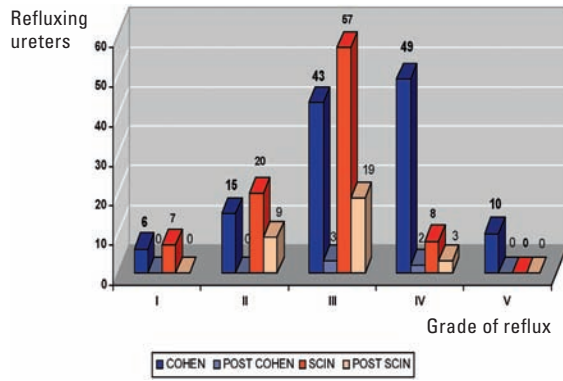


Figure 2

Repartition of recurrent refluxing ureters after treatment with SCIN endoscopic subureteral collagen injection (n = 92) or Cohen's reimplantation surgery (n = 123), according to grade of initial reflux.



the observation period between 12 months and 104 months (1 to 8.7 years) the overall absence of reflux after one or two injections was noted in 65 (71%) of the initial 92 refluxing ureters. In addition 19 ureters (21%) showed recurrent reflux of grade I or II not requiring further interventional treatment. In 6 ureters (6%) presenting with higher reflux recurrences antibiotic prophylaxis was re-administered and a further 2 ureters (2%) were operated upon with reimplantation surgery.

At 6 months reflux was absent in 118 of the 123 ureters (96%) treated by Cohen reimplantation. Of the 5 ureters with recurrent reflux at 6 months, 3 ureters in 2 patients (2.5% of the total of 123 ureters) required further interventional treatment, two by SCIN and one by reimplantation surgery. The remaining two were of low grade reflux and therefore did not require any treatment. One of 118 ureters where reflux was absent developed distal ureteral stenosis needing resection and secondary reimplantation.

Postoperative UTI were reported in 15 patients (27%) treated with collagen injection, and in 17 (23%) treated with Cohen reimplantation. In these patients pyelonephritis and bacteriuria were differentiated. Their appearance in relation to the following successful and non-successful treatment was analyzed and is shown in table 2. Postoperative dysuria was observed in 5 patients treated with SCIN and in 3 after Cohen reimplantation.

All patients had I-123-OIH-renography at diagnosis and follow-up. We analyzed separate renal function in subgroups of 39 children with bilateral grade III matched for the age at diagnosis, surgery and follow-up. High grade reflux, impaired renal function and break-through infection were indications per se to perform open reflux surgery. However, in patients with reflux grade III without impaired function and infection, collagen injection was preferably used. 20 children were treated with SCIN, 19 by Cohen reimplantation. Initial function was decreased in 9 (23%) of 40 kidneys selected for SCIN, in 20 (53%) of 38 selected for the Cohen operation. It remained decreased at follow-up in 7 (18%) and 9 (24%), respectively. Preoperative AI was 9.8 ± 1.7 %ID in the SCIN group, 8.0 ± 3.2 %ID in the Cohen group. At follow-up, AI increased in both groups: 11.4 ± 2.2 %ID and 10.4 ± 3.4 %ID, respectively. 20 children (8 SCIN, 12 Cohen) had surgery before 1 year of age, 19 children after this age (12 SCIN, 7 Cohen). In the younger infants, AI increased from 9.5 ± 1.7 %ID in the SCIN group, and from 7.7 ± 3.0 %ID in the Cohen group. One kidney treated with SCIN had an initially decreased

Table 1

Distribution of the recurring vesicoureteral reflux after treatment at 6 months, according to its initial grade.

Treatment	Grade of initial reflux	Number of initially refluxing ureters	Recurrent reflux according to its grade					Total
			I	II	III	IV	V	
SCIN	I	7	0	0	0	0	0	0
	II	20	0	7	2	0	0	9
	III	57	4	11	4	0	0	19
	IV	8	0	1	1	1	0	3
	V	0	-	-	-	-	-	-
COHEN	I	6	0	0	0	0	0	0
	II	15	0	0	0	0	0	0
	III	43	0	2	1	0	0	3
	IV	49	0	1	1	0	0	2
	V	10	0	0	0	0	0	0

Table 2

Repartition of patients with bacteriuria or pyelonephritis either with or without recurrent reflux after endoscopic subureteral collagen injection (SCIN) or Cohen reimplantation surgery.

Patients with	Scin (n = 56)		Cohen (n = 74)	
	Without reflux n = 26	With recurrent reflux n = 30	Without reflux n = 69	With recurrent reflux n = 5
Bacteriuria	4	6	7	1
Pyelonephritis	0	5	8	1

function that remained unchanged, whereas 13 of 24 kidneys submitted to Cohen had an initially decreased function that normalized in 8 at follow-up. In children operated after 1 year of age, AI re-

mained unchanged in the SCIN group (at diagnosis: 10.2 ± 1.8 %ID, at follow-up: 10.8 ± 2.8 %ID). In the Cohen group, AI increased from 8.5 ± 3.5 %ID to 10.4 ± 3.7 %ID.

Discussion

In this study the medium and long-term outcome following the treatment of VUR by endoscopic collagen injection (SCIN) is evaluated and compared to that after ureteral reimplantation surgery. In particular the reflux recurrence rate, the appearance of postoperative UTI and the dynamics of renal function were analyzed. This paper is based on a retrospective analysis. High grade reflux, impaired renal function and breakthrough infection were indications per se to perform open reflux surgery. However, in patients with reflux grade III without impaired function and infection, collagen injection was preferably used. Therefore no randomization of the patients regarding collagen injection and open surgery could be performed and statistical comparison was limited.

In our experience the recurrence rate of reflux after endoscopic injection was comparable to those reported in the literature. In our series an overall absence of reflux was found in 64% 6 months after the first injection. Over an average observation period of 50 months (12–104 months) the absence of reflux after one or two injections increased to 71%. In addition in 21% of ureters an improvement to reflux grade I or II was present, requiring no further treatment. Capozza et al. [19], who followed a larger cohort with 953 ureters in 679 patients, reported a over-all cure rate of reflux of 72% ureters following one or two injections after one year. Another study, where only collagen was used as injection material showed similar results [20], with 74% of refluxing ureters cured by SCIN. In 1995 Frey et al. [16] reported absence of reflux in 63%, after one and in 80% after two injections. Laeckgren et al. [21] using dextranomer/hyaluronic acid as injectable material reported comparable findings describing absence of reflux after 1 or 2 injections in 67%. In our study 36% of ureters showed recurrent reflux after one injection at 6 months, however, only 20% needed a second injection, where reflux was of persistent high grade (III–IV) or recurrent UTI of the upper tract was occurring. In accordance with other authors [22], we believe that even if reflux recurrence appears at a later state, the kidney is protected during the reflux-free period, in particular during early life when renal growth is accelerated and infection can be deleterious for renal function.

If we compare SCIN and Cohen reimplantation, the latter is more reliable with 96% of ureters free of reflux after operation. If reflux recurs following both methods of treatment, it is

in the majority of cases of a lesser grade. The risk of stenosis of the vesico-ureteral junction after Cohen reimplantation is small, with only 1.3% patients affected, however, if present, early surgical correction or dilatation is mandatory to preserve renal function. Following SCIN, high grade reflux persisted in only 2% after one or two injections and Cohen reimplantation could easily be performed, as SCIN does not cause any alterations of the uretero-vesical junction and in particular no unwanted scar formation compromising reflux surgery. Contrary to the Cohen procedure, SCIN allows easy endoscopic and radiological investigation of the ureters. Disappearance of reflux can be radiologically assessed in every patient during recovery from anaesthesia and if reflux persists, re-injection can be performed immediately. VCUG was performed at 6 months to evaluate efficacy of the treatment and at 12 months post-operatively to exclude occasionally appearing secondary reflux. The 12 months VCUG control has now been omitted after the learning curve was completed, in order to reduce exposure to radiation. Antibiotic treatment to prevent infection after cystoscopy and injection was given for 10 days and thereafter followed by prophylaxis until VCUG proved the absence of reflux at the 6-month control.

In our study, UTI was observed in 27% after SCIN and 23% after Cohen reimplantation. In addition in 9% of patients treated with SCIN and in 4% with Cohen procedure we found a dysuria syndrome. Beetz et al. [23] who followed patients after open surgical reflux correction reported that during the first 10-years 28% of the patients presented with a febrile and 18% with an afebrile UTI. After SCIN, lower UTI, characterized by bacteriuria without fever, was more frequently observed (10 of 56 patients, ie. 18%) than after open surgery (8 of 74 patients ie. 11%). Multiple bacteriuria were predominantly seen in patients treated with SCIN. After Cohen reimplantation 9 of 74 patients (12%) had pyelonephritis potentially affecting renal function, compared to 5 of 56 patients (9%) in the SCIN group. A possible explanation for these findings lies in the fact, that the patients were not randomized as in a prospective study. Patients with high-grade reflux, decreased renal function or recurrent UTI despite antibiotic prophylaxis were selected for open surgery procedure as first preference. UTI after open surgery occurred in patients free of reflux whereas UTI after SCIN occurred in patients with recurrent reflux. It might well be that in the reflux-free

Cohen group infection was caused by relative urinary stasis or occurred in a previously damaged kidney.

We are convinced, that active reflux treatment has a place in terms of renal protection and in preservation or improvement of renal function. This is supported by the "The International Reflux Study in Children" [24], stating that the development of pyelonephritis is significantly less frequent in the anti-reflux surgery group than in the medical group during 10 years of follow-up.

In this study, we restricted the descriptive statistical analysis of the renal function to a subgroup of children presenting bilateral grade III reflux. This allowed comparison of patients in both groups with comparable grade of bilateral reflux showing a comparable renal development profile. We observed that the accumulation index (AI) increased in both groups following treatment. It is known that AI reflects renal maturation during the first year of life and that normal values in infants aged less than 6 months were lower than those obtained in older children. In our study, infants less than 1 year of age showed an increase of AI in both groups, probably reflecting renal maturation. In older infants, we did not find any difference between pre- and postoperative AI in the SCIN group. This could be explained by the fact that these kidneys had normal function at diagnosis when compared to those

treated with open surgery. In the Cohen group, the increase of AI of kidneys in children aged more than 1 year at surgery reflected true renal function improvement. In 9 children, AI remained unilaterally decreased at follow-up, in 4 of them the contralateral kidney developed AI over normal range, indicating compensation [25].

In conclusion, re-implantation surgery remains the golden standard for treatment of high-grade VUR. Recurrence and complications are rare. SCIN offers an alternative method of treatment for grade III-IV reflux and for lower degrees of contralateral reflux. It is less invasive, can be performed as day surgery and is therefore less costly. It can easily be repeated or converted to open surgery if necessary. Recurrent bacteriuria was observed more often after SCIN and pyelonephritis more often after open surgery. In patients with grade III reflux, the renal function seems to be preserved with both techniques.

Correspondence:

Prof Dr Peter Frey

Department of Paediatric Surgery

Centre Hospitalier Universitaire Vaudois

Rue du Bugnon 46

CH-1011 Lausanne

Switzerland

E-Mail: Peter.Frey@chuv.ch

References

- Riccabona M. Management of recurrent urinary tract infection and vesico-ureteral reflux in children. *Curr Opin Urol.* 2000; 10:25-8.
- Jakobsson SH, Hansson S, Jakobsson B. Vesico-ureteric reflux: occurrence and long-term risks. *Acta Paediatr Suppl.* 1999;431: 22-30.
- Jakobsson B, Jakobsson SH, Hjalmas K. Vesico-ureteric reflux and other risk factors for renal damage: identification of high and low risk children. *Acta Paediatr Suppl.* 1999;431:31-9.
- Bailey RR, Lynn KL, Smith AH. Long term follow up of infants with gross vesicoureteral reflux. *J Urol.* 1992;148:1709-11.
- Tamminen-Mobius T, Brunier E, Ebel KD. Cessation of vesicoureteral reflux for 5 years in infants and children allocated to medical treatment. The International Reflux Study in Children. *J Urol.* 1992;148:1662-6.
- Cohen SJ. The Cohen reimplantation technique. *Birth Defects Orig Artic Ser.* 1977;13:391-5.
- Politano VA, Leadbetter WF. An operative technique for the correction of vesico-ureteral reflux. *J Urol.* 1958;79:932-41.
- Gregoir W. Le traitement chirurgical du reflux vesico-urétéral congénital. *Acta Chir Belg.* 1964;63:431-9.
- Aragona F, D'Urso L, Scremin E. Polytetrafluorethylen giant granuloma and adenopathy: a long-term complications following subureteral polytetrafluorethylen injection for the treatment of vesicoureteral reflux in children. *J Urol.* 1997;158:1539-42.
- Aaronson I, Rames R, Greene W. Endoscopic treatment of reflux: migration of Teflon to the lungs and brain. *Eur Urol.* 1993; 23:394-9.
- Lipsky H, Wuenschimmel E. Endoscopic treatment of vesicoureteric reflux with collagen. Five years experience. *Br J Urol.* 1993;72:965-8.
- Läckgren G, Wahlin N, Stenberg A. Endoscopic treatment of children with vesico-ureteric reflux. *Acta Paediatr Suppl.* 1999;431: 62-71.
- Läckgren G, Wahlin N, Stenberg A. Long-term follow up of children treated with dextranomer/hyaluronic acid copolymer for vesicoureteral reflux. *J Urol.* 2001;166:1887-92.
- Frey P, Berger D, Jenny P, Herzog B. Subureteral collagen injection for the endoscopic treatment of vesicoureteral reflux in children. Follow up study of 97 treated ureters and histological analysis of collagen implants. *J Urol.* 1992;148:718-23.
- Lebowitz RL, Olbing H, Parkkulainen KV, Smellie JM, Tamminen-Mobius TE. International system of radiographic grading of vesicoureteral reflux. International Reflux Study in Children. *Pediatr Radiol.* 1985;15:105-9.
- Frey P, Lutz N, Jenny P, Herzog B. Endoscopic subureteral collagen injection for the treatment of vesicoureteral reflux in infants and children. *J Urol.* 1995;154:804-7.
- Produit S, Bischof Delaloye A, Genton N, Delaloye B. Evaluation of separate renal function with 123I-hippuran in children with reflux uropathy before and after surgery. *Contrib Nephrol.* 1987;56:243-9.
- Boubaker A, Prior J, Antonescu C, Meyrat B, Frey P, Bischof Delaloye A. F+0 renography in neonates and infants younger than 6 months: an accurate method to diagnose severe obstructive uropathy. *J Nucl Med.* 2001;42:1780-8.
- Capozza N, Patricolo M, Lais A, Matarazzo E, Caione P. Endoscopic treatment of vesico-ureteral reflux: twelve years' experience. *Urol Int.* 2001;67:228-31.
- De Grazia E, Cimador M. Long term follow up results of vesicoureteral reflux treated with subureteral collagen injection (SCIN). *Minerva Pediatr.* 2000;52:7-12.
- Läckgren G, Wahlin N, Sköldenberg E, Stenberg A. Long-term follow up of children treated with dextranomer/hyaluronic acid copolymer for vesicoureteral reflux. *J Urol.* 2001;166:1887-92.
- Haferkamp A, Moehring K, Staehler G, Dorsam. Pitfalls of repeat subureteral bovine collagen injections for the endoscopic treatment of vesicoureteral reflux. *J Urol.* 2000;163:1919-21.
- Beetz R, Mannhardt W, Fisch M, Stein R, Thuroff JW. Long-term follow up of 158 young adults surgically treated for vesicoureteral reflux in childhood: the ongoing risk of urinary tract infections. *J Urol.* 2002;168:704-7.
- Jodal U, Koskimies O, Hansson EJ, Lohr G, Olbing H, Smellie J, et al. Infection pattern in children with vesicoureteral reflux randomly allocated to operation or long-term antibacterial prophylaxis. *J Urol.* 1992;148:1650-2.
- Boubaker A, Prior JO, Meuwly JY, Bischof Delaloye A. Radionuclide investigations of the urinary tract in the era of multimodality imaging. *J Nucl Med.* 2006;47:1819-36.

Official journal of the Swiss Society of Infectious diseases, the Swiss Society of Internal Medicine and the Swiss Respiratory Society

The many reasons why you should choose SMW to publish your research

What Swiss Medical Weekly has to offer:

- SMW's impact factor has been steadily rising. The 2005 impact factor is 1.226.
- Open access to the publication via the Internet, therefore wide audience and impact
- Rapid listing in Medline
- LinkOut-button from PubMed with link to the full text website <http://www.smw.ch> (direct link from each SMW record in PubMed)
- No-nonsense submission – you submit a single copy of your manuscript by e-mail attachment
- Peer review based on a broad spectrum of international academic referees
- Assistance of our professional statistician for every article with statistical analyses
- Fast peer review, by e-mail exchange with the referees
- Prompt decisions based on weekly conferences of the Editorial Board
- Prompt notification on the status of your manuscript by e-mail
- Professional English copy editing
- No page charges and attractive colour offprints at no extra cost

Editorial Board

Prof. Jean-Michel Dayer, Geneva
Prof. Peter Gehr, Berne
Prof. André P. Perruchoud, Basel
Prof. Andreas Schaffner, Zurich
(Editor in chief)
Prof. Werner Straub, Berne
Prof. Ludwig von Segesser, Lausanne

International Advisory Committee

Prof. K. E. Juhani Airaksinen, Turku, Finland
Prof. Anthony Bayes de Luna, Barcelona, Spain
Prof. Hubert E. Blum, Freiburg, Germany
Prof. Walter E. Haefeli, Heidelberg, Germany
Prof. Nino Kuenzli, Los Angeles, USA
Prof. René Lutter, Amsterdam, The Netherlands
Prof. Claude Martin, Marseille, France
Prof. Josef Patsch, Innsbruck, Austria
Prof. Luigi Tavazzi, Pavia, Italy

We evaluate manuscripts of broad clinical interest from all specialities, including experimental medicine and clinical investigation.

We look forward to receiving your paper!

Guidelines for authors:

http://www.smw.ch/set_authors.html



All manuscripts should be sent in electronic form, to:

EMH Swiss Medical Publishers Ltd.
SMW Editorial Secretariat
Farnsburgerstrasse 8
CH-4132 Muttenz

Manuscripts: submission@smw.ch
Letters to the editor: letters@smw.ch
Editorial Board: red@smw.ch
Internet: <http://www.smw.ch>