

LETTERS

B. henselae antigens (Houston-1 and Marseille) compared with the 4 different *B. henselae* antigens used in the present study. Most reactivity to *B. henselae* in the present study was directed against the Swedish isolate K68 (27%); only 0.8% of controls had antibodies against that antigen.

An increased prevalence of antibodies against *B. henselae* after exposure to cats has been reported from Spain (10). Because seroconversion against *B. henselae* occurred in 2 patients who had not been scratched, cat bites may contribute to transmission of *B. henselae*.

Acknowledgments

We thank Mardjan Arvand and Eva Olsson-Engvall for providing antigens of *B. henselae* Berlin1 and *B. henselae* K68, respectively.

The study was supported by local funds from the Academic Hospital, Uppsala Community.

**Katarina Westling, Anna Farra,
Christina Jorup,
Åsa Nordenberg,
Bo Settergren,² and Eva Hjelm**

Author affiliations: Karolinska Institutet, Stockholm, Sweden (K. Westling, A. Farra, C. Jorup, B. Settergren); and University Hospital, Uppsala, Sweden (Å. Nordenberg, E. Hjelm)

DOI: 10.3201/eid1412.080002

References

1. Regnery RL, Olson JG, Perkins BA, Bibb W. Serological response to "*Rochalimaea henselae*" antigen in suspected cat-scratch disease. *Lancet*. 1992;339:1443–5. DOI: 10.1016/0140-6736(92)92032-B
2. Koehler JE. *Bartonella*-associated infections in HIV-infected patients. *AIDS Clin Care*. 1995;7:97–102.
3. Chomel BB, Boulouis HJ, Maruyama S, Breitschwerdt EB. *Bartonella* spp. in pets and effect on human health. *Emerg Infect Dis*. 2006;12:389–94.

²Current affiliation: Central Hospital, Kristianstad, Sweden.

4. Hjelm E, McGill S, Blomqvist G. Prevalence of antibodies to *Bartonella henselae*, *B. elizabethae*, and *B. quintana* in Swedish domestic cats. *Scand J Infect Dis*. 2002;34:192–6. DOI: 10.1080/00365540110080188
5. Engvall EO, Brandstrom B, Fermer C, Blomqvist G, Englund L. Prevalence of *Bartonella henselae* in young, healthy cats in Sweden. *Vet Rec*. 2003;152:366–9.
6. Jameson P, Greene C, Regnery R, Dryden M, Marks A, Brown J, et al. Prevalence of *Bartonella henselae* antibodies in pet cats throughout regions of North America. *J Infect Dis*. 1995;172:1145–9.
7. Chomel BB, Kasten RW, Henn JB, Mollia S. *Bartonella* infection in domestic cats and wild felids. *Ann N Y Acad Sci*. 2006;1078:410–5. DOI: 10.1196/annals.1374.080
8. Westling K, Farra A, Cars B, Ekblom AG, Sandstedt K, Settergren B, et al. Cat bite wound infections: a prospective clinical and microbiological study at three emergency wards in Stockholm, Sweden. *J Infect Dis*. 2006;53:403–7. DOI: 10.1016/j.jinf.2006.01.001
9. McGill S, Wesslen L, Hjelm E, Holmberg M, Auvinen MK, Berggren K, et al. *Bartonella* spp. seroprevalence in healthy Swedish blood donors. *Scand J Infect Dis*. 2005;37:723–30. DOI: 10.1080/00365540510012152
10. Blanco Ramos JR, Oteo Revuelta JA, Martinez de Artola V, Ramalle Gomara E, Garcia Pineda A, Ibarra Cucalon V. Seroepidemiology of *Bartonella henselae* infection in a risk group [in Spanish]. *Rev Clin Esp*. 1998;198:805–9.

Address for correspondence: Katarina Westling, Division of Infectious Diseases, Department of Medicine, Karolinska University Hospital/Huddinge I 73, SE 141 86 Stockholm, Sweden; email: katarina.westling@ki.se

Letters

Letters commenting on recent articles as well as letters reporting cases, outbreaks, or original research are welcome. Letters commenting on articles should contain no more than 300 words and 5 references; they are more likely to be published if submitted within 4 weeks of the original article's publication. Letters reporting cases, outbreaks, or original research should contain no more than 800 words and 10 references. They may have 1 Figure or Table and should not be divided into sections. All letters should contain material not previously published and include a word count.

Fatal Case of Israeli Spotted Fever after Mediterranean Cruise

To the Editor: Israeli spotted fever (ISF) is caused by *Rickettsia conorii* subsp. *israelensis*. This recently described subspecies is genetically close to *R. conorii* subsp. *conorii*, the agent of Mediterranean spotted fever (MSF) (1,2). ISF is likely transmitted by the dog tick *Rhipicephalus sanguineus* (3). This tick, which is also the vector of *R. conorii* subsp. *conorii*, has low affinity for hosts other than dogs. Therefore, like MSF, cases of ISF will likely be sporadic (4,5). ISF was first reported in Israel (1) and was also recently described in Portugal and Italy (6–8). The clinical manifestations of ISF are similar to those of other spotted fever group infections, but an inoculation eschar is rarely observed and a history of tick exposure is not always present (4–6,9). The incubation period is ≈7–8 days after the tick bite (4).

We describe a 63-year-old man who had fatal ISF despite adequate therapy. The patient, who lived in Switzerland, took a cruise on the Mediterranean Sea, sailing for a week along the coasts of Crete, Libya, and Malta (Figure). With his wife, he visited several archeological sites in Libya (Cyrene, Apollonia, Ptolemais, Leptis Magna, Sabratha). Three days after returning to Switzerland, the patient reported loss of appetite, epigastric pain, and loose stools. Four days later, a fever (40°C) and generalized rash developed. The patient was hospitalized 6 days after symptom onset. At that time, he had fever (38.3°C), hypotension (85/55 mm Hg), tachycardia (100/min); a maculopapular rash involving the trunk, limbs, palms, and soles; and petechial lesions on the right arm. The patient was confused and exhibited bilateral dysidiadochokinesis. Laboratory investigations yielded the following

results: C-reactive protein level 183 mg/L; leukocyte count $4.9 \times 10^9/L$; platelet count $23 \times 10^9/L$; creatinine 741 $\mu\text{mol/L}$; sodium 127 mmol/L; aspartate aminotransferase 299 U/L; alanine aminotransferase 156 U/L; γ -glutamyl transpeptidase 160 U/L; pH 7.45; and lactate 4.5 mmol/L. A rapid blood test for malaria (OptiMAL-IT, DiaMed, Cressier, Switzerland) had negative results, and peripheral blood smears did not show any *Plasmodium* spp. During his trip, the patient had not had contact with animals and had no history of tick bite. His wife was asymptomatic.

The initial differential diagnosis mainly included typhoid fever, leptospirosis, malaria, HIV seroconversion, and MSF. Treatment with intravenous doxycycline, 100 mg twice a day, and ceftriaxone, 2 g every 24 h, was immediately started. The patient was admitted to the intensive care unit because of hypotension and received vasopressors. Twenty-four hours later, renal function deteriorated, and the patient was transferred to our university hospital in Lausanne, Switzerland,

for hemodialysis. Antimicrobial drug treatment was switched to intravenous imipenem, 500 mg 4 times a day, and clarithromycin, 500 mg twice a day. On day 8 after symptom onset, he had pulseless electrical heart activity probably caused by metabolic acidosis. He died on day 11 after symptom onset.

Blood was sterile but was not cultured for rickettsiae, and stool culture showed no pathogens. Using serum obtained on day 6, we conducted a *Rickettsia* spp. microimmunofluorescence test; results were negative. However, results of a skin biopsy, conducted after 2 days of antibiotherapy, were positive by 2 PCRs targeting the *ompA* and *gltA* genes (10). Sequencing allowed postmortem identification of the etiologic agent as *R. conorii* subsp. *israelensis*. The sequences of *ompA* exhibited 99.8% (532/533 bp) similarity with *R. conorii* subsp. *israelensis* strain ISTT-CDC1^T (GenBank accession no. U43797), 98.3% (524/533 bp) with *R. conorii* subsp. *caspia* strain A-167^T (U43791) and 96.8%

(540/558 bp) with *R. conorii* subsp. *conorii* strain Malish^T (AE008674). The sequences of *gltA* exhibited 100% (177/177 bp) similarity with *R. conorii* subsp. *israelensis* (U59727), 99.4% (176/177 bp) with *R. conorii* subsp. *caspia* (U59728), and 98.3% (174/177 bp) with *R. conorii* subsp. *conorii* (AE008677).

Autopsy showed severe pulmonary edema and liver ischemia. The brain had petechial hemorrhages in the left cerebellum and right frontal lobe, as well as a small recent ischemic infarction in the right caudate nucleus.

In this case of ISF, delayed medical consultation and thus late initiation of antimicrobial drug therapy (6 days after symptoms onset), the patient's age, and his chronic alcohol abuse probably contributed to the fatal course. The virulence of *R. conorii* subsp. *israelensis* might also be higher than that of *R. conorii* subsp. *conorii* (6,7).

ISF has not been described in any of the countries visited by the patient. Given the incubation time of spotted fever (7–8 days), he was probably infected in Libya, where he spent days 6–10 before symptom onset. Geographic distribution of ISF can thus be extended to North Africa. Since ISF and MSF share the same vector (*Rh. sanguineus*), disease-endemic areas probably overlap.

This report also points out the importance of early empirical treatment. Rickettsiosis should be suspected in febrile travelers, especially when they have a rash, even in the absence of history of tick exposure and inoculation eschar. Counseling before travel to areas endemic for spotted fever rickettsioses should include preventive measures for tick bites and recommendations to immediately seek medical advice in case of fever.

Acknowledgments

We thank Marie-Denise Schaller and André Zwahlen, who were involved in patient management; and Serge de Valliere and Philip Tarr for their critical review of

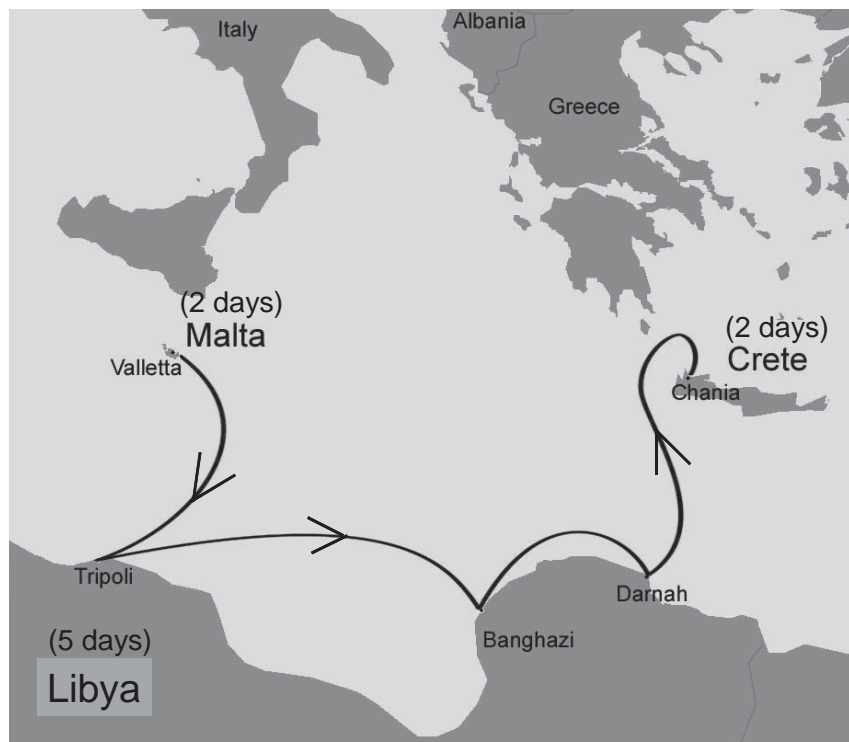


Figure. Cruise path on the Mediterranean Sea along the coasts of Crete, Libya, and Malta.

the manuscript. Written consent for publication was obtained from the patient's wife.

Noémie Boillat, Blaise Genton, Valérie D'Acremont, Didier Raoult, and Gilbert Greub
 Author affiliations: University Hospital of Lausanne, Lausanne, Switzerland (N. Boillat, B. Genton, V. D'Acremont, G. Greub); and Mediterranean University, Marseilles, France (D. Raoult)

DOI: 10.3201/eid1412.070641

References

- Zhu Y, Fournier PE, Ereemeeva M, Raoult D. Proposal to create subspecies of *Rickettsia conorii* based on multi-locus sequence typing and an emended description of *Rickettsia conorii*. BMC Microbiol. 2005;5:11.
- Fournier PE, Dumler JS, Greub G, Zhang J, Wu Y, Raoult D. Gene sequence-based criteria for identification of new *Rickettsia* isolates and description of *Rickettsia heilongjiangensis* sp. nov. J Clin Microbiol. 2003;41:5456–65.
- Giammanco GM, Mansueto S, Ammatuna P, Vitale G. Israeli spotted fever *Rickettsia* in Sicilian *Rhipicephalus sanguineus* ticks. Emerg Infect Dis. 2003;9:892–3.
- Gross EM, Yagupsky P. Israeli spotted fever in children. A review of 54 cases. Acta Trop. 1987;44:91–6.
- Wolach B, Franco S, Bogger-Goren S, Drucker M, Goldwasser RA, Sadan N, et al. Clinical and laboratory findings of spotted fever in Israeli children. Pediatr Infect Dis. 1989;8:152–5.
- Bacellar F, Beati L, França A, Poças J, Regnery R, Filipe A. Israeli spotted fever rickettsia (*Rickettsia conorii* complex) associated with human disease in Portugal. Emerg Infect Dis. 1999;5:835–6.
- Giammanco GM, Vitale G, Mansueto S, Capra G, Caleca MP, Ammatuna P. Presence of *Rickettsia conorii* subsp. *israelensis*, the causative agent of Israeli spotted fever, in Sicily, Italy, ascertained in a retrospective study. J Clin Microbiol. 2005;43:6027–31.
- De Sousa R, Ismail N, Doria-Nobrega S, Costa P, Abreu T, França A, et al. The presence of eschars, but not greater severity, in Portuguese patients infected with Israeli spotted fever. Ann N Y Acad Sci. 2005;1063:197–202.
- Yagupsky P, Wolach B. Fatal Israeli spotted fever in children. Clin Infect Dis. 1993;17:850–3.
- Fournier PE, Raoult D. Suicide PCR on skin biopsy specimens for diagnosis of rickettsioses. J Clin Microbiol. 2004;42:3428–34.

Address for correspondence: Gilbert Greub, Institute of Microbiology and Service of Infectious Diseases, University Hospital Center and University of Lausanne, Bugnon, 46 Lausanne 1011, Switzerland; email: gilbert.greub@chuv.ch

***Streptococcus suis* Meningitis without History of Animal Contact, Italy**

To the Editor: *Streptococcus suis*, a major swine pathogen worldwide, is emerging as a zoonotic agent capable of causing a variety of serious infections in swine as well as in persons exposed to pigs or to pork products. These infections include meningitis, septicemia, pneumonia, endocarditis, arthritis, and septic shock (1,2). Despite recent outbreaks among persons in China, *S. suis* disease in humans is a rare, probably underdiagnosed infection that usually occurs as sporadic cases (1,2). Persons in close occupational or accidental contact with pigs or pork products and those who eat uncooked or undercooked pork may be at higher risk than others. However, most infected persons are likely healthy carriers, and *S. suis* is believed to induce overt disease (especially meningitis) in only some circumstances (2). We describe a case of *S. suis* meningitis in a 68-year-old man from Sardinia, Italy, who had no reported contact with swine, other animals, or any animal products; the patient also had cancer, which was discovered incidentally during the workup.

In November 2007, the patient was hospitalized with a 48-hour his-

tory of fever, headache, nausea, and general malaise. Physical examination showed impaired consciousness, nuchal rigidity, and a temperature of 39.5°C. Laboratory findings were 20,700 leukocytes/mm³ with 92% neutrophils, glucose 95 mg/dL, and C-reactive protein 375 mg/L. Cerebrospinal fluid (CSF) analysis demonstrated 240 leukocytes/μL with 80% polymorphonuclear cells, glucose 24 mg/dL, and protein 277 mg/dL. A computed tomography scan of the head showed no abnormal findings. Gram stain of CSF showed gram-positive cocci, mostly in pairs (Figure).

Empirical therapy consisted of intravenous ceftriaxone (2 g twice a day) and oral chloramphenicol (2 g once a day). On day 5, α-hemolytic streptococci were isolated from CSF on sheep blood agar and identified as *S. suis* by using APIStrep (bioMérieux, Marcy l'Etoile, France). Serotyping, performed by slide agglutination with specific antiserum (Statens Serum Institute, Copenhagen, Denmark), identified the isolate as serotype 2.

Antimicrobial drug-susceptibility testing, performed according to guidelines of the Clinical and Laboratory Standards Institute (www.clsi.org), indicated susceptibility to penicillin, ceftriaxone, chloramphenicol, levofloxacin, and vancomycin and resistance to erythromycin (MIC >128 mg/L) and tetracycline (MIC 16 mg/L). Erythromycin resistance was constitutive and was mediated by the *erm*(B) determinant; tetracycline resistance was mediated by *tet*(W). Multilocus sequence typing (<http://ssuis.mlst.net>) assigned the *S. suis* isolate to sequence type (ST) 1.

The patient, a retired welder, denied any recent occupational or even occasional contact with swine or other animals and had no history of eating raw or undercooked pork. The patient's condition improved; chloramphenicol was discontinued on day 10, but the 14-day course of ceftriaxone was completed. On day 6, the patient