
UNIVERSITE DE LAUSANNE – FACULTE DE BIOLOGIE ET DE MEDECINE

DEPARTEMENT MEDICO-CHIRURGICAL DE PEDIATRIE – DIVISION DE PEDIATRIE
MOLECULAIRE

**Congenital disorder of glycosylation type Id (CDGId) : phenotypic,
biochemical, and molecular characterization of a new patient**

THESE

préparée sous la direction du Docteur Luisa Bonafé, Privat-Docent et
Maître d'Enseignement et de Recherche

et présentée à la Faculté de biologie et de médecine de l'Université de
Lausanne pour l'obtention du grade de

DOCTEUR EN MEDECINE

QU

55.5

RIM

Par

BHTE 3582

Aude RIMELLA-LE-HUU

Médecin diplômée de la Confédération Suisse

Originaire de Vevey (VD) et Sonviliers (BE)

Lausanne 2009

Bibliothèque Universitaire
de Médecine / BIUM
CHUV-BH08 - Bugnon 46
CH-1011 Lausanne

1

R 005681 970

Imprimatur

Vu le rapport présenté par le jury d'examen, composé de

Directeur de thèse Madame le Docteur Luisa Bonafe

Co-Directeur de thèse

Expert

Directrice de l'Ecole doctorale Madame le Professeur Stephanie Clarke

la Commission MD de l'Ecole doctorale autorise l'impression de la thèse de

Madame Aude Rimella-Le-Huu

intitulée

*Congenital disorder of glycosylation type Id (CDG Id):
phenotypic, biochemical, and molecular characterization of a
new patient*

Lausanne, le 7 juillet 2009

*pour Le Doyen
de la Faculté de Biologie et de Médecine*



*Madame le Professeur Stephanie Clarke
Directrice de l'Ecole doctorale*

Rapport de synthèse

Les troubles de la glycosylation (Congenital Disorders of Glycosylation, CDG) regroupent une famille de maladies multi-systémiques héréditaires causées par des défauts dans la synthèse de glycoconjugués. La glycosylation est une réaction enzymatique consistant à lier de façon covalente un glucide à une chaîne peptidique ou une protéine. Il existe deux types de glycosylation. La N-glycosylation est l'addition de glucides aux chaînes peptidiques en croissance dès leur entrée dans la lumière du réticulum endoplasmique. Elle s'effectue sur les futures glycoprotéines membranaires et conduit à des chaînes de sucres courtes et ramifiées. La O-glycosylation est l'addition de glucides au niveau des résidus hydroxylés des acides aminés sérine et thréonine des chaînes peptidiques déjà présentes dans la lumière de l'appareil de Golgi. Elle est, dans la plupart des cas, effectuée sur les protéoglycannes et conduit à des chaînes de sucres longues et non ramifiées. La classification des CDG repose sur le niveau de l'étape limitante de la glycosylation. Les CDG de type 1, plus fréquents, regroupent les déficits enzymatiques se situant en amont du transfert de l'oligosaccharide sur la chaîne peptidique. Les CDG de type 2 regroupent ceux ayant lieu en aval de ce transfert. Parmi les nombreux différents sous-types de CDG, le CDG de type 1d est causé par une anomalie de la mannosyltransferase, enzyme codée par le gène *ALG3* (chromosome 3q27). Jusqu'à ce jour, six patients atteints de CDG 1d ont été reportés dans la littérature. Notre travail a permis de décrire un septième patient et d'affiner les caractéristiques cliniques, biologiques, neuroradiologiques et moléculaires du CDG 1d. Notre patient est notamment porteur d'une nouvelle mutation de type missense sur le gène *ALG3*. Tous les patients atteints de CDG 1d présentent une encéphalopathie progressive avec microcéphalie, retard psychomoteur sévère et épilepsie. Une ostéopénie marquée est présente chez certains patients. Elle est parfois sous diagnostiquée et révélée uniquement lors de fracture pathologique. Les patients atteints de CDG 1d présentent également des traits dysmorphiques typiques, mais aucune atteinte multi-systémique ou anomalie biologique spécifique n'est retrouvée telle que dans les autres types de CDG. Le dépistage biochimique des troubles de la glycosylation se fait par une analyse simple et peu coûteuse qui est l'analyse de la transferrine sérique par isoelectrofocusing ou par électrophorèse capillaire. Un tel dépistage devrait être effectué chez tout patient présentant une encéphalopathie d'origine indéterminée, et cela même en l'absence d'atteinte multi-systémique. Notre travail a été publié sous forme d'article de type « short report », peer-reviewed, dans le Journal of Inherited Metabolic Diseases. Le Journal est une revue spécialisée du domaine des erreurs innées du métabolisme. S'agissant d'un seul patient rapporté, l'article ne montre que très synthétiquement le travail effectué, Pour cette raison un complément à l'article avec matériel, méthodes et résultats figure ci-après et concerne la partie de recherche moléculaire de notre travail. La doctorante a non seulement encadré personnellement le patient au niveau clinique et biochimique, mais a plus particulièrement mis au point l'analyse moléculaire du gène *ALG3* dans le laboratoire de Pédiatrie Moléculaire pour la première fois ; cela a impliqué l'étude du gène, le choix des oligonucleotides et l'optimisation des réactions d'amplification et séquençage.

Congenital disorder of glycosylation type Id (CDG Id): phenotypic, biochemical and molecular characterization of a new patient

A. Rimella-Le-Huu · H. Henry · I. Kern ·
S. Hanquinet · E. Roulet-Perez · C. J. Newman ·
A. Superti-Furga · L. Bonafé · D. Ballhausen

Received: 20 May 2008 / Submitted in revised form: 20 June 2008 / Accepted: 24 June 2008 / Published online: 9 August 2008
© SSIEM and Springer 2008

Summary Congenital disorders of glycosylation (CDG) are a family of multisystem inherited disorders caused by defects in the biosynthesis of *N*- or *O*-glycans. Among the many different subtypes of CDG, the defect of a mannosyltransferase encoded by the human *ALG3* gene (chromosome 3q27) is known to cause CDG Id. Six patients with CDG Id have been described in the literature so far. We further delineate the clinical, biochemical, neuroradiological and molecular features of CDG Id by reporting an additional patient bearing a novel missense mutation in the *ALG3* gene. All patients with CDG Id display a slowly progressive encephalopathy

with microcephaly, severe psychomotor retardation and epileptic seizures. They also share some typical dysmorphic features but they do not present the multisystem involvement observed in other CDG syndromes or any biological marker abnormalities. Unusually marked osteopenia is a feature in some patients and may remain undiagnosed until revealed by pathological fractures. Serum transferrin screening for CDG should be extended to all patients with encephalopathy of unknown origin, even in the absence of multisystem involvement.

Abbreviations

CDG congenital disorders of glycosylation
EEG electroencephalogram
LLO lipid-linked oligosaccharide
MRI magnetic resonance imaging

Communicating editor: Jaak Jaeken

Competing interests: None declared

References to electronic databases: CDG type Id: OMIM #601110.

A. Rimella-Le-Huu · L. Bonafé · D. Ballhausen
Division of Molecular Pediatrics,
University Hospital of Lausanne,
Lausanne, Switzerland

H. Henry
Central Clinical Chemistry Laboratory,
University Hospital of Lausanne,
Lausanne, Switzerland

I. Kern
Child Metabolic Unit, University Hospital of Geneva,
Geneva, Switzerland

S. Hanquinet
Child Radiology Unit, University Hospital of Geneva,
Geneva, Switzerland

E. Roulet-Perez · C. J. Newman
Child Neurology Unit,
University Hospital of Lausanne,
Lausanne, Switzerland

A. Superti-Furga
Centre for Pediatrics and Adolescent Medicine,
Freiburg University Hospital,
Freiburg, Germany

D. Ballhausen (✉)
Division de Pédiatrie Moléculaire, CHUV,
CI 02-35, Av. P. Decker 2,
1011 Lausanne, Switzerland
e-mail: diana.ballhausen@chuv.ch

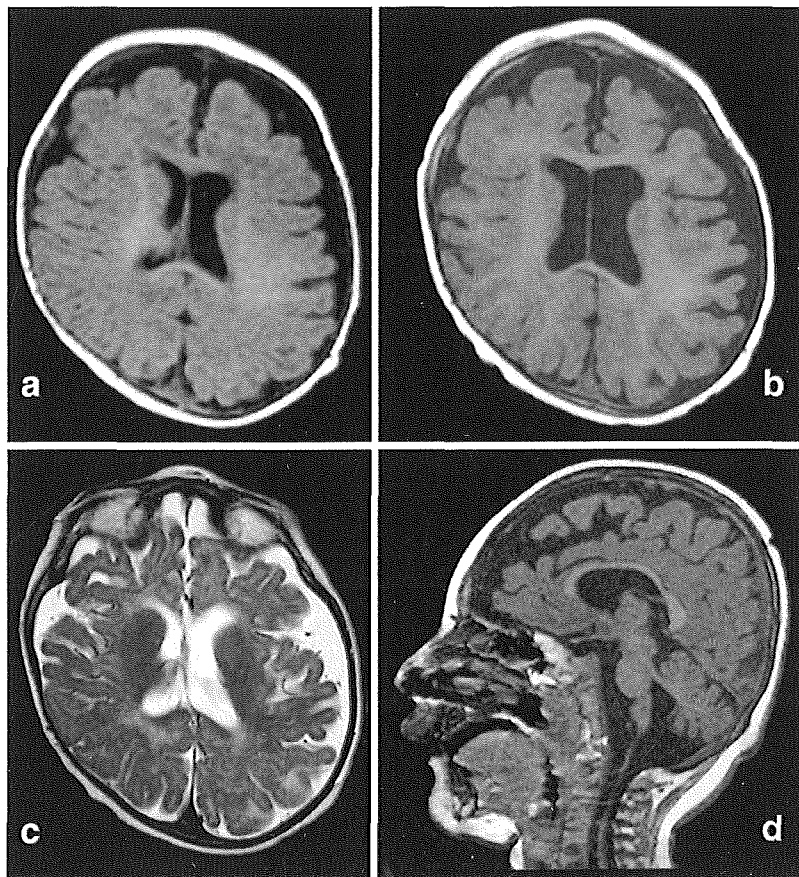
Introduction

Congenital disorders of glycosylation (CDG) are a family of heterogeneous multisystem inherited disorders caused by defects in the biosynthesis of glycoconjugates, affecting N- or O-glycosylation. N-Glycosylation of proteins starts in the endoplasmic reticulum, where different enzymes synthesize oligosaccharide chains linked to a membrane-bound lipid support (dolichol); these chains are then transferred to proteins. The process continues in the Golgi apparatus, where protein-bound glycans undergo remodelling and processing with addition and/or excision of individual sugars. Defects that alter the stepwise assembly of the lipid-linked oligosaccharide (LLO: Glc3Man9GlcNAc2) or its transfer to proteins within the endoplasmic reticulum are called CDG type I. In this group of defects, proteins lack entire sugar chains (glycans); this results in changes in protein folding, stability and turnover. Defects in the remodelling of protein-bound glycans in the Golgi are called CDG type II (Marquardt and Denecke 2003). Both isoelectric focusing and capillary electrophoresis of serum transferrin are sensitive screening methods to detect the two

patterns of CDG glycosylation anomaly, pointing to a defect in one of the two parts of the pathway. Today, at least 16 different subtypes of N-glycosylation defects are known (Marquardt and Denecke 2003; Jaeken and Matthijs 2007; Grünwald 2007; Vodopiutz and Bodamer 2008). Although the clinical diversity of CDG is remarkable, even within each group, most subtypes are characterized by a multisystem involvement with abnormalities in several biological markers.

Mutations in the human *ALG3* gene (chromosome 3q27), coding for the first dol-P-Man-dependent mannosyltransferase, were recognized as the molecular defect causing CDG type Id (OMIM #601110) (Körner et al 1999) in the first index patient described by Stibler (Stibler et al 1995). The resulting defect leads to accumulation of the LLO intermediate dol-PP-GlcNAc2Man5. N-Glycosylation is abnormal owing to the transfer of truncated LLOs and to the incomplete utilization of N-glycosylation sites. Six patients with CDG Id (formerly named CDG type IV) have been reported so far (Denecke et al 2004, 2005; Körner et al 1999; Kranz et al 2007; Schollen et al 2005; Sun et al 2005). Constant clinical features are severe epilepsy, microcephaly, visual

Fig. 1 Brain MRI of the patient at age 4 months (a) and 15 months (b, c and d). (a) Enlargement of subarachnoid spaces and plagiocephalic deformation of the skull in an axial T1-weighted image; (b) cortical atrophy with no abnormal gyration in an axial T1-weighted image; (c) white-matter atrophy in an axial T2-weighted image; (d) atrophy of the brainstem and vermis and thin corpus callosum in a sagittal T1-weighted image



impairment due to optic atrophy, and severely delayed psychomotor development.

We report a seventh patient with molecularly confirmed CDG Id in order to further delineate the clinical, biochemical and radiological features of this disease.

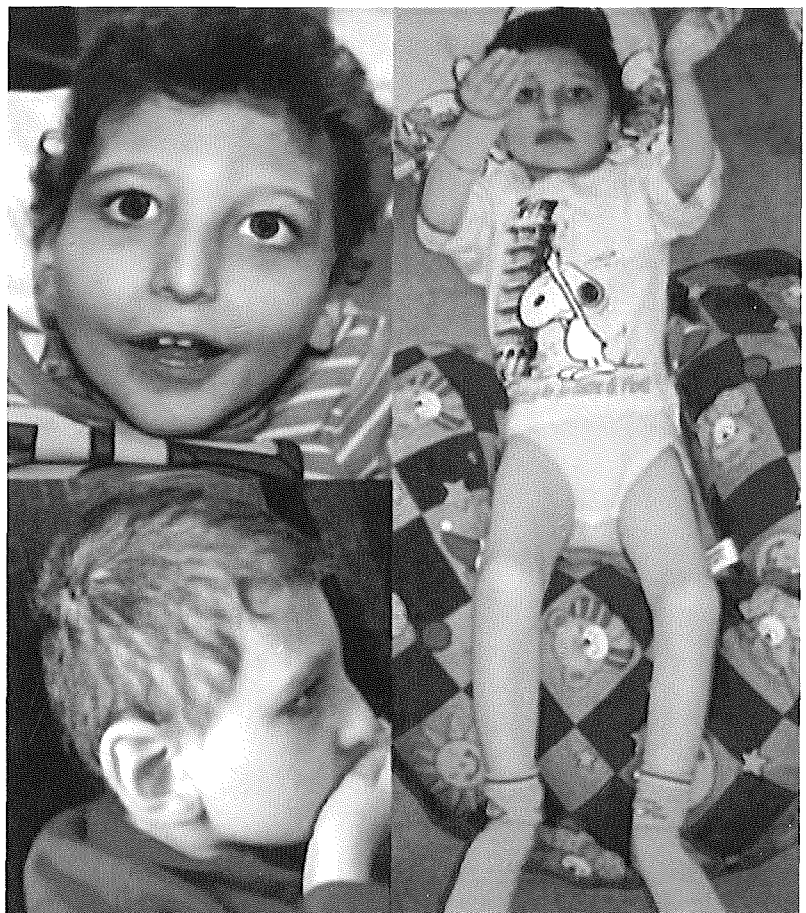Case report

Our patient is the third child of healthy non-consanguineous parents of Swiss and Italian origin. The family history is unremarkable. Pregnancy and delivery were uneventful. He was born at term with a weight of 3790g (>90th centile), a length of 50 cm (50th–90th centile) and a head circumference of 34 cm (50th centile). The neonatal period was uneventful. Epileptic seizures with hypotonia, tonic-clonic movements of the limbs, and eye revulsion started at 4 months and responded initially to benzodiazepines and phenobarbital. The child presented several dysmorphic features such as microcephaly, triangular face with retrognathism, hypertelorism, large low-implanted

ears, widened nasal bridge, adducted thumbs and long, thin fingers. There was bilateral cryptorchidism. He did not present inverted nipples, abnormal subcutaneous fat tissue distribution, heart anomalies or hepatic dysfunction as seen in other patients with CDG syndromes. Brain MRI performed at 4 months revealed enlarged subarachnoid spaces and cranial asymmetry (Fig. 1a). Spectroscopy revealed a discrete lactate elevation within the white matter in the frontal area. The EEG showed very frequent discharges (every 30s) from bi-occipital and bi-temporal focuses, corresponding to clinical episodes of gaze deviations upwards and towards the left, followed by rotatory eye movements and closure. These episodes lasted 6–7s, frequently accompanied by respiratory pauses. Clinical seizures and EEG improved under valproate treatment.

At 15 months the patient showed severe growth and psychomotor retardation. Epilepsy was reasonably controlled by valproate, with some rare epileptic seizures triggered by fever. Neurological examination showed severe axial hypotonia and spastic tetraparesis. He was unable to sit, to hold his head, and to open his hands, which were permanently fistled. He could hold

Fig. 2 Phenotypic features of the patient at age 5 years: microcephaly, large and low-set ears, broad and flat nasal bridge, thin upper lip, triangular mouth, long and thin fingers, adducted thumbs



objects and bring them to his mouth, but he could not transfer them from one hand to the other. Visual contact was poor and developmental age was estimated at a level of 4 months. The clinical course was marked by repetitive ear and pulmonary infections as well as gastro-oesophageal reflux. Brain MRI at 15 months of age (Fig. 1b, c, d) showed diffuse cortico-subcortical atrophy, progression of white-matter atrophy and mild atrophy of the vermis. Ophthalmological examination showed a latent nystagmus triggered by occlusion; funduscopy revealed hypopigmentation of the retina and optic atrophy. Abdominal ultrasound was normal, except for left pyelo-caliceal dilatation without reflux. No heart anomaly was found on echocardiography.

Metabolic investigations (amino acids, urinary organic acids, ammonia, lactate, blood pH, very long-chain fatty acids) were normal. Capillary electrophoresis analysis of serum transferrin showed a type 1 pattern with increased asialo- and disialotransferrin and presence of tetrasialotransferrin. CDG type Ia and Ib were excluded by enzymatic analysis in leukocytes.

Biochemical analysis of dolichol-oligosaccharides and protein-linked oligosaccharides in fibroblasts revealed accumulation of truncated Man5-GlcNAc2 oligosaccharide in addition to the mature Glc3Man9GlcNAc2 oligosaccharide; this feature is typical of CDG type Id.

Mutation analysis of the *ALG3* gene in both the cDNA and genomic DNA showed two compound heterozygous mutations, one in exon 1 [c.116C>T, p.P39L] and the other in exon 4 [c.512G>A, p.R171Q]. Sequencing of exons 1 and 4 of the *ALG3* gene in both parents confirmed segregation (maternal mutation p.P39L, paternal mutation p.R171Q). The two nucleotide changes found in our patient were not present in 100 chromosomes of anonymous unrelated European controls.

The patient is at present 5 years old, his weight follows the 3rd centile, his length follows the 25th centile and his head circumference is far below the 3rd centile (44 cm). His dysmorphic features are shown in Fig. 2. He is fed a diversified blended oral diet, with increasing difficulties due to his gastro-oesophageal

Table 1 Clinical and biochemical findings in our patient and all other CDG Id patients described so far (modified from Kranz et al 2007)

Source	This article	Kranz et al (2007)	Kranz et al (2007)	Sun et al (2005)	Schollen et al (2005)	J. Denecke, personal communication	Stibler et al (1995) Körner et al (1999)
Sex	M	F	M	F	F	M	M
Dysmorphic features							
Strabismus	++	++	+	n.k.	n.k.	+	n.k.
Facial dysmorphisms	+	+	+	++	+	+	+
Inverted nipples	-	+	+	+	n.k.	n.k.	-
Subcutaneous fat pads	-	-	-	+	n.k.	n.k.	-
Limb abnormalities	-	-	-	+	+	+	-
Neurological features							
Hypo-/hypertonia	++	+	++	+	+	+	+
Seizures	++	++	++	-	++	+	+
Visual Impairment	++	+	++	+	+	+	+
Cerebellar/cerebral hypoplasia	+	+	++	+	+	+	+
Psychomotor retardation	++	+	++	n.k. died too young	+	+	+
Liver/intestine/endocrine							
Hepatic fibrosis/cirrhosis	-	-	-	+	n.k.	-	n.k.
Hypoalbuminemia	-	++	++	+	n.k.	-	n.k.
Coagulopathy	-	+	-	+	n.k.	-	n.k.
Protein-losing enteropathy	-	-	-	n.k.	n.k.	-	n.k.
Hyperinsulinaemic hypoglycaemia	-	-	-	+	n.k.	-	n.k.
Food Intolerance	-	++	+	n.k.	n.k.	n.k.	n.k.
Skeletal manifestations							
Osteopenia/pathological fracture	+	-	+	n.k.	n.k.	n.k.	n.k.

++, very severe; +, symptom present; -, symptom absent; n.k., not known.

reflux. He attends a special needs school and is prescribed weekly physiotherapy, occupational therapy as well as assistive devices to improve muscle tone and comfort. Axial hypotonia remains very severe, with development of kyphoscoliosis. His movement pattern is abnormal, with continuous involuntary movements of the head and the upper limbs. Visual fixation is disturbed by the continuous head movement and, although the child seems to recognize familiar faces, there is no real visual contact. Communication is limited to undifferentiated vocalization with a better response to auditory than to visual stimulation. A pathological fracture of the right humerus recently occurred during the transfer between two caretakers. Radiological examination revealed severe osteopenia without specific bone changes; no shortened long bones or hypoplastic vertebral bodies and ribs were noted as reported in other CDG syndromes. Bone density measured on the lumbar spine showed a Z-score of -3.9 SD. Several biochemical parameters of multisystem functions were normal at follow-up from 15 months to 5 years, including liver function tests (transaminases, coagulation tests, plasma albumin), glomerular and tubular renal function tests (plasma urea and creatinine, tubular reabsorption of glucose, electrolytes and amino acids), muscle enzymes (creatine kinase), nutritional parameters, thyroid hormones, insulin/glucose ratios, calcium-phosphate metabolism and parathyroid hormone.

Discussion

On the basis of the clinical features of our patient and of the published data of the six known patients with CDG Id, some features of the syndrome seem to be common (Table 1). Microcephaly due to cerebral atrophy is mainly present at birth (Kranz et al 2007; Schollen et al 2005; Sun et al 2005) or develops in the first months of life as in the present patient (Denecke et al 2004, 2005; Körner et al 1999; Stibler et al 1995) and becomes progressively more evident in comparison with other growth parameters. An early-onset seizure disorder, often poorly controlled by antiepileptic medication, is present in nearly all patients (Denecke et al 2004, 2005; Körner et al 1999; Kranz et al 2007; Schollen et al 2005). Psychomotor retardation is usually severe with very little progress. Only in one of the siblings described by Kranz and coauthors did psychomotor development appear to be relatively preserved, with predominant digestive symptoms (Kranz et al 2007). There is usually profound axial hypotonia and limb spasticity. Eye and vision involvement is present in all

patients (Denecke et al 2004, 2005; Körner et al 1999; Kranz et al 2007; Stibler et al 1995; Schollen et al 2005; Sun et al 2005), often characterized by optic atrophy or strabismus. Club feet and contractures of digits are frequently seen at birth (Denecke et al 2005; Schollen et al 2005; Sun et al 2005). Dysmorphic features are usually mild at birth, but seem to become quite characteristic with time: the facial appearance and especially the profile with a broad and flat nasal bridge, micrognathia, thin upper lip, triangular mouth, down-slanting palpebral fissures, strabismus, and thickened, large, low-implanted ears are very similar in our patient and in the other photographically documented patients (Denecke et al 2005; Kranz et al 2007; Schollen et al 2005; Sun et al 2005); long and thin fingers seem to be typical (Kranz et al 2007; Sun et al 2005). Gastrointestinal symptoms such as recurrent vomiting (Denecke et al 2004, 2005), diarrhoea and food intolerance (Kranz et al 2007) are described in some cases and our patient presented gastro-oesophageal reflux. Metabolic abnormalities were reported in only one patient (Sun et al 2005), who presented with hyperinsulinaemic hypoglycaemia. Hypoglycaemia may have occurred in other patients but was not documented; in our patient no hypoglycaemia was found and fasting insulin/glucose ratio was normal. Some aspects of the disease such as failure to thrive and orthopaedic complications may be considered secondary effects of the neurological handicap rather than primary phenotypic features. Osteopenia may be linked to pathological muscular tone and immobilization. However, pathological fractures have been described in another CDG Id patient (Kranz et al 2007) at an early age (5 years in our patient): this suggests that osteopenia may result from a primary disturbance of bone mineralization (Coman et al 2008).

In contrast to other CDG types, CDG Id presents less multi-organ involvement; the phenotype is mainly dysmorphic and neurological. The prognosis and lifespan of CDG Id patients is difficult to assess because of the small number of known cases and the lack of detailed long-term follow-up descriptions. The clinical course is slowly progressive without episodes of decompensation and/or acute deterioration and without multisystem involvement as in other inherited metabolic disorders. Infections do not seem to trigger disease progression. Prognostic considerations may be very similar to those in other syndromic, non-metabolic severe encephalopathies, with respiratory and/or digestive complications expected as in other severely hypotonic patients. More insights on organ-specific pathophysiological mechanisms of CDG Id are probably needed to distinguish between primary and secondary signs of the disease.

The patient described here is compound heterozygote for two missense mutations in the *ALG3* gene causing CDG Id. The first mutation, p.P39L, has not been described so far. The second mutation, p.R171Q, was found at the homozygous state in the severe case of Sun and coauthors (Sun et al 2005); this patient manifested prenatal clinical signs and died in the neonatal period. Multiple sequence alignment of the ALG3 protein in different species showed that both proline 39 and arginine 171 are conserved in human, dog, mouse, and *Drosophila* (data not shown). Conservation through species and absence in controls strongly support the pathogenic role of p.P39L. The two missense mutations found in our patient lead to altered N-glycosylation, as shown by the typical accumulation of truncated LLOs in our patient's fibroblasts. However, the presence of mature Glc3Man9GlcNAc2 oligosaccharides reflects a residual mannosyltransferase activity. This residual activity might be important for future development of therapy for CDG Id. Indeed, Denecke and coauthors pointed at the possible role of maternal or placental factors responsible for a partially compensated N-glycosylation in CDG Id during pregnancy (Denecke et al 2005). Whether these factors compensate N-glycosylation by enhancing the residual enzymatic activity or through other mechanisms (chaperones?) remains to be clarified.

ALG3 gene analysis allows prenatal diagnosis in families with CDG Id index cases. The analysis of LLO in chorion cells could also be a helpful tool as shown by Denecke and coauthors (Denecke et al 2005). Serum transferrin profile is a simple screening test for CDG syndromes. Although multisystem involvement is usually considered a prerequisite for CDG screening, recent reports mention the existence of organ-specific CDG syndromes (Jaeken and Matthijs 2007). The present report underlines that epileptic encephalopathy can be the only phenotypic manifestation of a CDG syndrome and suggests that transferrin screening should be extended to all patients presenting an encephalopathy of unknown origin.

Acknowledgements We thank T. Hennet from the Institute of Physiology, University of Zurich, Switzerland, and C. G. Frank and M. Aebi from the Institute of Microbiology, Swiss Federal Institute of Technology, Zurich, Switzerland, for performing the LLO analysis. We also thank B. Steinmann from the Laboratory

of Metabolism and Molecular Pediatrics, University Children's Hospital, Zurich, Switzerland, for the enzymatic analysis of phosphomannomutase 2 and mannose-phosphate isomerase in leukocytes.

References

- Coman D, Irving M, Kannu P, et al (2008) The skeletal manifestations of the congenital disorders of glycosylation. *Clin Genet* **73**: 507–515.
- Denecke J, Kranz C, Kemming D, et al (2004) An activated 5' cryptic splice site in the human *ALG3* gene generates a premature termination codon insensitive to nonsense-mediated mRNA decay in a new case of congenital disorder of glycosylation type Id (CDG-Id). *Hum Mutat* **23**(5): 477–486. doi:10.1002/humu.20026.
- Denecke J, Kranz C, von Kleist-Retzow JC, et al (2005) Congenital disorder of glycosylation type Id: clinical phenotype, molecular analysis, prenatal diagnosis, and glycosylation of fetal proteins. *Pediatr Res* **58**(2): 248–253. doi:10.1203/01.PDR.0000169963.94378.B6.
- Grünwald S (2007) Congenital disorders of glycosylation: rapidly enlarging group of (neuro)metabolic disorders. *Early Hum Dev* **83**: 825–830. doi:10.1016/j.earlhumdev.2007.09.016.
- Jaeken J, Matthijs G (2007) Congenital disorders of glycosylation: a rapidly expanding disease family. *Annu Rev Genom Hum Genet* **8**: 261–278. doi:10.1146/annurev.genom.8.080706.092327.
- Körner C, Knauer R, Stephani U, et al (1999) Carbohydrate deficient glycoprotein syndrome type IV: deficiency of dolichyl-P-Man:Man(5)GlcNAc(2)-PP-dolichyl mannosyltransferase. *Embo J* **18**(23): 6816–6822. doi:10.1093/emboj/18.23.6816.
- Kranz C, Sun L, Eklund EA, et al (2007) CDG-Id in two siblings with partially different phenotypes. *Am J Med Genet A* **143A**(13): 1414–1420. doi:10.1002/ajmg.a.31796.
- Marquardt T, Denecke J (2003) Congenital disorders of glycosylation: review of their molecular bases, clinical presentations and specific therapies. *Eur J Pediatr* **162**(6): 359–379.
- Stibler H, Stephani U, Kutsch U (1995) Carbohydrate-deficient glycoprotein syndrome—a fourth subtype. *Neuropediatrics* **26**(5): 235–237.
- Schollen E, Grünwald S, Keldermans L, et al (2005) CDG-Id caused by homozygosity for an *ALG3* mutation due to segmental maternal isodisomy UPD3(q21.3-qter). *Eur J Med Genet* **48**(2): 153–158. doi:10.1016/j.ejmg.2005.01.002.
- Sun L, Eklund EA, Chung WK, et al (2005) Congenital disorder of glycosylation Id presenting with hyperinsulinemic hypoglycemia and islet cell hyperplasia. *J Clin Endocrinol Metab* **90**(7): 4371–4375. doi:10.1210/jc.2005-0250.
- Vodopiuiz J, Bodamer OA (2008) Congenital disorders of glycosylation—a challenging group of IEMs. *J Inher Metab Dis* **31**(2):267–269. doi:10.1007/s10545-008-0849-2.

Materials and Methods

Capillary electrophoresis of serum transferrin

To be able to have a robust capillary zone electrophoresis method for separation of the isoforms, a buffer system (CEofix™ CDT, Analis, Belgium) was used based on the patented dynamic double coating of the capillary wall. The analysis was then totally automated by a capillary electrophoresis instrument technique described previously [1, 2].

Analysis of Lipid-linked and Protein-Linked Oligosaccharides in cultured skin fibroblasts

N-glycosylation is initiated on the cytoplasmic side of the ER membrane by transferring two GlcNAc residues to Dolichol-P using UDP-GlcNAc as GlcNAc donor. The product GlcNAc₂-P-P-Dol is extended by successive five different mannosyltransferases using GDP-mannose as the donor substrate. The oligosaccharide product Man₅GlcNAc₂ is translocated from the cytoplasmic side of the ER-membrane to the luminal side of the organelle. This translocation is catalyzed by a flippase (Figure 1). On the luminal side of ER, mannosyl- and glucosyltransferases elongate the Man₅GlcNAc₂ oligosaccharide to a Glc₃Man₉GlcNAc₂ oligosaccharide. The Glc₃Man₉GlcNAc₂ oligosaccharide is transferred to a selected asparagine residue of the nascent protein. The glycoprotein is transferred to the Golgi by vesicular transport, after removal of the glucose residues and one mannose. The alteration of the N-glycosylation pathway in CDG Id is caused by a defect in the assembly of the lipid-linked oligosaccharide (LLO) precursor that serves as a donor for the oligosaccharides transferred onto nascent glycoproteins. The defective enzyme is a Man₅GlcNAc₂-PP-dolichyl mannosyltransferase that normally adds mannose to Man₅GlcNAc₂-PP-Dol in the endoplasmic reticulum. This enzyme defect leads to a typical accumulation of truncated LLOs (Man₅GlcNAc₂) in the cells of CDG Id patient. To characterize this accumulation, we used fibroblasts derived from the patient and one control were cultured in standard medium (Dulbecco's modified Eagle Medium, DMEM) and labeled with ³H-mannose. Oligosaccharides released from dolichol were fractionated by high performance liquid chromatography (HPLC) technique described previously [3].

Molecular analysis of ALG3 gene

RNA was extracted from control's and patient's fibroblasts according the protocol of the RNeasy Mini Kit (Qiagen, Hilden, Germany).

The *ALG3* cDNA was amplified in three fragments by RT-PCR (One step RT-PCR, Qiagen) using cDNA specific primers shown in Table 1 Primers were designed on the GenBank mRNA sequence (accession number NM_005787.2) and custom synthesized by Microsynth (Balgach, Switzerland).

The amplified cDNA fragments were purified (Montage PCR, Millipore, USA) and then sequenced using fluorescence-labeled terminator reagents (Big Dye v.1.1, Applied Biosystems) and an automated sequencer (ABI prism 3100, Applied Biosystems, Foster City, CA). The same primers used for amplification were also used for sequence analysis.

Genomic DNA was obtained from leucocytes, extracted according to standard methods. The nine exons and intron-exon boundaries of *ALG3* gene were PCR amplified and directly sequenced. Primers (Table 1) were designed on GenBank sequence (accession number NT_005612.14) and they were also synthesized by Microsynth (Balgach, Switzerland).

The amplified fragments were purified and then sequenced as described above for cDNA analysis. The same primers used for amplification were also used for sequence analysis. To rule out that the mutations found in our patient are a common polymorphism, sequence analysis of exons 1 and 4 of *ALG3* gene was performed in genomic DNA from 50 anonymous unrelated European controls.

Results:

Capillary electrophoresis of serum transferrin

The transferrin glycoforms separation by capillary electrophoresis in our patient was typical of a CDG syndrome type 1 with asialo- disialo- and tetrasialotransferrin (Figure 2).

Biochemical analysis of dolichol-oligosaccharides and protein-linked oligosaccharides.

Fully assembled oligosaccharide with the structure Glc3Man9GlcNAc2 are predominantly present in the fibroblasts of healthy controls with small amounts of intermediate assembly products. In our patient cells, the LLOs isolated showed two peaks, one corresponding to the mature Glc3Man9GlcNAc2 oligosaccharide and one major peak corresponding to the characteristic truncated Man5-GlcNAc2 structure.

Mutation analysis

In the cDNA sequence analysis of *ALG3* gene, two compound heterozygous mutations, one in exon 1 [c.116 C<T, p.P39L] and another in exon 4 [c.512 G<A, p.R171Q] were found in our patient.

The mutations were confirmed in the patient's genomic DNA, sequencing of exons 1 and 4 of *ALG3* gene in both parents confirmed segregation (maternal mutation: p.P39L, paternal mutation: p.R171Q). The 2 nucleotide changes found in our patient were not found in 100 chromosomes of anonymous unrelated European controls.

References:

1. Carchon, H.A., et al., *Diagnosis of congenital disorders of glycosylation by capillary zone electrophoresis of serum transferrin*. Clin Chem, 2004. **50**(1): p. 101-11.
2. Lanz, C., et al., *Improved capillary electrophoresis method for the determination of carbohydrate-deficient transferrin in patient sera*. Electrophoresis, 2004. **25**(14): p. 2309-18.
3. Kranz, C., et al., *A mutation in the human MPDU1 gene causes congenital disorder of glycosylation type If (CDG-If)*. J Clin Invest, 2001. **108**(11): p. 1613-9.
4. Korner, C., et al., *Carbohydrate deficient glycoprotein syndrome type IV: deficiency dolichyl-P-Man:Man(5)GlcNAc(2)-PP-dolichyl mannosyltransferase*. Embo J, 1999. **18**(23): p. 6816-22.
5. Denecke, J., et al., *An activated 5' cryptic splice site in the human ALG3 gene generates a premature termination codon insensitive to nonsense-mediated mRNA decay in a new case of congenital disorder of glycosylation type Id (CDG-Id)*. Hum Mutat, 2004. **23**(5): p. 477-86.

Primer name	Oligonucleotide primer sequence 5'-<3'
ALG3 F1 [4]	CACACAAGCGGCGCACCGTTAAG
ALG3 R1	GCACAAAGATGGAGTGGACACGG
ALG3 F2	TTGCTGTGCTCTACCTGGCTAC
ALG3 R2	AGAGGGCAAACAGCAGGAGCAG
ALG3 F3	TTCCTGCATCGAGCCTTCCACCTG
ALG3 R3 [4]	GTAGACTCAGGTCCTGAGGGAAAG
ALG3 Ex1 F [5]	ACCTAAGTGTCGAAGGTTCGG
ALG3 Ex1 R [5]	TCTGAGATCCAGITTTGGGTCG
ALG3 Ex2-4F[5]	GTGGCAGACAAGTTCTAGACTC
ALG3 Ex2-4 R	GCAGGAAATTGGGAAGAGATGG
ALG3 Ex5 F	TGTGAGTGTAGGTCCCATCTTG
ALG3 Ex5 R	AGAAAGAGGAAGGGTGAGATGG
ALG3 Ex6-7 F	CAATGAGTAGCATGAAGGCTGG
ALG3 Ex6-7 R	ACTCTGTCAGCACCTAGAGAG
ALG3 Ex8-9 F	AGAGCCAGAGGGCTATGTGACCTA
ALG3 R3	GTAGACTCAGGTCCTGAGGGAAAG

Table 1:

Primers used for cDNA analysis of ALG3 gene (NM_005787.2): F1 to R3

Primers used for genomic DNA analysis of ALG3 gene (NT_005612.14): Ex1 F to R3

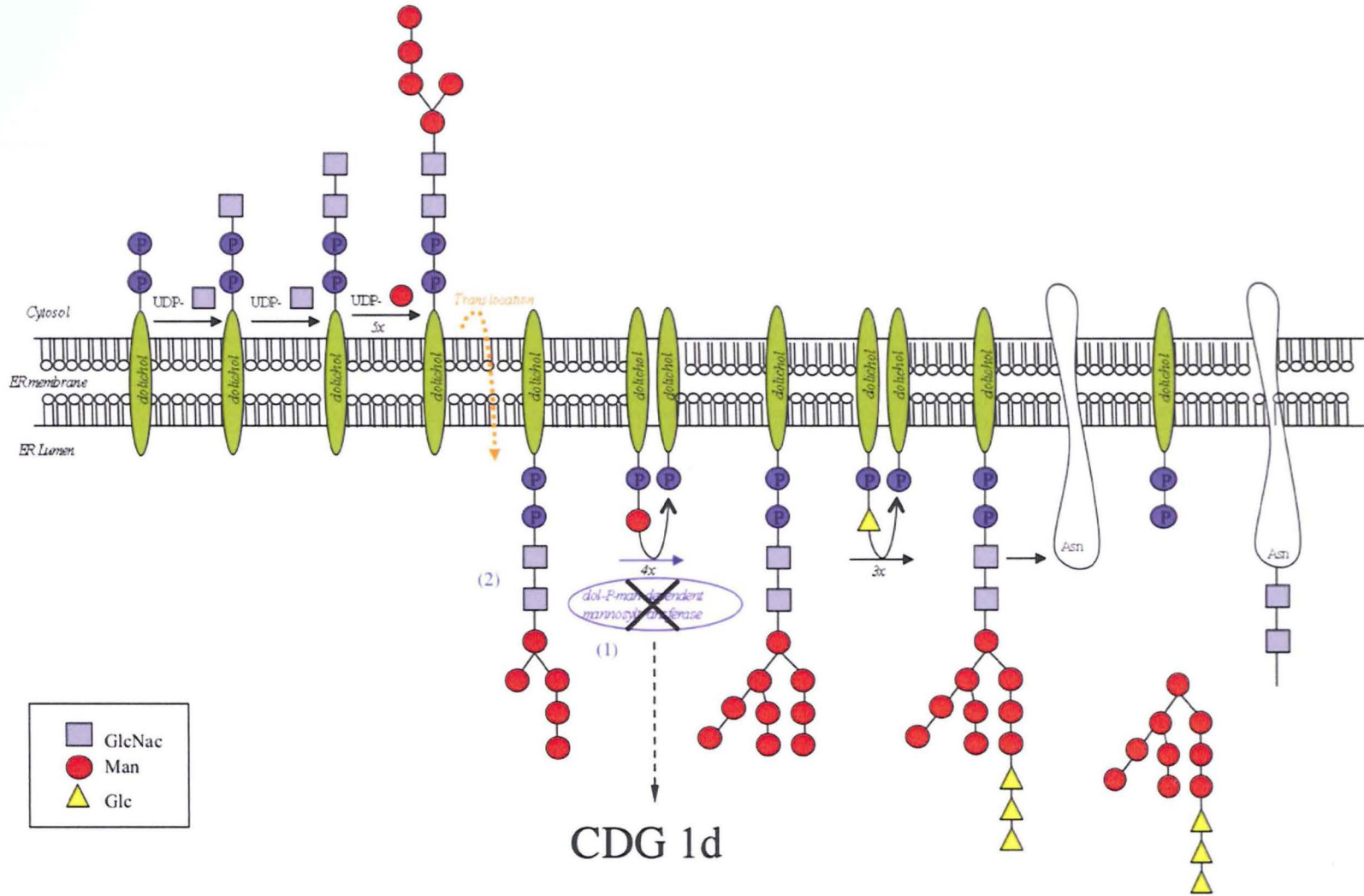


Figure 1: N-glycosylation is initiated on the cytoplasmic side of the ER membrane by transferring two GlcNAc residues (grey squares) to Dolichol-P using UDP-GlcNAc as GlcNAc donor. The product GlcNAc₂-P-P-Dol is extended by successive five different mannosyltransferases using GDP-mannose (mannose: red dots) as the donor substrate. The oligosaccharide product Man₅GlcNAc₂ is translocated from the cytoplasmic side of the ER-membrane to the luminal side of the organelle (orange arrow) catalyzed by a flippase. On the luminal side of ER, mannosyl- and glucosyltransferases elongate the Man₅GlcNAc₂ oligosaccharide to a Glc₃Man₉GlcNAc₂ oligosaccharide (glucose: yellow triangle). The Glc₃Man₉GlcNAc₂ oligosaccharide is transferred to the nascent protein. The glycoprotein is transferred to the Golgi by vesicular transport, after removal of the glucose residues and one mannose. The defective enzyme in CDG 1d is a Man₅GlcNAc₂-PP-dolichyl mannosyltransferase (1) that normally adds mannose to lipid-linked oligosaccharide (LLO) in luminal side of ER. This enzyme defect results in a typical accumulation of truncated LLOs with five mannoses (Man₅GlcNAc₂) (2)

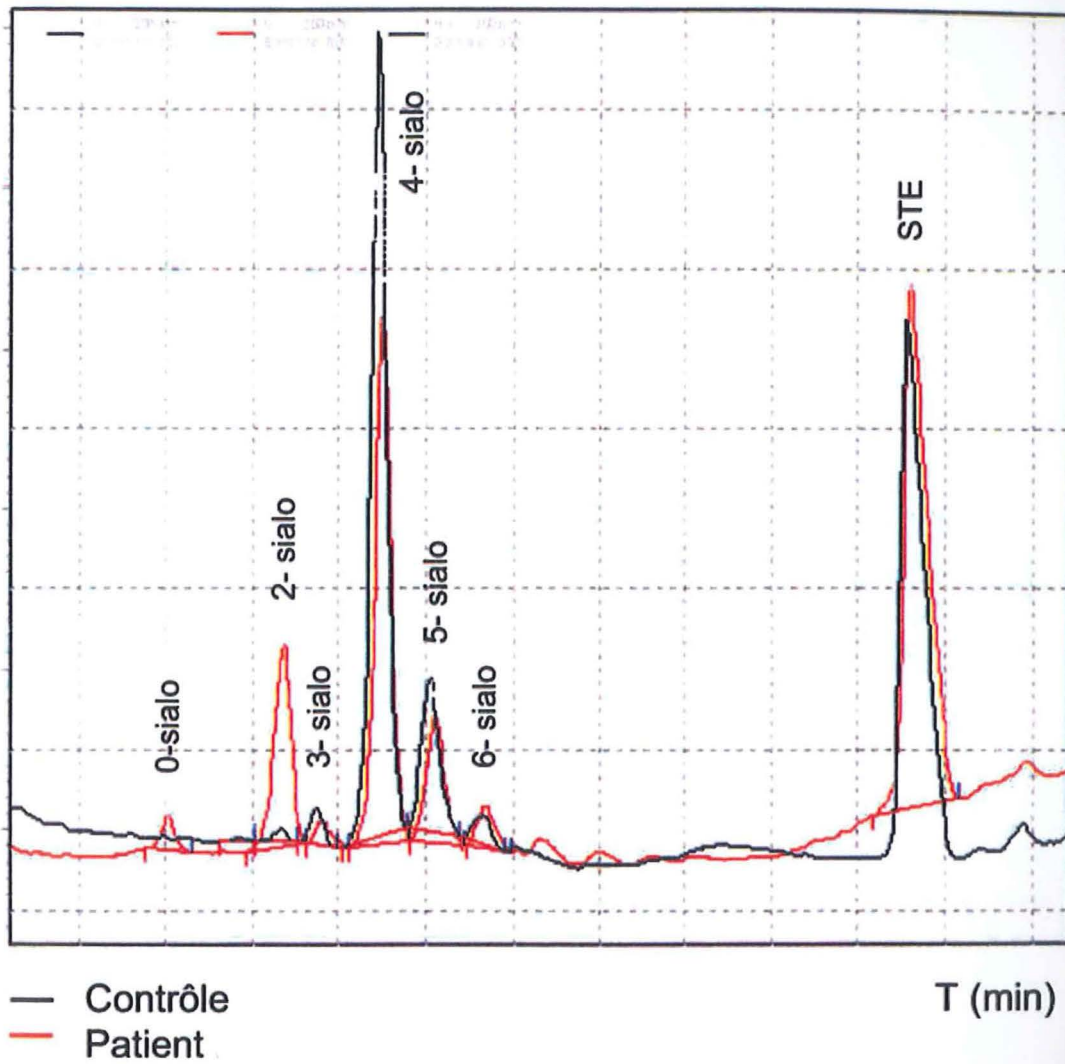


Figure 2: Capillary electrophoresis of serum transferrin. Fully glycosylated transferrin in a control patient has four sialic acids (4-sialo). CDG-Id patient has a typical glycosylation phenotype with increased asialo- disialo- and tetrasialotransferrin.