



Images in cardio-thoracic surgery

Atypical presentation of mature teratoma mimicking hydatidosis

Franco Gambazzi^{a,*}, Alex Ochsner^a, Hans-Beat Ris^b, Hans-Reinhard Zerkowski^a^aDivision of Cardiothoracic Surgery, University Hospital, Spitalstrasse 21, CH-4031 Basel, Switzerland^bDivision of Thoracic Surgery, University Hospital, 46 rue du Bugnon, CH-A0AA, Lausanne, Switzerland

Received 1 March 2005; received in revised form 28 March 2005; accepted 30 March 2005; Available online 4 June 2005

Keywords: Thoracic echinococcosis; Teratoma

Suspicion of a thoracic echinococcosis by radiologic findings (Figs. 1 and 2) in a 38-year-old asymptomatic Swiss woman with periodical stays in India. An antihelminthic 2-week therapy was followed by surgical resection, strictly

avoiding dissemination. Surprisingly, the cyst contained hair and seborrhoeic liquid. Histological confirmation of a mature teratoma.

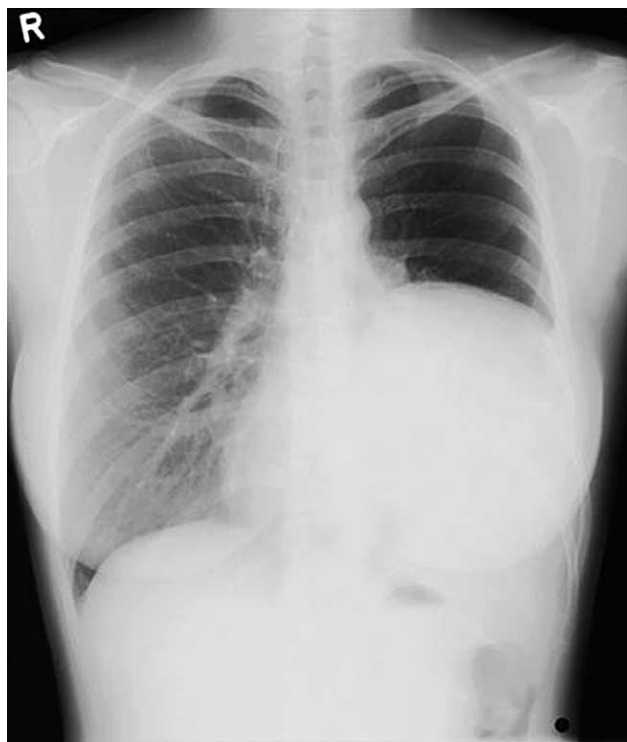

Fig. 1. Chest X-ray shows an apparent elevation of left hemidiaphragm.

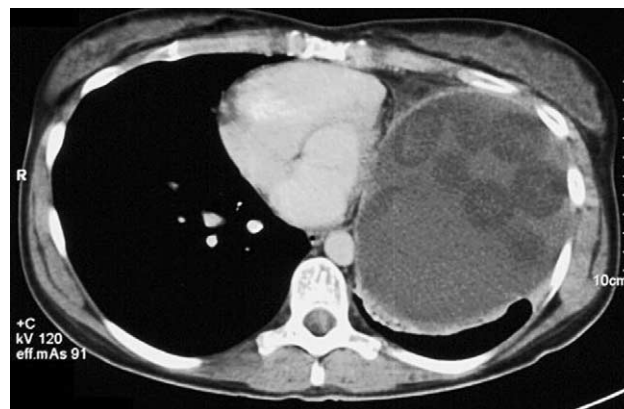


Fig. 2. CT scan reveals a large liquid mass in the left lower hemithorax with the aspect of a hydatid cyst containing daughter cysts.

* Corresponding author. Tel.: +41 61 265 71 99; fax: +41 61 265 73 24.
E-mail address: fgambazzi@uhbs.ch (F. Gambazzi).