

EDITORIAL COMMENTARY

A New Piece Added to the Whipple Puzzle: *Tropheryma whipplei* Primary Infection with Bacteremia and Cough

Gilbert Greub

Institute of Microbiology and Service of Infectious Diseases, University of Lausanne and University Hospital Center, Lausanne, Switzerland

(See the article by Fenollar et al, on pages 515–521.)

In 1907, when the first case of Whipple disease was described by George Whipple, the clinical presentation of the disease, although not considered to be of infectious origin, already included cough and diarrhea [1]. This index patient had a chronic form of the disease, coined here as late-onset Whipple disease. During the past century, Whipple disease has been considered to be a rare and chronic disease, mainly affecting white, middle-aged men and presenting mainly as diarrhea, weight loss, steatorrhea, arthralgia, lymphadenopathy, anemia, and, to a lesser extent, neurologic impairments, ocular involvement, and/or endocarditis [2]. The visualization by electron microscopy of rods in intestinal biopsy specimens suggested that Whipple disease was of microbial origin [3, 4], a hypothesis confirmed in the 1990s by sequencing the 16S ribosomal RNA encoding gene of the causative bacteria [5, 6], named *Tropheryma whipplei* [7].

However, our understanding of the ep-

idemiology, mode of transmission, pathogenesis, and natural history of Whipple disease remained largely incomplete, being impaired by the few diagnostic tools available. Indeed, the diagnosis still mainly relies on histologic analysis (periodic acid–Schiff–positive macrophages), polymerase chain reaction (PCR), and immunohistochemical analysis [2, 8, 9]. Culture proved to be challenging because of the slow replication rate of the bacteria (generation time of ~18 days) [10], and culture is still currently performed only in a few specialized laboratories. Moreover, development of serologic tools has been complicated by the paradoxical lack of antibody response in serum samples taken from patients with late-onset Whipple disease, likely related to glycosylation of bacterial antigens, which allows the bacteria to mask its own major antigens [11].

The mode of transmission and the clinical presentation of acute *T. whipplei* primary infection was partially uncovered recently. Fecal-oral transmission was suggested by the amplification of bacterial DNA from sewage and from feces of sewer workers and by the higher prevalence among this occupationally exposed population [12, 13]. Moreover, the coincidental presence of the bacteria with other enteric pathogens, such as *Giardia lamblia* [14], further supported the hypothesis of a fecal-oral transmission. Although fecal-

oral primary infection might be asymptomatic, Raoult et al [15] hypothesized that *T. whipplei* might cause gastroenteritis. They thus studied prospectively French children with and without gastrointestinal symptoms, convincingly demonstrating that *T. whipplei* may indeed represent an agent of gastroenteritis because both increased immunoglobulin M titers and higher bacterial DNA load were observed among cases.

The same group reported a high prevalence (44%) of *T. whipplei* DNA in stools from healthy 2- to 10-year-old children living in Ndiop and Dielmo, 2 rural villages located in the south of Senegal [16]. Suspecting an ongoing outbreak of acute Whipple disease, Fenollar et al [17] undertook the study reported in this issue and identified 13 bacteremic cases among febrile patients living in these 2 villages. Interestingly, most cases were identified during the dry season (December to January) and among children ($n = 10$). However, contrary to what has been expected, the bacteremia was not associated with diarrhea ($n = 1$) but rather with cough ($n = 10$) and sleep disorders ($n = 5$). This study thus adds an important new piece to the Whipple puzzle that makes it possible to consider febrile bacteremia and cough as possible common clinical presentations of acute *T. whipplei* infection. This new information completely changes

Received 26 May 2010; accepted 27 May 2010; electronically published 26 July 2010.

Reprints or correspondence: Dr Gilbert Greub, Infectious Diseases Service and Institute of Microbiology, University Hospital Center and University of Lausanne, Lausanne, Switzerland (gilbert.greub@chuv.ch).

Clinical Infectious Diseases 2010;51(5):522–524

© 2010 by the Infectious Diseases Society of America. All rights reserved.

1058-4838/2010/5105-0006\$15.00

DOI: 10.1086/655678

the way we perceive the pathogenesis and natural history of Whipple disease. Thus, in addition to the rare late-onset Whipple disease that includes both focal and multifocal clinical manifestations, *T. whipplei* also causes an acute common illness, likely corresponding to primary infection with bacteremia, cough, and/or gastroenteritis (Figure 1).

The absence of *T. whipplei* DNA in all investigated water sources present in Ndiop and Dielmo villages suggested human-to-human transmission. Although primary infection after oral-oral and/or fecal-oral transmission is suggested by the presence of *T. whipplei* DNA in both saliva and stools from healthy individuals (asymptomatic carriers), the clinical presentation observed by Fenollar et al [17] among 10 of the 13 bacteremic patients (ie, fever and cough) might also possibly reflect an airborne transmission. Thus, respiratory tract infection might be con-

secutive to inhalation of infected droplets, whereas gastroenteritis might follow ingestion of infectious particles.

Recent evidence suggests a role of *T. whipplei* as an agent of pneumonia [18, 19]. In 1 of these reports, *T. whipplei* was identified in 6 (3%) of 210 bronchoalveolar lavages tested [19]. Notably, 3 patients experienced aspiration pneumonia. Because *T. whipplei* may be present in the saliva of asymptomatic persons [20, 21], it has been proposed that this gram-positive rod could contribute to aspiration pneumonia along with other bacteria present in the oropharyngeal microbiota [19]. Conversely, the presence of *T. whipplei* DNA in the saliva of asymptomatic patients complicates the interpretation of DNA positivity in bronchoalveolar lavages (possible contamination of the respiratory sample with saliva). Moreover, in the work of Bousbia et al [19], *T. whipplei* was generally not the only detected agent. In that

context, the documentation by Fenollar et al [17] of an association between *T. whipplei* bacteremia and cough is important because it further supports a role of *T. whipplei* as a possible agent of lower respiratory tract infection.

One of the main limitations of the work performed by Fenollar et al [17] is the absence of a control group among Senegalese patients. Indeed, the negative results of the PCR performed on the French controls support an absence of PCR contamination but do not rule out horizontal contamination of the samples during the early phase of DNA extraction performed in Senegal.

Despite this limitation, the study performed by Fenollar et al [17] represents a pivotal work that opens new questions that need to be addressed in the near future. The prevalence of *T. whipplei* bacteremia and associated clinical manifestations needs to be defined thoroughly in

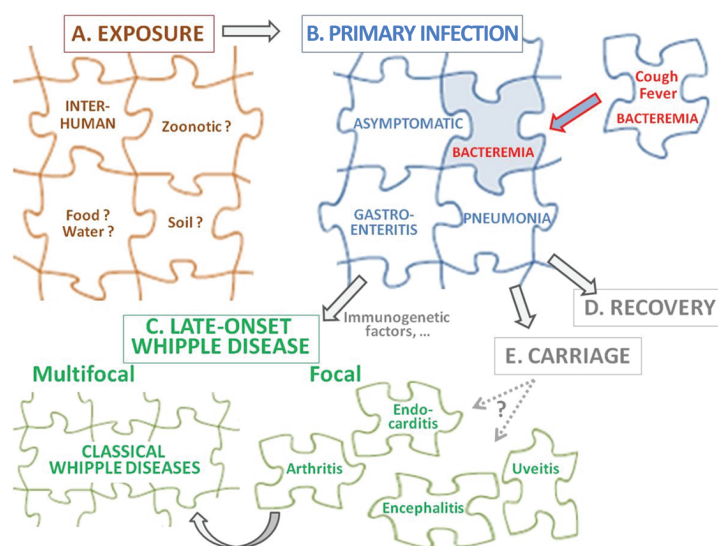


Figure 1. A new piece added to the puzzle describing the natural history of Whipple disease. *A*, Interhuman transmission likely takes place through fecal-oral contamination. However, infection might also possibly follow exposure to human saliva and/or aerosols or be associated with yet unknown environmental or zoonotic risks. *B*, Primary infection might be asymptomatic but may also present as a febrile illness associated with cough and sleep disorders, as demonstrated by Fenollar et al in this issue [17]. This additional piece added to the Whipple puzzle also supports previous reports that suggest a role of *T. whipplei* as an agent of pneumonia [18, 19]. Nevertheless, primary infection might also present as a common gastroenteritis [15] and some yet unknown additional syndromes. *C*, Only a limited number of patients will later develop focal or multifocal clinical manifestation of late-onset Whipple disease. Immunogenetic factors are likely important in this rare pathological evolution [23]. Please note that the list of manifestations provided here is not exhaustive. Focal manifestations such as prodromal arthritis may precede classic multifocal Whipple disease for years. *D* and *E*, Most infected patients would either become asymptomatic carriers or completely recover from *T. whipplei* primary infection. Whether asymptomatic carriers are at risk to later develop clinical manifestations of focal or multifocal late-onset Whipple disease is yet unknown.

various populations (children, adults, and immunocompromised individuals) from different geographical areas. The prevalence of *T. whipplei* pneumonia [19] and gastroenteritis [15] also needs to be studied in different settings. These studies may help to identify the reservoir and mode of transmission of *T. whipplei*. Although human-to-human transmission is likely, environmental (food, water, and soil) and/or zoonotic risks should also be searched for.

The documentation of *T. whipplei* bacteremia also raises important treatment issues. Apparently, all 13 bacteremic patients evolved favorably even though most of them were left untreated [17]. Nevertheless, we may wonder whether such bacteremia needs to be treated (1) to further improve short-term outcome, (2) to reduce transmission, (3) to avoid asymptomatic carriage, and/or (4) to prevent late-onset *T. whipplei* infection in some of these patients. The latter question will only be solved by starting a prospective randomized cohort study of any patients identified in similar outbreaks of acute infection. Randomization for treatment versus absence of treatment includes an important ethical issue given the unknown risk of development of severe difficult-to-treat late-onset Whipple disease, such as encephalitis or endocarditis. The untreated group will be pivotal to define the natural history of Whipple disease and to identify factors associated with the rare development of late-onset Whipple disease. Given the absence of correlation of *T. whipplei* genotypes with clinical presentation [22], host factors are likely to play a major role. Some immunogenetic factors have recently been identified [23], and these hosts factors may explain why such a common primary infection with bacteremia, pneumonia, and/or gastroenteritis only rarely causes focal or multifocal late-onset Whipple disease. Genetic factors may also potentially explain why late-onset Whipple disease has been reported

more frequently among white, male individuals. In addition to genetic factors, the apparent discrepancy between the relatively high prevalence of acute *T. whipplei* infection in Africa and the near absence of classic Whipple disease among African residents might also be partially explained by the lower rate of recognition of late-onset Whipple disease.

In conclusion, the landmark article by Fenollar and colleagues published in this issue of *Clinical Infectious Diseases* should be added to the list of major contributions to the understanding of Whipple disease because it provides the first evidence of *T. whipplei*-associated bacteremia and represents a missing piece of the primary-infection Whipple puzzle.

Acknowledgments

Financial support. G.G. is supported by the Leenards Foundation through a career award entitled "Bourse Leenards pour la relève académique en médecine clinique à Lausanne."

Potential conflict of interests. G.G.: no conflicts.

References

- Whipple GH. A hitherto undescribed disease characterized anatomically by deposits of fat and fatty acids in the intestinal and mesenteric lymphatic tissues. *John Hopkins Hosp Bull* **1907**; 18:381–392.
- Schneider T, Moos V, Lodenkemper C, Marth T, Fenollar F, Raoult D. Whipple's disease: new aspects of pathogenesis and treatment. *Lancet Infect Dis* **2008**; 8:179–190.
- Cohen AS, EM; Holt, PR; Isselbacher, KJ. Ultrastructural abnormalities in Whipple's disease. *Proc Soc Exp Biol Med* **1960**; 105:411–414.
- Cohen AS. An electron microscopic study of the structure of the small intestine in Whipple's disease. *J Ultrastruct Res* **1964**; 10:124–144.
- Wilson KH, Blitchington R, Frothingham R, Wilson JA. Phylogeny of the Whipple's-disease-associated bacterium. *Lancet* **1991**; 338: 474–475.
- Relman DA, Schmidt TM, MacDermott RP, Falkow S. Identification of the uncultured bacillus of Whipple's disease. *N Engl J Med* **1992**; 327:293–301.
- La Scola B, Fenollar F, Fournier PE, Altwegg M, Mallet MN, Raoult D. Description of *Tropheryma whipplei* gen. nov., sp. nov., the Whipple's disease bacillus. *Int J Syst Evol Microbiol* **2001**; 51:1471–1479.

- Fenollar F, Laouira S, Lepidi H, Rolain JM, Raoult D. Value of *Tropheryma whipplei* quantitative polymerase chain reaction assay for the diagnosis of Whipple disease: usefulness of saliva and stool specimens for first-line screening. *Clin Infect Dis* **2008**; 47:659–667.
- Lepidi H, Fenollar F, Gerolami R, et al. Whipple's disease: immunospecific and quantitative immunohistochemical study of intestinal biopsy specimens. *Hum Pathol* **2003**; 34:589–596.
- Raoult D, Birg ML, La Scola B, et al. Cultivation of the bacillus of Whipple's disease. *N Engl J Med* **2000**; 342:620–625.
- Bonhomme CJ, Renesto P, Desnues B, et al. *Tropheryma whipplei* glycosylation in the pathophysiological profile of Whipple's disease. *J Infect Dis* **2009**; 199:1043–1052.
- Schoniger-Hekele M, Petermann D, Weber B, Muller C. *Tropheryma whipplei* in the environment: survey of sewage plant influxes and sewage plant workers. *Appl Environ Microbiol* **2007**; 73:2033–2035.
- Fenollar F, Trani M, Davoust B, et al. Prevalence of asymptomatic *Tropheryma whipplei* carriage among humans and nonhuman primates. *J Infect Dis* **2008**; 197:880–887.
- Fenollar F, Lepidi H, Gerolami R, Drancourt M, Raoult D. Whipple disease associated with giardiasis. *J Infect Dis* **2003**; 188:828–834.
- Raoult D, Fenollar F, Rolain JM, et al. *Tropheryma whipplei* in children with gastroenteritis. *Emerg Infect Dis* **2010**; 16:776–782.
- Fenollar F, Trape JF, Bassene H, Sokhna C, Raoult D. *Tropheryma whipplei* in fecal samples from children, Senegal. *Emerg Infect Dis* **2009**; 15:922–924.
- Fenollar F, Mediannikov O, Socolovschi C, et al. *Tropheryma whipplei* bacteremia during fever in rural west Africa. *Clin Infect Dis* **2010**; 51(5):515–521 (in this issue).
- Harris JK, De Groote MA, Sagel SD, et al. Molecular identification of bacteria in bronchoalveolar lavage fluid from children with cystic fibrosis. *Proc Natl Acad Sci U S A* **2007**; 104:20529–20533.
- Bousbia S, Papazian L, Auffray JP, et al. *Tropheryma whipplei* in patients with pneumonia. *Emerg Infect Dis* **2010**; 16:258–263.
- Street S, Donoghue HD, Neild GH. *Tropheryma whippelii* DNA in saliva of healthy people. *Lancet* **1999**; 354:1178–1179.
- Ehrbar HU, Bauerfeind P, Dutly F, Koelz HR, Altwegg M. PCR-positive tests for *Tropheryma whippelii* in patients without Whipple's disease. *Lancet* **1999**; 353:2214.
- Li W, Fenollar F, Rolain JM, et al. Genotyping reveals a wide heterogeneity of *Tropheryma whipplei*. *Microbiology* **2008**; 154:521–527.
- Moos V, Schmidt C, Geelhaar A, et al. Impaired immune functions of monocytes and macrophages in Whipple's disease. *Gastroenterology* **2010**; 138:210–220.