

Frequently asked questions in the medical management of high-grade glioma: a short guide with practical answers

R. Stupp¹, A. F. Hottinger², M. J. van den Bent³, P.-Y. Dietrich² & A. A. Brandes⁴

¹Centre Hospitalier Universitaire Vaudois and University of Lausanne; ²Hôpitaux Universitaires Genevois and University of Geneva, Switzerland; ³Erasmus University/Daniel de Hoed Cancer Center, Rotterdam, The Netherlands; ⁴Bellaria-Maggiore Hospital, Azienda USL of Bologna, Bologna, Italy

introduction

Progress has been made over the last decade in the management of malignant glioma. New chemotherapy agents have been developed specifically for the treatment of malignant glioma [1–4]. Combined modality therapy with temozolomide (TMZ) and radiation (RT) have become the standard first-line treatment in glioblastoma [5]. New targeted and anti-angiogenic agents are under investigation for the treatment of newly diagnosed or recurrent glioma. Molecular markers, such as 1p and 19q status in oligodendrogliomas or promoter methylation status of the *MGMT* gene now allow the identification of distinct subtypes of gliomas and may help predict response to treatment and outcome [6, 7]. The current state of the art has been extensively reviewed recently [1, 2, 8]. Here we focus on recurrent questions in the daily management of glioma patients. Our answers aim at practical considerations, recommendations and suggestions.

what is the optimal duration of adjuvant (maintenance) TMZ treatment in glioblastoma?

In the randomized EORTC/NCIC (European Organisation for Research and Treatment of Cancer/National Cancer Institute of Canada) landmark phase III trial, TMZ was administered at a continuous low dose (75 mg/m² daily 7 days per week) from the first to the last day of RT, up to a maximum of 49 days, together with concomitant RT (TMZ/RT) [5]. The TMZ schedule was based on a phase I trial developed by Newlands and colleagues [9]. Standard focal fractionated RT was delivered up to a total of 60 Gy. After a 4-week break, adjuvant (or maintenance) TMZ treatment was given on a standard schedule (150–200 mg/m² daily for 5 days) for up to six cycles (Figure 1). In the preceding phase II trial, the duration of the maintenance therapy of 6 months had been arbitrarily chosen, based on experience with adjuvant chemotherapy in breast and colon cancer [10]. However, in contrast to other solid tumors, in malignant glioma residual macroscopic disease often remains despite surgery, and thus continuation of treatment for visible disease would be better termed ‘maintenance’.

To date, prolonged maintenance therapy with cytotoxic chemotherapy agents has not been shown to confer a benefit in many diseases. In glioma patients, even though no trial has ever been designed specifically to evaluate the duration of maintenance chemotherapy, the data available with carmustine (BCNU) or PCV (procarbazine, lomustine, vincristine) prescribed for up to 12 months failed to demonstrate a significant survival advantage [11, 12].

In patients with a macroscopically incomplete tumor resection (or a biopsy only), chemotherapy is not truly adjuvant as visible disease is treated. Some physicians pursue chemotherapy for as long as continuous tumor regression is visible on magnetic resonance imaging (MRI). It is of note, however, that due to the delayed radiological response of brain tumors, continuous response may be seen once therapy has been discontinued.

In our daily practice, we usually discontinue maintenance TMZ therapy after the standard six cycles for a number of reasons: (i) even though this treatment is usually well tolerated, cumulative bone marrow toxicity may limit subsequent salvage chemotherapy in case of recurrence; (ii) following chronic exposure to TMZ, there is a theoretical risk of development of myelodysplastic syndromes and secondary leukemia as with any other alkylating agents; (iii) a treatment-free interval may be associated with improved quality of life (e.g. less fatigue); (iv) this approach allows for the option of re-exposing recurrent patients to the same treatment at a later stage.

Nevertheless, and short of class I evidence, prolongation of TMZ maintenance for up to 12 cycles is considered in some centers for patients demonstrating continued tumor response on MRI and a favorable clinical evolution [13].

which is the most effective TMZ chemotherapy schedule?

Even though the only two formally approved administration regimen are the five daily dose schedule (150–200 mg/m², repeat after 28 days) and the low-dose daily (75 mg/m² for a maximum of 49 days) administration regimen in combination with radiotherapy, a number of different

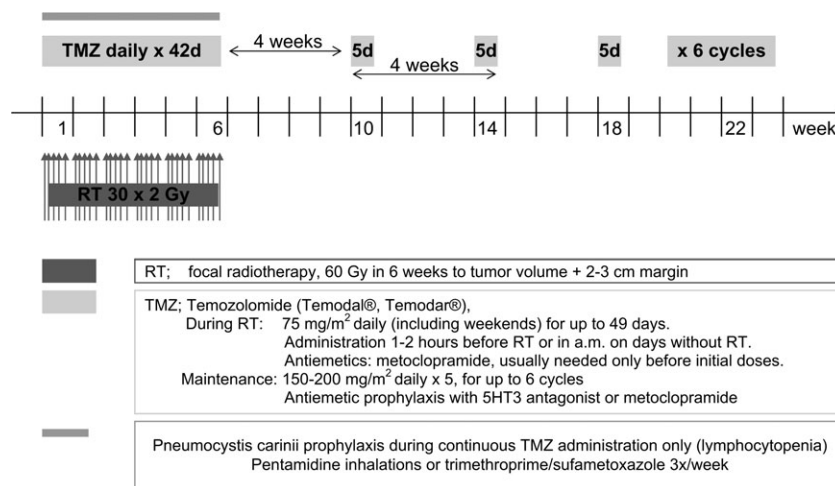


Figure 1. EORTC/NCIC treatment scheme for glioblastoma (adapted and reproduced with permission [1, 2]).

Table 1. Standard and dose-dense temozolomide administration schedules

Schedule	Dose: mg/m ²	Dose intensity : mg/m ² /week	References
Daily for 5 days, repeat every 28 days	150–200	250	Initially a approved standard dosing
Daily for 42–49 days, repeat every 70 days	75	315	Brock et al. [9] Approved in conjunction with RT [5]
Daily for 7 days, repeat every 14 days	150	525	Wick et al. [15], Tolcher et al. [16],
Daily for 21 days, repeat every 28 days	75–100	394–525	Tolcher et al. [16], Brandes et al. [17]
Daily for 3 days, repeat every 14 days	300	450	Vera et al. [53]

schedules of TMZ administration are in use (Table 1). Other, so-called dose dense regimens include one week on/1 week off (150 mg/m² for 7 days, every 14 days), 3 weeks on/1 week off (75–100 mg/m² for 21 days, every 28 days), metronomic daily TMZ (50 mg flat dose daily non-stop or 50 mg/m²/day non-stop) [14–17]. The dose dense schedules allow a significant increase in the dose intensity (over 2-fold) and the cumulative dose of TMZ. The rationale of these schedules is based on the theoretical considerations and data from peripheral blood mononuclear cells, which suggest that continuous exposure to TMZ may deplete the repair protein MGMT [16]. After repair, MGMT needs to be resynthesized by the cell and, theoretically, these schedules may exhaust the reservoir of the repair protein and therefore increase the toxic alkylating effect of TMZ. However, improved efficacy of these schedules remains to be demonstrated. A randomized Greek phase II trial compared intensified adjuvant TMZ therapy (150 mg/m² for 5 days) given every 2 weeks (instead of every 4 weeks) compared to RT alone [18]. The overall outcome of this study does not suggest a significant improvement over the results of our pilot phase II or the EORTC–NCIC phase III trial, even though cross-trial comparisons are to be made with great caution [5, 10]. In the ongoing Radiation Therapy Oncology Group (RTOG)–EORTC Intergroup trial, standard dose adjuvant TMZ chemotherapy (150–200 mg/m² daily for 5 days in a 28 day cycle) is compared with

a dose-dense regimen (75–100 mg/m² daily for 21 days in a 28 day cycle). This trial has reached its accrual goal of over 1100 patients in early summer 2008, and first results are expected in late 2009. Based on theoretical considerations, a low-dose continuous schedule has also been chosen for the randomized phase III EORTC trial (EORTC 22033-26033) in low-grade glioma. Patients with a low-grade glioma with documented clinical and radiological progression are randomized between standard radiotherapy versus TMZ (75 mg/m² for 21 days in a 28 day cycle) as initial therapy.

Continuous TMZ exposure may induce profound lymphocytopenia with decreased CD4 counts well below 200/mm³, a threshold at which antibiotic prophylaxis against pneumocystis pneumonia is recommended in HIV patients (see below). Recovery after discontinuation of TMZ may be slow.

The currently available data and clinical experience does not support the use of alternative TMZ regimen outside specific protocols and clinical investigation.

when is pneumocystis pneumonia antibiotic prophylaxis needed?

Lymphocytopenia resulting from continuous TMZ administration has been associated with opportunistic

infections and complications seen with profound cellular immunosuppression [10, 19]. In addition to pneumocystis pneumonia (PcP), infections with candida and listeria as well as Kaposi sarcoma have been reported [19, 20]. The immunosuppression may be further exacerbated by use of corticosteroid therapy in patients with brain tumors, which has by itself been associated with an increased risk of opportunistic infections [21, 22].

When treating our first series of patients with TMZ and concomitant radiotherapy, we observed two pneumocystis infections in the first 15 patients treated [10]. This was clearly more than could have been expected even with steroid use, thus we introduced PcP prophylaxis with pentamidine inhalations in our first line TMZ/RT and TMZ phase II and phase III trials, and PcP prophylaxis with either pentamidine or trimetoprim-sulfamethoxazol or dapsone [23] has been included in the official approval label for concomitant TMZ chemoradiotherapy. In our practice, we prefer once monthly pentamidine inhalations (Pentacarinat[®] 300 mg q 28d) over sulfur-drugs (e.g. Bactrim[®] forte/Sepra[®] DS three times per week, dapsone 100 mg/day) as the latter drugs are associated with a significant risk of myelosuppression that may exacerbate the bone marrow toxicity of TMZ. Moreover, with the appropriate infrastructure, pentamidine inhalations are simple and this approach avoids adding an extra medication to an often already long and complex list of drugs that must be taken daily by the patient (e.g. TMZ, corticosteroids, antiepileptics, among others).

The alternative to prescribing antibiotic prophylaxis to all patients is surveillance of the lymphocyte and/or CD4 counts. If this approach is selected, prophylaxis must be started once the absolute lymphocyte or CD4 counts drop below 500/mm³ or 200/mm³ (\geq grade 3), respectively. However, this requires compliance and regular active monitoring of counts, which may be beyond the routine surveillance procedures.

which component of the TMZ/RT → TMZ regimen is more important, the concomitant or the adjuvant part?

The EORTC/NCIC trial showed an overall survival improvement with the addition of TMZ chemotherapy concomitantly with RT followed by adjuvant (maintenance) single agent TMZ chemotherapy (TMZ/RT → TMZ) [5]. However, this trial did not include a comparison between concomitant versus adjuvant (after irradiation) chemotherapy, and the relative contribution of each treatment component cannot be assessed. A major difference between the TMZ/RT → TMZ adjuvant chemotherapy trial and previous trials using other alkylating agents was the addition of substantial and daily chemotherapy concomitant with radiation. Similarly, concomitant chemo-radiotherapy has improved outcomes in many other solid tumors, such as head and neck, cervix, non-small cell lung or esophageal carcinoma. Preclinical data suggests additive and synergistic effects of TMZ and radiotherapy [24–27]. Thus, one may speculate that concomitant chemotherapy has been the key component to the improved outcome. Nevertheless, TMZ chemotherapy, when given for recurrent disease, has also demonstrated efficacy

[28–30]. The question of concomitant versus adjuvant chemotherapy is the subject of an ongoing randomized EORTC/Intergroup trial (CATNON trial) in non-1p/19q-deleted anaplastic astrocytoma and oligoastrocytoma (see below).

In our opinion, and short of a better treatment option, the regimen has to be accepted as is, without modification in either dose or treatment duration. The TMZ should be administered daily during the radiotherapy, including on days without radiation (e.g. weekends).

why are anaplastic gliomas not treated just like glioblastoma?

One progress over the last decade has been to recognize that all gliomas are not alike and that there are specific subtypes. This reflects not only histological variations or variable underlying molecular changes but translates into a different natural history and differential response to treatment. Somewhat surprisingly, chemotherapy has been proven efficacious in glioblastoma, where responses are seen only rarely, while (neo-)adjuvant PCV chemotherapy has failed to improve overall survival (but with a trend towards prolonged disease-free survival) in the usually more responsive anaplastic oligo-astrocytoma and oligodendroglioma [31, 32]. Adjuvant nitrosourea-based chemotherapy has failed to demonstrate an improved outcome in randomized trials, even in the subgroup of patients with grade III tumors.

Late toxicity is of a lesser concern when treating glioblastoma, as this disease has a poor prognosis with a median survival of only 12–15 months. However, late toxicity does matter in patients with anaplastic astrocytoma or anaplastic oligodendroglioma who have a life expectancy of several years. Therefore the treatment philosophy for treating less aggressive disease may need to be different.

In an ongoing randomized phase III trial (CATNON-trial, Figure 2) in patients with anaplastic glioma without the combined 1p/19q deletion, the EORTC, together with the German Neuro-Onkologische Arbeitsgruppe (NOA), the British Medical Research Council (MRC), the US RTOG, North Central Cancer Treatment Group (NCCTG) and Eastern Cooperative Oncology Group (ECOG), will investigate concomitant versus adjuvant TMZ chemotherapy in a 2×2 design. Patients will be randomized to either RT alone or the combination of TMZ/RT, further to either adjuvant TMZ (standard schedule, 150–200 mg/m² daily for 5 days in a 28 days cycle) for 12 cycles (!) or observation after RT alone or TMZ/RT. A total of 748 patients are to be randomized over 4 years. Most importantly, for this trial pre-randomization assessment of the 1p/19q status is needed, and patients will be stratified for the methylation status of the *MGMT* gene promoter. Thus, a rapid flow of information, central pathology review and molecular analysis <6 weeks after surgery is required. The availability of tumor blocks will allow to also determine the *MGMT* gene promoter methylation status and, subsequently, any other markers or profile that may in future allow a better understanding of the disease or individually tailored therapy.

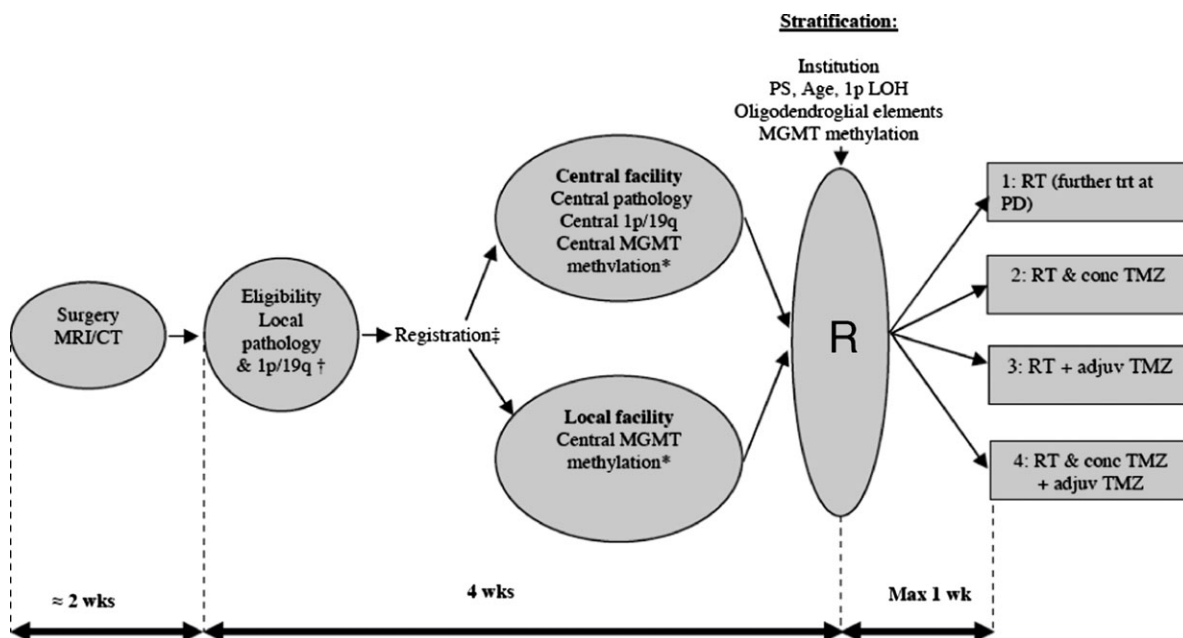


Figure 2. Design of ongoing phase III trial in anaplastic glioma (EORTC26053-22054/CATNON trial) for tumors without 1p/19q co-deletions.

should *MGMT* gene promoter methylation status be assessed routinely?

The DNA repair protein *MGMT* is associated with response to alkylating agent chemotherapy, as this enzyme repairs the toxic injuries inflicted to tumor cells by alkylating chemotherapeutic agents [33–36]. Treatment with TMZ chemotherapy and radiotherapy may induce upregulation of the *MGMT* expression [37]. The status of the *MGMT* gene promoter is an appropriate way of analyzing the capacity of the cells to upregulate *MGMT* as response to treatment. In a retrospective analysis of our phase II pilot trial and the subsequent phase III EORTC/NCIC trial we have shown that the benefit of the addition of TMZ chemotherapy is mainly restricted to patients whose tumors have a methylated *MGMT* gene promoter, thus a silenced gene and a limited capacity to repair some of the alkylating agent chemotherapy-induced DNA damage [7, 36]. The predictive value of the *MGMT* methylation will be confirmed in the ongoing RTOG0525/EORTC Intergroup trial. Central tissue review and determination of the *MGMT* gene promoter status by methylation-specific polymerase chain reaction (MSP) is a mandatory eligibility criterion in all patients. As this requires DNA extraction from the tumor cells after paraffin fixation, stereotactic biopsy will not provide sufficient tumor material for this analysis. However, if tumor tissue from a biopsy is immediately frozen, molecular analyses including *MGMT* gene status can be performed from minimal amounts of tumor tissue. Although protein expression can theoretically be assessed by immunohistochemistry or western blot, these methods ignore the potential induction of *MGMT* expression during therapy. Immunohistochemistry is poorly reproducible between different observers and lacks a consistent correlation with outcome [38, 39].

Information on a prognostic or predictive marker is only useful if it will allow to adapt the treatment strategy in order to improve the outcome and quality of life for patients. Although the data on the predictive value of *MGMT* methylation status is consistent and convincing, a prospective validation is pending. We still lack adequate alternative strategies for patients who do not have *MGMT* promoter methylation. In these patients, another agent with a different mechanism of action would best replace the TMZ chemotherapy. Unfortunately, no such agent with proven activity is currently available.

Short of an alternative strategy, we do not assess the *MGMT* gene promoter methylation status routinely. However, in patients who do not want to take TMZ chemotherapy, or in patients with a borderline performance status where treatment may be limited to supportive care only, or patients for whom we have doubts on tumor progression we may, after discussion with the patient on the consequences, decide to ask for this marker on an individual-by-individual basis. Questionable tumor progression or pseudoprogression (see below) following concomitant TMZ and radiation therapy occurs most frequently in patients with a methylated *MGMT* promoter [40]. Clearly, we only perform *MGMT* testing after having discussed with the patient the potential prognostic and therapeutic implications this may have.

is primary chemotherapy indicated for pure oligodendroglioma?

Oligodendroglioma with loss of heterozygosity (LOH) 1p/19q [recently identified as a translocation t(1p;19q)] has been considered as a particularly chemo-responsive glioma subtype [6, 41, 42]. Chemotherapy with PCV and TMZ has been effectively used in recurrent disease. Based on this experience,

patients with newly diagnosed oligodendroglioma have often been treated with chemotherapy as initial treatment.

Two recently published randomized trials confirmed that anaplastic oligodendroglioma is indeed a distinct clinical entity. Pure oligodendroglioma with LOH 1p/19q have a protracted natural history (median survival beyond 7 years) and a favorable outcome after RT with or without chemotherapy [31, 32]. The addition of chemotherapy, given either as a neo-adjuvant treatment before RT or in an adjuvant manner after RT, did not prolong overall survival, although progression-free survival was increased and therefore late toxicity from chemotherapy and RT therapy is a particular concern.

Therapeutic decisions for patients with oligodendroglioma need also to be guided by consideration of potential late treatment induced toxicities. For patients with progressive or anaplastic oligodendroglioma requiring treatment, focal radiotherapy remains the initial treatment of choice, and is likely to be the easiest and preferred treatment option for small tumors. However, for patients with large tumors that need

extensive radiation fields, primary chemotherapy may be advocated. A planned NCCTG lead international Intergroup study will compare primary radiotherapy alone to primary chemotherapy and to concomitant TMZ/RT.

are there clinical trials for glioma patients?

Never before have so many new agents been investigated in primary brain tumors. A number of ongoing trials, usually major international and Intergroup efforts have already been mentioned above. A selection of ongoing clinical trials investigating novel treatments are summarized in Table 2. The EORTC is involved in an industry-sponsored large international phase III trial evaluating the integrin inhibitor cilengitide in newly diagnosed glioblastoma (Figure 3). This first agent in its class with both direct anti-tumoral and vasculature modifying properties, has shown promising activity in phase I and phase II trials in recurrent and newly diagnosed

Table 2. Selection of ongoing trials in newly diagnosed glioblastoma (adapted and updated from Stupp et al. [1])

Investigational agent	Standard treatment	Phase	No of patients	Endpoint(s)	Sponsor	Remarks
Cilengitide (EMD121974)	TMZ/RT	III	>500	OS	Merck KGaA	Phase II completed [44]. Phase III trial in collaboration with EORTC and the Canadian Brain Tumor Consortium.
Cilengitide	TMZ/RT	II	112	OS	NABTT	Ongoing
Temsirolimus (CCI779)	TMZ/RT	I	46	Safety and toxicity	NCCTG	Started May 2006
Everolimus	TMZ/RT	I/II	108	PET uptake, survival	NCCTG	Start summer '08
Cetuximab	TMZ/RT	I/II	46	Feasibility, PFS, OS	Uni. Heidelberg, Germany	No maintenance TMZ
CDX-110	TMZ/RT	II/III	90–375	PFS	Celldex	Tumor-specific vaccine for EGFRvIII-expressing tumors
Bevacizumab	TMZ/RT	II	70		UCLA	Requires fresh-frozen tumor tissue
Bevacizumab	TMZ/RT → TMZ+CPT	II	75	Survival	Duke	
Bevacizumab	TMZ/RT	III	600	Survival	Genentech	Start planned summer 2007
Enzastaurin	TMZ/RT	I/II	72	Survival (phII)	Lilly/UCSF	Started September 2006
Enzastaurin	RT	II	54	PFS6	Lilly Germany	Only for patients with an unmethylated MGMT
Tipifarnib	TMT/RT	I	30	Safety and toxicity	NABTC	Completed
Tipifarnib	RT	II	27		Inst. Claude Regaud, Toulouse	France: Toulouse, Clermont-Ferrand
Lenalidomide	TMZ/RT	I/II	60	Survival	DFCI	Phase I: in phase II in combination with TMZ/RT planned
Vandetinib (ZD6474)	TMZ/RT	I/II (rand.)	150	Survival	DFCI	Start planned summer 2007. Harvard affiliates, MSKCC, U of Virginia, U of Pittsburgh
Hydroxychloroquine	TMZ/RT	I/II	94	Survival	NABTT	
Valproic acid	TMZ/RT	II	41	PFS, Survival	NCI	Valproate as a histone deacetylase inhibitor
131I-labelled anti-tenascin mab	TMZ/RT	III	760	Survival	Bradmer Pharma	Only for patients undergoing resection
Banaxtrone (AQ4N)	TMZ/RT	Ib/II	60	Safety, PFS6	Novacea	Bioreductive drug targeting hypoxic cells
Carmustine wafer	TMZ/RT	II	72	Survival	Johns Hopkins	

TMZ, temozolomide; RT, radiotherapy; NABTT, New Approaches to Brain Tumor Therapy CNS Consortium; NCCTG, North Central Cancer Treatment Group; EORTC, European Organisation for Research and Treatment of Cancer; UCLA, University of California, Los Angeles; NABTC, North American Brain Tumor Consortium; DFCI, Dana Farber Cancer Institute; MSKCC, Memorial Sloan Kettering Cancer Center; NCI, National Cancer Institute; PFS, progression-free survival; OS, overall survival; PFS6; 6-months progression-free survival rate, rand; randomized.

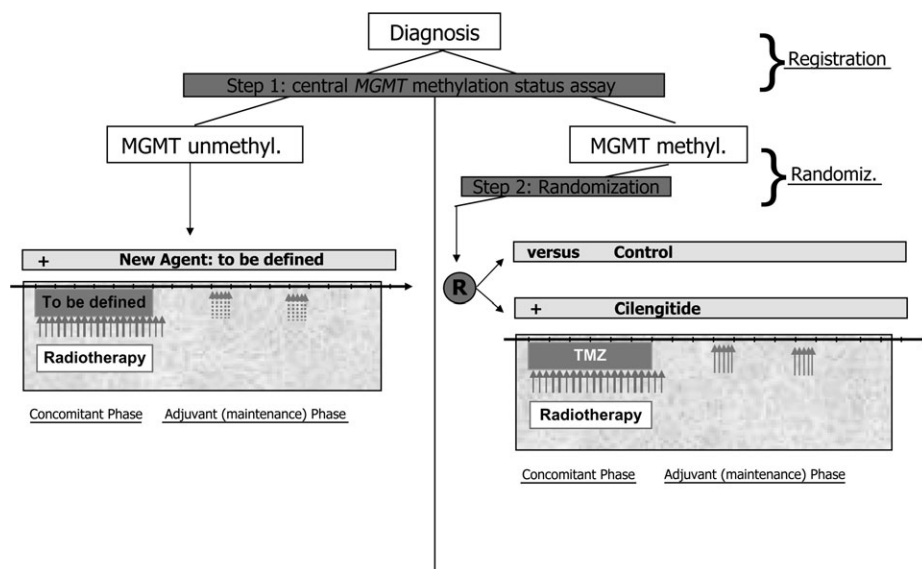


Figure 3. Cilengitide in newly diagnosed glioblastoma. Phase III trial concept with patient selection according to MGMT gene promoter status.

glioma [43–45]. Importantly, this agent seems to work best in conjunction with an active chemotherapy agent and, for this trial, only patients with a methylated *MGMT* gene promoter will be eligible. There remains a great need for improving outcome and developing novel strategies for patients whose tumor is non-methylated.

should antiepileptic therapy be used prophylactically in patients with gliomas?

A significant number of patients with high-grade gliomas develop seizures, especially if the tumor is localized close to the cortex and in the temporal, frontal or parietal lobe. They are typically simple partial, complex partial or secondary generalized seizures. Administration of anticonvulsants in patients with brain tumors is, however, complicated by a number of factors: typical side effects of anticonvulsants, including dermatologic reactions (up to the life threatening Steven–Johnson syndrome in patients undergoing radiotherapy to the brain), myelosuppression and cognitive alteration. Elevated liver function tests are common but usually without clinical relevance. More importantly, enzyme-inducing antiepileptic drugs (EIAED) stimulate cytochrome P450, which may increase the metabolism of a number of chemotherapeutic agents and tyrosine kinase inhibitors. In neuro-oncology this is clinically most relevant for treatments with irinotecan or erlotinib, and to a lesser extent also for nitrosoureas, thiotepa methotrexate and corticosteroids [46]. Conversely, many chemotherapeutic agents alter the metabolism of anticonvulsant agents. Given these potential side effects, administration of anticonvulsants should be reserved for patients who have had a seizure. There is no evidence that prophylactic administration of anticonvulsant medication can prevent the development of a first seizure in patients with brain tumors. Patients that are started on prophylactic

antiepileptics because of brain surgery should be tapering and discontinuing after the first postoperative week [47].

should all patients with gliomas be put on corticosteroids?

Symptomatic management remains a key area of the care of patients with high-grade glioma. Corticosteroids control symptoms related to peritumoral edema and consequently raised intracranial pressure. A number of other effects of steroids may improve quality of life of patients with brain tumor, including improvement in appetite, pain relief, sensation of well being or decreased nausea and vomiting. However, given the potential side effects (including insomnia, visual blurring, glaucoma, edema, gastrointestinal bleeding, bowel perforation, osteoporosis, avascular osteonecrosis, decreased immune function, hyperglycemia, proximal myopathy, mood and behavioral changes, increased appetite), a number of important aspects should be considered when prescribing steroids to maximize quality of life: (i) the lowest effective dose possible of corticosteroids should be used; (ii) regarding peritumoral edema, treat the patient and not the MRI image (clinically asymptomatic edema does not require steroid treatment); (iii) to reduce insomnia linked to steroids, avoid prescribing it in the evening; (iv) because of the risk of adrenal insufficiency following abrupt discontinuation, corticosteroids should be tapered progressively unless steroids have been administered for two weeks or less. Steroid taper occasionally may induce severe myalgia or arthralgia.

what is pseudoprogression?

One consequence of RT is temporary in vessel permeability, which may persist for several weeks after the end of RT (Figure 4). Subsequent imaging may show increasing or new contrast enhancement and a necrotic center that suggests rapid tumor

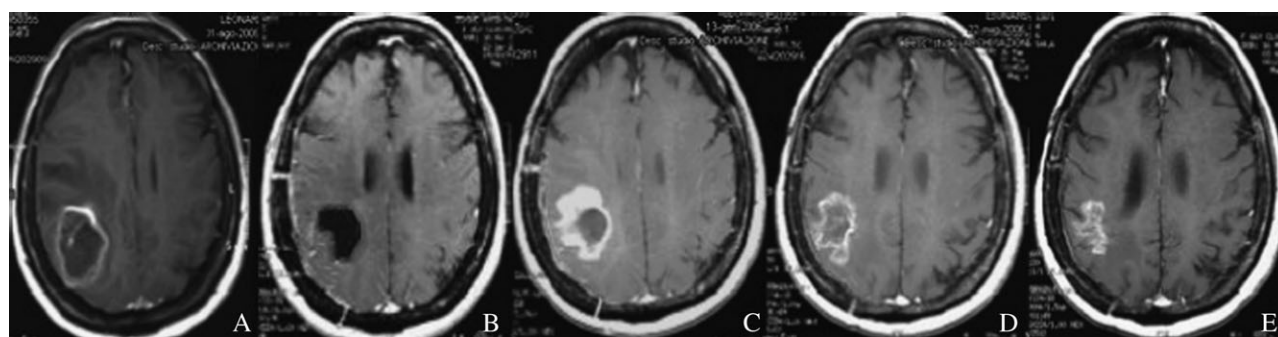


Figure 4. Clinical course of pseudoprogression in a 65-year-old patient with glioblastoma. (A) Presurgical MRI scan. (B) Postsurgical MRI scan. (C) MRI scan performed 1 month after combined TMZ/RT; adjuvant TMZ was continued. (D) Four months later, during administration of maintenance TMZ. (E) Eight months later, during administration of maintenance. Reproduced with permission [48].

progression, however over time these changes may spontaneously resolve without further therapy or evolve into true radiation necrosis. This may reflect a stronger tumor reaction to the treatment (reviewed in detail by Brandes et al. [48] and Brandsma et al. [49]). As the radiation field is larger than the initial tumor size, even changes suggesting tumor growth may be due to the recently completed treatment. This phenomenon, recognized at an increasing frequency, since the introduction of concomitant TMZ/RT, has been termed pseudoprogression, particularly in patients with a methylated *MGMT* gene promoter [40].

Recent reports indicate that pseudoprogression may be observed in 15–30% of the TMZ/RT-treated patients. Of patients whose tumors were radiologically considered as progressive at the end of RT, about half were subsequently identified as false progressions. Conversely, patients in whom pseudoprogression has been noted appear to even have a better outcome. Similarly, true radiation necrosis has been observed more frequently and earlier in the disease course after combined TMZ/RT. In one series, 26 of 51 patients treated with RT and concomitant TMZ had a radiological diagnosis of early disease progression. Fifteen of the presumed progressing tumors were resected and showed necrosis without evidence of tumor in seven (47%) accounting for an incidence of pseudoprogression of >14% [50–52].

Although perfusion MRI, MR spectroscopy and positron emission tomography (PET) may help in distinguishing between active tumor and necrosis, lesions are frequently composed of both tumor and necrotic cells. In addition, some of these techniques lack general availability. For patients demonstrating radiological tumor progression at the first evaluation after the end of radiotherapy, it is recommended to pursue with the planned standard maintenance TMZ therapy, possibly with an increased frequency in radiological surveillance. The knowledge of the *MGMT* methylation status may also guide further patient management, as pseudoprogression appears to be particularly frequent in patients with a methylated *MGMT* promoter—the group of patients who also benefits most from the alkylating agent chemotherapy [7, 40].

disclosures

RS, MJvdB and AA have served on Advisory Boards and Speakers Bureau for Schering-Plough and Merck Serono (RS).

references

- Stupp R, Hegi ME, Gilbert MR, Chakravarti A. Chemoradiotherapy in malignant glioma: Standard of care and future directions. *J Clin Oncol* 2007; 25: 4127–4136.
- Stupp R, Hegi ME, van den Bent MJ et al. Changing paradigms—an update on the multidisciplinary management of malignant glioma. *Oncologist* 2006; 11: 165–180.
- Reardon DA, Rich JN, Friedman HS, Bigner DD. Recent advances in the treatment of malignant astrocytoma. *J Clin Oncol* 2006; 24: 1253–1265.
- Mutter N, Stupp R. Temozolomide: a milestone in neuro-oncology and beyond? *Expert Rev Anticancer Ther* 2006; 6: 1187–1204.
- Stupp R, Mason WP, van den Bent MJ et al. Radiotherapy plus concomitant and adjuvant temozolomide for glioblastoma. *N Engl J Med* 2005; 352: 987–996.
- Jenkins RB, Blair H, Ballman KV et al. A t(1;19) (q10;p10) mediates the combined deletions of 1p and 19q and predicts a better prognosis of patients with oligodendroglioma. *Cancer Res* 2006; 66: 9852–9861.
- Hegi ME, Diserens AC, Gorlia T et al. *MGMT* gene silencing and benefit from temozolomide in glioblastoma. *N Engl J Med* 2005; 352: 997–1003.
- Stupp R, Rüegg C. New drugs and combinations for malignant glioma. *Forum (Genova)* 2003; 13: 61–75.
- Brock CS, Newlands ES, Wedge SR et al. Phase I trial of temozolomide using an extended continuous oral schedule. *Cancer Res* 1998; 58: 4363–4367.
- Stupp R, Dietrich P, Ostermann Kraljevic S et al. Promising survival for patients with newly diagnosed glioblastoma multiforme treated with concomitant radiation plus temozolomide followed by adjuvant temozolomide. *J Clin Oncol* 2002; 20: 1375–1382.
- Dinapoli RP, Brown LD, Arusell RM et al. Phase III comparative evaluation of PCNU and carmustine combined with radiation therapy for high-grade glioma. *J Clin Oncol* 1993; 11: 1316–1321.
- Medical Research Council Brain Tumor Working Party. Randomized trial of procarbazine, lomustine and vincristine in the adjuvant treatment of high-grade astrocytoma: A Medical Research Council trial. *J Clin Oncol* 2001; 19: 509–518.
- Mason WP, Maestro RD, Eisenstat D et al. Canadian recommendations for the treatment of glioblastoma multiforme. *Curr Oncol* 2007; 14: 110–117.
- Zhou Q, Guo P, Wang X et al. Preclinical pharmacokinetic and pharmacodynamic evaluation of metronomic and conventional temozolomide dosing regimens. *J Pharmacol Exp Ther* 2007; 321: 265–275.
- Wick W, Steinbach JP, Kuker WM et al. One week on/one week off: a novel active regimen of temozolomide for recurrent glioblastoma. *Neurology* 2004; 62: 2113–2115.
- Tolcher AW, Gerson SL, Denis L et al. Marked inactivation of O6-alkylguanine-DNA alkyltransferase activity with protracted temozolomide schedules. *Br J Cancer* 2003; 88: 1004–1011.
- Brandes AA, Tosoni A, Cavallo G et al. Temozolomide 3 weeks on and 1 week off as first-line therapy for recurrent glioblastoma: phase II study from gruppo italiano cooperativo di neuro-oncologia (GICNO). *Br J Cancer* 2006; 95: 1155–1160.

18. Athanassiou H, Synodinou M, Maragoudakis E et al. Randomized phase II study of temozolomide and radiotherapy compared with radiotherapy alone in newly diagnosed glioblastoma multiforme. *J Clin Oncol* 2005; 23: 2372–2377.
19. Su YB, Sohn S, Krown SE et al. Selective CD4+ lymphopenia in melanoma patients treated with temozolomide: a toxicity with therapeutic implications. *J Clin Oncol* 2004; 22: 610–616.
20. Ganiere V, Christen G, Bally F et al. Listeria brain abscess, Pneumocystis pneumonia and Kaposi's sarcoma after temozolomide. *Nat Clin Pract Oncol* 2006; 3: 339–343.
21. Mahindra AK, Grossman SA. Pneumocystis carinii pneumonia in HIV negative patients with primary brain tumors. *J Neurooncol* 2003; 63: 263–270.
22. Hughes MA, Kleinberg L, Parisi M, Grossman S. Low CD4 counts and PCP prophylaxis in patients with primary brain tumors treated with steroids and radiation. *Int J Radiat Oncol Biol Phys* 2003; 57: S369–S370.
23. Kovacs JA, Masur H. Prophylaxis against opportunistic infections in patients with human immunodeficiency virus infection. *N Engl J Med* 2000; 342: 1416–1429.
24. Wedge SR, Newlands ES. O(6)-Benzylguanine enhances the sensitivity of a glioma xenograft with low O(6)-allylguanine-DNA alkyltransferase activity to temozolomide and BCNU. *Br J Cancer* 1996; 73: 1049–1052.
25. van Rijn J, Heimans JJ, van den Berg J et al. Survival of human glioma cells treated with various combination of temozolomide and X-rays. *Int J Radiat Oncol Biol Phys* 2000; 47: 779–784.
26. Wick W, Wick A, Schulz JB et al. Prevention of irradiation-induced glioma cell invasion by temozolomide involves caspase 3 activity and cleavage of focal adhesion kinase. *Cancer Res* 2002; 62: 1915–1919.
27. Hirose Y, Berger MS, Pieper RO. p53 effects both the duration of G2/M arrest and the fate of temozolomide-treated human glioblastoma cells. *Cancer Res* 2001; 61: 1957–1963.
28. Yung WK, Prados MD, Yaya-Tur R et al. Multicenter phase II trial of temozolomide in patients with anaplastic astrocytoma or anaplastic oligoastrocytoma at first relapse. Temodal Brain Tumor Group. *J Clin Oncol* 1999; 17: 2762–2771.
29. Yung WK, Albright RE, Olson J et al. A phase II study of temozolomide vs. procarbazine in patients with glioblastoma multiforme at first relapse. *Br J Cancer* 2000; 83: 588–593.
30. Brada M, Hoang-Xuang K, Rampling R et al. Multicenter phase II trial of temozolomide in patients with glioblastoma multiforme at first relapse. *Ann Oncol* 2001; 12: 259–266.
31. van den Bent MJ, Carpentier AF, Brandes AA et al. Adjuvant Procarbazine, Lomustine, and Vincristine Improves Progression-Free Survival but Not Overall Survival in Newly Diagnosed Anaplastic Oligodendrogliomas and Oligoastrocytomas: A Randomized European Organisation for Research and Treatment of Cancer Phase III Trial. *J Clin Oncol* 2006; 24: 2715–2722.
32. Cairncross G, Berkey B, Shaw E et al. Phase III Trial of Chemotherapy Plus Radiotherapy Compared With Radiotherapy Alone for Pure and Mixed Anaplastic Oligodendroglioma: Intergroup Radiation Therapy Oncology Group Trial 9402. *J Clin Oncol* 2006; 24: 2707–2714.
33. Jaeckle KA, Eyre HJ, Townsend JJ et al. Correlation of tumor O6 methylguanine-DNA methyltransferase levels with survival of malignant astrocytoma patients treated with bis-chloroethylnitrosourea: a Southwest Oncology Group study. *J Clin Oncol* 1998; 16: 3310–3315.
34. Friedman H, McLendon R, Kerby T et al. DNA mismatch repair and O⁶-alkylguanine-DNA alkyltransferase analysis and response to temodal in newly diagnosed malignant glioma. *J Clin Oncol* 1998; 16: 3851–3857.
35. Esteller M, Garcia-Foncillas J, Andion E et al. Inactivation of the DNA-repair gene MGMT and the clinical response of gliomas to alkylating agents. *N Engl J Med* 2000; 343: 1350–1354.
36. Hegi ME, Diserens AC, Godard S et al. Clinical trial substantiates the predictive value of O-6-methylguanine-DNA methyltransferase promoter methylation in glioblastoma patients treated with temozolomide. *Clin Cancer Res* 2004; 10: 1871–1874.
37. Lefebvre P, Laval F. Enhancement of O6-methylguanine-DNA-methyltransferase activity induced by various treatments in mammalian cells. *Cancer Res* 1986; 46: 5701–5705.
38. Stupp R, Hegi ME. Methyl-guanine methyltransferase testing in glioblastoma: when and how? *J Clin Oncol* 2007; 25: 1459–1460 (and related correspondence: *J Clin Oncol* 2007; 25: 3550; author reply 3550–3551).
39. Preusser M, Janzer R, Felsberg J et al. Anti-MGMT immunohistochemistry in glioblastoma multiforme: observer variability and lack of association with patient survival impede its use as clinical biomarker. A translational research project of the European Organization for Research and Treatment of Cancer Brain Tumour Group. *Brain Pathol* 2008; In press.
40. Brandes A, Franceschi E, Tosoni A et al. MGMT promoter methylation status can predict the incidence and outcome of pseudoprogression after concomitant radiochemotherapy in newly diagnosed glioblastoma patients. *J Clin Oncol* 2008; 26: 2192–2197.
41. Griffin CA, Burger P, Morsberger L et al. Identification of der(1;19) (q10;p10) in five oligodendrogliomas suggests mechanism of concurrent 1p and 19q loss. *J Neuropathol Exp Neurol* 2006; 65: 988–994.
42. Ino Y, Betensky RA, Zlatescu MC et al. Molecular subtypes of anaplastic oligodendroglioma: implications for patient management at diagnosis. *Clin Cancer Res* 2001; 7: 839–845.
43. Nabors B, Mikkelsen T, Rosenfeld S et al. A phase I and correlative biology study of cilengitide in patients with recurrent malignant glioma. *J Clin Oncol* 2007; 25: 1651–1657.
44. Stupp R, Goldbrunner R, Neyns B et al. Phase I/IIa trial of cilengitide (EMD121974) and temozolomide with concomitant radiotherapy, followed by temozolomide and cilengitide maintenance therapy in patients with newly diagnosed glioblastoma. *J Clin Oncol* 2007 ASCO Annual Meeting Proceedings Part 1 2007; 25 (Suppl): 75s (Abstr 2000).
45. Stupp R, Rugg C. Integrin inhibitors reaching the clinic. *J Clin Oncol* 2007; 25: 1637–1638.
46. Vecht CJ, Wagner GL, Wilms EB. Interactions between antiepileptic and chemotherapeutic drugs. *Lancet Neurol* 2003; 2: 404–409.
47. Glantz MJ, Cole BF, Forsyth PA et al. Practice parameter: anticonvulsant prophylaxis in patients with newly diagnosed brain tumors. Report of the Quality Standards Subcommittee of the American Academy of Neurology. *Neurology* 2000; 54: 1886–1893.
48. Brandes A, Tosoni A, Spagnoli F et al. Disease progression or pseudoprogression after concomitant radiochemotherapy treatment: Pitfalls in neurooncology. *Neuro-Oncology* 2008; 10: in press.
49. Brandsma D, Stalpers L, Taal W et al. Clinical features, mechanisms, and management of pseudoprogression in malignant gliomas. *Lancet Oncol* 2008; 9: 453–461.
50. Chamberlain MC, Glantz MJ, Chalmers L et al. Early necrosis following concurrent Temodar and radiotherapy in patients with glioblastoma. *J Neurooncol* 2007; 82: 81–83.
51. de Wit MC, de Bruin HG, Eijkenboom W et al. Immediate post-radiotherapy changes in malignant glioma can mimic tumor progression. *Neurology* 2004; 63: 535–537.
52. Taal W, Brandsma D, de Bruin HG et al. The incidence of pseudo-progression in a cohort of malignant glioma patients treated with chemo-radiation with temozolomide. *ASCO Meeting Abstracts* 2007; 25: 2009.
53. Vera K, Djafari L, Faivre S et al. Dose-dense regimen of temozolomide given every other week in patients with primary central nervous system tumors. *Ann Oncol* 2004; 15: 161–171.