

corresponding to the fourth aortic arch. The reported anomaly may be attributed to the lack of caudal migration of the fourth arch with an interruption between the right subclavian and vertebral arteries, resulting in a left cervical aorta with a right vertebral artery arising from the aortic arch and assimilated to a vertebral arteria lusoria.

The present case report is an incidental asymptomatic finding. Aortic arch and great vessel anomalies are rare and mostly asymptomatic, but it remains important to know them, recognize them, and identify them, particularly before vascular surgery of the chest and neck and Willis polygon angiography, and because of the associated congenital cardiovascular diseases. Modern MDCT, with reconstructed and reformatted images, affords an excellent study of the supraaortic arteries and can be used preoperatively to guide endovascular and surgical treatment.^{15,16}

ACKNOWLEDGMENTS

Financial/nonfinancial disclosures: The authors have reported to *CHEST* that no potential conflicts of interest exist with any companies/organizations whose products or services may be discussed in this article.

REFERENCES

1. Edwards JE. Anomalies of the derivatives of the aortic arch system. *Med Clin North Am*. 1948;32:925-949.
2. El Hajjam M, Beigelman C, Pelage J-P, et al. Imagerie de l'aorte thoracique. In: Jeanbourquin, D, ed. *Imagerie Thoracique de l'Adulte*. 1st ed. Paris, France: Elsevier; 2003:597-628.
3. Predey TA, McDonald V, Demos TC, Moncada R. CT of congenital anomalies of the aortic arch. *Semin Roentgenol*. 1989;24(2):96-113.
4. Soler R, Rodríguez E, Requejo I, Fernández R, Raposo I. Magnetic resonance imaging of congenital abnormalities of the thoracic aorta. *Eur Radiol*. 1998;8(4):540-546.
5. De Luca L, Bergman J, Tytgat G. EUS imaging of the arteria lusoria: case series and review. *Gastrointest Endosc*. 2000;52:670-673.
6. Shennib H, Diethrich EB. Novel approaches for the treatment of the aberrant right subclavian artery and its aneurysms. *J Vasc Surg*. 2008;47(5):1066-1070.
7. Shuford WH, Sybers RG. *The Aortic Arch and Its Malformations*. Springfield, IL: Charles C Thomas; 1974:12-131.
8. Knight L, Edwards JE. Right aortic arch. Types and associated cardiac anomalies. *Circulation*. 1974;50(5):1047-1051.
9. Schlesinger AE, Krishnamurthy R, Sena ML, et al. Incomplete double aortic arch with atresia of the distal left arch distinctive imaging appearance. *AJR Am J Roentgenol*. 2005;184(5):1634-1639.
10. Fadel E, Chapelier AR, Cerrina J, Macchiarini P, Darteville PG. Vascular ring causing symptomatic tracheal compression in adulthood. *Ann Thorac Surg*. 1995;60(5):1411-1413.
11. Nicolosi AC, Cambria RA. Late development of esophageal compression from a vascular ring. *Ann Thorac Surg*. 1995;60(5):1413-1415.
12. Moes CAF, Freedom RM. Aortic arch interruption with truncus arteriosus or aorticopulmonary septal defect. *AJR Am J Roentgenol*. 1980;135(5):1011-1016.
13. Dillman JR, Yarram SG, D'Amico AR, Hernandez RJ. Interrupted aortic arch: spectrum of MRI findings. *AJR Am J Roentgenol*. 2008;190(6):1467-1474.
14. Beigelman C, Mourey-Gerosa I, Gamsu G, Grenier P. New morphologic approach to the classification of anomalies of the aortic arch. *Eur Radiol*. 1995;5(4):435-442.
15. Oh E, Quint DJ, Gross BH. Identification of vertebral arteries on CT of the chest. *Br J Radiol*. 2001;74(880):328-330.
16. Ka-Tak W, Lam W, Yu S. MDCT of an aberrant right subclavian artery and of bilateral vertebral arteries with anomalous origins. *AJR Am J Roentgenol*. 2007;188(3):W274-275.

Catheter Entrapment in a Pulmonary Vein

A Unique Complication of Pulmonary Vein Isolation

Pierre Monney, MD; Patrizio Pascale, MD; Martin Fromer, MD; and Etienne Pruvot, MD

Ablation strategies for the treatment of atrial fibrillation (AF) are associated with several potential complications. During electro-anatomic mapping of the left atrium (LA) before ablation, the ablation catheter was entrapped in the right inferior pulmonary vein (RIPV). After multiple unsuccessful gentle tractions, stronger maneuvers with rotation of the catheter slowly allowed its retrieval. Examination of the catheter showed a thin, translucent membrane covering its tip, suggesting complete stripping of a vein branch. Occlusion of the superior branch of the RIPV was confirmed by LA angiogram. During the following days, no pericardial effusion was noted, but the patient complained of light chest pain and mild hemoptysis, spontaneously resolving within 48 h. This case shows that catheter entrapment and mechanical disruption of a PV branch can be a rare potential complication of AF ablation. In this case, the outcome was spontaneously favorable and symptoms only included transient mild hemoptysis. *CHEST* 2010; 138(2):422-425

Abbreviations: AF = atrial fibrillation; LA = left atrium; PV = pulmonary vein; PVI = pulmonary vein isolation; RIPV = right inferior pulmonary vein; TEE = transesophageal echocardiography

Catheter ablation of atrial fibrillation (AF) by pulmonary vein isolation (PVI) is a complex procedure with an estimated 12-month success rate of up to 89%.¹ It also bears a significant risk of complications, ranging from 3.9% to 5.9%.^{2,3} We report a case of mechanical disruption of a pulmonary vein (PV) branch secondary to the entrapment of the ablation catheter during PVI.

Manuscript received November 9, 2009; revision accepted January 29, 2010.

Affiliations: From the Service de Cardiologie, Centre Hospitalier Universitaire Vaudois, Lausanne, Switzerland.

Correspondence to: Etienne Pruvot, MD, Service de Cardiologie, Centre Hospitalier Universitaire Vaudois (CHUV), CH-1011 Lausanne, Switzerland; e-mail: etienne.pruvot@chuv.ch

© 2010 American College of Chest Physicians. Reproduction of this article is prohibited without written permission from the American College of Chest Physicians (www.chestpubs.org/site/misc/reprints.xhtml).

DOI: 10.1378/chest.09-2675

CASE REPORT

A 60-year-old woman with drug refractory paroxysmal AF was referred for PVI. Because of a previous failed attempt, the puncture of the interatrial septum was performed under general anesthesia with transesophageal echocardiography (TEE) guidance. IV heparin anticoagulation was given to maintain an activated clotting time of between 250 and 350 s. An irrigated ablation catheter (3.5-mm-tip Navistar Thermocool; Biosense Webster; Diamond Bar, CA) was used for three-dimensional electroanatomic mapping (Carto XP; Biosense Webster). The catheter was deployed 2 to 4 cm into each PV and slowly pulled back to add separate PV geometries to the left atrium (LA) body. The right inferior PV (RIPV) was the last to be mapped; following the acquisition of a set of points, the catheter could not be maneuvered anymore. Figure 1A shows the position of the catheter in the RIPV. Gentle repetitive tractions were applied, which only produced a downward shift of the heart silhouette on fluoroscopy. The transeptal guiding sheath was advanced to provide additional support and optimize the vector of traction, and catheter irrigation flow was increased and IV nitrates were infused to try to dilate the distal PV, but all these maneuvers failed to free the catheter. TEE showed no pericardial effusion. A cardiothoracic surgical opinion was obtained. Only stronger tractions and rotations eventually allowed us to retrieve the catheter, but unusual resistance was felt during this maneuver. Visual inspection showed a thin, translucent membrane covering the catheter tip, suggesting mechanical disruption of a vein branch (Fig 2A). Figure 1B shows the LA angiogram after catheter removal. The main trunk of the RIPV remained patent with no contrast extravasations, but a tapered narrowing of its superior branch suggesting vascular wall tearing was observed. This superior branch was clearly seen on the preoperative MRI, as shown in Figure 2B, and its diameter was approximately the size of the ablation catheter. Because the patient remained stable, the procedure was resumed and was followed by

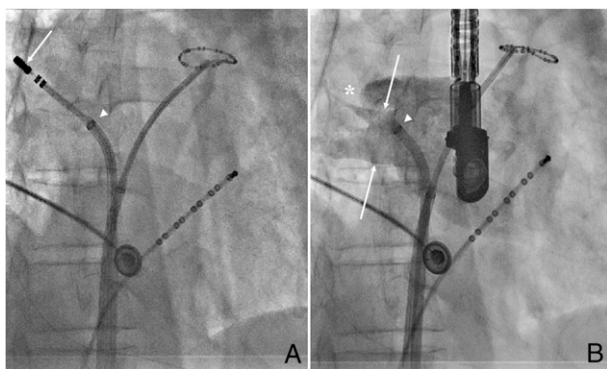


FIGURE 1. Right anterior oblique radiographic views of the left atrium (LA). The mapping catheter is inserted deep in the right inferior pulmonary vein (RIPV) (thin arrow). The tip of the transeptal sheath is indicated by the arrowhead (A). After retrieval of the catheter, an LA angiogram shows that the RIPV (two thin arrows) is patent but its superior branch is proximally occluded. (Asterisk shows the tapered narrowing of the vein branch). The arrowhead indicates the tip of the transeptal sheath (B).

a successful PVI. Repeat TEE procedures revealed no pericardial effusion. After recovery from general anesthesia, the patient reported continuous mild chest oppression and blood-tinged sputum. ECG, transthoracic echocardiographic, and chest radiographic results were normal, and all symptoms spontaneously resolved within 48 h. The patient was discharged 4 days after the procedure with low-molecular-weight heparin anticoagulation for a week before starting warfarin. A follow-up MRI scan, performed 2 months after the procedure, showed patency of the superior branch of the RIPV (data not shown). The disruption of the vein was thus transient, suggesting stripping of the internal layers of the vessel rather than complete avulsion.

DISCUSSION

In the two largest published registries of AF catheter ablation,^{2,3} the total incidence of complications ranges between 3.9% and 5.9%, including mainly access site vascular damages, pericardial effusion, and embolic events. Direct mechanical lesions of heart structures have rarely been reported.

A handful of case reports described entrapment of circular mapping catheters in the mitral valve apparatus.⁴ Mansour et al⁵ reported the entrapment of a circular mapping catheter in the left superior PV that was successfully released with the use of the ablation catheter deflectable tip to change the vector of traction. In another case by Echahidi et al,⁶ an RIPV laceration with left atrial wall hematoma and hemodynamic instability required immediate surgery.

Our case shows that catheter entrapment with vascular damage is a potential complication of PVI procedures. It involved a conventional cooled-tip ablation catheter and may have been the result of the deep intubation of a small RIPV branch with consecutive spasm or dissection of the vessel. Direct trauma could have occurred since the translucent membrane covers the distal dipole of the catheter and stops at the junction between the proximal pole of the distal dipole and the synthetic shaft of the catheter. However, we did not observe any unusual rough edge at the tip of the catheter. Also, previous reports suggested that dissection of the septal wall of the RIPV during transeptal puncture might play a role in the initiation of RIPV injury. In the present case, the transeptal puncture was performed in the middle of the fossa ovalis under TEE guidance, which showed no sign of interatrial septum dissection (data not shown).

We tried various unsuccessful maneuvers to free the catheter tip. One alternative would have been to apply radio frequency energy, but because of some concerns about potential deleterious effect to the surrounding pulmonary tissue, this option was not considered. Although surgical removal of the catheter may have been an initial option, a conservative approach was decided in accordance with our cardiothoracic surgeons. After the diagnosis of PV damage was determined, the decision to resume the PVI procedure may be criticized. The absence of pericardial effusion, pulmonary hemorrhage, and hemodynamic instability; the possibility for continuous

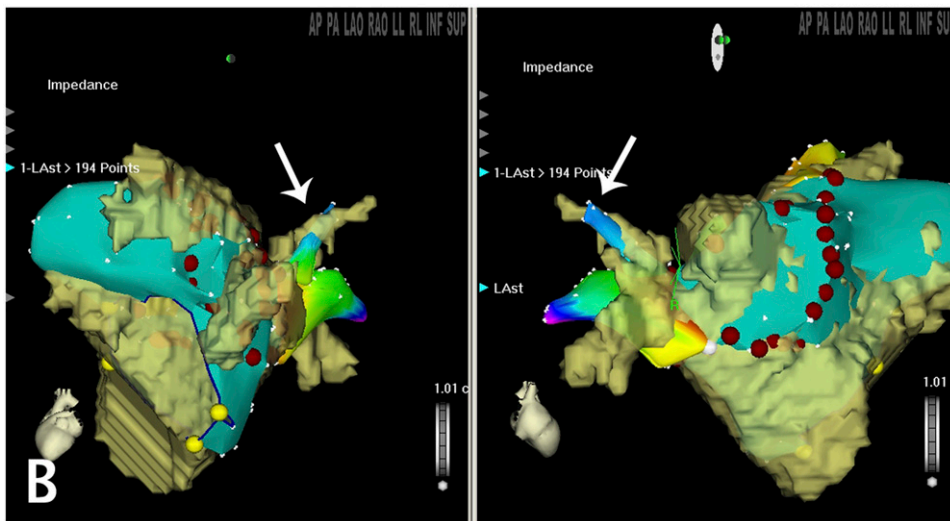


FIGURE 2. Close examination of the mapping catheter after removal from the LA. The tip of the catheter is covered by a thin, translucent membrane hiding the distal pole, suggesting that the wall of the superior branch of the RIPV has been stripped off (A). Left lateral and right anterior oblique (B) views showing the merging of MRI-segmented structures with reconstructed LA and RIPV structures. The white arrows point at the superior branch of the RIPV that was mechanically disrupted after deep intubation during reconstruction of the LA anatomy. See Figure 1 legend for expansion of abbreviations.

TEE monitoring; and the presence of a formal surgical backup team were the reasons to pursue the procedure.

Interestingly, mild hemoptysis but no pericardial effusion occurred after PV damage. PVs are covered by a pericardial sleeve not exceeding 10 to 15 mm along the proximal vein; pericardial effusion may thus be observed only for proximal PV lesions. The presence of hemoptysis indicates that bleeding occurred into the pulmonary parenchyma. This is in accordance with the evidence of deep intubation and distal damage of the vein, and with a recent anatomic study demonstrating that the pericardial sleeve over the RIPV (4.5 mm) is significantly shorter than that of the other three PVs (range 9.2-13.7 mm).⁷

In conclusion, mechanical disruption of a PV branch is a newly described and rare complication of catheter ablation

of AF. A conservative management appears as an acceptable first option, providing a formal cardiothoracic surgical backup team is available onsite.

ACKNOWLEDGMENTS

Financial/nonfinancial disclosures: The authors have reported to *CHEST* that no potential conflicts of interest exist with any companies/organizations whose products or services may be discussed in this article.

REFERENCES

1. Jaïs P, Cauchemez B, Macle L, et al. Catheter ablation versus antiarrhythmic drugs for atrial fibrillation: the A4 study. *Circulation*. 2008;118(24):2498-2505.
2. Bertaglia E, Zoppo F, Tondo C, et al. Early complications of pulmonary vein catheter ablation for atrial fibrillation: a

- multicenter prospective registry on procedural safety. *Heart Rhythm*. 2007;4(10):1265-1271.
3. Cappato R, Calkins H, Chen SA, et al. Worldwide survey on the methods, efficacy, and safety of catheter ablation for human atrial fibrillation. *Circulation*. 2005;111(9):1100-1105.
 4. Je HG, Kim JW, Jung SH, Lee JW. Minimally invasive surgical release of entrapped mapping catheter in the mitral valve. *Circ J*. 2008;72(8):1378-1380.
 5. Mansour M, Mela T, Ruskin J, Keane D. Successful release of entrapped circumferential mapping catheters in patients undergoing pulmonary vein isolation for atrial fibrillation. *Heart Rhythm*. 2004;1(5):558-561.
 6. Echahidi N, Philippon F, O'Hara G, Champagne J. Life-threatening left atrial wall hematoma secondary to a pulmonary vein laceration: an unusual complication of catheter ablation for atrial fibrillation. *J Cardiovasc Electrophysiol*. 2008;19(5):556-558.
 7. Chaffanjon P, Brichon PY, Faure C, Favre JJ. Pericardial reflection around the venous aspect of the heart. *Surg Radiol Anat*. 1997;19(1):17-21.