

## OBSERVATION

# Marked Hemiatrophy in Carriers of Duchenne Muscular Dystrophy

Sanjeev Rajakulendran, MRCP; Thierry Kuntzer, MD; Murielle Dunand, MD; Shu C. Yau, PhD; Emma J. Ashton, PhD; Helen Storey, PhD; Joanna McCauley, BSc; Stephen Abbs, PhD; Francine Thonney, PhD; France Leturcq, PhD; Johannes A. Lohrinus, MD; Tarek Yousry, FRCP; Simon Farmer, FRCP; Janice L. Holton, PhD; Michael G. Hanna, FRCP

**Objective:** To describe the clinical and molecular genetic findings in 2 carriers of Duchenne muscular dystrophy (DMD) who exhibited marked hemiatrophy. Duchenne muscular dystrophy is an X-linked disorder in which affected male patients harbor mutations in the dystrophin gene. Female patients with heterozygous mutations may be manifesting carriers.

**Design:** Case study.

**Setting:** Neurology clinic.

**Patients:** Two manifesting carriers of DMD.

**Interventions:** Clinical and radiologic examinations along with histologic and molecular investigations.

**Results:** Both patients had marked right-sided hemiatrophy on examination with radiologic evidence of muscle atrophy and fatty replacement on the affected side. In each case, histologic analysis revealed a reduction in dystrophin staining on the right side. Genetic analysis of the dystrophin gene revealed a tandem exonic duplication in patient 1 and a multiexonic deletion in patient 2 with no further point mutations identified on the other chromosome.

**Conclusions:** Marked hemiatrophy can occur in DMD manifesting carriers. This is likely to result from a combination of skewed X-inactivation and somatic mosaicism.

*Arch Neurol.* 2010;67(4):497-500

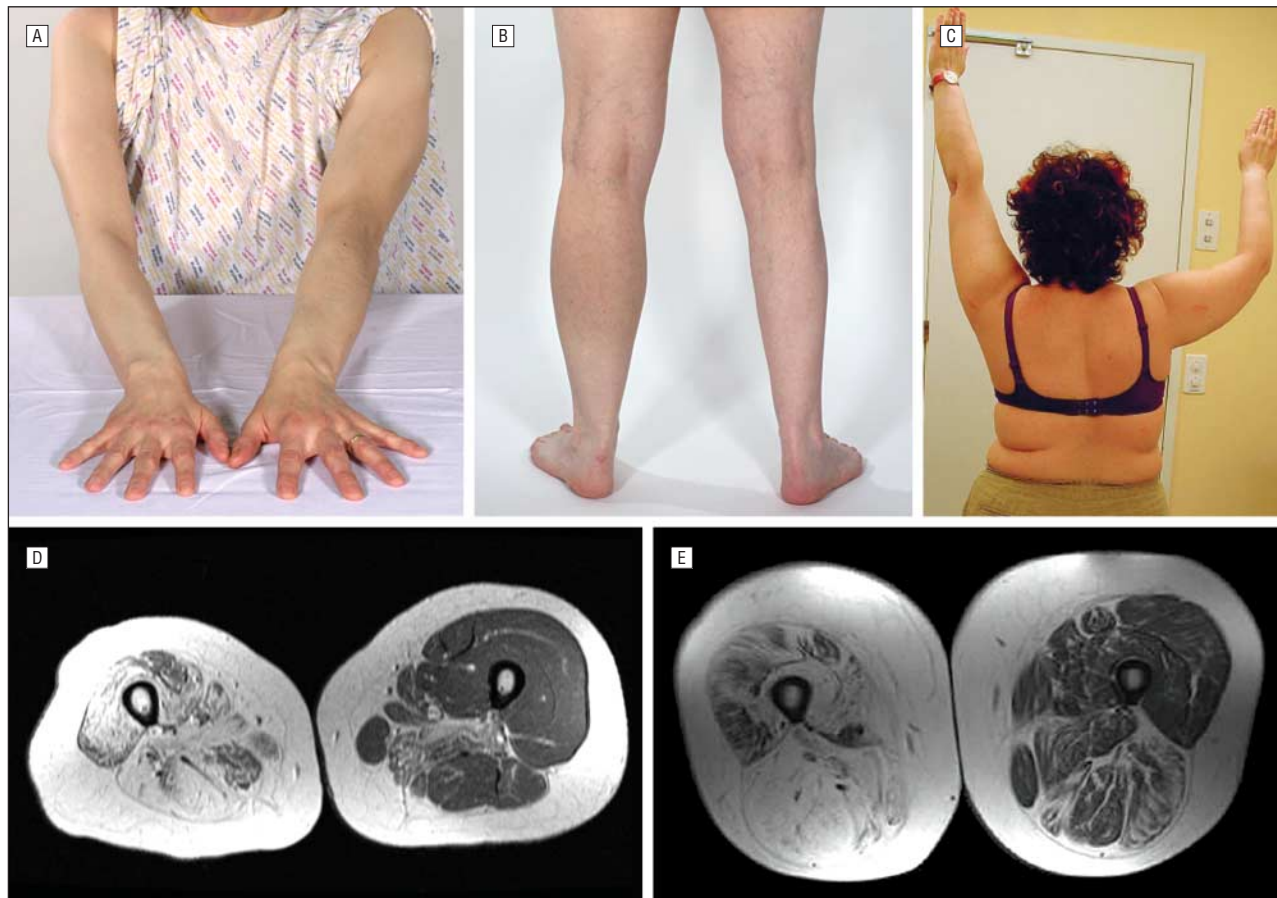
**Author Affiliations:** MRC (Medical Research Council) Centre for Neuromuscular Diseases, UCL (University College London) Institute of Neurology, and National Hospital for Neurology and Neurosurgery (Drs Rajakulendran, Yousry, Farmer, Holton, and Hanna), London, England; Nerve-Muscle Unit, Neurology Service (Drs Kuntzer and Dunand), and Division of Medical Genetics (Dr Thonney), Centre Hospitalier Universitaire Vaudois and University of Lausanne, Lausanne, Switzerland; DNA Laboratory, GSTS (Guy's and St Thomas') Pathology, Guy's Hospital, London (Drs Yau, Ashton, Storey, and Abbs and Ms McCauley); Laboratoire de Biochimie et Génétique Moléculaire, Hôpital Cochin, Paris, France (Dr Leturcq); and Department of Pathology, Geneva University Hospital, Geneva, Switzerland (Dr Lohrinus).

**M**ANIFESTING CARRIERS OF Duchenne muscular dystrophy (DMD) are heterozygous symptomatic female patients who generally present with a milder phenotype than affected male patients. The phenotypic spectrum of the manifesting carrier is broad, encompassing cramps, myalgia, muscle weakness, dilated cardiomyopathy, and, rarely, progressive proximal weakness.<sup>1</sup> This report describes 2 manifesting carriers of DMD who presented with striking right-sided asymmetrical hemiatrophy in the presence of normal left-sided musculature. We present clinical, genetic, radiologic, and histologic data and suggest that a combination of skewed X-inactivation and somatic mosaicism are the likely underlying mechanisms accounting for this unusual presentation.

Consent was obtained from both patients. Genomic DNA was extracted from leukocytes via a Chemagic Magnetic Separation Module I using the 3-mL Chemagic DNA blood kit special (chemagen Biopolymer-Technologie AG, Baesweiler, Germany) or via a Nucleon BACC3 kit (GE

Healthcare, Piscataway, New Jersey). Multiplex ligation-dependent probe amplification (MLPA) analysis using probe sets P034 and P035 (MRC-Holland, Amsterdam, the Netherlands) was performed according to the manufacturer's instructions. Muscle RNA was extracted from frozen muscle biopsy specimens using the RNeasy Fibrous Tissue Mini kit (Qiagen, Düsseldorf, Germany). Muscle DNA was extracted from frozen muscle biopsy specimens using organic extraction. To amplify the exon 10-11 duplication in patient 1, reverse transcriptase-polymerase chain reaction (RT-PCR) amplification was performed, as previously described.<sup>2</sup>

Open muscle biopsy specimens were frozen in 2-methyl-butane or isopentane, cooled by liquid nitrogen, and stored at -80°C. Ten-micrometer-thick sections were stained with hematoxylin-eosin, periodic acid-Schiff reagent, oil red O, Congo red, and a modified Gomori stain. Enzyme histochemical analysis with NADH (nicotinamide adenine dinucleotide)-tetrazolium-reductase, and adenosine triphosphatase at pH 4.2 and 4.6 was performed according to standard techniques. For immunohistochemical analysis, the



**Figure 1.** Wasting and atrophy in the subject patients. A and B, Wasting of the right arm and right leg in patient 1. C, Wasting and weakness of the right arm in patient 2. D and E, Magnetic resonance images of patients 1 and 2, respectively, demonstrating atrophy of the thigh muscles on the right with fatty replacement.

following antiserum solutions were used: ubiquitin (rabbit polyclonal antibody, code No. Z 0458, 1:200; Dako Corp, Carpinteria, Calif.); spectrin (mouse monoclonal antibody [mAb], clone SPEC1, 1:200 Novocastra Laboratories Ltd, Newcastle upon Tyne, England); dystrophin I, II, and III (mouse mAb, clones DYS1, DYS2, and DYS3, 1:20; Novocastra); and utrophin I and II (mouse mAb, clones DRP1/12B6 and DRP2/20C5, 1:20; Novocastra).

## REPORT OF CASES

### CASE 1

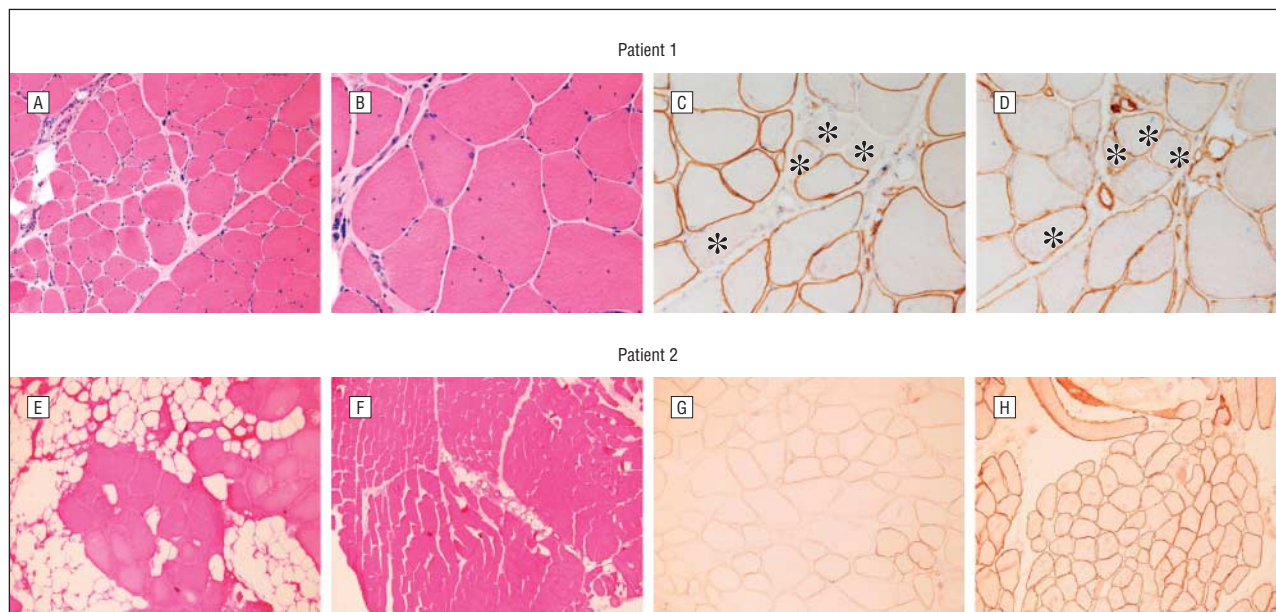
Patient 1 presented at age 50 years with an 18-year history of progressive wasting and weakness in her right arm and right leg. There was no family history of muscular dystrophy. The musculature in the left arm and leg was unaffected as were her facial muscles. She denied any cardiac symptoms.

On examination we found marked wasting of her right arm and leg with weakness proximally (Medical Research Council [MRC] grade 3/5) more than distally (**Figure 1** A and B). The biceps, supinator, knee, and ankle reflexes on the right were absent but present on the left side. The left arm and leg were entirely normal on examination. The creatinine kinase level was elevated (1448 U/L; reference range, <200 U/L). (To convert creatinine kinase to microkatal

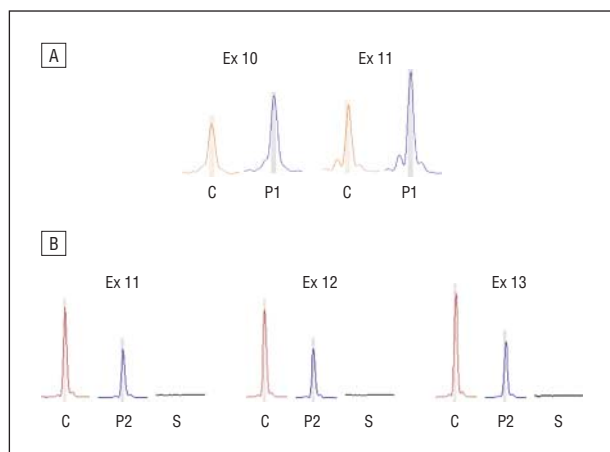
per liter, multiply by 0.0167.) An echocardiogram showed left ventricular dilatation. A magnetic resonance imaging (MRI) scan of her legs revealed clear right-sided muscle atrophy with fatty replacement compared with the left, which was only slightly infiltrated in the posterior compartment (**Figure 1** D).

Histologic examination of the affected right quadriceps muscle demonstrated reduced staining for dystrophin in scattered fibers (**Figure 2** A-D). DNA sequencing of the 79 coding exons of the *DMD* gene (OMIM 300377) did not identify any point mutations, but MLPA analysis revealed a heterozygous duplication of exons 10 and 11, which is predicted to cause a frame shift (**Figure 3** A). X-inactivation studies from genomic DNA, according to the previously published method,<sup>3</sup> revealed a ratio of 0.88, a result suggestive of nonrandom X-inactivation. However, clearly the inactivation pattern, at least in the lymphocytes, was not completely skewed.

To investigate the effect of this duplication on the patient's dystrophin in muscle messenger RNA (mRNA), RT-PCR analysis was performed using primers located in the coding sequence of exons 9 and 13 of the *DMD* gene and with primers designed to amplify across the duplication breakpoint at the RNA level.<sup>4</sup> In both cases, no mutant RT-PCR products were detected. Sequence analysis of the patient's dystrophin complementary DNA tran-



**Figure 2.** Histologic studies of the subject patients. A and B, Right quadriceps biopsy specimens of frozen muscle from patient 1 show increased variation in fiber size, a mild increase in endomysial connective tissue, and several fibers containing internal nuclei. C, Reduced staining for dystrophin (asterisks) in a small proportion of fibers from patient 1. D, The same fibers demonstrated increased expression of utrophin (asterisks). E and F, Histologic specimens of deltoid muscle from patient 2 demonstrate a dystrophic pattern on the right (E) compared with the left (F). G and H, Patient 2 dystrophin immunostains of the right deltoid muscle (G) show a mosaic expression of dystrophin-positive fibers and dystrophin-negative fibers, whereas the left-sided muscle sections (H) reveal only sporadic dystrophin-negative fibers.



**Figure 3.** Multiplex ligation-dependent probe amplification traces showing peak heights. The red peak is a control peak of known copy number with which the patient's DNA (blue peak) is compared. A, Patient 1 (P1) shows a 50% increase in peak height for exons 10 and 11 compared with the control (C), consistent with a tandem duplication. B, Patient 2 (P2) has a 50% reduction in peak height for exons 11, 12, and 13 compared with the control, indicating that she has only 1 copy of each of these exons. Her affected son (S) had no copies of exons 11 through 13.

script showed that she was heterozygous for the exon 53 coding sequencing polymorphism r.7728u→c, which had been previously detected in her genomic DNA.

## CASE 2

Patient 2 presented at age 35 years with progressive asymmetrical wasting and weakness of her right arm and leg with exertion-dependent myalgia and cramps but with no cardiac symptoms. Examination revealed wasting and weakness of her right arm (Figure 1C) and leg. Her left side was

unaffected. Deep tendon reflexes were absent on the right side and normal on the left. The creatinine kinase level was elevated at 958 U/L. An MRI scan of her thighs revealed fatty degeneration of the muscles on the right, while the left side showed slight but clear fatty infiltration of muscles from the posterior compartment (Figure 1E). Her echocardiogram showed no abnormalities.

Immunostaining of affected deltoid muscle from the right demonstrated a reduced expression of dystrophin compared with the clinically unaffected left side (Figures 2E-H); this was further confirmed by Western blot analysis, which showed a profound reduction in dystrophin expression in the right deltoid. Patient 2 was the mother of a boy diagnosed with DMD who was found to have a deletion of exons 3 through 13 of the *DMD* gene (Figure 3B). Although, this mutation is predicted to maintain the translation reading frame, it is likely that it has a severe disruptive effect on the function of the F-actin domain of the affected son's truncated dystrophin protein, explaining his DMD phenotype. Genetic analysis of the *DMD* gene of patient 2 showed that she was a carrier of this mutation (Figure 3B). X-inactivation studies on lymphocyte DNA revealed no difference in methylation between the 2 X chromosomes. Cytogenetic analysis revealed a normal karyotype, thus excluding Turner syndrome as a possible cause.

## COMMENT

The identification of a pathogenic duplication of *DMD* exons 10 and 11 in patient 1 and a deletion of exons 3 through 13 in patient 2 are consistent with both patients being manifesting carriers of DMD. Immunohistochemical studies on affected muscle further sup-



ported their carrier status: the biopsy specimens from both patients clearly demonstrated a reduction in dystrophin staining with compensatory upregulation of utrophin.<sup>4</sup> Patient 1 was also found to be heterozygous for a synonymous polymorphism in the coding sequence of exon 53 (c.7728t→c and r.7728u→c) at both the genomic DNA and RNA levels, indicating that she expressed dystrophin mRNA from both of her X chromosomes. A sensitive RT-PCR assay was used to amplify the mutant mRNA transcript from affected muscle, but we were nonetheless unable to detect the presence of the duplication. This suggests either that the mutant mRNA was not present at a sufficient level for detection, or that the mutation is more complex than a straightforward tandem duplication, in which case our RT-PCR assay would not be able to detect it.

The striking clinical feature in both patients was marked asymmetrical wasting. Although mild asymmetrical weakness is a common occurrence in DMD carriers, marked hemiatrophy is very unusual. In addition, patient 1 had a dilated cardiomyopathy, which is described in approximately 8% of manifesting carriers.<sup>1</sup> The MRI studies correlated with the marked asymmetrical phenotype but also indicated subclinical involvement of left-sided muscles.

The manifestation of X-linked recessive disorders in female patients is generally considered to arise from skewed X-inactivation, a process that is normally random and ensures dosage equalization of X-linked genes between XX female and XY male subjects.<sup>5</sup> Since no second DMD mutation was detected in the other chromosome in either patient, their phenotype is predicted to arise from nonrandom or skewed X-inactivation resulting in overexpression of the mutant X chromosome. Although X-inactivation ratios in lymphocyte DNA were normal in case 2 and suggestive of skewing in case 1, the pattern is likely to be tissue specific; hence, the result does not exclude higher levels of skewed X-inactivation in the affected muscle tissue.<sup>6</sup> It is possible that the higher 0.88 ratio seen in patient 1 may be the result of age-related skewing of X-inactivation.<sup>7</sup>

Skewed X-inactivation alone would not account for the very marked asymmetrical presentation. It is possible that the marked asymmetry reflects a disproportionately high expression of the X-chromosome carrying the mutant DMD gene on the more affected side, with preferential inactivation of the X chromosome harboring wild-type DMD. This may have arisen from an event early in embryogenesis when the X-chromosome-carrying wild-type DMD underwent preferential inactivation in the progenitor cells destined to become the muscles of the affected side. This event may have been either stochastic or genetic, involving for example the XIST gene,<sup>8</sup> a key player in the X-inactivation pathway. One can speculate that mosaicism of the XIST gene could account for the marked asymmetrical skewed inactivation.

**Accepted for Publication:** November 13, 2009.

**Correspondence:** Michael G. Hanna, FRCP, MRC Centre for Neuromuscular Diseases, National Hospital for Neurology and Neurosurgery, Queen Square, London, WC1N 3BG, England (m.hanna@ion.ucl.ac.uk).

**Author Contributions:** Drs Rajakulendran and Kuntzer contributed equally to this article as joint first authors. *Study concept and design:* Rajakulendran, Kuntzer, Dunand, Yau, Abbs, Lohrinus, Farmer, and Hanna. *Acquisition of data:* Rajakulendran, Kuntzer, Dunand, Yau, Storey, McCauley, Thonney, Leturcq, Lohrinus, Yousry, Farmer, and Holton. *Analysis and interpretation of data:* Rajakulendran, Kuntzer, Dunand, Yau, Ashton, Storey, McCauley, Abbs, Leturcq, Lohrinus, Yousry, and Hanna. *Drafting of the manuscript:* Rajakulendran, Kuntzer, Dunand, Yau, Abbs, Lohrinus, Farmer, and Hanna. *Critical revision of the manuscript for important intellectual content:* Rajakulendran, Kuntzer, Yau, Ashton, Storey, McCauley, Abbs, Thonney, Leturcq, Lohrinus, Yousry, Farmer, Holton, and Hanna. *Obtained funding:* Abbs, Leturcq, and Hanna. *Administrative, technical, and material support:* Rajakulendran, Kuntzer, Dunand, Yau, Ashton, Storey, McCauley, Thonney, Leturcq, Lohrinus, Yousry, Farmer, and Hanna. *Study supervision:* Rajakulendran, Kuntzer, Dunand, Yau, Abbs, Leturcq, Lohrinus, Farmer, and Hanna.

**Financial disclosure:** None reported.

**Funding/Support:** Part of this work was undertaken at University College London Hospitals and University College London, which received a proportion of funding from the Department of Health's National Institute for Health Research Biomedical Research Centres funding scheme. Researchers for this work were supported by the Swiss Association of Patients With Muscle Disease (ASRIM) (Dr Dunand); the Reta Lila Weston Institute for Neurological Studies (Dr Holton); and MRC Centre grant G0601943 (Dr Hanna).

## REFERENCES

1. Hoogerwaard EM, Bakker E, Ippel PF, et al. Signs and symptoms of Duchenne muscular dystrophy and Becker muscular dystrophy among carriers in the Netherlands: a cohort study. *Lancet*. 1999;353(9170):2116-2119.
2. Whitlock NV, Roberts RG, Mathew CG, Abbs SJ. Dystrophin point mutation screening using a multiplexed protein truncation test. *Genet Test*. 1997;1(2):115-123.
3. Allen RC, Zoghbi HY, Moseley AB, Rosenblatt HM, Belmont JW. Methylation of HpaII and HhaI sites near the polymorphic CAG repeat in the human androgen-receptor gene correlates with X chromosome inactivation. *Am J Hum Genet*. 1992;51(6):1229-1239.
4. Hoogerwaard EM, Ginjaar IB, Bakker E, de Visser M. Dystrophin analysis in carriers of Duchenne and Becker muscular dystrophy. *Neurology*. 2005;65(12):1984-1986.
5. Carrel L, Willard HF. X-inactivation profile reveals extensive variability in X-linked gene expression in females. *Nature*. 2005;434(7031):400-404.
6. Matthews PM, Benjamin D, Van Bakel I, et al. Muscle X-inactivation patterns and dystrophin expression in Duchenne muscular dystrophy carriers. *Neuromuscul Disord*. 1995;5(3):209-220.
7. Bolduc V, Chagnon P, Provost S, et al. No evidence that skewing of X chromosome inactivation patterns is transmitted to offspring in humans. *J Clin Invest*. 2008;118(1):333-341.
8. Plenge RM, Hendrich BD, Schwartz C, et al. A promoter mutation in the XIST gene in two unrelated families with skewed X-chromosome inactivation. *Nat Genet*. 1997;17(3):353-356.