

A 10-year experience in paediatric spontaneous cerebral haemorrhage: which children with headache need more than a clinical examination?

Sandrine de Ribaupierre^a, Bénédicte Rilliet^{a,b}, Jacques Cotting^c, Luca Regli^a

^a Service of Neurosurgery, Centre Hospitalier Universitaire Vaudois (CHUV), Lausanne

^b Service of Neurosurgery, Hôpital Universitaire de Genève (HUG), Genève

^c Paediatric intensive care unit, Centre Hospitalier Universitaire Vaudois (CHUV), Lausanne

Summary

Introduction: When a child is seen in a clinic with a headache, stroke is certainly not the first on the list of differential diagnoses. In western countries, stroke is typically associated with adults and the elderly. Although rare, haemorrhagic strokes are not exceptional in the paediatric population, as their incidence is around 1/100 000/year. Prompt diagnosis is essential, since delayed treatment may lead to disastrous prognosis in these children.

Materials and methods: This is a retrospective review of paediatric cases with spontaneous cerebral haemorrhage that presented in two university hospitals in the last ten years. The experience of these primary and tertiary referral centres comprises 22 consecutive cases that are analysed according to aetiology, presenting symptoms, treatment and outcome.

Results: 77% of the children diagnosed with haemorrhagic stroke presented with headaches. 41% of them had a sudden onset, while 9% developed headaches over a period of hours to weeks. While 9% presented only with headaches, the majority had either subtle (diplopia, balance problems) or obvious (focal deficits, unilateral weakness and decreased level of consciousness) concomitant neurological signs. 55% had an arteriovenous malformation (AVM), 18% had an aneurysm and 14% had a cavernous malformation. In 14% the aetiology could not be deter-

mined. The majority of haemorrhages (82%) were supratentorial, while 18% bled into the posterior fossa. All children underwent an emergency cerebral CT scan followed by specific investigations. The treatment was dependent on the aetiology as well as the mass effect of the haematoma. In 23% an emergent evacuation of the haematoma was performed. Two children (9%) died, and 75% had a favourable clinical outcome.

Conclusion: Headaches in children are a common problem, and a small minority may reveal an intracranial haemorrhage with poor prognosis if not treated promptly. Although characterisation of headaches is more difficult in a paediatric population, sudden, unusual or intense headaches should lead to imaging work-up. Any neurological finding, even one as subtle as hemianopsia or dysmetria, should alarm the physician and should be followed by emergency imaging investigation. If the cerebral CT reveals a haemorrhage, the child should be referred immediately to a neurosurgical referral centre without further investigation. The outcome is grim for children presenting in coma with fixed, dilated pupils. The long-term result overall for children after spontaneous intracranial haemorrhage is not dismal and depends critically on specialised management.

Key words: hemorrhagic stroke; pediatric; AVM; cavernoma; aneurysm; headache

Introduction

Headaches regularly or occasionally occur in 15–25% of the paediatric population [2–4]. When they occur, paediatricians or general practitioners are the first to be consulted. Their clinical appreciation of the headache plays a major role in de-

tecting a serious pathology such as intracerebral haemorrhage, sinus thrombosis, tumour or meningitis, as opposed to tension headache, migraine, or prodromal symptoms of flu or viral diseases.

Even though spontaneous cerebral haemorrhages are rare in children, they must be considered, and excluded rapidly in the differential diagnoses of headaches, as immediate treatment might be required in order to avoid devastating deficits. Unlike benign headaches, serious intracranial pathologies are often accompanied by symptoms, such as vomiting or focal neurological signs.

Haemorrhagic strokes will, in a majority of cases, reveal themselves with an altered level of consciousness, but might also be less symptomatic with headaches, vomiting, seizures or focal neurological deficits [5, 6]. The average incidence of haemorrhagic stroke in the paediatric population

is reported to be between 0.74–1.1/100 000/year [6–8]. Their incidence is slightly lower than that of ischaemic strokes; they represent between 27 and 52% of paediatric strokes [6, 9–11].

The purpose of this study is to analyse the signs and symptoms of a consecutive paediatric series presenting with spontaneous cerebral haemorrhages in two primary and tertiary referral centres. The work-up and the treatment of these children are reviewed. Main aetiologies are presented as well as recommendations for follow-up. Differences in the management of haemorrhagic stroke between the paediatric and adult populations will also be highlighted.

Materials and methods

We retrospectively reviewed the charts of paediatric patients (<18 years of age) who were consecutively admitted to two university hospitals for spontaneous cerebral haemorrhage from 1995 to 2005. The charts were found by searching the archives of the Centre Hospitalier Universitaire Vaudois (CHUV) in Lausanne and of the Hôpitaux Universitaires de Genève (HUG) in Geneva by diagnostic codes (ICD10). Since the charts were coded, we

were unlikely to miss cases with this search method, even if they had another associated diagnosis. We decided to exclude children with a known coagulopathy, such as thrombocytopenia, or haemophilia, children with sickle cell disease or children under anticoagulation, as they were not representative of a “normal” paediatric population.

Results

Twenty-two children were admitted during this period: 13 girls and 9 boys. The mean age was 10.8 years (median 11.8 years), ranging from 2 months to 18 years (table 1).

Fifteen children were admitted at the CHUV, while 7 were seen at the HUG. A demographic study was completed for the children admitted in Lausanne, and one child in Geneva. Eight of them initially presented at another peripheral hospital and 8 directly at the university hospital. The average distance between the location where the child presented the first alarming symptoms and the first consultation was 28 km (median 16 km) for the peripheral hospital and 56 km (median 42 km) for the university hospital. Three children were directly transferred by helicopter (REGA) to the CHUV; 4 were secondarily transferred by REGA from the peripheral hospital to the CHUV.

While children from Vallais, Fribourg and Neuchâtel are usually referred to Lausanne, there is a small surrounding French area (Ain, Haute-Savoie) as well as the Canton of Geneva that are referred to Geneva. The paediatric population (0–19 years) in the catchment area for the CHUV comprised approximately 250 800 (in 2006; www.bfs.admin.ch; www.scris.vd.ch), while that of the HUG was probably just over 100 000 (OC-STAT/OCP: www.geneve.ch/statistique/population_residante; www.geneve.statistique/statistique/

publications/pdf/2006/espace_lemanique/hc-el-t4-2006.pdf).

Symptoms at presentation

Seventeen (77%) children complained of headaches either on arrival or earlier the same day (table 1). Within this group, two children (12%) had only headaches with one or more vomiting episodes as the only symptoms on hospital admission. Eight (47%) had headaches a few hours preceding gradual or rapid neurological worsening. The other 7 (41%) had immediate or early associated neurological symptoms.

In four patients, it was impossible from the chart review to know whether they were complaining of headaches or not, while for one child, the history was clearly negative for headaches.

Nine children (41%) complained of sudden headaches, while 2 (9%) had a progressive headache. For the other 6 (27%) children complaining of headaches, the recorded information was not descriptive enough to differentiate between the two.

There were 5 patients (23%) with no, or subtle, neurological signs at the time of onset of the headaches, while 6 (27%) had moderate and 11 (50%) had severe symptoms. At the time of examination in the university hospital, one patient (5%) had no symptoms, two patients (9%) had

Table 1
L: left, R: right, AVM: arterio-venous malformation, HA: headache, NV: nausea and vomiting, GCS: Glasgow Coma Scale

Table 1	Age (years)	Aetiology	Grade	Localisation	Headaches	First symptoms	Signs/symptoms on arrival at university hospital	NV	Seizures	GCS
1	0,2	Aneurysm	Fischer IV	L anterior cerebral artery	?	Few convulsions, syncope	Cardiac arrest during transport, opisthotonos, dilated reactive pupils	-	Yes	3
2	1	Aneurysm	Fischer IV	Anterior communicating artery	Sudden	Cries holding his head, vomit	Reactive pupils	Yes	Yes	3
3	6	AVM	Spetzler III	R Parasplenium and intraventricular	Sudden	While at school, HA then decreased level of consciousness	Symmetric movements	-	-	9-10
4	6.5	AVM		Cerebellum and mesencephalon	?	Equilibrium	Ataxia	-	-	15
5	6.5	?		R Frontal	Yes	HA, left side paresis, memory difficulties, coordination	L side paresis	-	-	14
6	8	AVM	Spetzler IV	L Thalamic	No	Right side paresis	R side paresis	-	-	15
7	8	AVM	Spetzler I	L Frontal	Sudden	Left eye pain with HA, pallor, loss of consciousness, hypotonia	GCS 3 then improves to GCS 11, vomit, desorientation	-	?	3 to 11
8	9.5	AVM	Spetzler III	L Thalamic	?	R side paresis	R side paresis	-	-	15
9	9.5	Cavernoma		R Cerebellum	Yes	Cerebellar signs	Cerebellar syndrome	-	-	15
10	10	AVM	Spetzler III	R Frontal	Sudden	Complains of HA then loss of consciousness	R fixed dilated pupil	-	-	3
11	11	AVM		Cerebellum	Sudden	HA then decrease level of consciousness (10 min)	Bilateral fixed dilated pupils	-	-	7
12	11	?		Suprasellar	Progressive few weeks	Increase in HA, visual field loss, then vomiting	Progressive worsening, hypertension, bradycardia	Yes	-	12
13	12	AVM	Spetzler III	L trigone and intraventricular	Sudden	HA with NV	HA	Yes	-	15
14	12	?		R Fronto-temporal and Pallidum	Sudden	Complains of headache then loss of consciousness	Bilateral fixed dilated pupils	-	Yes	3
15	12	Cavernoma		R Fronto-temporal	Progressive few hours	HA then vomiting in the morning	R then L fixed dilated pupils, L Babinski	Yes	-	9
16	12	Aneurysm		R Carotid bifurcation	Yes	While watching TV, HA, visual difficulties then vomiting	Diplopia, desorientation	Yes	-	14
17	12.5	AVM	Spetzler II	R Sylvian, external capsule	Sudden	HA while skiing then rapid onset left side paresis	L side paresis	-	-	15
18	14	AVM	Spetzler IV	L Thalamic	?	Short loss of consciousness, disorientation then aphasia	R side paresis, aphasia	-	-	14
19	15	AVM		R Occipital	Sudden	HA, vomit, then decreased level of consciousness	R reactive dilated pupil	Yes	-	13
20	15.5	?		L Temporo-Parietal	Yes	While skiing, HA then vomiting	Reactive pupils	Yes	-	7
21	15.5	Aneurysm	Fischer V	L Carotid bifurcation	Yes	HA during gym, then vomiting	HA	Yes	-	15
22	17.5	Cavernoma		L Cerebellum	Progressive 3 days	Progressive HA, NV, equilibrium	Nystagmus, cerebellar syndrome	Yes	-	15
23	18	AVM	Spetzler I	R Parieto-Occipital	Yes	Hemianopsia 2 days prior then HA	Hemianopsia, GCS improved to 15 (was at 8 in peripheral hospital)	Yes	-	15

Table 2

Spetzler Grading System of arteriovenous malformation.

Spetzler Grading System		
Size of AVM	<3 cm	1
	3–6 cm	2
	>6 cm	3
Eloquent area	yes	1
	no	0
Deep venous drainage	yes	1
	no	0

Add the points to obtain the Grade. The higher the grade, the higher the risk of microsurgical resection [1]

mild neurological signs that were difficult to detect on general neurological examination (hemi-anopsia, moderate balance disorders), four (18%) had moderate neurological symptoms, including cerebellar signs, diplopia or disorientation, and 15 (68%) had severe symptoms ranging from clear motor deficit to altered state of consciousness. Three patients presented with onset of epileptic seizures (14%) (table 1).

Nine (41%) of the children had a normal Glasgow coma score (GCS), three (14%) had a GCS of 14, four (18%) had a GCS between 8 and 13, and six (27%) had a GCS less than 8 (table 1).

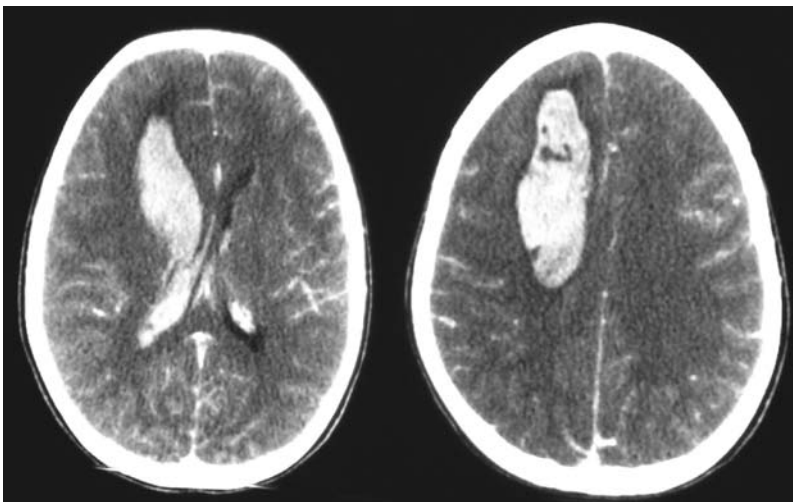
Aetiology of haemorrhage

Twelve (55%) of the children had an arteriovenous malformation (AVM) that bled (fig. 1–4). Arteriovenous malformations are classified according to Spetzler-Martin grade by their functional localisation, size and drainage type (table 2). Two AVMs were classified as grade I, one grade II, four grade III, and three were grade IV. Two cases could not be classified due to incomplete work-up.

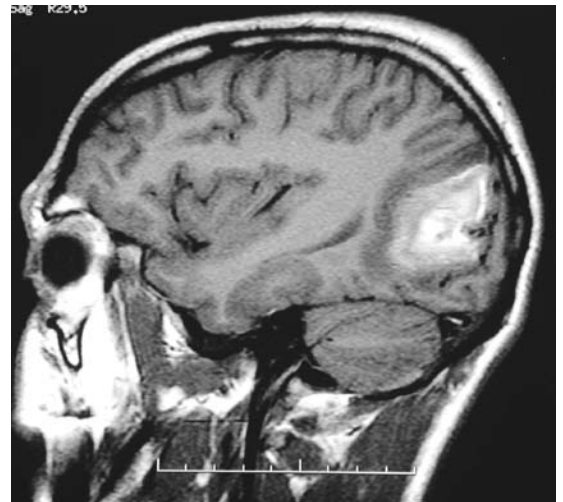Three patients (14%) had a cavernous angioma (fig. 5), and four children (18%) had a ruptured aneurysm (fig. 6). In three patients (14%), the aetiology of the haemorrhage could not be determined. In two of them, an AVM destroyed by the haemorrhage was suspected.

Figure 1

Cerebral CT-scan demonstrating a frontal haemorrhage with intraventricular rupture caused by an AVM.

**Figure 2**

Sagittal FLAIR image showing an occipital haemorrhage after an AVM bleeding.

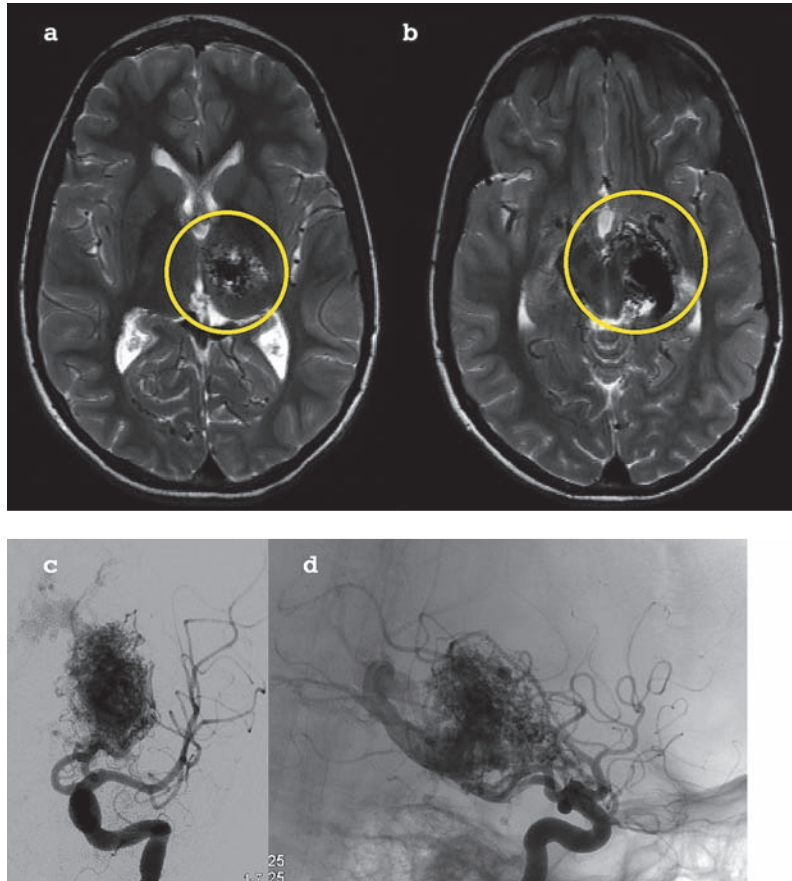
**Figure 3**

Right sylvian AVM. Left: Conventional angiogram revealing a right sylvian AVM fed by numerous small lateral branches. Right: Angio-MRI of the AVM. The haemorrhage is visualised, and partially masks the nidus of the AVM.

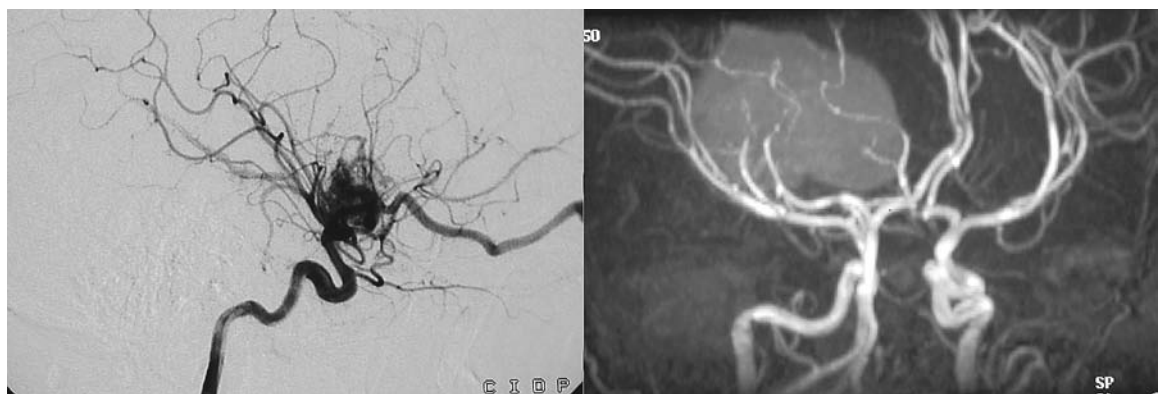

Figure 4

Large capsule-thalamic AVM. a-b: T2-weighted MRI demonstrating a left capsule-thalamic AVM with a large draining vein going into the Galen vein. c-d: Conventional angiography showing the thalamic AVM with deep venous drainage.



Localization

There were 18 supratentorial haemorrhages (82%), which could be subdivided into seven subcortical (considered superficial) and six deep (in the basal ganglia or thalamus). There was one isolated intraventricular haemorrhage. Four patients with ruptured aneurysms had subarachnoid bleeding, 2 of which also had an associated intracerebral clot.

There were 4 posterior fossa haemorrhages (18%): 3 involved only the cerebellum, while the

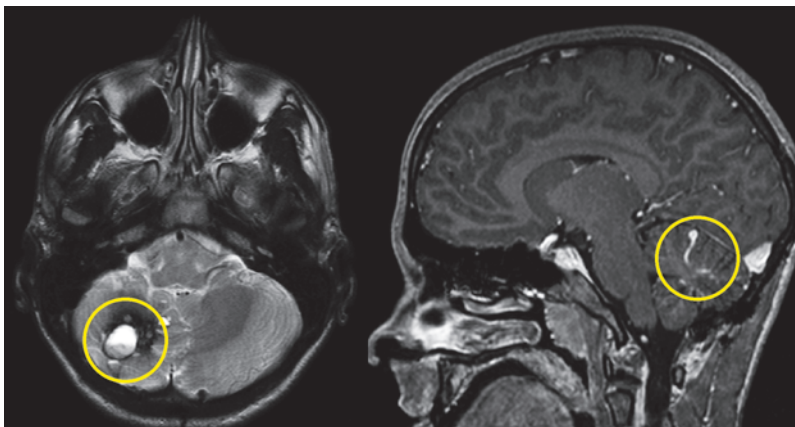
fourth involved the cerebellum and the mesencephalon.

In the superficial supratentorial haemorrhages there were 4 AVMs, 1 cavernous malformation and 1 haemorrhage of unknown aetiology. In the deep haemorrhages, there were 5 AVMs and 1 haemorrhage of unknown aetiology. The intraventricular haemorrhage came from an AVM and the subarachnoid haemorrhages from ruptured aneurysms.

The aetiologies in the posterior fossa were 2 cavernous malformations and 2 AVMs.

Figure 5

Cavernous malformation associated to a developmental anomaly. Left: T2-weighted MRI demonstrating a right cerebellar haemorrhage from a cavernous angioma (different signal intensities revealing different states of haemorrhage). Right: Associated developmental anomaly of the venous drainage, often present with the cavernoma seen on a sagittal T1-weighted MRI with gadolinium.



Investigations

All children underwent an emergency cerebral CT scan with and without contrast at admission except those that had a CT scan at an outside hospital.

Life-threatening mass effect indicated need for emergency surgical evacuation of the clot or drainage of acute hydrocephalus without further investigations in 8 (36%) of the children. Additional investigations were ordered dependant on the aspect and localisation of the haemorrhage.

- When haemorrhage suggested aneurysm rupture, multislice CT-angiography was performed urgently. Intraarterial angiography was not necessary for aneurysm diagnosis.
- When an arteriovenous malformation was suspected, intraarterial cerebral angiography

was always necessary. Since, unlike adults, most of the children required general anaesthesia for this investigation, endovascular treatment of the AVM was planned during the same procedure whenever feasible. All AVMs were managed by a multidisciplinary team involving the neurosurgeon, the interventional neuroradiologist, and the radiation specialist.

- When a cavernous angioma was suspected, or when the aetiology remained unknown despite angiography, MRI was the examination of choice.

Treatment

Management of cerebral vascular malformations necessitates a multidisciplinary approach involving a vascular neurosurgeon, an interventional neuroradiologist, a radiation specialist, as well as a paediatric neurointensivist, and a paediatric neurologist. Multimodal treatment options are frequent and have to be planned from the start whenever possible. The presence of life-threatening mass effect necessitates immediate surgical treatment. An arteriovenous malformation may be treated by microsurgery, by the endovascular approach and with radiosurgery. A cavernous angioma typically needs microsurgical resection, whereas an aneurysm may be treated surgically and by endovascular approaches.

Of the nine children with a mass effect, five (23%) required emergency evacuation of their haematoma as a life saving treatment. In four of those patients, the cause of the haemorrhage (AVM) was treated at the same time (table 3). One patient with a cavernoma underwent primary ur-

gent evacuation of the clot and then elective surgery for resection of the cavernous angioma.

Two patients (9%) had hydrocephalus with increased intracranial pressure requiring emergency external ventricular drainage; they had curative surgery a few days later after stabilisation of intracranial pressure. Both of them had an AVM. One patient (5%) had only an ICP monitor inserted.

Five other patients (23%) were treated surgically, semi-electively, within the week following the haemorrhage; two patients had an aneurysm, two had cavernomas, and the last one had an AVM. Two other patients (9%) who had an AVM underwent elective surgery at 1 month and at 4 months.

Two patients (9%) were embolised during the diagnostic angiography, one as the sole treatment, the other in a multimodality treatment plan followed by elective surgery. There was an attempt at embolisation in another patient with an AVM, but it was technically impossible to achieve, and he had subsequent surgical cure.

Three patients (14%) had elective radiosurgery as only treatment of their AVM, and two others in addition to their initial treatment (in one case surgery, in the other embolisation).

One child (5%) benefited from multimodal treatment with endovascular embolisation followed first by microsurgery and then by radiosurgery.

In one patient (5%) the causative lesion was not identified and no treatment was performed as the haematoma had no mass effect.

Figure 6

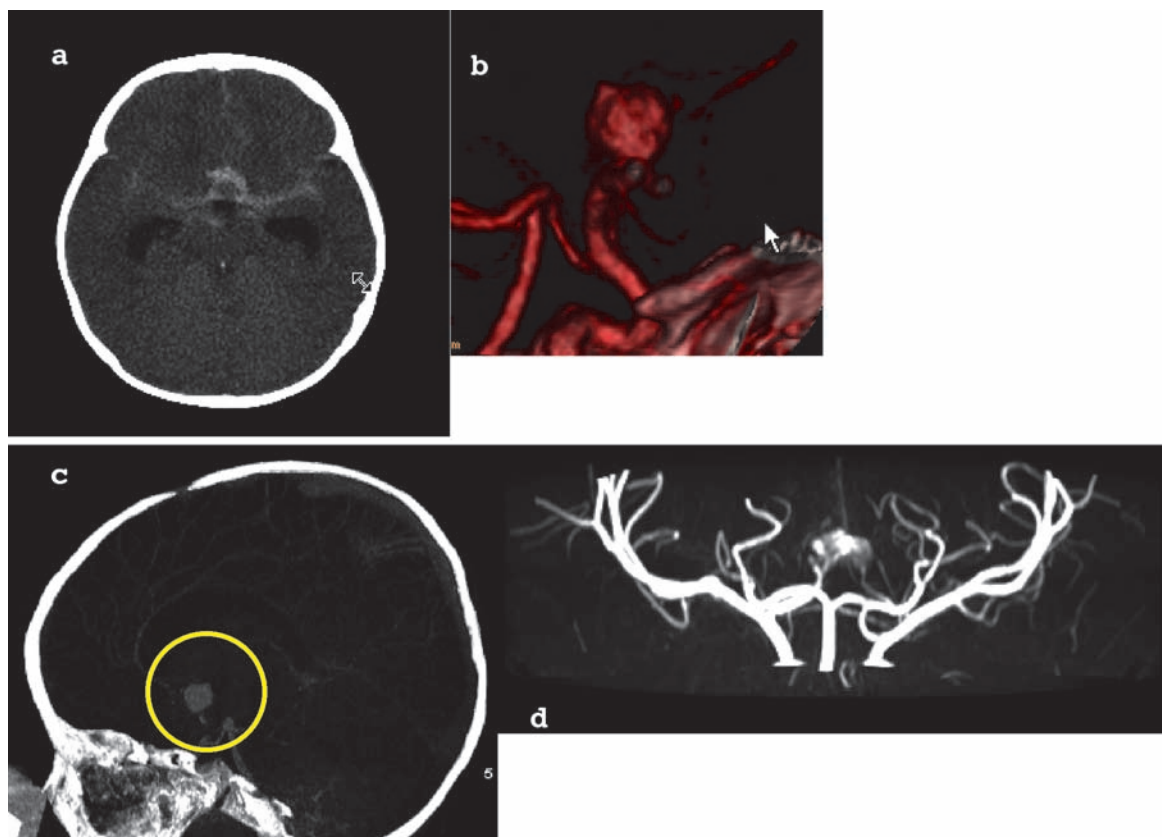
Subarachnoid blood due to an anterior communicating artery aneurysm.

a Cerebral CT-scan without contrast showing a subarachnoid haemorrhage, predominantly in the basal cistern, as well as in the Sylvian fissure.

b The cause of the haemorrhage was an anterior communicating artery aneurysm which is here reconstructed in 3D from the angio-CT.

c A sagittal reconstruction of the angio-CT showing the aneurysm

d The same anterior communicating aneurysm this time with an angio-MRI seen from an anterior point of view.



Follow-up and prognosis:

The mean follow-up time of the 20 children who survived was 35 months (median 16 months) (table 3).

Two children died (9%); both were intubated before admission (GCS <8) and had fixed, dilated pupils on arrival. Both had complained of acute headaches and then lost consciousness on site. The first patient had a cerebellar haemorrhage from an AVM, while the other had a large pallidal and frontotemporal lesion with a midline shift, the aetiology of which could not be identified. One child, who arrived in the hospital with a GCS of 3 and dilated pupils, remained in a persistent vegetative state.

Clinical outcome was favourable in 15 of 20 (75%) who were able to their pre-haemorrhage activity (school or apprenticeship) in normal classes: one (5%) had a normal examination but was too young to go to school, and two children (10%) were in specialised classes for moderate developmental delay. One child (5%) was in a vegetative state. No follow-up data was available for one child (5%).

Only one child developed late epileptic seizures after aneurysm rupture. Both children who had presented with epileptic seizures were gradually weaned off their anti-epileptic treatment without subsequent seizures.

Recurrent haemorrhage was observed in two children; both had an AVM. The first bled five years after his first haemorrhage from the AVM that had originally been treated with surgery, embolisation and radiosurgery. The radiosurgery had been completed one year prior, and some residual lesion was still visible at the time of recurrent haemorrhage. The other child had an incomplete resection of an AVM, and bled 4 months after the initial treatment.

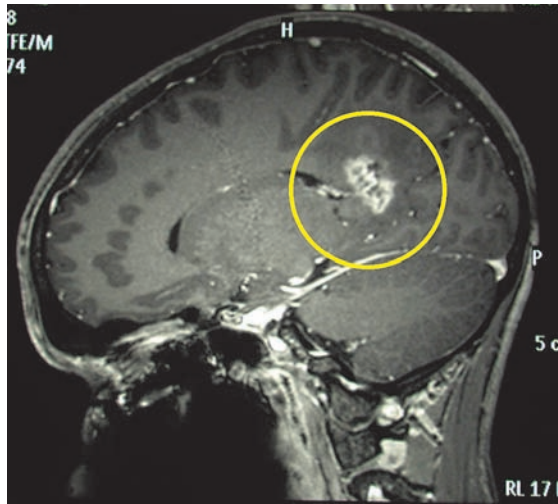
Treatment of the vascular malformation did not worsen the neurological condition in this small series. However, radionecrosis developed after radiosurgery for an AVM in two patients. In the first case, it was asymptomatic and diagnosed on follow-up MRI (fig. 7), and outcome was favourable. The second patient developed meningeal radionecrosis. His outcome was not favourable, as he was developmentally delayed

Table 3
Follow-up.

	Age (years)	Aetiology	Treatment	Treatment	FU (months)	Clinical outcome at FU	FU imaging
1	0,2	Aneurysm	Surgery	Within 48 h	89	Attention difficulties, developmental delay	Residual aneurysmal neck, stable
2	1	Aneurysm	Surgery	Emergency	16	N	?
3	6	AVM	Surgery	Emergency	4	Left hemianopsia	Small residual AVM
4	6.5	AVM	Surgery, then embolisation then radiosurgery	Emergency	90	Diplopia, slight R side paresis, dysarthria	No changes
5	6.5	?	-	None	87	Slight L side paresis	No residual lesion
6	8	AVM	Radiosurgery	Elective	40	Slight R side paresis	Regression of AVM
7	8	AVM	Surgery	Within 1 week	6	N	No residual lesion
8	9.5	AVM	Failed embolisation, radiosurgery	Elective	19	N	Small residual shunt
9	9.5	Cavernoma	Surgery	Emergency	108	N	Small residual cavernoma
10	10	AVM	Surgery	Emergency	9	Coma, reacting to noise and voices	Bilateral frontal ischemia
11	11	AVM	Surgery	Emergency	-	Death	-
12	11	?	Surgery	Emergency	23	Normal IQ but behavioural and learning difficulties	No residual lesion
13	12	AVM	Radiosurgery	Elective	16	N	Radionecrosis, complete regression of AVM
14	12	?	Surgery	Emergency	-	Death	-
15	12	Cavernoma	Surgery	Within 48 h	32	L upper limb paresis, mnesic difficulties, hemianopsia	No residual lesion
16	12	Cavernoma	Surgery	Within 1 week	13	N	No residual lesion
17	12.5	AVM	Surgery	Elective	1	Slight L side paresis	No residual lesion
18	14	AVM	Embolisation then radiosurgery	Emergency	101	Moderate R side paresis	Regression of AVM
19	15	AVM	Surgery	Emergency	1	Diplopia, hemianopsia	No residual lesion
20	15,5	?	Surgery (ICP)	Emergency	3	?	-
21	15,5	Aneurysm	Embolisation	Within 48 h	15	N	No residual lesion
22	17,5	Cavernoma	Surgery	Within 1 week	42	N	Residual cavernoma, stable
23	18	AVM	Surgery	Elective	2	N	No residual lesion

L: left, R: right, AVM: arterio-venous malformation, N: no neurological deficits

Figure 7
Radionecrosis following radiosurgery for an AVM shown on a T1-MRI with gadolinium.



and had to go into an institution. However, since this was the patient who had a second haemorrhage, the causality of the symptoms between the radionecrosis and the second bleed is difficult to assess.

From a *radiological point of view*, outcome analysis is easier to perform according to the aetiology:

In the 4 (18%) patients treated for an *aneurysm*, follow-up consisted of multislice CT-angiography that confirmed complete occlusion in 3 patients (75%). In one patient (25%), a small residual dilatation (<2 mm) was seen at the base of the aneurysm. Radiological follow-up with multislice CT-angiography showed no growth at 7 years.

Twelve children (55%) were treated for an *AVM*. Seven AVMs (58%) were completely resected by microsurgery, and one (8%) had incomplete AVM occlusion but remained stable on subsequent follow-up (4 months). Three AVMs (25%) were treated by radiosurgery alone. One showed complete occlusion and 2 showed decreased nidus size. Three years is still too short for final evaluation [12, 13]. There was no follow-up in the last one who died (8%).

In the 3 patients (14%) with a *cavernous angioma*, complete resection was obtained in one (33%), while two (66%) showed small cavernomatous residues. There was no evidence of re-bleeding or re-growth during follow-up (3.5 and 9 years).

Discussion

Headaches are not uncommon in children, but sudden or exceptional headaches should alert the doctor and should always lead to an emergency neurological work-up.

Should isolated headache necessarily lead to a radiological investigation? In our series, two children had nausea as the only additional sign and symptom to their headaches, whereas two others had only mild neurological deficits, which were detected only after an in-depth neurological examination. Depending on the child's age, it might be difficult to demonstrate a hemianopsia, for example, and this may easily be overlooked when assessing gross neurological status. In contrast to adults who can easily describe their headaches and characterise them as "the worst of my life", it is more difficult to obtain a precise description in children.

In several studies, either at the doctor's office or in the emergency department, the aetiology of headaches varied. Migraines accounted for 14–16% [3, 14], tension headaches for 5–9% [3, 14], post-traumatic headaches for 8–20% [3, 14, 15], sinusitis for 5–16% [3, 14], and general viral dis-

eases for 28–39% [3, 15]. Serious causes, such as tumours, CNS infection and haemorrhages, were found in 5–15% of cases [3, 14, 15].

In our series, while 78% of the children presented with headaches, only 30% described them as sudden, and 13% had headaches lasting from a few hours to a few weeks. In the literature, headaches are present in 58–67% of patients having a haemorrhagic stroke [16, 17].

In children presenting spontaneous intracranial haemorrhage, the other frequent symptoms are loss of consciousness (52%) [17] and vomiting (50%) [17]. A lateralised neurological deficit is found in 16–50% of cases [6, 16], and an epileptic seizure in 37% [16]. The frequencies of the neurological signs and symptoms are similar in our series and the literature, except for the higher epileptic seizure rate in the literature (table 4).

As the neurological signs and symptoms may be subtle, and as 5–15% of children presenting with headaches harbour a serious intracranial pathology, a more in-depth neurological examination should be performed and an imaging advised every time that the headache has one or more of

Table 4

Signs and symptoms of children with spontaneous cerebral haemorrhage in this case series and in the literature.

Signs and symptoms	Case series % (n = 23)	% in the literature
Headaches (\pm nausea and vomiting)	78%	58–67% [16, 17]
Lateralised deficit	20%	16–50% [6, 16]
Cerebellar signs (ataxia, dysmetria)	17%	not available
Epileptic seizure	13%	37% [16]
Hemianopia	4.3%	not available

these 3 characteristics: *sudden, unusual, worst*. If headache is associated with other neurological signs and symptoms, urgent investigation is also mandatory unless the clinical presentation is usual for the child and has already been investigated in the past.

The average incidence of haemorrhagic stroke in the literature varies between 0.74–1.1/100 000/year [6–8]. In our series, according to our recruitment population, it seems to be slightly lower with 0.66/100 000/year.

Since this is a small series, we found no statistical difference in outcome resulting from either the distance to the nearest hospital or whether the child was treated first in a peripheral hospital or in the university hospital.

The aetiologies of spontaneous intracerebral haemorrhages vary among the different published series. However, AVM is the leading cause in children, unlike in adults, and accounts for 14–56% [6, 7, 9, 16–19], followed by cavernous angiomas (3–27% [7, 9, 16]) and intracranial aneurysms (6–29% [6, 9, 16, 18]). An additional aetiology for spontaneous intracranial haemorrhage in children is the vein of Galen malformation, no cases were found in our series. It can reveal itself at birth, usually with cardiac failure, but in some rare cases it can lead, if undiagnosed, to haemorrhages in older children. The localisation of the haemorrhage depends upon the underlying lesion. Although AVMs are more common in the posterior fossa in children than in adults, they remain more frequent in the supratentorial space even in children [13, 20]. Aneurysmal ruptures are more frequent in the anterior circulation than in the posterior circulation [21], and according to Proust [22], they tend to be located on the internal carotid artery bifurcation (36%), middle cerebral artery (36%), anterior communicating artery (18%) or within the vertebrobasilar system (9%). Supratentorial localisation is also more common for cavernomas [23, 24].

Improved management thanks to specialised neurovascular teams and technological developments has decreased morbidity and mortality of intracerebral haemorrhage in the last 50 years. However, the mortality of haemorrhagic strokes in children remains high, ranging between 6 and 38% [10, 11, 16–18, 25]. Mortality varies depending on the primary lesion; it reaches 40–42% for AVMs and increases to 42–75% for posterior fossa AVMs [20, 26, 27]. In our series, mortality was in the lower range: 8% for AVMs, and 9% in total).

This series confirms that morbidity and mortality depend mainly on the location of the haemorrhage. While any clot leading to a significant mass effect can threaten survival, a posterior fossa bleed has a comparatively higher risk, as it may directly compress the brainstem. The following are poor prognostic factors in the literature: comatose state (GCS <8), infratentorial haematoma, and younger age (<3 years) [28]. We were not able

to find the same prognostic factors in our series, except for presentation with a GCS lower than 8. In the 4 children that presented with fixed and dilated pupils, 2 died, one is in a vegetative state, and the last one has a normal cognitive function but has some neurological deficits.

In regards to functional outcome, supratentorial haemorrhages may lead to more neurological sequelae with greater functional disabilities, such as lateralised motor deficit, language deficit, memory deficits, spatio-visual, and behavioural problems. Depending on the published studies, significant sequelae are found in 3–35% of children, although no reliable outcome scale has been applied to children [16, 17]. In our series, 71% of the children suffering a spontaneous intracranial haemorrhage were able to return to their former activity (normal school or apprenticeship), a higher frequency than in the adult population, where physical impairment, anxiety and depression, with institutionalisation were present in 80%, and nearly 25% had a score of quality of life (AQoL) lower than 0.1 (0 being equivalent to death) [29, 30]. Considering that the child's brain is a developing organ, the late sequelae of a haemorrhage may be better compensated, even if functional regions are damaged. Preserved cerebral plasticity may be an explanation [19, 31]. It is well known from the experience of epileptic surgery in the paediatric population that resection of the language zone before the age of 6 is less likely to create long term language deficit [32, 33]. It is more difficult to objectively assess the potential behavioural, socialisation, and emotional difficulties [10, 18].

In the treatment of AVMs, significant improvements have been achieved in microsurgery, as well as in endovascular techniques and radiosurgery [12, 20]. Multimodal treatment plans are not infrequent and increase the rate of complete AVM obliteration. Incomplete treatment of the malformation expose to the risk of a recurrent haemorrhage. De novo AVM formation is more frequent in children than in adults [8, 20]. In our series, two children had recurrent haemorrhage after incomplete treatment of an AVM.

According to the literature, haemorrhages due to AVM rupture in children show less favourable outcomes than in adults, probably due to a higher percentage of haemorrhage in the posterior fossa and higher incidence of AVMs presenting with haemorrhage. Indeed, 80% of paediatric AVMs reveal themselves with a haemorrhage [20].

Aneurysms can be either clipped microsurgically or embolised endovascularly [22, 34, 35]. Today, no studies have shown an advantage of one technique over the other in the paediatric population. In this series, the endovascular treated aneurysm (1 case) and the surgically treated aneurysms (3 patients) had good outcomes, with complete occlusion for all except one with a small residual neck which is stable on follow-up.

Cavernous angiomas are typically microsurgical lesions and should be resected *in toto* if possible [23, 36]. Cavernous angiomas are often associated with developmental venous drainage anomalies that increase the risk of surgical resection and favor recurrence of a cavernous angioma. Radiosurgery did not show favourable outcomes and is not indicated [23, 24]. In our series only 1 out of 3 children operated upon for a cavernous angioma were completely cured.

Follow-up imaging is particularly important in the paediatric population as recurrences can be observed even after complete cure of an intracranial vascular malformation. In children and young adults re-growth after complete obliteration of AVMs have been described. AVMs seem to have a different pattern of angiogenesis in children than in adults, with a higher potential for new abnormal vessels to form [37]. Similarly, cavernous angiomas can recur after complete resection, especially if they are associated with a developmental anomaly of the venous drainage [38]. Intracranial aneurysms can grow and re-bleed, if they are incompletely excluded. The higher recurrence rate of coiled aneurysms than for clipped ones, is of importance when treating children [39]. In the absence of sufficient data in aneurysm treatment in children, we favour surgical clipping due to its better durability. The review of this paediatric series allows us to emphasise some differences in the management of spontaneous intracranial haemorrhages between the paediatric and adult

population at our institutions. To start let us recall that in the paediatric population AVMs are the most frequent cause of spontaneous haemorrhage. Emergent work-up is mandatory and CT-scan with multislice CT-angiography is the preferred imaging study [40]. In most situations it allows to diagnose the aetiology in the emergency setting and safer life-saving surgery when needed. MRI and MRAngiography have their role in the follow-up as well as in the diagnosis of unclear aetiology. However, in an emergency setting, they have little place. Diagnostic angiography necessitates general anaesthesia in the paediatric population. For this reason we prefer to combine and plan the diagnostic angiography and the therapeutic endovascular treatment in one session. This mandates excellent collaboration between the neurosurgeon, the interventional radiologist and the paediatric neurointensivist. Finally, the follow-up of the paediatric population after treatment of an intracranial vascular malformation needs to be more aggressive, with repeated imaging studies, as the risk of recurrence and de novo formation of vascular malformations is higher than in adults. Our preferred imaging for follow-up is MRI, followed by multislice CT-angiography [41]. Intraarterial angiography is only recommended for detailed treatment planning. Although there are no evidence-based recommendations in the literature, we recommend imaging at least once at the beginning of adulthood.

Conclusion

Headaches are frequent also in the paediatric population and are of benign origin in the vast majority. However, emergency neurological work-up is mandatory if the headache is sudden, unusual or intense. Emergency admission is mandatory if those headaches are associated with neurological signs or symptoms. Urgent admission should be considered for every headache characterised as *first* and *worst*.

Work-up includes an emergency CT-scan without and with contrast. If this shows a haemorrhage, then a multislice CT-angiography should be added. The choice of the additional investigations depends on the suspected diagnosis; for example an intraarterial angiography would be used for arteriovenous malformations and an MRI for cavernous angiomas.

Intracranial vascular malformations that bled should be treated when ever possible because the natural history carries a high cumulative risk of re-bleeding, particularly in the paediatric population due to the long life expectancy.

The follow-up is important in the paediatric population and should include imaging studies, because there is a risk of recurrence even after complete occlusion of the malformation.

The long-term result for children after spontaneous intracranial haemorrhage is not dismal and emphasises the importance of emergency transfer to a referral centre. The outcome is grim for children presenting in coma with fixed dilated pupils.

In conclusion, the most important factor is not to delay diagnosis and emergency transfer. Whereas an emergency CT scan may be performed in a general hospital setting, we strongly believe that the rest of the management has to be conducted in a specialised referral centre, where the child can benefit from the expertise of a specialised neurovascular team including neurosurgeons, interventional neuroradiologists and paediatric neurointensivists.

Correspondence:

Luca Regli

Service of Neurosurgery

Centre Hospitalier Universitaire Vaudois
(CHUV)

CH-1011 Lausanne

E-Mail : Luca.Regli@chuv.ch

References

- 1 Spetzler RF, Zabramski JM. Grading and staged resection of cerebral arteriovenous malformations. *Clin Neurosurg.* 1990; 36:318-37.
- 2 Bandell-Hoekstra IE, et al. Prevalence and characteristics of headache in Dutch schoolchildren. *Eur J Pain.* 2001;5(2):145-53.
- 3 Burton LJ, et al. Headache etiology in a pediatric emergency department. *Pediatr Emerg Care.* 1997;13(1):1-4.
- 4 Deda G, Caksen H, Ocal A. Headache etiology in children: a retrospective study of 125 cases. *Pediatr Int.* 2000;42(6):668-73.
- 5 Calder K, et al. Emergency department presentation of pediatric stroke. *Pediatr Emerg Care.* 2003;19(5):320-8.
- 6 Eeg-Olofsson O, Ringheim Y. Stroke in children. Clinical characteristics and prognosis. *Acta Paediatr Scand.* 1983;72(3): 391-5.
- 7 Jordan LC, Hillis AE. Hemorrhagic stroke in children. *Pediatr Neurol.* 2007;36(2):73-80.
- 8 Celli P, et al. Cerebral arteriovenous malformations in children. Clinical features and outcome of treatment in children and in adults. *Surg Neurol.* 1984;22(1):43-9.
- 9 Giroud M, et al. Stroke in children under 16 years of age. Clinical and etiological difference with adults. *Acta Neurol Scand.* 1997;96(6):401-6.
- 10 Hurvitz E, et al. Long-term functional outcome of pediatric stroke survivors. *Top Stroke Rehabil.* 2004;11(2):51-9.
- 11 Simma B, et al. Risk factors for pediatric stroke: consequences for therapy and quality of life. *Pediatr Neurol.* 2007;37(2):121-6.
- 12 Levy EI, et al. Radiosurgery for childhood intracranial arteriovenous malformations. *Neurosurgery.* 2000;47(4):834-41; discussion 841-2.
- 13 Smyth MD, et al. Stereotactic radiosurgery for pediatric intracranial arteriovenous malformations: the University of California at San Francisco experience. *J Neurosurg.* 2002;97(1): 48-55.
- 14 Leon-Diaz A, Gonzalez-Rabelino G, Alonso-Cervino M. Analysis of the aetiologies of headaches in a paediatric emergency service. *Rev Neurol.* 2004;39(3):217-21.
- 15 Guidetti V, Galli F. Recent development in paediatric headache. *Curr Opin Neurol.* 2001;14(3):335-40.
- 16 Al-Jarallah A, et al. Nontraumatic brain hemorrhage in children: etiology and presentation. *J Child Neurol.* 2000;15(5): 284-9.
- 17 Lin CL, et al. Spontaneous intracerebral hemorrhage in children. *Kaohsiung J Med Sci.* 1999;15(3):146-51.
- 18 Blom I, et al. Prognosis of haemorrhagic stroke in childhood: a long-term follow-up study. *Dev Med Child Neurol.* 2003;45 (4):233-9.
- 19 Takeshita M, et al. Hemorrhagic stroke in infancy, childhood, and adolescence. *Surg Neurol.* 1986;26(5):496-500.
- 20 Humphreys RP, et al. Choices in the 1990s for the management of pediatric cerebral arteriovenous malformations. *Pediatr Neurosurg.* 1996;25(6):277-85.
- 21 Sanai N, et al. Pediatric intracranial aneurysms: durability of treatment following microsurgical and endovascular management. *J Neurosurg.* 2006;104(2 Suppl):82-9.
- 22 Proust F, et al. Pediatric cerebral aneurysms. *J Neurosurg.* 2001;94(5):733-9.
- 23 Di Rocco C, Iannelli A, Tamburrini G. Cavernous angiomas of the brain stem in children. *Pediatr Neurosurg.* 1997;27(2):92-9.
- 24 Mottolse C, et al. Central nervous system cavernomas in the pediatric age group. *Neurosurg Rev.* 2001;24(2-3):55-71; discussion 72-3.
- 25 Lanthier S, et al. Stroke in children: The coexistence of multiple risk factors predicts poor outcome. *Neurology.* 2000;54: 371-8.
- 26 Meyer PG, et al. Emergency management of deeply comatose children with acute rupture of cerebral arteriovenous malformations. *Can J Anaesth.* 2000;47(8):758-66.
- 27 Puzilli F, et al. Spontaneous cerebellar haemorrhages in childhood. *Childs Nerv Syst.* 1997;13(11-12):601-3; discussion 604.
- 28 Meyer-Heim AD, Bolthausen E. Spontaneous intracranial haemorrhage in children: aetiology, presentation and outcome. *Brain Dev.* 2003;25:416-21.
- 29 Haacke C, et al. Long-term outcome after stroke. Evaluating health-related quality of life using utility measurements. *Stroke.* 2006;37:193-8.
- 30 Sturm JW, et al. Quality of life after stroke: The north east Melbourne stroke incidence study. *Stroke.* 2004;35(10):2340-5.
- 31 Cioni G, et al. Reorganisation of the sensorimotor cortex after early focal brain lesion: a functional MRI study in monozygotic twins. *Neuroreport.* 2001;12(7):1335-40.
- 32 Boatman D, et al. Language recovery after left hemispherectomy in children with late-onset seizures. *Ann Neurol.* 1999; 46(4):579-86.
- 33 Hertz-Pannier L, et al. Late plasticity for language in a child's non-dominant hemisphere: a pre- and post-surgery fMRI study. *Brain.* 2002;125(Pt 2):361-72.
- 34 Huang J, et al. Intracranial aneurysms in the pediatric population: case series and literature review. *Surg Neurol.* 2005;63 (5):424-32; discussion 432-3.
- 35 Pollo C, et al. Ruptured cerebral aneurysm in the early stage of life - a congenital origin? *Neuropediatrics.* 2004;35(4):230-3.
- 36 Bruneau M, et al. Early surgery for brainstem cavernomas. *Acta Neurochir (Wien)* 2006;148(4):405-14.
- 37 Kader A, et al. Recurrent cerebral arteriovenous malformations after negative postoperative angiograms. *J Neurosurg.* 1996;85 (1):14-8.
- 38 Wurm G, et al. Recurrent cryptic vascular malformation associated with a developmental venous anomaly. *Br J Neurosurg.* 2003;17(2):188-95.
- 39 Campi A, et al. Retreatment of Ruptured Cerebral Aneurysms in Patients Randomized by Coiling or Clipping in the International Subarachnoid Aneurysm Trial (ISAT). *Stroke.* 2007;38: 1538-44.
- 40 Wintermark M, et al. Multislice computerized tomography angiography in the evaluation of intracranial aneurysms: a comparison with intraarterial digital subtraction angiography. *J Neurosurg.* 2003;98(4):828-36.
- 41 Dehdashti AR, et al. Comparison of multislice computerized tomography angiography and digital subtraction angiography in the postoperative evaluation of patients with clipped aneurysms. *J Neurosurg.* 2006;104(3):395-403.

SMW

Established in 1871
Formerly: Schweizerische Medizinische Wochenschrift
Swiss Medical Weekly

The European Journal of Medical Sciences

The many reasons why you should choose SMW to publish your research

What Swiss Medical Weekly has to offer:

- SMW's impact factor has been steadily rising. The 2006 impact factor is 1.346.
- Open access to the publication via the Internet, therefore wide audience and impact
- Rapid listing in Medline
- LinkOut-button from PubMed with link to the full text website <http://www.smw.ch> (direct link from each SMW record in PubMed)
- No-nonsense submission – you submit a single copy of your manuscript by e-mail attachment
- Peer review based on a broad spectrum of international academic referees
- Assistance of professional statisticians for every article with statistical analyses
- Fast peer review, by e-mail exchange with the referees
- Prompt decisions based on weekly conferences of the Editorial Board
- Prompt notification on the status of your manuscript by e-mail
- Professional English copy editing

Editorial Board

Prof. Jean-Michel Dayer, Geneva
Prof Paul Erne, Lucerne
Prof. Peter Gehr, Berne
Prof. André P. Perruchoud, Basel
Prof. Andreas Schaffner, Zurich
(editor in chief)
Prof. Werner Straub, Berne (senior editor)
Prof. Ludwig von Segesser, Lausanne

International Advisory Committee

Prof. K. E. Juhani Airaksinen, Turku, Finland
Prof. Anthony Bayes de Luna, Barcelona, Spain
Prof. Hubert E. Blum, Freiburg, Germany
Prof. Walter E. Haefeli, Heidelberg, Germany
Prof. Nino Kuenzli, Los Angeles, USA
Prof. René Lutter, Amsterdam, The Netherlands
Prof. Claude Martin, Marseille, France
Prof. Josef Patsch, Innsbruck, Austria
Prof. Luigi Tavazzi, Pavia, Italy

We evaluate manuscripts of broad clinical interest from all specialities, including experimental medicine and clinical investigation.

We look forward to receiving your paper!

Guidelines for authors:

http://www.smw.ch/set_authors.html

All manuscripts should be sent in electronic form, to:

EMH Swiss Medical Publishers Ltd.
SMW Editorial Secretariat
Farnsburgerstrasse 8
CH-4132 Muttenz

Manuscripts: submission@smw.ch
Letters to the editor: letters@smw.ch
Editorial Board: red@smw.ch
Internet: <http://www.smw.ch>