

Alma Mater Studiorum – Università di Bologna

DOTTORATO DI RICERCA IN SCIENZE CHIRURGICHE
PROGETTO N.3 "SCIENZE DERMATOLOGICHE"

Ciclo XXV

Settore Concorsuale di afferenza: 06/D4

Settore Scientifico disciplinare: MED/35

The *KIT* gene in familial mastocytosis

[Il gene *KIT* nella mastocitosi familiare]

Presentata da: Dott.ssa Athanasia Turlaki

Coordinatore Dottorato

Relatore

Chiar.mo Prof. Andrea Stella

Chiar.mo Prof. Carlo Gelmetti

Esame finale anno 2013

Summary

Familial cutaneous mastocytosis is an exceptional condition of unknown etiology. In this study we report the largest series of patients with familial cutaneous mastocytosis without other manifestations (18 affected subjects from seven unrelated families), and we investigate the role of germ-line *KIT* mutations in the pathogenesis of the disease. The mean age at onset was 5.4 years (range from birth to 22 years), and the clinical behavior was variable over a mean follow up period of 15.1 years (range 2-36): improvement in seven, stability in eight and worsening in the remaining three patients. The pattern of inheritance was compatible with an autosomal dominant trait with incomplete penetrance; a female preponderance (14 females vs 4 males, ratio 3.5:1) was noted; among the six women who have been pregnant at least once, three experienced important clinical changes during pregnancy. No germ-line mutation was found in the exons 10, 11, and 17 of the *KIT* proto-oncogene, which are the most commonly mutated exons in sporadic mastocytosis. However, in the majority of affected subjects we found the Met541Leu polymorphic variant of the *KIT* gene, which seems to confer a growth advantage to mast cells *in vitro*. This observation further suggests that the Met541Leu may be a predisposing factor of cutaneous mastocytosis, although it seems to be neither necessary nor sufficient for the development of the disease.

Introduction

Mastocytosis (OMIM 154800) is a group of disorders which have in common abnormal accumulation of mast cells in different organs and apparatuses, including the skin, bone marrow, gastrointestinal tract, spleen, liver, and lymph nodes. According to the World Health Organization (WHO) classification, based on clinical, biochemical and pathological criteria [Valent *et al.*, 2001; Sánchez-Muñoz *et al.*, 2011], seven variants of mastocytosis are defined: cutaneous mastocytosis (in which mast cell infiltration is limited to the skin), extracutaneous mastocytoma, indolent systemic mastocytosis, aggressive systemic mastocytosis, systemic mastocytosis associated with other clonal hematological non-mast cell lineage disease, mast cell leukemia, and mast cell sarcoma [Valent *et al.*, 2001].

The skin is the organ most commonly involved, and especially in children, is usually the only organ affected [Carter *et al.*, in Fitzpatrick's 7th edition]. There are four types of cutaneous mastocytosis: a) maculopapular type (formerly: urticaria pigmentosa), b) mastocytoma, c) diffuse cutaneous mastocytosis, and d) telangiectasia macularis eruptiva perstans. The first two variants are the most common, accounting for around 85 and 10 per cent of cases of cutaneous mastocytoses, respectively [Lange *et al.*, 2011]. Classic clinical manifestations of both these major types of cutaneous mastocytosis include a single brownish nodule (in case of mastocytoma), or a number of brownish, yellow-tan or reddish-brown macules, papules or plaques (in case of urticaria pigmentosa), usually located on the trunk and extremities. These lesions usually urticate and may also blister with rubbing; this reaction is known as *Darier's sign*. Other clinical features such as flushing, urticaria, headache, diarrhea and abdominal pain, caused by the excessive production of mast cell-dependent mediators, such as histamine, may also be present.

Cutaneous mastocytosis are divided into two groups based on the age of onset. The first group encompasses the most part of cases, which occur in pediatric age and usually disappear by adolescence. The second group of patients has adult-onset disease, which typically persists or progresses and may involve other organs (systemic mastocytosis). However, distinction is not always clear, and some cases of early onset disease may persist or have systemic involvement [Caplan, 1963; Kettelhut *et al.*, 1991].

The cause of cutaneous mastocytosis is unknown, but somatic mutations in the *KIT* gene has been related to this disease. The *KIT* gene encodes for the tyrosine kinase receptor KIT, and it is physiologically activated by its ligand, the stem cell factor (SCF), which plays a key role in mast cell proliferation. According to this, mast cell hyperplasia, which is the key pathological feature of mastocytosis, is usually caused by *gain-of-function KIT* mutations, which lead to the *constitutive* activation of the receptor (**Figure 1**) [Longley *et al.*, 1996; Yang *et al.*, 2010].

Somatic *KIT* mutations, including the common mutations in the codon 816, have been found in the skin lesions of the most part of adult patients with sporadic mastocytosis [Longley *et al.*, 1999; Yanagihori *et al.*, 2005]. In contrast, only recently, it has been consistently proved that somatic *KIT* mutations are also common in sporadic childhood-onset mastocytosis [Yanagihori *et al.*, 2005; Bodemer *et al.*, 2010], while the role of *KIT* in familial mastocytosis still remains unclear [Rosbotham *et al.*, 1999; Bodemer *et al.*, 2010; Wöhrl *et al.*, 2013].

Familial cutaneous mastocytosis is a very rare condition; nevertheless, it is being reported with increased frequency during the last decades [Fett *et al.*, 2013]. The aim of our study is to report the familial cases of mastocytosis examined in our Dermatology Unit since 1990,

and to shed some more light on the pathogenesis of the disease by searching for germ-line *KIT* mutations in our patients with familial cutaneous mastocytosis.

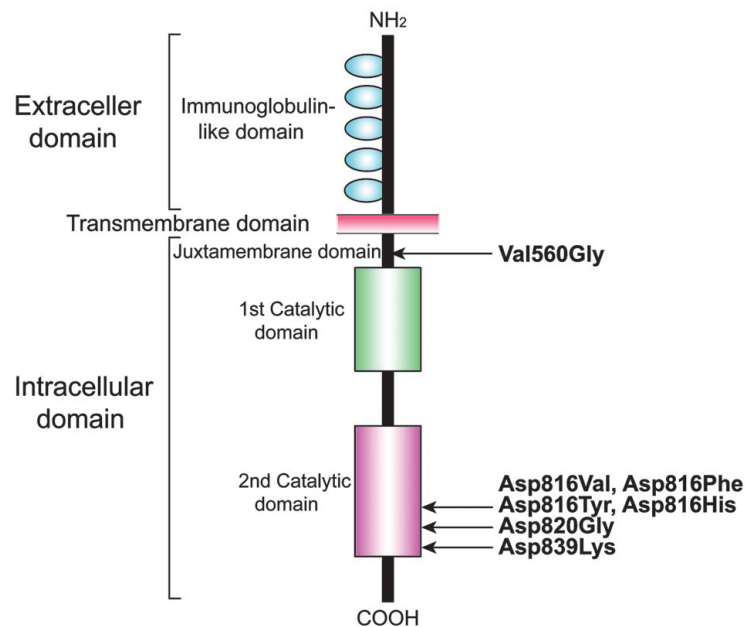


Figure 1. Schematic representation of KIT protein and location of *KIT* gene mutations described previously. The mutation at codon 560 (exon 11), which is within the juxtamembrane domain, and the mutations at codon 816/820 (exon 17), which are within the second catalytic domain, cause ligand-independent autophosphorylation of KIT receptor protein. In contrast, the mutation at codon 839 (exon 18, not investigated in the present work) results in loss of receptor function [Yanagihori *et al.*, 2005]. The Met541Leu polymorphic variant is within the transmembrane domain (not shown), and seems to confer an enhanced proliferative response to low levels of its ligand, the stem cell factor [Foster *et al.*, 2008]. The illustration is from Yanagihori *et al.*, 2005.

PATIENTS AND METHODS

Patients

The inpatient clinical records of the Pediatric Dermatology Unit of the University of Milan have been reviewed in order to identify familial cases of cutaneous mastocytosis over a 22 year period (1990-2012). Overall, ten families with at least two patients with cutaneous mastocytosis have been identified. Subsequently, patients were contacted by telephone and asked to participate in our study. Finally, a total of 18 patients, members of seven families, accepted to be available for an interview, physical examination, clinical photographs, and a venous blood sample for genetic analysis. All adult patients gave written informed consent and parents gave consent for their children prior to enrolment in the study.

DNA extraction from human polymorphonuclear neutrophils.

Human polymorphonuclear neutrophils (PMNs) were separated from whole blood by using the PolymorphprepTM solution (Axis-Shield, prod. No. 1114683; www.axis-shield.com). Then, genomic DNA (gDNA) was isolated from PMNs by using the DNAzol[®] Reagent (Invitrogen Life Technologies, Cat. No. 10503-027; www.invitrogen.com) according to the manufacturer's instructions. Briefly, PMNs were lysed in DNAzol[®] Reagent and gDNA was precipitated with 100% ethanol. Subsequently, after two 75% ethanol washes, gDNA was solubilized in water and stored at 4°C.

Screening of mutations in the *KIT* gene.

The presence of mutations in the exons 10 and 11 of the *KIT* gene (NCBI Reference Sequence: NG_007456) was investigated using direct sequencing, whereas the presence of

mutations in the exon 17 of the *KIT* gene was investigated using direct sequencing and two other more sensitive assays: the *Hinf*I assay and the amplification refractory mutation system (ARMS) polymerase chain reaction (PCR) for the Asp816Val and Asp816Tyr mutation, respectively.

The primer pairs 10A [5'-GATCCCATCCTGCCAAAGT-3' (forward)] and 10B [5'-ATTGTCTCAGTCATTAGAGCAC-3' (reverse)] (annealing temperature: 60°C), 11A [5'-CAGGTAACCATTTATTTGT-3' (forward)] and 11B [5'-TCATTGTTTCAGGTGGAAC-3' (reverse)] (annealing temperature: 54°C), and 17A [5'-AGTTTTCACTCTTTACAAG-3' (forward)] and 17B [5'-TGTC AAGCAGAGAAATGGGT-3' (reverse)] (annealing temperature: 53°C) were used to obtain PCR products of 206 base pairs (bp), 327 bp and 212 bp, which contain the exons 10, 11 and 17 of the *KIT* gene, respectively. Subsequently, each PCR product was sequenced using the Applied Biosystems BigDye® Terminator v1.1 Cycle Sequencing Kit (Applied Biosystems; www.lifetechnologies.com) and the Applied Biosystems 16-capillary 3130xl Genetic Analyzer (Applied Biosystems).

For the screening of the c.2447A>T (p.Asp816Val) mutation in the *KIT* gene, we also used the *Hinf*I (from *Haemophilus Influenzae*) restriction enzyme assay. Briefly, the 212-bp PCR product containing the exon 17 of the *KIT* gene was digested with *Hinf*I, which recognizes the 5'-G|ANTC-3' sequence. In case of wild-type sequence, the digestion gives rise to a 161 bp fragment, but when an A>T transition is present at position 2447 of the coding sequence of the *KIT* gene (ENST00000288135), an additional *Hinf*I site is created leading to a 147 bp DNA fragment [Beghini *et al.*, 2000].

Finally, for the screening of the c.2446G>T (p.Asp816Tyr) mutation, we also used the ARMS PCR. Briefly, 167 (wild-type) and 168 (mutated) ARMS PCR products of the exon 17 of the *KIT* gene were generated using the forward 17A primer 5'-

AGTTTTCACTCTTTACAAG-3' and the following fluorescently labeled reverse primers: 17B-Fam-wt 5'-TAGAATCATTCTTGATGTC-3' for the wild-type allele, and 17B-Hex-Tyr 5'-TTAGAATCATTCTTGATGTA-3' for the mutated allele. The PCR programs consisted of an initial denaturation step at 94°C for 5 min, followed by 33 cycles at 94°C for 30 s, 52°C for 15 s and 72°C for 15 sec, and a final extension step at 72°C for 10 min. The PCR products were resolved on 2% agarose-gel and visualized using a Typhoon 9200 Imager system (GE Healthcare Life Sciences; www.gelifesciences.com) [Beghini *et al.*, 2004].

RESULTS

Clinical features of the patients with familial cutaneous mastocytosis.

A total of 18 patients, members of seven unrelated families, agreed to participate in this study. More specifically, we studied 14 females and 4 males (F/M ratio: 3.5:1) with familial mastocytosis. The mean age at onset was 5.4 years, with range from 0 (at birth) to 22 years. Fourteen out of 18 patients were affected by urticaria pigmentosa at the time of diagnosis, two subjects (F3-II:3 and F6-I:1) had no clinical manifestations at that time, but a history of urticaria pigmentosa, and another two cases, part of the same family (F1-II:1 and F1-II:2), had a solitary mastocytoma. Not all family members had undergone skin biopsy, but at least one member of each family had a previous histological confirmation of cutaneous mastocytosis.

The main clinical data of these 18 patients are reported in **Table 1**, the family pedigrees are illustrated in **Figure 2**, while images representing examples of clinical and histopathological features are shown in **Figures 3 and 4**, respectively.

The first family consisted of:

Patient 1 (F1-II:3)

A 18-year-old woman, sister of the patients 2 e 3, who was diagnosed with cutaneous mastocytosis at the age of 9 years. She had frequent headaches and episodes of flushing. A few years earlier, she had an episode of angioedema with laryngeal involvement and airway obstruction, but the precise cause was unknown. Physical examination revealed two reddish brown macules on the abdomen. Darier's sign was positive, and dermographic urticaria was present. Serum tryptase level was < 20 ng/mL, routine blood analysis and total blood levels of IgE were normal. Both chest X-ray and abdominal ultrasound showed no evidence of systemic involvement.

Patient 2 (F1-II:2)

The 20-year-old sister of patients 1 e 3, who had a tan plaque on her trunk at birth. This lesion has been stable over time. As her sister, she had frequent headaches and episodes of flushing. She also suffered from allergic rhinitis due to ambrosia artemisiifolia and grass pollen, as well as from atopic dermatitis. Physical examination revealed a large light brown urticating plaque on her lower abdomen. Darier's sign was positive, and dermographic urticaria was present. Abdominal ultrasound revealed a slightly enlarged retroperitoneal lymph node but no organomegaly. Serum tryptase level was < 20 ng/mL. Routine blood analysis and total blood levels of IgE were normal.

Patient 3 (F1-II:1)

The 22-year-old brother of patients 1 e 2, who had had a solitary, large brown plaque on the abdomen since the age of 10 years. Darier's sign was positive. Past medical history included

also allergic rhinitis and asthma since childhood. Serum tryptase level was < 20 ng/mL. Routine blood analysis, chest X-ray and abdominal ultrasound were normal.

The second family was composed of:

Patient 4 (F2-II:1)

A 5-year-old girl, daughter of patient 5, who began developing tan lesions over the trunk at 3 years of age. She had no associated manifestations. Physical examination revealed numerous light brown maculopapular lesions and patches on the trunk and neck. Darier's sign was positive. No systemic manifestations were detected.

Patient 5 (F2-I:2)

A 35-year-old woman, mother of patient 4, who was diagnosed with urticaria pigmentosa at the age of 8. She presented with a few light brown macules on her abdomen and neck with edges being not completely sharp. Darier's sign was positive. No organomegaly or lymphadenopathy was appreciated. Skin biopsy revealed sheets of mast cells in the dermis in hematoxylin and eosin (see Figure 4), better demonstrated by the use of Giemsa stain. Serum tryptase level was < 20 ng/mL, routine blood analysis and total blood levels of immunoglobulin E (IgE) were normal.

The third family consisted of:

Patient 6 (F3-III:2)

A 7-year-old girl, daughter of patient 7, who began developing tan skin lesions on the trunk, neck and scalp, starting at 4 years of age. Examination disclosed eight yellowish brown

maculopapules involving the anatomical areas mentioned above. Darier's sign was positive. No organomegaly or lymphadenopathy was appreciated.

Patient 7 (F3-II:1)

A 36-year-old woman, mother of patient 6, who was diagnosed with cutaneous mastocytosis at the age of 6. She recalled having an episode of anaphylaxis after appendectomy at the age of 10 years. In addition, she had had some episodes of generalized pruritus before, mainly after exposure to excessive heat. She presented with four reddish-brown urticating macules on her trunk. Darier's sign was positive. The liver, the spleen and the lymph nodes were not clinically enlarged.

Patient 8 (F3-II:3)

A 39-year-old woman, sister of patient 7 and mother of patient 9, who began to have tan macules around her neck and on her scalp when she was 10 years old. She noted gradual fading of these lesions until complete clearing during her late 20s. She suffered from allergic contact dermatitis due to thimerosal. Examination showed dermographic urticaria but no skin lesions suggestive of mastocytosis. No systemic manifestations were identified.

Patient 9 (F3-III:4)

A 9-year-old girl, daughter of patient 8, who began to have cutaneous tan lesions at the age of 5 years. Physical examination revealed a few yellowish brown maculopapules on the trunk and neck. Darier's sign was positive. Clinical examination revealed a soft abdomen with no organomegaly. There was no lymphadenopathy. As her mother, she presented dermographic urticaria.

The fourth family consisted of:

Patient 10 (F4-II:1)

A 2-year-old boy, monozygotic twin of the patient 11, who began developing large patches on his trunk and arms at 2 months of age. He presented with about a dozen light brown patches located on his trunk, thigh, forearm, neck and face. Darier's sign was positive. Physical examination was otherwise normal. Two months before, he had an acute episode of urticaria but the precise cause was unknown. In the past he had also developed a morbilliform rash after taking an oral cephalosporin (cefprozil). Blood tests were unremarkable except for elevated blood levels of IgE (= 90 kUA/I, normal values \leq 30). The parents were not consanguineous and there was not family history of mastocytosis.

Patient 11 (F4-II:2)

A 2-year-old boy, monozygotic twin of the patient 10, who developed two yellowish brown patches, one on his trunk and one on the neck, at 5 months of age. Since then, these lesions have remained unchanged. Darier's sign was positive. He had no associated systemic manifestations. As with his twin brother, blood analyses showed raised blood levels of IgE (= 100 kUA/I, normal values \leq 30).

The fifth family consisted of:

Patient 12 (F5-II:2)

A 15-year-old boy, son of the patient 13, who developed tan papules on his trunk at 3 years of age. The number of lesions progressively increased over time. In fact, physical

examination revealed numerous small sized macules on the trunk. Darier's sign was negative. There was no evidence of internal lesions.

Patient 13 (F5-I:2)

The 47-year-old mother of patient 12, who was diagnosed with cutaneous mastocytosis at the age of 11 years. At the age of 30, after the birth of her first son, the skin lesions had cleared except for one on her trunk. Indeed, she presented with a brown patch next to her left shoulder. Darier's sign was positive and she had dermographic urticaria. No visceromegaly or lymphadenopathy was appreciated.

The sixth family consisted of:

Patient 14 (F6-III:1)

A 7-year-old girl, daughter of the patient 15, who began developing tan skin lesions on her trunk and neck at 3 years of age. She had frequent headaches and episodes of flushing. Physical examination revealed numerous reddish brown urticating papules and about a dozen similar plaques. Darier's sign was positive and she had dermographic urticaria. The remainder of the physical examination was unremarkable.

Patient 15 (F6-II:2)

The 32-year-old mother of patient 14 and daughter of patient 16, who first developed slightly itchy pigmented lesions on the trunk at 4 years of age. These lesions were numerous until the age of 20, when she had her first pregnancy. After that, the majority of these lesions were spontaneously cleared. Like her daughter, she suffered from frequent headaches and episodes of flushing. Physical examination showed nearly a dozen brown

macules on the trunk. Darier's sign was positive and she had dermographic urticaria. No organomegaly or lymphadenopathy was appreciated.

Patient 16 (F6-I:1)

The 56-year-old mother of patient 15 and grandmother of patient 14, who began developing tan macules on the trunk and neck during her first pregnancy, at the age of 22 years. Two years after, she noted gradual fading of these lesions until complete clearing. A few years later, she had two other pregnancies which did not lead to recurrence of the disease. Physical examination was unremarkable.

The seventh family consisted of:

Patient 17 (F7-II:3)

A 7-year-old girl, sister of patient 18, who began developing small tan skin lesions on the trunk, neck and upper limbs at 8 months of age. These lesions tended to increase in number over time. At the age of 6 years, she had an episode of acute urticaria related to ingestion of shrimp. Physical examination revealed numerous light brown maculopapular lesions on the trunk, neck and arms, as well as three larger, light brown patches on the trunk. Darier's sign was positive. No systemic manifestations were detected.

Patient 18 (F7-II:2)

The 11-year-old sister of patient 17, who had three tan lesions on the trunk and on the neck at birth. These lesions have been quite stable over time, except for slight fading in the last years. Past medical history included skin rash caused by oral amoxicillin/clavulanic acid and an episode of urticaria "after the use of a colored soap". Physical examination revealed

three faint reddish brown patches, one on the neck and two on the trunk. Darier's sign was negative, but her parents reported that in the past, these lesions used to become red and swollen after rubbing. No organomegaly or lymphadenopathy was appreciated.

Table 1. Clinical data regarding the 18 patients with familial cutaneous mastocytosis followed in our department.

Patient	Age (years)/sex	Age at onset	Extent of lesions	Lesion sites	Systemic involvement	Disease evolution
1	18/F	8 years	2 macules	trunk	(flushing, headaches)	stable
2	20/F	birth	1 patch	trunk	(flushing, headaches)	stable
3	22/M	10 years	1 plaque	trunk	no	stable
4	5/F	3 years	~100 macules	neck, trunk	no	stable
5	35/F	8 years	4 macules	neck, trunk	no	improved
6	7/F	4 years	8 maculopapules	neck, scalp, trunk	no	stable
7	36/F	6 years	4 macules	trunk	(pruritus, 1 anaphylaxis)	improved
8	39/F	10 years	0	-	no	improved
9	9/F	5 years	7 maculopapules	neck, trunk	no	stable
10	2/M	2 months	9 patches	trunk, forearm,	no	stable
11	2/M	5 months	2 patches	trunk, neck	no	stable
12	15/M	3 years	>200 macules	trunk	no	worsened
13	47/F	11 years	1 patch	trunk	no	improved
14	7/F	3 years	>200 papules+ plaques	trunk	(flushing, headaches)	worsened
15	32/F	4 years	~15 macules	trunk	(flushing, headaches)	improved
16	56/F	22 years	0	trunk, neck	no	improved
17	7/F	8 months	~200 macules	trunk, arms, neck	no	worsened
18	11/F	birth	3 patches	trunk, neck	no	improved

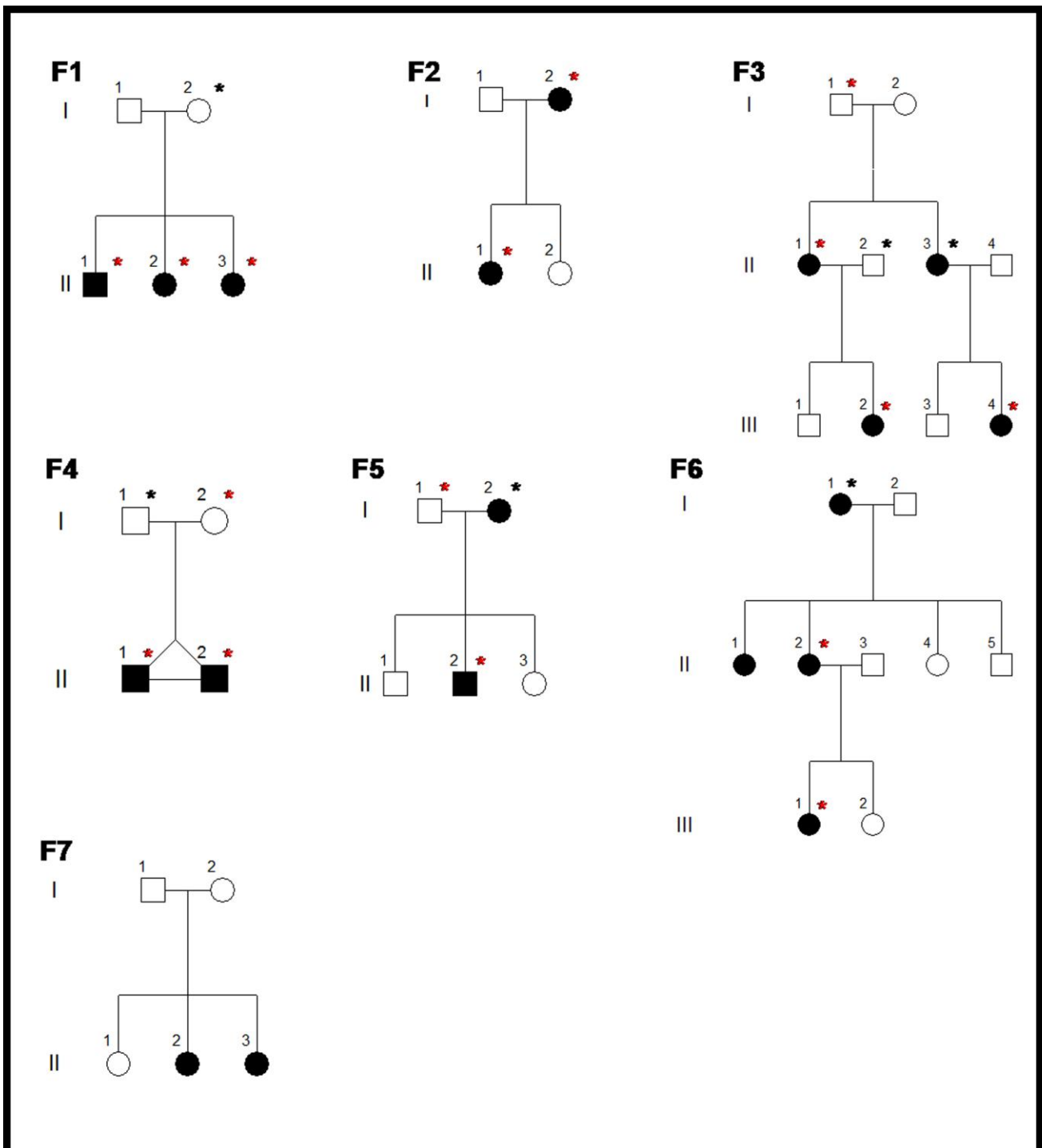


Figure 2. Pedigrees of the seven families in which more than one member had cutaneous mastocytosis. Subjects investigated for the single nucleotide polymorphism (SNP) A1621C (rs3822214) in the *KIT* gene, resulting in a Met541Leu substitution, are indicated with an asterisk; red asterisk = presence of the SNP; black asterisk = absence of the SNP.

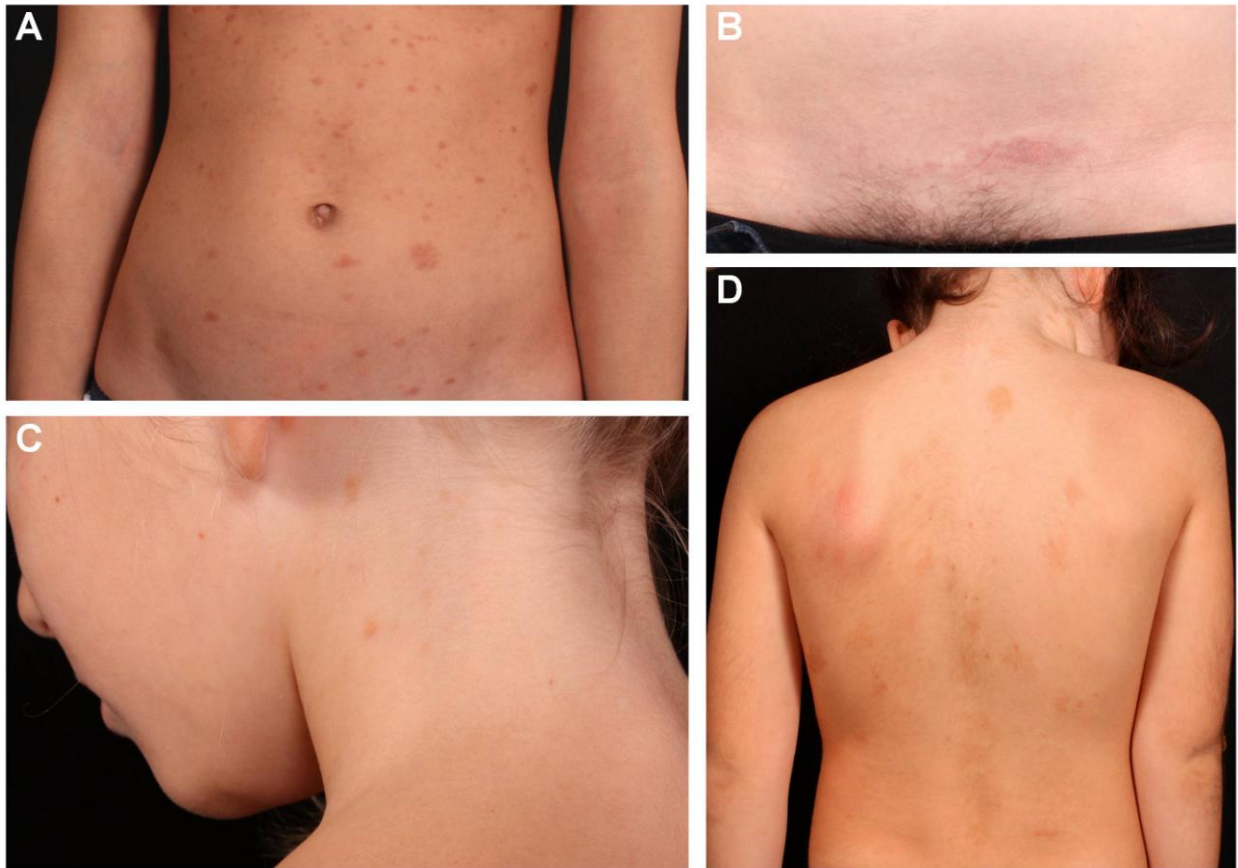

Figure 3. Clinical features of four patients with familial cutaneous mastocytosis. A: numerous tan macules and patches on the abdomen of patient 14; B: solitary reddish brown plaque on the suprapubic area of patient 2; C: a few yellowish brown maculopapules on the neck of patient 9; D: light brown patches on the back of patient 4.

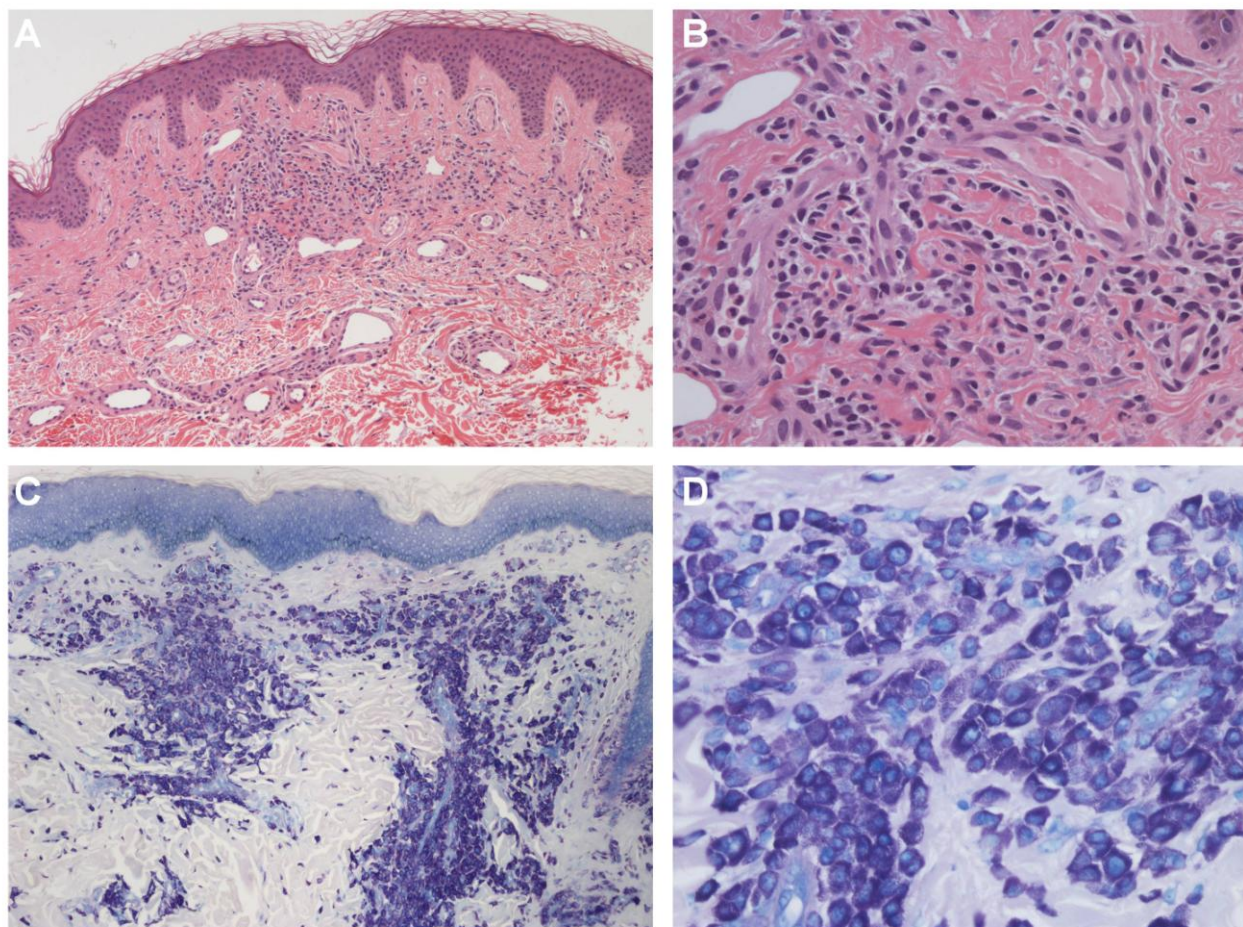


Figure 4. Histopathological features of two patients with familial cutaneous mastocytosis. A, B: histopathological examination of a skin biopsy from the abdominal skin of patient 5 revealed excessive numbers of mast cells in the dermis (hematoxylin and eosin stain, original magnification $\times 100$ and $\times 400$, respectively). In patient 15, mast cells were strongly positive with Giemsa stain and they were localized mainly around blood vessels (C: original magnification $\times 100$). At high magnification, these cells showed purple granules in the cytoplasm (D: original magnification $\times 400$).

Results of the molecular analyses

No mutation in the exons 10, 11 and 17 of the *KIT* gene, encompassing the amino-acids 514-549, 550-592, and 788-828, respectively, was identified by direct sequencing of the

DNA isolated from PMNs of all the subjects with familial cutaneous mastocytosis investigated in this study. In addition, as shown in **Figures 5 and 6**, the gain-of-function p.Asp816Val (p.D816V) and p.Asp816Tyr (p.D816Y) mutations were *not* identified by using the more sensitive HinfI restriction enzyme and ARMS PCR assays, respectively, in the subjects investigated from six out of the seven families.

Notably, in 13 out of 16 affected (~80%) members of the six families investigated, we found the single nucleotide polymorphism (SNP) A1621C (rs3822214) in the exon 10 of the *KIT* gene (ENST00000288135), resulting in a Met541Leu substitution. This variant was also found in three unaffected family members (F3-I:1, F4-I:2, and F5-I:1) and it was absent in three affected subjects (F3-II:3, F5-I:2, and F6-I:1) (see **Figure 2** and **Table 2** for further details) ($p = 0.2829$, not significant; Fisher's exact test).

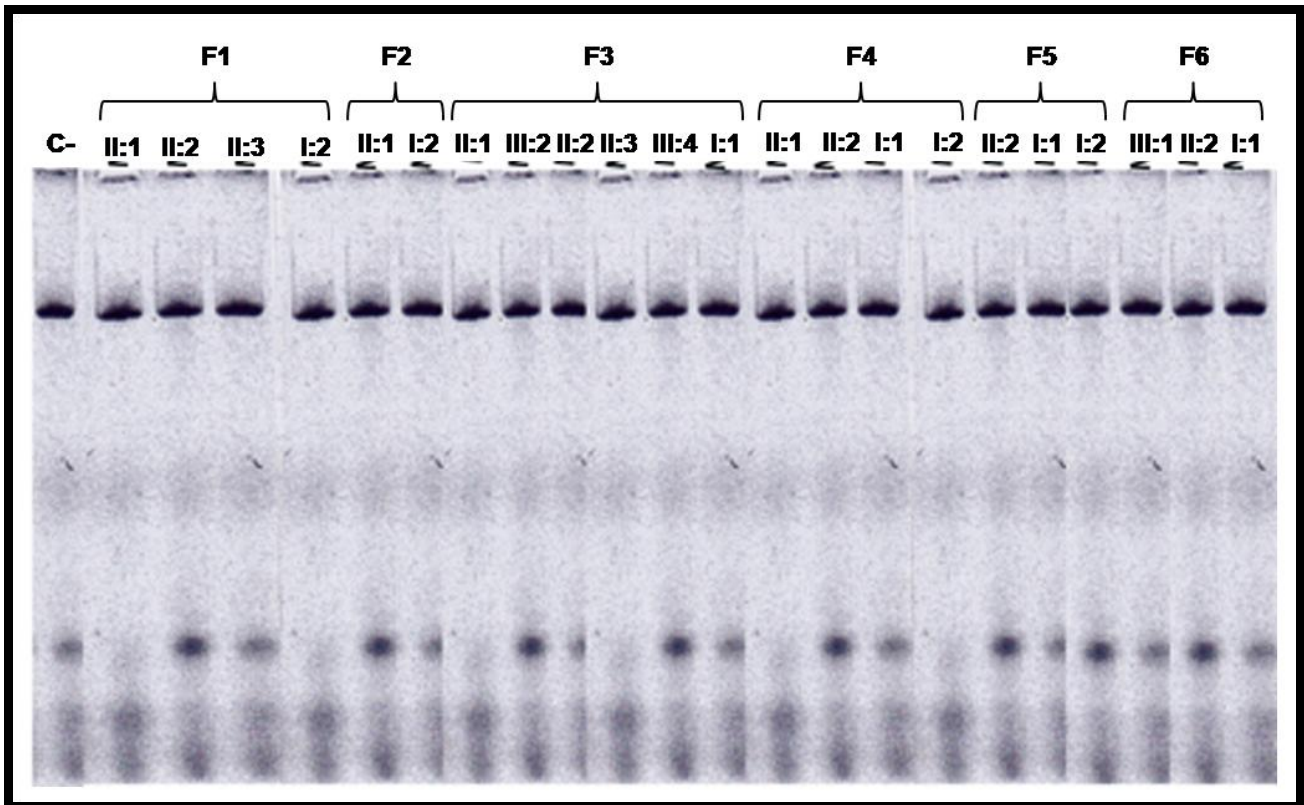


Figure 5. *HinfI* restriction enzyme assay for detection of the Asp816Val (D816V) mutation in the *KIT* gene. The digestion of the 212 base-pair (bp) polymerase chain reaction (PCR) product encompassing the exon 17 of the *KIT* gene gives rise to a 161 bp fragment in all the investigated patients, including a normal subject (C-); no additional fragment of 147 bp was observed, thus confirming the *lack* of the gain-of-function Asp816Val (D816V) mutation in all the cases. The members of each family investigated by *HinfI* assay are indicated as in the pedigrees of the **Figure 2**. No subject from Family 7 was investigated by *HinfI* assay. F1-6: Family 1-6.

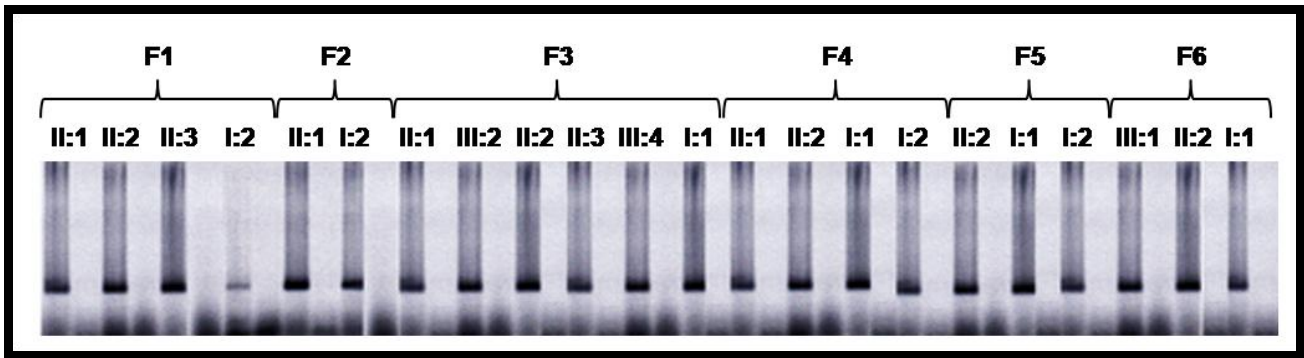


Figure 6. Amplification refractory mutation system (ARMS) polymerase chain reaction (PCR) for detection of the Asp816Tyr (D816Y) mutation in the *KIT* gene. The 167 base-pair wild-type PCR product is present in all the investigated subjects, whereas no 168 base-pair PCR product was obtained by using the fluorescently labeled reverse primer 17B-Hex-Tyr 5'-TTAGAATCATTCTTGATGTA-3' for the mutated allele, thus confirming the *lack* of the gain-of-function Asp816Tyr (D816Y) mutation in all the cases. The members of each family investigated by ARMS PCR are indicated as in the pedigrees of the **Figure 2**. No subject from Family 7 was investigated by ARMS PCR. F1-6: Family 1-6.

Table 2. Distribution of the p.Met541Leu (p.M541L) polymorphism in the exon 10 of the *KIT* gene in subjects from the families with familial cutaneous mastocytosis. The members of each family are indicated as in the pedigrees of the Figure 2.

Subject	Sex	Clinical phenotype	p.Met541Leu (p.M541L)
F1-I:2	F	Unaffected	negative
F1-II:1	M	Affected	+ve
F1-II:2	F	Affected	+ve
F1-II:3	F	Affected	+ve
F2-I:2	F	Affected	+ve
F2-II:1	F	Affected	+ve
F3-I:1	M	Unaffected	+ve
F3-II:1	F	Affected	+ve
F3-II:2	M	Unaffected	negative
F3-II:3	F	Affected	negative
F3-III:2	F	Affected	+ve
F3-III:4	F	Affected	+ve
F4-I:1	M	Unaffected	negative
F4-I:2	F	Unaffected	+ve
F4-II:1	M	Affected	+ve
F4-II:2	M	Affected	+ve
F5-I:1	M	Unaffected	+ve
F5-I:2	F	Affected	negative
F5-II:2	M	Affected	+ve
F6-I:1	F	Affected	negative
F6-II:2	F	Affected	+ve
F6-III:1	F	Affected	+ve

Discussion

Cutaneous mastocytosis is an uncommon disease, and usually occurs sporadically [Feger *et al.*, 2004]. Different somatic mutations (screened from cutaneous lesions) in *KIT* gene, most frequently at position D816, have been associated with the development of the disease, in both pediatric and adult sporadic cases [Yanagihori *et al.*, 2005; Bodemer *et al.*, 2010; Kambe *et al.*, 2010].

Familial cases of cutaneous mastocytosis have been rarely described, and only a few families have been studied genetically [Zanotti *et al.*, 2013; Fett *et al.*, 2013].

In the present work, we reported the largest series of familial cases with cutaneous mastocytosis, and we investigated the possible contribution of germ-line *KIT* mutations or polymorphic variants in the development of the disease. More specifically, we observed 18 patients, part of seven unrelated families, with no systemic manifestation other than some features caused by the excess production of mast cell-dependent mediators (e.g. episodes of flushing and headache).

Fourteen out of 18 patients (F/M ratio: 3.5:1) with familial cutaneous mastocytosis were female, and this female preponderance has been noted in previous reports [Fowler *et al.*, 1986; Anstey *et al.*, 1991], but the numbers are too small for statistical significance.

Mean follow-up was 15.1 (range 2-36) years. During this period of time, the clinical behavior of the disease was variable. In particular, seven out of 18 patients had an improvement over time, eight were stable, and three experienced a progressive worsening of cutaneous mastocytosis. Of note, among the six women who have been pregnant at least once, three experienced important clinical changes during pregnancy: two of them had a dramatic improvement (F5-I:2 and F6-II:2), while another subject (F6-I:1) experienced the onset of the disease.

The pattern of inheritance in our families (see pedigree in **Figure 2**) is compatible with an autosomal dominant trait with incomplete penetrance, as previously suggested [Anstey *et al.*, 1991]. Although sporadic cases of cutaneous mastocytosis have been related to *somatic* mutations in the *KIT* gene, no *germ-line* *KIT* mutation in the exon 10, 11 and 17 (which are the hotspot mutation regions of *KIT* gene) was found in any of the affected subjects.

To our knowledge, only one family with a novel, activating germ-line *KIT* mutation in the exon 17 (p. N8222I) suffering from urticaria pigmentosa (not associated with other diseases) has been reported so far [Wasag *et al.*, 2011]. In contrast, no germ-line *KIT* mutation (screened from blood samples) was found in the familial cases investigated by Rosbotham *et al.* in 1999, Sato-Matsumura *et al.* in 1999, Bodemer *et al.* in 2009, and Wöhrl *et al.* in 2013. In other familial cases, a *germ-line* *KIT* mutation was found, indeed, but the picture was more complex because of the co-presence of a gastrointestinal stromal tumor [Beghini *et al.*, 2001; Hartmann *et al.*, 2005], or the presence of more severe forms of mastocytosis [Tang *et al.*, 2004; Zhang *et al.*, 2006].

Although the entire coding region of the *KIT* gene was not investigated, the lack of germ-line mutations in the most commonly affected exons of the *KIT* gene provides conclusive evidence that distinct factors are involved in familial cutaneous mastocytoses.

Polymorphisms of *KIT*, IL4-receptor [Daley *et al.*, 2001] or mast cell growth factors might be taken into account for explaining the variety of cutaneous mastocytosis. In particular, as suggested by Foster *et al.* [2008], the presence of the polymorphism M541L in the transmembrane domain of the *KIT* gene can be a predisposing factor to the disease, because - in our cohort - it was found in the majority of affected subjects (13 out of 16) from all the families investigated, whereas its frequency in healthy individuals is 0.05-0.12 according to the 1000 Genomes Project data (i.e., in healthy population, it is present at a frequency of 5-

12 per 100 individuals). Indeed, mast cells expressing the M541L KIT may have a proliferative and/or a survival advantage, as demonstrated *in vitro* by Foster *et al.* [2008]. It should be stressed, however, that the M541L KIT seems to be neither sufficient nor necessary to cause mastocytosis, because in our series of familial cutaneous mastocytosis it was found in *unaffected* family members, and it was absent in *affected* family members. Our data should be carefully verified, as pre-analytical biases (including sampling errors – see for example the segregation of the polymorphism in the case of family 3) cannot be ruled out *a priori*, but the presence of the M541L KIT in *unaffected* family members was also noted by Foster *et al.* [2008].

In our series, screening for mutations in the *KIT* gene was not performed on skin biopsy samples, given the lack of proper material for genetic analyses. Therefore, we were unable to verify whether *somatic* mutations in the *KIT* gene commonly occur also in familial cases of cutaneous mastocytosis. The gain-of-function D816V *KIT* mutation was found in the skin lesions of 2 out of 4 subjects with familial cutaneous mastocytosis by Bodemer *et al.* [2009] suggesting that somatic *KIT* mutations may play a key role in familial cases of cutaneous mastocytosis, as well as in sporadic cases. However, no *KIT* mutation was found in skin lesions of three subjects with familial cutaneous mastocytosis reported by Longley *et al.* [1999] and in the proband of the family with urticaria pigmentosa reported by Rosbotham *et al.* [1999].

Given the presence of the above-mentioned uncertainties, future studies regarding familial cases of cutaneous mastocytosis, including complete sequencing of the *KIT* gene, genetic analyses on skin biopsy samples, and exome sequencing might allow the identification of new molecular determinants of cutaneous mastocytosis.

ACKNOWLEDGMENTS

I am particularly indebted to Prof. Alessandro Beghini, Dr. Vinicio Boneschi, Dr. Stefano Cambiagli, Dr. Francesca Lazzaroni, Dr. Iria Neri and Prof. Annalisa Patrizi who made possible this thesis with their work and insightful comments.

References

- Anstey A, Lowe DG, Kirby JD, Horton MA. Familial mastocytosis: a clinical, immunophenotypic, light and electron microscopic study. *Br J Dermatol.* 1991 Dec;125(6):583-7.
- Beghini A, Peterlongo P, Ripamonti CB, Larizza L, Cairoli R, Morra E, Mecucci C. C-kit mutations in core binding factor leukemias. *Blood.* 2000 Jan 15;95(2):726-7.
- Beghini A, Ripamonti CB, Cairoli R, Cazzaniga G, Colapietro P, Elice F, Nadali G, Grillo G, Haas OA, Biondi A, Morra E, Larizza L. KIT activating mutations: incidence in adult and pediatric acute myeloid leukemia, and identification of an internal tandem duplication. *Haematologica.* 2004 Aug;89(8):920-5.
- Beghini A, Tibiletti MG, Roversi G, Chiaravalli AM, Serio G, Capella C, Larizza L. Germline mutation in the juxtamembrane domain of the kit gene in a family with gastrointestinal stromal tumors and urticaria pigmentosa. *Cancer.* 2001 Aug 1;92(3):657-62.
- Bodemer C, Hermine O, Palmérini F, Yang Y, Grandpeix-Guyodo C, Leventhal PS, Hadj-Rabia S, Nasca L, Georgin-Lavialle S, Cohen-Akenine A, Launay JM, Barete S, Feger F, Arock M, Catteau B, Sans B, Stalder JF, Skowron F, Thomas L, Lorette G, Plantin P, Bordigoni P, Lortholary O, de Prost Y, Moussy A, Sobol H, Dubreuil P. Pediatric mastocytosis is a clonal disease associated with D816V and other activating c-KIT mutations. *J Invest Dermatol.* 2010 Mar;130(3):804-15.
- Caplan RM. The natural course of urticaria pigmentosa. Analysis and follow-up of 112 cases. *Arch Dermatol.* 1963 Feb;87:146-57.

- Carter MC, Metcalfe DD. Biology of Mast Cells and the Mastocytosis Syndromes. In: *Fitzpatrick's Dermatology In General Medicine* (Wolff K, Goldsmith L, Katz S, *et al.*), 7th edition. McGraw-Hill Companies, 2008; 1434-43.
- Daley T, Metcalfe DD, Akin C. Association of the Q576R polymorphism in the interleukin-4 receptor alpha chain with indolent mastocytosis limited to the skin. *Blood*. 2001 Aug 1;98(3):880-2.
- Feger F, Hermine O, Guillosso JJ, Arock M (2004) C-kit and mastocytosis. In: Pahl HL and Petrides PE (eds) *Molecular basis of myeloproliferative disorders*, Springer-Verlag, Berlin Heidelberg, pp. 169-178.
- Fett NM, Teng J, Longley BJ. Familial urticaria pigmentosa: report of a family and review of the role of KIT mutations. *Am J Dermatopathol*. 2013 Feb;35(1):113-6.
- Foster R, Byrnes E, Meldrum C, Griffith R, Ross G, Upjohn E, Braue A, Scott R, Varigos G, Ferrao P, Ashman LK. Association of paediatric mastocytosis with a polymorphism resulting in an amino acid substitution (M541L) in the transmembrane domain of c-KIT. *Br J Dermatol*. 2008 Nov;159(5):1160-9.
- Fowler JF Jr, Parsley WM, Cotter PG. Familial urticaria pigmentosa. *Arch Dermatol*. 1986 Jan;122(1):80-1.
- Hartmann K, Wardelmann E, Ma Y, Merkelbach-Bruse S, Preussner LM, Woolery C, Baldus SE, Heinicke T, Thiele J, Buettner R, Longley BJ. Novel germline mutation of KIT associated with familial gastrointestinal stromal tumors and mastocytosis. *Gastroenterology*. 2005 Sep;129(3):1042-6.

- Kambe N, Longley BJ, Miyachi Y, Kabashima K. KIT masters mast cells in kids, too. *J Invest Dermatol*. 2010 Mar;130(3):648-50.
- Kettelhut BV, Metcalfe DD. Pediatric mastocytosis. *J Invest Dermatol* 1991; 96(3 Suppl): 15S-18S.
- Lange M, Niedoszytko M, Renke J, Gleń J, Nedoszytko B. Clinical aspects of paediatric mastocytosis: a review of 101 cases. *J Eur Acad Dermatol Venereol*. 2013 Jan;27(1):97-102.
- Longley BJ Jr, Metcalfe DD, Tharp M, Wang X, Tyrrell L, Lu SZ, Heitjan D, Ma Y. Activating and dominant inactivating c-KIT catalytic domain mutations in distinct clinical forms of human mastocytosis. *Proc Natl Acad Sci U S A*. 1999 Feb 16;96(4):1609-14.
- Longley BJ, Longley BJ, Tyrrell L, Lu SZ, Ma YS, Langley K, Ding TG, Duffy T, Jacobs P, Tang LH, Modlin I. Somatic c-KIT activating mutation in urticaria pigmentosa and aggressive mastocytosis: establishment of clonality in a human mast cell neoplasm. *Nat Genet*. 1996 Mar;12(3):312-4.
- Rosbotham JL, Malik NM, Syrris P, Jeffery S, Bedlow A, Gharraie S, Murday VA, Holden CA, Carter ND. Lack of c-kit mutation in familial urticaria pigmentosa. *Br J Dermatol*. 1999 May;140(5):849-52.
- Sánchez-Muñoz L, Sánchez-Muñoz L, Alvarez-Twose I, García-Montero AC, Teodosio C, Jara-Acevedo M, Pedreira CE, Matito A, Morgado JM, Sánchez ML, Mollejo M, Gonzalez-de-Olano D, Orfao A, Escribano L. Evaluation of the WHO criteria for the classification of patients with mastocytosis. *Mod Pathol*. 2011 Sep;24(9):1157-68.

- Sato-Matsumura KC, Matsumura T, Koizumi H, Sato H, Nagashima K, Ohkawara A. Analysis of c-kit exon 11 and exon 17 of urticaria pigmentosa that occurred in monozygotic twin sisters. *Br J Dermatol*. 1999 Jun;140(6):1130-2.
- Tang X, Boxer M, Drummond A, Ogston P, Hodgins M, Burden AD. A germline mutation in KIT in familial diffuse cutaneous mastocytosis. *J Med Genet*. 2004 Jun;41(6):e88.
- Valent P, Valent P, Horny HP, Escribano L, Longley BJ, Li CY, Schwartz LB, Marone G, Nuñez R, Akin C, Sotlar K, Sperr WR, Wolff K, Brunning RD, Parwaresch RM, Austen KF, Lennert K, Metcalfe DD, Vardiman JW, Bennett JM. Diagnostic criteria and classification of mastocytosis: a consensus proposal. *Leuk Res*. 2001 Jul;25(7):603-25.
- Wasag B, Nidoszytko M, Piskorz A, Lange M, Renke J, Jassem E, Biernat W, Debiec-Rychter M, Limon J. Novel, activating KIT-N822I mutation in familial cutaneous mastocytosis. *Exp Hematol*. 2011 Aug;39(8):859-65.e2.
- Wöhrl S, Moritz KB, Bracher A, Fischer G, Stingl G, Loewe R. A c-kit Mutation in Exon 18 in Familial Mastocytosis. *J Invest Dermatol*. 2013 Mar;133(3):839-41.
- Yanagihori H, Oyama N, Nakamura K, Kaneko F. c-kit Mutations in patients with childhood-onset mastocytosis and genotype-phenotype correlation. *J Mol Diagn*. 2005 May;7(2):252-7.
- Yang Y, Yang Y, Létard S, Borge L, Chaix A, Hanssens K, Lopez S, Vita M, Finetti P, Birnbaum D, Bertucci F, Gomez S, de Sepulveda P, Dubreuil P. Pediatric mastocytosis-associated KIT extracellular domain mutations exhibit different functional and signaling

properties compared with KIT-phosphotransferase domain mutations. *Blood*. 2010 Aug 19;116(7):1114-23.

- Zanotti R, Simioni L, Garcia-Montero AC, Perbellini O, Bonadonna P, Caruso B, Jara-Acevedo M, Bonifacio M, De Matteis G. Somatic D816V KIT mutation in a case of adult-onset familial mastocytosis. *J Allergy Clin Immunol*. 2013Feb;131(2):605-7.
- Zhang LY, Smith ML, Schultheis B, Fitzgibbon J, Lister TA, Melo JV, Cross NC, Cavenagh JD. A novel K509I mutation of KIT identified in familial mastocytosis-in vitro and in vivo responsiveness to imatinib therapy. *Leuk Res*. 2006 Apr;30(4):373-8.