

University of Nebraska - Lincoln

DigitalCommons@University of Nebraska - Lincoln

USDA National Wildlife Research Center - Staff
Publications

U.S. Department of Agriculture: Animal and
Plant Health Inspection Service

2005

West Nile Virus Infection In Farmed American Alligators (*Alligator Mississippiensis*) In Florida

Elliott R. Jacobson

University of Florida, jacobsons@mail.vetmed.ufl.edu

Pamela E. Ginn

University of Florida

J. Mitchell Troutman

University of Florida

Lisa Farina

University of Florida

Lillian Stark

Florida Department of Health Bureau of Laboratories

See next page for additional authors

Follow this and additional works at: https://digitalcommons.unl.edu/icwdm_usdanwrc

 Part of the [Environmental Sciences Commons](#)

Jacobson, Elliott R.; Ginn, Pamela E.; Troutman, J. Mitchell; Farina, Lisa; Stark, Lillian; Klenk, Kaci; Burkhalter, Kristen L.; and Komar, Nicholas, "West Nile Virus Infection In Farmed American Alligators (*Alligator Mississippiensis*) In Florida" (2005). *USDA National Wildlife Research Center - Staff Publications*. 1042.

https://digitalcommons.unl.edu/icwdm_usdanwrc/1042

This Article is brought to you for free and open access by the U.S. Department of Agriculture: Animal and Plant Health Inspection Service at DigitalCommons@University of Nebraska - Lincoln. It has been accepted for inclusion in USDA National Wildlife Research Center - Staff Publications by an authorized administrator of DigitalCommons@University of Nebraska - Lincoln.

Authors

Elliott R. Jacobson, Pamela E. Ginn, J. Mitchell Troutman, Lisa Farina, Lillian Stark, Kaci Klenk, Kristen L. Burkhalter, and Nicholas Komar

WEST NILE VIRUS INFECTION IN FARMED AMERICAN ALLIGATORS (*ALLIGATOR MISSISSIPPIENSIS*) IN FLORIDA

Elliott R. Jacobson,^{1,5} Pamela E. Ginn,¹ J. Mitchell Troutman,¹ Lisa Farina,¹ Lillian Stark,²
Kaci Klenk,^{3,4} Kristen L. Burkhalter,³ and Nicholas Komar³

¹ College of Veterinary Medicine, University of Florida, Gainesville, Florida 32610, USA

² Florida Department of Health Bureau of Laboratories, Tampa, Florida 33612, USA

³ Division of Vector-Borne Infectious Diseases, Centers for Disease Control and Prevention, Fort Collins, Colorado 80522-2089, USA

⁴ Current address: USDA National Wildlife Research Center, Fort Collins, Colorado 80521, USA

⁵ Corresponding author (email: jacobsons@mail.vetmed.ufl.edu)

ABSTRACT: In September and October 2002, an epizootic of neurologic disease occurred at an alligator farm in Florida (USA). Three affected American alligators (*Alligator mississippiensis*) were euthanatized and necropsied, and results confirmed infection with West Nile virus (WNV). The most significant microscopic lesions were a moderate heterophilic to lymphoplasmacytic meningoencephalomyelitis, necrotizing hepatitis and splenitis, pancreatic necrosis, myocardial degeneration with necrosis, mild interstitial pneumonia, heterophilic necrotizing stomatitis, and glossitis. Immunohistochemistry identified WNV antigen, with the most intense staining in liver, pancreas, spleen, and brain. Virus isolation and RNA detection by reverse transcription–polymerase chain reaction confirmed WNV infection in plasma and tissue samples. Of the tissues, liver had the highest viral loads (maximum $10^{8.9}$ plaque-forming units [PFU]/ 0.5cm^3), whereas brain and spinal cord had the lowest viral loads (maximum $10^{6.6}$ PFU/ 0.5cm^3 each). Virus titers in plasma ranged from $10^{3.6}$ to $10^{6.5}$ PFU/ml, exceeding the threshold needed to infect *Culex quinquefasciatus* mosquitoes (10^5 PFU/ml). Thus, alligators may serve as a vertebrate amplifying host for WNV.

Key words: *Alligator mississippiensis*, American alligator, infection, molecular virology, pathology, West Nile Virus.

INTRODUCTION

West Nile virus (WNV) is a mosquito-borne flavivirus (Family *Flaviviridae*) that is transmitted by various species of adult *Culex* mosquitoes to a variety of mammals and birds (Hayes, 1989). It emerged in North America in 1999 when it infected and caused the deaths of people, horses, and birds in New York (USA) (Komar, 2000). By the year 2001, WNV had spread into the southeastern US, including Florida (USA) (Blackmore et al., 2003). The continued expansion of WNV in North America presents an emerging threat to human and animal health in the Western Hemisphere.

Reptiles are known to be infected with several mosquito-borne viruses. Western equine encephalomyelitis virus (Family *Togaviridae*) was isolated from blood and found to overwinter in garter snakes (*Thamnophis* spp.; Thomas and Eklund, 1962; Gebhardt et al., 1973) and the Texas

tortoise (*Gopherus berlandieri*; Bowen, 1977). Japanese encephalitis virus (Family *Flaviviridae*) was isolated from Chinese rat snakes (*Elaphe rufodorsata*) in Korea (Lee et al., 1972). In a survey in Venezuela, tegu lizards (*Tupinambis nigropunctatus*) were found to have antibody against eastern equine encephalomyelitis (EEE; Family *Togaviridae*) and Venezuelan encephalitis viruses (Family *Togaviridae*; Walder et al., 1984). In crocodylians, seropositive wild American alligators (*Alligator mississippiensis*) for EEE virus (Karstad, 1961) and farmed Nile crocodiles (*Crocodylus niloticus*) in Israel for WNV (Steinman et al., 2003) have been reported. Recently, mortality associated with WNV infection was reported in farmed American alligators in Georgia, USA (Miller et al., 2003). There are no additional reports of WNV in reptiles (Komar, 2003). Here we report an outbreak of WNV infection in farmed American alligators in Florida. Viremia

data are presented that implicate the American alligator as a potential amplifying host for WNV in southeastern North America.

MATERIALS AND METHODS

Animals

Between early September and mid-October 2002, a central Florida alligator farm (28°32'N, 80°56'W) had a large die-off of alligators that were up to 1.3 m in length and up to 3 yr old. Alligators were kept at a constant ambient temperature of 32 C in water-filled igloo-shaped or rectangular concrete pens, which on average held approximately 200 animals of approximately the same size and age. The igloo-shaped pens had 848–897 l of water and the rectangular pens had 799–3,464 l of water. Pens were kept dark and completely enclosed with the exception of narrow gaps around the entry door for feeding or maintenance. Pens were provided with chlorine-treated well water that was drained and refilled three times a week. Alligators were maintained on a diet of ground beef and alligator chow (Burris Alligator Food, Burris Mill and Feed, Franklinton, Louisiana, USA).

Pens with affected and unaffected alligators were randomly dispersed. Mortality was highest in the youngest alligators, with up to 56 dying per pen, whereas older alligators died at up to 32 per pen. Approximately 300 from a population of 9,000 (3.33% of the total population) died over a 2-mo period. Clinical signs included anorexia, lethargy, intention tremors, swimming on their sides, spinning in the water, and opisthotonus. Death occurred 24–48 hr after onset of clinical signs. All alligators on the farm were hatched from wild collected eggs that were purchased from the Florida Department of Fish and Wildlife Conservation Commission.

Three of the youngest alligators (<30.5 cm long and less than 1 mo old) with signs of neurologic disease were submitted alive to the University of Florida College of Veterinary Medicine (Gainesville, Florida) for physical examination and pathologic investigations. Blood was obtained from the supravertebral vein and plasma was removed and frozen at –70 C.

Pathology

The three alligators were euthanatized with an intracoelomic cavity injection of pentobarbital (80 mg/kg of body weight). Tissues collected at necropsy and examined histologically were heart, lung, liver, spleen, kidney, brain, spinal cord, adrenal gland, pharyngeal mucosa, small intestine, pancreas, and tongue. Tissues

were fixed in 10% neutral phosphate-buffered formalin, routinely processed, sectioned at 5 μ m, and stained with hematoxylin and eosin. Tissues from major organs were also frozen and stored at –80 C for virus isolation and viral RNA detection by reverse transcription–polymerase chain reaction (RT-PCR).

Immunohistochemistry (IHC) was used to identify tissues infected with WNV and to determine cellular tropism of the virus. Formalin-fixed paraffin-embedded 5- μ m sections of brain, spinal cord, liver, lung, spleen, kidney, small intestine, pancreas, and pharyngeal mucosa were mounted on positively charged slides. A mouse monoclonal antibody to WNV (BioReliance, Rockville, Maryland, USA) diluted 1:200 in Dako antibody diluent (Dako Corporation, Carpinteria, California, USA) served as the primary antibody and a standard immunoperoxidase protocol was implemented according to the manufacturer's directions (Dako Envision System, Dako Corporation) using 3,3'-diaminobenzidine as the chromogen and hematoxylin as a counterstain. Before incubation with the primary antibody, tissue sections were treated with 40 μ l of proteinase K (Dako Corporation) diluted in 2 ml of Tris HCl buffer at room temperature for 5 min, followed by peroxidase blocking for 5 min at room temperature in 0.03% H₂O₂. A section of equine brain from a WNV-infected horse served as a positive control. Substitution of the primary antibody with normal mouse serum served as a negative control.

Immunohistochemistry also was used to determine the presence of chlamydial antigen. A monoclonal antibody (Virostat 1631, Virostat, Portland, Maine) that recognizes chlamydial LPS antigen including serotypes of *Chlamydia trachomatis*, *Chlamydophila psittaci*, and *Chlamydophila pneumoniae*, was used as the primary antibody. The working dilution was 1:10 in blocking buffer and the IHC procedure was the same as above. Liver from a puff adder (*Bitis arietans*) with chlamydiosis served as the positive control (Jacobson et al., 2002).

Microbiology

Blood, portions of lung, and swabs of the oral cavity were obtained from the alligators and cultured for *Mycoplasma alligatoris* using previously described methods (Brown et al., 2001).

Portions of frozen heart, liver, lung, kidney, spinal cord, and brain from the three alligators were processed for WNV isolation by plaque assay in Vero cells as previously described (Pannella et al., 2001). Plasma samples also were submitted and were treated as clarified tissue homogenates. Viral titers in all specimens were

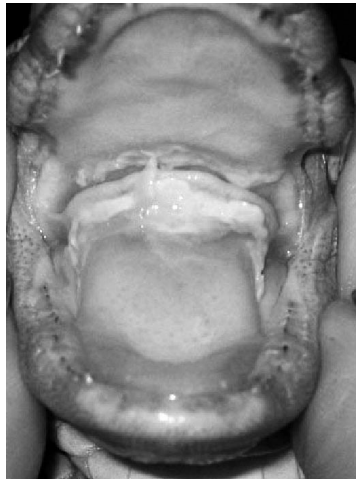


FIGURE 1. Oral cavity of a hatchling alligator with necrotizing pharyngitis. Fibrinous material and exudate can be seen covering the base of the tongue and palate.

quantified by plaque assay of serial 10-fold dilutions.

Infected cell culture supernatants and tissue homogenates were examined for the presence of WNV RNA using a TaqMan RT-PCR assay (Lanciotti et al., 2000). RNA was extracted from a 140- μ l aliquot of each sample using a QIAamp Viral RNA mini Kit (Qiagen Inc, Valencia, California) according to manufacturer's instructions. The RT-PCR was performed using the ABI Prism 7000 Sequence Detection System (Applied Biosystems, Foster City, California) or the Bio-Rad Icyler IQ[®] Real-Time Detection System (Bio-Rad, Hercules, California) according to manufacturers' specifications. Selected viral harvests from plaque assays were identified as WNV using a WNV-specific antigen detection assay (Medical Analysis Systems, Inc., Camarillo, California; Ryan et al., 2003).

RESULTS

Clinical findings

The three alligators weighed 110.4 gm, 191.8 gm, and 238.3 gm respectively. No muscle atrophy was evident and no lesions were seen affecting the integumentary system. The eyes were clear and a blink response was present. Each alligator had a mildly distended abdomen and all had fibrinonecrotic material in the oral cavity just cranial to the glottal flap (Fig. 1). Two alligators were listless and depressed. One alligator exhibited intention tremors, indi-

cating central nervous system (CNS) disease.

Pathologic findings

The coelomic cavities of each alligator contained moderately sized fat bodies and approximately 3–5 ml of clear yellow fluid. The liver in each case was slightly enlarged with rounded edges and mottled yellow to red. The spleens and areas of the myocardium were mottled tan to red. All other organs were grossly within normal limits.

Light microscopic abnormalities were similar for the three alligators. The liver was characterized by randomly scattered individual or clusters of necrotic hepatocytes accompanied by mild infiltrates of heterophils. Kupffer cells often contained cell debris (Fig. 2A). Portal regions had mild bile ductular hyperplasia and fibrosis and a mild to moderate infiltrate of heterophils, lymphocytes, and plasma cells. Occasional hepatocytes contained lipid vacuoles. The myocardium had mild infiltrates of plasma cells, lymphocytes, heterophils, and macrophages. Scattered single to small groups of degenerating and necrotic myocardial fibers characterized by hyper eosinophilia, fragmentation, and occasional nuclear pyknosis were present. In the kidneys, rare tubular epithelial cells were necrotic. The renal interstitium had minimal infiltrates of lymphocytes and plasma cells. The small intestine had a mild to moderate infiltrate of lymphocytes, plasma cells, and heterophils and mild enterocyte necrosis and hyperplasia. The pancreas had widespread necrosis of acinar cells (Fig. 2B). The adrenal glands were moderately edematous and had a mild heterophilic infiltrate and mild individual cell necrosis. The pharyngeal mucosa was mildly hyperplastic with multifocal epithelial cell necrosis and mild intraepithelial heterophilic infiltrates. In some areas, there were extensive areas of ulceration covered with a dense layer of necrotic cellular debris. The submucosa was edematous with mild to moderate perivascular infiltrates of lymphocytes and

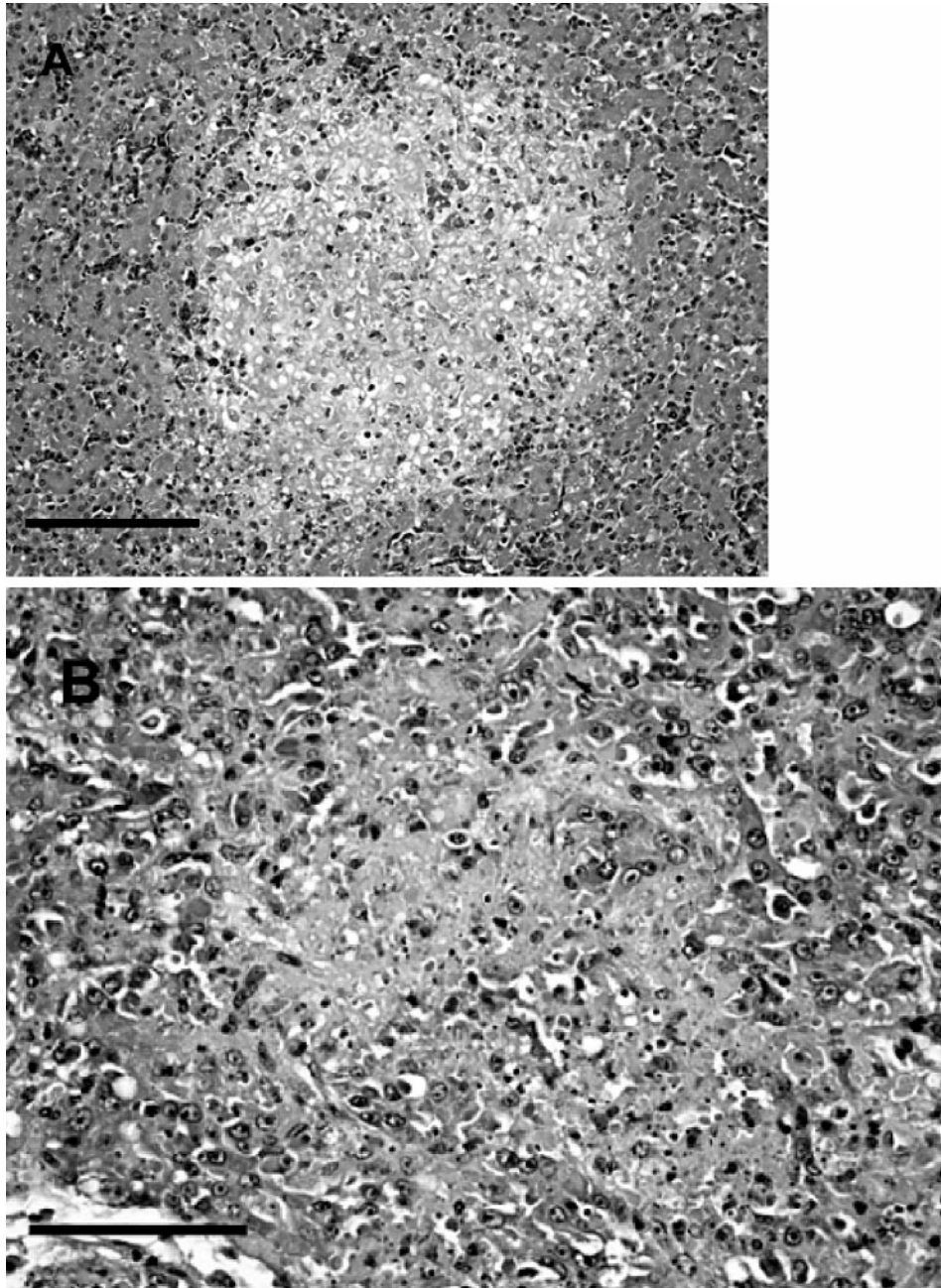


FIGURE 2. Organs from an alligator with West Nile virus infection. (A) Liver. Note the area of hepatocellular necrosis and infiltrates of leukocytes. H&E stain. Bar=200 μ m. (B) Pancreas. Note the extensive necrosis of pancreatic acinar cells. H&E stain. Bar=100 μ m.

plasma cells. The lungs were characterized by a moderate heterophilic to lymphoplasmacytic interstitial pneumonia and mild respiratory epithelial cell hyperplasia. The spleen had a moderate infiltrate of heter-

ophils and plasma cells and was depleted of lymphocytes and contained large amounts of cellular debris frequently phagocytosed by numerous macrophages. A moderate to severe heterophilic to lym-

phoplasmacytic meningoencephalomyelitis affected the brain and spinal cord (Fig. 3A). Vessels were surrounded by dense cuffs of mononuclear leukocytes and heterophils, which extended to a milder degree into the neuropil (Fig. 3B). Both grey and white matter were affected. The cerebellum was affected to a more severe degree than other areas of the brain. In some areas, the meninges and Virchow-Robin spaces were heavily infiltrated primarily by heterophils.

Immunohistochemistry

Immunostaining indicated the presence of WNV antigen in multiple tissues. In the liver, degenerating and necrotic hepatocytes, Kupffer cells, and some leukocytes within sinusoids contained antigen. Small numbers of macrophages within the inflamed pharyngeal mucosa contained antigen. Large numbers of splenic macrophages contained antigen. The pancreas had widespread labeling of acinar cells. Occasional enterocytes and leukocytes within the lamina propria of the small intestine contained antigen as well as small number of renal tubular epithelial cells. In the brain and spinal cord, small numbers of neurons and mononuclear leukocytes in perivascular regions and within the neuropil were labeled (Fig. 4). Immunohistochemical staining for chlamydial antigen was negative.

Microbiology

Blood, lung, and throat swabs from each alligator submitted for *M. alligatoris* isolation yielded no growth.

All tissue homogenates tested positive for WNV RNA. Viral plaques were detected after 3 days of culture, and identity of WNV was confirmed by antigen detection. Of the tissues, liver had the highest viral loads (maximum $10^{8.9}$ plaque forming units [PFU]/ 0.5cm^3), whereas brain and spinal cord had the lowest viral loads (maximum $10^{6.6}$ PFU/ 0.5cm^3 each (Table 1). Viral loads in plasma ranging from $10^{3.6}$ to

$10^{6.5}$ PFU/ml confirmed viremia in each of the alligators.

DISCUSSION

There is a paucity of information on causes of mortality in both farmed and wild alligators. Some information is available for crocodiles being farmed in Australia, New Guinea, Africa, and Thailand (Foggin, 1987; Ladds and Sims, 1990; Buenviaje et al., 1994; Youngprapakorn et al., 1995; Huchzermeyer, 2003). For the most part, alligator farmers in Florida and elsewhere in the US do not routinely submit dead and dying alligators for thorough postmortem evaluations. Such is the case for the alligators of the present case report. At the time of the outbreak at the farm in Florida, the owner received information that other farms were affected. However, no alligators were submitted for postmortem evaluations from these farms.

Many ill alligators at the affected farm in Florida exhibited signs of CNS disease. Little is known about the causes of CNS disease in alligators and other crocodilians. Adult alligators dying in Lake Griffin (306 deaths), a lake in central Florida, from December 1998 through November 2000 were found to have clinical signs of CNS disease that included swimming in circles, inability to submerge, lethargy, weakness, unresponsiveness, slow reflexes, dragging the dorsal surfaces of the hind feet, head tilt, and anisocoria (Schoeb et al., 2002). Histopathology identified necrosis of the torus semicircularis of the midbrain. The lesions seen in the brains of the three alligators of this report revealed inflammatory infiltrates that were distinct from the lesions seen in the alligators in Lake Griffin.

Because mycoplasmosis is a recognized disease in farmed alligators in Florida, and can infect the CNS causing weakness and limb paresis (Clippinger et al., 2000), attempts were made to culture mycoplasma from tissues and blood of the submitted alligators. Mycoplasma was not isolated. Although hepatitis can be seen in alligator

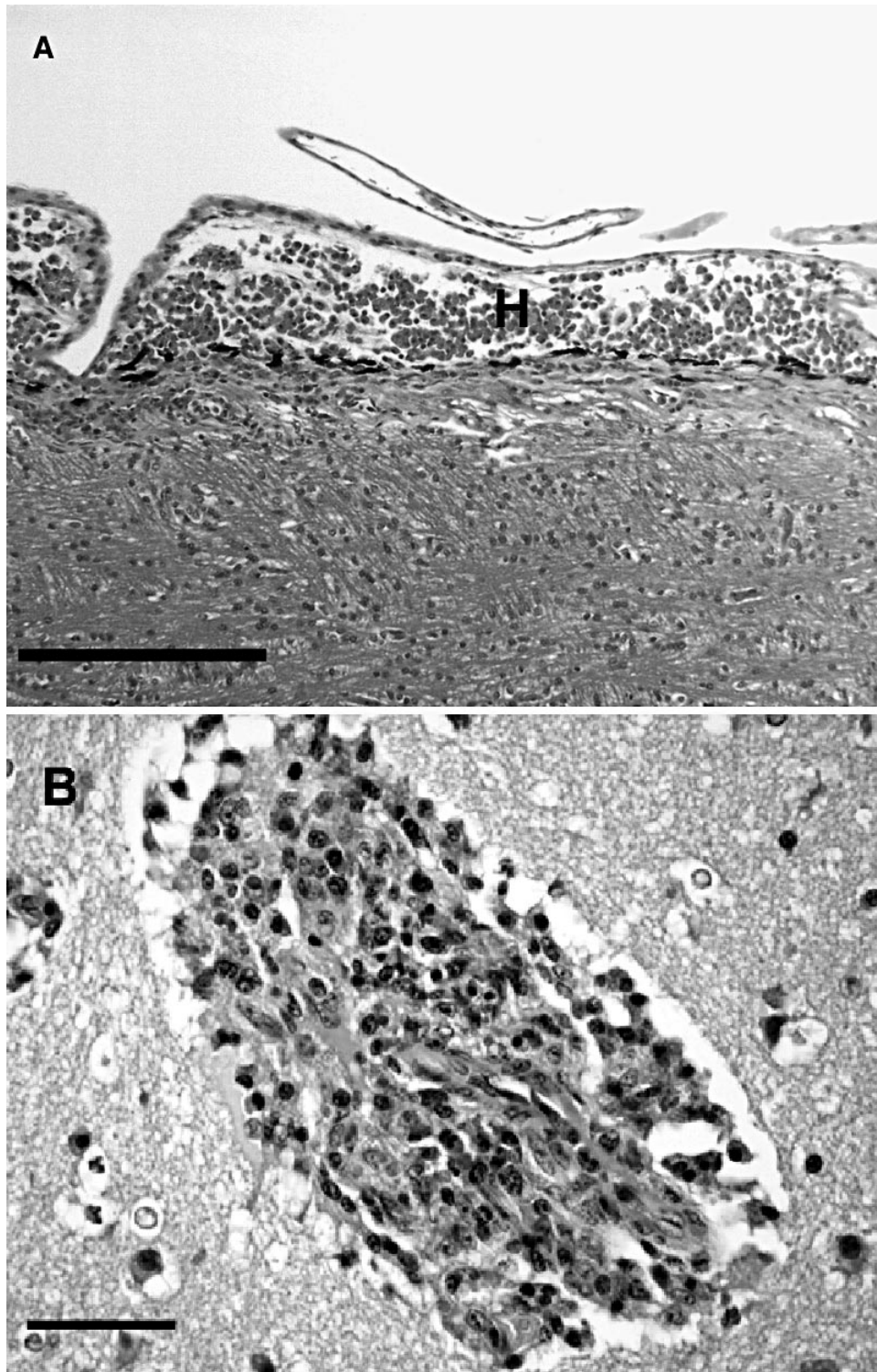


FIGURE 3. Cerebrum of an alligator with meningoencephalitis due to West Nile virus infection. (A) Note the meningeal infiltrate of heterophils (H). H&E stain. Bar=200 μ m. (B) Note the dense perivascular cuff of mononuclear leukocytes and heterophils. H&E stain. Bar=50 μ m.

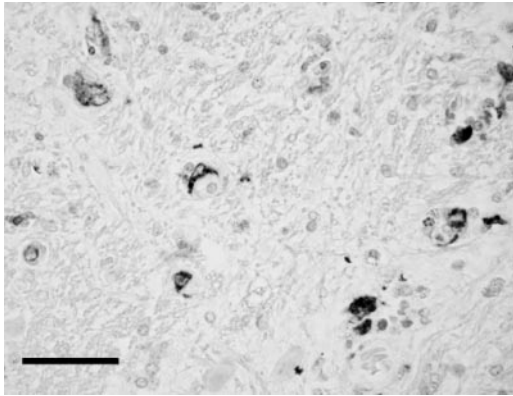


FIGURE 4. Brain of an alligator with West Nile virus encephalitis. Note labeling of neurons and leukocytes within the neuropil. Immunoperoxidase stain. Bar=50 μ m.

mycoplasmosis, the hepatitis seen in the alligators in the current case report was necrotizing and primarily heterophilic compared to that in mycoplasmosis, which consists of a variable portal to periportal lymphocytic hepatitis. The pneumonia in alligator mycoplasmosis is predominantly proliferative compared to interstitial in WNV-infected alligators in this report and the alligators infected with WNV had myocardial necrosis compared to fibrinous pericarditis in alligators infected with mycoplasma. Joint disease seen in alligators with mycoplasmosis (Clippinger et al., 2000; Brown et al., 2001; Pye et al., 2001) was not seen in the alligators of this report.

Because *Chlamydia* has been identified and believed to be responsible for hepatitis in farmed Nile crocodiles in South Africa (Huchzermeyer et al., 1994), an IHC staining procedure using a monoclonal an-

tibody against *Chlamydia* LPS antigen was used to assay for the presence of this pathogen. This monoclonal antibody has been used to detect chlamydial antigen in other reptiles (Jacobson et al., 2002). No labeling for chlamydial antigen was present in tissues of alligators of this report.

At the time the sick alligators in this study were evaluated by us, there were no published accounts of WNV disease in alligators or other reptiles. Attempts to show that reptiles and amphibians may contribute to WNV transmission as amplifying hosts in North America failed using three other species of reptiles and the American bullfrog (*Rana catesbiana*) (Klenk and Komar, 2003). Still, because of WNV activity in birds, horses, and humans in Florida (Blackmore et al., 2003), an investigation into the possible role of WNV in the outbreak of neurological disease in alligators was warranted. At approximately the same time a large die-off of farmed alligators was associated with WNV infection in Georgia (Miller et al., 2003).

Histologic lesions and positive labeling for WNV IHC in the Florida alligators were similar to that reported in birds with WNV in that similar organs were affected by necrosis and lymphoplasmacytic to heterophilic inflammation (Steele et al., 2000). The lesions reported in birds, however, were more severe in some organs (CNS, heart, kidney, intestines) than those seen in the alligators of this report. West Nile virus-infected alligators in Georgia (Miller et al., 2003) had lesions in the CNS and in some cases, parenchymal organs,

TABLE 1. West Nile viral loads determined by Vero plaque assay for plasma and selected tissues of three alligators.

Alligator	Plasma (log ₁₀ PFU/mL)	Tissue (log ₁₀ PFU ^a /0.5 cm ³)					
		Heart	Liver	Lung	Kidney	Spinal cord	Brain
A	6.0	7.9	8.9	8.9	8.3	6.6	NT ^b
B	6.5	7.6	8.9	7.1	8.3	5.3	5.2
C	3.6	8.4	8.8	7.9	8.3	5.2	6.6

^a PFU = plaque forming units.

^b NT = not tested.

that were similar to the alligators in this report; however, we did not observe lesions attributed to systemic bacterial infections as was documented in the alligators from Georgia.

Viral loads in alligator tissues were similar in magnitude to viral loads detected in fatal cases of WNV infection in experimentally infected corvids (Komar et al., 2003). One notable difference was the higher virus titer in liver of affected alligators compared to the liver of crows, which have lower viral loads compared with other organs (Steele et al., 2000; Komar et al., 2003).

The finding of viremia greater than $10^{5.0}$ PFU/ml plasma suggests that WNV-infected alligators may be infectious to mosquitoes. This level of viremia was shown to be the threshold above which *Culex pipiens* and *C. quinquefasciatus* mosquitoes become infected (Turell et al., 2000; Sardelis et al., 2001). *Culex quinquefasciatus* is one of the principle vectors of WNV in Florida (Blackmore et al., 2003), suggesting that alligators, like some bird species, may serve as a vertebrate amplifying host. This differs from dead-end hosts such as humans and horses in which the virus is unlikely to be transmitted to mosquitoes to perpetuate the transmission cycle. It is suspected that certain arboviruses such as western equine encephalomyelitis virus can overwinter in certain poikilotherms such as tortoises and snakes (Gebhardt et al., 1973; Bowen, 1977). This may also occur with WNV in alligators and thus needs to be investigated.

Alligators are derived from the same phylogenetic lineage common to birds (Hedges, 1994). Alligators and certain birds may share biologic attributes that allow WNV to replicate to infectious levels in these hosts. Not all birds, however, develop infectious viremias (Komar, 2003; Komar et al., 2003), and of the 23 species of crocodylians, we do not know the range of their susceptibility to WNV. Since differential pathogenicity of *M. alligatoris* has been demonstrated in crocodylians, with

Siamese crocodiles (*Crocodylus siamensis*) resistant to pathogenic effects (Pye et al., 2001), similar differential pathogenicity in crocodylians may be seen with WNV. For instance, although serum neutralization results indicated that 70% of Nile crocodiles sampled at two farms in Israel were seropositive for exposure to WNV, no mortality was seen (Steinman et al., 2003).

Florida is one of several southeastern states in the US where alligators are farmed for meat and hides. In Florida, there are approximately 49 alligator farming operations. Of these, 19 have more than 1,000 alligators at any one time. At these farms, alligators are generally reared under highly controlled environmental conditions to achieve maximal growth rates in the shortest period of time. Since growth rates are directly influenced by environmental temperature, they are often raised in pens maintained at an ambient temperature of 32 C. The alligators in the current report were from pens kept at this temperature for up to 3 yr while they matured. Because alligators are typically housed in large numbers, they are also kept in the dark to reduce aggression and damage to their hides. These conditions are in contrast to fluctuating environmental conditions that wild alligators encounter throughout their life. The body temperature of wild alligators typically fluctuates both daily and seasonally. Since alligators are from a temperate climate, winter months are typically cool with minimum growth rates. Although the affected farm was adjacent to a tourist attraction where adult alligators were kept outdoors under fluctuating environmental conditions, no deaths or signs of CNS disease were seen in these older and larger alligators.

Body temperature affects the immune system of all reptiles (Ambrosius 1976; Cooper et al., 1988) and environmental temperatures directly affect body temperature of alligators. Environmental temperature is known to affect both the humoral response to antigens and graft rejection in

reptiles (Cooper et al., 1988). Although there is little scientific information on the effect of varying body temperatures on susceptibility to infection with different pathogens, there is some evidence to support the notion of an ideal body temperature for infection of reptiles with certain pathogens. For instance, a paramyxovirus known to infect snakes optimally replicates in cell cultures at 27–33 C, with less efficient replication at 37 C (Clark et al., 1979). Studies are needed to investigate the interplay between environmental temperature and age on the ability of WNV to infect alligators, establish a viremia, and cause lesions in the CNS.

We do not know how WNV infected the alligators at the farm. Miller et al (2003) provided evidence that horsemeat fed to alligators in Georgia in 2002 was contaminated with WNV genetic material, suggesting that contaminated feed may have been the source for late fall epizootics occurring in 2001 and 2002. They suggested that WNV-infected horses sold for food consumption may have inadvertently been fed to alligators, and linked the late fall seasonality of WNV outbreaks in farmed alligators with the peak of WNV infection in horses. In contrast, no horsemeat (only beef and alligator chow) was fed to the alligators that are the subject of this report. At the Florida farm, frozen beef was defrosted in the open and may have been contaminated by feces of wild birds. Numerous bird species have been shown to shed WNV per cloaca, presumably leading to fecal contamination (Langevin et al., 2001; Komar et al., 2003).

The epizootics in Florida and Georgia occurred during September through October, the peak period for WNV infection in horses in Florida. Mosquitoes have been seen feeding upon alligators at other alligator farms in Florida, but the species of mosquitoes feeding upon alligators and their ability to transmit WNV await further studies. Because of the high viral titers in tissues of these alligators, WNV may be shed through the feces into the water, re-

sulting in horizontal transmission. Although we did not attempt to determine viral shedding in the feces of the alligators we necropsied, this has now been observed in experimentally infected alligators that shed virus per cloaca and infected pen-mates in the absence of mosquitoes (Klenk et al., 2004). All three WNV-infected alligators had oral lesions. Although the exact cause of these lesions is unknown, virus may have been able to infect the alligators through damaged mucosal tissues.

Mosquitoes may have infected alligators with WNV, followed by subsequent spread between alligators. Morbidity and mortality in the affected farm appeared to be restricted to certain pens, suggesting that direct transmission among alligators may have been occurring. Mosquito trapping studies are ongoing at the affected farm to identify the species and determine which feed upon alligators.

Further work is needed to better understand the impact of WNV on farmed and wild alligators. Experimental transmission studies of juvenile alligators taken from Florida farms have confirmed that alligators are susceptible to WNV infection, develop high levels of WNV viremia capable of infecting mosquitoes, and occasionally develop clinical signs as a result of the infection (Klenk et al., 2004).

The effect of WNV in wild alligators is unknown. It is rare to find dead alligators in the wild unless there is massive mortality. Die-offs that are seen are generally in populations being monitored for biologic studies or are being harvested. If young animals were at a greater risk to illness and death from WNV than adults, die-offs in these young animals would most likely be missed. In the absence of recognized die-offs, serologic surveys are a very practical method of monitoring populations for outbreaks of disease. Recently, an indirect enzyme-linked immunosorbent assay was developed and validated for determining antibodies to WNV in alligators (Jacobson et al., 2005), a tool that will be useful in eval-

uating the impact of WNV on alligator populations. A serologic survey from northern to southern Florida indicated low seroprevalence to WNV in wild populations of alligators (Jacobson et al., 2005). This probably indicates that epizootics of disease or mortality events due to WNV in wild alligators have not occurred at these sampling sites. This survey will serve as a baseline for future seroepidemiologic studies.

ACKNOWLEDGMENTS

We are grateful to G. Eldred, J. Velez, D. Kazanis, R. Krueger, M. Casteneda, and R. Schofield for laboratory assistance. We also thank F. S. Kennedy, Veterinary Pathology Services, for initially describing an encephalitis in a farmed alligator that led to case submissions of the alligators in this report to the University of Florida. Published as University of Florida College of Veterinary Medicine, Journal Series 636.

LITERATURE CITED

- AMBROSIUS, H. 1976. Immunoglobulins and antibody production in reptiles. *In* Comparative Immunology, J. J. Marchalonis (ed.). Blackwell Scientific, Oxford, UK, pp. 298–334.
- BLACKMORE, C. G. M., L. M. STARK, W. C. JETER, R. L. OLIVERI, R. G. BROOKS, L. A. CONTI, AND S. T. WIERSMA. 2003. Surveillance results from the first West Nile virus transmission season in Florida, 2001. *American Journal of Tropical Medicine and Hygiene* 69: 141–150.
- BOWEN, G. S. 1977. Prolonged western equine encephalitis viremia in the Texas tortoise (*Gopherus berlandieri*). *American Journal of Tropical Medicine and Hygiene* 26: 171–175.
- BROWN, D. R., M. F. NOGUEIRA, T. R. SCHOEB, K. A. VLIET, R. A. BENNETT, G. W. PYE, AND E. R. JACOBSON. 2001. Pathology of experimental mycoplasmosis in American alligators. *Journal of Wildlife Diseases* 37: 671–679.
- BUENVIAJE, G., P. W. LADDS, L. MELVILLE, AND S. C. MANOLIS. 1994. Disease-husbandry associations in farmed crocodiles in Queensland and the Northern Territory. *Australian Veterinary Journal* 71: 165–173.
- CLARK, H. F., F. S. LIEF, P. D. LUNGER, D. WATERS, P. LELOUP, D. W. FOELSCH, AND R. W. WYLER. 1979. Fer de Lance virus (FDLV): A probable paramyxovirus isolated from a reptile. *Journal of General Virology* 44: 405–418.
- CLIPPINGER, T. L., R. A. BENNETT, C. M. JOHNSON, K. A. VLIET, S. L. DEEM, J. OROS, E. R. JACOBSON, I. M. SCHUMACHER, AND M. B. BROWN. 2000. Morbidity and mortality associated with a new *Mycoplasma* species from captive American alligators (*Alligator mississippiensis*). *Journal of Zoo and Wildlife Medicine* 31: 303–314.
- COOPER, E. L., A. E. KLEMPAU, AND A. G. ZAPATA. 1988. Reptilian immunity. *In* Biology of the reptilia (16), C. Gans (ed.). University of Chicago Press, Chicago, Illinois, pp. 298–352.
- FOGGIN, C. M. 1987. Diseases and disease control on crocodile farms in Zimbabwe. *In* Wildlife management: Crocodiles and alligators, G. Webb and C. Norton (eds.). Surrey, Beatty & Sons, Pty, Chipping Norton, NSW, Australia, pp. 351–362.
- GEBHARDT, L. P., S. C. ST. JEOR, G. J. STANTON, AND D. A. STRINGFELLOW. 1973. Ecology of western encephalitis virus. *Proceedings of the Society of Experimental Biology and Medicine* 142: 731–733.
- HAYES, C. G. 1989. West Nile fever. *In* The arboviruses: Epidemiology and ecology, Vol V, T. P. Monath (ed.). CRC Press, Boca Raton, Florida, pp. 59–88.
- HEDGES, S. B. 1994. Molecular evidence for the origin of birds. *Proceedings of the National Academy of Science USA* 91: 2621–2624.
- HUCHZERMAYER, F. W. 2003. Crocodiles: Biology, husbandry, and diseases. CABI Publishing, Cambridge, Massachusetts, USA.
- , G. H. GERDES, C. M. FOGGIN, K. D. HUCHZERMAYER, AND L. C. LIMPER. 1994. Hepatitis in farmed hatchling Nile crocodiles (*Crocodylus niloticus*) due to chlamydial infection. *Journal of South African Veterinary Association* 65: 20–22.
- JACOBSON, E., F. ORIGGI, D. HEARD, AND C. DETRISAC. 2002. Immunohistochemical staining of chlamydial antigen in emerald tree boas (*Coralus caninus*). *Journal of Veterinary Diagnostic Investigation* 14: 487–494.
- , A. JOHNSON, J. A. HERNANDEZ, S. J. TUCKER, A. P. DUPUIS, R. STEVENS, D. CARBONNAU, AND L. STARK. 2005. Validation and use of an indirect enzyme-linked immunosorbent assay for detection of antibodies to West Nile Virus in American alligators (*Alligator mississippiensis*) in Florida. *Journal of Wildlife Diseases* 41: 107–114.
- KARSTAD, L. 1961. Reptiles as possible reservoir hosts for eastern encephalitis virus. *Transactions of the 26th North American Wildlife and National Resources Conference, Wildlife Management Institute, Washington, D.C.*, pp. 185–202.
- KLENK, K., AND N. KOMAR. 2003. Poor replication of West Nile virus (New York 1999 strain) in three reptilian and one amphibian species. *American Journal of Tropical Medicine and Hygiene* 69: 260–262.
- , J. SNOW, K. MORGAN, R. BOWEN, M. STEPHENS, F. FOSTER, P. GORDY, S. BECKETT, N. KOMAR, D. GUBLER, AND M. BUNNING. 2004. Juvenile American alligators (*Alligator mississippiensis*).

- piensis*) as amplifiers of West Nile virus. *Emerging Infectious Diseases* 10: 2150–2155.
- KOMAR, N. 2000. West Nile viral encephalitis. *Review of Science and Technology, Office International des Epizooties* 19: 166–176.
- . 2003. West Nile virus: Epidemiology and ecology in North America. *Advances in Virus Research* 61: 185–234.
- , S. LANGEVIN, S. HINTEN, N. NEMETH, E. EDWARDS, D. HETTLER, B. DAVIS, R. BOWEN, AND M. BUNNING. 2003. Experimental infection of the New York 1999 strain of West Nile virus in North American birds. *Emerging Infectious Diseases* 9: 311–322.
- LADDS, P. W., AND L. D. SIMS. 1990. Diseases of young captive crocodiles in Papua New Guinea. *Australian Veterinary Journal* 67: 323–330.
- LANCIOTTI, R. S., A. J. KERST, R. S. NASCI, M. S. GODSEY, C. J. MITCHELL, H. M. SAVAGE, N. KOMAR, N. A. PANELLA, B. C. ALLEN, K. E. VOLPE, B. S. DAVIS, AND J. T. ROEHRIG. 2000. Rapid detection of West Nile virus from human clinical specimens, field-collected mosquitoes, and avian samples by a TaqMan reverse transcriptase-PCR assay. *Journal of Clinical Microbiology* 38: 4066–4071.
- LANGEVIN, S. A., M. BUNNING, B. DAVIS, AND N. KOMAR. 2001. Experimental infection of chickens as candidate sentinels for West Nile virus. *Emerging Infectious Diseases* 7: 726–729.
- LEE, H. W., B. W. MIN, AND Y. W. LIM. 1972. Isolation and serologic studies of Japanese encephalitis virus from snakes in Korea. *Journal of the Korean Medical Association* 15: 69–74.
- MILLER, D. L., M. J. MAUEL, C. BALDWIN, G. BURTLE, D. INGRAM, M. E. HINES II, AND K. S. FRAZIER. 2003. West Nile virus in farmed alligators. *Emerging Infectious Diseases* 9: 794–799.
- PANELLA, N. A., A. J. KERST, R. S. LANCIOTTI, P. BRYANT, B. WOLF, AND N. KOMAR. 2001. Comparative West Nile virus detection in organs of naturally infected American crows (*Corvus brachyrhynchos*). *Emerging Infectious Diseases* 7: 754–755.
- PYE, G. W., D. R. BROWN, M. F. NOGUEIRA, K. A. VLIET, T. R. SCHOEB, E. R. JACOBSON, AND R. A. BENNETT. 2001. Experimental inoculation of broad-nosed caimans (*Caiman latirostris*) and Siamese crocodiles (*Crocodylus siamensis*) with *Mycoplasma alligatoris*. *Journal of Zoo and Wildlife Medicine* 32: 196–201.
- RYAN, J., K. DAVE, E. EMMERICH, B. FERNANDEZ, M. TURELL, J. JOHNSON, K. GOTTFRIED, K. BURKHALTER, A. KERST, A. HUNT, R. WIRTZ, AND R. NASCI. 2003. Wicking assays for the rapid detection of West Nile and St. Louis encephalitis viral antigens in mosquitoes (Diptera: Culicidae). *Journal of Medical Entomology* 40: 95–99.
- Sardelis, M. R., M. J. Turell, D. J. Dohm, and M. L. O'Guinn. 2001. Vector competence of selected North American Culex and Coquillettia mosquitoes for West Nile virus. *Emerging Infectious Diseases* 7: 1018–1022.
- SCHOEB, T. R., T. G. HEATON-JONES, R. M. CLEMONS, D. A. CARBONNEAU, A. R. WOODWARD, D. SHELTON, AND R. H. POPPENG. 2002. Clinical and necropsy findings associated with increased mortality among American alligators of Lake Griffin, Florida. *Journal of Wildlife Diseases* 38: 320–337.
- STEELE, K. E., M. J. LINN, R. J. SCHOEPP, N. KOMAR, T. W. GEISBERT, R. M. MANDUCA, P. P. CALLE, B. L. RAPHAEL, T. L. CLIPPINGER, T. LARSEN, J. SMITH, R. S. LANCIOTTI, N. A. PANELLA, AND T. S. MCNAMARA. 2000. Pathology of fatal West Nile virus infections in native and exotic birds during the 1999 outbreak in New York City, New York. *Veterinary Pathology* 37: 208–224.
- STEINMAN, A., C. BANET-NOACH, S. TAL, O. LEVI, L. SIMANOV, S. PERK, M. MALKINSON, AND N. SHPIGEL. 2003. West Nile virus infection in crocodiles. *Emerging Infectious Diseases* 9: 887–889.
- THOMAS, L. A., AND C. M. EKLUND. 1962. Overwintering of western equine encephalomyelitis virus in garter snakes experimentally infected by *Culex tarsalis*. *Proceedings of the Society of Experimental Biology and Medicine* 109: 421–424.
- TURELL, M. J., M. O'GUINN, AND J. OLIVER. 2000. Potential for New York mosquitoes to transmit West Nile Virus. *American Journal of Tropical Medicine and Hygiene* 62: 413–414.
- WALDER, R., O. M. SUAREZ, AND C. H. CALISHER. 1984. Arbovirus studies in the Guajira region of Venezuela: Activities of eastern equine encephalitis and Venezuelan equine encephalitis viruses during an interepizootic period. *American Journal of Tropical Medicine and Hygiene* 33: 699–707.
- YOUNGPRAPAKORN, P., L. OUSAVAPLANGCHAI, AND S. KANCHANAPANGKA. 1995. A color atlas of diseases of the crocodile. Style Creative House, Thailand. 76 pp.

Received for publication 13 April 2004.