

Department of Otorhinolaryngology – Head and Neck Surgery
University of Helsinki
Finland

RECURRENT RESPIRATORY PAPILLOMATOSIS – CAUSES AND CONSEQUENCES

Taru Ilmarinen

ACADEMIC DISSERTATION

To be publicly discussed with permission of the Medical Faculty of
the University of Helsinki

in Lecture Hall 2 of Haartman Institute Helsinki

Haartmaninkatu 3 on October 25th, 2013 at 12 noon

Helsinki 2013

Supervised by

Docent Leena-Maija Aaltonen
Department of Otorhinolaryngology – Head and Neck Surgery
Helsinki University Hospital
University of Helsinki, Finland

Professor Anne Pitkäranta
Department of Otorhinolaryngology – Head and Neck Surgery
Helsinki University Hospital
University of Helsinki, Finland

Reviewed by

Docent Eeva Sala
Department of Phoniatics
Turku University Hospital
University of Turku, Finland

Docent Pekka Nieminen
Department of Gynecology and Obstetrics
Helsinki University Hospital
University of Helsinki, Finland

Opponent

Professor Stina Syrjänen
Department of Oral Pathology and Oral Radiology
University of Turku, Finland
Department of Pathology
Turku University Hospital

Cover: Olli Vaskelainen

ISBN 978-952-10-9320-3 (pbk.)

ISBN 978-952-10-9321-0 (PDF)

Unigrafia Oy, Helsinki 2013

CONTENTS

Abstract.....	5
Tiivistelmä	7
List of original publications	10
Abbreviations	11
1 Introduction.....	12
2 Review of the literature	15
2.1 HPV	15
2.1.1 General aspects	15
2.1.2 HPV transmission	16
2.1.3 HPV structure and mechanism of action	17
2.1.4 Methods for HPV detection	18
2.1.5 Immunological aspects	20
2.1.6 HPV-induced carcinogenesis	20
2.1.7 HPV vaccines.....	21
2.2 Recurrent respiratory papillomatosis	23
2.2.1 Clinical features	23
2.2.2 Epidemiology	24
2.2.3 Surgical treatment	25
2.2.4 Cidofovir	26
2.2.5 Other adjuvant modalities	28
2.2.6 Health-related quality of life	29
2.2.7 Functional assessment of voice	31
2.2.8 Malignant transformation of RRP	33
2.3 Toll-like receptors in HPV-associated carcinogenesis	35
3 Aims of the study	36
4 Patients and methods	37

4.1	Clinical features, health-related quality of life and adult voice in JORRP (Study I)	37
4.2	Safety of intralesional cidofovir in RRP (Study II)	38
4.3	Malignant transformation of RRP (Study III)	39
4.4	Transmission of HPV DNA from patients to health care personnel (Study IV)	41
4.5	Statistical analyses	42
4.6	Ethics	43
5	Results	44
5.1	Clinical features, health-related quality of life and adult voice in JORRP (Study I)	44
5.2	Safety of intralesional cidofovir in RRP (Study II)	46
5.3	Malignant transformation of RRP (Study III)	48
5.4	Transmission of HPV DNA from patients to health care personnel (Study IV)	49
6	Discussion	51
6.1	JORRP as a risk factor for permanent laryngeal pathology and voice disturbances in adulthood	51
6.2	Safety of intralesional cidofovir in RRP	52
6.3	Malignant transformation rate of RRP and expression of TLRs in laryngeal papillomas converting into laryngeal SCC	54
6.4	Transmission of HPV DNA from patients to health care personnel	57
7	Conclusions	59
	Acknowledgements	60
	References	63
	Original publications	

ABSTRACT

Some manifestations of human papillomavirus (HPV) infection are indolent and self-limiting, while others cause considerable morbidity. In recurrent respiratory papillomatosis (RRP), low-risk HPV types within the respiratory tract cause wart-like lesions, typically on vocal folds. The most common symptom is hoarseness, but stridor may also occur due to airway obstruction. In a minority of patients, the disease becomes aggressive and may undergo malignant transformation.

Medical records were reviewed from all patients (n=32) treated for juvenile-onset recurrent respiratory papillomatosis (JORRP) between 1975 and 1994 at Helsinki University Hospital. Eighteen patients participated in a study assessing the effect of JORRP on adult voice quality and health-related quality of life (HRQOL). Compared to age- and gender-matched controls with similar smoking habits, the quality of voice in these adult patients with a history of JORRP was significantly lower in both acoustic and perceptual analyses. Significant differences emerged neither in HRQOL, nor in subjective voice-related handicap.

Despite the viral etiology, treatment of RRP is based on surgery. Patients with frequently relapsing or otherwise aggressive disease may benefit from adjuvant medical therapies, such as local injections of cidofovir. Cidofovir is an antiviral medicine officially indicated for intravenous treatment of cytomegalovirus (CMV) retinitis in patients with acquired immunodeficiency syndrome (AIDS). Intravenous administration of cidofovir has caused nephrotoxic side-effects and neutropenia. Animal studies have raised suspicions of its carcinogenicity. According to its manufacturer, patients treated either by off-label indications, or by an unapproved route of administration (intraocular or topical) have developed severe side-effects.

An international multicenter study collected data from 635 RRP patients, 275 of which were treated with cidofovir. Mean follow-up after the first cidofovir injection was 3.3 years. Differences in incidence of upper respiratory tract

and tracheal malignancies were non-significant between patients treated with and without cidofovir. After local administration of cidofovir, no clinical evidence emerged for nephrotoxicity or neutropenia.

Between 1975 and 2011, a total of 324 RRP patients underwent treatment at Helsinki University Hospital for laryngeal papillomas (LPs). Nine patients (2.8%) developed laryngeal squamous cell carcinoma (SCC). Expression of toll-like receptors (TLRs) 2, 4, and 9 were analyzed in laryngeal tissue specimens from these patients by immunohistochemistry (IHC). Controls were nine RRP patients without malignant transformation, 23 patients clinically presenting with chronic laryngitis, and 19 laryngeal SCC patients without pre-existing RRP. Compared to specimens from those with chronic laryngitis and laryngeal SCC, expression of cytoplasmic TLR4 and TLR9 was significantly lower in LPs. Nuclear TLR4 staining was significantly lower in LPs undergoing transformation into laryngeal SCC, than in LPs without malignant conversion. In laryngeal SCCs, high cytoplasmic staining for TLR4 was associated with higher grade and advanced T stage.

HPV infections are spread through direct contact from skin or mucosa during sexual contact, and from mother to child during labor. Five RRP patients and five patients with genital warts participated with six physicians and 12 nurses in a study investigating transmission of HPV from patients to the oral mucosa and surgical gloves and masks of health care personnel during carbon dioxide (CO₂) laser treatment. HPV deoxyribonucleic acid (DNA) was detected by polymerase chain reaction (PCR) on the surgical gloves, but not on the surgical masks or oral mucosa of health care personnel. Provided that protection is sufficient during CO₂ laser treatment, the risk for HPV transmission to health care personnel seems low.

TIIVISTELMÄ

Osa ihmisen papilloomaviruksen (engl. human papillomavirus, HPV) aiheuttamista infektioista on luonteeltaan hyvänlaatuisia ja itsestään rajoittuvia, kun taas osa tuottaa potilaille merkittävää haittaa. Hengitysteissä ns. matalan syöpäriskin HPV-tyypit aiheuttavat taudin, jossa tyypillisesti äänihuulissa esiintyy toistuvasti hyvänlaatuisia papilloomia (engl. recurrent respiratory papillomatosis, RRP). Äänenkäheys on tavallisin oire, mutta myös myös hengenahdistusta voi esiintyä, jos papilloomat ahtaavat ilmatien. Pienellä osalla potilaista tauti on aggressiivinen ja voi muuttua pahanlaatuiseksi.

Tässä väitöskirjatyössä käytiin läpi kaikkien niiden potilaiden (n=32) sairauskertomukset, joita oli hoidettu lapsuusiällä alkaneen kurkunpään papilloomatoosin takia HYKS korvaklinikalla vuosina 1975-1994. Kahdeksantoista potilasta osallistui tutkimukseen, jossa selvitettiin taudin vaikutuksia aikuisiän äänen- ja elämänlaatuun. Potilaiden akustisesti - ja aistinvaraisesti arvioitu äänen laatu oli merkittävästi heikompi kuin ikä-, tupakointi- ja sukupuolivakioitujen verrokkien. Subjektiiivisesti arvioitu terveyteen liittyvä elämänlaatu ja äänihäiriön aiheuttama haitta ei poikennut merkittävästi potilaiden ja verrokkien välillä.

Hengitysteiden papilloomia hoidetaan kirurgisesti vaikka tauti on viruksen aiheuttama. Usein toistuvassa tai muuten aggressiivisessä taudissa joudutaan turvautumaan ns. liitännäishoitoihin, kuten paikallisiin sidofoviiri-injektioihin. Sidofoviiri on antiviraalinen lääkeaine, jota annetaan virallisen käyttöaiheen mukaan suonensisäisenä infuusiona sytomegaloviruksen aiheuttamaan verkkokalvontulehdukseen AIDS-potilailla. Suonensisäisessä käytössä sidofoviirin on todettu aiheuttavan munuaishaittoja ja neutropeniaa. Epäilyt sidofoviirin karsinogeenisuudesta perustuvat lähinnä eläinkokeisiin. Lääkkeen valmistaja on raportoinut hankalia sivuvaikutuksia potilailla, joilla sidofoviiria on annosteltu vastoin alkuperäistä indikaatiota, kuten silmään tai iholle.

Kansainväliseen monikeskustutkimukseen kerättiin retrospektiivisesti tiedot 635:stä hengitysteiden papillomatoosia sairastavasta potilaasta. Näistä 275 oli saanut sidofoviiria. Sidofoviiripotilaiden seuranta-ajan keskiarvo oli 3.3 vuotta ensimmäisen injektion jälkeen. Sidofoviiria saaneilla papillomapotilailla ei todettu enempää ylähengitysteiden - tai henkitorven pahanlaatuisia kasvaimia kuin niillä potilailla, joiden papilloomia hoidettiin ilman sidofoviiria. Tutkimuksessa ei saatu lisänäyttöä siitä, että sidofoviiri aiheuttaisi munuaisvaurioita tai neutropeniaa ylähengitysteiden papilloomien paikallisissa injektioissa.

HYKS korvaklinikalla hoidettiin vuosina 1975-2011 yhteensä 324 kurkunpään papillomatoosia sairastavaa potilasta, joista yhdeksälle (2.8%) kehittyi kurkunpään levyepiteelisyöpä. Tutkimuksessa analysoitiin tollin kaltaisten reseptorien (engl. toll-like receptors, TLR) 2, -4 ja -9 immunoekspressiota näiden potilaiden papillooma- ja syöpäkudoksessa. Verrokkeina oli yhdeksän kurkunpään papilloomaa jotka eivät pahanlaatuistuneet, 23 näytettä kroonista laryngiittia sairastavilta potilailta, sekä 19 näytettä kurkunpään levyepiteelisyövistä joita ei edeltänyt papillomatoosi. Sytoplasminen TLR4- ja TLR9-ekspressio oli merkittävästi matalampi kurkunpään papilloomissa kuin kroonisissa laryngiiteissa tai kurkunpääsyövissä. Tuman TLR4-ekspressio oli merkittävästi matalampi niissä papilloomissa jotka muuttuivat pahanlaatuisiksi verrattuna eimalignisoituneisiin papilloomiin. Kurkunpään levyepiteelisyövissä korkea sytoplasman TLR4-ekspressio oli yhteydessä kohtalaiseen - tai huonoon erilaistumisasteeseen, sekä pidemmälle edenneeseen tautiin.

HPV:n tiedetään tarttuvan iholta tai limakalvolta seksikontakteissa ja mm. synnytyksen yhteydessä äidiltä lapselle. Tässä tutkimuksessa analysoitiin PCR-menetelmällä HPV DNA:n leviämistä hoitohenkilökunnan suun limakalvoille, sekä leikkauskäsineisiin ja -maskeihin, kun he hoitivat hiilidioksidilaserilla potilaiden kurkunpään papilloomia ja genitaalialueen kondyloomia. Tutkimukseen osallistui viisi kurkunpään papilloomien - ja viisi genitaalialueen kondyloomien takia hoidettavaa potilasta, sekä kuusi lääkäriä ja 12 hoitajaa. HPV DNA:ta löytyi hoitohenkilökunnan hanskoista,

mutta ei maskeista eikä suun limakalvoilta. Löydökset viittaavat siihen, että hoitohenkilökunnan riski saada HPV-tartunta potilaalta hiilidioksidilaserhoidon yhteydessä on vähäinen, kun asianmukaisia suojarusteita käytetään.

ORIGINAL PUBLICATIONS

This thesis is based on the following publications, which are referred to in the text by their Roman numerals:

- I Ilmarinen T, Nissila H, Rihkanen H, Roine RP, Pietarinen-Runtti P, Pitkäranta A, Aaltonen LM. Clinical features, health-related quality of life, and adult voice in juvenile-onset recurrent respiratory papillomatosis. *Laryngoscope*. 121:846-51 (2011).
- II Tjon Pian Gi REA, Ilmarinen T, van den Heuvel ER, Aaltonen LM, Andersen J, Brunings JW, Chirila M, Dietz A, Ferran Vilà F, Friedrich G, de Gier HHW, Golusinski W, Goumans J, Graupp M, Hantzakos A, Horcasitas R, Jackowska J, Koelmel JC, Lawson G, Lindner F, Remacle M, Sittel C, Weichbold V, Wierzbicka M, Dikkers FG on behalf of the RRP study group of the ELS (European Laryngological Society). Safety of intralesional cidofovir in patients with recurrent respiratory papillomatosis -an international retrospective study on 635 RRP patients. *Eur Arch Otorhinolaryngol*. 270:1679-87 (2013).
- III Ilmarinen T, Hagström J, Haglund C, Auvinen E, Leivo I, Pitkäranta A, Aaltonen LM. Malignant transformation rate of recurrent respiratory papillomatosis – low expression of nuclear toll-like receptor 4 in laryngeal papillomas transforming into squamous cell carcinoma. Submitted.
- IV Ilmarinen T, Auvinen E, Hiltunen-Back E, Ranki A, Aaltonen LM, Pitkäranta A. Transmission of human papillomavirus DNA from patient to surgical masks, gloves and oral mucosa of medical personnel during treatment of laryngeal papillomas and genital warts. *Eur Arch Otorhinolaryngol*. 269:2367-71 (2012).

I, II, and IV are reprinted here with the publishers' permission.

ABBREVIATIONS

AIDS	acquired immunodeficiency syndrome
AORRP	adult-onset recurrent respiratory papillomatosis
CIN	cervical intraepithelial neoplasia
CMV	cytomegalovirus
CO ₂	carbon dioxide
DNA	deoxyribonucleic acid
eGFR	estimated glomerular filtration rate
H&E	hematoxylin and eosin
HPV	human papillomavirus
HRQOL	health-related quality of life
IHC	immunohistochemistry
ISH	in situ hybridization
JORRP	juvenile-onset recurrent respiratory papillomatosis
LP	laryngeal papilloma
LPS	lipopolysaccharide
mRNA	messenger ribonucleic acid
PCR	polymerase chain reaction
pRb	retinoblastoma protein
RRP	recurrent respiratory papillomatosis
SIL	squamous intraepithelial lesion
SCC	squamous cell carcinoma
TLR	toll-like receptor
VHI	voice handicap index
V-RQOL	voice-related quality of life

1 INTRODUCTION

Recurrent respiratory papillomatosis (RRP) is a disease characterized by wart-like lesions within the respiratory tract, most commonly on the vocal folds (1). These lesions may recur at short intervals, resolve spontaneously, or reappear after a latent period (2, 3). For both respiratory papillomas and genital warts, the main causative agents are low-risk human papillomavirus (HPV) types 6 and 11 (4).

Dysphonia is the most typical presenting symptom in RRP, but laryngeal papillomas (LPs) may also cause stridor by narrowing the airway (5, 6). Since no cure exists for RRP, the treatment focuses on surgical removal of exophytic lesions to maintain a serviceable quality and function of voice and to prevent airway obstruction. Few patients require tracheotomy, small children more often than adults (7).

Since HPV vaccination is now available for disease prevention, it has become increasingly important to assess the effects of RRP on health-related quality of life (HRQOL) (8). Although RRP is a rare disease, its chronic nature with frequent relapses causes substantial morbidity in patients, as well as considerable costs to the healthcare system (9, 10). Irreversible vocal fold tissue damage, due to repeat surgery, may cause vocal symptoms even when remission has been achieved.

Both commercialized HPV vaccines, Gardasil® and Cervarix®, protect from the most common high-risk HPV types 16 and 18 (11). Low-risk HPV types 6 and 11 are covered only by Gardasil®, a quadrivalent vaccine which could markedly reduce the incidence of RRP and genital warts through widespread immunization. However, these vaccines are primarily indicated for the prevention of premalignant and cancerous anogenital lesions. Several aspects, such as cost-effectiveness and cross-protection from other oncogenic HPV types, must be taken into account when considering national HPV immunization (12, 13).

The presumed mode of HPV transmission in children with RRP is through an infected birth canal, although horizontal routes of transmission after birth also exist (14, 15). In adults, HPV infection is usually transmitted by sexual contact (16). HPV deoxyribonucleic acid (DNA) has been detected in the plume produced by carbon dioxide (CO₂) laser treatment, raising questions as to risks of HPV transmission from patients to health care workers (17). Recommendations for personal protective equipment are not consistent between health care institutions, and personnel treating patients may be unaware of the infectious etiology. Case reports have described RRP in personnel repeatedly exposed to the CO₂ laser plume during treatment of HPV-associated lesions (18, 19).

RRP patients with frequently relapsing or otherwise aggressive disease, requiring more than four operations annually or spreading into extralaryngeal sites, may need adjuvant therapy (20, 21). Cidofovir (Vistide®) is an antiviral agent with an official indication for intravenous treatment of cytomegalovirus (CMV) retinitis in patients with acquired immunodeficiency syndrome (AIDS) (22). It has been locally injected in RRP, usually after surgical removal of exophytic papillomas.

Neutropenia (23) and renal toxicity (22, 24) can occur after large doses of cidofovir in immunocompromized patients. Although suspicions of its carcinogenicity are mainly based on in vitro studies (25, 26) and animal models (27), malignant transformation of RRP following cidofovir treatment has raised questions about its safety (28). The manufacturer has prohibited its use outside the original indications because off-label use, such as administration directly onto the skin or eyes, has resulted in severe local and general side-effects (29). The lack of therapeutic options for RRP patients with aggressive disease causes patients and clinicians considerable distress.

The malignant transformation rate of RRP has ranged from 1% to 23% (30, 31). Several factors may contribute to the cancer risk: irradiation therapy, laryngopharyngeal reflux, smoking, and exposure to other carcinogens. In most studies, the follow-up data are either inadequately reported, or come from patient records in a single institution. In RRP, dysplasia is common

(32). To detect those laryngeal papillomas (LPs) progressing from dysplasia into invasive carcinoma is only possible by obtaining biopsy specimens repeatedly under general anesthesia. Therefore, a biomarker able to predict increased risk for malignancy would be useful in detecting those RRP patients requiring closer follow-up.

The aim of this study was to assess clinical features, sequelae of treatment, and factors contributing to malignant transformation in RRP.

2 REVIEW OF THE LITERATURE

2.1 HPV

2.1.1 GENERAL ASPECTS

Human papillomavirus (HPV) infections have a wide spectrum of clinical manifestations. Some infections are self-limiting and merely indolent, whereas others cause significant concern, morbidity, and mortality (33, 34). At present, more than 170 different HPV types have undergone complete characterization, and new types are being found continuously (35). Mucosotropic HPVs have been divided into low-risk and high-risk types depending on their carcinogenic potential (36, 37).

HPV infections are extremely common, they are usually transient in nature, and rarely become life-threatening. In a Finnish HPV Family Study, the point prevalence of oral HPV infection ranged from 15% to 24% during a follow-up of six years. High-risk HPV type 16 was most frequently detected (38). The majority of mucosal HPV infections resolve without treatment. Some individuals, however, fail to clear the infection. In recurrent respiratory papillomatosis (RRP), a chronic infection by low-risk HPV types may require frequent laryngeal surgery or securing of the airway (39).

An estimated cumulative incidence of genital HPV infection is between 50% and 80% (40). The median time for clearance of cervicovaginal HPV infections is approximately eight months (41, 42). In 10-20% of women, however, genital HPV infections become persistent, with potential for malignant transformation (43, 44).

High-risk HPV infections contribute to a substantial proportion of oropharyngeal squamous cell carcinomas (SCCs), and they are strongly associated with cervical intraepithelial neoplasias (CINs), and cancers of the cervix, vulva, vagina, and penis (33, 45-47).

2.1.2 HPV TRANSMISSION

Detection of HPV deoxyribonucleic acid (DNA) in amniotic fluid, cord blood, and placenta suggests that exposure to HPV may already occur before birth (48, 49). Transmission of HPV from the infected birth canal during vaginal delivery is common. In a study by Rintala et al. infants were repeatedly tested for high-risk HPV DNA from birth until 36 months of age. Of 324 infants, 63% had an oral mucosal sample positive for high-risk HPV at least once. Only 47% of infants never tested positive for genital high-risk HPV (50). Although persistent oral or genital HPV carriage is uncommon in childhood, the majority of individuals acquire HPV later in life through sexual activity (51).

Association between maternal genital warts and juvenile-onset recurrent respiratory papillomatosis (JORRP) was already suggested in 1956 (52), and confirmed thereafter several times (53-55). Although HPV DNA has been detected in a substantial proportion of offspring from mothers with genital HPV lesions, only a few of these children develop RRP (56, 57). Oral sex is considered to be the most common mode of HPV transmission in adult-onset recurrent respiratory papillomatosis (AORRP). Kashima et al. reported that, compared to controls, patients with AORRP had more life-time sex partners and a higher frequency of oral sex (16).

The personnel are constantly exposed to HPV, in specialized health care units treating HPV-associated lesions of the urogenital area and respiratory tract, but few studies have investigated the risks of HPV transmission from patients to personnel. HPV DNA has been detected in the CO₂ laser plume during treatment of HPV lesions, and two case-reports have described onset of RRP in individual health care workers treating patients with anogenital condylomas (17-19, 58, 59). Virus particles dispersed in the laser plume may, however, be incapable of causing an infection (60). Since HPV is frequently present in macroscopically normal mucosa, it is often impossible to determine the source of infection and the point in time when a person - a health care worker for example - acquired HPV. Further information is vital as to the actual risks of HPV transmission from patients to health care

personnel, as well as to the usefulness of personal protective equipment in preventing infection.

2.1.3 HPV STRUCTURE AND MECHANISM OF ACTION

Human papillomavirus (HPV) belongs to the Papovavirus family. It is an epitheliotropic, non-enveloped, icosahedrally-shaped virus. Its double-stranded DNA genome is approximately 8000 base pairs in length. HPV DNA has three regions, designated according to the phase of infection in which they are expressed: an upstream regulatory region, an early (E) and a late (L) region. E-region consists of genes involved in viral replication and interaction with host cells. Some of the E-region gene products bind and inactivate host tumor-suppressor proteins (61). L-region genes code structural viral proteins. HPV infects basal cells of the epithelium, disturbs the normal process of cell differentiation, and triggers cell proliferation, leading to increased thickness of the epithelium.

Histologically, respiratory papillomas typically present with finger-like projections with a fibrovascular core, and a varying level of dyskeratosis, parakeratosis, or dysplasia (Figure 1). Vacuolated cells with clear cytoplasmic inclusions, termed koilocytes, indicate viral etiology (62). Most of the larynx is lined by pseudostratified ciliated columnar “respiratory” epithelium, whereas vocal folds are covered with nonkeratinizing stratified squamous epithelium. A squamocolumnar junction area between them, that resembles the epithelial transition zone in the cervix, is a preferential localization for HPV-associated lesions (63). Squamous metaplastic epithelium, and areas of mucosal injury are also vulnerable to HPV infection (44).

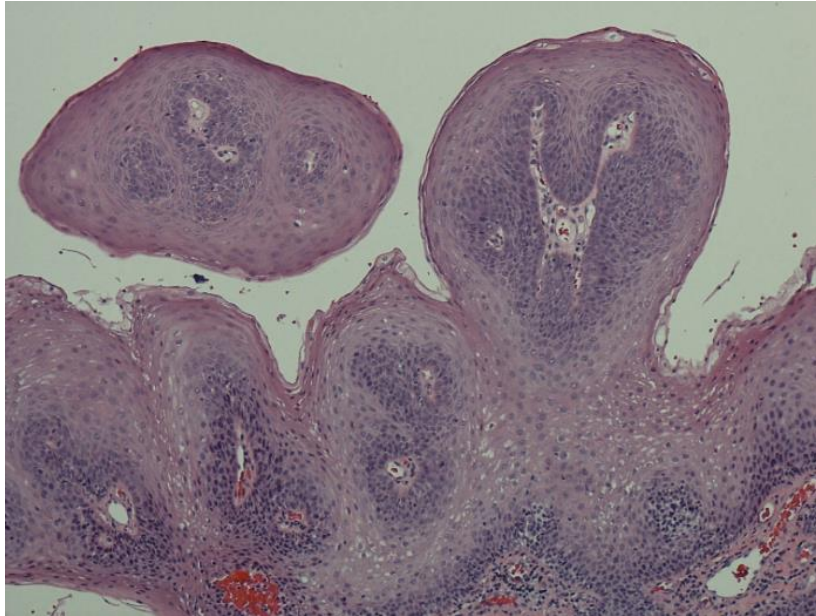


Figure 1. Histological image of a typical vocal fold papilloma with finger-like projections and a fibrovascular core. Image: Jaana Hagström

2.1.4 METHODS FOR HPV DETECTION

In situ hybridization (ISH) is a method that allows not only identification but also localization of a specific region of HPV DNA or messenger ribonucleic acid (mRNA) in a tissue specimen, using a specific chromogen or fluorescent labeled probe. Dot-like or punctuate positivity on microscopic examination means that the viral genome has integrated into the host cell nuclei. ISH is highly specific for HPV infection, but one of its obvious drawbacks is low sensitivity. Several copies of viral DNA or mRNA are required for the detection of HPV (64).

In contrast to ISH, polymerase chain reaction (PCR) is a highly sensitive method for HPV analysis. It is based on amplification of a specific sequence of DNA or mRNA during several repeated cycles of heating and cooling. For example, a DNA sequence belonging to the highly conserved viral L1 gene can be detected using specific probes such as GP5/6, its extended version GP5+/6+, PGMYO9/11, or degenerate primers MYO9/11. Different HPV types can then be analyzed using restriction fragment length polymorphism or hybridization with type-specific probes. Theoretically, PCR can detect even a

single copy of DNA through exponential amplification (65). HPV PCR is more sensitive in fresh tissue biopsy specimens than in formalin-fixed paraffin-embedded tissue (66). Due to the exponential amplification, PCR is more sensitive to contamination than ISH.

Exfoliated cells from macroscopically healthy oral mucosa can be obtained for HPV PCR analysis either by oral brushing or using a mouthwash (67). These methods cause less mucosal damage than a tissue biopsy, and they enable collecting cells from a larger surface area. For example, PCR can detect the viral L1 gene in the superficial epithelial cells during productive HPV infection.

Fresh tissue biopsy may be more useful for HPV PCR when a distinct pathological lesion such as a malignant tumor or a respiratory papilloma is excised for diagnostic purposes (68). HPV status of the basal epithelial layer can be determined more reliably than in a specimen containing only exfoliated surface cells. The rest of the biopsy specimen can be processed into formalin-fixed, paraffin-embedded tissue blocks without shearing off the superficial cells. During HPV-associated carcinogenesis, viral L1 and E2 genes may be present in low copy numbers or even be completely disrupted (69). Thus, an assay that amplifies the intact E6/7 region is required for reliable detection of a transforming high-risk HPV infection. Reverse transcriptase PCR targets mRNA of oncogenic E6 and E7, allowing detection of transcriptionally active HPV DNA (70).

HPV seropositivity cannot determine the site of HPV infection, nor does it distinguish between past exposure and ongoing HPV infection. Laryngeal HPV infection appears to induce a weak antibody response; in one study only 23% of RRP patients had antibodies against HPV type 6, and 33% against HPV type 11. HPV antibodies showed no correlation with the virus types detected by PCR in laryngeal papillomas (71).

In a cohort of 588 college women, nearly half of those with an incident infection by HPV type 16 or 18 stayed seronegative. In some individuals, even persistent high-risk genital HPV infection failed to produce an antibody

response (72). Although HPV serology is of limited usefulness in the clinical setting, it is an important method for evaluating the strength and long-term efficacy of antibody responses produced by HPV vaccines.

2.1.5 IMMUNOLOGICAL ASPECTS

Oral and genital HPV infections are extremely common, but RRP is rare. It seems clear that genetic factors or some failure in host immunity (or both) play a role in the activation of latent HPV infection. Local mucosal damage may also expose basal epithelial cells to HPV. Stern et al. showed that in 20 children with RRP the ratio of CD4/CD8 cells and the response of lymphocytes to mitogen stimulation were significantly reduced compared to healthy age-matched controls (73). In that study, frequent papilloma recurrences were also associated with an abnormal natural killer cell function. Gelder et al. used sequence-specific primer PCR to determine HLA class I and II alleles, finding HLA DRB1*0301 to be significantly more common in patients with RRP than in healthy controls (74).

2.1.6 HPV-INDUCED CARCINOGENESIS

During the early stages of HPV infection, viral E2 protein restrains transcription of viral oncogenes E6 and E7 (75, 76). During carcinogenic progression, the viral genome integrates into the host genome, and E2 is disrupted, leading to elevated expression of E6 and E7. Production of viral E6 protein results in degradation of p53, a tumor-suppressor protein required for growth arrest following DNA damage (77); therefore, cells without functional p53 display genomic instability. E6 protein activates a telomerase enzyme which maintains the telomeric DNA at the ends of linear chromosomes (78). Activation of that enzyme is seen in nearly all human cancers and immortalized cell lines. E7 binds to the retinoblastoma protein (pRb), and it also interacts with several other proteins that are important regulators of cell cycle.

Low-risk HPV types 6 and 11, the causative agents of RRP, are also responsible for the majority of genital warts. High-risk HPV types, such as 16

and 18, are only infrequently present in RRP, and in laryngeal carcinomas arising from papillomas (31). Although HPV types 6 and 11 are considered nononcogenic in both oropharyngeal and urogenital area, integration of the HPV 11 genome in carcinomas arising from LPs suggests that HPV contributes to the malignant transformation of RRP (79).

Increased expression of E7 from high-risk HPV types, causing degradation of functional pRb, results in strong upregulation of cyclin-dependent kinase inhibitor p16^{INK4A}. Overexpression of p16^{INK4A} is used as a surrogate marker for HPV association in head and neck squamous cell carcinoma (SCC), especially tonsillar SCC (80). E7 protein from low-risk HPV types is less effective in binding pRb. A study by Thomas et al. compared expression patterns of p16^{INK4A} between HPV-positive and -negative head and neck SCCs and papillomas. p16^{INK4A} staining was typically intense, strong, diffuse, cytoplasmic, and nuclear in tumors harboring high-risk HPV. In contrast, papillomas showed a more variable focal, weak to strong basal layer or scattered transepithelial positive cells (81). Another study showed that p16^{INK4A} immunohistochemistry was of limited usefulness in predicting malignant transformation of RRP (82).

In a meta-analysis summarizing 55 studies, the overall prevalence of HPV in laryngeal cancer was 28% (83). The authors conclude that especially HPV type 16, with a prevalence of 19.8%, is significantly associated with laryngeal carcinoma, although the mere presence of an episomal virus does not indicate HPV-associated carcinogenesis.

2.1.7 HPV VACCINES

Two HPV vaccines are on the market. The quadrivalent HPV vaccine Gardasil® contains virus-like particles of the L1 protein of both low-risk (6, 11) and high-risk (16, 18) HPV types (84). A total of three intramuscular injections consist of initial dose, and doses administered 2 and 6 months later. Another HPV vaccine Cervarix® protects from high-risk types 16 and 18, but also from some other non-vaccine oncogenic HPV types (85, 86). The vaccines are designed to induce a virus-neutralizing antibody response,

protecting from infection. Since they contain no live virions, they are incapable of causing an infection. Australia was the first country to commence national government-funded HPV vaccination in 2007. The prevalence of HPV genotypes 6, 11, 16 and 18 in cervical samples from women aged 18 to 24 years was significantly lower in the postvaccine period (2010-2011) than in the prevaccine period (2005-2007) (87). Furthermore, comparison of the 12-month periods of 2007/2008 and 2010/2011 showed a decline from 18.6% to 1.9% in the presence of genital warts among women under age 21, based on the proportion of new patients attending the Melbourne Sexual Health Centre (87).

Current evidence is sufficiently strong to conclude that HPV vaccination protects from precancerous cervical lesions and genital warts (88). To show similar advantages for the prevention of RRP takes large study populations from nations with widespread immunization programs, and a longer period of follow-up, since this disease is less common (89). Countries undertaking national immunization programs against both low-risk and high-risk HPV types are expected to reduce dramatically their incidence of RRP, or even eliminate the disease. A longer time is needed for a significant decline to occur in the incidence of HPV-associated head and neck carcinomas in the vaccinated age-groups, since the disease is uncommon during the first decades of life.

Neutralizing antibodies against viral L1 protein cannot cure established HPV-associated tumors. Therapeutic HPV vaccines that produce an E6/E7-specific immune response have been studied in both animals and humans. Combining these antigen-specific immunotherapies and certain immunomodulating agents such as toll-like receptor (TLR) agonists may well become an integral part of modern cancer therapies. Of 20 women with high-grade vulvar intraepithelial neoplasia who received three or four injections of vaccine containing nine HPV-16 E6 and four HPV-16 E7 synthetic peptides, 15 had responded either partially or completely 12 months later, probably as a result of a vaccine induced HPV-16-specific immune response (90).

2.2 RECURRENT RESPIRATORY PAPILLOMATOSIS

2.2.1 CLINICAL FEATURES

In recurrent respiratory papillomatosis (RRP), verrucous epithelial tumours typically present on the vocal folds, but they may spread to extralaryngeal sites or, in some cases, exclusively affect the oral cavity, pharynx, trachea, or bronchi (91). Macroscopically, papillomas may appear as exophytic “cauliflower” projections with an irregular surface, or abnormally thick epithelium with less prominent borders (Figure 2).

Dysphonia is the most common presenting symptom, with stridor due to airway obstruction less frequently present (92). RRP is a disease of an unpredictable nature; some patients achieve remission after a single procedure, while others undergo several surgical debulking operations over years, or even decades.

In a study by Buchinsky et al. describing 118 patients with juvenile-onset recurrent respiratory papillomatosis (JORRP), the total number of surgeries ranged from 2 to 402 per patient (93). Typically, younger age at onset is associated with more aggressive disease.

According to the most recent publications, the proportion of children with JORRP undergoing tracheotomy ranges from 0% to 10% (10, 93-95). Early decannulation is advisable, since tracheotomy may iatrogenically create an area of mucosal metaplasia predisposing to papilloma spread to the stomal site and distal trachea (96).

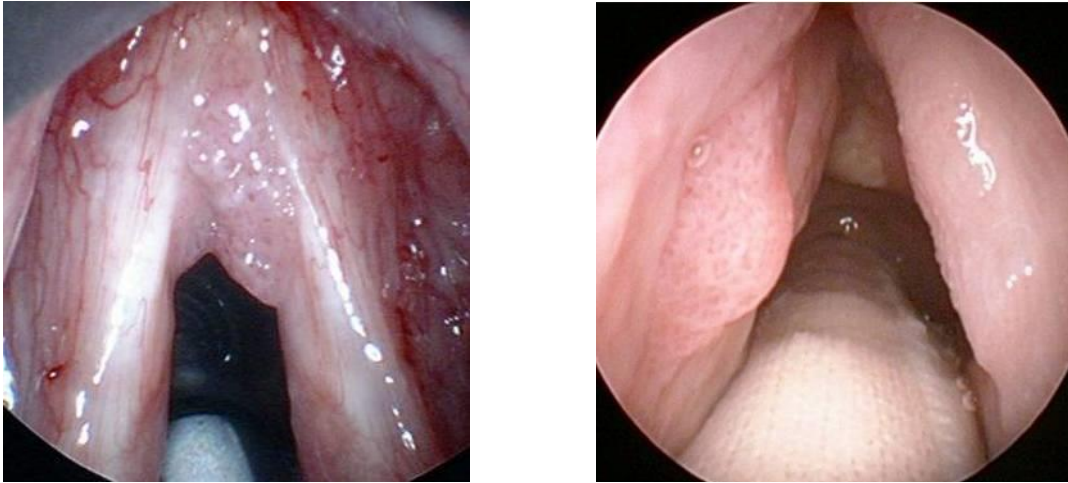


Figure 2. Vocal fold papillomas with a typical red dotted surface.

2.2.2 EPIDEMIOLOGY

Although RRP has probably presented in humans for a long period of time, it was not until the mid-19th century that the disease was first described in the medical literature (97). Based on responses from 315 American otolaryngologists, Derkay et al. estimated in 1995 that the incidence of RRP was 1.8 per 100 000 among adults and 4.3 per 100 000 among children in the USA (98). One study suggested a somewhat lower incidence of JORRP, 0.36 per 100 000 in Seattle and 1.11 per 100 000 in Atlanta. That study's estimate was based on identification of individual patients from medical records of practicing otolaryngologists in 1996 (99). Recently, Omland et al. reported an even lower overall incidence of JORRP, 0.17 per 100 000, in a Norwegian subpopulation of 2.6 million inhabitants. Incidence of adult-onset recurrent respiratory papillomatosis (AORRP) was 0.54 per 100 000 in a subpopulation of 1.1 million inhabitants (100). In that study, both groups showed male preponderance. Previous literature suggests that boys and girls are equally affected in childhood, whereas male adults predominate among AORRP patients (39).

Although severe disease, with pulmonary spread and malignant transformation has been more frequently reported in patients with HPV type

11 (101), a study by Buchinsky suggested that age, rather than HPV type, is associated with the disease severity in children (93).

2.2.3 SURGICAL TREATMENT

Aggressive RRP may primarily require surgical debulking to ensure an open airway. More often, surgery aims at removing vocal fold papillomas in order to maintain acceptable voice function. Patients usually undergo surgery under general anesthesia with a suspension laryngoscope and a microscope for visualization. Several techniques for debulking are available, some of which may cause less vocal fold scarring.

Micro-resectors are instruments widely used in endoscopic sinus surgery for the removal of bony and soft tissue. In 1999, Myer et al. described a laryngeal modification of a microdebrider or a “shaver,” an electric powered instrument with suction and irrigation combined with rotating blade (102). This allows safe and efficient removal of exophytic papillomas (103).

A study describing eleven patients aged 3 to 17, found both acoustic and perceptual evaluation to indicate better postoperative voice outcome in their microdebrider group, than in their CO₂ laser group (104). Other reported benefits of the microdebrider include shorter duration of surgery, less thermal injury, and no risk of airway fire or burns (105).

Interventions that can be delicately applied in the office under local anesthesia, such as the 532-nm potassium titanyl phosphate laser and 585-nm pulsed dye laser, have become popular among some clinicians (106).

Since most studies assessing surgical treatment of RRP describe case series, without any control group undergoing some other surgical modality, comparison between techniques is difficult. Furthermore, diversity exists in evaluating treatment outcomes. In some studies, patients have undergone perceptual and acoustic voice assessment. Others have utilized RRP severity scores to assess disease regression.

2.2.4 CIDOFOVIR

Adjuvant medical therapies for RRP include antiviral agents and immunomodulators. Combining adjuvant therapies and surgery is considered necessary in patients requiring frequent operations and those with a rapid or distal disease progression. In 1998, Snoeck et al. reported promising results from treatment of severe RRP with intralesional injections of cidofovir [(S)-1-(3-hydroxy-2-phosphonylmethoxypropyl) cytosine] (107).

Cidofovir is a cytosine nucleoside analogue, meaning that it becomes incorporated into the DNA and suppresses DNA replication, with a higher affinity against viral DNA synthesis. The official indication for cidofovir is intravenous treatment of cytomegalovirus (CMV) retinitis in patients with acquired immunodeficiency syndrome (AIDS). In addition to the herpes viruses, cidofovir is active against several other DNA viruses such as Epstein-Barr virus, poxviruses, and HPVs.

Unlabeled intravenous use of cidofovir has been reported in life-threatening infections of patients with severely suppressed T cell function, such as in adenovirus infections of leukemia patients undergoing stem cell transplantation (108). Topical cidofovir has been used for extensive molluscum contagiosum and herpes virus infections of immunocompromized patients unresponsive to other treatment modalities (109).

In 2004, a survey of American Society of Pediatric Otolaryngology members reported that intralesional cidofovir had become the most common adjuvant therapy for children with RRP (20). Since no widely adopted recommendations exist for cidofovir in RRP, clinicians have varying protocols for dosage, frequency, and length of treatment, as well as for monitoring potential side-effects. Typically, concentrations have ranged from 2.5 to 7.5 mg/ml, with an administration interval of 2 to 6 weeks (110). Some clinicians use cidofovir after surgical removal of papillomas, while for others it is the sole treatment.

In one randomized, double-blind placebo-controlled study, 19 patients received relatively low concentrations of cidofovir (children 0.3 mg/ml, adults 0.75 mg/ml at the start; midway into the study the US Food and Drug Administration allowed 5 mg/ml for everyone). At 2- and 12-month follow-ups, both a placebo and the cidofovir group showed a significant improvement in Derkey Severity Scores, but with no significant differences emerging between groups (111). One systematic review combined results from 17 case series with intralesional cidofovir therapy: of 158 patients, 90 (57%) had a complete response, 55 (35%) a partial response, and 13 (8%) no improvement (112). However, to assess the true benefits of cidofovir is difficult due to the uncontrolled nature of the studies, variation in length of follow-up (1 to 66 months), and diverse combinations of other adjuvant therapies and surgical treatments with intralesional cidofovir.

Nephrotoxicity and neutropenia have been associated with intravenous cidofovir in humans (23). In one randomized, controlled study describing 150 patients with AIDS and CMV retinitis, 58 (39%) developed asymptomatic proteinuria when they received intravenous cidofovir 5 mg/kg once weekly for two weeks, and thereafter either 3 mg/kg or 5 mg/kg once every other week ; serum creatinine increased in 35 patients (24%) (22).

An intravenous toxicology study has reported carcinogenicity in rats (27). An *in vitro* study showed that two doses of cidofovir raised HPV E6 RNA levels 8-fold in low-risk, and 20-fold in high-risk E6-expressing HPV_{ve} C33A cervical carcinoma cells (26). The authors hypothesize that cidofovir may increase risk for genetic instability in cells. In another study, both high-risk and low-risk E6-expressing, telomerase-immortalized human keratinocyte cell lines, when treated with cidofovir for 2 days, showed significantly improved long-term survival (25).

Whether observations from these experimental models apply to human beings remains unclear. However, the most significant concern with intralesional cidofovir in RRP is the risk for malignant transformation. One retrospective case series analyzed laryngeal biopsy specimens obtained from 13 RRP patients before and after cidofovir injections. Grade of dysplasia

tended to worsen in two (15%) of these patients after cidofovir injections, whereas in others the grade of dysplasia either improved or remained relatively unchanged. Of the 13 patients, in six (46%), the post-cidofovir follow-up period exceeded 5 years. The authors conclude that cidofovir therapy does not correlate with worsening dysplastic progression, although an obvious disadvantage is the lack of a control group treated without cidofovir (113).

In 2011, the producer of cidofovir prohibited its off-label use, because the majority of newly reported side-effects, such as renal toxicity, neutropenia and ocular toxicity, involved the use of cidofovir for either unapproved indications or by an unapproved route of administration (29). Whether systemic toxicity was encountered in patients with RRP was not addressed. After this general warning from the manufacturer, 82 laryngeal surgeons responded to a survey addressing the use of cidofovir and its side-effects in 2012. The authors estimated that in RRP patients with and without exposure to cidofovir, the incidences of upper aerodigestive tract carcinoma were similar. Based on these results, the RRP task force stated that intralesional cidofovir should still be considered in RRP patients requiring surgery every 2 to 3 months with regular biopsy (110).

2.2.5 OTHER ADJUVANT MODALITIES

Interferon- α , an immunomodulatory agent usually administered by subcutaneous injection, has antiviral and antiproliferative effects. Both acute reactions (flu-like symptoms, fever, headache) and delayed adverse effects (pancytopenia, alopecia, hepatorenal failure, cardiac dysfunction) have limited its use (114). Activation of the disease following withdrawal of interferon- α is also a major disadvantage (115).

Other adjuvant treatments, such as acyclovir, ribavirin, cyclo-oxygenase inhibitors, indole-3-carbinol and medications against laryngopharyngeal reflux disease, have been suggested as having some effect, but their usefulness in controlling the disease is difficult to evaluate due to lack of placebo-controlled trials (116-119). RRP is a rare disease with unpredictable

behavior. To prove superiority of one treatment modality over another, either surgical or medical, is therefore challenging, since a considerable number of patients should be recruited, and study groups should be similar in terms of disease severity. Therapeutic HPV vaccination in patients with severe RRP requires further investigation. A multi-center placebo-controlled, randomized study could clarify the potential of neutralizing antibodies against low-risk HPV types in controlling an aggressive disease.

2.2.6 HEALTH-RELATED QUALITY OF LIFE

Measuring health-related quality of life (HRQOL) has become increasingly important due to the development of therapeutic and preventive interventions and increasing health care costs. In clinical studies, the HRQOL instrument should be comprehensive and sensitive, with sufficient test-retest reliability (120).

The 15D, a self-administered instrument for measuring HRQOL, is a questionnaire that takes 5 to 10 minutes to complete. It provides a description of the patient's health status in 15 different dimensions: mobility, vision, hearing, breathing, sleeping, eating, speech, excretion (previously called "elimination"), usual activities, mental function, discomfort and symptoms, depression, distress, vitality, and sexual activity (121). Each dimension is divided into 5 levels from 1 (no problems) to 5 (extreme problems). A 15D profile shows the position of a study group in each of the 15 dimensions. A utility score from 0 (death) to 1 (full health with no problems in any dimension) combines all 15 dimensions. A 15D profile of a study population can be compared to the sex- and gender-matched general Finnish population.

JORRP appears to reduce HRQOL in children, and a marked impact has been reported on the psychosocial health of the family (122, 123). In adult patients, RRP substantially interferes with communication and work. Symptoms of mental disorders, such as depression, moodiness, and excessive tiredness were also significantly more common in RRP patients than in controls matched for age, sex, and smoking habits (124, 125). Studies

addressing HRQOL and voice-related quality of life (V-RQOL) in patients with RRP are listed in Table 1.

Table 1. Health-related quality of life and voice-related quality of life in recurrent respiratory papilloma patients in the literature. Age is presented in years.

Author (reference)	Number of patients	Mean age (range)	Study aims	Methods	Conclusions
Hill 2000 (124)	26	43 (21-65)	To measure QOL issues in RRP by two questionnaires.	-SF-36 -A questionnaire covering laryngeal functions specifically designed for the study.	In SF-36 patients scored lower especially in Role limitation (physical), Energy / Vitality, and Pain. Patients had significantly more limitations in voice use, as well as depression and difficulties at work than did controls.
Lindman 2005 (122)	22	9 (2-15)	To compare QOL in children with RRP to that of healthy children, and children with other chronic diseases	Pediatric Quality of Life Inventory (PedsQL)	In children with RRP QOL is lower than in those who are healthy, and similar to those children with other chronic diseases.
Nieuwenhuizen 2010 (126)	34	52 (25-85)	To assess the impact of patient-reported voice outcome on QOL and emotional functioning in patients treated for RRP.	-VHI -Hospital Anxiety and Depression Scale -SF-36 -Utrechtse Coping list	Patients often reported voice problems in everyday life, which was related to passive coping style, social functioning, and mental health.
Chadha 2010 (123)	20	NA (1-17)	To measure the impact of JORRP on HRQOL, V-RQOL, and family psychosocial well-being by standardized interviews (parents and children).	-Health Utilities Index version 3 -Pediatric V-RQOL survey -Impact on Family Scale -Visual analogue health preference measure	JORRP had a marked impact on V-RQOL and psychosocial health of the family.

Abbreviations: (HR)QOL, (health-related) quality of life; (JO)RRP, (juvenile-onset) recurrent respiratory papillomatosis; SF-36, Short Form-36; VHI, Voice Handicap Index; V-RQOL, voice-related quality of life

2.2.7 FUNCTIONAL ASSESSMENT OF VOICE

Both objective and subjective methods can be used to assess patients with voice disorders. Minimal basic measurements suitable for all common voice disorders are listed in Table 2. When clinical studies assess the degree of a voice disorder, or the outcome of phonosurgical procedures, uniformity in methodology and expression of data allows comparison between patient groups (127).

Most studies have focused on assessing the quality of voice in RRP before and after treatment, or on comparing outcomes between surgical modalities, while only a few have compared the quality of voice between RRP patients and healthy controls. Lindman et al. compared voice quality in prepubescent children (n=4) with their RRP in remission to that of age- and sex-matched controls (128). In that study, RRP patients' voices were more hoarse, breathy, and rough in perceptual evaluation, than were voices of controls. In another study, seven male patients with longstanding laryngeal papillomatosis had poorer quality of voice in perceptual analysis, than did their age- and sex-matched controls (129).

Table 2. A basic protocol for functional assessment of a voice disorder according to the committee of phoniatricians of the European Laryngological Society (127).

Method	Aims	Technique	Parameters
Perceptual assessment of voice	To assess perceptually the degree of of voice abnormality	A panel of speech-language therapists listens to an audio-recorded short passage read by the patient.	G (Grade, degree of abnormality of voice quality) R (Roughness) B (Breathiness) A (Asthenicity) S (Strain) Each component is graded on a 4-point grading scale from 0 (normal) to 3 (severe deviance).
Videolaryngostroboscopy	To visualize laryngeal pathology, and to assess the mode of vocal fold wave and vocal fold closure.	A fiber-optic or a straight scope with a strobe light is connected to a video camera, a recorder and a monitor.	Vocal fold closure (complete, partial, no contact) Mucosal wave phase symmetry (always, most of the time, irregular, or absent) Mucosal wave amplitude symmetry (yes / no)
Computerized acoustic analysis	To provide objective measures of vocal function.	Patient pronounces the vowel /a:/ three times at a comfortable pitch and loudness. A computer program analyzes the audio-recorded vowels.	Percent jitter (frequency perturbation) Percent shimmer (amplitude perturbation) Noise-to-harmonics ratio (aperiodic noise) Fundamental frequency
Aerodynamics	To measure aerodynamic parameters of voicing.	Prolongation of /a:/ for as long as possible after maximal inspiration. Spirometry lung function test.	Maximum phonation time in seconds. Vital capacity, the maximum amount of air (liters) a patient can expel after a maximal inspiration.
Subjective rating by patient	To measure the severity of voice-related handicap in daily life as perceived by the patient.	A questionnaire such as the Voice Handicap Index (VHI)	The Voice Handicap Index comprising 30 statements divided into physical, emotional, and functional subscales. Zero VHI points indicates lowest possible handicap and 120 points maximum perceived handicap (130).

2.2.8 MALIGNANT TRANSFORMATION OF RRP

The proportion of RRP patients undergoing malignant transformation has ranged considerably among studies, from 1.2% to 23% (Table 3). HPV types 6 and 11 have been present in the majority of papillomas undergoing malignant transformation, as well as carcinomas arising from papillomas, whereas high-risk HPV types 16 and 18 have been infrequently detected (31). Histological characteristics that could differentiate papillomas undergoing malignant transformation from those following a less severe course have not been identified.

Laryngeal dysplasia is a dynamic process with potential for progression into invasive carcinoma. In mild dysplasia, the cytologic and architectural atypia is limited to the basal / parabasal layer. In moderate dysplasia, these changes progress into the mid spinous layer and in severe dysplasia, to the upper third of the epithelium. Some pathologists classify severe dysplasia and carcinoma in situ, characterized by atypical changes throughout the entire epithelium, into the same category (131).

In RRP, dysplasia is common. One study reviewed pathology reports and charts from 54 RRP patients, none of whom had undergone cidofovir treatment, to determine the presence and progression of dysplasia (32). Half the patients developed no dysplasia during follow-up. Of the 54, 14 (26%) presented with mild dysplasia, six (11%) with moderate dysplasia, two (4%) with severe dysplasia, four (7%) with carcinoma in situ, and one with SCC. Of 24 patients, 22 (92%) with two or more operations initially presenting with either mild or no dysplasia did not progress beyond mild dysplasia. In some RRP patients, progressive dysplasia precedes invasive carcinoma, but a quick transformation has been reported in others, even after a long latent period (30). Dysplasia is, therefore, an unreliable predictor of cancer development. In order to assess progression of laryngeal dysplasia, the patient must undergo repeated biopsy procedures under general anesthesia. Malignant transformation may occur at the primary site of disease presentation, but RRP patients with pulmonary spread may be at increased risk for developing carcinoma (132).

Table 3. Representative studies estimating incidence of malignant transformation in recurrent respiratory papillomatosis. Among those 45 patients developing malignancy 9 (20%) were reported with juvenile-onset disease. Age is presented in years.

Author (reference)	Total RRP study population	Patients developing malignancy, n (%)	Mean age at CA diagnosis (range)	Location of CA, n
Lie ^a 1994 (133)	102	8 (7.8)	52 in females 64 in males	Larynx, 7 Bronchial tree, 1
Klozar ^b 1997 (134)	179	3 (1.7)	65 (56-81)	Larynx, 3
Dedo ^c 2001 (92)	244	4 (1.6)	NA	NA
Gerein ^d 2005 (132)	42	5 (12)	NA	Lungs, 4 Nasopharynx, 1
Preuss ^e 2007 (135)	188	17 (9.0)	NA	Larynx, 16 Bronchial tree, 1
Jeong ^f 2008 (31)	241	3 (1.2)	53 (39-64)	Larynx, 1 Larynx and trachea, 2
Lee ^g 2008 (30)	26	6 (23)	NA (18-60)	Larynx, 6

Abbreviations: CA, carcinoma; HPV, human papillomavirus; RRP, recurrent respiratory papillomatosis; NA, not available; PCR, polymerase chain reaction

^a Two patients had undergone radiation treatment, and 2 had been treated with bleomycin for RRP before CA diagnosis. This study utilized the Norwegian Cancer Registry.

^b One patient had verrucous CA.

^c Two patients had verrucous CA.

^d All 42 study patients had undergone alfa-interferon treatment.

^e Seventeen cases include 8 with CA in situ. All patients with invasive laryngeal CA were smokers.

^f Increase observed in p53 and Ki-67 protein in foci of dysplasia and CA.

^g Two patients had verrucous CA, without detectable HPV in the premalignant specimens by PCR.

2.3 TOLL-LIKE RECEPTORS IN HPV-ASSOCIATED CARCINOGENESIS

Toll-like receptors (TLR) are evolutionarily conserved receptors presented on cells of the human immune system. They play a key role in innate immune responses by detecting distinct pathogen-associated molecular patterns of invading microorganisms (136-139). This leads to a series of signaling events, including increased expression of pro-inflammatory cytokines targeted against the pathogen. TLRs are also presented on several cancer cells, and they may either promote or suppress tumor development. TLRs 2, 3, 4, and 9 have been detected in laryngeal SCC (140, 141). Lipopolysaccharide (LPS) binding to TLR4 has enhanced proliferation of head and neck cancer cells (142, 143). In contrast, stimulation of head and neck cancer cells with OK-PSA, an active component of streptococcal agent OK-432, induced cell-growth inhibition. These findings suggest that OK-432 acts not only by enhancing anti-cancer host responses (144), but also acts on cancer cells directly.

The role of TLRs in HPV-associated head and neck tumors requires further research. One study investigated the association between TLR expression and cervical HPV persistence or clearance in young women. HPV16 infections that cleared were significantly associated with increased expression of TLRs 3, 7, 8 and 9, whereas dampened TLR expression was associated with persistent HPV infections (145). Another study showed that expression of TLR4 was down-regulated during progression of cervical neoplasia, and that TLR4 expression was inversely associated with p16^{INK4A} expression (146).

3 AIMS OF THE STUDY

The general objective of this study was to improve knowledge of clinical features, sequelae of treatment, and factors contributing to malignant transformation in recurrent respiratory papillomatosis (RRP). The specific aims were to:

1. Assess clinical features, health-related quality of life, and adult voice in juvenile-onset recurrent respiratory papillomatosis (JORRP).
2. Discover whether intralesional cidofovir treatment causes neutropenia, renal insufficiency, malignancies, or other adverse events in patients with RRP.
3. Determine the rate of malignant transformation in RRP patients treated for laryngeal papillomas (LPs) and analyze the role of toll-like receptors (TLRs) 2, 4, and 9 in malignant transformation of LPs.
4. Determine the risk of HPV transmission from patient to medical personnel during carbon dioxide (CO₂) laser treatment of LPs and genital warts.

4 PATIENTS AND METHODS

4.1 CLINICAL FEATURES, HEALTH-RELATED QUALITY OF LIFE AND ADULT VOICE IN JORRP (STUDY I)

In Study I, medical records were reviewed for all 32 patients treated for juvenile-onset recurrent respiratory papillomatosis (JORRP) at Helsinki University Hospital between 1975 and 1994. In 2008, 18 (56%) of them accepted an invitation to come for an outpatient visit, and participated in the study. Of the 14 non-participants, two had moved away from the hospital district, and 12 either refused to participate or never replied to our invitation. The participants and the non-participants were similar with respect to male-female ratio, age at diagnosis, and the number of phonosurgical procedures and tracheotomies.

Patients underwent a regular ear-, nose, and throat examination, and had their larynxes visualized by a rigid 70° -angle telescope and a stroboscope. The videolaryngostroboscopy recordings were stored on DVD and later evaluated by a phoniatician and a laryngologist blinded to the patient histories. The voice sample comprised a short story and pronunciation of the vowel [a] three times for as long as possible after maximal inspiration. A condenser microphone was placed 30 cm from the subject's mouth. The voice samples were recorded on a DAT tape in a soundproof chamber in the Phoniatic Department of Helsinki University Hospital.

A three-second sample of the second vowel [a] served for acoustic analysis in all except two subjects. A 2.5-second sample was used for the two subjects who failed to phonate for longer than 5 seconds. The first second of the vowel was excluded, as well as the section following the three-second sample. A Multi-Dimensional Voice Program served for acoustic analysis of sustained vowel phonations. Percent jitter is a measure of frequency perturbation, and percent shimmer is a measure of amplitude perturbation. Thus, a high percentage of jitter indicates high variation in the frequency ("pitch") of the

sound wave from cycle-to-cycle, whereas a high percentage of shimmer indicates high variation in the amplitude (intensity) of the sound wave.

A panel of three experienced speech and language pathologists assessed the voice quality perceptually by listening to the speech samples. GRBAS quality categories were used with a four-point grading scale from 0 (normal) to 3 (severe deviance). Evaluation of videolaryngoscopy findings and voice quality analysis by acoustic and perceptual assessment are described in Table 2 (p. 32).

Patients filled in a Voice Handicap Index (VHI) questionnaire which measures voice-related handicap in daily life (130). A 15D form assessed health-related quality of life. The patient interview consisted of questions regarding occupational status, education, and the effect of voice problems on vocational choice and amount of sick leave. Each patient had an age- (+/- 5 years) and gender-matched control subject with similar use / non-use of tobacco, who underwent the same study protocol. Eighteen control subjects were recruited among hospital staff members, their friends, and family members.

4.2 SAFETY OF INTRALESIONAL CIDOFOVIR IN RRP (STUDY II)

In 2011, all members of the European Laryngological Society were invited to participate in a retrospective study addressing side-effects of intralesional cidofovir treatment in RRP. From 11 countries, 16 otorhinolaryngology centers reported data from 635 RRP patients, of whom 275 were treated with cidofovir. The study protocol was designed by the first (R.E.A.T) and the last (F.G.D.) authors, representing the University Medical Center Groningen, The Netherlands. Patients treated at Helsinki University Hospital (n=244) comprised the largest patient group reported by one single institution.

The study consisted of two parts: a questionnaire inquiring about the general use of cidofovir in each participating center and a retrospective case file report in which hospital patient records and laboratory parameters were

individually reviewed for each RRP patient treated in the participating center between 1998 and 2011. A manual with instructions on completing the forms was attached to obtain consistent data from each hospital.

In the questionnaire, each clinic described its protocol for treatment of RRP patients and reported the number of RRP patients treated with and without cidofovir. It provided details of cidofovir treatment such as concentration, number of administrations, maximum cumulative dose, and observed side-effects, as well as policies for monitoring renal function and blood neutrocyte levels before and after treatment.

The retrospective case file report consisted of a clinical segment with the following data for each individual patient: date of birth, gender, type of RRP (juvenile or adult onset), number of cidofovir injections, HPV type, and upper respiratory tract and tracheal malignancies diagnosed after onset of RRP. Furthermore, it covered clinical signs of renal toxicity and length of follow-up both after RRP diagnosis and onset of cidofovir treatment. A laboratory segment involved patients with cidofovir treatment only: parameters for kidney function (serum creatinine, normal range 0-110 mmol/l and estimated glomerular filtration rate (eGFR), normal range 52-max ml/min/1.73 m²) and blood neutrocyte levels (normal range 1.8-7.7 x10⁹ /l) were reported before and after cidofovir treatment.

4.3 MALIGNANT TRANSFORMATION OF RRP (STUDY III)

Study III reviewed hospital patient records and pathology reports from all RRP patients (n=324) treated between 1975 and 2011 for laryngeal papillomas (LPs) at Helsinki University Hospital. To confirm the number of RRP patients developing laryngeal SCC, approval was obtained from the National Institute for Health and Welfare to access the Finnish Cancer Registry. The Finnish Cancer Registry, founded in 1952 by Cancer Society of Finland, receives cancer notifications from hospitals and physicians, as well as from pathology and hematology laboratories. It collects and monitors data

on individual cancer cases and produces cancer statistics and data for research purposes. Statistics Finland provides annual reports on all cancer deaths. Thus, the Finnish Cancer Registry is virtually a complete database on all cancers diagnosed among the residents of Finland since 1953 (147).

Of 324 RRP patients nine (2.8%) developed laryngeal SCC. They were all males with glottal SCC, aged 43 to 88 (mean 68) years at diagnosis. All patients had AORRP and had undergone a median of 3 operations (range 1-7) during a mean period of 5 (range 1-9) years, before laryngeal SCC. All except two were smokers. In addition to these nine patients with laryngeal SCC, one female patient with an aggressive, extralaryngeally spread JORRP developed squamous cell lung carcinoma, and died soon after cancer diagnosis at the age of 33 years.

Control subjects were nine RRP patients who remained free of laryngeal SCC (mean age 60, range 52-78), 23 patients with laryngeal squamous intraepithelial lesions (SILs) clinically presenting with chronic laryngitis (mean age 62, range 46-76), and 19 laryngeal SCC patients without pre-existing RRP (mean age 68, range 53-86). RRP patients who stayed free of laryngeal SCC had been on surveillance for a mean period of 72 (range 30-165) months after the tissue specimen was obtained, and four out of the nine had a smoking history. All the patients with laryngeal SILs were smokers, and of the 23, 15 had stayed free of laryngeal SCC during a mean follow-up of 54 (range 6-117) months. Seven patients treated for laryngeal SILs later developed laryngeal SCC within 6 to 52 (mean 24) months. The mean age of laryngeal SCC patients without prior RRP was 68 (range 53-86) years, and all of them were smokers.

Formalin-fixed, paraffin-embedded laryngeal tissue blocks from patients and controls were retrieved from the archives of Helsinki University Hospital Department of Pathology, and standard H&E stained sections prepared for histopathological analysis. LP tissue from five RRP patients developing laryngeal SCC, and seven specimens from laryngeal SCCs arising from LPs were available for study purposes. The study pathologist (J.H.) reviewed standard hematoxylin and eosin (H&E) sections, and confirmed LP tumor

histology characterized by koilocytes, para/hyperkeratosis, and papillomatous epithelium with a fibrovascular core (62). Laryngeal SCCs were graded into well- (G1), moderately (G2), or poorly (G3) differentiated.

Sections (4 µm) were cut from formalin-fixed and paraffin-embedded tissue samples to prepare immunohistochemistry (IHC) slides. The sections were subjected to IHC with monoclonal TLR 2 (1:50), TLR 4 (1:50) and TLR 9 (1:100) antibodies (Santa Cruz Biotechnology, Inc, Santa Cruz, CA, USA). p16^{INK4a} staining was performed with the p16^{INK4a} ready to use antibody (CINtech® Histology Kit, Roche, Germany). Intensity of immunostaining was scored on a scale from 0 to 3. Nuclear and cytoplasmic staining was separately scored for TLRs. Two researchers, including the study pathologist, evaluated the slides independently, blinded to the clinical data.

4.4 TRANSMISSION OF HPV DNA FROM PATIENTS TO HEALTH CARE PERSONNEL (STUDY IV)

Study IV included five RRP patients operated on for LPs at the Department of Otorhinolaryngology – Head and Neck Surgery, and another five patients undergoing treatment for genital warts at the Department of Dermatology and Venereology, Helsinki University Hospital. All employees selected the material and manufacturer of their surgical gloves, and used protective plastic goggles, and laser plume masks during each operation.

RRP patients were treated in an operating room under general anesthesia. A CO₂ laser was applied to four of the five RRP patients after microdebrider removal of the macroscopic papilloma tumor. Three employees, including the surgeon, the nurse anesthetist, and the surgical nurse, participated in the study during each operation. Over the whole study period, a total of three surgeons and nine nurses performed the LP operations.

Two employees, a physician and a nurse, administered CO₂ laser vaporization for urethral warts during each procedure. A total of three physicians and three nurses conducted the CO₂ laser treatments for genital warts during the study period.

A cytobrush was used to collect oral mucosal specimens for HPV DNA testing from the study patients and the employees immediately before and after each procedure. One half of each LP biopsy specimen was processed for standard H&E sections, and the other half went for HPV PCR analysis. Cells were collected from the surface of urethral warts with a cytobrush for HPV DNA testing.

After each procedure, specimens from the surgical masks and gloves were collected for HPV DNA analysis from all except the nurse anesthetist. A 1-cm² piece of each glove was cut from the area covering the top of the right index finger, as was a 1-cm² piece from each mask where it covered the employee's mouth. These samples were individually placed in tubes containing 1 ml of phosphate-buffered saline and processed for HPV PCR analysis and genotyping by the clinical diagnostic laboratory of Quattromed HTI in Tartu, Estonia. DNA integrity was confirmed by amplification of human β -globin gene (148). Degenerated MY09/11/HMBO1 primers were used to detect HPV by PCR (149). All positive results were genotyped by restriction fragment length polymorphism analysis (150).

4.5 STATISTICAL ANALYSES

Data are presented as mean or median values, range or real case number and percentage. In Study II, the interquartile range of nonparametric variables is presented inside brackets. In Study I, the Wilcoxon signed rank test served for comparison of the nonparametric acoustic and perceptual voice quality parameters, whereas the Mann-Whitney test enabled comparison of VHI and 15D scores between patients and controls. The chi square test and Pearson's and Spearman's correlation tests served in analysis of associations between variables (Studies I, II, III). Fisher's exact test was used to compare IHC scores and clinicopathological characteristics (Study III). The paired sample T-test enabled comparison of laboratory values before and after cidofovir treatment (Study II) and the Kaplan-Meier method and Fisher's exact test were applied when occurrences of malignancies in the cidofovir and the non-cidofovir group were compared. Significance level was set at 0.05.

4.6 ETHICS

The Ethics Committee of Helsinki University Hospital approved Studies I, III, and IV. For Study II, approval was not necessary, since it only involved reviewing medical records. Informed written consent was given by all participants in Studies I and IV, but not required in Study III, since the patients were neither interviewed nor examined for research purposes.

5 RESULTS

5.1 CLINICAL FEATURES, HEALTH-RELATED QUALITY OF LIFE AND ADULT VOICE IN JORRP (STUDY I)

Table 4 presents the main clinical characteristics of 18 patients participating in Study I. The median follow-up was 40.1 (range 18.0-65.6) years. All five patients diagnosed with juvenile-onset recurrent respiratory papillomatosis (JORRP) before the age of 2 years achieved remission before age 7.5 years. Of the four patients (22%) who had undergone tracheotomy, each was diagnosed with JORRP before age 5.

Table 4. Main clinical characteristics of adult patients (n=18) with a history of juvenile-onset recurrent respiratory papillomatosis examined in Study I. Age is presented in years.

Gender, n (%)	
Male	12 (67)
Female	6 (33)
Age at diagnosis	
Mean	5.4
Range	0.5-16.7
Age at examination	
Mean	46.5
Range	22.0-68.4
Number of laryngeal procedures	
Median	11.5
Range	1-70
Tracheotomy, n (%)	
Yes	4 (22)
No	14 (78)
Recurrences age \geq 18, n (%)	
Yes	10 (56)
No	8 (44)

Of the 18, 4 patients (22%) were suspected of having laryngeal papillomas during videolaryngostroboscopy examinations. The vocal fold closure was either complete or partial in all control subjects, whereas six patients had

either no contact, or vocal fold closure was impossible to assess (due to papilloma recurrences in two, and hyperactivity of ventricular folds in two). Abnormal mucosal wave phase symmetry, as well as absence of mucosal wave amplitude symmetry, was more common in patients, than in controls.

Both acoustic and perceptual analyses showed poorer voice quality in patients than in controls. Patients had significantly higher percentage jitter ($P=0.001$) and percentage shimmer ($P=0.003$). The noise-to-harmonics ratio was also significantly higher in patients ($P=0.006$) (Table 5). High number of laryngeal procedures was statistically significantly associated with poorer quality of voice in acoustic analyses. In the perceptual assessment, patients' values were significantly higher for grade ($P<0.001$), roughness ($P<0.001$), breathiness ($P<0.001$), and strain ($P=0.017$), but their mean values exceeded 1 (slight deviance) only in grade and roughness. A statistically significant correlation emerged between grade and number of laryngeal procedures.

Five patients and two control subjects had a Voice Handicap Index (VHI) score exceeding 30, whereas all others scored below 30. Differences in VHI scores between patients and controls were statistically non-significant. Health-related quality of life analysis indicated no statistically significant differences in any of the 15 dimensions between patients and controls. The mean 15D utility score was only slightly lower in patients (0.914) than in controls (0.948).

Table 5. Comparison of main outcome measures between JORRP patients (n=18) and controls (n=18).

		Patients	Controls	P
		Mean	Mean	
Acoustic analysis	Percent Jitter	2.27	0.85	0.001
	Percent Shimmer	10.92	4.54	0.003
	Noise-to-harmonics ratio	0.20	0.15	0.006
Perceptual voice assessment	Grade	1.33	0.43	<0.001
	Roughness	1.26	0.50	<0.001
	Breathiness	0.96	0.33	<0.001
	Asthenia	0.15	0.15	NS
	Strain	0.65	0.35	0.017
Voice-related handicap	VHI score	21.1	13.6	NS
Health-related quality of life	15D score	0.914	0.948	NS

Abbreviations: NS, non-significant; VHI, voice handicap index

5.2 SAFETY OF INTRALESIONAL CIDOFOVIR IN RRP (STUDY II)

Of all 635 patients with recurrent respiratory papillomatosis (RRP) reviewed in Study II, 71% were male, and 81% had adult-onset disease. The percentage of male patients was 53.4% in the juvenile-onset group and 75.2% in the adult-onset group. Thus, a statistically significant difference in male-to-female ratio appeared between juvenile-onset and adult-onset groups. The mean follow-up after diagnosis was 7.7 years, and of 635 patients, 25 (3.9%) developed an upper airway or tracheal malignancy. Of 198 patients who had undergone HPV typing, 165 (83%) presented with low-risk HPV, 10 (5%) had high-risk HPV, seven (4%) had both low and high-risk HPV, and 10 (5%) were HPV negative. Six patients (3%) were positive for HPV, but the type of HPV was not specified.

A total of 275 patients had undergone intralesional cidofovir treatment, at a concentration ranging from 5 to 75 mg/ml. The maximum dose ranged from 20 to 375 mg per intervention. Considerable variation occurred between different centers in maximum cumulative dose. Some units defined a minimum of cidofovir injections (from 3 to 6), others limited the maximum number of injections (from 6 to 15), while some centers designed cidofovir treatment individually for each patient, depending on recurrences and symptoms. Only five centers routinely monitored renal function before and after cidofovir administration.

Of 275 patients treated with intralesional cidofovir, 184 (67%) were male and 205 (75%) had adult-onset recurrent respiratory papillomatosis (AORRP). The number of women ($P=0.038$) and of patients with juvenile-onset recurrent respiratory papillomatosis (JORRP) ($P<0.001$) was statistically significantly higher in the cidofovir group, than in the non-cidofovir group. The mean follow-up period after start of cidofovir treatment was 3.3 years (interquartile range 1.3-4.6 years), during which four patients (1.5%) developed an upper airway or tracheal malignancy. No significant differences emerged in the occurrence of upper airway or tracheal malignancies between the cidofovir (1.5%) and the non-cidofovir (5%) groups.

None of the patients, after cidofovir treatment, developed clinical signs of nephrotoxicity. Although creatinine concentrations monitored after intralesional cidofovir treatment were statistically higher than were those tested before cidofovir, no significant differences emerged in the number of patients with creatinine values exceeding normal. No statistically significant differences emerged in blood neutrocyte count, eGFR, or proteinuria before and after cidofovir treatment. One patient had proteinuria both before and after cidofovir injections. Other adverse events after cidofovir treatment included diarrhea in two, nausea in one, chronic uveitis in one, and elevation of the liver enzymes aspartate aminotransferase and alanine aminotransferase in two patients.

5.3 MALIGNANT TRANSFORMATION OF RRP (STUDY III)

Of 324 patients with recurrent respiratory papillomatosis (RRP), treated between 1975 and 2011 at Helsinki University Hospital for laryngeal papillomas (LPs), 9 (2.8%) developed laryngeal squamous cell carcinoma (SCC). Immunostaining for toll-like receptor (TLR) 2 was stronger in all three groups of histology (LPs, laryngeal squamous intraepithelial lesions (SILs), and SCCs) when compared to TLR4 and TLR9 staining intensity.

Cytoplasmic TLR4 staining was significantly lower in LPs than in laryngeal SILs. Cytoplasmic TLR4 negativity, when staining was categorized as either negative or positive, was significantly more common in LPs than in laryngeal SCCs. Cytoplasmic staining for TLR9 was statistically significantly stronger in laryngeal SILs and laryngeal SCCs than in LPs. p16^{INK4a} staining showed no statistically significant differences between histology groups.

LPs that transformed into SCC had significantly lower scores for nuclear TLR4 than did LPs without malignant transformation (Figure 3). None of the biomarkers showed statistically significant differences between laryngeal SCCs arising from LPs and those without RRP etiology.

Immunostaining for cytoplasmic TLR4 correlated significantly with tumor grade and T stage in laryngeal SCCs; high immunostaining for cytoplasmic TLR4 was typical for moderately and poorly differentiated tumors, and for laryngeal SCCs at a more advanced T stage.

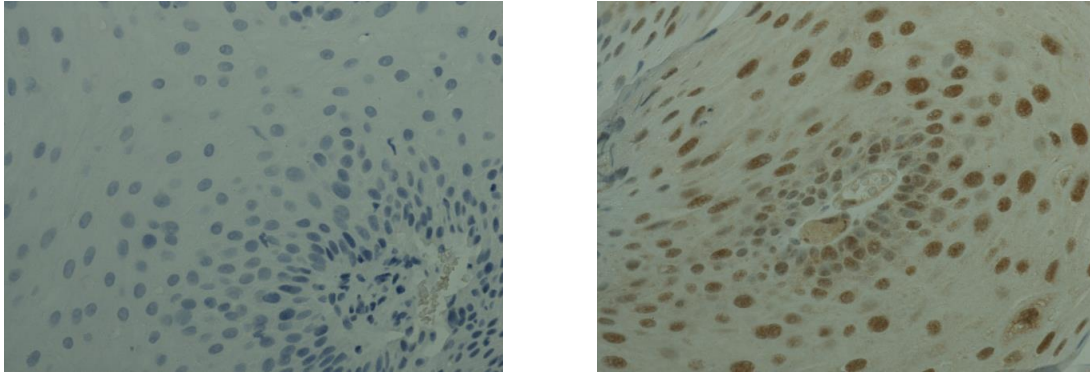


Figure 3. Left: Nuclear TLR4 negativity in a laryngeal papilloma later transforming into squamous cell carcinoma. Right: Nuclear TLR4 positivity in a laryngeal papilloma without malignant transformation. Image: Jaana Hagström.

5.4 TRANSMISSION OF HPV DNA FROM PATIENT TO HEALTH CARE PERSONNEL (STUDY IV)

In total, 120 samples were analyzed for the presence of HPV DNA. Laryngeal papillomas (LPs) and genital warts were all found positive for HPV DNA. Results of PCR analysis are presented in Table 4. After LP procedures, one of the five surgeons' glove samples tested HPV positive, and those of the surgical nurse for three of the five samples. After treatment of genital warts, all samples from the surgical gloves of both physicians and nurses were positive for HPV DNA that corresponded to the patient tissue specimens.

All oral mucosa specimens from patients with genital warts tested negative for HPV. An oral sample from one patient with LPs was positive for HPV DNA before and after surgery, whereas oral specimens from two LP patients tested positive for HPV only after surgery. HPV DNA was absent in all of the oral mucosa specimens and surgical mask samples of personnel.

Table 6. HPV DNA in specimens from patients' oral mucosa and tumor, and the surgical gloves of the employees. All oral mucosa specimens and surgical mask samples of personnel were negative for HPV DNA (data not shown).

Patient	BEFORE	AFTER SURGERY			
	Oral mucosa	Oral mucosa	Glove (surgeon)	Glove (surgical nurse)	Tumor (genital wart / laryngeal papilloma)
Genital wart					
1	-	-	HPV6	HPV6	HPV6
2	-	-	HPV84	HPV84	HPV53 and 84
3	-	-	HPV6 and 61	HPV61	HPV6 and 61
4	-	-	HPV6 and 84	HPV84	HPV6 and 84
5	-	-	HPV6	HPV6	HPV6 and 18
Laryngeal papilloma					
1	-	-	-	HPV6	HPV6
2	-	-	-	-	HPV6
3	-	HPV11	-	-	HPV11
4	-	HPV6	-	HPV6	HPV6
5	HPV6	HPV6	HPV6	HPV6	HPV6

6 DISCUSSION

6.1 JORRP AS A RISK FACTOR FOR PERMANENT LARYNGEAL PATHOLOGY AND VOICE DISTURBANCES IN ADULTHOOD

In 18 patients previously treated for juvenile-onset recurrent respiratory papillomatosis (JORRP) the quality of adult voice, measured by both acoustic and perceptual analyses, was significantly lower than in controls. Of 18 patients only five (28%), however, had a moderate voice-related handicap in daily life, according to their Voice Handicap Index (VHI) score (130). Vocational choice was influenced by voice quality in only one patient. Although the literature has reported a significantly lower health-related quality of life (HRQOL) in both adult (124) and juvenile (122) patients with active recurrent respiratory papillomatosis (RRP), our findings suggest that the majority of JORRP patients were able to adapt well to their disease and experienced no significant limitations in their adult life, despite their poorer quality of voice. Studies assessing the HRQOL and voice-related quality of life in RRP patients are listed in Table 1 (p. 30).

Voice-quality impairment and pathological videolaryngoscopy findings correlated with a high number of laryngeal operations. Patients who had undergone numerous procedures often presented with scar formation, ventricular fold hyperactivity, and mucosal-wave abnormalities. However, the degree of laryngeal pathology we observed may not apply to the majority of patients treated for JORRP today. Modern surgical treatment modalities, such as the use of a microdebrider and a CO₂ laser, have reduced postoperative scarring and improved treatment outcomes. The importance of meticulous phonosurgical techniques that preserve the underlying mucosa is now well-acknowledged.

In this study, over half the patients continued to relapse in adulthood. However, five patients diagnosed before the age of two years achieved complete remission. Clearance of laryngeal papillomas in patients with an

early-onset disease may be due to maturation of the immune system with age. In four patients who underwent tracheotomy, the mean age at diagnosis was 2.2 (range 0.8-4.9) years. Studies have shown that children diagnosed with JORRP at an early age more often end with a tracheotomy, which may be in part explained by the smaller diameter of the airway. However, extralaryngeal spread is also more common in small children with JORRP, suggesting that more aggressive disease is associated with younger age at diagnosis (94). During the last two decades, the proportion of JORRP patients requiring tracheotomy has ranged from 0% to 10% (10, 93-95). The four patients with tracheotomies in this study were treated before modern treatment modalities such as the carbon dioxide (CO₂) laser, were applied. Nowadays, at our institution a JORRP patient requiring tracheotomy is extremely uncommon.

Selection bias can always emerge when patients are invited to participate in a study voluntarily. However, our 18 participants were a rather representative sample of the whole JORRP patient population (n=32) reviewed here. Having a large JORRP patient population for a clinical study is challenging, because the disease is rare.

This study provides new insights into the natural course of JORRP and potential impacts of the disease in adult life. These are often the main concerns among parents whose children are diagnosed with JORRP. Our patients' perceptions of HRQOL and voice-related handicap in adulthood were not strongly influenced by JORRP, although frequent surgical operations caused irreversible laryngeal pathology and permanent voice impairment. These aspects should be taken into consideration when evaluating the advantages of preventive measures such as HPV vaccination.

6.2 SAFETY OF INTRALESIONAL CIDOFOVIR IN RRP

In 2011, the producer of cidofovir announced that from April 2009 to April 2010, 46 of 53 (87%) cidofovir adverse event reports received by the company involved its use either for an unapproved indication or via an

unapproved route of administration, such as intraocular or topical. The most frequent and serious reactions were renal toxicity, ocular toxicity, and neutropenia. Although intralesional use of cidofovir in recurrent respiratory papillomatosis (RRP) was not addressed, the general warning by the producer caused many otorhinolaryngologists to cease their administration of cidofovir. Members of the European Laryngological Society were soon asked to participate in our retrospective study, collecting information about the potential side-effects of cidofovir in laryngology.

Our study is in agreement with the earlier finding that males are more often affected by RRP than females (95, 134). Our male preponderance was particularly clear in patients with adult-onset recurrent respiratory papillomatosis (AORRP). A substantially greater proportion of patients with juvenile-onset recurrent respiratory papillomatosis (JORRP), 70 of 118 (59%), had undergone cidofovir treatment, compared to the 205 of 517 (40%) patients with AORRP. The greater proportion of children requiring adjuvant therapy may be explained by the more aggressive course of their disease, as well as by the smaller diameter of their airways.

In this study, no statistically significant difference emerged in incidence of tracheal and upper respiratory tract malignancies between the cidofovir and the non-cidofovir groups. The mean duration of follow-up was, however, only 3.3 years after the first cidofovir injection. Malignant transformation is a process which may take years, or even decades, and several factors such as exposure to tobacco and other carcinogens, age, and aggressiveness of RRP contribute to cancer risk. Since cidofovir patients often have a history of frequent relapses, some defect in their immune response may also contribute to the cancer risk.

Due to the retrospective nature of the study, all cases of malignant transformation may not have been reported. A longer study period is needed, with sufficient comparison of baseline characteristics and underlying risk factors between patient groups, to reliably assess the impact of cidofovir on cancer risk.

Although no statistically significant differences emerged in number of patients with creatinine values exceeding the normal limit before and after cidofovir treatment, creatinine concentrations monitored after intralesional cidofovir treatment were statistically higher than those before cidofovir. Considering that cidofovir is known to be nephrotoxic, these findings suggest that monitoring renal function before and after cidofovir treatment is recommendable.

Whether or not other reported side-effects (diarrhea, nausea, uveitis, elevation of liver enzymes) were associated with cidofovir remains elusive, since cidofovir and non-cidofovir patients were neither interviewed nor examined according to a standardized protocol after treatment. We found no association between intralesional cidofovir treatment and neutropenia.

Although several uncontrolled trials have suggested either a partial or complete response with intralesional cidofovir in the majority of RRP patients (112), their observations may be in part explained by the natural course of the disease. Adjuvant medical therapies for RRP should be carefully considered, individually planned, and used only when the potential benefits are likely to outweigh the risks. Clinicians should pay attention to all potential side-effects, and report them adequately.

6.3 MALIGNANT TRANSFORMATION RATE OF RRP AND EXPRESSION OF TLRS IN LARYNGEAL PAPILOMAS CONVERTING INTO LARYNGEAL SCC

According to this study, malignant transformation of RRP (recurrent respiratory papillomatosis) is a rare event. In Study III, nine of 324 RRP patients (2.8%) developed laryngeal squamous cell carcinoma (SCC). Only a slightly higher rate of upper respiratory tract and tracheal malignancies, 3.9%, emerged in Study II. Assessments of the rate of malignant transformation in RRP are summarized in Table 3 (p. 34). The Norwegian Cancer Registry was utilized in one study by Lie et al., nearly 20 years ago

(133). They reported that of 102 patients with laryngeal papillomas (LPs), treated between 1950 and 1979 in Norway, seven (6.9%) were diagnosed with laryngeal SCC, and one RRP patient with extralaryngeal spread developed bronchial SCC. Of eight patients with SCC in that study, two had been irradiated and two had undergone bleomycin treatment. In our study, of nine RRP patients seven were smokers, which was likely to contribute to their cancer risk. Genetic factors, as well as varying exposure to different carcinogens, may explain the wide range of malignant transformation rates of RRP published, from 1.2% to 23%. Furthermore, not all estimates may be reliable, since follow-up data are often based on patient records from only a single institution.

This study showed that the expression of cytoplasmic toll-like receptors (TLRs) 4 and 9 was significantly lower in LPs, than in laryngeal squamous intraepithelial lesions (SILs) and in laryngeal SCCs. Furthermore, all LPs transforming into laryngeal SCC were negative for nuclear TLR4, whereas of 9 LPs without malignant transformation, 7 showed positive nuclear TLR4 staining.

One study analyzed the presence of TLR4 and p16^{INK4a} in cervical intraepithelial neoplasia (CIN) and cervical carcinoma, both of which are strongly associated with high-risk HPV types. TLR4 expression was significantly stronger in normal cervical tissue and early stages of CIN, than in high grade CINs and cervical SCC (146). Daud et al. suggested that increased expression of TLRs 3, 7, 8, and 9 was associated with cervical HPV clearance, whereas decreased TLR expression was associated with persistent HPV infections (145). These findings may indicate that TLR expression is either down-regulated by HPV or that those individuals with deficient immune responses are less likely to clear their HPV infections.

The immunohistochemical data of this study should be interpreted with caution, because the number of samples was limited. Laryngeal tissue specimens are often small. Due to the lack of tissue material, HPV typing was impossible. Some clinicians obtain a biopsy specimen at the first papilloma operation to confirm diagnosis, and thereafter only if clinical features or

papillomas' growth pattern change. Retrospectively collected archival tissue specimens may, therefore, not ideally represent histological features of the whole patient population.

Although RRP is a rare disease, and malignant transformation of LPs occurs infrequently, it is important to understand the mechanisms of HPV-associated carcinogenesis in the head and neck region. In contrast to cervical carcinomas, no precursors have been identified to oropharyngeal SCCs, a substantial proportion of which harbor HPV. The role of host-defense mechanisms, and molecular changes preceding SCC can be analyzed in LPs and in laryngeal SILs, since these are both potential precursors for laryngeal SCC.

Two studies have shown that binding of lipopolysaccharide (LPS) to TLR4 induces proliferation of human head and neck cancer cell lines. In contrast, activation of TLR4 by OK-PSA, an active component of bacteria-derived immunotherapeutic agent OK-432, leads to cell-growth inhibition and apoptosis (142, 143). A complex interplay between host immune cells and epithelium may either eliminate neoplastic development or promote carcinogenesis. Stimulation of TLRs is already used in modern biological anti-cancer therapies (151). These treatment modalities are primarily targeted at cells of the immune system, not at tumor cells. For example, imiquimod, used against actinic keratosis, superficial basal cell carcinoma and genital warts, exerts its immunomodulatory effects by binding to TLR7. Expression of TLRs in different types of tumor cells should be analyzed, in order to assess the benefits of biological cancer therapies.

The present study reaffirmed that p16^{INK4a} expression is neither a specific nor a sensitive marker for HPV infection in benign laryngeal lesions, nor is it useful in determining risk for malignant transformation in RRP. Here, high staining intensity of cytoplasmic TLR4 in laryngeal SCCs correlated with higher tumor grade and more advanced T stage. Conversely, an earlier study reported a strong positive reaction for TLR4 as typical in well or moderately differentiated SCCs. However, nuclear and cytoplasmic staining for TLR4

was not separately assessed, in that study, and 12 oral-cavity cancers were analyzed in addition to 27 laryngeal SCCs (152).

6.4 TRANSMISSION OF HPV DNA FROM PATIENTS TO HEALTH CARE PERSONNEL

Here, HPV DNA was transmitted from the patients to the surgical gloves of the employees during carbon dioxide (CO₂) laser treatment of laryngeal papillomas (LPs) and genital warts. Direct contact between gloves and HPV-infected tumors is not common during treatment of LPs, but when a laryngoscope is inserted into the mouth to allow visualization, gloves frequently become contaminated by saliva. Direct contamination of surgical gloves may occur during the examination and treatment of genital warts, and instruments used in the operation may indirectly contaminate gloves. Contamination of surgical gloves by a CO₂ laser plume is possible. However, surgical masks located further away from the treatment area and having no contact with the patient or secretions, remained negative for HPV DNA.

Including patients with genital warts was intriguing, since both diseases are caused by HPV types 6 and 11. Furthermore, genital warts are more common than LPs, and a greater number of health care personnel examine and treat genital HPV-associated lesions.

HPV DNA was present in the oral mucosa specimen of only one LP patient preoperatively, but detected in three of five postoperatively. HPV DNA may have been transmitted to their oral mucosa by the CO₂ laser plume, but endotracheal tube, laryngoscope, or surgical instruments may also have contaminated the upper respiratory tract mucosa.

One study found no HPV DNA corresponding to patient-derived HPV types in the Petri dishes left open at a distance of 1 and 2 m from the treatment area, nor on the swabs from the eyeglasses and nasolabial folds of the operator during multilayer argon plasma coagulation treatment and the CO₂ laser ablation of genital warts (153). In another study, specimens from the nasolabial folds of personnel tested HPV positive in 2 of the 11 cases

preoperatively and in 3 of the 11 cases postoperatively, and 2 of the 5 Petri dishes left open as far as 2 m away from the treatment area tested positive for HPV DNA. However, the source of HPV DNA was not confirmed by HPV genotyping patients' tissue specimens (154). Although HPV DNA has been detected in the CO₂ laser plume by PCR (17), one study showed that only a few morphologically intact cells were present in the plume collected during the CO₂ laser treatment of genital warts. In that study, no metabolic activity, replication or transcription of HPV occurred during incubation of the cellular debris (60).

The prevalence of HPV DNA in oral mucosa specimens from young women ranged in a Finnish HPV Family Study from 15% to 24% (38). In our study, none of the oral mucosa specimens from 18 employees tested positive for HPV. Case reports have described RRP in health care workers after providing repeated laser therapies for patients with genital HPV lesions (18, 19), but studies on the actual prevalence of HPV infections among health care personnel are few. Since HPV may persist in the oral mucosa for a long time without causing any symptoms, it is often impossible to determine where and when a person diagnosed with RRP acquired HPV, making it difficult to confirm any association between occupational HPV exposure and laryngeal HPV infection.

A larger multicenter study with a similar protocol could have provided more strength to these observations, but it may have been unrewarding, considering that HPV appeared neither in the oral mucosa nor in surgical masks of the personnel. HPV DNA located outside the sampling area, of course, remains undetected. Theoretically, a health care worker acquiring HPV at the time of the procedure could be more reliably tested after a few weeks, during productive viral infection. However, participating personnel had conducted similar medical procedures before the study, most for several years. Re-testing the same personnel after a longer period was considered fruitless, since exclusion of HPV transmission outside work, through oral sex for example, would have been impossible.

7 CONCLUSIONS

1. A considerable proportion of patients with juvenile-onset recurrent respiratory papillomatosis (JORRP) continue to relapse after puberty. JORRP is a risk factor for permanent laryngeal pathology and voice disorders. However, patients do not perceive themselves as having a considerable voice-related handicap or health-related quality of life impairment in adulthood.
2. A multicenter retrospective chart review found no further evidence of long-term nephrotoxicity, carcinogenicity, or neutropenia after intralesional cidofovir treatment for recurrent respiratory papillomatosis (RRP).
3. Malignant transformation of RRP is a rare event. Expression of toll-like receptor (TLR) 4 may be valuable in predicting malignant conversion of laryngeal papillomas (LPs). High cytoplasmic expression of TLR4 in laryngeal squamous cell carcinomas (SCCs) may be associated with a more aggressive disease.
4. Absence of HPV DNA from the surgical masks and oral mucosa specimens of health care personnel suggests that during carbon dioxide (CO₂) laser treatment of LPs and genital warts, HPV transmission from patient to personnel is unlikely to occur. However, laser plume masks, surgical gloves, and protective eyewear should be essential, and contaminated equipment be disposed of carefully, to prevent HPV transmission.

ACKNOWLEDGEMENTS

This study was conducted at the Helsinki University Hospital Department of Otorhinolaryngology – Head and Neck Surgery between 2008 and 2013. My deepest gratitude goes to everyone who helped me during these years. I especially thank

Professor and Dean of Education Anne Pitkäranta, who always found time for my questions and ideas despite all her other duties. I admire virtually everything about Anne Pitkäranta, but especially her creativity, courage, and ability to take things up to the next level.

Docent Leena-Maija Aaltonen, who has patiently helped and guided me through these years. Her positivity, strength, and confidence have kept me going, and taught me never to give up nor to underestimate my skills. I have been extremely lucky to have a supervisor in whom intelligence, fast thinking, warmth, and sense of humor unite.

Docent Hans Ramsay, Chief of the Clinic Group, and Docent Heikki Rihkanen, Head of the Clinic, for providing a firm ground for professional growth.

Professor Antti Mäkitie, a skilled surgeon and a scientist, for sharing his wide knowledge and for creating an inspiring and encouraging atmosphere.

Docent Jaana Hagström, who not only introduced me to the world of pathology, and shared her invaluable knowledge, but also instructed me on how to balance work and family. Working with her was always inspiring and fun!

Docent Eeva Auvinen, whose expertise in virology and laboratory diagnostics was extremely important for this work to be finished. I especially praise her calm and friendly way of explaining complex issues outside the core of my own field.

Professor Annamari Ranki, Docent Eija Hiltunen-Back, and personnel of the Department of Dermatology and Venereology for support and great collaboration.

My reviewers Docents Eeva Sala and Pekka Nieminen for their friendly, encouraging attitude and constructive comments.

My co-authors Professors Ilmo Leivo and Caj Haglund, Docent Risto P. Roine, and Heljä Nissilä, MA, for their kind collaboration.

Colleagues around the world who participated in a demanding international multi-center study. Professor Frederik Dikkers and Robin Tjon Pian Gi, MD, are especially acknowledged for their courage and enormous amount of work.

Eija-Riitta Lauri, MD, for her expertise in the evaluation of videolaryngoscopy findings and speech-language pathologists Laura Lehto, Kaarina Ruusuvirta and Jaana Sellman for perceptual analysis of voice quality. Staff at the Department of Phoniatics are warmly thanked for their assistance during patient examinations.

Tiina Puttonen, Eija Nenye, and Leena Juvonen for their efforts in recruiting patients and processing study samples.

Päivi Peltokangas and Ge Qiu whose contribution at the Department of Pathology has been extremely important.

Carol Norris for her impeccable language editing.

My colleagues and the personnel in the ENT clinic for their continuous help, and for sharing their thoughts on scientific and clinical work, and on life in general. Petra Pietarinen, MD, PhD, and Docent Teemu Kinnari are especially thanked for sharing their knowledge on laryngology, and for creating a friendly atmosphere.

My parents Aino and Seppo Ilmarinen for their care and support.

My sisters, their families, and all my friends who instantly made my anxiety disappear when work was replaced by moments of leisure and fun.

Olli Vaskelainen for his help in computing, and for providing an alternative perspective in life, outside medicine. Our mischievous children Elias and Alisa earn thanks for bringing joy and laughter into our lives.

This work was financially supported by grants from Helsinki University Hospital Research Funds (EVO), the Finnish-Norwegian Medical Foundation and the Finnish Otologic Research Funds.

Helsinki, September 2013

Taru Ilmarinen

REFERENCES

1. Lindeberg H, Oster S, Oxlund I, Elbrond O. Laryngeal papillomas: Classification and course. *Clin Otolaryngol Allied Sci.* 11: 423-9 (1986).
2. Mounts P, Shah KV, Kashima H. Viral etiology of juvenile- and adult-onset squamous papilloma of the larynx. *Proc Natl Acad Sci U S A.* 79: 5425-9 (1982).
3. Gissmann L, Diehl V, Schultz-Coulon HJ, zur Hausen H. Molecular cloning and characterization of human papilloma virus DNA derived from a laryngeal papilloma. *J Virol.* 44: 393-400 (1982).
4. Gissmann L, zur Hausen H. Partial characterization of viral DNA from human genital warts (condylomata acuminata). *Int J Cancer.* 25: 605-9 (1980).
5. Stamataki S, Nikolopoulos TP, Korres S, Felekis D, Tzangaroulakis A, Ferekidis E. Juvenile recurrent respiratory papillomatosis: Still a mystery disease with difficult management. *Head Neck.* 29: 155-62 (2007).
6. Gallagher TQ, Derkay CS. Recurrent respiratory papillomatosis: Update 2008. *Curr Opin Otolaryngol Head Neck Surg.* 16: 536-42 (2008).
7. Donne AJ, Hampson L, Homer JJ, Hampson IN. The role of HPV type in recurrent respiratory papillomatosis. *Int J Pediatr Otorhinolaryngol.* 74: 7-14 (2010).
8. Jit M, Chapman R, Hughes O, Choi YH. Comparing bivalent and quadrivalent human papillomavirus vaccines: Economic evaluation based on transmission model. *BMJ.* 343: d5775 (2011).
9. Bishai D, Kashima H, Shah K. The cost of juvenile-onset recurrent respiratory papillomatosis. *Arch Otolaryngol Head Neck Surg.* 126: 935-9 (2000).
10. Reeves WC, Ruparelia SS, Swanson KI, Derkay CS, Marcus A, Unger ER. National registry for juvenile-onset recurrent respiratory papillomatosis. *Arch Otolaryngol Head Neck Surg.* 129: 976-82 (2003).
11. Schiller JT, Castellsague X, Garland SM. A review of clinical trials of human papillomavirus prophylactic vaccines. *Vaccine.* 30 Suppl 5: F123-38 (2012).
12. Wheeler CM, Castellsague X, Garland SM, Szarewski A, Paavonen J, Naud P, Salmeron J, Chow SN, Apter D, Kitchener H, Teixeira JC, Skinner SR, Jaisamrarn U, Limson G, Romanowski B, Aoki FY, Schwarz TF, Poppe WA, Bosch FX, Harper DM, Huh W, Hardt K, Zahaf T, Descamps D, Struyf F, Dubin G, Lehtinen M, HPV PATRICIA Study Group. Cross-protective efficacy of HPV-16/18 AS04-adjuvanted vaccine against cervical infection and precancer caused by non-vaccine oncogenic HPV types: 4-year end-of-study analysis of the randomised, double-blind PATRICIA trial. *Lancet Oncol.* 13: 100-10 (2012).
13. Salo H, Leino T, Kilpi T, Auranen K, Tiihonen P, Lehtinen M, Vanska S, Linna M, Nieminen P. The burden and costs of prevention and management of genital disease caused by HPV in women: A population-based registry study in Finland. *Int J Cancer.* (2013).

14. Syrjanen S. Current concepts on human papillomavirus infections in children. *APMIS*. 118: 494-509 (2010).
15. Koskimaa HM, Waterboer T, Pawlita M, Grenman S, Syrjanen K, Syrjanen S. Human papillomavirus genotypes present in the oral mucosa of newborns and their concordance with maternal cervical human papillomavirus genotypes. *J Pediatr*. 160: 837-43 (2012).
16. Kashima HK, Shah F, Lyles A, Glackin R, Muhammad N, Turner L, Van Zandt S, Whitt S, Shah K. A comparison of risk factors in juvenile-onset and adult-onset recurrent respiratory papillomatosis. *Laryngoscope*. 102: 9-13 (1992).
17. Kashima HK, Kessis T, Mounts P, Shah K. Polymerase chain reaction identification of human papillomavirus DNA in CO₂ laser plume from recurrent respiratory papillomatosis. *Otolaryngol Head Neck Surg*. 104: 191-5 (1991).
18. Hallmo P, Naess O. Laryngeal papillomatosis with human papillomavirus DNA contracted by a laser surgeon. *Eur Arch Otorhinolaryngol*. 248: 425-7 (1991).
19. Calero L, Brusis T. Laryngeal papillomatosis - first recognition in germany as an occupational disease in an operating room nurse. *Laryngorhinootologie*. 82: 790-3 (2003).
20. Schraff S, Derkay CS, Burke B, Lawson L. American society of pediatric otolaryngology members' experience with recurrent respiratory papillomatosis and the use of adjuvant therapy. *Arch Otolaryngol Head Neck Surg*. 130: 1039-42 (2004).
21. Tasca RA, McCormick M, Clarke RW. British association of paediatric otorhinolaryngology members experience with recurrent respiratory papillomatosis. *Int J Pediatr Otorhinolaryngol*. 70: 1183-7 (2006).
22. Lalezari JP, Holland GN, Kramer F, McKinley GF, Kemper CA, Ives DV, Nelson R, Hardy WD, Kuppermann BD, Northfelt DW, Youle M, Johnson M, Lewis RA, Weinberg DV, Simon GL, Wolitz RA, Ruby AE, Stagg RJ, Jaffe HS. Randomized, controlled study of the safety and efficacy of intravenous cidofovir for the treatment of relapsing cytomegalovirus retinitis in patients with AIDS. *J Acquir Immune Defic Syndr Hum Retrovirol*. 17: 339-44 (1998).
23. Kendle JB, Fan-Havard P. Cidofovir in the treatment of cytomegaloviral disease. *Ann Pharmacother*. 32: 1181-92 (1998).
24. Ortiz A, Justo P, Sanz A, Melero R, Caramelo C, Guerrero MF, Strutz F, Muller G, Barat A, Egido J. Tubular cell apoptosis and cidofovir-induced acute renal failure. *Antivir Ther*. 10: 185-90 (2005).
25. Donne AJ, Hampson L, He XT, Day PJ, Salway F, Rothera MP, Homer JJ, Hampson IN. Potential risk factors associated with the use of cidofovir to treat benign human papillomavirus-related disease. *Antivir Ther*. 14: 939-52 (2009).
26. Donne AJ, Hampson L, He XT, Rothera MP, Homer JJ, Hampson IN. Cidofovir induces an increase in levels of low-risk and high-risk HPV E6. *Head Neck*. 31: 893-901 (2009).
27. Wutzler P, Thust R. Genetic risks of antiviral nucleoside analogues--a survey. *Antiviral Res*. 49: 55-74 (2001).

28. Lott DG, Krakovitz PR. Squamous cell carcinoma associated with intralesional injection of cidofovir for recurrent respiratory papillomatosis. *Laryngoscope*. 119: 567-70 (2009).
29. Gillen D. Direct healthcare professional communication regarding serious adverse reactions following off-label use of vistide.
<http://www.cbg-meb.nl/NR/rdonlyres/FFB51936-EC22-4180-A213-9E907F06A774/0/VistideDHPCletterJanuary2011.pdf> Accessed 8 September 2013.
30. Lee LA, Cheng AJ, Fang TJ, Huang CG, Liao CT, Chang JT, Li HY. High incidence of malignant transformation of laryngeal papilloma in taiwan. *Laryngoscope*. 118: 50-5 (2008).
31. Jeong WJ, Park SW, Shin M, Lee YJ, Jeon YK, Jung YH, Hah JH, Kwon TK, Song YS, Kim KH, Sung MW. Presence of HPV type 6 in dysplasia and carcinoma arising from recurrent respiratory papillomatosis. *Head Neck*. 31: 1095-101 (2009).
32. Hall JE, Chen K, Yoo MJ, Fletcher KC, Ossoff RH, Garrett CG. Natural progression of dysplasia in adult recurrent respiratory papillomatosis. *Otolaryngol Head Neck Surg*. 144: 252-6 (2011).
33. Giuliano AR, Tortolero-Luna G, Ferrer E, Burchell AN, de Sanjose S, Kjaer SK, Munoz N, Schiffman M, Bosch FX. Epidemiology of human papillomavirus infection in men, cancers other than cervical and benign conditions. *Vaccine*. 26 Suppl 10: K17-28 (2008).
34. Gillison ML, Castellsague X, Chaturvedi A, Goodman MT, Snijders P, Tommasino M, Arbyn M, Franceschi S. Comparative epidemiology of HPV infection and associated cancers of the head and neck and cervix. *Int J Cancer*. (2013).
35. Bzhalava D, Guan P, Franceschi S, Dillner J, Clifford G. A systematic review of the prevalence of mucosal and cutaneous human papillomavirus types. *Virology*. (2013).
36. zur Hausen H. Papillomaviruses and cancer: From basic studies to clinical application. *Nat Rev Cancer*. 2: 342-50 (2002).
37. Bernard HU, Burk RD, Chen Z, van Doorslaer K, Hausen H, de Villiers EM. Classification of papillomaviruses (PVs) based on 189 PV types and proposal of taxonomic amendments. *Virology*. 401: 70-9 (2010).
38. Rautava J, Willberg J, Louvanto K, Wideman L, Syrjanen K, Grenman S, Syrjanen S. Prevalence, genotype distribution and persistence of human papillomavirus in oral mucosa of women: A six-year follow-up study. *PLoS One*. 7: e42171 (2012).
39. Lindeberg H, Elbrond O. Laryngeal papillomas: Clinical aspects in a series of 231 patients. *Clin Otolaryngol Allied Sci*. 14: 333-42 (1989).
40. Baseman JG, Koutsky LA. The epidemiology of human papillomavirus infections. *J Clin Virol*. 32 Suppl 1: S16-24 (2005).

41. Ho GY, Bierman R, Beardsley L, Chang CJ, Burk RD. Natural history of cervicovaginal papillomavirus infection in young women. *N Engl J Med.* 338: 423-8 (1998).
42. Dalstein V, Riethmuller D, Pretet JL, Le Bail Carval K, Sautiere JL, Carbillet JP, Kantelip B, Schaal JP, Mouglin C. Persistence and load of high-risk HPV are predictors for development of high-grade cervical lesions: A longitudinal french cohort study. *Int J Cancer.* 106: 396-403 (2003).
43. Plummer M, Schiffman M, Castle PE, Maucort-Boulch D, Wheeler CM, ALTS Group. A 2-year prospective study of human papillomavirus persistence among women with a cytological diagnosis of atypical squamous cells of undetermined significance or low-grade squamous intraepithelial lesion. *J Infect Dis.* 195: 1582-9 (2007).
44. Stanley M. Pathology and epidemiology of HPV infection in females. *Gynecol Oncol.* 117: S5-10 (2010).
45. Durst M, Gissmann L, Ikenberg H, zur Hausen H. A papillomavirus DNA from a cervical carcinoma and its prevalence in cancer biopsy samples from different geographic regions. *Proc Natl Acad Sci U S A.* 80: 3812-5 (1983).
46. Snijders PJ, Cromme FV, van den Brule AJ, Schrijnemakers HF, Snow GB, Meijer CJ, Walboomers JM. Prevalence and expression of human papillomavirus in tonsillar carcinomas, indicating a possible viral etiology. *Int J Cancer.* 51: 845-50 (1992).
47. Iwasawa A, Nieminen P, Lehtinen M, Paavonen J. Human papillomavirus DNA in uterine cervix squamous cell carcinoma and adenocarcinoma detected by polymerase chain reaction. *Cancer.* 77: 2275-9 (1996).
48. Tseng CJ, Lin CY, Wang RL, Chen LJ, Chang YL, Hsieh TT, Pao CC. Possible transplacental transmission of human papillomaviruses. *Am J Obstet Gynecol.* 166: 35-40 (1992).
49. Armbruster-Moraes E, Ioshimoto LM, Leao E, Zugaib M. Presence of human papillomavirus DNA in amniotic fluids of pregnant women with cervical lesions. *Gynecol Oncol.* 54: 152-8 (1994).
50. Rintala MA, Grenman SE, Jarvenkyla ME, Syrjanen KJ, Syrjanen SM. High-risk types of human papillomavirus (HPV) DNA in oral and genital mucosa of infants during their first 3 years of life: Experience from the finnish HPV family study. *Clin Infect Dis.* 41: 1728-33 (2005).
51. Patel H, Wagner M, Singhal P, Kothari S. Systematic review of the incidence and prevalence of genital warts. *BMC Infect Dis.* 13: 39,2334-13-39 (2013).
52. HAJEK EF. Contribution to the etiology of laryngeal papilloma in children. *J Laryngol Otol.* 70: 166-8 (1956).
53. Cook TA, Brunschwig JP, Butel JS, Cohn AM, Goepfert H, Rawls WE. Laryngeal papilloma: Etiologic and therapeutic considerations. *Ann Otol Rhinol Laryngol.* 82: 649-55 (1973).
54. Quick CA, Watts SL, Krzyzek RA, Faras AJ. Relationship between condylomata and laryngeal papillomata. clinical and molecular virological evidence. *Ann Otol Rhinol Laryngol.* 89: 467-71 (1980).

55. Hallden C, Majmudar B. The relationship between juvenile laryngeal papillomatosis and maternal condylomata acuminata. *J Reprod Med.* 31: 804-7 (1986).
56. Kosko JR, Derkay CS. Role of cesarean section in prevention of recurrent respiratory papillomatosis--is there one? *Int J Pediatr Otorhinolaryngol.* 35: 31-8 (1996).
57. Silverberg MJ, Thorsen P, Lindeberg H, Grant LA, Shah KV. Condyloma in pregnancy is strongly predictive of juvenile-onset recurrent respiratory papillomatosis. *Obstet Gynecol.* 101: 645-52 (2003).
58. Sawchuk WS, Weber PJ, Lowy DR, Dzubow LM. Infectious papillomavirus in the vapor of warts treated with carbon dioxide laser or electrocoagulation: Detection and protection. *J Am Acad Dermatol.* 21: 41-9 (1989).
59. Ferenczy A, Bergeron C, Richart RM. Human papillomavirus DNA in CO₂ laser-generated plume of smoke and its consequences to the surgeon. *Obstet Gynecol.* 75: 114-8 (1990).
60. Bellina JH, Stjernholm RL, Kurpel JE. Analysis of plume emissions after papovavirus irradiation with the carbon dioxide laser. *J Reprod Med.* 27: 268-70 (1982).
61. Yugawa T, Kiyono T. Molecular mechanisms of cervical carcinogenesis by high-risk human papillomaviruses: Novel functions of E6 and E7 oncoproteins. *Rev Med Virol.* 19: 97-113 (2009).
62. Abramson AL, Steinberg BM, Winkler B. Laryngeal papillomatosis: Clinical, histopathologic and molecular studies. *Laryngoscope.* 97: 678-85 (1987).
63. Kashima H, Mounts P, Leventhal B, Hruban RH. Sites of predilection in recurrent respiratory papillomatosis. *Ann Otol Rhinol Laryngol.* 102: 580-3 (1993).
64. Cantley RL, Gabrielli E, Montebelli F, Cimbaluk D, Gattuso P, Petruzzelli G. Ancillary studies in determining human papillomavirus status of squamous cell carcinoma of the oropharynx: A review. *Patholog Res Int.* 2011: 138469 (2011).
65. Allen CT, Lewis JS, Jr, El-Mofty SK, Haughey BH, Nussenbaum B. Human papillomavirus and oropharynx cancer: Biology, detection and clinical implications. *Laryngoscope.* 120: 1756-72 (2010).
66. Miller CS, White DK. Human papillomavirus expression in oral mucosa, premalignant conditions, and squamous cell carcinoma: A retrospective review of the literature. *Oral Surg Oral Med Oral Pathol Oral Radiol Endod.* 82: 57-68 (1996).
67. Syrjanen S, Lodi G, von Bultzingslowen I, Aliko A, Arduino P, Campisi G, Challacombe S, Ficarra G, Flaitz C, Zhou HM, Maeda H, Miller C, Jontell M. Human papillomaviruses in oral carcinoma and oral potentially malignant disorders: A systematic review. *Oral Dis.* 17 Suppl 1: 58-72 (2011).
68. Termine N, Giovannelli L, Rodolico V, Matranga D, Pannone G, Campisi G. Biopsy vs. brushing: Comparison of two sampling methods for the detection of HPV-DNA in squamous cell carcinoma of the oral cavity. *Oral Oncol.* 48: 870-5 (2012).

69. Ragin CC, Reshmi SC, Gollin SM. Mapping and analysis of HPV16 integration sites in a head and neck cancer cell line. *Int J Cancer*. 110: 701-9 (2004).
70. Allen CT, Lewis JS, Jr, El-Mofty SK, Haughey BH, Nussenbaum B. Human papillomavirus and oropharynx cancer: Biology, detection and clinical implications. *Laryngoscope*. 120: 1756-72 (2010).
71. Aaltonen LM, Auvinen E, Dillner J, Lehtinen M, Paavonen J, Rihkanen H, Vaheri A. Poor antibody response against human papillomavirus in adult-onset laryngeal papillomatosis. *J Med Microbiol*. 50: 468-71 (2001).
72. Carter JJ, Koutsky LA, Hughes JP, Lee SK, Kuypers J, Kiviat N, Galloway DA. Comparison of human papillomavirus types 16, 18, and 6 capsid antibody responses following incident infection. *J Infect Dis*. 181: 1911-9 (2000).
73. Stern Y, Filipovich A, Cotton RT, Segal K. Immunocompetency in children with recurrent respiratory papillomatosis: Prospective study. *Ann Otol Rhinol Laryngol*. 116: 169-71 (2007).
74. Gelder CM, Williams OM, Hart KW, Wall S, Williams G, Ingrams D, Bull P, Bunce M, Welsh K, Marshall SE, Borysiewicz L. HLA class II polymorphisms and susceptibility to recurrent respiratory papillomatosis. *J Virol*. 77: 1927-39 (2003).
75. Bernard BA, Bailly C, Lenoir MC, Darmon M, Thierry F, Yaniv M. The human papillomavirus type 18 (HPV18) E2 gene product is a repressor of the HPV18 regulatory region in human keratinocytes. *J Virol*. 63: 4317-24 (1989).
76. Thierry F, Howley PM. Functional analysis of E2-mediated repression of the HPV18 P105 promoter. *New Biol*. 3: 90-100 (1991).
77. Jeon S, Lambert PF. Integration of human papillomavirus type 16 DNA into the human genome leads to increased stability of E6 and E7 mRNAs: Implications for cervical carcinogenesis. *Proc Natl Acad Sci U S A*. 92: 1654-8 (1995).
78. Greider CW, Blackburn EH. Identification of a specific telomere terminal transferase activity in tetrahymena extracts. *Cell*. 43: 405-13 (1985).
79. Reidy PM, Dedo HH, Rabah R, Field JB, Mathog RH, Gregoire L, Lancaster WD. Integration of human papillomavirus type 11 in recurrent respiratory papilloma-associated cancer. *Laryngoscope*. 114: 1906-9 (2004).
80. Singhi AD, Westra WH. Comparison of human papillomavirus in situ hybridization and p16 immunohistochemistry in the detection of human papillomavirus-associated head and neck cancer based on a prospective clinical experience. *Cancer*. 116: 2166-73 (2010).
81. Thomas J, Primeaux T. Is p16 immunohistochemistry a more cost-effective method for identification of human papilloma virus-associated head and neck squamous cell carcinoma? *Ann Diagn Pathol*. 16: 91-9 (2012).
82. Pham TT, Ongkeko WM, An Y, Yi ES. Protein expression of the tumor suppressors p16INK4A and p53 and disease progression in recurrent respiratory papillomatosis. *Laryngoscope*. 117: 253-7 (2007).

83. Li X, Li H, Gao J, Yang Y, Zhou F, Gao C, Li M, Jin Q, Gao L. Human papillomavirus infection and laryngeal cancer risk: A systematic review and meta-analysis. *J Infect Dis.* (2012).
84. FUTURE II Study Group. Quadrivalent vaccine against human papillomavirus to prevent high-grade cervical lesions. *N Engl J Med.* 356: 1915-27 (2007).
85. Paavonen J, Naud P, Salmeron J, Wheeler CM, Chow SN, Apter D, Kitchener H, Castellsague X, Teixeira JC, Skinner SR, Hedrick J, Jaisamrarn U, Limson G, Garland S, Szarewski A, Romanowski B, Aoki FY, Schwarz TF, Poppe WA, Bosch FX, Jenkins D, Hardt K, Zahaf T, Descamps D, Struyf F, Lehtinen M, Dubin G, HPV PATRICIA Study Group. Efficacy of human papillomavirus (HPV)-16/18 AS04-adjuvanted vaccine against cervical infection and precancer caused by oncogenic HPV types (PATRICIA): Final analysis of a double-blind, randomised study in young women. *Lancet.* 374: 301-14 (2009).
86. Lehtinen M, Paavonen J, Wheeler CM, Jaisamrarn U, Garland SM, Castellsague X, Skinner SR, Apter D, Naud P, Salmeron J, Chow SN, Kitchener H, Teixeira JC, Hedrick J, Limson G, Szarewski A, Romanowski B, Aoki FY, Schwarz TF, Poppe WA, De Carvalho NS, Germar MJ, Peters K, Mindel A, De Sutter P, Bosch FX, David MP, Descamps D, Struyf F, Dubin G, HPV PATRICIA Study Group. Overall efficacy of HPV-16/18 AS04-adjuvanted vaccine against grade 3 or greater cervical intraepithelial neoplasia: 4-year end-of-study analysis of the randomised, double-blind PATRICIA trial. *Lancet Oncol.* 13: 89-99 (2012).
87. Tabrizi SN, Brotherton JM, Kaldor JM, Skinner SR, Cummins E, Liu B, Bateson D, McNamee K, Garefalakis M, Garland SM. Fall in human papillomavirus prevalence following a national vaccination program. *J Infect Dis.* 206: 1645-51 (2012).
88. Schiller JT, Castellsague X, Garland SM. A review of clinical trials of human papillomavirus prophylactic vaccines. *Vaccine.* 30 Suppl 5: F123-38 (2012).
89. Chesson HW, Forhan SE, Gottlieb SL, Markowitz LE. The potential health and economic benefits of preventing recurrent respiratory papillomatosis through quadrivalent human papillomavirus vaccination. *Vaccine.* 26: 4513-8 (2008).
90. Kenter GG, Welters MJ, Valentijn AR, Lowik MJ, Berends-van der Meer DM, Vloon AP, Essahsah F, Fathers LM, Offringa R, Drijfhout JW, Wafelman AR, Oostendorp J, Fleuren GJ, van der Burg SH, Melief CJ. Vaccination against HPV-16 oncoproteins for vulvar intraepithelial neoplasia. *N Engl J Med.* 361: 1838-47 (2009).
91. Derkay CS, Wiatrak B. Recurrent respiratory papillomatosis: A review. *Laryngoscope.* 118: 1236-47 (2008).
92. Dedo HH, Yu KC. CO(2) laser treatment in 244 patients with respiratory papillomas. *Laryngoscope.* 111: 1639-44 (2001).
93. Buchinsky FJ, Donfack J, Derkay CS, Choi SS, Conley SF, Myer CM, 3rd, McClay JE, Campisi P, Wiatrak BJ, Sobol SE, Schweinfurth JM, Tsuji DH, Hu FZ, Rockette HE, Ehrlich GD, Post JC. Age of child, more than HPV type, is associated with clinical course in recurrent respiratory papillomatosis. *PLoS ONE.* 3: e2263 (2008).

94. Armstrong LR, Derkay CS, Reeves WC. Initial results from the national registry for juvenile-onset recurrent respiratory papillomatosis. RRP task force. Arch Otolaryngol Head Neck Surg. 125: 743-8 (1999).
95. Carvalho CM, Huot L, Charlois AL, Ayari Khalfallah S, Chapuis F, Froehlich P. Prognostic factors of recurrent respiratory papillomatosis from a registry of 72 patients. Acta Otolaryngol. 1-9 (2009).
96. Kashima H, Mounts P, Leventhal B, Hruban RH. Sites of predilection in recurrent respiratory papillomatosis. Ann Otol Rhinol Laryngol. 102: 580-3 (1993).
97. Green H. *A treatise on diseases of the air passages: comprising an inquiry into the history, pathology, causes and treatment of those affections of the throat called bronchitis, chronic laryngitis, clergyman's sore throat etc.* (1846).
98. Derkay CS. Task force on recurrent respiratory papillomas. A preliminary report. Arch Otolaryngol Head Neck Surg. 121: 1386-91 (1995).
99. Armstrong LR, Preston EJ, Reichert M, Phillips DL, Nisenbaum R, Todd NW, Jacobs IN, Inglis AF, Manning SC, Reeves WC. Incidence and prevalence of recurrent respiratory papillomatosis among children in atlanta and seattle. Clin Infect Dis. 31: 107-9 (2000).
100. Omland T, Akre H, Vardal M, Brondbo K. Epidemiological aspects of recurrent respiratory papillomatosis: A population-based study. Laryngoscope. 122: 1595-9 (2012).
101. Wiatrak BJ, Wiatrak DW, Broker TR, Lewis L. Recurrent respiratory papillomatosis: A longitudinal study comparing severity associated with human papilloma viral types 6 and 11 and other risk factors in a large pediatric population. Laryngoscope. 114: 1-23 (2004).
102. Myer CM, 3rd, Willging JP, McMurray S, Cotton RT. Use of a laryngeal micro resector system. Laryngoscope. 109: 1165-6 (1999).
103. El-Bitar MA, Zalzal GH. Powered instrumentation in the treatment of recurrent respiratory papillomatosis: An alternative to the carbon dioxide laser. Arch Otolaryngol Head Neck Surg. 128: 425-8 (2002).
104. Holler T, Allegro J, Chadha NK, Hawkes M, Harrison RV, Forte V, Campisi P. Voice outcomes following repeated surgical resection of laryngeal papillomata in children. Otolaryngol Head Neck Surg. 141: 522-6 (2009).
105. Pasquale K, Wiatrak B, Woolley A, Lewis L. Microdebrider versus CO2 laser removal of recurrent respiratory papillomas: A prospective analysis. Laryngoscope. 113: 139-43 (2003).
106. Kuet ML, Pitman MJ. Photoangiolytic laser treatment of recurrent respiratory papillomatosis: A scaled assessment. J Voice. 27: 124-8 (2013).
107. Snoeck R, Wellens W, Desloovere C, Van Ranst M, Naesens L, De Clercq E, Feenstra L. Treatment of severe laryngeal papillomatosis with intralesional injections of cidofovir [(S)-1-(3-hydroxy-2-phosphonylmethoxypropyl)cytosine. J Med Virol. 54: 219-25 (1998).

108. Matthes-Martin S, Feuchtinger T, Shaw PJ, Engelhard D, Hirsch HH, Cordonnier C, Ljungman P, Fourth European Conference on Infections in Leukemia. European guidelines for diagnosis and treatment of adenovirus infection in leukemia and stem cell transplantation: Summary of ECIL-4 (2011). *Transpl Infect Dis.* 14: 555-63 (2012).
109. Zabawski EJ, Jr, Cockerell CJ. Topical and intralesional cidofovir: A review of pharmacology and therapeutic effects. *J Am Acad Dermatol.* 39: 741-5 (1998).
110. Derkay CS, Volsky PG, Rosen CA, Pransky SM, McMurray JS, Chadha NK, Froehlich P. Current use of intralesional cidofovir for recurrent respiratory papillomatosis. *Laryngoscope.* 123: 705-12 (2013).
111. McMurray JS, Connor N, Ford CN. Cidofovir efficacy in recurrent respiratory papillomatosis: A randomized, double-blind, placebo-controlled study. *Ann Otol Rhinol Laryngol.* 117: 477-83 (2008).
112. Chadha NK, James A. Adjuvant antiviral therapy for recurrent respiratory papillomatosis. *Cochrane Database Syst Rev.* (1): CD005053 (2010).
113. Gupta HT, Robinson RA, Murray RC, Karnell LH, Smith RJ, Hoffman HT. Degrees of dysplasia and the use of cidofovir in patients with recurrent respiratory papillomatosis. *Laryngoscope.* 120: 698-702 (2010).
114. Gerein V, Rastorguev E, Gerein J, Jecker P, Pfister H. Use of interferon-alpha in recurrent respiratory papillomatosis: 20-year follow-up. *Ann Otol Rhinol Laryngol.* 114: 463-71 (2005).
115. Healy GB, Gelber RD, Trowbridge AL, Grundfast KM, Ruben RJ, Price KN. Treatment of recurrent respiratory papillomatosis with human leukocyte interferon. results of a multicenter randomized clinical trial. *N Engl J Med.* 319: 401-7 (1988).
116. Kiroglu M, Cetik F, Soyly L, Abedi A, Aydogan B, Akcali C, Kiroglu F, Ozsahinoglu C. Acyclovir in the treatment of recurrent respiratory papillomatosis: A preliminary report. *Am J Otolaryngol.* 15: 212-4 (1994).
117. Borkowski G, Sommer P, Stark T, Sudhoff H, Luckhaupt H. Recurrent respiratory papillomatosis associated with gastroesophageal reflux disease in children. *Eur Arch Otorhinolaryngol.* 256: 370-2 (1999).
118. Kimberlin DW. Current status of antiviral therapy for juvenile-onset recurrent respiratory papillomatosis. *Antiviral Res.* 63: 141-51 (2004).
119. Rosen CA, Bryson PC. Indole-3-carbinol for recurrent respiratory papillomatosis: Long-term results. *J Voice.* 18: 248-53 (2004).
120. Bakas T, McLennon SM, Carpenter JS, Buelow JM, Otte JL, Hanna KM, Ellett ML, Hadler KA, Welch JL. Systematic review of health-related quality of life models. *Health Qual Life Outcomes.* 10: 134,7525-10-134 (2012).
121. Sintonen H. The 15D instrument of health-related quality of life: Properties and applications. *Ann Med.* 33: 328-36 (2001).
122. Lindman JP, Lewis LS, Accortt N, Wiatrak BJ. Use of the pediatric quality of life inventory to assess the health-related quality of life in children with

- recurrent respiratory papillomatosis. *Ann Otol Rhinol Laryngol.* 114: 499-503 (2005).
123. Chadha NK, Allegro J, Barton M, Hawkes M, Harlock H, Campisi P. The quality of life and health utility burden of recurrent respiratory papillomatosis in children. *Otolaryngol Head Neck Surg.* 143: 685-90 (2010).
 124. Hill DS, Akhtar S, Corroll A, Croft CB. Quality of life issues in recurrent respiratory papillomatosis. *Clin Otolaryngol Allied Sci.* 25: 153-60 (2000).
 125. van Nieuwenhuizen AJ, Rinkel RN, de Bree R, Leemans CR, Verdonck-de Leeuw IM. Patient reported voice outcome in recurrent respiratory papillomatosis. *Laryngoscope.* 120: 188-92 (2010).
 126. van Nieuwenhuizen AJ, Rinkel RN, de Bree R, Leemans CR, Verdonck-de Leeuw IM. Patient reported voice outcome in recurrent respiratory papillomatosis. *Laryngoscope.* 120: 188-92 (2010).
 127. Dejonckere PH, Bradley P, Clemente P, Cornut G, Crevier-Buchman L, Friedrich G, Van De Heyning P, Remacle M, Woisard V, Committee on Phoniatics of the European Laryngological Society (ELS). A basic protocol for functional assessment of voice pathology, especially for investigating the efficacy of (phonosurgical) treatments and evaluating new assessment techniques. guideline elaborated by the committee on phoniatics of the european laryngological society (ELS). *Eur Arch Otorhinolaryngol.* 258: 77-82 (2001).
 128. Lindman JP, Gibbons MD, Morlier R, Wiatrak BJ. Voice quality of prepubescent children with quiescent recurrent respiratory papillomatosis. *Int J Pediatr Otorhinolaryngol.* 68: 529-36 (2004).
 129. Lehto L, Aaltonen LM, Rihkanen H. Longstanding recurrent laryngeal papillomatosis: Impact on voice quality. *Eur Arch Otorhinolaryngol.* 264: 777-82 (2007).
 130. Jacobson B, Johnson A, Grywalski C, Silbergleit A, Jacobson G, Benninger M, Newman CW. The voice handicap index (VHI) development and validation. *Am J Speech Lang Pathol.* 6: 66-70 (1997).
 131. Eversole LR. Dysplasia of the upper aerodigestive tract squamous epithelium. *Head Neck Pathol.* 3: 63-8 (2009).
 132. Gerein V, Rastorguev E, Gerein J, Draf W, Schirren J. Incidence, age at onset, and potential reasons of malignant transformation in recurrent respiratory papillomatosis patients: 20 years experience. *Otolaryngol Head Neck Surg.* 132: 392-4 (2005).
 133. Lie ES, Engh V, Boysen M, Clausen OP, Kvernfold H, Stenersen TC, Winther FO. Squamous cell carcinoma of the respiratory tract following laryngeal papillomatosis. *Acta Otolaryngol.* 114: 209-12 (1994).
 134. Klozar J, Taudy M, Betka J, Kana R. Laryngeal papilloma--precancerous condition? *Acta Otolaryngol Suppl.* 527: 100-2 (1997).
 135. Preuss SF, Klussmann JP, Jungehulsing M, Eckel HE, Guntinas-Lichius O, Damm M. Long-term results of surgical treatment for recurrent respiratory papillomatosis. *Acta Otolaryngol.* 127: 1196-201 (2007).

136. Hemmi H, Takeuchi O, Kawai T, Kaisho T, Sato S, Sanjo H, Matsumoto M, Hoshino K, Wagner H, Takeda K, Akira S. A toll-like receptor recognizes bacterial DNA. *Nature*. 408: 740-5 (2000).
137. Takeuchi O, Kaufmann A, Grote K, Kawai T, Hoshino K, Morr M, Muhlradt PF, Akira S. Cutting edge: Preferentially the R-stereoisomer of the mycoplasmal lipopeptide macrophage-activating lipopeptide-2 activates immune cells through a toll-like receptor 2- and MyD88-dependent signaling pathway. *J Immunol*. 164: 554-7 (2000).
138. Iwaki D, Mitsuzawa H, Murakami S, Sano H, Konishi M, Akino T, Kuroki Y. The extracellular toll-like receptor 2 domain directly binds peptidoglycan derived from staphylococcus aureus. *J Biol Chem*. 277: 24315-20 (2002).
139. Chen K, Huang J, Gong W, Iribarren P, Dunlop NM, Wang JM. Toll-like receptors in inflammation, infection and cancer. *Int Immunopharmacol*. 7: 1271-85 (2007).
140. Szczepanski M, Stelmachowska M, Stryczynski L, Golusinski W, Samara H, Mozer-Lisewska I, Zeromski J. Assessment of expression of toll-like receptors 2, 3 and 4 in laryngeal carcinoma. *Eur Arch Otorhinolaryngol*. 264: 525-30 (2007).
141. Sikora J, Frydrychowicz M, Kaczmarek M, Brzezicha B, Mozer-Lisewska I, Szczepanski M, Zeromski J. TLR receptors in laryngeal carcinoma - immunophenotypic, molecular and functional studies. *Folia Histochem Cytobiol*. 48: 624-31 (2010).
142. Szczepanski MJ, Czystowska M, Szajnik M, Harasymczuk M, Boyiadzis M, Kruk-Zagajewska A, Szyfter W, Zeromski J, Whiteside TL. Triggering of toll-like receptor 4 expressed on human head and neck squamous cell carcinoma promotes tumor development and protects the tumor from immune attack. *Cancer Res*. 69: 3105-13 (2009).
143. Tano T, Okamoto M, Kan S, Nakashiro K, Shimodaira S, Yamashita N, Kawakami Y, Hamakawa H. Growth inhibition and apoptosis by an active component of OK-432, a streptococcal agent, via toll-like receptor 4 in human head and neck cancer cell lines. *Oral Oncol*. 48: 678-85 (2012).
144. Tano T, Okamoto M, Kan S, Bando T, Goda H, Nakashiro K, Shimodaira S, Koido S, Homma S, Fujita T, Sato M, Yamashita N, Hamakawa H, Kawakami Y. Immunochemoradiotherapy for patients with oral squamous cell carcinoma: Augmentation of OK-432-induced helper T cell 1 response by 5-FU and X-ray irradiation. *Neoplasia*. 15: 805-14 (2013).
145. Daud II, Scott ME, Ma Y, Shiboski S, Farhat S, Moscicki AB. Association between toll-like receptor expression and human papillomavirus type 16 persistence. *Int J Cancer*. 128: 879-86 (2011).
146. Yu L, Wang L, Li M, Zhong J, Wang Z, Chen S. Expression of toll-like receptor 4 is down-regulated during progression of cervical neoplasia. *Cancer Immunol Immunother*. 59: 1021-8 (2010).
147. Teppo L, Pukkala E, Lehtonen M. Data quality and quality control of a population-based cancer registry. experience in finland. *Acta Oncol*. 33: 365-9 (1994).

148. Saiki RK, Scharf S, Faloona F, Mullis KB, Horn GT, Erlich HA, Arnheim N. Enzymatic amplification of beta-globin genomic sequences and restriction site analysis for diagnosis of sickle cell anemia. *Science*. 230: 1350-4 (1985).
149. Hildesheim A, Schiffman MH, Gravitt PE, Glass AG, Greer CE, Zhang T, Scott DR, Rush BB, Lawler P, Sherman ME. Persistence of type-specific human papillomavirus infection among cytologically normal women. *J Infect Dis*. 169: 235-40 (1994).
150. Meyer T, Arndt R, Stockfleth E, Flammann HT, Wolf H, Reischl U. Strategy for typing human papillomaviruses by RFLP analysis of PCR products and subsequent hybridization with a generic probe. *BioTechniques*. 19: 632-9 (1995).
151. Vacchelli E, Galluzzi L, Eggermont A, Fridman WH, Galon J, Sautes-Fridman C, Tartour E, Zitvogel L, Kroemer G. Trial watch: FDA-approved toll-like receptor agonists for cancer therapy. *Oncoimmunology*. 1: 894-907 (2012).
152. Szczepanski MJ, Czystowska M, Szajnik M, Harasymczuk M, Boyiadzis M, Kruk-Zagajewska A, Szyfter W, Zeromski J, Whiteside TL. Triggering of toll-like receptor 4 expressed on human head and neck squamous cell carcinoma promotes tumor development and protects the tumor from immune attack. *Cancer Res*. 69: 3105-13 (2009).
153. Weyandt GH, Tollmann F, Kristen P, Weissbrich B. Low risk of contamination with human papilloma virus during treatment of condylomata acuminata with multilayer argon plasma coagulation and CO laser ablation. *Arch Dermatol Res*. 303: 141-4 (2011).
154. Bergbrant IM, Samuelsson L, Olofsson S, Jonassen F, Ricksten A. Polymerase chain reaction for monitoring human papillomavirus contamination of medical personnel during treatment of genital warts with CO₂ laser and electrocoagulation. *Acta Derm Venereol*. 74: 393-5 (1994).