

The Journal of Laryngology & Otology

<http://journals.cambridge.org/JLO>

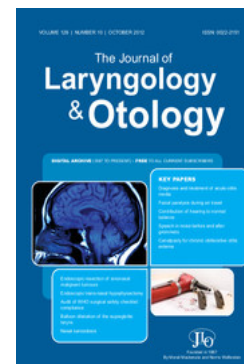Additional services for *The Journal of Laryngology & Otology*:

Email alerts: [Click here](#)

Subscriptions: [Click here](#)

Commercial reprints: [Click here](#)

Terms of use : [Click here](#)



Closure of the nasal cavities in the treatment of refractory hereditary haemorrhagic telangiectasia

Valerie J. Lund and David J. Howard

The Journal of Laryngology & Otology / Volume 111 / Issue 01 / January 1997, pp 30 - 33
DOI: 10.1017/S0022215100136369, Published online: 29 June 2007

Link to this article: http://journals.cambridge.org/abstract_S0022215100136369

How to cite this article:

Valerie J. Lund and David J. Howard (1997). Closure of the nasal cavities in the treatment of refractory hereditary haemorrhagic telangiectasia. *The Journal of Laryngology & Otology*, 111, pp 30-33 doi:10.1017/S0022215100136369

Request Permissions : [Click here](#)

Closure of the nasal cavities in the treatment of refractory hereditary haemorrhagic telangiectasia

VALERIE J. LUND, DAVID J. HOWARD

Abstract

From a cohort of 35 patients with hereditary haemorrhagic telangiectasia (HHT), 12 patients have undergone closure of the one or both nasal cavities during the last three years for refractory epistaxis. All had failed other forms of treatment including hormone therapy, laser coagulation and septodermoplasty. All patients were available for follow-up at six months or longer. In all patients where complete closure was achieved (11 out of 12) bleeding ceased completely from the operated side.

Key words: Hereditary haemorrhagic telangiectasia, surgery

Introduction

The condition of hereditary haemorrhagic telangiectasia (HHT) was first described in the 1860s by Sutton (1864) and Babington (1865) although the names of Osler, Rendu, and Weber (1901, 1896, 1907) are more commonly associated with the condition. The hereditary nature of the vascular defect responsible for the telangiectasia is autosomally dominant and non-sex linked.

The clinically established condition has been recognised in all European races and can affect any cutaneous or mucosal surface. Whilst the tongue, skin and nail beds are generally 'protected', lesions on the nasal mucosa, lips and gastrointestinal tracts are particularly vulnerable to trauma. As a consequence epistaxis is present in over 90 per cent of afflicted individuals and serious nose bleeds occur by the age of 30 in 80 per cent of patients (Harrison, 1956). Severe gastrointestinal bleeding and multiple arterio-venous fistulae within the liver and lung can also have serious clinical consequences but it is the repeated nose bleeds which produce the most physically and socially disabling problems for patients.

A variety of treatment strategies have been employed in addition to the usual first aid measures. These include various forms of cautery and laser coagulation, hormonal therapy with oestrogens and progesterones, the use of antifibrinolytic agents such as tranexamic acid and aminocaproic acid, embolization and various forms of septodermoplasty. The clinical success in the short and long term will vary from individual to individual and in any group of patients one encounters those whose nose bleeds continue to be an intractable and

debilitating problem. In these patients, airflow alone provides sufficient trauma to produce bleeding and an alternative therapeutic approach is to close the nostril by a modification of Young's procedure.

Materials and method

From a cohort of 35 patients with HHT receiving various forms of regular treatment, 12 individuals have undergone a modified Young's procedure designed to completely close the nasal cavity. Closure was performed bilaterally in eight individuals on the first occasion but only on the worse side in four, two of whom later requested closure of the second side. There were six men and six women, their ages ranging from 28 to 85 years (Table I). Follow-up ranged from six months to 36 months, mean 21 months. All patients had received previous treatment with argon laser, hormones or septodermoplasty. All patients were suffering frequent severe nose bleeds and were receiving regular iron supplements and/or blood transfusions (10 out of 12).

Technique

When Taylor and Young described their procedure in 1961, little detail was given on the precise technique, other than to state that folds of skin were raised inside the nostrils and sutured together. In the authors' experience, the success of the procedure is entirely dependent upon complete closure of the nasal cavity. This is achieved by a circumferential incision at the muco-cutaneous junction of the nasal vestibule which is divided to form three anterior flaps after infiltration with adrenalin 1:1000 under general anaesthesia (Figure 1). These are then raised

TABLE I
DETAILS OF PATIENTS UNDERGOING NASAL CLOSURE

Subject	Age	Sex	Previous treatment	Young's
1	51	F	Cryotherapy, CO ₂ and argon laser, oral oestrogens, septodermoplasty	Bilateral, re-opened after 4 months
2	43	F	Arterial ligation, radiotherapy, septodermoplasty, argon laser	Bilateral
3	85	M	Oral progesterone, septodermoplasty, argon laser	Bilateral
4	44	F	Argon laser	Bilateral
5	52	M	Oral progesterone, argon laser	Right
6	58	M	Cryotherapy, KTP and argon laser, oral oestrogens	Right
7	58	F	Aminocaproic acid, tranexamic acid, oral oestrogen and progesterone, CO ₂ and argon laser, arterial ligation	Right then left after 6/12
8	28	M	Argon laser	Left
9	58	M	Argon laser	Right
10	37	M	Septodermoplasty, argon laser	Bilateral
11	50	M	Argon laser	Bilateral
12	44	F	Argon laser	Bilateral

retrogradely towards the nasal aperture as atraumatically as possible. Great care should be taken to avoid bleeding from the telangiectasia on the nasal mucosa. The flaps must be sufficiently elevated to allow a completely tension-free closure and may be supported with gel foam soaked in adrenalin. This is done with meticulously placed interrupted sutures of 4/0 catgut. A small amount of chloromycetin ointment is applied to the area. Patients must be instructed to avoid any trauma to the area in the post-operative period. In exceptional cases where advice is unlikely to be taken, a plaster of Paris cast may be applied to the nose for seven to 10 days.

Results

In 11 of the 12 patients, complete closure of the nasal cavity was achieved and this was associated with complete cessation of bleeding. In the first individual in whom the procedure was undertaken, only two flaps were raised and a small dehiscence occurred inferiorly through which some bleeding continued. As a consequence the patient requested that the nasal cavity be reopened. In those four individuals where unilateral closure was performed on their worse side, two subsequently requested closure of the second side, again with complete cessation of bleeding. Many patients are alarmed at the prospect of complete nasal blockage but will frequently agree to closure of the worst side. This is

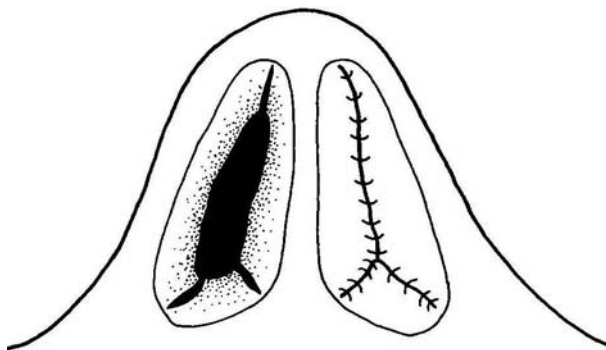


FIG. 1

Schematic drawing of surgical technique showing: three flaps before (right nostril) and after closure (left nostril).

only possible however in the absence of a septal perforation which is sometimes present in patients who have undergone previous bilateral septodermoplasty.

As a consequence of the modified Young's procedure the need for regular blood transfusion has disappeared and patients are now able to undertake social activities hitherto impossible.

Discussion

HHT is a clinically and socially debilitating disease in which epistaxis is one of the major symptoms. The bleeding is sudden and often unpredictable, precipitated by minor actions such as drinking a cup of tea or pulling a jumper over the head, which makes it difficult to pursue a normal job and renders many individuals house-bound creating an inevitable burden on their family. Whilst many treatment strategies are available none have proved entirely successful for all individuals.

The underlying lesion comprises a large vascular channel lined with a single layer of endothelial cells of varying thickness on a continuous basement membrane. Although smooth muscle cells are present they do not form a complete perivascular layer and no elastic tissue is present in relation to the vascular spaces. This inherited defect involves not only terminal but also large vessels as indicated by the associated findings of arterio-venous fistulae (Menefee *et al.*, 1957; Jahnke, 1970). As a consequence any trauma, however slight, may result in bleeding which can be profuse in the absence of normal vasoconstriction. Thus, normal first aid measures such as packing the nose may actually exacerbate the situation by creating further trauma to the vessels. Septodermoplasty, described by Saunders in 1960, aims to remove the mucosa from those parts of the nose most affected by the telangiectasia, i.e. the anterior part of the nasal septum, nasal floor and as much of the lateral wall as proves feasible. A split skin graft is generally used to cover the denuded area though a variety of other materials including amniotic membrane (Laurian *et al.*, 1979) and buccal mucosa have also been suggested (Milton *et al.*, 1993). Inevitably over a period of time there is contraction of the graft and

some revascularization, although this technique can produce an amelioration of the symptoms for several years (McCabe and Kelly, 1972; Harrison, 1982).

The use of systemic oestrogen was first proposed by Koch *et al.* in 1952 and was popularized by Harrison (1963, 1982). The resultant squamous metaplasia from large doses of ethinyl oestradiol significantly reduces the frequency and severity of epistaxis but has inevitable side effects which most male patients find unacceptable. In some male subjects progesterone in doses of 20–30 mg a day seems to offer some of the beneficial effects of oestrogen but with diminished feminising side effects, though some do describe the sensation of bloating due to fluid retention and, occasionally, quite severe pruritus (Richtsmeier *et al.*, 1984).

Applications of caustic soda, submucosal injections of sclerosing fluids, local coagulation with snake venom, and radiotherapy, have all been used with little long-term benefit. However, more recently precise coagulation with the argon, neodymium-YAG and KTP laser can offer reasonable palliation for mild to moderately affected patients (Shapsay and Oliver, 1984; Illum and Bjerring, 1988; Siegel *et al.*, 1991).

It is clear, therefore, that a cohort of patients exists whose epistaxes have proved refractory to many forms of treatment and who represent a significant management problem. In 1961 Taylor and Young described closure of the nostril in the treatment of atrophic rhinitis in a review of 10 patients (five children and five adults). In 1967, Young described his patients' reaction to the procedure as mixed but felt that the disadvantages were outweighed by the advantages in controlling the condition. Most patients described dryness due to mouth breathing and five individuals subsequently underwent tonsillectomy. No adverse effect was reported on the dentition. In five cases the nostrils were reopened, though the problems of vestibular stenosis are mentioned only in passing. In 1991, Brooker and Cinnamon described two cases of epistaxis due to self-inflicted trauma, in one case of which closure of the nostril was performed. In 1993, Gluckman and Portugal presented three cases to the American Triologic Society in whom a modified Young's procedure had been used in the treatment of hereditary haemorrhagic telangiectasia. A more complex technique than that implied by Young was employed, involving the raising of circumferential skin and mucosal flaps via an alarotomy-releasing incision. These individuals had failed other treatment options including neodymium-YAG laser, oestrogen therapy and septodermoplasty and were available for five, seven and eight year follow-up. These cases were published in 1994 coincident with two cases reported by Hosni and Innes.

Most patients are less than enthusiastic at the prospect of complete nasal obstruction fearing problems with respiration, particularly at night and the consequences of a nose bleed after nasal closure. As bleeding is extremely unlikely after the operation and as the adult human is only a facultative nasal

breather, they can be reassured on both scores. However, unilateral closure of the worse side may be one way of allaying their concerns with a view to closure of the second side at a later date. This can only be done in the absence of a septal perforation. It has been our experience that only complete cessation of airflow is effective in preventing epistaxis. In all 11 cases where total closure has been achieved, bleeding has completely ceased. This was also the experience of Gluckman and Portugal (1994) but it was not the case in two individuals reported by Hosni and Innes (1994). Re-opening of the nose would almost certainly be associated with clinical relapse so patients should regard closure as permanent. Notwithstanding this, the benefits of cure are regarded by the patients (and their families) as significantly outweighing the disadvantages.

Conclusion

In the management of HHT, a range of treatment options are available and must be selected on an individual basis. However, in those suffering from severe refractory epistaxis, the most effective results are achieved by permanently preventing air flow through the nasal cavity by a modified Young's procedure. This inevitably produces complete nasal obstruction but is an acceptable price for such a successful clinical outcome. The effectiveness of this relatively simple technique is enormously gratifying for both the patients and the surgeon and the excellent long-term results offer a much needed addition to our therapeutic options in this difficult and debilitating condition.

References

- Babington, B. G. (1865) Hereditary epistaxis. Letter to the Editor of the *Lancet* **2**: 362–363.
- Brooker, D. S., Cinnamon, M. J. (1991) Young's procedure in the treatment of epistaxis. *Journal of Laryngology and Otology* **105**: 847–848.
- Gluckman, J. L., Portugal, L. G. (1994) Modified Young's procedure for refractory epistaxis due to hereditary hemorrhagic telangiectasia. *Laryngoscope* **104**: 1174–1177.
- Harrison, D. F. N. (1956) Babington's disease, Hereditary haemorrhagic telangiectasia. *Guy's Hospital Reports* **104**: 246–266.
- Harrison, D. F. N. (1963) Familial haemorrhagic telangiectases. Twenty cases treated with systemic oestrogen. *Quarterly Journal of Medicine* **33**: 25–38.
- Harrison, D. F. N. (1982) Use of oestrogen in the treatment of familial haemorrhagic telangiectasia. *Laryngoscope* **92**: 314–320.
- Hosni, A. A., Innes, A. J. (1994) Hereditary haemorrhagic telangiectasia: Young's procedure in the management of epistaxis. *Journal of Laryngology and Otology* **108**: 754–757.
- Illum, P., Bjerring, P. (1988) Hereditary hemorrhagic telangiectasia treated by laser surgery. *Rhinology* **26**(1): 19–24.
- Jahnke, V. (1970) Ultrastructure of hereditary telangiectasia. *Archives of Otolaryngology* **92**: 262–265.
- Koch, H. J., Escher, G. C., Lewis, J. S. (1952) Hormonal management of hereditary hemorrhagic telangiectasia. *Journal of the American Medical Association* **149**: 1376–1380.
- Laurian, N., Kalmanovitch, M., Shimberg, R. (1979) Amniotic graft in the management of severe epistaxis due to hereditary haemorrhagic telangiectases. *Journal of Laryngology and Otology* **93**: 589–595.

- McCabe, W. P., Kelly, A. P. (1972) Management of epistaxis in Osler-Rendu-Weber disease. Recurrence of telangiectases within a nasal skin graft. *Plastic and Reconstructive Surgery* **50**: 114-118.
- Menefee, M. G., Flessa, H. C., Glueck, H. I. (1957) Hereditary hemorrhagic telangiectasia. An electron microscopic study of the vascular lesions before and after therapy with hormones. *Archives of Otolaryngology* **101**: 246-251.
- Milton, C. M., Shotton, J. C., Premachandran, D. J., Woodward, B. M., Fabre, J. W., Sergeant, R. J. (1993) A new technique using cultured epithelial sheets for the management of epistaxis associated with hereditary haemorrhagic telangiectasia. *Journal of Laryngology and Otology* **107**: 510-513.
- Osler, W. (1901) On a family form of recurring epistaxis associated with multiple telangiectases of skin and mucous membrane. *John's Hospital Medical Bulletin* **12**: 333-337.
- Rendu, M. (1896) Epistaxis repetees chez un sujet posteur de petits angiones cutanes et murquex. *Bulletin Medical Society of the Medical Hospital Paris* **13**: 731-733.
- Richtsmeier, W., Weaver, G., Steck, W., Jacobson, H., Dewell, R., Olson, J. (1984) Estrogen and progesterone receptors in hereditary haemorrhagic telangiectasia. *Otolaryngology - Head and Neck Surgery* **92**: 564-570.
- Saunders, W. H. (1960) Septal dermoplasty for control of nose bleeds in hereditary hemorrhagic telangiectasia. *Transactions of the American Academy of Ophthalmology and Otolaryngology* **64**: 500-506.
- Shapshay, S. M., Oliver, P. (1984) Treatment of hereditary hemorrhagic telangiectasia by Nd-YAG laser photocoagulation. *Laryngoscope* **94**: 1554-1556.
- Siegel, M. B., Keane, W. M., Atkins, J. F., Rosen, M. R. (1991) Control of epistaxis in patients with hereditary hemorrhagic telangiectasia. *Otolaryngology - Head and Neck Surgery* **105(5)**: 675-679.
- Sutton, H. G. (1864) Epistaxis as an indicator of impaired nutrition and degeneration of the vascular system. *Medical Mirror* **1**: 769-771.
- Taylor, M., Young, A. (1961) Histopathological and histochemical studies on atrophic rhinitis. *Journal of Laryngology and Otology* **75**: 574-590.
- Weber, F. M. (1907) Multiple hereditary developmental angiomas of the skin and mucous membranes with recurrent haemorrhage. *Lancet* **2**: 160-162.
- Young, A. (1967) Closure of the nostrils in atrophic rhinitis. *Journal of Laryngology and Otology* **81**: 515-524.

Address for correspondence:

Professor V. J. Lund, M.S., F.R.C.S.,

Professorial Unit,

Royal National Throat Nose and Ear Hospital,

330/332 Gray's Inn Road,

London WC1X 8DA.