


Accepted Manuscript

Fetal midline anomalies: diagnosis and counselling Part 2: Septal anomalies

Martina Leombroni, Asma Khalil, Marco Liberati, Francesco D'Antonio



PII: S1090-3798(18)30466-5

DOI: <https://doi.org/10.1016/j.ejpn.2018.10.003>

Reference: YEJPN 2488

To appear in: *European Journal of Paediatric Neurology*

Received Date: 23 April 2018

Revised Date: 26 August 2018

Accepted Date: 27 August 2018

Please cite this article as: Leombroni M, Khalil A, Liberati M, D'Antonio F, Fetal midline anomalies: diagnosis and counselling Part 2: Septal anomalies, *European Journal of Paediatric Neurology*, <https://doi.org/10.1016/j.ejpn.2018.10.003>.

This is a PDF file of an unedited manuscript that has been accepted for publication. As a service to our customers we are providing this early version of the manuscript. The manuscript will undergo copyediting, typesetting, and review of the resulting proof before it is published in its final form. Please note that during the production process errors may be discovered which could affect the content, and all legal disclaimers that apply to the journal pertain.

Fetal midline anomalies: diagnosis and counselling**Part 2: Septal anomalies**

Martina Leombroni¹, Asma Khalil², Marco Liberati¹, Francesco D'Antonio^{3,4}

1: Department of Obstetrics and Gynecology, University of Chieti, Chieti, Italy

2: Fetal medicine Unit, Division of Developmental Sciences, St. George's University of London, London, United Kingdom

3: Women's Health and Perinatology Research Group, Department of Clinical Medicine, Faculty of Health Sciences, UiT-The Arctic University of Norway, Tromsø, Norway

4: Department of Obstetrics and Gynaecology, University Hospital of Northern Norway, Tromsø, Norway

Corresponding Author: Francesco D'Antonio, MD, PhD
Department of Clinical Medicine
Faculty of Health Sciences
UiT - The Arctic University of Norway
Hansine Hansens veg 18
9019 Tromsø, Norway
francesco.dantonio@uit.no

HOLOPROSENCEPHALY

1. Definition and prevalence

Holoprosencephaly (HPE) is a heterogeneous spectrum of disorders resulting from failure of induction and patterning of the prosencephalon leading to various degrees of incomplete separation of the cerebral hemispheres, a process normally complete by the fifth week of gestation¹.

HPE is the human most common malformation of the brain²⁻⁴ with a prevalence of 1:250 in embryos⁵ and 1:10 000 among live-born infants⁶⁻⁸, given the high abortively rate.

2. Etiology and pathophysiology

HPE is multifactorial condition involving environmental, teratogenic and genetic causes⁹, commonly acting in the same scenario.

Maternal diabetes mellitus is one of the most common maternal conditions associated with HPE, and infants from diabetic having a 200-fold increase risk for HPE¹⁰. The pathophysiology for the occurrence of HPE in fetuses from diabetic mothers has not been completely elucidated yet but it has been hypothesized to be associated with an interference in the glycolytic process and/or an increase production of oxygen reactive species induced by fetal hyperglycemia which interferes with the development of neural crest cells. Alcohol, retinoic acid and isotretinoin are other commons teratogens associated with an increased risk of HPE¹¹. Recently, animal models of maternal hypocholesterolemia have been reported to increase the risk of HPE⁵; likewise, cholesterol-lowering agents (i.e., statins) have been associated with HPE, although a clear relationship between statin intake during pregnancy and HPE has not been established yet¹².

HPE is common in fetuses with abnormal karyotype and approximately 25-50% of fetuses with HPE have abnormal karyotype^{2,13-15}. The most common aneuploidy associated with HPE is Trisomy 13, followed by Trisomy 18 and triploidy. Furthermore, HPE can be the results of a single gene defect or part of a monogenic syndrome. Autosomal dominant, autosomal recessive, and X-linked patterns of inheritance have been described in genetic HPE. Furthermore, multiple genetic loci have been such as the Sonic Hedgehog (SHH), ZIC2, SIX3, and TG-interacting factor (TGIF) have been described to be associated with induce HPE. The most common genetic syndromes associated with HPE are Smith-Lemli-Opitz, Pallister-Hall, Meckel and Rubinstein-Taybi syndrome¹⁶.

3. Classification

HPE encompasses a heterogeneous group of conditions classified according to the severity of the failure of prosencephalic development in alobar, semilobar and lobar (Figure 1)¹⁷.

Alobar HPE is a lethal anomaly and the most severe type of HPE, characterized by the complete failure of cleavage of the prosencephalon resulting in fused cerebral hemispheres, single midline ventricle (called holovertricle), usually having the appearance of a pancake-like mass, which often communicates posteriorly with a dorsal sac as the result of the posterior bulging of the dorsal wall of the ventricle¹⁸. The interhemispheric fissure, falx cerebri and CC are absent, while basal ganglia, hypothalamic and thalamic nuclei are usually not separated, resulting in the absence of the third ventricle¹⁹. Olfactory bulbs and tracts are absent²⁰.

In *Semilobar HPE*, there is no anterior cleavage the prosencephalon which results in anteriorly fused cerebral hemispheres which show a certain degree of posterior separation. The non-cleaved frontal lobes are usually small, the frontal horns of the lateral ventricle are absent, while posterior horns and trigones are present. A small rudimentary interhemispheric fissure is present in the posterior part of the brain. The CSP and the anterior part of the CC are present, but often rudimentary^{18,21}. The deep gray nuclei are incompletely separated, usually resulting in a small third ventricle, while the head of caudate nuclei is often non-separated. The olfactory bulbs are absent or hypoplastic.

Lobar HPE is the milder phenotypic form of the disease; the cerebral hemispheres are well separated in the posterior middle part of the brain while anteriorly the frontal horns are fused and have a flat roof that communicates with the third ventricle. CPS is always absent while CC may be normal, absent or hypoplastic. Thalami may be fused while olfactory bulbs and tracts may be present, although they are usually hypoplastic.

The middle interhemispheric (MIH) variant or syntelencephaly^{21,22} is thought to be caused by a lack of induction of the dorsal midline and it is characterized by failed separation of the posterior frontal and parietal lobes, while the anterior poles of the frontal and occipital lobes are well divided. The body of the CC is absent, and the caudate nuclei and thalami are incompletely separated. MIH is the only brain anomaly in which the posterior part of the CC forms in the absence of its anterior or middle portion²³.

HPE is associated with other CNS and extra-CNS anomalies in about 90% of cases; the type and incidence of such anomalies is related to the specific cause of HPE²⁴. The most common

anomalies associated with HPE include ACC, microcephaly, facial anomalies, congenital heart diseases, omphalocele, clubfoot, gastrointestinal and renal anomalies.

Facial anomalies are common in HPE; the primary defect leading to a failed cleavage of the prosencephalon is also responsible for an abnormal differentiation of the facial structures, which is directly related to the severity of HPE. The most common facial anomalies associated with HPE are cyclopia (single or fused eyes, absent nose, with or without a proboscis), etmocephaly (severe hypotelorism associated with the presence of a proboscis between the rudimentary eyes), cebocephaly (severe hypotelorism and a single nostril nose), median cleft lip and palate and severe hypotelorism²⁵.

4. Prenatal diagnosis

Prenatal diagnosis of HPE depends upon the severity of the condition. In its most severe forms, prenatal diagnosis is possible since the early first trimester of pregnancy at approximately 9-10 weeks of gestation on a standard axial view of the brain, while semilobar and especially lobar HPE are usually detected in the second trimester of pregnancy but can be also overlooked.

On ultrasound, alobar HPE is characterized by an absent interemispheric fissure, lack of visualization of two distinct cerebral hemispheres filled by the choroid plexus (“butterfly sign”) and presence of a single ventricular cavity communicating with a dorsal sac²⁶⁻²⁹ (Figure 2). Microcephaly is present in 30%³⁰ while abnormal head shape in 80% of cases²⁹. Detection of the severe facial anomalies associated with alobar HPE is not always feasible in the early first trimester although 3D ultrasound may help in their visualization³¹⁻³⁴.

In semilobar HPE, the interemispheric fissure is absent anteriorly, frontal horns are fused and have a flat roof that freely communicates with the third ventricle. Third ventricle is present but small while the posterior horns of the lateral ventricles and the posterior part of the interemispheric fissure is present posteriorly. The dorsal sac is present in 28% of cases of semilobar compared to 92% of alobar HPE³⁵. The hippocampus is seen close to the thalami to form the echogenic ambient cistern and could be used in the differential diagnosis from alobar HPE.

Prenatal diagnosis of lobar HPE can be challenging and this condition is commonly not diagnosed in the first or early second trimester of pregnancy as its main ultrasound feature, an absent CSP, cannot be reliably imagined on ultrasound until 18 weeks of gestation.

Sagittal and especially coronal views of the brain are fundamental in order to make an accurate diagnosis. Furthermore, absent CSP is not specific of lobar HPE and can be associated with other CNS anomalies, such as ACC and SOD. Interhemispheric fissure is rudimentary in its anterior part and present posteriorly; frontal horns are rudimentary and fused to each other. CC can be present, absent, hypo- or dysplastic. On coronal views, frontal lobes appear fused, frontal horns rudimentary with a communication between the lateral bodies of the ventricles and columns of the fornix are fused in the midline. On color Doppler, the anterior cerebral artery is often pushed anteriorly alongside the frontal bone by an abnormal bridge of cortical tissue between the two frontal gyri (snake under the skull sign)³⁶. MIH variant of HPE is rarely diagnosed on prenatal ultrasound with only sporadic cases reported in the published literature. The anomaly is usually suspected in fetuses referred for absent CSP or ACC, especially on coronal views of fetal brain. On ultrasound, interhemispheric fissure is present in the anterior frontal but absent in the posterior frontal and parietal regions. Frontal horns of the lateral ventricles can be normal or rudimentary but well separated. CPS is absent while CC can be totally or partially agenetic or dysplastic. In the median in the median part, the ventricles communicated, thalami are fused in about one third of cases while basal ganglia are normal. Posteriorly, interhemispheric fissure is present and occipital lobes separated.

Ultrasound characteristics of HPE are reported in Table 1²⁶⁻³⁶.

Differential diagnosis of the different variants of HPE is fundamental as the prognosis may significantly vary among the different sub-types of the disease. Alobar HPE is easily recognized since the early first trimester of pregnancy while differential diagnosis between lobar and semilobar HPE is more challenging as no clear boundary exists between the two forms. In semilobar HPE, interhemispheric fissure is always absent anteriorly and present posteriorly, frontal horns are absent while posterior are present, thalami are generally partially fused, and third ventricle is small while a dorsal cyst is generally present. Conversely in lobar HPE a rudimentary interhemispheric fissure can be present anteriorly and well developed posteriorly, third ventricle is generally formed, and thalami separated. The presence of a normal cleavage in the proximal anterior part of the brain helps in differentiating MHI variant from lobar HPE; furthermore, the hypothalamus and basal ganglia are commonly affected in lobar compared to MIH variant of HPE³⁷.

HPE may be sometimes difficult to differentiate from severe ventriculomegaly and hydranencephaly, which, in the most severe cases are characterized by a destruction of the midline structure with a large communication between the lateral bodies of the ventricles.

The presence of the anterior and posterior interemispheric fissure, communication between the lateral ventricles mainly in their median portion, normal cleavage of the thalami, presence of a normal corpus callosum, both choroid plexuses in the same side and absence of facial anomalies may trigger the diagnosis of severe ventriculomegaly or hydranencephaly. Conversely, absent or rudimentary anterior interemispheric fissure, communication between the ventricles starting in their anterior portion, lack of cleavage of cerebral hemispheres, presence of fused thalami, callosal agenesis, absent choroid plexus and presence of facial anomalies are typical of HPE.

Other differential diagnoses of lobar HPE includes SOD and isolated agenesis of the CSP³⁴. Ultrasound is the primary imaging modality in detecting HPE, especially in its most severe forms. Fetal MRI can be useful in the milder forms of HPE which are not easily recognized on ultrasound³⁸. MRI can detect fusion of the fornices in lobar HPE and hypoplasia of the optic tract in SOD; furthermore, MRI has been shown to be useful in differentiating between lobar and MIH variant of HPE³⁷.

5. Prognosis

Fetuses affected by alobar HPE, especially if associated with other CNS or extra-CNS anomalies or abnormal karyotype, have a high risk of miscarriage and intra-uterine death and usually do not survive to infancy. In surviving infants, severe neurological deficits, including generalized hypotonia, seizures, feeding problems and mental retardation become apparent since the early neonatal period. Abnormalities of the hypothalamic functions, such as diabetes insipidus and temperature instability are commonly associated with alobar HPE and may require emergency medical treatment, while other endocrine dysfunctions such as hypothyroidism, hypoadrenocorticism and growth hormone deficiency are less common^{39,40}. In children with facial anomalies, impaired oromotor function may lead to aspiration syndrome, recurrent respiratory distress and chronic lung disease. In some cases, tracheostomy is needed to correct respiratory dysfunction. Length of survival has been reported to be correlated with facial anomalies type, from few days in the most severe forms to 12-18 months in children with less severe facial anomalies⁴¹. Survival to adulthood has been rarely reported^{42,43}.

Children with less severe forms of HPE often survive neonatal period and may reach adulthood; in these cases, the most common causes of death include respiratory infections,

aspiration syndrome, dehydration secondary to uncontrolled diabetes insipidus, endocrine anomalies, failure of respiratory and control and heart rate, risk of aspiration, epilepsy and temperature instability^{39,44}. Less severe of HPE form are characterized by mild to moderate mental retardation and about one-half of children with lobar HPE have normal or nearly normal motor function, while almost all have apparently normal vision and hearing³⁹. Children with MIH variant of HPE typically have less severe motor and cognitive disabilities than do those with alobar or semilobar HPE; spasticity, hypotonia, dystonia, and motor development are the most common clinical symptoms affecting these children³⁹.

6. Pre- and post-natal management

Once HPE is detected, prenatal invasive diagnosis, including CMA analysis, should be offered to parents in view of the high risk of chromosomal anomalies. Magnetic resonance imaging is usually not required in case of alobar HPE but can be useful in differentiating among semilobar, lobar and MIH variant HPE which are less commonly detected on ultrasound. Prenatal counselling should mention the high risk of recurrence in case of HPE not associated with chromosomal anomalies. In a small series 21 women with euploid holoprosencephaly, recurrence risk was 20%, thus highlighting the need for genetic parental analysis. Early first ultrasound assessment in the subsequent pregnancy should also be scheduled in these cases in order to detect recurrence⁴⁵. In cases associated with chromosomal anomalies, risk of recurrence is about 1%.

Post-natal management of children with HPE involves multiple medical treatments related to specific clinical symptoms.

SEPTO-OPTIC DYSPLASIA

1. Definition and prevalence

Septo-optic dysplasia (SOD), also known as de Morsier syndrome, is a rare disorder characterized by the presence of optic nerve hypoplasia, midline abnormalities, mainly ACC, and pituitary dysfunctions common leading to panhypopituitarism⁴⁶⁻⁴⁸. It is rather a spectrum of anomalies characterized by a peculiar clinical phenotype including optic nerve, midline and endocrine anomalies rather than a single clinical entity; anomalies of the cortical development, mainly schizencephaly, can co-exist within the classical clinical picture (SOD-plus).

Prevalence is about 1:100000 live-birth and most cases are sporadic with a recurrence risk <1%⁴⁹⁻⁵⁰.

2. Etiology and pathophysiology

Pathogenesis of SOD has not been completely elucidated yet although it has been proposed to be the results of mutation in HESX1, SOX1, SOX3, OTOX 2 e FGF8 genes, which play an essential role in the normal forebrain/pituitary development⁵¹. In particular, cases with SOX2 mutations are associated with severe bilateral eye abnormalities, developmental delay, short stature, esophageal atresia, male genital tract abnormalities and sensorineural hearing loss⁴⁶. Despite this, genetic abnormalities are identified in <1% of SOD. Viral infections, teratogens, such as valproic acid⁵² and maternal cocaine abuse have been also linked with sporadic forms of SOD⁵³.

3. Prenatal diagnosis

Absent CSP and communicating frontal horns of the lateral ventricles, which gives a squared roof appearance, are the classical ultrasound signs of SOD. However, these signs are not specific of SOD and can be encountered even in lobar HPE and isolated agenesis of the CSP⁵⁴⁻⁵⁶.

Interemispheric fissure is normal, while the corpus callosum may be present absent or hypoplastic; when present the course of the anterior cerebral arteries is normal. Fornices are not fused and thalami appear normal, mild ventriculomegaly can be also observed. Schizencephaly may be also observed (SOD-plus). Hypoplasia of the optic nerves and/or chiasma is fundamental in order to diagnose SOD; however, it cannot be easily detected on ultrasound or even MRI and may sometimes develop only after birth. Likewise,

pituitary hypoplasia cannot be detected on ultrasound and may lead to severe hormone deficiency only after birth. Facial anomalies such as hypotelorism, cleft lip and palate and flat nasal bridge are common in fetuses with SOD (Figure 3)⁵⁶⁻⁵⁷.

Differential diagnosis between SOD and lobar HPE is not always feasible prenatally; the anterior part of interhemispheric fissure is normal in SOD while it can be rudimentary in lobar HPE. CSP is absent and frontal horns are fused in either SOD and lobar HPE; however, SOD is characterized by squared appearance of the frontal horns with inferior pointing compared to the flat appearance observed in lobar HPE⁵⁸. Fornices are normal in SOD while are fused in the midline creating an echogenic tick fascicle in the inferior part of the fused frontal horns in lobar HPE (Figure 3). Anomalies in maternal and fetal endocrine function may help in differentiating SOD from lobar HPE. Maternal urinary and serum estriol levels could be low in SOD while analysis of fetal cord blood could reveal fetal growth, adrenocorticotropic hormone (ACTH) and thyroid stimulating hormones deficiency⁵⁷.

In SOD, the optic tract can become abnormal only in the late third trimester or after birth; likewise, endocrine anomalies may not be evident before birth thus SOD cannot be completely rule out prenatally⁵⁷.

Fetal MRI can be useful to detect and quantify the degree of optical nerve and tract involvement, rule out schizencephaly and look associated supra and infra-tentorial anomalies.

5. Prognosis

Clinical presentation of children with SOD is highly variable and depends upon the presence of associated anomalies, such as schizencephaly and ACC, and degree of pituitary involvement. Approximately 30% of SOD cases have complete manifestation of the clinical triad⁵⁹. Ocular anomalies include nystagmus, blindness, inward and outward deviation of the eyes and microphthalmia. Optic nerve dysplasia has an early onset and is common bilateral (88% of cases)⁶⁰⁻⁶¹. However, vision can be nearly normal in a small subset of affected cases. Neurological deficits range from focal epilepsy or hemiparesis to severe mental retardation⁶²⁻⁶³. Abnormal tone and seizures are common in case of SOD associated with schizencephaly.

Furthermore, other neurological anomalies such as cerebellar hypoplasia, schizencephaly, aplasia of the fornix and cortical dysplasia can be present⁶⁴.

Signs of pituitary deficiency are present in 45% to 90% of affected cases and range from isolated GH-deficit to severe panhypopituitarism⁶⁵.

6. Pre- and post-natal management

Fetuses suspected to be affected by SOD, on the basis of absent CSP and fused frontal horns, should undergo a detailed examination of cranial and extracranial structures in order to confirm the diagnosis and rule out associated anomalies. Invasive prenatal diagnosis, including CMA analysis, should be offered to rule out aneuploidy. MRI should be performed in order to detect signs of optic nerve involvement, although this may not be easily detected on MRI and can develop only after birth. Therefore, a follow-up MRI in the third trimester scan can be necessary also to rule out schizencephaly. Cordocentesis should be offered to look for signs of fetal hypopituitarism, although this may become evident only after gestation or after birth. Prenatal counselling should stress the fact that SOD cannot be reliably ruled out prenatally even in fetuses not showing the classical ocular or endocrine anomalies of the disease.

After birth, close follow-up by a multi-disciplinary team is needed in order to optimize hormonal replacements, ensuring ophthalmological care and neurodevelopmental support⁶⁶⁻⁶⁷.

ISOLATED AGENESIS OF THE CAVUM SEPTI PELLUCIDUM

1. Definition and incidence

CSP is an important landmark in the prenatal ultrasound evaluation of the fetal brain and is a marker for normal central forebrain development.

CSP agenesis is a non-specific condition which may be congenital or acquired, isolated or associated with a large variety of CNS anomalies, including ACC, HPE, SOD and hydranencephaly, thus highlighting the need for a thorough examination of fetal brain with either ultrasound and MRI⁶⁸.

It is a rare disorder with an estimated incidence of 2 to 3 cases per 100 000 livebirths⁶⁹.

2. Prenatal diagnosis: ultrasound and MRI

On ultrasound, septal agenesis presents with lack of visualization of CSP and a large communication between the frontal horns of the lateral ventricles (Figure 4). In the partial forms, frontal horns can be identified separately. Septal agenesis is not a specific condition with many midline anomalies presenting with lack of visualization of the CSP, such as lobar HPE and SOD. Therefore, a thorough examination of the midline structures should be performed in order to ascertain whether septal agenesis is isolated or associated with other major CNS anomalies. Furthermore, in some CNS anomalies not involving the midline such as severe ventriculomegaly and hydranencephaly visualization of the CSP may be impaired by the accumulation of cerebrospinal fluid in the ventricular cavity and by the destructive process involving the midline respectively.

Barkovich and Norman⁶⁹ and Malinger et al⁵⁴. have developed a diagnostic algorithm to apply in case of absent visualization of the CSP. Lack of visualization of the CSP should prompt a detailed assessment of the interhemispheric fissure and frontal horns. If there is communication at the level of anterior portion of the lateral ventricles, possible diagnoses are alobar, semilobar or lobar HPE or SOD. Complete absence of interhemispheric fissure, lack of distinct visualization of cerebral hemispheres and presence of a single ventricular cavity suggests alobar HPE, while presence of a posterior cleavage, fusion of the frontal horns and fornices is typical of lobar HPE. Anomalies of the optic nerves and tract, especially on MRI, normal anterior cleavage and downward pointing frontal horns suggests SOD. In case of separated anterior portion of the lateral ventricles, abnormal cleavage at the level of posterior frontal, parietal bones and basal ganglia suggest MIH variant of HPE, while a normal appearance should focus the attention on the presence of severe ventriculomegaly/hydranencephaly, cortical anomalies or an isolated agenesis of the CSP.

Serial follow-up scans during pregnancy are needed in order to elucidate whether agenesis is actually isolated as many anomalies, especially those involving neuronal migration processes, can be evident only in late gestation. Fetal MRI is needed to assess the optic nerves and tract and to rule out cortical anomalies. Despite this, a definitive diagnosis of isolated septal agenesis cannot be reliably performed prenatally as many anomalies may become apparent only after birth.

3. Prognosis

Prognosis of septal agenesis associated with other CNS anomalies is strictly dependent upon the type and severity of the anomaly.

Despite its commonly reported association, failure to visualize the CSP during the second trimester may not always be associated with a CNS anomaly, but may represent a different condition with a peculiar clinical outcome.

In a series of 16 fetuses with absent CSP, normal brain anatomy and a dedicated post-natal follow-up, normal development was reported in 14 children, one child had infantile hypotonia but normal developmental milestones while the other mild motor delay and language delay, thus suggesting that, when isolated, agenesis of CSP may be considered a variation of normal development and carry a relatively good prognosis⁷⁰. Karyotype was normal in all cases. More importantly, complete septal agenesis seems to carry a better prognosis compared to partial. In a retrospective series of seventeen cases with either complete or partial septal agenesis, of the fourteen children with isolated complete SA, thirteen had normal neurological examination while one showed behavioural problems. Furthermore, none of them showed endocrine anomalies. Conversely, of the four children with a partial AS, two had a speech delay and visual-spatial dyspraxia. Similarly, none of the children with complete CSP agenesis had abnormal neuropsychological outcome compared to two with partial agenesis⁷¹. These findings, although affected by the small number of cases analysed, suggest that in most of the cases complete septal agenesis may represent a normal variant with relative good neurodevelopmental outcome, while partial agenesis a destructive process leading to a more generalized neurodevelopmental impairment.

3. Pre and post-natal management

Prenatal identification of apparently isolated septal agenesis should prompt a detailed assessment of fetal brain with either ultrasound and MRI. Invasive prenatal diagnosis should be offered to parents to rule out aneuploidy, while cordocentesis should be proposed to assess

the endocrine status of the fetus which may be altered in SOD. Serial follow-up scans should be arranged in order to rule out anomalies which may become apparent only later on in gestation such as cortical malformations. MRI should be arranged to assess the optical nerves and tract, although this assessment may not always be feasible prenatally and reveal abnormalities only in late gestation or after birth. Parental counselling should stress the fact that a diagnosis of isolated agenesis of CSP cannot be reliably made prenatally in view of the high risk of associated anomalies which can become apparent only later on in gestation or after birth, that postnatal imaging and clinical examination is warranted in order to confirm the diagnosis.

Post-natal management should include MRI, clinical and neuro-ophthalmic examination in order to rule out all the anomalies associated with septal agenesis such as SOD. Long term follow-up is needed to confirm diagnosis as some conditions, such as SOD, may become clinically evident only months after birth.

REFERENCES

- 1- Golden JA. Holoprosencephaly: a defect in brain patterning. *J Neuropathol Exp Neurol* 1998; 57: 991-9
- 2- Roessler E, Muenke M. The molecular genetics of holoprosencephaly. *Am J Med Genet C Semin Med Genet* 2010; 154: 52-61.
- 3- Muenke M, Beachy PA. Holoprosencephaly. In: Scriver CR, et al., editors. *The Metabolic & Molecular Bases of Inherited Disease*. McGraw-Hill; New York: 2001, 6203-6230.
- 4- Cohen MM Jr. Holoprosencephaly: clinical, anatomic, and molecular dimensions. *Birth Defects Res Part A Clin Mol Teratol* 2006; 76: 658-673.
- 5- Edison R, Muenke M. The interplay of genetic and environmental factors in craniofacial morphogenesis: holoprosencephaly and the role of cholesterol. *Congenit Anom (Kyoto)* 2003; 43:1-21.
- 6- Matsunaga E, Shiota K. Holoprosencephaly in human embryos: epidemiologic studies of 150 cases. *Teratology* 1977; 16: 261-72.
- 7- Orioli IM, Castilla EE. Birth prevalence of holoprosencephaly genes in a South American (ECLAMC) population. *Hum Genet* 2010; 109:1-6.
- 8- Leoncini E, Baranello G, Orioli IM. Frequency of holoprosencephaly in the International Clearinghouse Birth Defects Surveillance Systems: Searching for population variations. *Birth Defects Res A Clin Mol Teratol* 2008; 82: 585-91.
- 9- Wallis D, Muenke M. Mutations in holoprosencephaly. *Hum Mutat* 2000; 16:99-108.
- 10- Barr M Jr, Hanson JW, Currey K. Holoprosencephaly in infants of diabetic mothers. *J Pediatr* 1983; 102: 565-8.
- 11- Johnson CY, Rasmussen SA. Non-genetic risk factors for holoprosencephaly. *Am J Med Genet C Semin Med Genet* 2010; 154C: 73-85.
- 12- Edison RJ, Munke M. Central nervous system and limb anomalies in case reports of first trimester statin exposures. *New Engl J Med* 2004; 350: 1579-82.
- 13- Olsen CL, Hughes JP, Youngblood LJ, Sharpe-Stimac M. Epidemiology of holoprosencephaly and phenotypic characteristics of affected children: New York State, 1984-1989. *Am J Med Genet* 1997; 73:217-26.

- 14- Solomon BD, Rosenbaum KN, Meck JM, Muenke M. Holoprosencephaly due to numeric chromosome abnormalities. *Am J Med Genet C Semin Med Genet* 2010; 154C:146-148.
- 15- Petryk A, Graf D, Marcucio R. Holoprosencephaly: signaling interactions between the brain and the face, the environment and the genes, and the phenotypic variability in animal models and humans. *Wiley Interdiscip Rev Dev Biol* 2015; 4: 17-32.
- 16- Berry SM, Gosden C, Snijders RJ, Nicolaidis KH. Fetal holoprosencephaly: associated malformations and chromosomal defects. *Fetal Diagn Ther* 1990; 5: 92-9.
- 17- DeMyer W. Holoprosencephaly (cyclopia- arhinencephaly). In: Vinken PJ, Bruyn GW, Klawans HL eds. *Handbook of clinical neurology. Revised series, 6th ed.* Amsterdam:Elsevier Science Publishers, 1987: 225-244
- 18- Hahn JS, Barnes PD. Neuroimaging advances in holoprosencephaly: Refining the spectrum of the midline malformation. *Am J Med Genet C Semin Med Genet* 2010; 15:120-32.
- 19- Simon EM, Barkovich AJ. Holoprosencephaly: New concepts. *Magn Reson Imaging Clin N Am* 2001; 9: 149-164.
- 20- Yamada S, Uwabe C, Fujii S, Shiota K. Phenotypic variability in human embryonic holoprosencephaly in the Kyoto Collection. *Birth Defects Res A Clin Mol Teratol* 2004; 70: 495-508.
- 21- Winter TC, Kennedy AM, Woodward PJ. Holoprosencephaly: a survey of the entity, with embryology and fetal imaging. *Radiographics* 2015; 35: 275e90.
- 22- Simon EM, Hevner RF, Pinter JD et al. The middle interhemispheric variant of holoprosencephaly. *AJNR Am J Neuroradiol* 2002; 23: 151-155
- 23- Marcorelles P, Laquerriere A. Neuropathology of holoprosencephaly. *Am J Med Genet C Semin Med Genet* 2010; 154: 109-19.
- 24- Shiota K, Yamada S, Komada M, Ishibashi M. Embryogenesis of holoprosencephaly. *Am J Med Genet A* 2007; 143: 3079-87.
- 25- Berry SM, Gosden C, Snijders RJ, Nicolaidis KH. Fetal holoprosencephaly: associated malformations and chromosomal defects. *Fetal Diagn Ther* 1990; 5: 92-9.
- 26- Blaas HG, Eik-Nes SH, Vainio T, Isaksen CV. Alobar holoprosencephaly at 9 weeks gestational age visualized by two- and three-dimensional ultrasound. *Ultrasound Obstet Gynecol* 2000; 15: 62-5.
- 27- Blaas HG. Holoprosencephaly at 10 weeks 2 days (CRL 33 mm). *Ultrasound Obstet Gynecol* 2000; 15: 86-7

- 28- Sepulveda W, Dezerega V, Be C. First- trimester sonographic diagnosis of holoprosencephaly: Value of the “butterfly” sign. *J Ultrasound Med* 2004; 23: 761-765.
- 29- Pilu G, Romero R, Rizzo N et al. Criteria for the prenatal diagnosis of holoprosencephaly. *Am J Perinatol* 1987; 4: 41-9.
- 30- Khalil A, Papageorghiou A, Bhide A, Akolekar R, Thilaganathan B. Biparietal diameter at 11 to 13 weeks' gestation in fetuses with holoprosencephaly. *Prenat Diagn* 2014; 34:134-8.
- 31- Filly RA, Chinn DH, Callen PW. Alobar holoprosencephaly: ultrasonographic prenatal diagnosis. *Radiology* 1984; 151: 455-9.
- 32- Nyberg DA, Mack LA, Bronstein A, Hirsch J, Pagon RA. Holoprosencephaly: prenatal sonographic diagnosis. *AJR Am J Roentgenol* 1987; 149: 1051-1058.
- 33- Huibers M, Papatsonis DN. Prenatal diagnosis of alobar holoprosencephaly, by use of ultrasound and magnetic resonance imaging in the second trimester. *J Matern Fetal Neonatal Med* 2009; 22: 1204-6
- 34- Pilu G, Rizzo N, Orsini LF, Bovicelli L. Antenatal recognition of cerebral anomalies. *Ultrasound Med Biol* 1986; 12: 319-326.
- 35- Plawner LL, Delgado MR, Miller VS et al. Neuroanatomy of holoprosencephaly as predictor of function: Beyond the face predicting the brain. *Neurology* 2002; 59: 1058-1066.
- 36- Bernard JP, Drummond CL, Zaarour P, Molho M, Ville Y. A new clue to the prenatal diagnosis of lobar holoprosencephaly: the abnormal pathway of the anterior cerebral artery crawling under the skull. *Ultrasound Obstet Gynecol* 2002; 19: 605-7.
- 37- Pulitzer SB, Simon EM, Crombleholme TM, Golden JA. Prenatal MR findings of the middle interhemispheric variant of holoprosencephaly. *AJNR Am J Neuroradiol* 2004; 25: 1034-6.
- 38- Griffiths PD, Jarvis D. In utero MR imaging of fetal holoprosencephaly: A structured approach to diagnosis and classification. *AJNR Am J Neuroradiol* 2016; 37: 536-43.
- 39- Barr M, Cohen MM. Holoprosencephaly survival and performance. *Am J Med Genet* 89:116-120.
- 40- Hahn JS, Hahn SM, Kammann H et al. Endocrine disorders associated with holoprosencephaly. *J Pediatr Endocrinol Metab* 2005 18: 935-941.
- 41- Cohen MM, Jr. Holoprosencephaly: clinical, anatomic, and molecular dimensions. *Birth Defects Res A Clin Mol Teratol* 2006; 76: 658-73

- 42- Raam, MS, Solomon BD, Muenke M. Holoprosencephaly: A Guide to Diagnosis and Clinical Management. *Indian Pediatr* 2011; 48: 457-466.
- 43- Croen LA, Shaw GM, Lammer EJ. Holoprosencephaly: epidemiologic and clinical characteristics of a California population. *Am J Med Genet* 1996; 64: 465-72.
- 44- Levey EB, Stashinko E, Clegg NJ, Delgado MR. Management of children with holoprosencephaly. *Am J Med Genet C Semin Med Genet* 2010; 154:183-90.
- 45- David AL, Gowda V, Turnbull C, Chitty LS. The risk of recurrence of holoprosencephaly in euploid fetuses. *Obstet Gynecol* 2007; 110: 658-62.
- 46- Kelberman D, Dattani MT. Genetics of septo-optic dysplasia. *Pituitary* 2007; 10:393-407.
- 47- Reeves DL. Congenital absence of the septum pellucidum. *Bull Johns Hopkins Hosp* 1941; 69: 61-71.
- 48- De Morsier G. Studies on malformation of cranio-encephalic sutures. III. Agenesis of the septum lucidum with malformation of the optic tract. *Schweiz Arch Neurol Psychiatr* 1956; 77: 267-292.
- 49- Patel L, McNally RJ, Harrison E, Lloyd IC, Clayton PE. Geographical distribution of optic nerve hypoplasia and septo-optic dysplasia in Northwest England. *J Pediatr* 2006; 148: 85-88.
- 50- Elster AB, McAnarney ER. Maternal age re septo-optic dysplasia. *J Pediatr* 1979; 94: 162-163.
- 51- McCabe MJ, Alatzoglou KS, Dattani MT. Septo-optic dysplasia and other midline defects: The role of transcription factors: HESX1 and beyond. *Best Pract Res Clin Endocrinol Metab* 2011; 25: 115-24.
- 52- McMahon CL, Braddock SR. Septo-optic dysplasia as a manifestation of valproic acid embryopathy. *Teratology* 2001; 64: 83-6.
- 53- Saranac L, Gucev Z. New insights into septo-optic dysplasia. *Pril (Makedon Akad Nauk Umet Odd Med Nauki)* 2014; 35: 123-7.
- 54- Malinger G, Lev D, Kidron D et al. Differential diagnosis in fetuses with absent septum pellucidum. *Ultrasound Obstet Gynecol* 2005; 25: 42-9.
- 55- Pilu G, Tani G, Carletti A et al. Difficult early sonographic diagnosis of absence of the fetal septum pellucidum. *Ultrasound Obstet Gynecol* 2005; 25: 70-2.
- 56- Polizzi A, Pavone P, Iannetti P, Manfré L, Ruggieri M. Septo-optic dysplasia complex: a heterogeneous malformation syndrome. *Pediatr Neurol* 2006; 34: 66-71.

- 57- Lepinard C, Coutant R, BouSSION F et al. Prenatal diagnosis of absence of the septum pellucidum associated with septo-optic dysplasia. *Ultrasound Obstet Gynecol* 2005; 25: 73-5.
- 58- Volpe P, Campobasso G, De Robertis V, Rembouskos G. Disorders of prosencephalic development. *Prenat Diagn* 2009; 29: 340-54.
- 59- Morishima A, Aranoff GS: Syndrome of septo-optic-pituitary dysplasia: the clinical spectrum. *Brain Dev* 1986; 8: 233-239
- 60- Brodsky MC, Glasier CM. Optic nerve hypoplasia. Clinical significance of associated central nervous system abnormalities on magnetic resonance imaging. *Arch Ophthalmol* 1993; 111: 491.
- 61- Shamma NW, Brown JD, Foreman BW et al. Septo- optic dysplasia associated with polyendocrine dysfunction. *J Med* 1993; 24: 67-74
- 62- Kuriyama M, Shigematsu Y, Konishi K et al. Septo-optic dysplasia with infantile spasms. *Pediatr Neurol* 1988; 4: 62-65.
- 63- Miller SP, Shevell MI, Patenaude Y, Poulin C, O’Gorman AM. Septo-optic dysplasia plus: a spectrum of malformations of cortical development. *Neurology* 2000; 54: 1701-1703.
- 64- Harrison IM, Brosnahan D, Phelan E, Fitzgerald RJ, Reardon W. Septo-optic dysplasia with digital anomalies – a recurrent pattern syndrome. *American Journal of Medical Genetics* 2004; 131: 82-85.
- 65- Hellström A, Aronsson M, Axelson C et al. Children with septo-optic dysplasia - how to improve and sharpen the diagnosis. *Horm Res* 2000; 53: 19-25.
- 66- Hagstrom SA, Pauer GJT, Reid J et al. SOX2 mutation causes anophthalmia, hearing loss, and brain anomalies. *Am J Med Genet A* 2005; 138: 95-98.
- 67- Webb EA, Dattani MT. Septo-optic dysplasia. *Eur J of Hum Genet* 2010; 18: 393-397.
- 68- Schaefer GB, Bodensteiner JB, Thompson JN Jr. Subtle anomalies of the septum pellucidum and neurodevelopmental deficits. *Dev Med Child Neurol* 1994; 36: 554-9.
- 69- Barkovich AJ, Norman D. 1989. Absence of the septum pellucidum: a useful sign in the diagnosis of congenital brain malformations. *AJR Am J Roentgenol* 1989; 152: 353-360.
- 70- Malinger G, Lev D, Oren M, Lerman-Sagie T. Non-visualization of the cavum septi pellucidi is not synonymous with agenesis of the corpus callosum. *Ultrasound Obstet Gynecol* 2012; 40: 165-70

71- Damaj L, Bruneau B, Ferry M et al. Pediatric outcome of children with the prenatal diagnosis of isolated septal agenesis. *Prenat Diagn* 2010; 30: 1143-50.

Table 1. Prenatal US characteristics of HPE

Figure legend

Figure 1. Anatomical representation of the different types of HPE.

Figure 2. HPE in a fetus at 9 weeks of gestation. On ultrasound, alobar HPE is characterized by an absent interemispheric fissure, lack of visualization of two distinct cerebral hemispheres filled by the choroid plexus (“butterfly sign”) and presence of a single ventricular cavity communicating with a dorsal sac. Thalami are also fused in the midline.

Figure 3. Coronal view of a fetus with normal brain anatomy (a), SOD (b) and lobar HPE (c). The anterior part of interemispheric fissure is normal in SOD while it can be rudimentary in lobar HPE. CSP is absent and frontal horns are fused in either SOD and lobar HPE; however, SOD is characterized by squared appearance of the frontal horns with inferior pointing compared to the flat appearance observed in lobar HPE (Figure 3b, arrows). Fornices are normal in SOD while are fused in the midline creating an echogenic tick fascicle in the inferior part of the fused frontal horns in lobar HPE (Figure c) (Courtesy of Professor. P. Volpe).

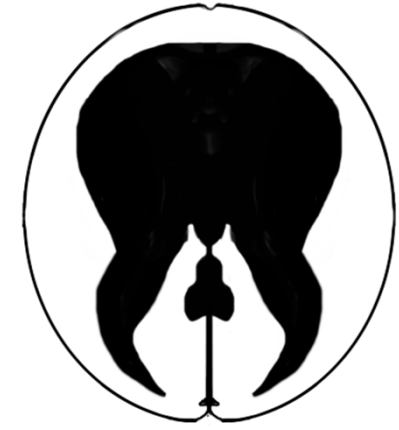Figure 4. Ultrasound axial (a) and coronal (b) views of a fetus affected by isolated septal agenesis. Frontal horns are fused in the midline, the anterior portion of the interemispheric fissure (a) and the corpus callosum (b) are present. (c) coronal view of the same fetus on MRI (Figures 7b and 7c courtesy of Professor T.Lerman-Sagie).



Normal brain




Alobar HPE



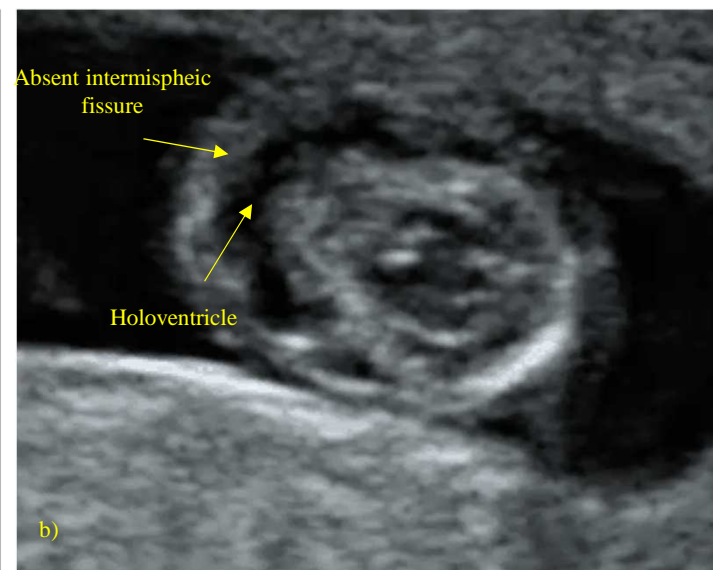
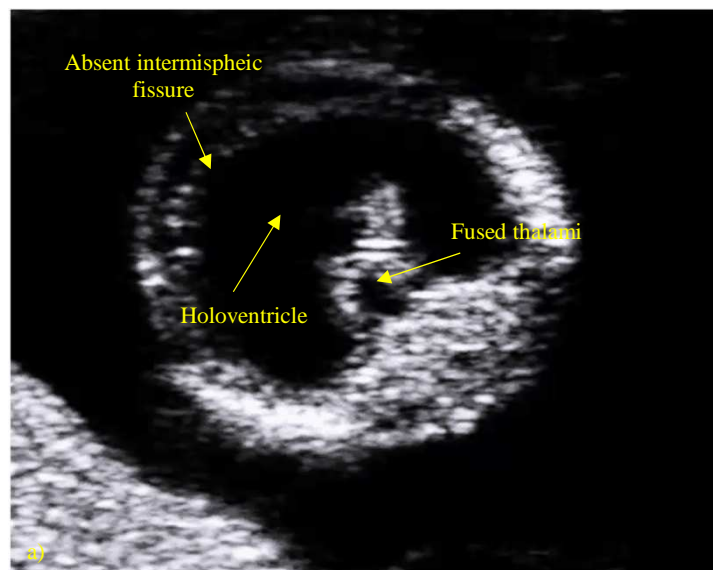
Semilobar HPE

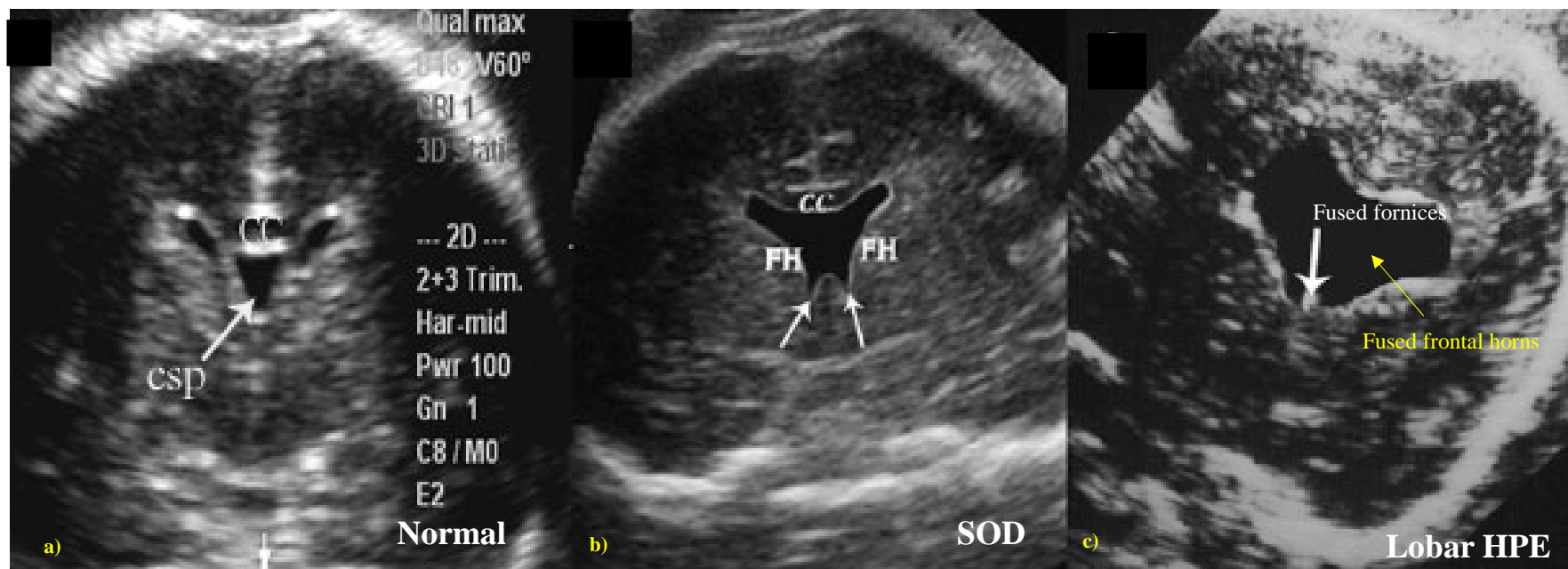


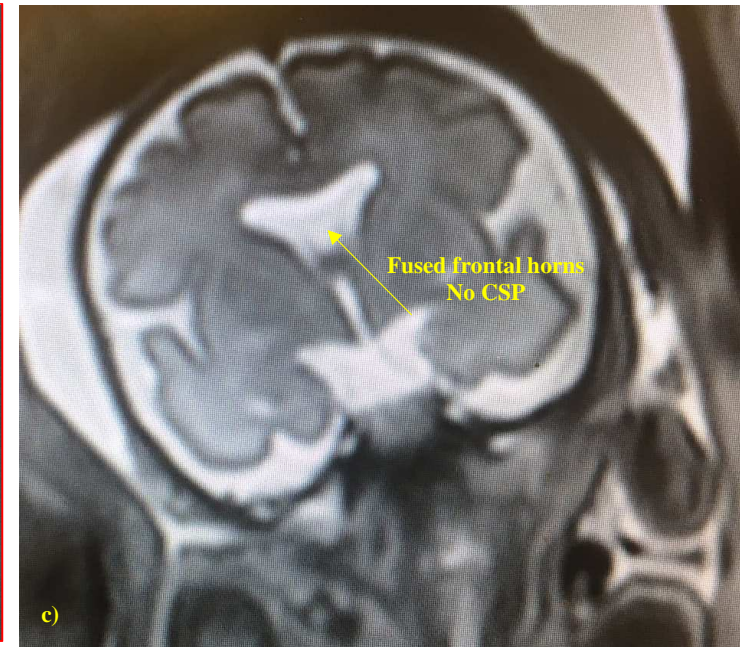
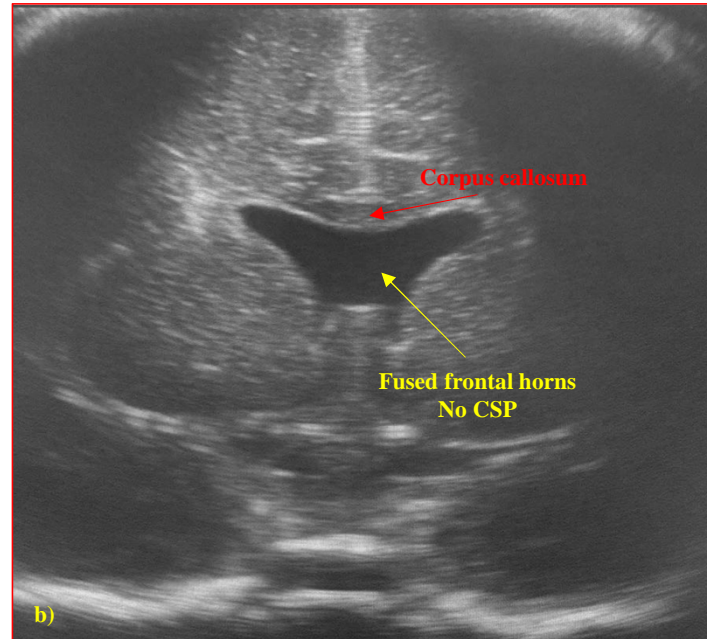
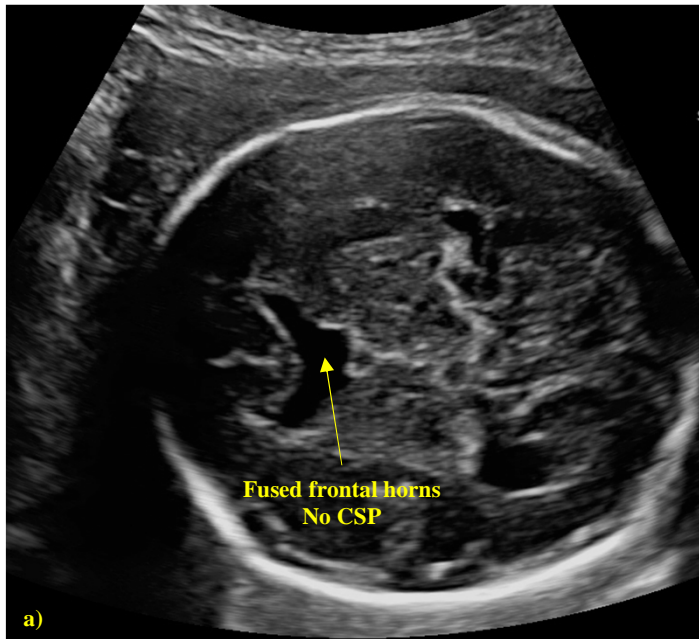
Lobar HPE



Middle interemispheric variant of HPE







	Alobar HPE	Semilobar HPE	Lobar HPE	MIH Varinat
Interemispheric fissure	Absent	Absent anteriorly Presence of some portions of posterior part	Rudimentary in its anterior part Present posteriorly	Present in the anterior frontal Absent in the posterior frontal and parietal regions
Ventricles and Frontal Horns	Single midline ventricular cavity communicating with a dorsal sac	Rudimentary frontal horns Posterior horns are present Hypoplastic third ventricles	Central fusion of the frontal horns, which communicate with the third ventricle	Frontal horns of the lateral ventricles can be normal or rudimentary but well separated In the median part the ventricles communicate
CSP	Absent	Absent	Absent	Absent
Dorsal sac	Present (92%)	Present (30%)	Absent/dysplastic	Absent
Corpus Callosum	Absent	Rostrum, genu and body absent Splenic present	Splenic present. Anterior body could be present	Genu variably present Splenic present Body absent
Thalami and basal ganglia	Fused	Partial fused	Separated	Incompletely separated in many patients
Craniofacial anomalies	Severe	Variable	Moderate/Absent	Moderate/Absent