

Journal of Laryngology & Otology

<http://journals.cambridge.org/JLO>


Additional services for *Journal of Laryngology & Otology*:

Email alerts: [Click here](#)

Subscriptions: [Click here](#)

Commercial reprints: [Click here](#)

Terms of use : [Click here](#)



Optimum imaging and diagnosis of cerebrospinal fluid rhinorrhoea

ValerieJ. Lund, Lloyd Savy, Glyn Lloyd and David Howard

Journal of Laryngology & Otology / Volume 114 / Issue 12 / December 2006, pp 988 - 992
DOI: 10.1258/0022215001904572, Published online: 08 March 2006

Link to this article: http://journals.cambridge.org/abstract_S0022215100002826

How to cite this article:

ValerieJ. Lund, Lloyd Savy, Glyn Lloyd and David Howard (2006). Optimum imaging and diagnosis of cerebrospinal fluid rhinorrhoea. Journal of Laryngology & Otology, 114, pp 988-992
doi:10.1258/0022215001904572

Request Permissions : [Click here](#)

Radiology in Focus

Optimum imaging and diagnosis of cerebrospinal fluid rhinorrhoea

VALERIE J. LUND, M.S., F.R.C.S., F.R.C.S.ED., LLOYD SAVY, B.Sc., M.B., B.S., F.R.C.R., GLYN LLOYD, D.M., F.R.C.R., F.R.C.OPHTH., DAVID HOWARD, F.R.C.S., F.R.C.S.(ED.)

Abstract

Imaging is an important component in the investigation of unilateral watery rhinorrhoea suspicious of cerebrospinal fluid (CSF). Whilst the demonstration of the presence of beta 2 transferrin confirms that CSF is present it may prove difficult to demonstrate the exact site of origin. Fine detail coronal computed tomography (CT) with sections of 1–2 mm thickness through the anterior skull base may show small dehiscences and fractures. The commonest site for congenital dehiscences is the cribriform niche adjacent to the vertical attachment of the middle turbinate anteriorly and the superior and lateral walls of the sphenoid posteriorly. In the presence of frequent or constant CSF rhinorrhoea a CT cisternogram can be helpful in defining the exact site of the leak. Magnetic resonance imaging (MRI) is reserved for defining the nature of soft tissue *i.e.* inflammatory tissue, meningoencephalocele or tumour. Finally, per-operative intrathecal fluorescein is helpful when imaging does not prove positive. A management algorithm for CSF rhinorrhoea is presented.

Key words: Cerebrospinal Rhinorrhoea; Tomography, X-ray Computed; Magnetic Resonance Imaging

Introduction

Cerebrospinal fluid (CSF) rhinorrhoea can occur in a variety of ways, either congenital or acquired (Table I). The most important factor in its detection is a low threshold of suspicion and this may often arise from the history. Any case of unilateral watery rhinorrhoea, particularly if it is increased by posture, should not be empirically treated with intranasal corticosteroids but requires further investigation. Generally it is difficult to identify a leak on simple endoscopic examination of the nose in the Out-patients department but careful examination will assist in the differential diagnosis and may occasionally reveal an encephalocele in the nasal vault. Placing a Dextrastix or similar into the olfactory niche and/or spheno-ethmoidal recess is of interest if the presence of glucose is confirmed as this is highly suggestive of CSF but it is frequently falsely negative and is therefore of limited diagnosis utility.^{1,2,3}

TABLE I
CAUSES OF CSF RHINORRHOEA

Congenital
Acquired
– Trauma – non-surgical
– surgical
– Granulomatous disease
– Tumour
– Spontaneous

CSF = cerebrospinal fluid.

Materials and methods

This paper is based on a review of the literature and a cohort of 33 patients referred with CSF rhinorrhoea between 1993 and 2000. There were 19 females and 14 males. Their ages ranged from six to 68 years with a mean of 38 years. Five were congenital, presenting from birth or in childhood and all of these were associated with encephaloceles. Their ages ranged from 11 to 18 years at the time of referral. Of the acquired leaks, 14 were traumatic (five iatrogenic and nine following head injuries) and 12 occurred spontaneously in adult life. Ten of these were obese women. In seven of the 12 the defect occurred in the anterior skull base, in the cribriform niche adjacent to the vertical attachment of the middle turbinate, and in five the defect was in the sphenoid sinus. One further leak occurred in a patient with significant skull base erosion associated with Wegener's granulomatosis.

Testing of nasal secretion

If the patient is able to produce the rhinorrhoea, often by bending their head forwards, a small sample may be sent for beta transferrin/tau protein analysis. Only a small quantity is required (approximately 0.4 ml) and the patient may be supplied with a sterile container to send a specimen at a later date to the appropriate laboratory. The finding of this protein, which is highly specific to CSF, significantly aids diagnosis^{4,5} but its absence or the inability to collect sufficient secretion does not exclude the diagnosis and therefore recourse to imaging of the skull base is required in all cases.

From the Royal National Throat, Nose and Ear Hospital, Gray's Inn Road, London, UK.

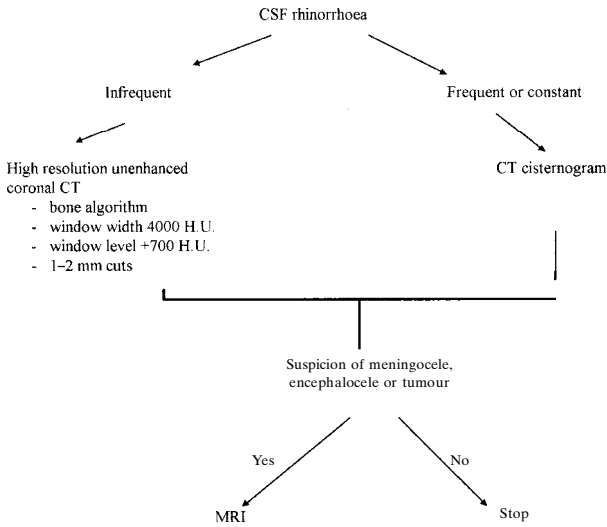


FIG. 1

Imaging protocol for cerebrospinal fluid (CSF) rhinorrhoea.

Imaging

Plain sinus X-rays are of little, if any, value in the precise localization of skull base defects.

Computed Tomography scanning (Figure 1). Imaging plays a pivotal role in the management of CSF rhinorrhoea. A fine detail coronal computed tomography (CT) with sections of 1–2 mm thickness through the anterior skull base may show small defects and fractures in this region. However, partial volume averaging can cause both false negative and false positive findings. These are minimized by using the thinnest sections possible, but at the expense of significantly higher radiation dose to the eyes. Axial CT is not of any value in searching for small defects of the

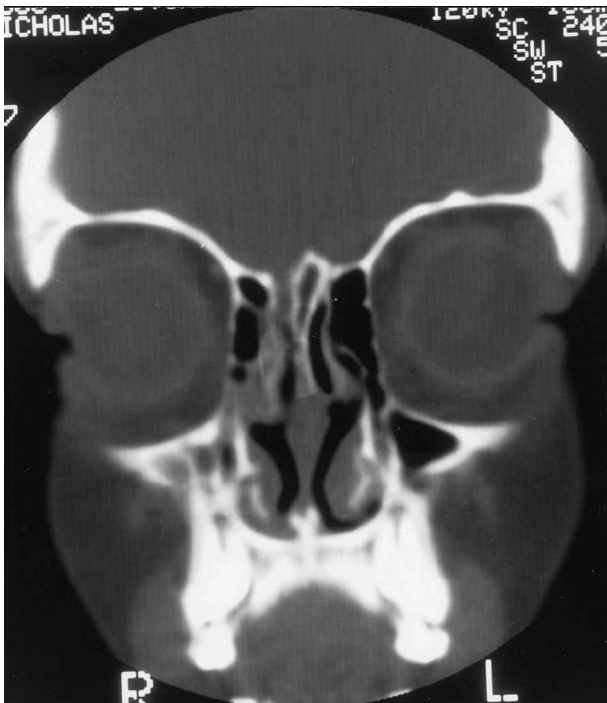


FIG. 2

Coronal computed tomogram showing congenital leak on anterior skull base adjacent to vertical attachment of middle turbinate in cribriform niche.

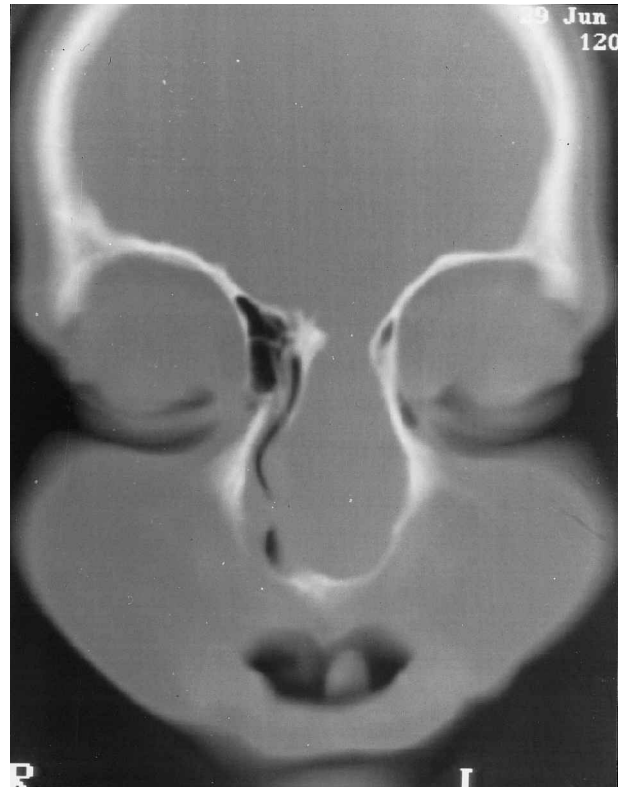


FIG. 3a

Coronal computed tomogram showing large meningo-encephalocele.

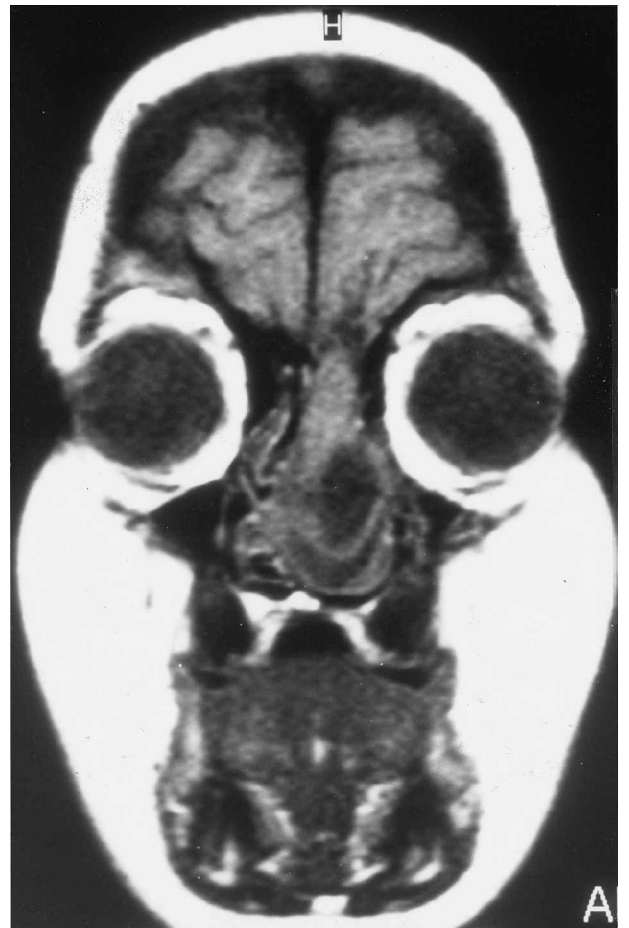

FIG. 3b

T1-weighted magnetic resonance imaging scan showing meningo-encephalocele in same patient.

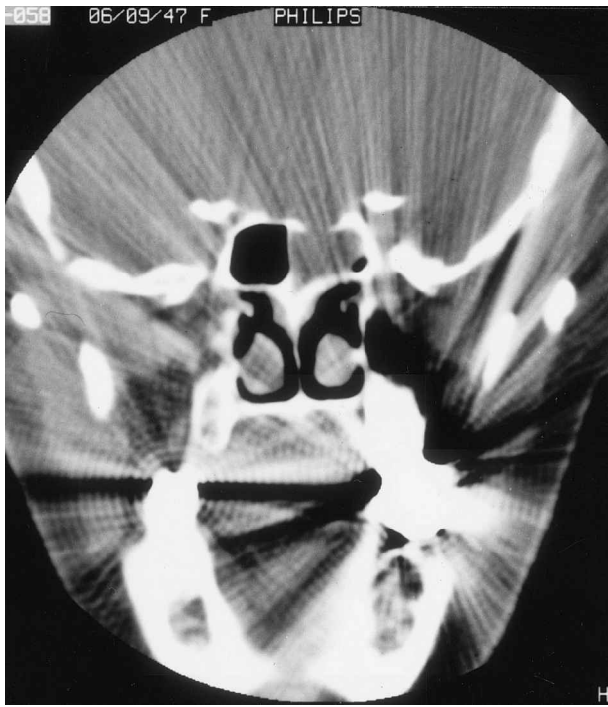


FIG. 4a

Coronal computed tomogram showing congenital encephalocele in roof of left sphenoid.

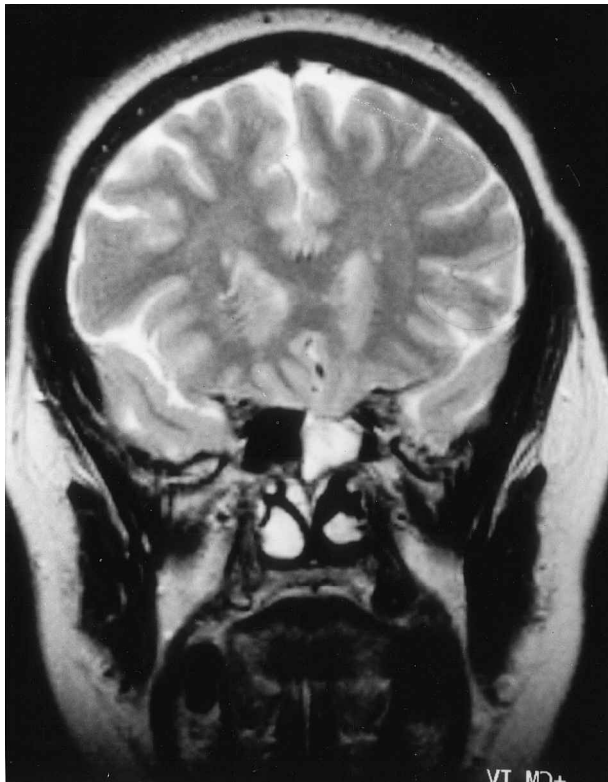


FIG. 4b

T2-weighted coronal magnetic resonance imaging in same patient.

anterior skull base, but is better at assessing the posterior walls of frontal sinuses.

Whilst congenital dehiscences can occur at any point on the skull base, the cribriform niche adjacent to the vertical attachment of the middle turbinate anteriorly and the superior and lateral walls of the sphenoid are the

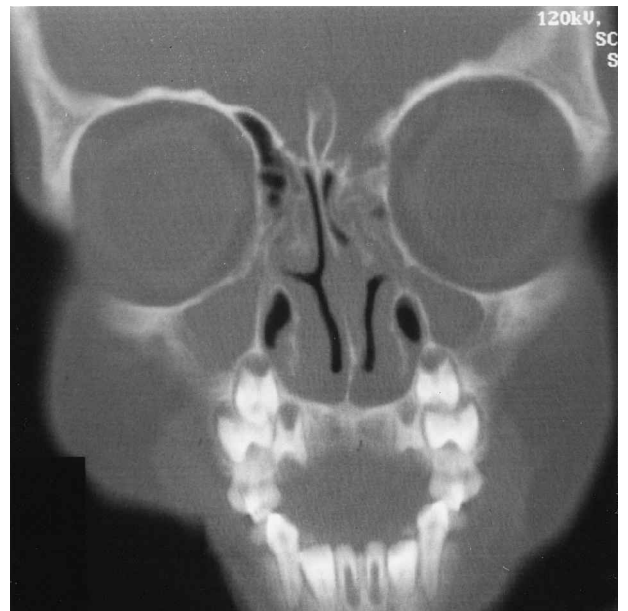


FIG. 5

Coronal computed tomogram showing left skull base fracture in child who has sustained a severe head injury.

commonest sites for congenital defects (Figures 2, 3a, 4a). The size of the defect and associated encephalocele can vary enormously as shown in these examples. Similarly the anterior skull base is the most frequent site for both iatrogenic defects and traumatic fractures (Figure 5). An interesting finding in 10 patients with primary spontaneous CSF rhinorrhoea was a deviation of the crista galli in 50 per cent of cases presumed to result in a weakness at the junction of the crista galli with the cribriform plate.⁶ Not only can CT accurately demonstrate the position of the leak but also the size of the defect and aetiological factors. In so doing it is an important investigation in determining the surgical approach.

CT cisternography (Figure 6). In the majority of cases, CSF is unlikely to be actively leaking at the time of investigation. In such cases the administration of intrathecal

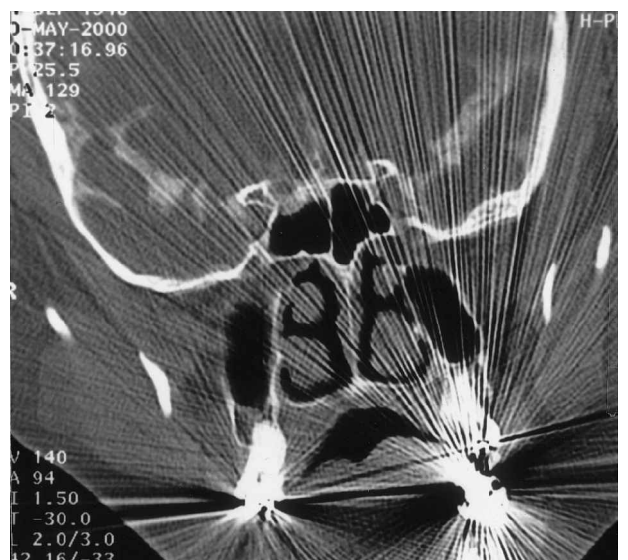

FIG. 6

Coronal computed tomography cisternogram showing cerebrospinal fluid leakage in roof of right sphenoid sinus.

TABLE II
PER-OPERATIVE PROTOCOL FOR CEREBROSPINAL FLUID (CSF)
RHINORRHOEA

Day before operation

Skin test patient with fluorescein (Minims eye drops 2%)

Day of operation

10 mm IM chlorpheniramine followed 5 mins later by 0.5 ml of 5% fluorescein (or 0.25 ml of 10% fluorescein diluted to 0.5 ml with water for injection) IV

Approximately 20 min later intrathecal injection of 0.5 ml 5% fluorescein (or 0.2 ml 10% fluorescein) made up to 10 ml with CSF.

Patient goes to recovery or ward with head of bed tipped down for approximately 2 hours or longer. Patient undergoes normal anaesthetic as for endoscopic sinus surgery. The visualization of the fluorescein may be enhanced by the use of a blue optical filter system introduced into the light source.

iodinated contrast medium prior to high resolution coronal CT (CT cisternography) is unlikely to demonstrate a leak of contrast-enhanced CSF, and thus will be no more accurate than unenhanced CT. However, when the leak is constant, frequent or can be induced by voluntary measures such as the Valsalva manoeuvre, bending down or exercise, then cisternography can provide proof rather than circumstantial evidence of the true site of the leak (a small apparent bone defect on unenhanced CT does not prove that the leak is occurring at that site). Modern low osmolarity, non-ionic contrast agents such as iohexol and iopamidol have a very low incidence of major side-effects seen much more frequently with older compounds such as metrizamide.^{7,8}

Successful CT cisternography requires liaison between radiographic and ward staff and an experienced radiologist. The patient should be admitted to the ward as a day case and transferred to the radiology department preferably when the CSF is leaking. Ten mls of contrast (240 mg/ml) is injected intrathecally via lumbar puncture and the patient is tipped head down on a fluoroscopy table. Less mixing of contrast with CSF occurs if the patient lies decubitus while the contrast enters the head, and then rolls into the prone position, so that contrast reaches the anterior cranial fossae by gravity. Finally the chin is raised so that the contrast pools at the floor of the anterior fossae, and the patient is transferred to CT without delay, where high resolution coronal skull base imaging is performed. The images need to be presented at window settings which differentiate between cortical bone and contrast-enhanced CSF. This method is the optimal imaging modality for demonstrating the site of a CSF leak in the absence of an obvious skull base defect.

It is important to decide whether CT or CT cisternogram should be used at the outset depending on the rate of CSF leak. A common error in imaging strategy is to perform both of these investigations, thus subjecting the patient to a very high and unnecessary radiation dose to the eyes.

Radioisotope cisternography: Radioisotope cisternography was popular in the late 1970s and early '80s^{9,10} using agents such as Indium¹¹¹, DTPA but this has been abandoned largely due to both false positive and false negative results and the inability of the technique to show the fine anatomical detail required to locate the exact site of the defect.

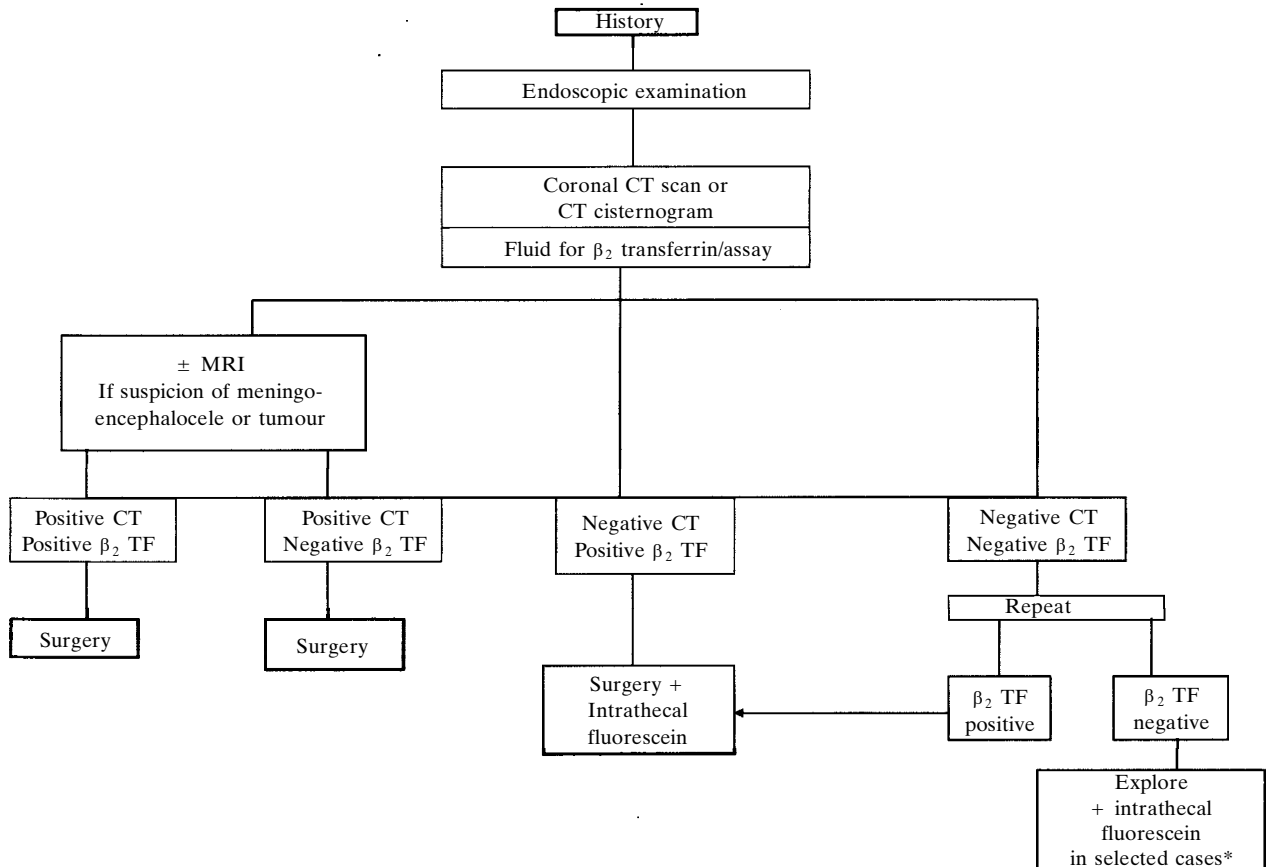


FIG. 7

Management algorithm for CSF rhinorrhoea, after Marshall *et al.*¹⁴ TF = transferrin, = recurrent meningitis, for example; CT = computed tomography; MRI = magnetic resonance imaging.

MRI. MRI cisternography using highly T2-weighted thin sections (without any need for intrathecal contrast) has its proponents and detractors, but the lack of fine bone detail severely limits its accuracy in localizing CSF leaks. However it can be helpful in distinguishing inflammatory tissue from meningo-encephalocele and in determining the exact contents of the sac (Figure 3b, 4b).

Per-operative diagnosis

If, despite careful imaging, the site of the CSF leak has not been demonstrated and there remains a strong clinical suspicion it may be possible to determine the position of the leak using intrathecal fluorescein.⁵ This is almost always combined with an endoscopic approach for repair of the skull base. Although concerns have been expressed about the potential side effects of fluorescein,^{11,12} if the following protocol is adhered to, the chance of a complication is negligible, (Table II). It is important that the fluorescein is prepared for this indication and is not only sterilized but also filtered to exclude any particulate matter. This protocol is a modification of that described by Stammberger *et al.*¹³ and no side-effects have been encountered in any of the patients treated to date. The use of fluorescein may be integrated into a management protocol for any patient with a history suggestive of CSF rhinorrhoea. (Figure 7)

References

- 1 Kosoy J, Trieff NM, Winklemann P, Bailey BJ. Glucose in nasal secretions. *Arch Otolaryngol* 1972;**95**:225-9
- 2 Persky MS, Rothstein SG, Breda SD, Cohen NL, Cooper P, Ransohoff J. Extracranial repair of cerebrospinal fluid otorhinorrhea. *Laryngoscope* 1991;**101**:134-6
- 3 Calcaterrat T. Diagnosis and management of ethmoid cerebrospinal rhinorrhea. *Otolaryngol Clin North Am* 1985;**18**:99-105
- 4 Meurman OH, Irgala K, Suonpaa J. A new method for the identification of cerebrospinal fluid leakage. *Acta Laryngol* 1979;**87**:366-9
- 5 Oberascher G. A modern concept of cerebrospinal fluid diagnosis in oto- and rhinorrhea. *Rhinology* 1988;**26**:89-103
- 6 Tolley NS, Lloyd GAS, Williams HOL. Radiological study of primary spontaneous CSF rhinorrhoea. *J Laryngol Otol* 1991;**105**:274-7
- 7 Drayer BP, Wilkins RH, Boehnke M, Horton JA, Rosenbaum AE. Cerebrospinal fluid rhinorrhoea demonstrated by metrizamide CT cisternography. *Am J Radiol* 1977;**129**:149-51
- 8 Manelfe C, Guirand B, Tremoulet M. Diagnosis of CSF rhinorrhoea by computerized cisternography using metrizamide. *Lancet* 1997;**2**:1073
- 9 Salar G, Carteri A, Zampieri P. The diagnosis of CSF fistulas with rhinorrhoea by isotope cisternography. *Neuroradiology* 1978;**15**:185-7
- 10 Lantz EJ, Forbes GS, Brown ML, Laws ER. Radiology of cerebrospinal fluid rhinorrhoea. *Am J Neuroradiol* 1980;**1**:391-8
- 11 Mahaley MS, Odom GL. Complications following intrathecal injection of fluorescein. *Neurosurgery* 1966;**25**:298-9
- 12 Moseley JI, Carton CA, Stern WE. Spectrum of complication in the use of intrathecal fluorescein. *J Neurosurg* 1978;**48**:765-7
- 13 Stammberger H. *Functional endoscopic sinus surgery* Philadelphia: B Dekker. 1991
- 14 Marshall AN, Jones NS, Robertson IJA. An algorithm for the management of CSF rhinorrhoea illustrated by 36 cases. *Rhinology* 1999;**37**:182-5

Address for correspondence:

Professor V. J. Lund,
Professor of Rhinology,
Institute of Laryngology and Otology,
University College London,
330 Gray's Inn Road,
London WC1X 8DA, UK

Fax: + 44 (0)20 7833 9480