

Journal of Laryngology & Otology

<http://journals.cambridge.org/JLO>


Additional services for *Journal of Laryngology & Otology*:

Email alerts: [Click here](#)

Subscriptions: [Click here](#)

Commercial reprints: [Click here](#)

Terms of use : [Click here](#)



Imaging for juvenile angiofibroma

Glyn Lloyd, David Howard, ValerieJ. Lund and Lloyd Savy

Journal of Laryngology & Otology / Volume 114 / Issue 09 / September 2000, pp 727 - 730
DOI: 10.1258/0022215001906642, Published online: 08 March 2006

Link to this article: http://journals.cambridge.org/abstract_S0022215100002036

How to cite this article:

Glyn Lloyd, David Howard, ValerieJ. Lund and Lloyd Savy (2000). Imaging for juvenile angiofibroma. Journal of Laryngology & Otology, 114, pp 727-730 doi:10.1258/0022215001906642

Request Permissions : [Click here](#)

Radiology in Focus

Imaging for juvenile angiofibroma

GLYN LLOYD, D.M., F.R.C.R., F.R.C.O.HTH., DAVID HOWARD, F.R.C.S., F.R.C.S.(ED.),
VALERIE J. LUND, M.S., F.R.C.S., F.R.C.S.(ED.), LLOYD SAVY, B.Sc., F.R.C.R.

Abstract

Juvenile angiofibroma presents characteristic imaging signs, many of which allow diagnosis and accurate estimation of extent without recourse to the dangers of biopsy. The diagnosis by computed tomography (CT) is based upon the site of origin of the lesion in the pterygopalatine fossa. There are two constant features: (1) a mass in the posterior nasal cavity and pterygopalatine fossa; (2) erosion of bone behind the sphenopalatine foramen with extension to the upper medial pterygoid plate. Good bone imaging on CT is essential to show invasion of the cancellous bone of the sphenoid. This is the main predictor of recurrence: the deeper the extension, the larger the potential tumour remnant likely to be left following surgery. The characteristic features on magnetic resonance imaging (MRI) are due to the high vascularity of the tumour causing signal voids and strong post-contrast enhancement. MRI shows the pre-operative soft tissue extent of angiofibroma optimally, but its more important application is to provide post-operative surveillance: to show any residual or recurrent tumour, record tumour growth or natural involution and monitor the effects of radiotherapy.

Key words: Angiofibroma; Tomography, X-Ray Computed; Magnetic Resonance Imaging

Introduction

Imaging is now of paramount importance at all stages in the management of angiofibroma. In some patients it may be needed to make the initial diagnosis: with such a vascular tumour severe bleeding may accompany biopsy. For this reason surgeons are reluctant to undertake biopsy of a nasopharyngeal mass in an adolescent male patient and prefer to rely upon imaging methods for deciding whether the mass is likely to be an angiofibroma, or a non-vascular lesion such as an antro-choanal polyp. Once the diagnosis is established the task of imaging is to show the extent of the tumour. Of particular importance is the presence and extent of invasion of the sphenoid, for this is the main determinant of recurrence, a conspicuous feature of the natural history of angiofibroma.¹ The final role of imaging is post-operative surveillance: to show the extent of any recurrence, to allow the size assessment after radiotherapy, or to monitor natural tumour involution.

Materials and method

This review is based on an analysis of the imaging of 84 male patients (8–29 years, mean 15.3 years) with histologically proven angiofibroma; a series collected over a 22-year period since the introduction of routine biplane head and neck computed tomography (CT) in 1978.

Plain X-ray changes

On plain X-ray the tumour presents as a soft tissue mass in the nasopharynx and may resemble an antro-choanal polyp. Holman and Miller² described a characteristic

feature of these tumours on a lateral radiograph, that depends upon its typical location in the pterygomaxillary groove. This is the so called 'antral' sign and consists of an anterior bowing of the posterior wall of the maxillary antrum. The sign is often difficult to recognize on plain X-ray. It is not unique to angiofibroma,³ occurring in other slow-growing neoplasms e.g. schwannoma and is better demonstrated by axial CT.

CT and magnetic resonance imaging

The diagnosis by CT is based on the site of origin of the tumour. The evidence is that angiofibroma arises in the pterygo-palatine fossa in the recess behind the sphenopalatine ganglion, at the exit aperture of the pterygoid (vidian) canal.¹ By the time the tumour has enlarged enough to give rise to symptoms, it will have expanded medially into the nasal cavity via the sphenopalatine foramen, and by erosion of the palatine bone forming the medial boundary of the recess. On coronal CT this gives rise to a combination of two features diagnostic of angiofibroma: namely a mass in the nose and pterygopalatine fossa and erosion of bone behind the sphenopalatine foramen at the root of the medial pterygoid plate (Figure 1).

To show the pre-operative extension of angiofibroma both CT and magnetic resonance imaging (MRI) are employed – the former to show bone changes and the latter to show the soft tissue extent. Of the two, CT is the more important. The complexity of the bony structures at the skull base invaded by angiofibroma demands the best bone imaging available, and this can only be provided by

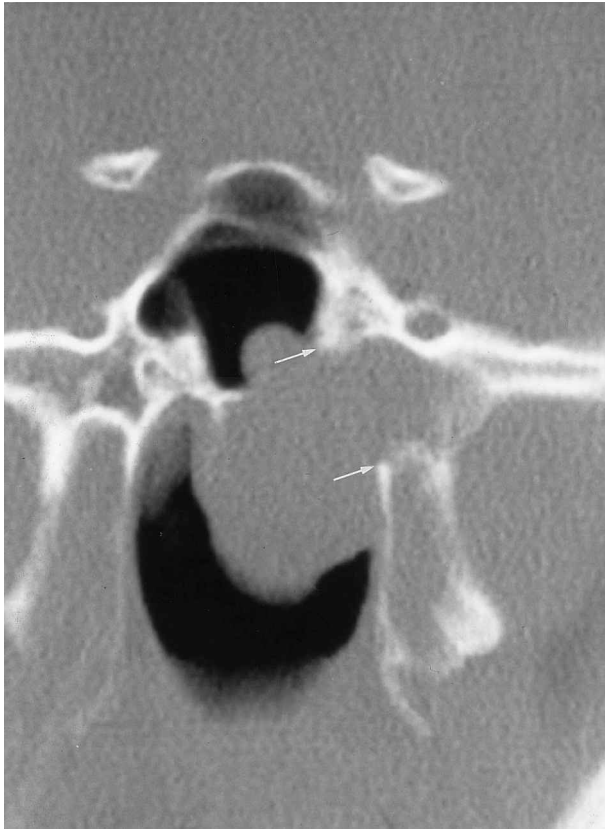

FIG. 1

Coronal CT showing the characteristic changes of angiofibroma: soft tissue mass encroaching on the air space with erosion of bone behind the sphenopalatine foramen (arrows) and early invasion of the sphenoid sinus.

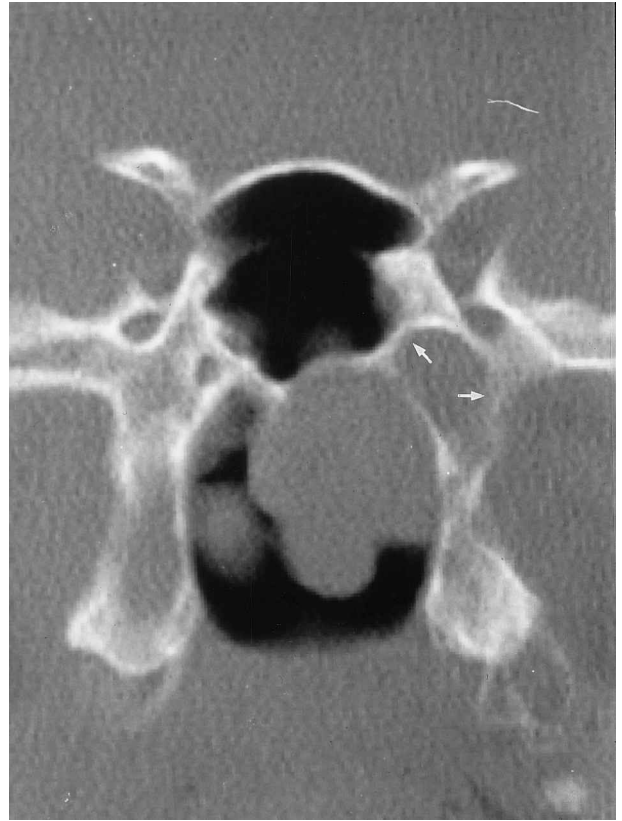

FIG. 2

Coronal CT section showing expansion of the pterygoid canal (arrows) and the soft tissue mass of the angiofibroma in the posterior nasal air space.

CT. From its site of origin in the pterygo-palatine fossa the expanding tumour grows medially into the nose and nasopharynx, gains access to the infratemporal fossa via the pterygo-maxillary fissure and may invade the apex of the orbit through the inferior orbital fissure. From here lying outside the muscle cone, it may extend to the middle fossa of the skull through the superior orbital fissure.

Growth of tumour posteriorly occurs along the line of the pterygoid canal (Figures 2 and 3) invading and eroding the base of the pterygoid process. Two varieties of this extension can be recognized: in the first there is a simple pressure erosion of the pterygoid base and the vaginal process of the sphenoid but without invasion of the pterygoid base or body of the sphenoid; the tumour is largely exophytic within the nasal cavity. In the second variety there is deep extension into the cancellous bone at the base of the pterygoid process via the pterygoid canal (Figure 4a and b) often with invasion and expansion of the diploe of the body and the greater wing of the sphenoid and, in some patients, invasion of the middle cranial fossa (Figure 5).

Invasion of the sphenoid is the main predictor of recurrence in angiofibroma: the deeper the extension, the larger the tumour remnant likely to be left following surgery, and multiple recurrences are liable to occur, when the middle fossa is involved by this route. Recognition of the importance of sphenoid invasion is the major contribution that CT has made to the management of

angiofibroma. The identification of patients at high risk of recurrence has established the need for more radical surgery to eliminate or reduce in size any tumour remnant within the sphenoid.

The high rate of recurrence in angiofibroma^{1,4,5} makes the post-operative surveillance of these patients a most important part of the imaging process. Recurrence occurs at the initial site of origin or within the sphenoid, characteristically expanding the pterygoid base and greater wing. In some patients this expansion of the pterygoid process produces a forward displacement of the pterygoid laminae on post-operative CT scans (Figures 6 and 7), when the main bulk of the tumour in the pterygo-palatine fossa has been removed at surgery, and there is no resistance to the forward pressure by the recurrence behind the pterygoids. At this stage MRI is the important investigation. Recurrences of angiofibroma can occur with astonishing rapidity,⁶ as early as three to four months following surgery. Patients, identified by CT, with a high risk of tumour recurrence therefore require early imaging surveillance. Serial subtraction MRI studies⁷ are used to show the precise size and extent of any residual tumour, record tumour growth or natural involution,⁸ and monitor the effects of radiotherapy.

Role of angiography

The application of CT and MRI has eliminated the need for the routine use of diagnostic angiography and the latter

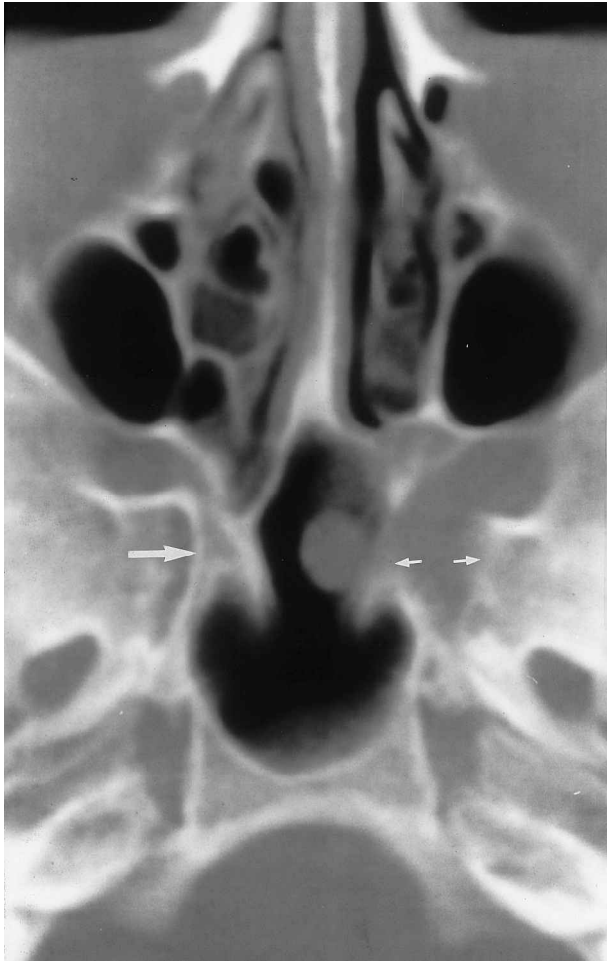

FIG. 3

Same patient as in Figure 2. Axial CT shows expansion of the pterygo-palatine recess and pterygoid canal (small arrows). Normal appearance is shown on the opposite side (large arrow).

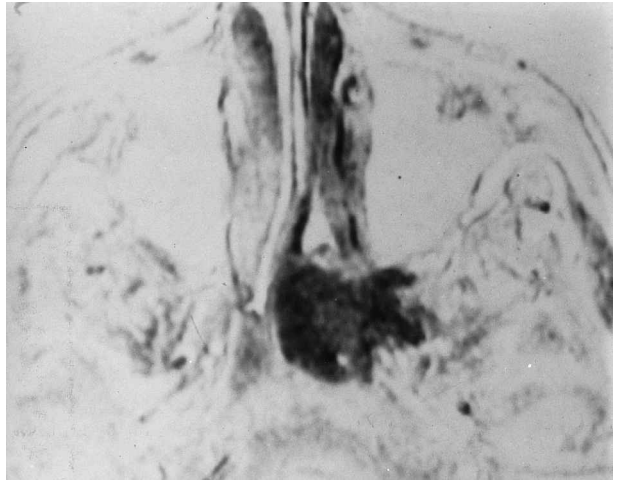


FIG. 4

(b) Corresponding axial section to 4(a) shown by subtraction MRI. The soft tissue extent of the angiofibroma is demonstrated in the pterygoid base.

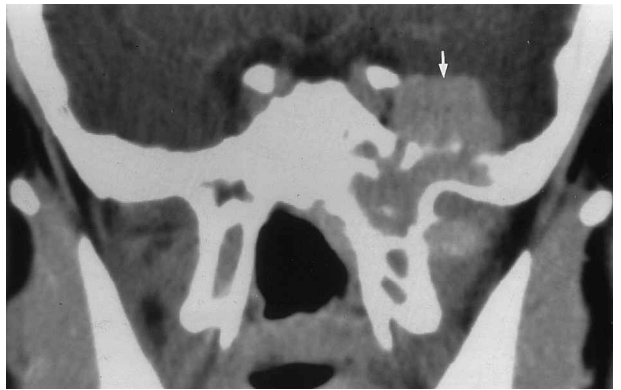


FIG. 5

Coronal CT section at the level of the pterygoids. After introduction of contrast medium, the angiofibroma is shown invading the middle cranial fossa (arrow) from the diploe of the greater wing of the sphenoid.

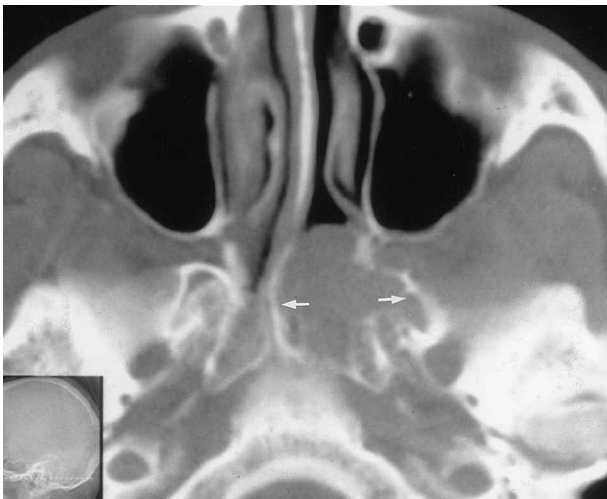

FIG. 4

(a) Angiofibroma invading and expanding the base of the pterygoid process on axial CT (arrows).

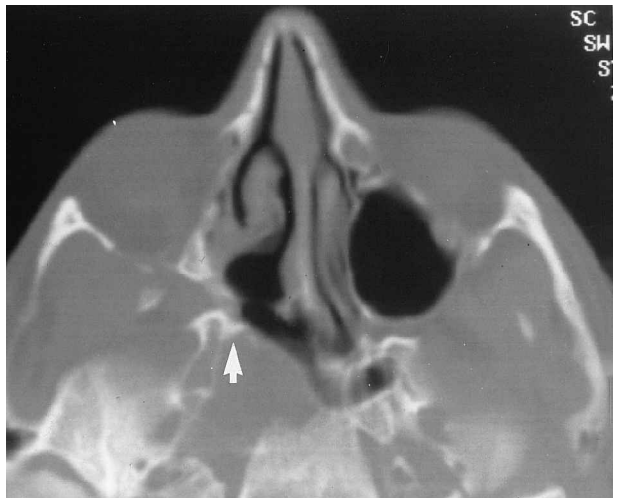

FIG. 6

Recurrence of angiofibroma. Axial CT of the skull base showing forward displacement of the pterygoid laminae (arrow). Previous surgery has removed tumour from the pterygo-palatine fossa, and there is no resistance to the pressure of the recurrence behind the pterygoids.

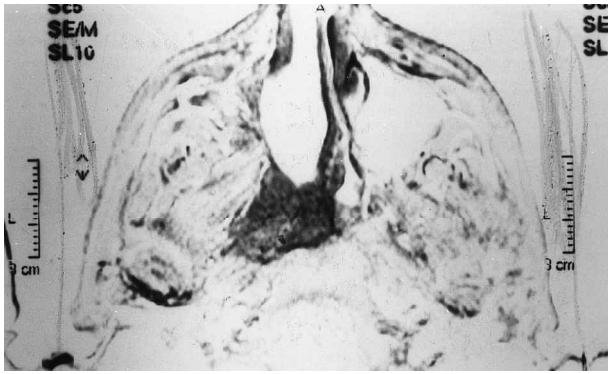

FIG. 7

Subtraction gadolinium-enhanced MRI. Same patient as in Figure 6. The corresponding axial section shows the soft tissue extent of the recurrence.

is only indicated when pre-operative embolization is used. Embolization has not been routinely used in the surgical management of the majority of our patients with angiofibroma, and is reserved for a small minority with massive intracranial involvement. Although there is evidence that it reduces pre-operative blood loss, it may increase the risk of tumour recurrence.¹

References

- 1 Lloyd G, Howard D, Phelps P, Cheesman A. Juvenile angiofibroma: the lessons of 20 years of modern imaging. *J Laryngol Otol* 1999;**113**:127-34
- 2 Holman CB, Miller WE. Juvenile nasopharyngeal angiofibroma. *Am J Roentgenol* 1965;**94**:292-8
- 3 Lloyd GAS, Phelps PD. Juvenile angiofibroma: imaging by magnetic resonance, CT and conventional techniques. *Clin Otolaryngol* 1986;**11**:247-59
- 4 Harma RA. Nasopharyngeal angiofibroma. *Acta Otolaryngol* 1959;(Suppl 147):7-74
- 5 Gullane PJ, Davidson J, O'Dwyer T, Forte V. Juvenile angiofibroma: a review of the literature and a case series report. *Laryngoscope* 1992;**102**:928-33
- 6 Lafargue B. Considerations sur les fibrose nasopharyngiens étude anatomico-clinique. *Rev Laryngol* 1947;**68**:436-65, 514-39
- 7 Lloyd GAS, Barker PB. Subtraction magnetic resonance for tumours of the skull base and sinuses: a new imaging technique. *J Laryngol Otol* 1991;**105**:628-31
- 8 Weprin LS, Siemers PT. Spontaneous regression of juvenile nasopharyngeal angiofibroma. *Arch Otolaryngol Head Neck Surg* 1991;**117**:796-9

Address for correspondence:
 Professor V. J. Lund,
 Institute of Laryngology and Otology,
 University College London,
 330 Gray's Inn Road,
 London WC1X 8DA, UK.

Fax: +44 (0)20 7833 9480