

Tissue screening after breast reduction

Patients who undergo breast reduction surgery have a low risk of being found to have breast cancer, but they need to be made aware of it—and doctors need to debate whether routine histological examination of tissue specimens is a good idea say **Mohammed Keshtgar and colleagues**. We also sought the views of **Tom Treasure**, a surgeon, **Jeremy Sugarman**, an ethicist, and **Tessa Boase**, a lay person

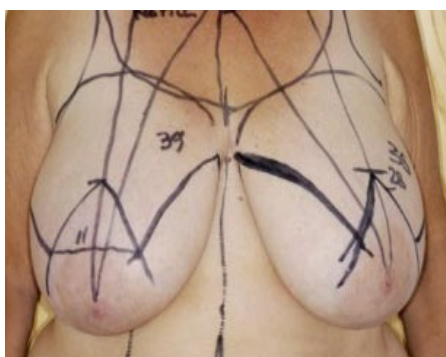
Reduction mammoplasty is one of the most common procedures performed by plastic surgeons all around the world.¹ For decades, it has been a common practice to send even normal looking surgical specimens for histopathological analysis because of the possibility of finding asymptomatic breast cancer. A postal questionnaire sent to consultant members of the British Association of Plastic Surgeons in 1994 found that 89% routinely sent breast reduction tissue for histopathology, and 42% of respondents had seen at least one case of breast cancer from these tissues.²

Pathological findings of breast cancer at the time of reduction mammoplasty have been reported.³ In 1960 the incidence of breast carcinoma found after breast reduction surgery was reported to be 0.38%.⁴ In different series, occult carcinoma has been found in 0.05-1.66% of breast reduction specimens, and the chance of finding such a cancer is affected by thoroughness of preoperative and postoperative examinations.⁵ Other authors have described in detail the pathological findings in breast reduction specimens but not found breast cancer in their studies.^{2,6,7} In 27 500 women in Ontario, Canada, who had reduction mammoplasty, 0.06% (95% confidence interval 0.03% to 0.09%) had invasive carcinoma.⁸ In our institution a retrospective review of a prospectively maintained database of over a five year period found positive histology in 0.8% of 391 patients.

The decrease in detection of occult cancer in breast reduction specimens in recent years has been explained by advances in early detection of cancers, improvement in patient education, a younger group of patients undergoing this surgery, and more thorough preoperative screening of patients.^{9,10}

Case history

A 37 year old woman with no known risk factors for breast cancer underwent bilateral reduction mammoplasty and mastopexy for cosmetic reasons. Recovery was uneventful, but histology of the right breast showed non-comedo small cell type ductal carcinoma in



Woman's breasts with incision guidelines prior to reduction

situ with cancer in the lobules. The left breast specimen showed no abnormality.

As the specimens were not oriented the pathologist was unable to be precise about the site of the lesion, but excision was thought to be complete. Follow-up mammograms were done annually, along with physical examination. After her first assessment, microcalcifications were seen in the right breast and interpreted as benign. Three years later new microcalcifications in the midline of the lower right breast were seen; mammotome biopsy showed an area of mixed lobular carcinoma in situ and ductal carcinoma in situ.

A wide local excision was performed, but histology showed that the lesion had not been excised completely. Furthermore, the cosmetic result of this procedure was not satisfactory.

The patient was offered a choice of further excision and radiotherapy or mastectomy and immediate reconstruction, and she chose the latter. The mastectomy with a free flap reconstruction was uneventful, but she will have to undergo further surgery to reconstruct the nipple.

Discussion

Currently, screening for breast cancer by any modality is not recommended in the UK for women under the age of 50—but young women throughout the world are in effect undergoing a “screening” procedure after cosmetic reduction surgery without their informed consent. In this case, a 37 year old

woman, as a result of this screening, was found to have pathology of uncertain clinical importance and has undergone years of anxiety and multiple surgical procedures. Furthermore, she cannot be reassured that this surgery has benefited her.

Several authors have reported that part of the clinical difficulty arises because specimens are not oriented during surgery and therefore it is not possible to identify the exact area affected. Intraoperative tailoring, which includes mobilisation of the tissues, will distort the normal architecture of the breast.^{9,11,12} Thus, the subsequent radiological assessment is not simple, and the surgical decision is often not easy.⁸

The concern is always to achieve complete clearance of the disease. In the survey from Ontario, even though cancers found after breast reduction were detected in an earlier stage than symptomatic cancers in the same region, patients who had had breast reduction were more likely to have mastectomy (67%) than conservative surgery (52%).⁸

Either the routine practice of screening the excised breast tissue should be abandoned completely, or women should be given the opportunity of informed consent for an unproved and potentially harmful screening practice.

Mohammed Keshtgar consultant breast surgeon

Alireza Hamidian Jahromi clinical fellow in breast surgery

Tim Davidson consultant breast surgeon

Paula Escobar clinical fellow in breast surgery

Patrick Mallucci consultant plastic surgeon

Afshin Mosahebi consultant plastic surgeon

Michael Baum emeritus professor of breast surgery,

University Department of Surgery, Royal Free Hampstead NHS Trust and Royal Free and University College Medical School, London NW3 2QG

Correspondence to: M Keshtgar mo.keshtgar@royalfree.nhs.uk

Accepted: 19 November 2008

Contributors and sources: All senior authors have extensive experience in oncological and aesthetic aspects of breast surgery. Data came from their own patient and from a PubMed search using keywords “breast reduction”, “cancer screening”, “reduction mammoplasty”, “breast cancer”, and “ethics”.

Funding: None.

Competing interests: None declared.

Provenance and peer review: Not commissioned; externally peer reviewed.

Patient consent obtained.

- Colwell AS, Kukreja J, Breuing KH, Lester S, Orgill DP. Occult breast carcinoma in reduction mammoplasty specimens: 14-year experience. *Plast Reconstr Surg* 2004;113:1984-8.
- Tittley OG, Armstrong AP, Christie JL, Fatah MF. Pathological findings in breast reduction surgery. *Br J Plast Surg* 1996;49:447-51.
- Maliniac JW. Use of pedicle dermofat flap in mammoplasty. *Plast Reconstr Surg* 1953;12:110-5.
- Snyderman RK, Lizardo JG. Statistical analysis of malignancies found before, during or after routine breast plastic operations. *Plast Reconstr Surg Transplant Bull* 1960;25:253-6.
- Hage JJ, Karim RB. Risk of breast cancer among reduction mammoplasty patients and the strategies used by plastic surgeons to detect such cancer. *Plast Reconstr Surg* 2006;117:727-35.
- Cruz NI, Guerrero A, Gonzalez CI. Current findings in the pathological evaluation of breast reduction specimens. *Bol Asoc Med P R* 1989;81:387-9.
- Strombeck JO. Macromastia in women and its surgical treatment. *Acta Chir Scan Suppl* 1964;341:1-214.
- Tang CI, Brown MH, Levine R, Sloan M, Chong N, Holowaty E. Breast cancer found at the time of breast reduction. *Plast Reconstr Surg* 1999;103:1682-6.
- Jansen DA, Murphy M, Kind GM, Sands K. Breast cancer in reduction mammoplasty: case reports and a survey of plastic surgeons. *Plast Reconstr Surg* 1998;101:361-4.
- White RR IV. Incidence of breast carcinoma in patients having reduction mammoplasty. *Plast Reconstr Surg* 1998;102:1774-5.
- Van der Torre PM, Butzelaar RM. Breast cancer and reduction mammoplasty: the role of routine pre-operative mammography. *Eur J Surg Oncol* 1997;23: 341-2.
- Dinner MI, Artz JS. Carcinoma of the breast occurring in routine reduction mammoplasty. *Plast Reconstr Surg* 1989;83:1042-4.

Cite this as: *BMJ* 2009;338:b630

COMMENTARY

The lay view

If my life had been made unbearable by outsize breasts, and I was finally to undergo the operation leading to their reduction, I think I would be feeling a mixture of anxiety and euphoria as I waited for the anaesthetic. At last, I'd be thinking, life was about to improve immeasurably. No more back ache, chafing, embarrassment, unflattering clothes. Furthest from my mind would be the thought that the surgeons might find cancerous tissue in my breast.

Imagine coming round from the operation: yes, the weight has literally been lifted from your chest. The operation has worked. But there is something else: the surgeon wishes to have a little chat with you. In private. Still tender from surgery, you're told that cancerous cells were found in your breast tissue after routine screening. Would you like to opt for radiotherapy, or perhaps a complete mastectomy?

I exaggerate the brutality of this little interview—but for the woman

in this case report, this is essentially what she will have understood. She went in to acquire more flattering curves. She came out with cancer. Nothing prepared her for this discovery.

Why, she asks, didn't you warn her that there was a risk, no matter how slight, of finding cancer? Why was there no counselling, if you knew you were going to send part of her breast away for histological screening? It would have helped her with the shock, and perhaps encouraged her to think of the operation less as a little cosmetic nip and tuck (as cosmetic surgery is so often presented to women) and more of a surgical procedure.

The other disturbing aspect to this report is the apparently random nature of the sampling and screening. It seems nearly impossible to identify exactly where in the breast the tissue came from (the specimens were not oriented). If you're going to bother with histological screening, surely it

should be done as conscientiously as possible, given the chance (however slight) of discovering cancer?

Like any potential patient, I welcome any procedures made to safeguard my health and would appreciate being informed of every aspect (and associated risk) of an operation. I would not appreciate being left in the dark.

This is supposedly an era of accountability and transparency—of the patient being put first. The current practice of screening of breast tissue after reduction mammoplasty should be maintained and perhaps refined, but the patient should, from start to finish, be kept in the loop. Who else, after all, is this screening supposed to benefit?

Tessa Boase London

tessa.boase@tiscali.co.uk

Competing interests: None declared.

Provenance and peer review:

Commissioned; not externally peer reviewed.

Cite this as: *BMJ* 2009;338:b776

COMMENTARY

A call for preventive ethics

The current practice of sending reduction mammoplasty specimens for routine histological examination can result in a complicated set of circumstances that raise important ethical issues. As described by Keshtgar and colleagues, a small but measurable subset of these specimens show malignancy of uncertain clinical significance.¹ Since patients undergoing this reconstructive procedure apparently are not informed about screening of the tissue removed during surgery, they may be understandably surprised that cancer was found and also face difficult questions about management. This situation is an opportunity for preventive ethics—which seeks to avoid vexing ethical issues by taking steps to avert them. The authors wonder whether

patients should be told explicitly about histological examination and the potential consequences if it turns out to be positive. It would be hard to imagine a justification for not including this sort of information in the consent process for reduction mammoplasty. Even though the likelihood of the specimens being malignant is small, discussing this issue in advance should help to prepare patients to receive the news and to face the complex decisions that follow.

The authors also describe that clinical management may be complicated by the fact that most specimens are not orientated and they ask whether surgeons should make an effort to orientate the specimens as far

as possible. If the tissue is going to be analysed the answer seems to be an unequivocal yes. The primary intent of mammoplasty is cosmetic, but it is a medical procedure, taking place in a medical setting, and those performing it have a fiduciary obligation towards their patients' health and wellbeing. Orientating the specimen would seem to need little extra work and would seem to increase the clinical utility of the information.

Nevertheless, since the proper management of incidentally detected early stage breast cancer is unsettled, there is a crucial lingering important question regarding the appropriateness of routine histological review of these specimens. This matter

warrants careful, expert review of available data and the potential implications of alternative approaches. In the meantime, obtaining informed consent for the histological examination of mammoplasty specimens and orientating these specimens should help to mitigate some of the difficult ethical issues that are encountered in practice.

Jeremy Sugarman Harvey M Meyerhoff professor of bioethics and medicine, Berman Institute of Bioethics and Department of Medicine, 624 N Broadway, Baltimore, MD 21205, USA jsugarml@jhmi.edu

Competing interests: None declared.

Provenance and peer review:

Commissioned; not externally peer reviewed.

1 Keshtgar M, Hamidian Jahromi A, Davidson T, Escobar P, Malluci P, Mosahebi A, et al. Tissue screening after breast reduction. *BMJ* 2009;338:b630.

Cite this as: *BMJ* 2009;338:b753