

Circulation

JOURNAL OF THE AMERICAN HEART ASSOCIATION



S-Nitrosoglutathione Reduces Asymptomatic Embolization After Carotid Angioplasty

Zoltan Kaposzta, Andrew Clifton, Jane Molloy, John F. Martin and Hugh S. Markus

Circulation 2002;106;3057-3062; originally published online Nov 11, 2002;

DOI: 10.1161/01.CIR.0000041251.07332.28

Circulation is published by the American Heart Association, 7272 Greenville Avenue, Dallas, TX 72514

Copyright © 2002 American Heart Association. All rights reserved. Print ISSN: 0009-7322. Online ISSN: 1524-4539

The online version of this article, along with updated information and services, is located on the World Wide Web at:

<http://circ.ahajournals.org/cgi/content/full/106/24/3057>

Subscriptions: Information about subscribing to *Circulation* is online at
<http://circ.ahajournals.org/subscriptions/>

Permissions: Permissions & Rights Desk, Lippincott Williams & Wilkins, a division of Wolters Kluwer Health, 351 West Camden Street, Baltimore, MD 21202-2436. Phone: 410-528-4050. Fax: 410-528-8550. E-mail:
journalpermissions@lww.com

Reprints: Information about reprints can be found online at
<http://www.lww.com/reprints>

S-Nitrosoglutathione Reduces Asymptomatic Embolization After Carotid Angioplasty

Zoltan Kaposzta, MD; Andrew Clifton, FRCR; Jane Molloy, MD;
John F. Martin, F Med Sci; Hugh S. Markus, FRCP

Background—The major complication of carotid angioplasty is embolic stroke, which may occur after balloon inflation and deflation or in the early postintervention period. Platelet adhesion and aggregation to the angioplasty site with subsequent embolization seems to play a major role in early postangioplasty embolization and stroke. During this period, asymptomatic embolic signals can be detected in patients by transcranial Doppler ultrasound despite aspirin and heparin treatment. S-Nitrosoglutathione (GSNO) is a nitric oxide donor that appears to have relative platelet specificity. We evaluated its effectiveness in reducing embolization after carotid angioplasty.

Methods and Results—Sixteen patients undergoing carotid angioplasty and stenting for symptomatic $\geq 70\%$ internal carotid artery stenosis were randomized in a double-blind manner to GSNO or placebo given after surgery for 90 minutes. All patients were pretreated with aspirin and given heparin for 24 hours after the procedure. Transcranial Doppler recordings were made from the ipsilateral middle cerebral artery for 1 hour before treatment and at 0 to 3, 6, and 24 hours after treatment. GSNO resulted in a rapid reduction in the frequency of embolic signals of 95% at 0 to 3 hours and 100% at 6 hours ($P=0.007$ and $P=0.01$ versus placebo, respectively). In the placebo group, 2 patients experienced ipsilateral stroke after the angioplasty. No cerebrovascular events occurred in the GSNO group.

Conclusions—S-Nitrosoglutathione was highly effective in rapidly reducing the frequency of embolic signals after endovascular treatment for symptomatic high-grade carotid stenosis. (*Circulation*. 2002;106:3057-3062.)

Key Words: carotid arteries ■ angioplasty ■ platelets ■ embolism ■ nitric oxide

Clinical trials have demonstrated that carotid endarterectomy reduces recurrent stroke risk in patients with symptomatic carotid stenosis of $\geq 70\%$.^{1,2} Surgery, however, does have several limitations. The perioperative risk of stroke or death was 6.7%¹ and 7%² in recent large clinical trials, but in high-risk patients with significant coronary artery disease, morbidity and mortality may be higher.³ Carotid surgery may cause cranial or superficial nerve injury, and additional complications related to the operative procedure include wound hematoma or infection and anesthetic-related complications.

Percutaneous transluminal angioplasty and stenting have been proposed as an alternative to endarterectomy.⁴⁻⁷ Potential advantages include avoidance of anesthesia, neck wound complications, and nerve injuries. Recent data from a worldwide registry have shown a high technical success rate and an overall stroke rate of $<3\%$,⁵ although other series give rates of 5% or higher. The only randomized study to date, the recently published CAVATAS trial comparing carotid angioplasty and endarterectomy, demonstrated similar stroke rates for the 2 groups of 10% and 9.9%, respectively.⁶

The major complication of carotid angioplasty and stenting is distal embolization, which is the usual cause of perioper-

ative stroke.^{4,5} Two main mechanisms underlie this. First, events may occur immediately after balloon deflation. Rupture of the atherosclerotic plaque results in release of embolic material. More aggressive peri-interventional antiplatelet regimens are unlikely to reduce this embolization. However, the risk of such events can be reduced by distal cerebral protection devices.⁸ Second, embolization may occur in the immediate postangioplasty period. This is presumed to be a result of platelet aggregation and thrombosis at the angioplasty site. Such stroke occurs despite the use of preoperative aspirin and intraintervention heparin.⁴⁻⁶ Ohki et al⁹ used carotid plaques obtained from 8 patients who underwent endarterectomy to examine the mechanism of embolization during angioplasty in an ex vivo model. Particles released were collected and analyzed with light microscopy. The majority of particles (160 with a diameter range of 200 to 1100 μm) were released during balloon dilatation and stenting. A few smaller particles (25 with a diameter range of 120 to 500 μm) were also released during initial guidewire and filter passage.

Consistent with these findings, transcranial Doppler ultrasound studies have demonstrated that high rates of asymptomatic embolization can occur during the early postinterven-

Received August 9, 2002; revision received September 24, 2002; accepted September 24, 2002.

From Clinical Neuroscience, St George's Hospital Medical School (Z.K., H.S.M.); the Department of Neuroradiology, Atkinson Morley's Hospital (A.C.); the Department of Clinical Neuroscience, King's College (J.M.); and University College of London (J.F.M.), London, UK.

Correspondence to Professor Hugh Markus, Clinical Neuroscience, St George's Hospital Medical School, Cranmer Terrace, London SW17 0RE, UK. E-mail h.markus@sghms.ac.uk

© 2002 American Heart Association, Inc.

Circulation is available at <http://www.circulationaha.org>

DOI: 10.1161/01.CIR.0000041251.07332.28

tion phase despite aspirin and heparin therapy.¹⁰ More aggressive antiplatelet regimens might reduce this postangioplasty embolization.⁴ Antiplatelet regimens have been shown to be effective in coronary angioplasty and stenting. However, they may also increase the risk of cerebral hemorrhage, which is a rare complication of carotid angioplasty.¹¹ Because of the serious outcome of cerebral hemorrhage, the results of trials examining antiplatelet regimens on coronary stenting cannot be directly extrapolated to the cerebral circulation. An optimal regimen will be one that reduces this embolization with a minimum risk of cerebral hemorrhage.

Endothelium-derived nitric oxide (NO) plays an important role in preventing platelet aggregation¹² and adhesion.¹³ Conventional NO donors such as glyceryl trinitrate have an antiplatelet effect but also cause hypotension, which may be unwanted in patients with hemodynamically significant carotid stenosis.¹⁴ *S*-Nitrosoglutathione (GSNO) is an *S*-nitrosothiol from which NO is released by the action of enzymes associated with platelet membranes.¹⁵ It has platelet specificity and inhibits platelet adhesion and aggregation to a greater extent than its effect on vascular tone. GSNO inhibits platelet activation in the setting of acute myocardial infarction and unstable angina¹⁶ and coronary angioplasty.¹⁷ GSNO has been shown to markedly reduce the rate of asymptomatic embolization in the immediate postendarterectomy setting at doses that do not cause hypotension.¹⁸ Previous studies in animals and humans have demonstrated few side effects.^{16–18} Pharmacodynamic studies have demonstrated a short half-life of ≈ 6 to 7 minutes.¹⁹

In the present randomized double-blind treatment study, we examined the hypothesis that GSNO reduces cerebral embolization, as detected by transcranial Doppler ultrasound, in patients after carotid angioplasty.

Methods

Subjects

We studied 16 consecutive patients presenting to 2 cerebrovascular services who were undergoing endovascular treatment for symptomatic internal carotid artery stenosis of $\geq 70\%$. No patients had a cardioembolic source of embolism. All were pretreated with aspirin (75 to 300 mg/d) for ≥ 1 week before the treatment. The first 7 received simple balloon angioplasty, and the remaining 9 had primary stent insertions. The study was approved by both local hospital research ethics committees, and each patient gave written informed consent.

Interventional Procedure

Standard carotid artery catheterization was performed via the femoral route. In all cases, sodium heparin (5000 IU IV) was administered 2 minutes before balloon inflation. For the prevention of bradycardia, 0.5 to 1 mg of atropine was administered immediately before each balloon dilation. An exchange wire was inserted either into the distal common carotid artery or the external carotid artery, and a guide sheath (shuttle flexor Tuohy Borst side-arm introducer 7F Cook; William Cook) was introduced into the common carotid artery. The stenosis was then crossed either with a 0.014-inch wire, if no cerebral protection was used, or alternatively with a 0.014- or 0.018-inch support wire, if a cerebral protection device was used. For primary angioplasty, the stenosis was then dilated with a balloon sized to the normal carotid diameter, and 1 to 3 inflations were performed. For primary stenting, the stenosis was predilated with a 3-mm balloon before insertion of a stent sized according to the diameter of the common carotid artery. Cerebral protection devices were used in 6

cases, 4 in the GSNO group and 2 in the placebo group. In 5 cases, Mednova Neuroshield (Mednova Inc) devices were used. In the remaining case, an AngioGuard (Cordis Corp) device was used.

After intervention, full anticoagulation with heparin was given for 24 hours initially at a rate of 1000 IU/h, with adjustment to ensure a 2.5-fold prolongation of the activated partial thrombin time. All patients had a full neurological examination within the first 48 hours and a follow-up duplex carotid scan within the first week.

Study Medication

Patients were randomly allocated to treatment with GSNO ($n=8$) or an identical volume of normal saline ($n=8$) on a double-blind basis. The study medication was administered as an intravenous infusion starting 30 minutes after removal of the intra-arterial catheter and continuing for 90 minutes. GSNO was infused at a rate of 2.2 nmol \cdot kg⁻¹ \cdot min⁻¹ and if this was tolerated without hypotension, increased to a rate of 4.4 nmol \cdot kg⁻¹ \cdot min⁻¹ after 10 minutes.

Transcranial Doppler Ultrasound Recordings

All recordings were performed with a commercially available system (TC4040, Nicolet-EME GmbH) equipped with a 2-MHz transducer. Recordings were made from the ipsilateral middle cerebral artery via the transtemporal window, and the transducer was fixed in position by use of a standard headset. A sample volume of 5 mm, a sweep speed of 5 seconds, and a mean (SD) recording depth of 52.0 (1.6) mm were used. After randomization and before treatment with the study drug, a 60-minute recording was made. After the initiation of the study drug, a recording was performed for 3 hours starting at the same time as the study drug, and then for 1-hour duration at both 6 and 24 hours after initiation of treatment. Recordings of the raw Doppler signal were made onto digital audiotape for subsequent offline analysis.

Analysis of Doppler Recordings

All analysis was performed by an experienced observer blinded to study group and time of recording. The Doppler signal was played from the digital audiotape into the same transcranial Doppler ultrasound equipment for spectral analysis; a 128-point fast Fourier transform was used with a time window overlap $>66\%$. Embolic signals (ESs) were identified by their characteristic visual appearance and chirping sound according to recent consensus criteria.²⁰ An intensity threshold of ≥ 7 dB was used because this has been shown to increase interobserver agreement without excessive loss of sensitivity.^{20,21} Intensity was determined from the color-coded intensity scale on the spectral display.²¹ Interobserver reproducibility in identifying ESs was assessed by 2 observers independently analyzing a separate recording that had been prepared from recordings from 6 patients with carotid stenosis. Agreement was calculated with the use of the proportion of specific agreement.²¹ A probability of 1 indicates complete agreement. Observer 1 detected 90 ESs, and the agreement of observer 1 with observer 2 was 0.92. Observer 2 detected 89 ESs, and the agreement of observer 1 was 0.90.

Statistical Considerations

A sample size of 8 in each group was decided on to allow detection of a 50% reduction in ESs during the 3-hour postintervention recording with a power of 0.8 and a significance of 0.05. This assumed a mean (SD) frequency of ESs of 30 (10) per hour as determined from previous recordings in percutaneous transluminal angioplasty patients treated with aspirin alone and previously published data.¹⁰ The 50% reduction was based on the previously reported 80% reduction in GSNO-treated patients after carotid endarterectomy.²² In the results of this study, the number of ESs in each group was not normally distributed; therefore, comparison between the numbers of ESs detected in each group was performed with the Mann-Whitney *U* test for nonparametric data. For comparison of ES intensity, an unpaired *t* test was used.

Patient Characteristics in the 2 Treatment Groups

	GSNO Group (n=8)	Control Group (n=8)	<i>P</i>
Male	8	5	0.20
Age, y (mean±SD)	67.1±6.8	66.9±5.9	0.64
Diabetes mellitus	3	1	0.57
Hypertension	3	3	1.00
Current smoker	3	2	0.59
Angina	5	4	0.63
Myocardial infarction	2	2	1.00
Hypercholesterolemia	4	7	0.28
Mean ICA stenosis by ultrasound, % (±SD)	88±4	89±5	0.58
Mean ICA stenosis by angiography, % (±SD)	84±6	81±5	0.34
Mean length of stenosis by angiography, mm (±SD)	4.4±0.8	4.2±0.5	0.58
Daily aspirin dose, mg (mean±SD)	225±106	244±104	0.80
Time since last event, d, mean (range)	58.4 (10–120)	90.6 (12–240)	0.23
ESs detected on preoperative recording	4	2	0.61
Stent placement	5	4	0.63
Cerebral protection balloon	4	2	0.61

Hypertension is defined as >160 mm Hg systolic or >90 mm Hg diastolic or being on antihypertensive treatment. Hypercholesterolemia is defined as a fasting cholesterol level of >6.0 mmol/L or drug therapy. Angiographic stenosis was measured by the NASCET method.¹ Values are numbers of patients unless given otherwise.

Results

Baseline characteristics are shown in the Table. There were no significant differences in any of these parameters between groups. Similar proportions of patients in each group underwent angioplasty alone and primary stenting. There was no difference between groups in the proportion of patients with ESs detected on the pretreatment recording. Before treatment, the median of ESs per hour was 0.5 (mean, 3.9; range, 0 to 27) in the GSNO group and 0 (mean, 1.9; range, 0 to 14) in the placebo group ($P=0.44$). All patients tolerated the full dose of GSNO administered with no clinically apparent side effects and no hypotensive episodes, defined as a decrease in mean arterial pressure of >10 mm Hg.

In the placebo group, the median (range) number of ESs detected during the whole initial 3-hour postangioplasty period was 25.5 (0–76). At 6 hours, this number had fallen to 2.0 (0–11) during a single hour. GSNO resulted in a highly significant and rapid reduction in the frequency of embolization, with the median of ESs in the 3-hour period being 2 (range, 0 to 3, $P=0.007$ versus placebo). The onset of this effect was rapid and clearly present within the first hour (Figure 1). Results for individual patients during the first postoperative hours are shown in Figure 2. This difference remained significant after control for both the use of stents versus percutaneous transluminal angioplasty alone and the use of a cerebral protection device ($P=0.01$). No patients in the GSNO group had ESs at the 6-hour recording time point ($P=0.01$ versus control group). None of the patients in either group had ESs 24 hours after the angioplasty. Mean (SD) embolic signal intensity was lower in the GSNO group than with placebo: 12.41 (3.27) versus 15.94 (3.89) dB, $P<0.001$.

In the placebo group, 2 patients experienced ipsilateral stroke within 24 hours after the procedure. Both of them

underwent balloon angioplasty without stent placement. One of them had a minor stroke, and the deficit had completely resolved within 7 days. A brain CT scan did not show a new infarct. The second patient had a disabling stroke, and a brain CT scan showed a new infarct in the ipsilateral carotid territory. None of the patients in the GSNO group had ischemic events. In the placebo group, 2 patients experienced asymptomatic ipsilateral carotid artery occlusion, detected by a follow-up carotid duplex scan. One of them had balloon angioplasty, and the second received primary stenting. None of the patients in the GSNO group had perioperative ipsilateral carotid artery occlusion. The risk of any stroke or carotid occlusion was higher in the placebo than the GSNO group (χ^2 , $P=0.021$). The median (range) number of ESs detected during the initial 3-hour postangioplasty period was higher in patients who suffered ipsilateral stroke or carotid occlusion within 24 hours after angioplasty than in patients without complications: 37.5 (25–76) versus 2 (0–3), $P<0.006$.

Discussion

In this randomized double-blind placebo-controlled study, the intravenous administration of GSNO resulted in a marked reduction in asymptomatic embolization after endovascular treatment of symptomatic carotid stenosis, despite treatment of all patients with aspirin and heparin. Embolization was rapidly reduced after the initiation of treatment and was completely abolished by 3 hours after treatment. Further embolization was not observed at 6 hours after treatment, although GSNO was administered for only 90 minutes. All patients tolerated the full dose of the study drug with no clinically apparent side effects. The mean intensity of ESs was lower in the GSNO group than in the control group.

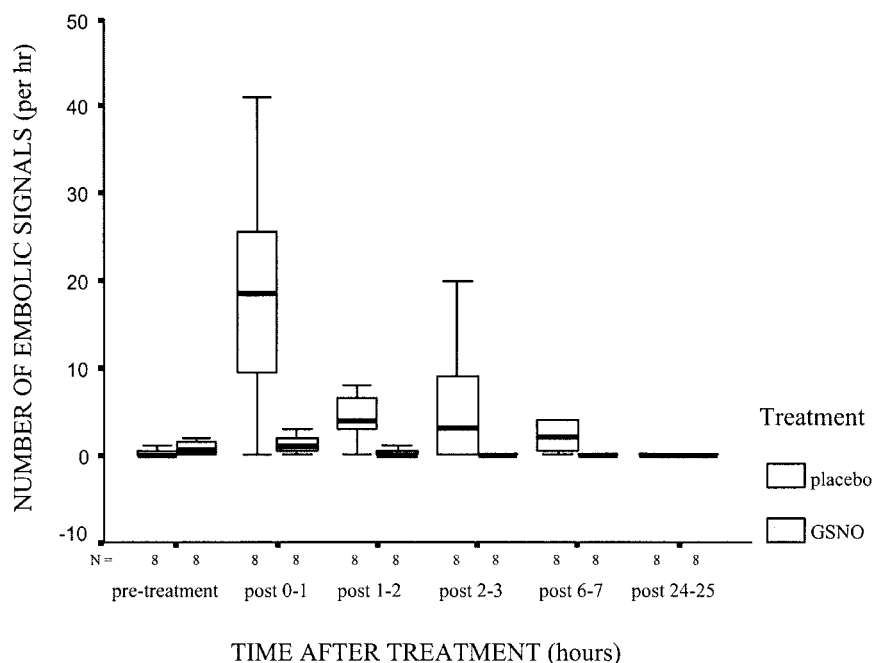


Figure 1. ESs per hour vs time according to treatment groups. Solid line represents median value; boxes, 25th to 75th percentile; and vertical lines, range.

Assuming that embolus composition was similar in the 2 groups, our results are consistent with treatment resulting in smaller, as well as fewer, emboli.²³

Our results have a number of important clinical implications. First, cerebral embolization is common in the first 6 hours after completion of carotid angioplasty and stenting despite the administration of both aspirin and heparin. Second, the frequency of ESs is sufficient to allow us to use them as potential surrogate markers in the evaluation of new antithromboembolic agents during the procedure. Third, in this setting, the platelet-specific NO donor GSNO can markedly reduce the rate of embolization.

Recent transcranial Doppler studies have demonstrated that asymptomatic cerebral ESs are common after carotid endarterectomy, and a high frequency during the early postopera-

tive phase predicts a risk of early stroke and transient ischemic attack.²⁴ During endarterectomy, however, a long strip of endothelium and inner media is removed, creating a highly thrombogenic surface on which platelet adherence and aggregation occur. This extensive endothelial denudation causes an extreme drop in endothelial NO production. Therefore, drugs acting on the NO system would be expected to be particularly effective in this setting. Consistent with this, GSNO markedly reduced the rate of ESs in the immediate postendarterectomy setting.^{18,22}

During angioplasty, endothelial microinjuries and disruption of the fibrous cap of the plaque may occur, leading to the exposure of a highly thrombogenic surface of subendothelial matrix elements. Angioplasty usually causes less endothelial damage than endarterectomy, but it may result in endothelial malfunction caused by insufficient NO production.²⁵ If endothelial NO production is impaired, platelet adhesion to the exposed subendothelial surface can be triggered.²⁵ Our results demonstrate that GSNO is equally effective in this setting as after endarterectomy.

Despite its potent effect on reducing embolization, GSNO did not result in significant hypotension. This is consistent with previous studies suggesting that GSNO has platelet specificity.^{15,16} In human forearm studies, GSNO had significant antiplatelet action at doses that caused less hemodynamic effect than seen with conventional NO donors.¹⁵ In these studies, the antiplatelet activity of GSNO was measured with *ex vivo* methods such as flow cytometry^{16,17} or aggregometry.¹⁵ Although these methods provide an indication of antiplatelet activity, they are only indirect measures. Our results and the previous studies in carotid endarterectomy^{18,22} demonstrate that this antiplatelet effect translates into an effect on a clinical surrogate end point, asymptomatic embolization. We did not perform studies of platelet aggregation or activation in this study. *Ex vivo* samples from normal individuals²⁶ and the normal

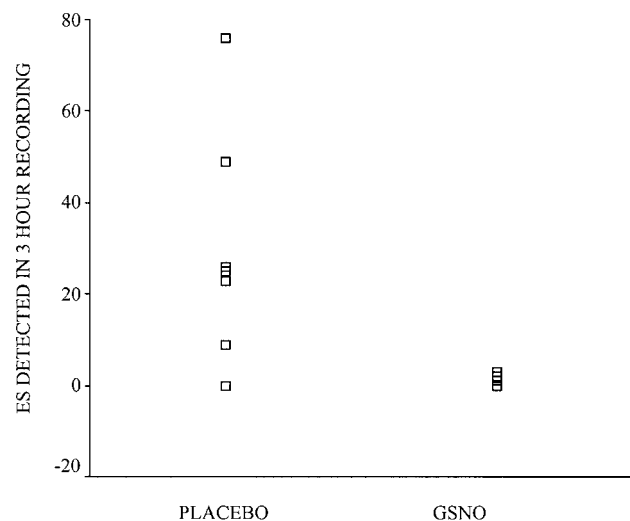


Figure 2. Scatter distribution of total ESs detected in each patient during 3-hour postintervention recording according to treatment group.

forearm¹⁵ have shown GSNO to be a potent inhibitor of platelet aggregation. In pathological states in humans, relevant changes are best assessed distal to the potential site of platelet activation, and samples drawn from the venous circulation may provide only limited information. We have shown that GSNO is a potent inhibitor of platelet activation, as determined by platelet surface expression of P-selectin and glycoprotein IIb/IIIa, in patients undergoing coronary angioplasty who were already pretreated with aspirin.¹⁷ In this setting, we sampled blood from the coronary sinus. In the same study, patients treated with aspirin who did not receive GSNO showed marked platelet activation after angioplasty in blood sampled from the coronary sinus, whereas less consistent activation was detected with peripheral venous sampling. In patients undergoing carotid angioplasty, platelet activation may occur locally; therefore, optimal sampling would be distal to the carotid stenosis (ie, in the distal internal carotid artery) or, less optimally, from the jugular vein. For ethical reasons, we were unable to sample from these sites. It is likely, however, that such sampling would have revealed effects similar to those after coronary angioplasty.

Our study was powered to detect a reduction in embolization and not clinical events. Nevertheless, there was a trend toward improved outcome in the GSNO-treated group. No patients in the GSNO group had stroke, transient ischemic attack, or early carotid occlusion. In contrast, in the GSNO group, there was 1 disabling and 1 reversible stroke and 2 asymptomatic carotid occlusions. Asymptomatic embolization was more frequent in the early postoperative period in the 2 patients who suffered postintervention stroke.

Transcranial Doppler ultrasound has been shown to be highly sensitive and specific for the detection of platelet and thrombus emboli in both in vitro and in vivo models.^{23,27} Prospective studies in both patients with symptomatic²⁸ and asymptomatic²⁹ carotid stenosis have found ESs to be an independent predictor of risk of combined stroke and transient ischemic attack. Their high frequency compared with the clinical end points of stroke and transient ischemic attack, combined with their clinical significance, suggests that they may be useful surrogate markers for the evaluation of new antithromboembolic agents. Our study demonstrates that results can be obtained from studies in relatively small numbers of patients with this technique. One limitation of current Doppler embolus detection is that solid and gaseous emboli cannot be reliably differentiated.²³ Gaseous ESs, secondary to air introduced in injections, are very common during both carotid angiography and carotid angioplasty.¹⁰ The clinical significance of these air emboli is likely to be much less than that of the less frequent solid emboli, and they would not be expected to respond to antiplatelet agents. Because of this limitation, reliable conclusions can be drawn only from recordings made after removal of the catheter, and for this reason, we limited our recordings to this period.

Our results demonstrate that aspirin and heparin alone are inadequate therapy in this group of patients. For coronary angioplasty and stenting, a large number of

studies have demonstrated the benefit of adding the thienopyridine derivatives ticlopidine and clopidogrel and the glycoprotein IIb/IIIa receptor antagonist abciximab. There have been no randomized-treatment trials of these alternative agents in patients undergoing carotid angioplasty and stenting, and in the recent CAVATAS study, most patients were treated with aspirin without other antiplatelet agents (Martin Brown, personal communication, 2002). Although such approaches may also be beneficial for carotid stenting, direct extrapolation from the coronary artery may be dangerous. Cerebral hemorrhage can occur as a complication of carotid angioplasty, and these more aggressive antiplatelet regimens are likely to increase the risk of this complication. The combination of other antiplatelet agents with aspirin and heparin may be beneficial in this clinical setting, because the therapeutic efficacy of aspirin and heparin is limited. The optimal approach is likely to be the one that reduces embolization without excessive antiplatelet inhibition. GSNO seems to be a promising approach, and the use of Doppler ultrasound to detect asymptomatic emboli may allow this to be compared with other agents before testing in large randomized clinical trials.

Acknowledgments

This work was supported by a project grant from the British Heart Foundation (PG98146). Dr Martin is a British Heart Foundation Professor of Cardiovascular Sciences. We are grateful to Dr David Madge for supplying GSNO and to Dr Martin Jeffrey for his help.

References

1. Ferguson GG, Eliasziw M, Barr HWK, et al. The North American Symptomatic Carotid Endarterectomy Trial: surgical results in 1415 patients. *Stroke*. 1999;30:1751–1758.
2. European Carotid Surgery Trialists' Collaborative Group. Randomised trial of endarterectomy for recently symptomatic carotid stenosis: final results of the MRC European Carotid Surgery Trial (ECST). *Lancet*. 1998;351:1379–1387.
3. Sieber FE, Toung TJ, Diringer MN, et al. Preoperative risks predict neurological outcome of carotid endarterectomy related stroke. *Neurosurgery*. 1992;30:847–854.
4. Roubin GS, New G, Ivyer SS, et al. Immediate and late clinical outcomes of carotid artery stenting in patients with symptomatic and asymptomatic carotid artery stenosis: a 5-year prospective analysis. *Circulation*. 2001;103:532–537.
5. Wholey MH, Wholey M, Mathias K, et al. Global experience in cervical carotid artery stent placement. *Cathet Cardiovasc Interv*. 2000;50:160–167.
6. CAVATAS Investigators. Endovascular versus surgical treatment in patients with carotid stenosis in the Carotid and Vertebral Artery Transluminal Angioplasty Study (CAVATAS): a randomised trial. *Lancet*. 2001;357:1729–1737.
7. Dietz A, Berkefeld J, Theron JG, et al. Endovascular treatment of symptomatic carotid stenosis using stent placement: long-term follow-up of patients with a balanced surgical risk/benefit ratio. *Stroke*. 2001;32:1855–1859.
8. Reimers B, Corvaja N, Moshiri S, et al. Cerebral protection with filter devices during carotid artery stenting. *Circulation*. 2001;104:12–15.
9. Ohki T, Roubin GS, Veith FJ, et al. Efficacy of a filter device in the prevention of embolic events during carotid angioplasty and stenting: an ex vivo analysis. *J Vasc Surg*. 1999;30:1034–1044.
10. Markus HS, Clifton A, Buckenham T, et al. Carotid angioplasty: detection of embolic signals during and after the procedure. *Stroke*. 1994;25:2403–2406.
11. Qureshi A, Saad M, Zaidat OO, et al. Intracerebral hemorrhages associated with neurointerventional procedures using a combination of anti-thrombotic agents including abciximab. *Stroke*. 2002;33:1916–1919.

12. Radomski MW, Palmer RMJ, Moncada S. Comparative pharmacology of endothelium-derived relaxing factor, nitric oxide and prostacyclin in platelets. *Br J Pharmacol.* 1987;92:181–187.
13. Radomski MW, Palmer RMJ, Moncada S. Endogenous nitric oxide inhibits human platelet adhesion to vascular endothelium. *Lancet.* 1987; 2:1057–1058.
14. Mehta J, Mehta P. Comparative effects of nitroprusside and nitroglycerin on platelet aggregation in patients with heart failure. *J Cardiovasc Pharmacol.* 1980;2:25–33.
15. de Belder AJ, MacAllister R, Radomski MW, et al. Effects of S-nitroso-glutathione in the human forearm circulation: evidence for selective inhibition of platelet activation. *Cardiovasc Res.* 1994;28:691–694.
16. Langford EJ, Wainwright RJ, Martin JF. Platelet activation in acute myocardial infarction and unstable angina is inhibited by nitric oxide donors. *Arterioscler Thromb Vasc Biol.* 1996;16:51–55.
17. Langford EJ, Brown AS, Wainwright RJ, et al. Inhibition of platelet activity by S-nitrosoglutathione during coronary angioplasty. *Lancet.* 1994;344:1458–1460.
18. Kaposzta Z, Baskerville PA, Madge D, et al. L-Arginine and S-nitrosoglutathione reduce embolization in humans. *Circulation.* 2001; 103:2371–2375.
19. Marley R, Patel RP, Orie N, et al. Formation of nanomolar concentrations of S-nitroso-albumin in human plasma by nitric oxide. *Free Radic Biol Med.* 2001;31:688–696.
20. Ringelstein EB, Droste DW, Babikian VL, et al. Consensus on micro-embolus detection by TCD. International Consensus Group on Micro-embolus Detection. *Stroke.* 1998;29:725–729.
21. Markus HS, Bland JM, Rose G, et al. How good is inter-center agreement in the identification of embolic signals in carotid artery disease? *Stroke.* 1996;27:1249–1252.
22. Molloy J, Martin JF, Baskerville PA, et al. S-Nitrosoglutathione reduces the rate of embolization in humans. *Circulation.* 1998;98:1372–1375.
23. Markus HS, Brown MM. Differentiation between different pathological cerebral embolic materials using transcranial Doppler in an in vitro model. *Stroke.* 1993;24:1–5.
24. Levi CR, Roberts AK, Fell G, et al. Transcranial Doppler microembolus detection in the identification of patients at high risk of perioperative stroke. *Eur J Vasc Endovasc Surg.* 1997;14:170–176.
25. Willerson JT, Cohen LS, Maseri A. Pathophysiology and clinical recognition. In: Willerson JT, Cohn JN, eds. *Cardiovascular Medicine.* New York, NY: Churchill Livingstone; 1995:333–365.
26. Radomski MW, Rees DD, Dutra A, et al. S-Nitroso-glutathione inhibits platelet activation in vitro and in vivo. *Br J Pharmacol.* 1992;107: 745–749.
27. Russell D, Madden KP, Clark WM, et al. Detection of arterial emboli using Doppler ultrasound in rabbits. *Stroke.* 1991;22:253–258.
28. Molloy J, Markus HS. Asymptomatic embolization predicts stroke and TIA risk in patients with carotid artery stenosis. *Stroke.* 1999;30: 1440–1443.
29. Siebler M, Nachtmann A, Sitzer M, et al. Cerebral microembolism and the risk of ischemia in asymptomatic high-grade internal carotid artery ischaemia. *Stroke.* 1995;26:2184–2186.