

Lemierre's syndrome: case of a patient with pulmonary embolism and cavernous sinus thrombosis complicating a septic internal jugular vein thrombus

VOJKO FLIS • NINA KOBILICA • ANDREJ BERGAUER

VOJKO FLIS (✉) •
NINA KOBILICA •
ANDREJ BERGAUER
Department of Vascular Surgery
Surgical Clinics Maribor
University Clinical Center Maribor
Ljubljanska 5, 2000 Maribor, Slovenia
Phone: +3862 3211291
Fax: +3862 3312393
E-mail: vojko.flis@guest.arnes.si

ABSTRACT

Lemierre's syndrome is a complex and unusual clinical entity, characterized by septic thrombophlebitis of the internal jugular vein. We present the case of a patient with Lemierre's syndrome, pulmonary embolism and propagation of an internal jugular vein thrombus retrograde to the cavernous sinus. The patient was treated with antibiotics and heparin. The importance of rapid diagnosis of the extent of the disease, in directing the otherwise somewhat controversial treatment with heparin in patients with Lemierre's syndrome, is stressed.

Key words: Lemierre's syndrome, internal jugular vein, septic venous thrombosis, anticoagulation treatment

Introduction

In 1936, Andre Lemierre described 20 cases of internal jugular vein thrombophlebitis (IJVT), with postanginal sepsis that would later become known as Lemierre's syndrome. (1) Septicemia was mostly associated with anaerobic oropharyngeal infection extending to the neck, with disseminated (mostly pulmonary) abscesses. (1,2) The mortality rate in Lemierre's series was 90%. (1) The syndrome is usually characterized by a history of recent oropharyngeal infection, clinical or radiological evidence of IJVT, including remote septic emboli, and isolation of anaerobic pathogens, mainly *Fusobacterium necrophorum*, although other pathogens have been reported. (2-7) Reports of Lemierre's syndrome significantly declined after

the widespread use of antibiotics and it was thought to be a rare and forgotten disease with a suggested incidence of approximately one per million. (5) However, an increase in frequency over the past years is thought to be due to changes in antibiotic usage. (8) Lemierre's syndrome occurs mainly in previously healthy children and young adults, although it spares no age group. (3,6) We present a case in which an adult patient suffered from Lemierre's syndrome as a complication of an untreated oropharyngeal infection.

Case report

A 56-year old previously healthy male patient presented to our emergency department with a 5-day history of fever and one day history of a swollen neck. The patient had been in good health until 5 days earlier, when he began to have a sore throat and fever. He reported that he was examined by his physician who told him that it was probably

a viral infection. On the sixth day he developed painful swelling in the right anterior side of his neck. He reported no previous history of trauma, malignant disease, infection, operation or IV catheterization, and had never consumed tobacco or alcohol.

Physical examination revealed a nontender, soft and immobile mass in the right anterior side of his neck. The mass was not associated with hyperemia or local heat. Oropharyngeal examination was significant for pharyngeal erythema with no exudates. Examination of other systems was normal.

Ultrasonography revealed a hyperechogenic mass around the right internal jugular vein (IJV), which was suggestive of a thrombus. Blood flow was not demonstrated by Doppler ultrasonography and the vein was not compressible. The patient was diagnosed with IJVT and admitted to hospital. Computed tomography (CT) images demonstrated complete thrombosis of the

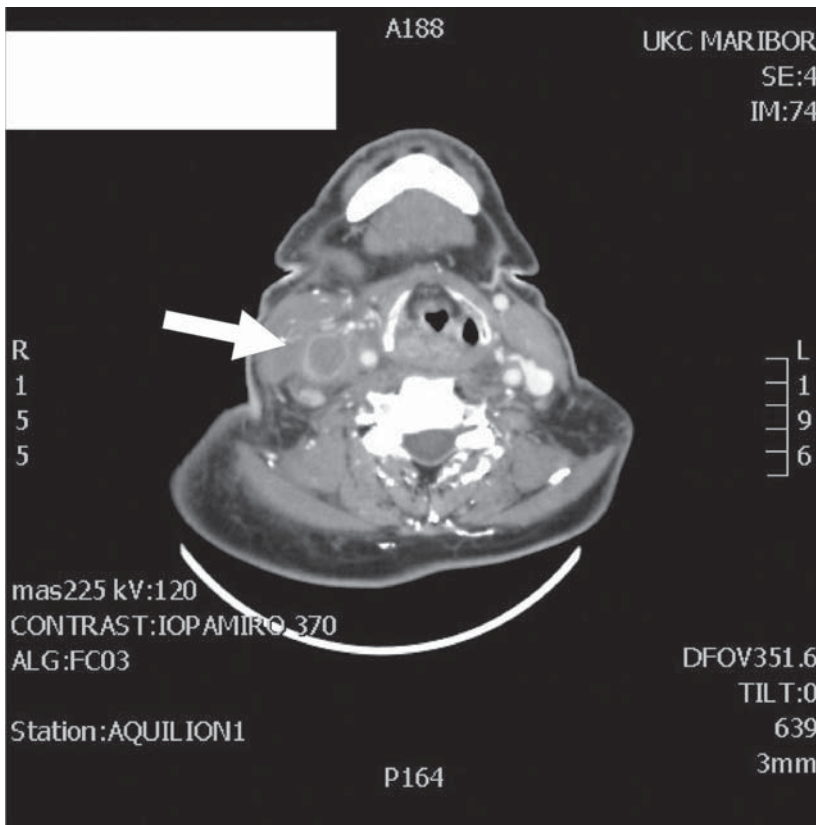


Figure 1. Transverse section through the neck (CTA). Arrow is denoting the thrombosed internal jugular vein with a perivascular area of inflammation.

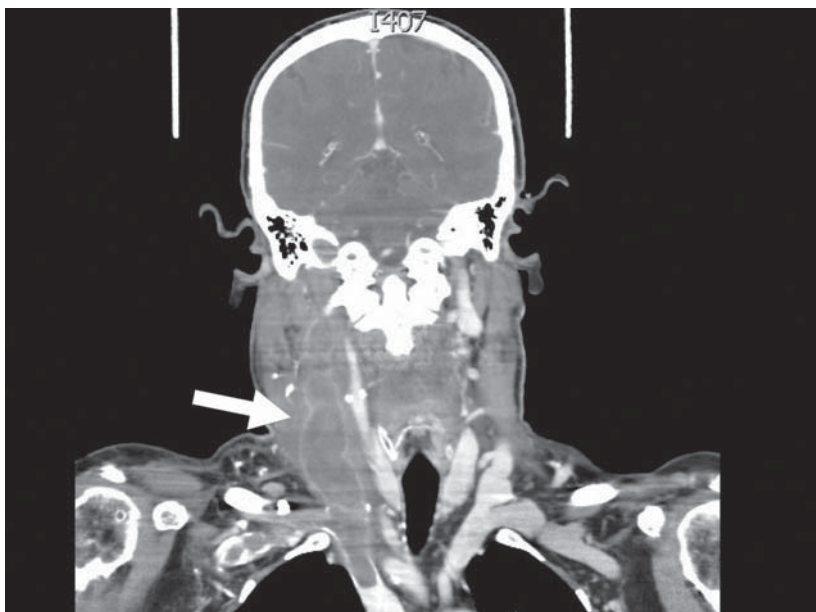


Figure 2. Frontal section through the neck (CTA). Arrow is denoting thrombosed internal jugular vein with massive propagation of the thrombus in a cranial and caudal direction.

right internal jugular vein, thrombosis of the cavernous sinus, multiple septic pulmonary emboli, and bilateral necrotizing pneumonia. His vital signs were: temperature 38.6°C, pulse 125 beats/min, respiration 20 breaths/min, blood pressure 100/80 mmHg, and room air pulse oximetry was 100%. Laboratory investigation revealed a white blood cell count of 18,600/ μ L; hemoglobin 12.8 g/dL; red blood cell count, 4.2x10⁶/mL; platelet count, 282x10³/mL; prothrombin time, 18.1; partial thromboplastin time (PTT), 46.5; international normalized ratio (INR), 1.45; C-reactive protein, 128 mg/L. Within one hour of the patient's arrival he reported increased difficulty breathing. The patient underwent intubation and was admitted to the Intensive Care Unit with a diagnosis of Lemierre's syndrome.

Empirical antibiotic treatment was started with imipenem and metronidazole. Low molecular weight heparin in therapeutic doses was given. The blood culture obtained at the time of hospitalization revealed no organisms. A follow-up CT scan of the neck and chest showed a decrease in the size of thrombi. He was extubated on day 7 of hospitalization. He underwent six weeks of vancomycin therapy with good recovery. Anticoagulation treatment with a vitamin K antagonist was prolonged for 6 months.

Discussion

The two leading causes of IJVT are iatrogenic trauma secondary to jugular vein catheterization, and repeated IV injections by drug users. (9) Lemierre's syndrome was thought to be a rare and forgotten disease with a suggested incidence of approximately one per million. (5) However, an increase in frequency over the past years has been attributed to changes in antibiotic usage. (8) Unfortunately, wide spread antibiotic usage has also changed the clinical picture of Lemierre's syndrome and it is often difficult to recognize this unusual illness in the Emergency Department (ED). (10) Systemic septic complications may range from deep neck infections over septic arthritis

to brain infections. (11) Every organ system may be involved. (11) Delays in diagnosis ranging up to 11 days after admission have been reported. (12,13) Our patient was admitted to hospital five days after the onset of symptoms. Early diagnosis, complete radiologic diagnostic assessment of the patient and no delays in treatment are vital. It has been suggested that bedside ultrasound of the internal jugular vein in the ED, before other radiologic imaging, may lead to rapid diagnosis and treatment of Lemierre's syndrome. (10) However, ultrasound examination will not reveal the extent of the disease, which is needed to direct anticoagulation treatment, considered somewhat controversial in patients with Lemierre's syndrome. (4,14) We believe that in patients with Lemierre's syndrome a rapid whole body CT is indicated. When

the CT scan shows propagation of the IJV thrombus retrograde to the cavernous sinus, and pulmonary emboli, rapid treatment with heparin may stop the growth of thrombi. The role of anticoagulant treatment in patients with Lemierre's syndrome is not well defined. (2) Theoretically, they entail a risk of septic embolism by fragmentation of the venous thrombus, however they are recommended in cases of retrograde extension of the thrombus toward the intracranial venous drainage and in cases of pulmonary embolism. (2) Prolonged anticoagulation treatment with vitamin K antagonists should be considered in patients with pulmonary embolism, such as in the presented case. The mainstay of treatment of Lemierre's syndrome is a prolonged course of high-dose, intravenously administered

antibiotics based on penicillin (or 2nd or 3rd generation cephalosporin's) and metronidazole (or clindamycin monotherapy) as initial therapy. The antibiotic treatment will then be adapted based on the clinical course and on the results of testing. It seems that most patients will require at least six weeks of antibiotics. (14) In rare cases, surgical treatment with ligation or even excision of the jugular vein is needed. (4,14) Lemierre's syndrome is a complex and potentially lethal illness arising not only from the oropharynx but also from extrapharyngeal sources. Early recognition of the extent of the disease and high-dose antibiotics are critical elements in reducing mortality. Immediate anticoagulation treatment is beneficial in patients with pulmonary embolism and propagation of the IJV thrombus retrograde to the cavernous sinus.

REFERENCES

1. Lemierre A. On certain speticæmias due to anaerobic organisms. *Lancet* 1936;1:701-3.
2. Tourniaire T, Rtail R, Timi N, Righini CA. A syndrome first described in 1936, still relevant today. *European Annals of Otorhinolaryngology, Head and Neck diseases* 2010;doi:10.1016/j.anorl.2010.11.002.
3. Karkos PD, Asrani S, Karkos DC, Leong SC, Theocari EG, Alexopoulou TD, et al. Lemierre's syndrome: a systematic review. *The Laryngoscope* 2009;119:1552-9.
4. Puymirat E, Biais M, Camou F, Lefevre J, Guisset O, Gabinski C. A Lemierre syndrome variant caused by staphylococcus aureus. *Am J Emerg Med* 2008;26:380.c5-380.c7.
5. Hagelskjaer LH, Prag J, Malczynsky J, Kristensen JH. Incidence and clinical epidemiology of necrobacillosis, including Lemierre's syndrome, in Denmark 1990-1995. *Eur J Clin Microbiol Infect Dis* 1998;17:561-5.
6. Shah RK, Wofford MM, West TG, Shetty MD. Lemierre syndrome associated with group A streptococcal infection. *Am J Emerg Med* 2010;28:643.e5-643.e8.
7. Hile LM, Gibbons MD, Hile DC. Lemierre syndrome complicating otitis externa: case report and literature review. *Jour Emerg Med* 2009;doi:10-1016/j.jemermed.2009.02.14.
8. Ramirez S, Hild TG, Rudolph CN, Styr JR, Havens P, Henrickson K, et al. Increased diagnosis of Lemierre,s syndrome and other Fusobacterium necrophorum infections at a children's hospital. *Pediatrics* 2003;112e:380.
9. Chowdhury K, Bloom J, Black MJ, al-Noury K. Spontaneous and non spontaneous internal jugular vein thrombosis. *Head Neck* 1990;12:168-73.
10. Castro-Marin F, Kendall JL. Diagnosis of Lemierre syndrome by bedside emergency department ultrasound. *J Emerg Med* 2010;39:436-9.
11. Papadopoulos D, Assimakopoulos AD. Lemierre syndrome: no delays in management. Case report. *Amer J Emerg Med* 2010;28:844.e1-844.e2.
12. Nadkarni MD, Verchik J, O'Neill JC. Lemierre syndrome. *J Emerg Med* 2005;28:297-9.
13. Hoehn S, Dominguez TE. Lemierre's syndrome: an unusual case of sepsis and abdominal pain. *Crit Care Med* 2002;30:1644-7.
14. Golpe R, Marin B, Alonso M. Lemierre's syndrome (necrobacillosis). *Postgrad Med J* 1999;75:141-4.