

## STRUMAL CARCINOID OF THE OVARY: REPORT OF TWO CASES\*

Tanja Leniček<sup>1</sup>, Davor Tomas<sup>1,3</sup>, Hrvojka Soljačić-Vraneš<sup>2</sup>, Zdenko Kraljević<sup>2</sup>, Petar Klarić<sup>2</sup>, Milan Kos<sup>4</sup>  
and Marina Kos<sup>1,3</sup>

<sup>1</sup>Ljudevit Jurak University Department of Pathology, <sup>2</sup>University Department of Gynecology and Obstetrics, Sestre milosrdnice University Hospital Center; <sup>3</sup>School of Medicine, University of Zagreb; <sup>4</sup>Vili Polyclinic, Zagreb, Croatia

**SUMMARY** – Primary carcinoid tumors of the ovary account for 5% of ovarian teratomas. They are frequently components of mature cystic teratomas or, less commonly, mucinous cystadenomas. Most tumors are seen in peri- or postmenopausal women with symptoms of enlarging mass, or are incidental findings. Microscopically, there are four major variants of ovarian teratomas of carcinoid type: insular, trabecular, strumal and mucinous. One-third of patients with the insular type of carcinoids have symptoms of the carcinoid syndrome. Strumal carcinoid is an unusual form of ovarian teratoma composed of an intimate admixture of thyroid and carcinoid tissues that vary in their relative proportions. Two patients with ovarian tumors showing typical morphology of primary ovarian strumal carcinoid are described.

Key words: *Ovary; Strumal carcinoid; Carcinoid syndrome*

### Introduction

Primary carcinoid tumors of the ovary are uncommon, rarer than struma ovarii, and account for 5% of ovarian teratomas. They are frequently components of mature cystic teratomas or, less commonly, mucinous cystadenomas. Most tumors are seen in peri- or postmenopausal women with symptoms of enlarging mass, or are incidental findings, but one-third of patients with the insular type of carcinoids have symptoms of the carcinoid syndrome.

Strumal carcinoid is an unusual form of ovarian teratoma composed of an intimate admixture of thyroid and carcinoid tissues that vary in their relative

proportions. In half of the cases, the carcinoid component is purely trabecular and, in the rest, it is a mixture of trabecular and insular patterns<sup>1,2</sup>

We describe two patients with primary ovarian strumal carcinoid.

### Case 1

In January 2008, a 40-year-old woman was admitted to the hospital with a 4-year clinical history of myoma uteri and no symptoms except for constipation persisting for several months. Pelvic examinations revealed a mass behind the uterus that on ultrasonic examination measured 5.0x4.2 cm and was closely connected to the left ovary that measured 5.8x4.0 cm. CA-125 was 23.5 U/mL. At laparotomy, a smooth, hard, solid tumor originating in the left ovary that adhered slightly to the uterus was found. There was also a small amount of fluid in the pouch of Douglas, which was sent for cytopathologic examination. The uterus, right fallopian tube and right ovary were nor-

\* Cases were partially presented at 21<sup>st</sup> Ljudevit Jurak International Symposium on Comparative Pathology, June 4-5, 2010, Zagreb, Croatia

Correspondence to: *Prof. Marina Kos, MD, PhD*, Ljudevit Jurak University Department of Pathology, Sestre milosrdnice University Hospital Center, Vinogradska c. 29, HR-10000 Zagreb, Croatia

E-mail: [dr-marina-kos@yahoo.com](mailto:dr-marina-kos@yahoo.com)

Received January 2, 2012, accepted July 12, 2012

mal in size and appearance. The tumor was sent for frozen section analysis, where it was suspected to be a granulosa cell tumor. Because of the frozen section report, left salpingoophorectomy with omental resection and peritoneal biopsy were performed, and the material was sent for final pathologic examination.

The gross pathologic examination revealed a predominantly solid, hard, grayish-white tumor of the left ovary with smooth outer surface and intact capsule that measured 9x5x5 cm in size. The fallopian tube on the surface of the tumor measured 6.2x0.4 cm. The cut surface of the tumor was partly solid and partly cystic (Fig. 1).

Microscopically, the larger part of the tumor consisted of long ribbons of uniform, elongated cells oriented perpendicularly to the long axes of the ribbons, interspersed with a small amount of loose fibrous connective stroma. Immunohistochemically, tumor cells were positive for chromogranin A and synaptophysin and this part of the tumor was considered to be a trabecular carcinoid. Smaller areas of insular type carcinoid and minute foci of few individual mucinous cells were also found. Tumor cells exhibited 2 mitoses *per* 10 high power fields (HPF). The smaller part of the tumor was composed of thyroid tissue, with typical thyroid follicles lined by cells that were positive for thyroglobulin and filled with colloid. Between these two components there was a transitional area of intimately admixed carcinoid and thyroid components. The fallopian tube, omentum and peritoneal biopsy

showed normal morphology. Cytopathologic examination of the fluid from the pouch of Douglas revealed no tumorous cells.

Definitive diagnosis was strumal carcinoid of the left ovary.

## Case 2

In January 2010, a 44-year-old asymptomatic woman was admitted to the hospital because of clinical findings of the left ovarian cyst and endometrial polyp. On pelvic examination there was a mass in the region of the left ovary, which on ultrasonic examination measured 8.5x6.5 cm, showing multicystic appearance with fluid content. CA 125 was 4.4 U/mL. There was also a 1.2x0.5 cm polypous mass in the uterine cavity. At laparoscopy, a multicystic left ovarian tumor with smooth outer surface was found. The cysts contained clear fluid. There was no ascites, and the uterus and contralateral adnexa appeared normal. The polyp in the uterine cavity was removed by hysteroscopy.

Ten irregular samples of tissue measuring between 2 and 8.5 cm in diameter were received for pathologic analysis. The samples appeared as parts of a cystic tumor with smooth outer surface and slightly irregular inner surface. The cyst walls were 0.3 to 1.1 cm thick and contained firm, whitish-yellow areas (Fig. 2). On the surface of one of the samples there was a fallopian tube that measured 8x0.3 cm.

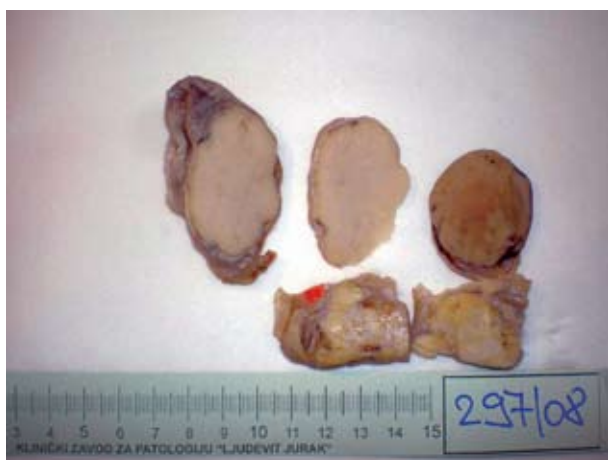

Fig. 1. A solid, hard, grayish-white tumor of the ovary with smooth outer surface and intact capsule.



Fig. 2. Parts of a cystic tumor with smooth outer surface and slightly irregular inner surface.

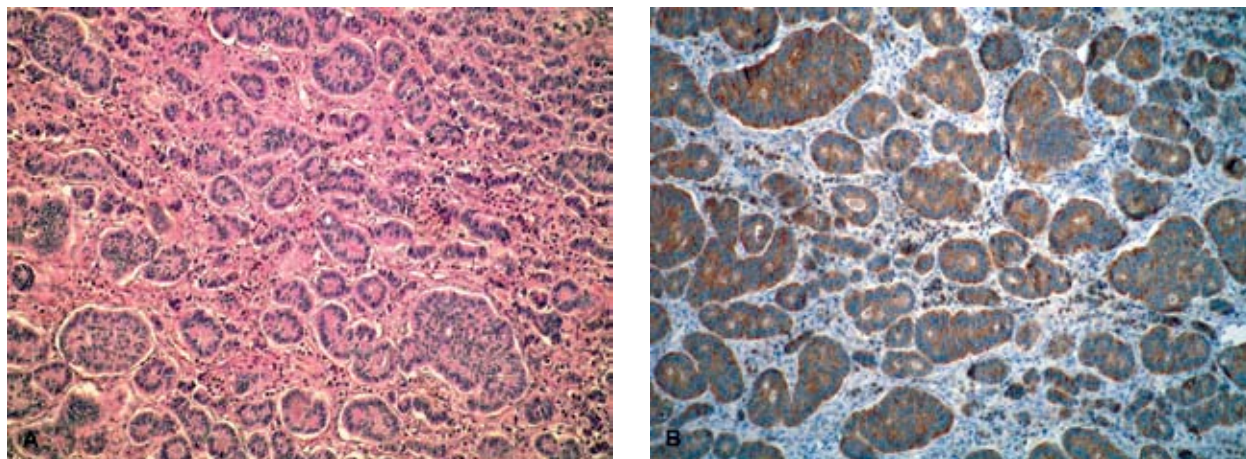


Fig. 3. (A) Microscopically, the majority of the tumor consisted of small acini and round to oval islands of uniform cells with some peripheral palisading (H&E, X100); (B) immunohistochemically, tumor cells were diffusely positive for synaptophysin (X100).

Microscopically, the majority of the tumor consisted of small acini and round to oval islands of uniform cells with some peripheral palisading (Fig. 3A). Some of the small acini contained eosinophilic secretions that stained positive for mucin. Immunohistochemically, the tumor cells were diffusely positive for synaptophysin (Figs. 3B and 4C) and neuron specific enolase (NSE) and focally positive for chromogranin A and this part of the tumor was diagnosed as an insular carcinoid. Smaller areas of the tumor showed trabecular type of carcinoid and minute foci of tumor with few individual mucinous cells were also found. Mitotic activity of the tumor cells was 4 mitoses/10 HPF and the proliferative index measured with Ki67 was less than 5%. The second very small part of the tumor (about 5%) was composed of thyroid tissue

with typical thyroid follicles filled with colloid (Fig. 4A) and surrounded by cells positive for thyroglobulin (Fig. 4B) and thyroid transforming factor. Near the thyroid component of the tumor, there was also a small component of mature teratoma (about 10%). The fallopian tube showed normal morphology. The polyp of the uterine cavity was an endometrial glandular polyp.

Definitive diagnosis was strumal carcinoid of the left ovary.

## Discussion

Primary ovarian carcinoid tumors are uncommon and account for less than 0.1% of ovarian malignancies<sup>3</sup>. According to the World Health Organization

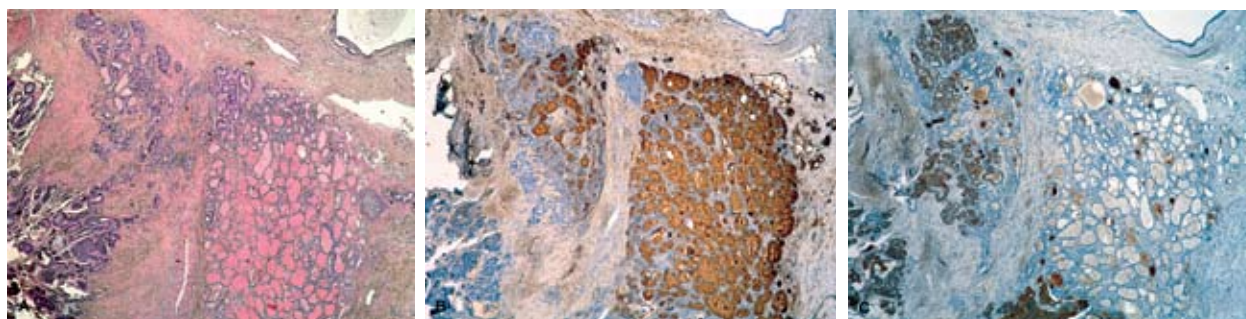


Fig. 4. (A) A small part of the tumor was composed of thyroid tissue with typical thyroid follicles filled with colloid (H&E, X40); (B) follicles were surrounded by cells immunohistochemically positive for thyroglobulin (X40); (C) carcinoid part of the tumor immunohistochemically showed positive reaction for synaptophysin (X40).

classification, they represent a group of ovarian mono-dermal teratomas<sup>4</sup>. Most tumors are seen in peri- or postmenopausal women as cystic or solid ovarian mass, generally about 10 cm in maximal dimension. They are virtually always unilateral, but in up to 15% of cases there is also a mature cystic teratoma or mucinous tumor in the contralateral ovary. Sixty percent of ovarian carcinoids are components of mature cystic teratoma or, in a minority of cases, mucinous cystadenomas. Secondary or metastatic carcinoids from the gastrointestinal tract in the ovary are four times less common than primary carcinoids<sup>1</sup>.

Patients with primary ovarian carcinoids show symptoms of an abdominal mass, or the tumor is an incidental finding. Some patients show signs of carcinoid syndrome (episodic cutaneous flushing, cyanosis, abdominal cramps, diarrhea, carcinoid heart disease, etc.) mediated by bioactive polypeptides produced by carcinoid tumor cells. This syndrome typically occurs in patients with functioning hepatic metastases of gastrointestinal carcinoids whose cells release metabolic substances *via* hepatic veins directly into the systemic circulation. In the absence of hepatic metastases, gastrointestinal carcinoids do not usually produce this syndrome, since metabolic substances released by the tumor are rapidly destroyed by blood and liver enzymes in the portal circulation. The products of primary ovarian carcinoids, as well as of primary pulmonary carcinoids, bypass the portal route and may induce symptoms of carcinoid syndrome even in the absence of hepatic metastases.

Microscopically, there are four major variants of ovarian teratomas of carcinoid type: insular, trabecular, strumal and mucinous<sup>1,5</sup>. Insular carcinoids are characterized by islands of uniform neoplastic cells, some of which are admixed by small acini. One-third of these tumors are associated with carcinoid syndrome. Trabecular carcinoids are characterized by the growth of tumor cells in ribbons and thicker trabeculae and only rarely present with endocrine manifestations. Mucinous carcinoid tumors of the ovary are generally pure tumors, and are uncommonly part of the strumal carcinoid. They consist of small and large acini lined partly by mucinous and neuroendocrine cells, often lying in mucin pools<sup>5</sup>. They can show more nuclear atypia and mitotic activity than other variants.

Strumal carcinoids show an intimate, at least focal admixture of carcinoid and thyroid tissue. Carcinoid component can be of trabecular or mixed trabecular and insular type, but 46% of tumors also contain a small number of mucinous cells. Differential diagnoses of primary ovarian carcinoid include metastatic carcinoid, granulosa cell tumors, poorly differentiated primary or metastatic adenocarcinoma, Brenner tumors and androblastoma.

Carcinoid syndrome is a very rare manifestation of strumal carcinoid. Even though carcinoids can typically cause the carcinoid syndrome, with diarrhea as one of the symptoms, several cases of strumal carcinoid have been reported in patients exhibiting severe constipation<sup>3,6</sup>. The constipation was considered as a symptom of carcinoid syndrome induced by the gut hormone, peptide YY that has strong inhibitory effect on intestinal motility. The first patient we describe also suffered from constipation that was relieved after the surgery. Strumal carcinoid can also be responsible for carcinoid heart disease<sup>7</sup>. In the largest reported series of strumal carcinoids consisting of 50 patients, 8% of the patients exhibited clinical signs of androgen production and virilism, and no patient had carcinoid syndrome<sup>2</sup>. None of these symptoms was present in our patients.

Approximately 5% of primary carcinoid tumors of non-mucinous type have a malignant clinical course, but there are no histologic features that are predictive of malignancy<sup>1,5</sup>. Insular carcinoids are best considered as tumors of low malignant potential and trabecular carcinoids are very infrequently associated with metastases. Rare reported cases of strumal carcinoid metastases were both of carcinoid or thyroidal type<sup>1</sup>. Clinical course of mucinous carcinoids tend to be more aggressive and the metastases can be present at the time of laparoscopy.

The patients we describe had ovarian tumors showing typical morphology of ovarian strumal carcinoids. They had no symptoms of carcinoid syndrome, but the first patient suffered from constipation that could be connected to the ovarian tumor. Clinical follow up of the patients described is only two years in the first case and six months in the second case, but the patients have no signs of recurrence or distant spread of the tumor so far.



## References

1. ROBBY SJ. Pathology of the female reproductive tract. 2<sup>nd</sup> ed. USA: Churchill Livingstone, 2009.
2. GORIN I, SASTRE-GARAU X. Strumal carcinoid tumor of the ovary. *J Clin Oncol* 2008;27:80-1.
3. MATSUDA K, MAEHAMA T, KANAZAWA K. Strumal carcinoid tumor of the ovary: a case exhibiting severe constipation associated with PYY. *Gynecol Oncol* 2002;87:143-5.
4. TAVASSOLI FA, DEVILEE P, editors. World Health Organization classification of tumors of the breast and female genital organs. Lyon: IARC Press, 2003.
5. BAKER PM, OLIVA E, YOUNG RH, TALERMAN A, SCULLY RE. Ovarian mucinous carcinoids including some with a carcinomatous component. *Am J Surg Pathol* 2001;25:557-68.
6. CHEN CW, CHANG WC, CHANG DY. Laparoscopic resection of an ovarian strumal carcinoid tumor with dramatic relief of severe constipation. *J Min Inv Gynecol* 2010;17:242-5.
7. BRUNAUD L, ANTUNES L, SEBBAG H, BRESLER L, VILLEMONT JP, BOISSEL P. Ovarian strumal carcinoid tumor responsible for carcinoid heart disease. *Eur J Obstet Gynecol Reprod Biol* 2001;98:124-6.

## Sažetak

### STRUMALNI KARCINOID JAJNIKA: PRIKAZ DVAJU SLUČAJEVA

*T. Leniček, D. Tomas, H. Soljačić-Vraneš, Z. Kraljević, P. Klarić, M. Kos i M. Kos*

Primarni karcinoidi jajnika čine 5% svih teratoma jajnika. Najčešće se nalaze kao komponenta zrelog cističnog teratoma jajnika, a rjeđe kao komponenta mucinoznog cistadenoma. Najčešće se pojavljuju u peri- ili postmenopauzalnih žena sa simptomima tumora male zdjelice ili su slučajan klinički nalaz. Histološki se razlikuje četiri glavna tipa karcinoidnih tumora jajnika: inzularni, trabekularni, strumalni i mucinozni tip. Jedna trećina bolesnica s inzularnim tipom karcinoida ima simptome karcinoidnog sindroma. Strumalni karcinoid je rijetka varijanta teratoma jajnika koji se sastoji od različitog udjela tkiva štitnjače i tkiva karcinoidnog tumora. Ovdje se prikazuju dvije bolesnice s tumorima jajnika koji pokazuju karakterističnu građu primarnih strumalnih karcinoida.

Ključne riječi: *Jajnik; Strumalni karcinoid; Karcinoidni sindrom*

