

# MANAGEMENT OF THE DIFFICULT AIRWAY

Vesna Novak-Jankovič

Clinical Department of Anesthesiology and Intensive Therapy, University Medical Centre Ljubljana, Ljubljana, Slovenia

**SUMMARY** – Management of difficult airway is one of the most challenging tasks for anesthesiologists, and failure of securing it could have fatal consequences. We must be prepared to deal with problems in management of difficult airway at any time. Difficult intubation can either be anticipated or unanticipated. An anesthesiologist must be aware of the possibility of both situations to arise and preparations must be taken to deal with such cases and improve the safety of our patients. Practice guidelines are systematically developed recommendations that help anesthesiologists in the management of difficult airway.

**Key words:** *Difficult airway, management, unanticipated, anticipated*

## Introduction

The failure to maintain a patient airway is a source of serious concern for anesthesiologists. A difficult airway is defined as the clinical situation in which a conventionally trained anesthesiologist experiences difficulty with face mask ventilation and/or difficulty with tracheal intubation<sup>1</sup>. Difficult mask ventilation is defined as the inability of a trained anesthesiologist to maintain oxygen saturation >90%, using a face mask, 100% oxygen and positive pressure ventilation. Difficult intubation is defined as the need for more than three attempts for intubation of the trachea or more than 10 minutes to achieve it. The incidence of difficult mask ventilation is estimated to be 0.9%-5%, and the incidence of difficult intubation is 0.13%-13%<sup>2-7</sup>. The major complications associated with the difficult airway include death, hypoxic brain injury, cardiopulmonary arrest, unnecessary tracheotomy, airway

trauma including aspiration of gastric contents, and damage of soft tissues and teeth. In order to avoid this fatal outcome, several societies have developed guidelines for management of the difficult airway<sup>8-11</sup>.

## Prediction of Difficult Airway Management

Medical history and physical examination are important tools in prediction of the difficult airway. An airway physical examination should be performed prior to the initiation of anesthetic care in all patients. Focused medical history (previous anesthesia record or anesthesia document) may detect medical, surgical and anesthetic factors that may indicate the presence of a difficult airway<sup>1</sup>. Patients with congenital syndromes (Pierre-Robin, Treacher-Collins, Klippel-Feil, etc.) and acquired diseases (acromegaly, ankylosing spondylitis, tumors, burns, hematoma, cervicofacial injuries, Madelung's disease, etc.) are associated with the presence of a difficult airway<sup>12</sup>. An airway physical examination should be performed before anesthetic management to detect physical characteristics that may indicate the presence of a difficult airway (Table 1).

Correspondence to: *Prof. Vesna Novak-Jankovič, MD, PhD*, Clinical Department of Anesthesiology and Intensive Therapy, University Medical Centre Ljubljana, Zaloška 7, 1000 Ljubljana, Slovenia

E-mail: [vnovakjankovic@gmail.com](mailto:vnovakjankovic@gmail.com)

Received July 9, 2012, accepted August 23, 2012

Table 1. Components of the preoperative airway physical examination

Airway examination component	Findings that give cause for concern
Face inspection	Beard, size of nose, mouth and tongue, jaw protrusion, jewelry
Patency of nares	Masses inside nasal cavity, deviated nasal septum
Teeth	Relatively long upper incisors or canines, protruding teeth, lack of teeth, an edentulous state
Relation of maxillary and mandibular incisors during normal jaw closure	Maxillary incisors anterior to mandibular incisors
Relation of maxillary and mandibular incisors during voluntary protrusion of lower jaw	Inability to protrude the lower jaw and mandibular incisors beyond the upper incisors
Temporomandibular joint movement	Interincisor distance less than 3 cm
Visibility of uvula	Not visible
Shape of palate	Highly arched or very narrow
Compliance of mandibular space	Stiff, indurated, occupied by mass
Shape of neck	Thick and short (sternomental distance below 12 cm)
Voice	Presence of hoarse voice or stridor
Scars	Presence of signs of previous tracheostomy
Range of motion of head and neck	Patient cannot touch tip of chin to chest or cannot extend neck more than 35°
Assessment of submandibular space	Hypomental distance less than 3 cm Thyromental distance less than three ordinary finger breadths less than 6.5 cm
Assessment of body habitus	Pregnancy, obesity, snoring

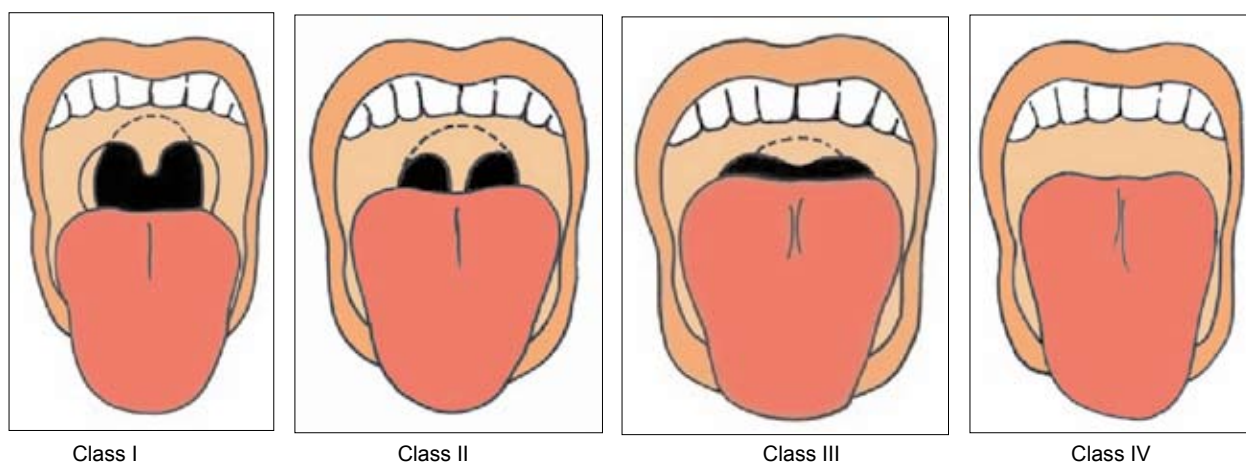


Fig. 1. Classification according to the modified Mallampati test.

Class I: visualization of the soft palate, fauces, uvula, anterior and posterior pillars.

Class II: visualization of the soft palate, fauces and uvula.

Class III: visualization of the soft palate and base of uvula.

Class IV: visualization of only hard palate.

### Specific Screening Test to Predict Difficult Intubation

There are a number of specific clinical assessments that have been developed to try to identify patients

who will prove difficult to intubate: Mallampati test (Fig. 1), thyromental distance (normal  $\geq 6.5$  cm), sternomental distance (normal  $\geq 12.5$  cm), protrusion of the mandible, and radiographic assessment<sup>13-15</sup>.

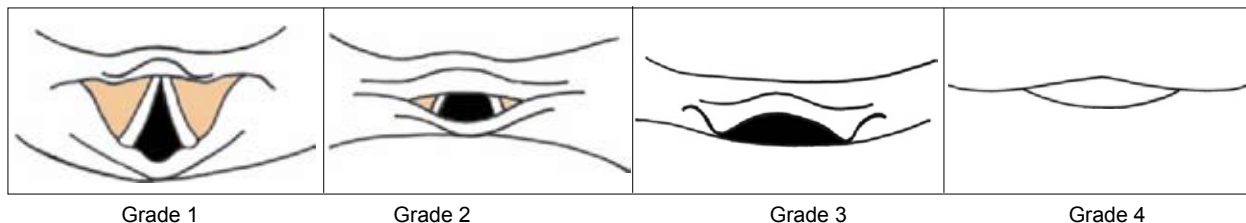


Fig. 2. Classification according to Cormack and Lehane during direct laryngoscopy.

Grade 1: visualization of the entire laryngeal aperture.

Grade 2: visualization of the posterior commissure of the laryngeal aperture only.

Grade 3: visualization of the epiglottis only.

Grade 4: visualization of the soft palate only.

Direct laryngoscopy visualization of the larynx according to Cormack and Lehane is illustrated in Figure 2<sup>16</sup>.

### Preparation for Anticipated Difficult Airway

Appropriate equipment must be immediately available on the portable storage unit (Fig. 3). This will include laryngoscopes with a selection of blades, a variety of endotracheal tubes, stylets, flexible bougies, oral and nasal airways, a cricothyroid puncture kit, reliable suction equipment, supraglottic ventilatory devices, video laryngoscopes, rigid optic laryngoscopes, and flexible fiberoptic bronchoscopes. Awake intubation under local anesthesia may be performed using fiberoptic flexible bronchoscope. Retrograde intubation is a technique for patients with cancerum oris.

### Management of Unanticipated Difficult Airway

The British Difficult Airway Society (DAS) has developed very simple algorithms that use only a few airway devices which are available in many settings<sup>17-19</sup>.

Our national guidelines are adopted and modified DAS guidelines (Fig. 4).

The anesthesiologist should inform the patient on the airway difficulty and notification cards which we use at University Medical Centre Ljubljana are very useful (Fig. 5).

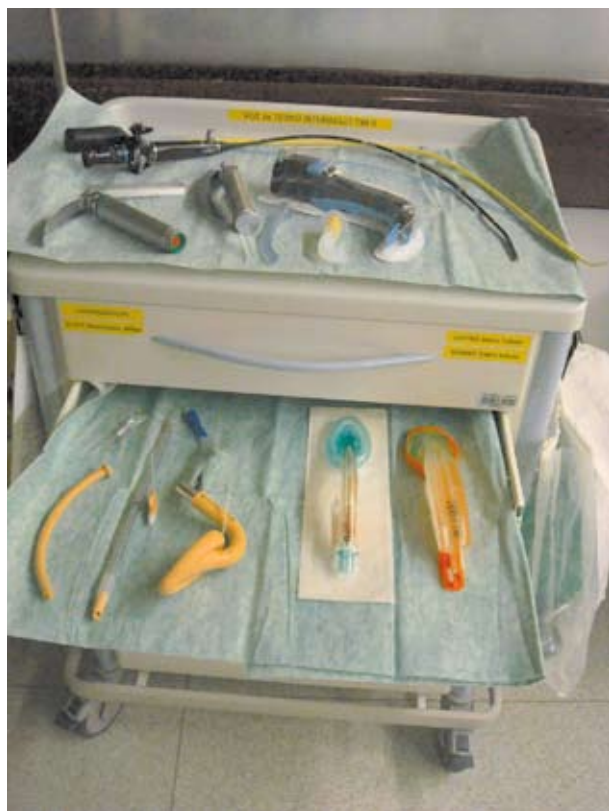

Fig. 3. Portable storage unit for difficult airway management at University Medical Centre Ljubljana.

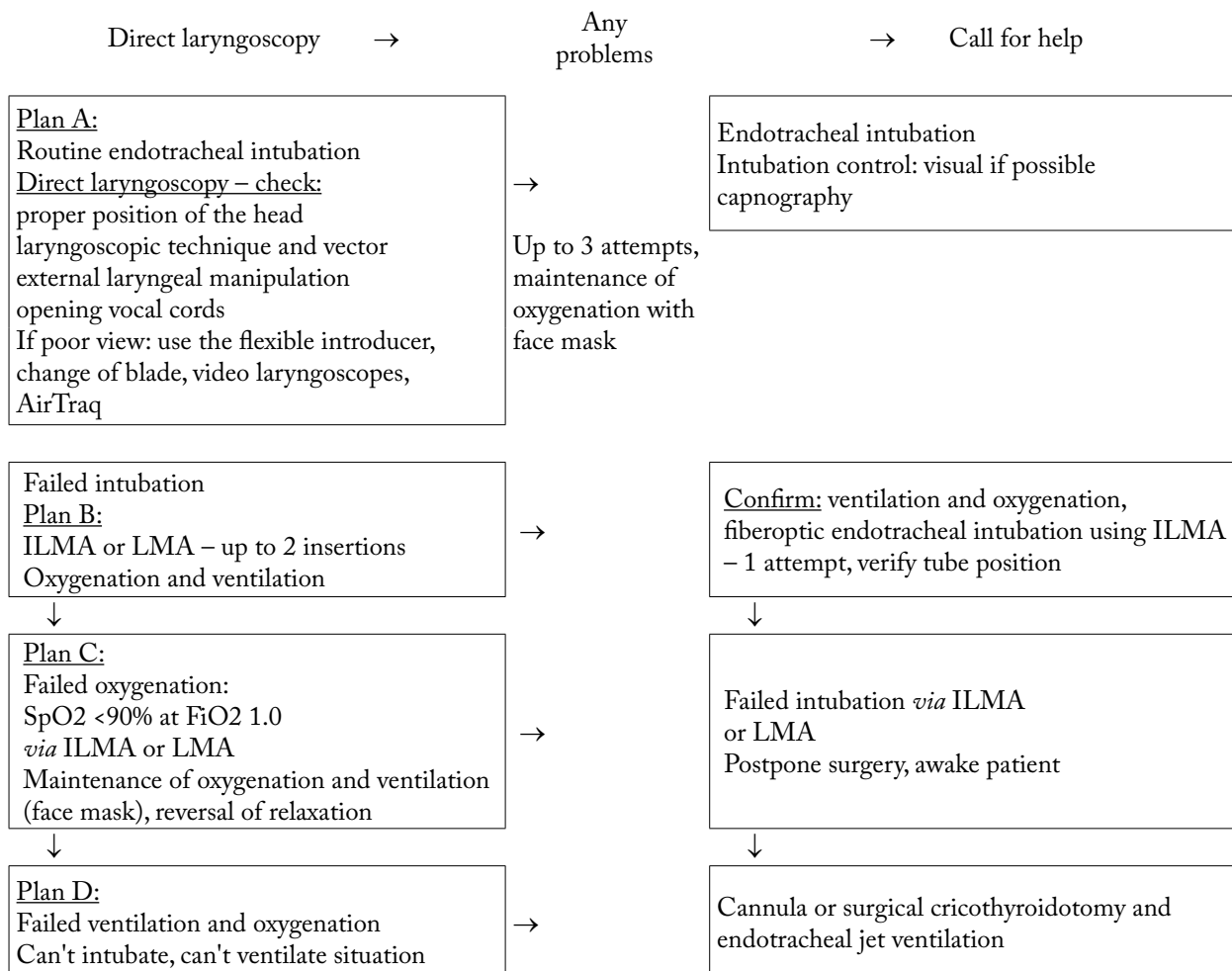


Fig. 4. Unanticipated difficult tracheal intubation during routine induction of anesthesia in adult patients.

## Conclusion

Difficult airway management is a major responsibility for the anesthesiologist. Identifying situations and patients at frequent risk of airway management problems is a key to optimal care. The use of guidelines is to facilitate the management of the difficult airway and to reduce the incidence of catastrophic outcomes.

## References

- American Society of Anesthesiology. Practice guidelines for management of the difficult airway. *Anesthesiology* 2003;98:1269-77.
- ROSE DK, COHEN MM. The airway: problems and predictions in 18,500 patients. *Can J Anesth* 1994;41:372-83.
- LANGERON O, MASSO E, HURAUX C, *et al.* Prediction of difficult mask ventilation. *Anesthesiology* 2000;92:1229-36.
- KHETERPAL S, HAN R, TREMPER KK, *et al.* Incidence and predictors of difficult and impossible mask ventilation. *Anesthesiology* 2006;105:885-91.
- DJABATEY EA, BARCLAY PM. Difficult and failed intubation in 3430 obstetric general anaesthetics. *Anaesthesia* 2009;64:1168-71.
- BARNARDO PD, JENKINS JG. Failed tracheal intubation in obstetrics: a 6-year review in a UK region. *Anaesthesia* 2000;55:690-4.
- RANDELL T. Prediction of difficult intubation. *Acta Anaesthesiol Scand* 1996;40:1016-23.
- HENDERSON JJ, POPAT MT, LATTO IP, *et al.* Difficult Airway Society guidelines for management of the unanticipated difficult intubation. *Anaesthesia* 2004;59:675-94.





**Kartica anestezioloških posebnosti (Anaesthesia Problem Card)**

Težave pri intubaciji (Intubation problems):

1. Glasniklita vidi (Vocal cords can be seen)
2. Spodnja stran grla je vidna (Posterior extremity of glottis can be seen)
3. Samo epiglota je vidna (Only epiglottis can be seen)
4. Epiglota ni vidna (Epiglottis cannot be seen)

Druge težave pri intubaciji, kot npr. revmatoidni artritis, tumor itd. (Other intubation problems eg. Rheumatoid arthritis, others):

Da (Yes)  Ne (No)  Opredelite (Specify):

All je bilo bolnika mogoče predihavati z masko? (Could the patient be ventilated with a mask?)

Da, brez težav (Yes, easily)  Da, s težavo (Yes, with difficulty)  Ne (No)

Kako so težave odpravili? Priporočila za bodoče intubacije (How the problem was solved; recommendations for future intubations):

Alergične reakcije (Drug adverse reaction, drug allergy):

1. Tovarniško/Generično ime (Commercial/generic name) \_\_\_\_\_
2. Tovarniško/Generično ime (Commercial/generic name) \_\_\_\_\_

Vrsta alergične reakcije (Adverse reaction type)

1. Blage, kožne izpuščaje (Light skin rash)
2. Srednje hude: pljučna, hemodinamska (Moderate: pulmonary, haemodynamic)
3. Hude: pljučna, hemodinamska (Severe: pulmonary, haemodynamic)

Kako so težave odpravili? Priporočila za bodoče anestezije (How the problem was solved; recommendations for future anaesthesia):

Druge bolezni, pomembne za anestezijo - maligna hipertenzija, presnovne bolezni, drugo (Other anaesthesia relevant disease, malignant hypertension, metabolic disease):

Da (Yes)  Ne (No) Opredelite (Specify):

\_\_\_\_\_

Anesteziolog (Anaesthesiologist) \_\_\_\_\_ Bolnišnica (Hospital) \_\_\_\_\_ Datum (Date) \_\_\_\_\_

Fig. 5. Slovenian Anesthesia Problem Card.

9. BOISSON-BERTRAND D, BOURGAIN JL, CAMBOULIVES J, *et al*. Intubation difficile. Societe francaise d'anesthesie et de reanimation. Expertise collective. Ann Fr Anesth Reanim 1996;15:207-14.
10. CROSBY ET, COOPER RM, DOUGLAS MJ, *et al*. The unanticipated difficult airway with recommendations for management. Can J Anesth 1998;45:757-76.
11. SIAARTI. Task Force on Difficult Airway Management. L'intubazione difficile e la difficoltà di controllo delle vie aeree nell'adulto. Minerva Anestesiologica 1998;64:361-71.
12. STOPAR T, NOVAK-JANKOVIC V, CASATI A. Four different airway-management strategies in patient with Launois-Bensaude syndrome or Madelung's disease undergoing surgical excision of neck lipomatosis with a complicated postoperative course. J Clin Anesth 2005;17:300-3.
13. SAMSOON GL, YOUNG JR. Difficult tracheal intubation: a retrospective study. Anaesthesia 1987;42:487-90.
14. EZRI T, WARTERS RD, SZMUK P, *et al*. The incidence of class zero airway and the impact of Mallampati score, age, sex and body mass on prediction of laryngoscopy grade. Anesth Analg 2001;93:1073-5.
15. KANAYA N, KAWANA S, WATANABE H, *et al*. The utility of three-dimensional computed tomography in unanticipated difficult endotracheal intubation. Anesth Analg 2000;91:752-4.
16. CORMACK RS, LEHANE J. Difficult tracheal intubation in obstetrics. Anaesthesia 1984;39:1105-11.
17. COMBES X, Le ROUX B, SUEN P, *et al*. Unanticipated difficult airway in anesthetized patients: prospective validation of a management algorithm. Anesthesiology 2004;100:1146-50.
18. BUDDE A, POTT L. Management of unanticipated difficult tracheal intubation: routine induction and rapid sequence induction of the non-obstetric patient. Special edition: Guidelines for management of emergencies in anaesthesia. Update Anaesth 2009;25:10-4.
19. HODZOVIC I, JANAKIRAMAN C, SUDHIR G, *et al*. Fiberoptic intubation through the laryngeal mask airway: effect of operator experience. Anaesthesia 2009;64:1066-71.

## Sažetak

## ZBRINJAVANJE OTEŽANOG DIŠNOG PUTA

*V. Novak-Janković*

Zbrinjavanje otežanog dišnog puta je jedan od najzahtjevnijih postupaka u anesteziologiji i neuspjeh pri tome može imati fatalne posljedice. Anesteziolog mora u svakom trenutku biti pripremljen za ovaj postupak. Teška intubacija može biti očekivana i neočekivana. Posjedovanje posebnih znanja i vještina u zbrinjavanju navedenih situacija je ključni čimbenik za sigurnost bolesnika. Na temelju iskustava i preporuka su nastale smjernice koje pomažu anesteziologu u zbrinjavanju otežanog dišnog puta.

Ključne riječi: *Otežani dišni put, zbrinjavanje, neočekivani, očekivani*