

Use of Mutaf Triangular Flap in a Case of Major Nasal Ala Substance Loss

Antonio Ascari-Raccagni¹, Adina Dondas¹, Nicola Di Meo², Giusto Trevisan²

¹Department of Dermatology, G.B. Morgagni-L. Pierantoni General Hospital, Forlì; ²Institute of Dermatology, University of Trieste, Trieste, Italy

Corresponding author:

Antonio Ascari-Raccagni, MD
Department of Dermatology
G.B. Morgagni-L. Pierantoni General Hospital
via Forlanini
I-34 47121 Forlì
Italy
ascrac@libero.it

SUMMARY Nasal ala, due to its characteristics, is a unique anatomical part of the body. Unfortunately, nasal ala often suffers traumas or is affected by cancers, the treatment of which can imply all-thickness amputation. In such cases, complex reconstruction is necessary to recreate both a satisfying cosmetic structure and to ensure free airflow. We present a clinical case of nasal ala major substance loss due to cancer, which was treated by use of the new Mutaf triangular flap.

KEY WORDS: Mutaf triangular flap, nasal ala, nasal sept

Received: April 21, 2012

Accepted: November 20, 2012

INTRODUCTION

The nasal ala, by definition, is a unique anatomical part of the body due to its characteristics: a structure made up of mucous membrane, fibrocartilage and skin; for its functional importance in allowing correct breathing but also for its convex and elongated shape positioned in the center of the face.

Unfortunately, the nasal ala often suffers traumas that may lead to major substance losses and cancers the radical removal of which results not only in the loss of the skin component but also of the fibrocartilage and mucus membrane, thus implying an all-thickness amputation.

In such cases, reconstruction is both fundamental and extremely complex from the technical point of view, since it is necessary to recreate a structure made

up of three tissue components, while making constantly sure that the patency of the areal entrance is free, avoiding the so-called "valve" mechanisms, but also guaranteeing a satisfying cosmetic result at such a delicate and essential site from the inter-relational point of view.

A clinical case is presented in which the nasal ala major substance loss was managed by using a new methodology called the Mutaf triangular flap.

METHODS

In the literature, there are articles that indicate and evaluate different reconstructive methods used in cases of nasal substance losses. In some cases, an



algorithm is taken into consideration, which allows, when planning surgery, to choose the most suitable reconstructive method according to the characteristics and site of the defect (1-3). Substance losses in which only the nasal ala skin area is involved can be reconstructed with a simple skin graft and at least partially with second instance healing (4). Some authors suggest a combination of second instance healing with a graft cartilage in cases of deeper and major substance losses (5,6).

In the reconstruction of nasal ala defects, the most flexible and easiest flap is a simple nasolabial flap, which does not only allow for reconstruction of skin defects, but can also be used in full-thickness defects of nasal ala by rotating the distal part of the flap and making it the flooring of the nasal cavity; later on, it can be completed by a minor graft cartilage to replace the ala cartilage. In some selected cases, the nasolabial flap can be combined with a minor hinge flap in order to reconstruct the inner side of the nasal cavity (7).

In case of minor full-thickness substance loss, the nasal defect can be repaired by employing a simple chondrocutaneous graft taken from the auricular pavilion.

In defects involving full-thickness of the whole nasal ala, only a forehead flap might allow a satisfying and complete reconstruction, even though during surgery planning the need of further surgical interventions for flap autonomization and its final adjustment have to be taken into consideration (8,9).

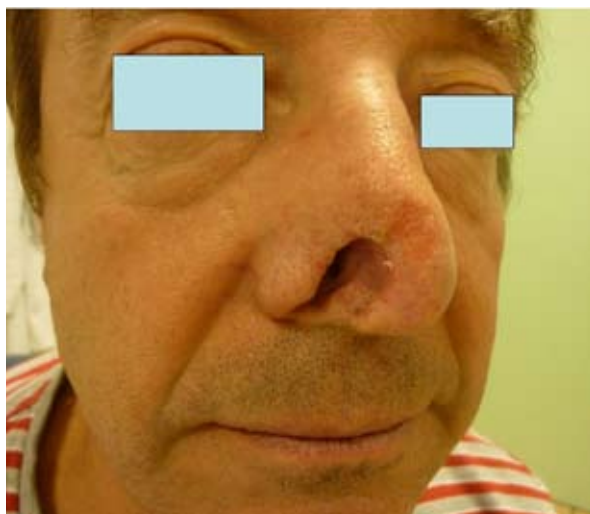

Figure 1. The major full-thickness substance loss at the level of the right nasal ala; note its almost triangular shape with upper apex and lower base, very close to the tip of the nose.

A triangular flap used in the repair of a nasal ala congenital defect has been recently illustrated.

It is apparently quite a simple procedure, able to correct some full-thickness ala defects that are quite extensive and close to the nose tip, and can be included in an isosceles triangle with lower base; we believe that such a procedure could be used in other cases, not just those of congenital defects, as suggesting by the article title (10).

This procedure called Mutaf triangular flap permits reconstruction by using skin taken exclusively from the nasal pyramid, therefore quite similar to the one to be replaced and mobilized avoiding removal of any healthy skin from the nearby nose areas.

CASE REPORT

A 60-year-old patient was referred from another dermatological department after having undergone radical surgery for a squamous cell carcinoma of the right nasal ala. The substance loss was major, full-thickness triangular in shape, with upper apex and lower base, very close to the tip of the nose (Fig. 1). We decided to use the Mutaf triangular flap in the reconstruction of the defect.

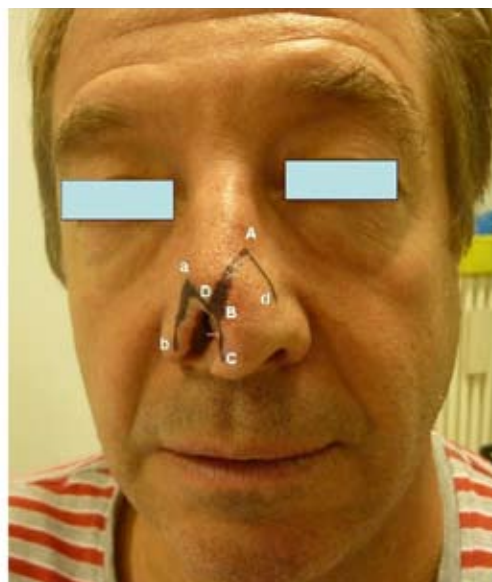

Figure 2. During surgery planning, we included the full-thickness defect in a triangle with upper apex and lower base (abC), coinciding with the nasal ala border and designed a second triangle with upper apex and lower base (ABd), located at about half way the length of the side of the first triangle (where BC must be almost the same as bC). In the moving dynamics of our Mutaf triangular flap, A will be rotated in correspondence to a, B transferred onto b, and D moved onto d.

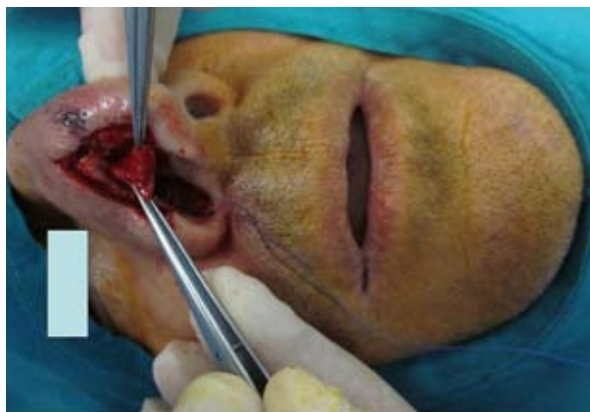

Figure 3. The right cavity nasal flooring was obtained with a small triangular flap with upper apex taken from the nasal sept mucous membrane and rotated onto the upper peduncle so as to keep the mucous membrane side towards the nasal cavity.

During surgery planning, we decided to include the substance loss in a triangle with upper apex and lower base and designed a second triangle with upper apex and lower base located at almost half way of the length of the side the first triangle, with BC almost the same as bC (Fig. 2). In the moving dynamics of our Mutaf triangular flap, A will be rotated in correspondence to a, B will be transferred onto b, and D moved onto d.

After local anesthesia with lidocaine 2% solution diluted and buffered with sodium bicarbonate, we started the procedure converting the defect to be reconstructed in a triangle with lower base as designed during the planning.

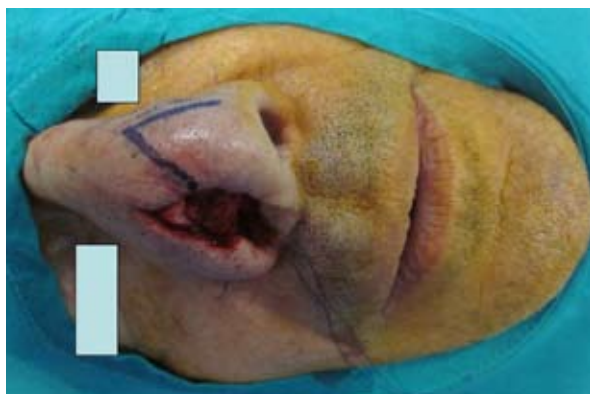

Figure 4. The mucous flap was sutured into its final site using reabsorbing sutures and successfully reconstructing the inner side of the nasal cavity. The solution of continuity at the nasal sept level was partially sutured and partially left to self-heal later on. The design of the Mutaf triangular flap still to be autonomized can be appreciated.

Then we moved to the reconstruction of the right cavity nasal flooring with a small triangular flap with upper apex taken from the mucous membrane of the nasal sept and rotated on the upper peduncle in such a fashion as to keep the mucus side towards the nasal cavity (Fig. 3). The mucous flap was sutured into its final position by using reabsorbing sutures (Safil 4.0) and successfully reconstructing the inner side of the nasal cavity, the solution of continuity at the nasal sept level was partially sutured and partially left to self-heal (Fig. 4). Then we incised the second planned triangle borders and broadly undermined the nearby skin, guaranteeing the mobility of the skin to be transferred (Fig. 5).

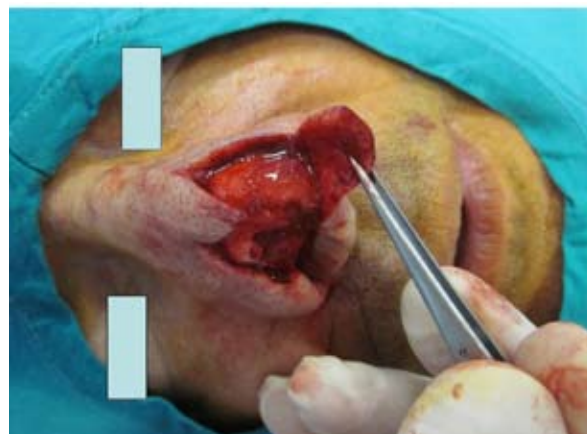

Figure 5. The second designed and autonomized triangle with the ample surrounding skin undermining, which allows mobilization of our flap.

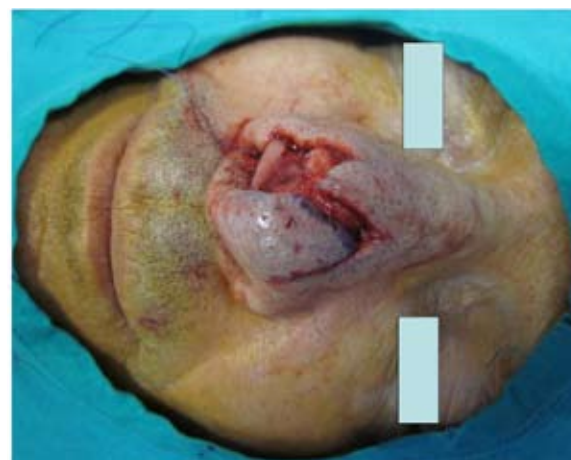

Figure 6. The thin layer of cartilage taken at the level of the quadrangular cartilage sept, sutured in its final site to guarantee a good structural support to the nasal ala.

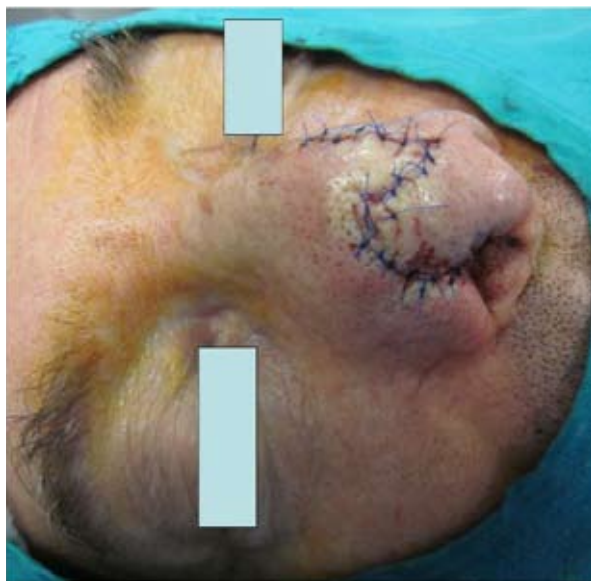


Figure 7. The Mutaf triangular flap sutured into its final site to obtain a satisfying reconstruction of the major right nasal ala substance loss.

After having performed this ample undermining, we took a thin layer of cartilage at the level of the quadrangular lamina of the sept and sutured it in its final site with reabsorbing sutures (Safil 4.0), ensuring good structural support to the nasal ala (Fig. 6). Our Mutaf triangular flap was then positioned and sutured with non-reabsorbing sutures (Premilene 5.0) in its final site obtaining a satisfactory reconstruction of the existent right nasal ala major substance loss (Fig. 7). Although postoperative infections affected the cosmetic result of the surgical scars, nonetheless, in our opinion, quite a satisfactory final outcome was achieved (Fig. 8).

DISCUSSION

At the time of observation, our patient presented a major loss, representing quite a difficult reconstruction considering that in such cases there is no perfect reconstructive methodology. Therefore, we had to take into consideration several techniques, for instance, a wedge chondrocutaneous graft taken from the auricular pavilion, easy and simple to perform but quite poor in its cosmetic outcome and often not very viable.

We also considered a nasolabial flap in which the distal part of the flap is rotated in order to reconstruct the mucous membrane, eventually followed by a graft cartilage to support the nasal ala, in our opinion not a very suitable method in case of substance loss so close to the tip of the nose.

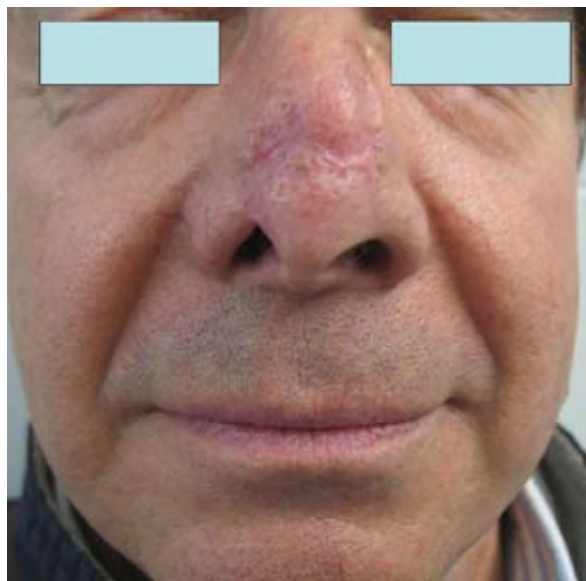

Figure 8. The cosmetic outcome was quite successful; however, postoperative infections affected the final cosmetic result of the surgical scars.

Among others, we also considered a frontal flap, no doubt more suitable in such a challenging reconstruction, but very complex and to be followed by a second surgery for the flap autonomization and with the result of a major scar in the middle of the forehead.

After all these considerations, we came to the decision that the Mutaf triangular flap was the best option to repair the surgical oncologic substance loss; it seemed in our opinion a simple, easy procedure to be performed in local anesthesia and free from scars to the nearby tissues of the nasal pyramid.

CONCLUSIONS

The Mutaf triangular flap is a technique that can be used in local anesthesia, easy to learn, simple to apply with a major advantage of not leaving scars to the nearby tissues of the nasal pyramid. It can be used not only in cases of congenital defects, but is also very suitable in reconstructions of ala substance losses located near the tip of the nose.

References

1. Romani J, Yébenes M. Repair of surgical defects of the nasal pyramid. *Actas Dermosifiliogr* 2007;98:302-11.
2. Parrett BM, Pribaz JJ. An algorithm for treatment of nasal defects. *Clin Plast Surg* 2009;36:407-20.
3. Guo L, Pribaz JR, Pribaz JJ. Nasal reconstruction with local flaps: a simple algorithm for mana-

- gement of small defects. *Plast Reconstr Surg* 2008;122:130e-139e.
4. McCluskey PD, Constantine FC, Thornton JF. Lower third nasal reconstruction: when is skin grafting an appropriate option? *Plast Reconstr Surg* 2009;124:826-35.
 5. van der Eerden PA, Verdam FJ, Dennis SC, Vuyk H. Free cartilage grafts and healing by secondary intention: a viable reconstructive combination after excision of nonmelanoma skin cancer in the nasal alar region. *Arch Facial Plast Surg* 2009;11:18-23.
 6. Ewanowski CD, Cook J. Using cartilage and skin grafts concurrently: an alternate route to repair. *Dermatol Surg* 2009;35:1809-17.
 7. Plotner AN, Gloster HM Jr. Combined hinge and nasolabial transposition flap for repair of a full-thickness nasal alar defect. *Dermatol Surg* 2011;37:371-4.
 8. Menick FJ. A 10-year experience in nasal reconstruction with the three-stage forehead flap. *Plast Reconstr Surg* 2002;109:1839-55; discussion 1856-61.
 9. Brodland DG. Paramedian forehead flap reconstruction for nasal defects. *Dermatol Surg* 2005;31(8 Pt 2):1046-52.
 10. Mutaf M, Günal E. A new technique for reconstruction of a congenital isolated alar defect. *J Craniofac Surg* 2010;2:503-5.

