

Downloaded from bmj.com on 7 September 2007

BMJ

An undiagnosed bicuspid aortic valve can result in severe left ventricular failure

Sagar Saha, Rachel Bastiaenen, Martin Hayward and Jean R McEwan

BMJ 2007;334:420-422
doi:10.1136/bmj.39065.624815.80

Updated information and services can be found at:
<http://bmj.com/cgi/content/full/334/7590/420>

These include:

References

This article cites 12 articles, 4 of which can be accessed free at:
<http://bmj.com/cgi/content/full/334/7590/420#BIBL>

Rapid responses

You can respond to this article at:
<http://bmj.com/cgi/eletter-submit/334/7590/420>

Email alerting service

Receive free email alerts when new articles cite this article - sign up in the box at the top left of the article

Topic collections

Articles on similar topics can be found in the following collections

[Other Cardiovascular Medicine](#) (2094 articles)
[Other Pediatrics](#) (1850 articles)

Notes

To order reprints follow the "Request Permissions" link in the navigation box

To subscribe to *BMJ* go to:
<http://resources.bmj.com/bmj/subscribers>

LESSON OF THE WEEK

An undiagnosed bicuspid aortic valve can result in severe left ventricular failure

Sagar Saha, Rachel Bastiaenen, Martin Hayward, Jean R McEwan

Heart Hospital, London W1G 8PH
Correspondence to: J R McEwan
j.mcewan@ucl.ac.uk

BMJ 2007;334:420-2
doi: 10.1136/bmj.39065.624815.80

Asymptomatic bicuspid aortic valves diagnosed in childhood need regular monitoring to allow early surgical intervention and prevention of left ventricular failure

Bicuspid aortic valve occurs in 0.8-2% of European and North American populations.^{1 2} It is the most common reason for a predisposition to severe aortic regurgitation or stenosis in middle life, but patients are asymptomatic until late in the disease. Failure to present until clinical symptoms develop—either because the murmur is not detected or is lost to follow-up—can have important consequences. Early detection and continued surveillance are crucial to allow early intervention and preservation of cardiac function. We describe two patients with heart murmurs diagnosed in childhood who were lost to follow-up. Both presented as adults with heart failure and complications of bicuspid aortic valves. One developed aortic stenosis, the other aortic incompetence. Both needed urgent surgery. Many people in the general population with bicuspid aortic valves have never been diagnosed or have been reassured in childhood and are no longer under review.

Case 1

A 48 year old builder presented with shortness of breath at rest and mild icterus. He had been prescribed antibiotics for a presumed chest infection when he visited his general practitioner six months earlier. A heart murmur was noted during that consultation but not followed up. He later recalled that as a child he underwent annual

review for a heart murmur. At age 16 he was reassured and discharged from clinic.

On clinical examination the patient had severe aortic stenosis with a slow rising pulse, narrow pulse pressure, and an ejection systolic murmur radiating to the carotids. He had left ventricular failure.

The transthoracic echocardiogram showed a bicuspid aortic valve with severe stenosis (peak pressure gradient 70 mm Hg). The left ventricle was severely dilated and impaired.

Early admission for valve replacement was arranged but he developed hepatorenal failure, which necessitated emergency surgery. The excised bicuspid aortic valve was heavily calcified with a pinhole orifice. It was replaced with a metal prosthesis and the mildly dilated aorta was supported by a pericardial wrap. Renal and liver function improved after the operation. The left ventricle remains dilated and impaired.

Case 2

A 46 year old postman was admitted with increasing shortness of breath on minimal exertion (New York Heart Association functional class III). In early childhood, he had been diagnosed with a heart murmur and followed up in a tertiary centre. At age 10 he was either discharged or stopped attending appointments.

Clinically he had severe aortic regurgitation with a collapsing pulse, positive Corrigan's sign, a loud early diastolic murmur, and additional diastolic deep rumble (Austin Flint murmur). He had evidence of cardiac failure. Inflammatory markers were normal and blood cultures were sterile.

His electrocardiogram showed left ventricular hypertrophy with widespread fixed T wave inversion (fig 1). The transthoracic echocardiogram confirmed a calcified bicuspid aortic valve with an eccentric jet of severe aortic regurgitation directed along the anterior mitral valve leaflet. The ascending aorta was dilated. He had severe left ventricular dilatation and impairment (fig 2).

He responded to initial treatment with diuretics. Angiography showed normal coronary arteries. He underwent urgent aortic valve replacement during that admission. The ascending aorta measured 5 cm intraoperatively and was therefore also replaced.

Discussion

The normal aortic valve has three almost equally sized leaflets. A bicuspid aortic valve is the result of abnormal aortic cusp formation during valvulogenesis. Although bicuspid aortic valves can function normally, the valve leaflets are subject to increased haemodynamic stress because of their shape and can therefore degenerate,

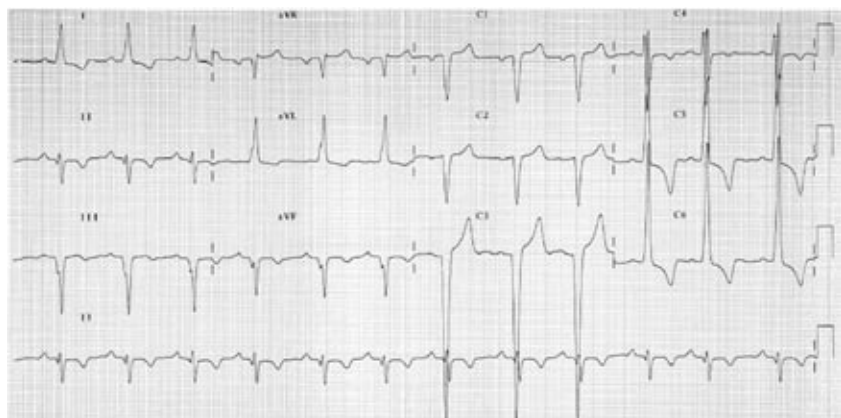


Fig 1 | Electrocardiogram showing left ventricular hypertrophy with widespread fixed T wave inversion

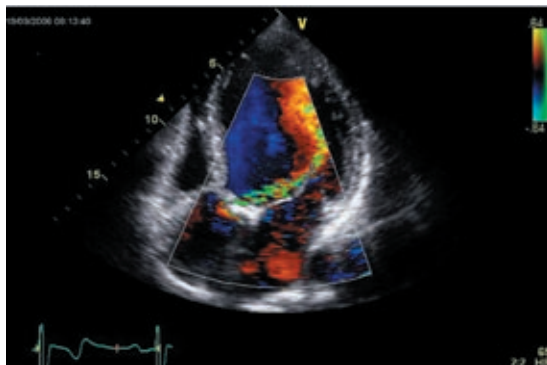


Fig 2 | Transthoracic echocardiogram showing a calcified bicuspid aortic valve with an eccentric jet of moderate to severe aortic regurgitation directed along the anterior mitral valve leaflet. Severe left ventricular dilatation is present

calcify, and stenose or become incompetent. Bicuspid aortic valves also predispose the patient to endocarditis and are strongly associated with aneurysms and dissection of the aorta.^{3,4} Bicuspid aortic valves have been suggested to be associated with greater mortality and morbidity than all other congenital heart defects combined.⁵

The proposed 0.8-2% prevalence of bicuspid aortic valves in the general UK population would equate to 16-40 patients in an average general practice population of 2000 patients. Bicuspid aortic valves are present in 54% of adults with valvular aortic stenosis who have aortic valve replacement and are the main reason for aortic valve replacement up to the eighth decade of life.⁶ As the incidence of rheumatic heart disease falls, a greater proportion of patients who have aortic valve replacement will have bicuspid aortic valves. By their second decade most patients with this condition have evidence of valvular calcification. The pressure gradient across a stenotic bicuspid aortic valve increases by 18 mm Hg each decade and even more rapidly if the cusps are asymmetric in size or in the anteroposterior location.⁷

Bicuspid aortic valves present as aortic regurgitation in 66% of cases.¹ Patients with such regurgitation need surgery at an earlier age than those with aortic stenosis.^{4,8} This may reflect the association with coarctation of the aorta and the complication of infective endocarditis.⁹

Clinical diagnosis of bicuspid aortic valves by auscultation of an aortic ejection click is beyond the skill of most non-specialists, but often an ejection systolic murmur is present and easily heard. Diagnosis is most simply confirmed with cross sectional and Doppler echocardiography. Transthoracic echocardiography has a sensitivity of 78% and specificity of 96% for the identification of a bicuspid aortic valve (though the underlying pathology may be obscured when severe stenosis, cuspal fusion, or a prominent raphe is present). Transoesophageal echocardiography may be better at identifying bicuspid aortic valves,¹⁰ but it is not usually carried out for purely diagnostic purposes.

Because transthoracic echocardiography was not widely available until 15 years ago, and general practitioners have had access only in recent years, many

patients have had no definitive diagnosis of their childhood murmur. A further population has defaulted or been lost to follow-up. Women may be more likely than men to be identified as the heart is usually examined at the antenatal clinic.

Once the diagnosis is made, the patient needs follow-up with transthoracic echocardiography three to five yearly because aortic valve disease progresses inexorably. When a gradient of 20 mm Hg or more develops or when greater than mild aortic regurgitation is noted, annual review should be offered until symptoms or the degree of dysfunction indicate the need for surgery.¹¹

No drugs have been found to reduce the progression of stenosis, though trials of statins are under way.¹² Antibiotic prophylaxis for dental work is advised by the European and US cardiac societies.^{11,13} Screening of first degree relatives of patients with a bicuspid valve is also advocated because of the high degree of familial association.¹⁴

Our cases highlight the potential complications of a bicuspid valve, which could have been prevented by regular monitoring and earlier surgery. Avoiding urgent and emergency surgery has advantages in terms of surgical mortality (perioperative mortality for first time aortic valve replacement in the United Kingdom: emergency surgery 12%; urgent 5%; elective 1.9%; personal communication, Bruce Keogh, Society of Cardiothoracic Surgeons and AD Cunningham, Central Cardiac Audit Database) and the longer term effects of ventricular impairment. Bicuspid valves are present in many people who were reassured in early life or lost to follow-up and in many "healthy" middle aged men whose hearts have never been examined. These patients could be identified by auscultation and echocardiography and referred to cardiologists at an early stage. This approach would increase demand for echocardiography, and population screening would have wider implications.

Contributors: SS and RB wrote the initial draft and MH and JRM revised it. JRM is guarantor. The authors all cared for these patients and conceived the idea of the report.

Funding: None.

Competing interests: None declared.

- Nistri S, Basso C, Marzari C, Mormino P, Thiene G. Frequency of bicuspid aortic valve in young male conscripts by echocardiogram. *Am J Cardiol* 2005;96:718-21.
- Roberts WC. The congenitally bicuspid aortic valve. A study of 85 autopsy cases. *Am J Cardiol* 1970;26:72-83.
- Fedak PW, David TE, Borger M, Verma S, Butany J, Weisel RD. Bicuspid aortic valve disease: recent insights in pathophysiology and treatment. *Expert Rev Cardiovasc Ther* 2005;3:295-308.
- Olson LJ, Subramanian R, Edwards WD. Surgical pathology of pure aortic insufficiency: a study of 225 cases. *Mayo Clinic Proc* 1984;59:835-41.
- Ward C. Clinical significance of the bicuspid aortic valve. *Heart* 2000;83:81-5.
- Roberts WC, Ko JM. Frequency by decades of unicuspid, bicuspid, and tricuspid aortic valves in adults having isolated aortic valve replacement for aortic stenosis, with or without associated aortic regurgitation. *Circulation* 2005;111:920-5.
- Beppu S, Suzuki S, Matsuda H, Ohmori F, Nagata S, Miyatake K. Rapidity of progression of aortic stenosis in patients with congenital bicuspid aortic valves. *Am J Cardiol* 1993;71:322-7.
- Subramanian R, Olson LJ, Edwards WD. Surgical pathology of pure aortic stenosis: a study of 374 cases. *Mayo Clin Proc* 1984;59:683-90.

- 9 Lamas CC, Eykyn SJ. Bicuspid aortic valve—a silent danger: analysis of 50 cases of infective endocarditis. *Clin Infect Dis* 2000;30:336-41.
- 10 Espinal M, Fuisz AR, Nanda NC, Aaluri SR, Mukhtar O, Sekar PC. Sensitivity and specificity of transesophageal echocardiography for determination of aortic valve morphology. *Am Heart J* 2000;139:1071-6.
- 11 Bonow RO, Carabello BA, Kanu C, de Leon AC Jr, Faxon DP, Freed MD, et al. ACC/AHA 2006 guidelines for the management of patients with valvular heart disease: a report of the American College of Cardiology/American Heart Association task force on practice guidelines (writing committee to revise the 1998 guidelines for the management of patients with valvular heart disease): developed in collaboration with the Society of Cardiovascular Anesthesiologists: endorsed by the Society for Cardiovascular Angiography and Interventions and the Society of Thoracic Surgeons. *Circulation* 2006;114:e84-231.
- 12 Newby DE, Cowell SJ, Boon NA. Emerging medical treatments for aortic stenosis: statins, angiotensin converting enzyme inhibitors, or both? *Heart* 2006;92:729-34.
- 13 Horstkotte D, Follath F, Gutschik E, Lengyel M, Oto A, Pavie A, et al. Guidelines on prevention, diagnosis and treatment of infective endocarditis executive summary; the task force on infective endocarditis of the European Society of Cardiology. *Eur Heart J* 2004;25:267-76.
- 14 Huntington K, Hunter AG, Chan KL. A prospective study to assess the frequency of familial clustering of congenital bicuspid aortic valve. *J Am Coll Cardiol* 1997;30:1809-12.

Accepted: 11 December 2006

BMJ UPDATES

Hypochondriasis is treatable

Research question

What are the comparative effects of paroxetine and cognitive behaviour therapy in treating severe hypochondriasis?

Answer

Paroxetine probably works as well as cognitive therapy but causes more side effects

Why did the authors do the study?

Hypochondriasis is a common mental illness with a reputation for being hard to treat. There's some evidence that cognitive behaviour therapy improves symptoms, but the evidence for antidepressants is much weaker. There are no high quality head to head trials comparing the two.

What did they do?

They recruited 112 Dutch adults to a randomised controlled trial comparing cognitive behaviour therapy, the selective serotonin reuptake inhibitor paroxetine, and a placebo. The comparison between paroxetine (up to 60 mg a day) and the placebo was double blind, and the main analyses were intention to treat. The trial lasted 16 weeks.

All the participants had severe symptoms of hypochondriasis, and three quarters had other mood or anxiety disorders. One in five (21/112) continued to take benzodiazepines during the trial.

The authors assessed participants before and after treatment using the Whitely index, a standard instrument for measuring the core symptoms of hypochondriasis. They used other standard instruments to measure changes in comorbid mood and anxiety symptoms.

What did they find?

All the groups improved significantly during the trial. There were no significant differences between the cognitive behaviour therapy and the paroxetine group on any outcome measure, including change in the Whitely index

score. In a pooled analysis of data from both treatment groups, active treatment worked better than placebo. The effect sizes on the Whitely index were 0.44 (modest) for cognitive behaviour therapy versus placebo, and 0.4 (slightly more modest) for paroxetine versus placebo.

Forty five per cent of those treated with cognitive behaviour therapy responded to treatment (a change of ≥ 1 standard deviation in Whitely index score), as did 30% of those who took paroxetine and 14% of those who took a placebo. In this analysis, cognitive therapy looked significantly better than placebo ($P=0.004$), but paroxetine did not ($P=0.17$). Again, the two active treatments did not differ significantly from each other.

The commonest side effects that were reported more often by the paroxetine group than the placebo group were fatigue (39% v 29%, $P=0.02$) and sexual dysfunction, including anorgasmia, (32% v 9%, $P=0.01$).

Thirty of the 112 participants dropped out of their assigned treatment. Participants were equally likely to drop out of all three groups.

What does it mean?

This small trial confirms that up to four months of cognitive behaviour therapy helps people with chronic hypochondriasis, improving their core symptoms as well as comorbid symptoms of depression and anxiety. Paroxetine probably does too, although the results for this treatment were less robust and seemed to depend more on patients completing their treatment. The authors don't report a power calculation, so it's hard to know whether they could have missed a clinically important difference between cognitive behaviour therapy and paroxetine. In any event, paroxetine caused more side effects.

Greeven et al. Cognitive behavior therapy and paroxetine in the treatment of hypochondriasis: a randomized controlled trial. *American Journal of Psychiatry* 2007;164:91-9

This summarises a paper that has been selected by [bmjupdates](http://bmjupdates.com). To register for [bmjupdates](http://bmjupdates.com) (free email about high quality new papers in your favourite subjects) go to <http://bmjupdates.com/>